YALE COLLEGE LIBRARY

SIGILL: COL: YALEN: NOV: PORT: NOV: ANGL:

LUX ET VERITAS

אורים
תמים

Presented by
Mr. Geo. D. Miller
1868.

TRANSFERRED TO
YALE MEDICAL LIBRARY

$\frac{7=c}{nt_y}$

Digitized by the Internet Archive
in 2012 with funding from
Open Knowledge Commons and Yale University, Cushing/Whitney Medical Library

http://www.archive.org/details/treatiseondi00lawr

A TREATISE

ON THE

DISEASES OF THE EYE.

BY

W. LAWRENCE, F.R.S.,

SURGEON EXTRAORDINARY TO THE QUEEN; SURGEON TO ST. BARTHOLOMEW'S HOSPITAL AND LECTURER ON SURGERY AT THAT HOSPITAL; SURGEON TO BETHLEM AND BRIDEWELL HOSPITALS; AND LATE SURGEON TO THE LONDON OPHTHALMIC INFIRMARY.

A NEW EDITION.

EDITED, WITH NUMEROUS ADDITIONS, AND

ONE HUNDRED AND SEVENTY-SIX ILLUSTRATIONS,

BY ISAAC HAYS, M.D.,

SURGEON TO WILLS' HOSPITAL; PHYSICIAN TO THE PHILADELPHIA ORPHAN ASYLUM; MEMBER OF THE AMERICAN PHILOSOPHICAL SOCIETY; FELLOW OF THE COLLEGE OF PHYSICIANS OF PHILADELPHIA, ETC. ETC.

PHILADELPHIA:
LEA AND BLANCHARD.
1847.

Entered, according to the Act of Congress, in the year 1847, by
LEA AND BLANCHARD,
in the Clerk's Office of the District Court of the United States in and for the Eastern District of Pennsylvania.

RE46
847e

PHILADELPHIA:
T. K. AND P. G. COLLINS,
PRINTERS.

ADVERTISEMENT

TO THE

AMERICAN EDITION.

THE early call for a new edition of this work, confirms the opinion expressed by the editor of its great value, and has stimulated him to renewed exertions to increase its usefulness to practitioners, by incorporating in it the recent improvements in Ophthalmic Practice. In availing himself, as he has freely done, of the observations and discoveries of his fellow-laborers in the same field, the editor has endeavored to do so with entire fairness, always awarding to others what justly belongs to them. Among the additions which have been made, may be noticed,—the descriptions of several affections not treated of in the original,—an account of the catoptric examination of the eye, and of its employment as a means of diagnosis,—one hundred and seventy-six illustrations, some of them from original drawings,—and a very full index. There have also been introduced in the several chapters on the more important diseases, the results of the editor's experience in regard to their treatment, derived from more than a quarter of a century's devotion to the subject, during all of which period he has been attached to some public institution for the treatment of diseases of the eye.

The additions are inclosed in brackets.

Philadelphia, March, 1847.

ADVERTISEMENT

TO

THE FIRST EDITION.

The basis of the following Treatise consists of the Lectures on the Anatomy, Physiology, and Diseases of the Eye, which I delivered at the London Ophthalmic Infirmary. The subjects are now considered in greater detail; the opinions and experience of others are quoted and examined; and cases are introduced, for practical illustration, wherever it could be done with advantage.

To have treated of the Anatomy and Physiology of the Eye at full length, would have been inconsistent with the limits and objects of this work. The short account of those subjects given in the lectures has been retained, merely for the purpose of introduction and explanation, in reference to the pathological and practical part of the Treatise.

W. LAWRENCE.

Whitehall Place, June 29, 1833.

ADVERTISEMENT

TO

THE SECOND EDITION.

This Edition has been committed to press after a careful revisal of the whole work. The arrangement has been altered in many respects, so as to make it more methodical, and thus to facilitate reference. Much additional matter has been introduced throughout; a larger and fuller page having been adopted, that the bulk of the volume might not be inconveniently increased. The subject of squinting and the new operation for its removal have been fully considered.

W. L.

Whitehall Place, November, 1840.

CONTENTS.

	PAGE
Introduction	xxiii.
General view of the subject	xxiv.
Mode of study	ib.
History	xxvii.
Anatomy of the eyeball	49
Form and composition of the globe	ib.
Sclerotica	50
Cornea	52
Vessels of the cornea	54
Nerves of the cornea	55
Choroid coat	ib.
Pigmentum	56
Blood-vessels of the choroid	57
Corpus ciliare	58
[Annulus albidus]	59
Iris	ib.
Blood-vessels of the iris	61
Nerves	ib.
Color	62
Muscularity	63
Membrana pupillaris	65
Arachnoid coat of the eye	66
Retina, and optic nerve	67
Membrane of Jacob	68
Connections of the coats	69
Ciliary ligament	70
Vitreous humor	ib.
Zonula ciliaris	71
Crystalline lens	ib.
Aqua Morgagni	72
Capsule of the lens	73
Aqueous humor	ib.
Membrane of the aqueous humor	74
Physiology of the eyeball	ib.
Light	ib.
Its reflection and refraction	75
Action of the transparent media of the eye on light	75
Movements of the iris, and consequent changes in the state of the pupil	79
Independent and associated actions of the iris	ib.
Muscularity of the iris	82
Use of the pigmentum	86
Situation of the impression on the retina	87
Its size	ib.
Inversion of the image on the retina	88
Single vision with two impressions	ib.
Course of the fibres in the optic nerves and the chiasma	89
[The eye as a catoptric instrument]	90
Anatomy of the appendages of the eye	91
The muscles of the globe	ib.
[Anatomical relations]	92
[Ocular fasciæ]	93
Nerves	95
Other contents of the orbit; periorbita	96
Eyebrow	ib.
Eyelids; their muscles	97
Component tissues of the eyelids	100
Tarsi; sebaceous glands	ib.
Cellular substance of the lids	101
Ciliary margins	ib.
Cilia; canthi	ib.
Conjunctiva	102
C. palpebralis	103
C. scleroticæ; c. corneæ	ib.
Lachrymal organs; gland	105
Puncta; sac; nasal duct	ib.
Caruncula lachrymalis	106
Semilunar fold of the conjunctiva	ib.

CHAPTER I.

PATHOLOGY OF THE EYE—INFLAMMATION—CLASSIFICATION OF OPHTHALMIC DISEASES.

SECTION I.

Pathology of the eye	106

SECTION II.

Inflammation	108
Varieties of inflammation; acute and chronic	110
Various effects	112
Common and specific	ib.
Varieties from difference of texture	113
Other modifications	ib.

SECTION III.

Arrangement of the subject	114

CHAPTER II.

AFFECTIONS OF THE EYELIDS.

SECTION I.

PAGE
Injuries 114
Wounds of the eyebrows and eyelids . . . . ib.
Poisoned wounds . . . 116
Malignant pustule . . . ib.
Scalds and burns . . . ib.
Amaurosis from wounds of the eyebrow . . . . ib.
Ecchymosis of the eyelids . . 122

SECTION II.

Inflammation of the eyelids and their consequences . . . 123
Inflammation of the cellular texture; abscess . . . . ib.
Erysipelatous inflammation of the lids 124
[Carbuncle of the eyelids] . . ib.
Œdema 125
Emphysema . . . ib.
Ophthalmia tarsi . . . ib.
Catarrhal inflammation . . ib.
Lippitudo 126
Psorophthalmia . . . 128
Scrofulous inflammation . . ib.
Inflammation of the lids with ulceration . . . . ib.
[Meibomian calculus] . . 131
Hordeolum . . . . ib.
Secondary inflammations . . ib.
Thickening and induration of the margins (tylosis) . . 132
Loss of the eyelashes (ptilosis) . ib.

SECTION III.

Ulcerations 133
Syphilitic diseases . . . ib.
Syphilitic ulcerations . . ib.
Cancer of the lower eyelid . . 135

SECTION IV.

Changes of figure and position . 141
Ptosis . . . . ib.
Lagophthalmus . . . 143
Paralysis of the orbicularis palpebrarum . . . . ib.
Blepharospasmus . . . ib.
Ectropium . . . . ib.
[Operation of Sir William Adams] 144
Operations of Jaeger and Dieffenbach 145
Operation of Jaeger for lagophthalmus 146
Transplantation of skin for the repair or restoration of the lids . 147
[Ammon's operation] . . 148
[Horner's operation] . . ib.
[Brainard's operation] . . 149
Entropium 150
Treatment by concentrated acid; by removing a portion of skin . 151
Operations of Messrs. Crampton and Guthrie . . . 152
[Operation of Jacob] . . 153
Excision of the cilia . . 154
[Operation of Gerdy] . . 155
Trichiasis 157
Distichiasis 158
[Additional observations on inverted ciliæ] . . . ib.

SECTION V.

Morbid connections of the eyelids . 160
Ancyloblepharon; symblepharon . ib.
Epicanthus . . . 161

SECTION VI.

Tumors 162
Nævi materni . . . ib.
Encysted tumors . . . 162
Half-encysted tumors . . 163
Tarsal tumors . . . 164
Chalazion or grando . . 164
Milium and phlyctenula . . 165
Verrucæ . . . . ib.
[Horny excrescences] . . ib.
Pediculi, phtheriasis . . 166

CHAPTER III.

INJURIES OF THE EYEBALL.

SECTION I.

Wounds of the globe . . 166
Conjunctiva; ecchymosis, accidental and spontaneous . . . 167
Wounds of the globe, their nature and general treatment . . ib.
Cornea 168
Foreign bodies in the anterior chamber 169
Gunshot injuries of the eye . 171
Injuries by exploded percussion caps ib.
Wounds of the cornea with prolapsus iridis 174

PAGE
Injuries of the eye from gunpowder 174
Sclerotica 176
Iris 177
Detachment of the iris from the ciliary ligament . . . ib.
Effusion of blood into the anterior chamber 178
Discoloration of the iris or aqueous humor . . . . . ib.
Wounds of the choroid and ciliary body—effusion of blood before or behind the iris . . . 179
Crystalline lens and capsule . 180
Traumatic cataract . . 181
Dislocated lens forced through the sclerotica . . . 182
Extraction of the dislocated lens 183
Wounds of vitreous humor . 184
[Additional remarks on dislocation of lens] 184
Retina 185
Sympathetic influence on the uninjured eye 187
Cases of amaurosis, internal inflammation and atrophy from injuries ib.
Cases of sympathetic inflammation affecting the opposite eye . 189

SECTION II.

Injuries of the eye from foreign substances passing between the lids 189
Various irritating matters . . ib.
Effect of lime 190
Particles of dust under the upper lid 191
Metallic particles sticking in the cornea 192

CHAPTER IV.

CAUSES OF OPHTHALMIC INFLAMMATION.

Immediate or exciting causes . 195
Injuries; chemical irritants . ib.
Contagious matters: excessive exertion; atmospheric causes . 196
Strong lights . . . . ib.
Remote or predisposing causes . 198
Light or dark eyes—morbid dispositions . . . . . ib.
Excessive exertion of the organ 199
Unhealthy states of constitution . 199
Plethora . . . . . ib.
Constitutional weakness . . 201
Determination of blood to the head ib.
Disordered functions and deficient excretion . . . . . ib.
Impaired nervous energy . . 202
Idiopathic and sympathetic inflammations . . . . . ib.

CHAPTER V.

TREATMENT OF OPHTHALMIC INFLAMMATION.

SECTION I.

Treatment of acute inflammation 203
General indications . . 204
Loss of blood . . . 205
General bleeding . . . ib.
Local bleeding—cupping . . 207
Leeches—scarifications . . 208
Purgatives and diet . . 209
Other internal remedies; antimony ib.
Mercury; counter irritation . 210
Local applications . . . 211

SECTION II.

Treatment of chronic ophthalmia 214
General means . . . ib.
Local measures; counter-irritation 216
Use of stimuli and astringents; vinum opii 217
Various saline substances in solution 218
Nitrate of silver . . . ib.
General summary of treatment in ophthalmic inflammation . 220

CHAPTER VI.

DIVISIONS AND CLASSIFICATION OF OPHTHALMIC INFLAMMATIONS.—SIMPLE AND CATARRHAL INFLAMMATION OF THE CONJUNCTIVA.

Divisions and classification . 220
Simple inflammation of the conjunctiva 222
Catarrhal ophthalmia; its nature ib.
Causes . . . . . ib.
Symptoms 223
Prognosis; diagnosis . . 225
Treatment . . . . . ib.
Use of astringents . . . 226

CHAPTER VII.

PURULENT OPHTHALMIA.—PURULENT OPHTHALMIA OF NEWLY-BORN INFANTS.

PAGE
Nature and general character of purulent ophthalmia . . 228
Purulent ophthalmia of infants . 229
Symptoms and progress . . ib.
Effects 231
Mode of examining the eye . 232
Causes 233
Prognosis 234
Treatment 235
Purulent ophthalmia in children . 239

CHAPTER VIII.

PURULENT OPHTHALMIA IN THE ADULT.

Character 241
Symptoms and progress . . 243
Purulent ophthalmia in its milder form 244
Effects of the inflammation . 248
Diagnosis; prognosis; causes . 250
Direct communication by application of discharge . . . ib.
Indirect or atmospheric contagion 255
Arguments against contagion . 256
General result of evidence respecting contagion . . . 258
Treatment 260
Treatment of acute purulent ophthalmia 261
General measures . . . ib.
Local applications . . . 263
Astringents and tonic medicines . 264
Treatment of purulent ophthalmia in its milder form . . 267
Treatment of the thickened and granulated conjunctiva . . 268
[Additional remarks on granulated conjunctiva] . . . 271

CHAPTER IX.

GONORRHŒAL OPHTHALMIA.

SECTION I.

Acute gonorrhœal inflammation of the conjunctiva . . . 279
Symptoms and progress . . ib.
Effects; sloughing of the cornea . 281
Suppuration and ulceration . 282
Interstitial deposition . . 283
Diagnosis . . . . ib.
Prognosis 284
Causes 285
Direct application of gonorrhœal matter . . . . ib.
Metastasis 287
Treatment 288
Incisions of the sclerotic conjunctiva 290

SECTION II.

Mild gonorrhœal inflammation of the conjunctiva . . . 294

SECTION III.

Gonorrhœal inflammation of the external tunics and iris . . 295
Rheumatic nature of this disease ib.

CHAPTER X.

ERYSIPELATOUS OPHTHALMIA; PUSTULAR OPHTHALMIA; STRUMOUS OR SCROFULOUS OPHTHALMIA.

SECTION I.

Erysipelatous ophthalmia . . 298

SECTION II.

Pustular ophthalmia . . 298

SECTION III.

Scrofulous ophthalmia . . 299
Scrofulous constitution . . 299
Exciting causes of scrofula . 300
Symptoms and course of scrofulous ophthalmia . . . 301
Effects 303
Diagnosis 304
Prognosis . . . . ib.
Causes; treatment; general means 305
Local treatment . . . 308

CHAPTER XI.

VARIOLOUS, MORBILLOUS, AND SCARLATINOUS OPHTHALMIA.

PAGE
Variolous ophthalmia . . 310
Secondary variolous ophthalmia . 313
Morbillous and scarlatinous ophthalmia 314

CHAPTER XII.

VARIOUS AFFECTIONS OF THE CONJUNCTIVA.

Granulated conjunctiva—ulcers . 315
Pterygium; general description . ib.
Pterygium tenue; crassum . 317
Malignant pterygium . . 318
Diagnosis, treatment . . ib.
Pterygium pingue . . . 320
Dry conjunctiva . . . ib.
Discoloration of the conjunctiva by nitrate of silver . . . 322
[Copper-colored syphilitic eruption of conjunctiva] 322
Polypi, warts and other excrescences ib.
Cartilaginous formations . . 324
Tumors . . . . ib.
with hairs . . . ib.
encysted . . . 327

CHAPTER XIII.

DISEASES OF THE SCLEROTICA.

SECTION I.
Inflammation . . . 327
Symptoms and progress . . ib.
Diagnosis 329

SECTION II.
Rheumatic ophthalmia; Catarrho-rheumatic ophthalmia . . 330
Chronic rheumatic ophthalmia . 331
Catarrho-rheumatic ophthalmia . 333

SECTION III.
Staphyloma scleroticæ . . 333

SECTION IV.
Cysts and tumors of the sclerotica 335

CHAPTER XIV.

DISEASES OF THE CORNEA.

SECTION I.
Inflammation . . . 336
Acute corneitis with suppuration . 337
Evacuation of matter by puncture . ib.
Symptoms of corneitis . . 340
Prognosis 341
Treatment . . . . ib.
Partial inflammation of the cornea 342
Strumous corneitis . . . 343
Inflammation with vesication . 345
[Affection of the cornea in nurses] ib.

SECTION II.
Vascularity of the cornea . . 345

SECTION III.
Ulceration of the cornea . . 346
Hernia corneæ . . . 348

SECTION IV.
Opacity of the cornea . . . 348
Arcus senilis . . . ib.
Other opacities . . . 349
Treatment 350
[Additional remarks on treatment] . ib.
Effect of treatment in the various forms of opacity . . . 354
Congenital opacity of the cornea . 356

SECTION V.
Staphyloma 357
Causes 360
Treatment . . . . ib.
Adaptation of an artificial eye . 362
Conical cornea . . . ib.

CHAPTER XV.

DISEASES OF THE AQUEOUS MEMBRANE AND CHAMBERS.

PAGE

SECTION I.

Internal inflammations of the eye . 365
Artificial dilatation of the pupil . 366

SECTION II.

Inflammation of the aqueous membrane 369
Symptoms 370
Treatment 371
Diagnosis 372

SECTION III.

Hypopyon 374
Question of opening the cornea to let out the matter . . . 375

PAGE

SECTION IV.

Evacuation of the aqueous humor . 376

SECTION V.

Effusion of blood and other matters into the anterior chamber . . 378
Hæmophthalmus . . . ib.
Hypolympha; hypogala . . 382

SECTION VI.

Enlargement of the cavity containing the aqueous humor; dropsy of the anterior chamber . . . 382
Congenital dropsy . . . ib.
Other cases 383

CHAPTER XVI.

DISEASES OF THE IRIS.

INFLAMMATION OF THE IRIS; IRITIS.

SECTION I.

General account of iritis and its treatment 384
General character of iritis . . ib.
Change of color . . . 385
Effusion of lymph . . . ib.
Abscess 386
Motions of the iris, and state of the pupil 388
Increased redness of the eye . ib.
State of the cornea and aqueous humor 389
Intolerance of light, and pain . ib.
General symptoms . . . 390
Progress and extension of the inflammation . . . ib.
Effects; gradual recovery . . 391
Change of texture and color in the iris ib.
Adhesions of the pupil . . 392
Adventitious membranes . . ib.
Closure of the pupil; atrophy of the globe and synchisis . . 393
Impaired vision . . . 394
Causes . . . . ib.
Whether iritis is caused by the use of mercury . . . 395
Prognosis 396
Treatment; antiphlogistic means; and mercury . . . ib.
Whether the use of mercury is essential 398
Beneficial action of mercury after or with direct depletion . . 400
Caution against its indiscriminate and excessive employment . 401
Its favorable action in small doses under certain circumstances . ib.
Local employment of mercury . 402
Belladonna . . . . ib.
Operation of mercury . . 403
Local applications: vinum opii, blisters 405
Precaution against relapse . . ib.
Oil of turpentine . . . ib.

SECTION II.

Acute and chronic iritis . . 407

SECTION III.

Syphilitic iritis . . . 408
Diagnosis 410

SECTION IV.

Arthritic iritis . . . 410
Scrofulous iritis . . . 413
[Additional remarks on iritis] . ib.

CHAPTER XVII.

MALFORMATIONS AND VARIOUS AFFECTIONS OF THE IRIS.

PAGE
Congenital deficiency . . 418
Coloboma iridis . . . 419
Change of color; spotted iris; prolapsus iridis . . . 420
Synechia anterior and posterior . 422
[Staphyloma iridis] . . ib.
Fungous excrescences from the iris and ciliary body . . . 423
Tumors growing from the iris . 424
Myosis 425
Mydriasis . . . . ib.
Tremulous iris . . . 426

CHAPTER XVIII.

FORMATION OF AN ARTIFICIAL PUPIL.

SECTION I.

General and preliminary considerations 427
States of the eye requiring the operation . . . . ib.
Diagnosis 429
Prognosis 431
Position of the artificial pupil . 433
Previous considerations . . 434
Various operations . . . 435

SECTION II.

Operation by incision . . 436
Methods of Cheselden . . 436
Wenzel, Janin . 437
Sir W. Adams . . 438
Maunoir . . 439
[More particular account of Maunoir's method] . . . 442

SECTION III.

Operation by excision . . 443
Method of Mr. Gibson . . ib.
Mr. Tyrrell . . 446

SECTION IV.

Operation by separation; coredialysis 447
The operation of Scarpa and Schmidt . . . . ib.
The operation by detachment and strangulation . . . 449
Langenbeck's operation . . ib.
Reisinger's double hook . . 452
Operation by separation and excision 453
[Distortion] 455
Formation of an artificial pupil in the sclerotica . . . 457

CHAPTER XIX.

AFFECTIONS OF THE CHOROID COAT, RETINA, VITREOUS HUMOR, LENS, AND CAPSULE.

SECTION I.

Affections of the choroid coat . 458
Choroiditis . . . . ib.
Inflammation of the orbiculus ciliaris 461
Deficiency of pigment . . ib.

SECTION II.

Inflammation of the retina . 461
Cases . . . . ib.

SECTION III.

Inflammation of the internal tunics generally 465
Internal inflammation of the eye consequent on fever . . 466
[Additional remarks on internal inflammation of the eye consequent on fever] 469
Arthritic inflammation of the internal tunics . . . 474
Glaucoma 476
Symptoms . . . . ib.
Causes 477
Seat of disease . . . ib.
Diagnosis 479
Prognosis; treatment . . ib.
[Additional remarks] . . 480

SECTION IV.

Affections of the vitreous humor 485
Hypertrophy; ecchymosis; synchisis ib.
Change of structure and consistence 486

SECTION V.

Affections of the lens and capsule 486
Inflammation . . . ib.
Calcareous and bony change . 487
Spontaneous passage into the anterior chamber . . . 488

CHAPTER XX.

AMAUROSIS AND OTHER DEFECTS OF SIGHT.

SECTION I.

PAGE
General observations . . 490
Divisions of amaurosis . . 493

SECTION II.

Amaurosis from affections of the brain 493

SECTION III.

Amaurosis from diseases of the optic nerve 501

SECTION IV.

Amaurosis from affection of the retina 504
Symptoms of amaurosis; impaired and altered sight . . . 507
Progress of the disease . . 510
State of the pupil and iris . . ib.
Other symptoms . . . 513
Causes; age; the disease sometimes congenital . . . ib.
Hereditary disposition . . 514
General causes; plethora . . ib.
Excessive exertion of the organ . ib.
Determination to the head . . 515
Sympathetic influences . . ib.
Syphilis 516
Gout and rheumatism . . ib.
Narcotic poisons, and various other substances . . . 517
Diagnosis 519
Prognosis . . . . ib.
Treatment; antiphlogistic measures 521
Use of mercury . . . ib.
Counter-irritation . . . 522
Cases 524
Local applications . . . 530
Emetics 531
Electricity 533

PAGE
Sternutatories . . . 533
Stimuli and tonics . . . 534
Use of strychnia . . . 535
[Case illustrating its efficacy] . 537

SECTION V.

Particular kinds of nervous affection 538
Affection of the retina from excessive exertion . . . ib.
[Additional remarks on asthenopia] 540
Symptomatic and sympathetic amaurosis 553
Amaurosis from debility . . 555
[Hysteric amaurosis] . . 560
Amaurosis from affection of the nervus trigeminus . . 561
Amaurotic cat's-eye . . 564
Muscæ volitantes . . . 566
[Diagnosis] 567
Cause . . . . ib.
Treatment 572
Hemeralopia . . . 573
Congenital and hereditary hemeralopia 575
Nyctalopia 576
[Hemiopia] 577
Want of power to distinguish colors 582
[Additional remarks on inability to distinguish colors] . 584

SECTION VI.

Near sight and far sight . . 593
Nearsightedness; myopia . . ib.
[Treatment of nearsightedness] . 596
[Concave glasses] . . . ib.
Farsightedness . . . 600
[Use of glasses] . . . 601
[Irregular refraction] . . 606
[Colored vision] . . . 609
[Photopsia] 610

CHAPTER XXI.

CATARACT.

SECTION I.

General description of the disease; its causes and treatment; various operations 612
Color and situation of the opacity; state of vision . . . 614
State of iris and pupil . . 615
[Diagnosis by a catoptric examination] . . . . ib.
Various species of cataract; the lenticular 617
Morgagnian cataract . . 619
Capsular cataract . . . 620
Capsulo-lenticular cataract . . 621
Varieties of color and consistence . 623
Mature and immature; complications; adhesions of the pupil . 624
Glaucoma . . . . ib.
Amaurosis 625

PAGE
Varieties dependent on age . . . 625
Causes . . . . ib.
Treatment 629
Prognosis . . . . ib.
Time for operating . . . 631
Operations 633
Preparation of the patient . . ib.
Various operations . . . 634

SECTION II.

Extraction of the cataract . . 635
Questions of operating on both eyes at the same time . . . ib.
Instruments; various knives . 636
Position of the patient . . 638
Fixing the eye . . . 639
Division of the cornea . . ib.
Superior section . . . 640
Division of the capsule and removal of the lens . . . 643
Escape of vitreous humor . . 644
Exterior and inferior section . 645
Inferior section . . . 646
Operation of extraction without an assistant . . . . ib.
Treatment after the operation . 647
Inflammation . . . 649
Prolapsus iridis . . . 650
Cases fit or unfit for extraction . 651

SECTION III.

Depression or couching . . 652
Reclination 653
After treatment . . . 654
Absorption of the depressed lens . 656

SECTION IV.

The operation by solution or absorption 658
[Additional remarks on operation by absorption] . . . 659
Whether the lens is removed by absorption or solution . . 661
Danger from the passage of a hard lens or hard fragments into the anterior chamber . . ib.
Capsule not absorbed . . 662
Keratonyxis . . . ib.
[Jacob's needle and mode of operating with] 664
Operation when the capsule is opaque, and the pupil adherent . 666

SECTION V.

Congenital cataract; its nature . 666
Whether really congenital . . 667
Affecting several members of the same family . . . 668
Operation on infants . . ib.
Operation on opaque capsule . 669
Various proceedings . . ib.
Anterior operation on the infant . 670
Posterior 671
Proper age for the operation . ib.
Secondary cataract . . . 672

CHAPTER XXII.

GENERAL AFFECTIONS OF THE GLOBE.

SECTION I.

Inflammation of the globe . . 673
Symptoms . . . . ib.
Effects 675
Diagnosis 676
Treatment . . . . ib.
Ophthalmitis arthritica . . 677

SECTION II.

Inflammation and destructive suppuration of the eye, as a secondary effect of phlebitis . . . 677
[Additional remarks] . . 679

SECTION III.

Sympathetic ophthalmia . . 682

SECTION IV.

Hydrophthalmia . . . 686

SECTION V.

Atrophy of the eye . . . 687
Collapse of the globe from suppuration 688

SECTION VI.

Exophthalmia . . . 688

CHAPTER XXIII.

MALIGNANT DISEASES OF THE EYE.

SECTION I.

PAGE

Fungous growths not malignant . 689

SECTION II.

Carcinoma of the eye . . 693

SECTION III.

Fungus hæmatodes of the eye . 697
Symptoms and progress . . ib.
Seat and nature of the disease . 699
Diagnosis; cancer and melanosis; age of the patient . . 705
Effusion of lymph after injuries . 706
Effusion of pus from internal inflammation . . . 707
Change of structure in the vitreous humor . . . . ib.
Yellow appearance in the pupil of doubtful seat and nature . . 708
Treatment; question of extirpation 709
Cases of supposed success . . ib.
Proposal of evacuating the globe at an early period . . . 711
Objections . . . . ib.
Use of mercury . . . 713
Cases of fungus hæmatodes . 714

SECTION IV.

Melanosis of the eye . . 720
Cases 722
[Melanotic deposit beneath the conjunctiva] 737

SECTION V.

Extirpation of the eye . . 740

CHAPTER XXIV.

OSSIFICATIONS. CALCULOUS CONCRETIONS. ENTOZOA IN THE EYE.

SECTION I.

Ossification of various parts of the eye 742

SECTION II.

Calculous concretions . . 744

SECTION III.

Entozoa in the eyes of man and other vertebralia . . . 745
Filaria in the aqueous humor . 746
Filaria under the conjunctiva and in the lens 747
Filaria and monostoma in the lens ib.
Distoma in lens . . . ib.
Cysticercus in the anterior chamber 748
Cysticercus in the subconjunctival tissue 750

CHAPTER XXV.

AFFECTIONS OF THE ORBIT.

SECTION I.

Injuries 750
Penetrating wounds . . ib.
Protrusion of the globe . . 752

SECTION II.

Acute inflammation and suppuration of the orbital cellular texture 753
[Cases] 754

SECTION III.

Chronic abscess in the orbit . 757
Propagation of inflammation to the contents of the cranium . . 758

SECTION IV.

Protrusion of the globe from changes of obscure nature . . 760

SECTION V.

Induration of the orbital cellular texture 763

SECTION VI.

Tumors in the orbit . . 764
Operation of extirpation . . ib.
Steatomatous tumors . . 765

PAGE
Medullary tumors . . . 767
Encysted tumors . . . 768
Cysts containing hydatids . . 772

SECTION VII.

Aneurismal affections in the orbit 773
Aneurism by anastomosis . . 774
Aneurism of the ophthalmic artery 775
[Periostitis of orbit] . . 777
[Rheumatic inflammation of the tunica vaginalis oculi] . . 782

SECTION VIII.

Affections of the muscles in the orbit 789
Injuries—paralytic affections—ophthalmoptosis . . . ib.
Irregular motions . . . 790
Nystagmus; tetanus; monoblepsis ib.
Diplopia . . . . ib.
Squinting; general description . 792
Causes 794
State of the affected muscles . 798
Thickening and induration of the cellular texture . . . 799

PAGE
Treatment 799
Operation of dividing the recti muscles 801
Cases proper for the operation . 801
Position of the patient . . 802
Operation on the internal straight muscle with the curved director and knife 803
Operation with forceps and scissors 804
Operation with blunt hook . . ib.
Specula for separating and fixing the eyelids . . . ib.
Double convergent strabismus . 807
[Editor's method of operating] . 808
Treatment after the operation . 811
Effects of the operation on the internal straight muscle . . 812
Effects on the position and motions of the eye . . . ib.
Effects on vision . . . 813
Causes of failure in the operation 815
Incomplete division of the tendon or of cellular adhesion . . 815
Unnatural eversion; prominence of the eye . . . . ib.
[Results of the operation, &c.] . 816
Luscitas 818

CHAPTER XXVI.

AFFECTIONS OF THE LACHRYMAL ORGANS.

SECTION I.

Injuries of the lachrymal apparatus 819
Foreign substances in the puncta lachrymalia . . . ib.

SECTION II.

Diseases of the lachrymal gland . 819
Enlargement and induration . 820
Hydatid of the lachrymal gland . 825

SECTION III.

Epiphora, or watery eye . . 825
Stillicidium lachrymarum . . 826

SECTION IV.

Diseases of the semilunar membranes and caruncula lachrymalis 827
Encanthis . . . . ib.
[Spontaneous hemorrhage from the caruncula lachrymalis] . . ib.

SECTION V.

Affections of the lachrymal sac and nasal duct . . . 828
Capillary aperture of the sac . ib.
Inflammation of the internal angle 829
Acute inflammation of the sac . ib.
Chronic inflammation of the lachrymal sac 831
Permanent obstruction of the nasal duct 833
Hernia sacci lachrymalis . . ib.
Hydrops sacci lachrymalis . . ib.
Various modes of treatment; probe and syringe . . . 834
Injection of the sac with quicksilver 835
Tube in the nasal duct . . ib.
Enlargement of the duct by catgut 837
Introduction of instruments from the nose . . . . ib.
Use of the silver style . . 838
[Lubbock's operation] . . 839
[Treatment by dilatation with Anel's probes] 840
[Morgan's curved probe] . . 842
[Congenital absence of nasal duct] 843

ERRATA.

PAGE 227, line 31 from top, for p. 204 read p. 219.

509, line 16 from top, for *metamorphosia* read *metamorphopsia*.

540, line 37 from top, for ωκ read ωψ.

540, line 39 from top, for ωκ read ωψ.

789, line 10 from top, for p. 133 read p. 141.

LIST OF ILLUSTRATIONS.

Figure 1. Horizontal section of eyeball, after T. W. Jones - - *Plate* I.
——— 2. Longitudinal section of the globe of the eye, after Wilson - - I.
——— 3. Anterior segment of a transverse section of the globe of the eye, seen from within - - - - - - - II.
——— 4. Posterior segment of a transverse section of the globe of the eye seen from within - - - - - - - II.
——— 5. View of the choroid coat with its vessels injected - - - II.
——— 6. View of the veins of the choroid coat, as distended by blood - - II.
——— 7. Anterior view of the iris as attached to the choroid coat - - II.
——— 8. Anterior view of the choroid, iris and membrana pupillaris of a fœtus of seven months, highly injected and magnified four diameters - II.
——— 9. Front view of the retina, with the lens in its capsule - - - II.
——— 10. Anterior surface of iris after Bauer and Sir Everard Home - - III.
——— 11. Posterior surface of iris after do. do. - - III.
——— 12. Anterior view of the iris and membrana pupillaris of an infant of six and a half months, with their vessels injected—highly magnified III.
——— 13. Posterior view of the same, also much magnified, and with the membrana pupillaris ruptured - - - - - - - III.
——— 14. Segment of the anterior face of the iris with its vessels injected—magnified 25 diameters - - - - - - - III.
——— 15. The external face of the retina, with the lens attached to it - - IV.
——— 16. Portion of the retina of an infant, with its vessels injected and magnified 25 diameters - - - - - - - - IV.
——— 17. Part of the retina of a frog, seen from the outer surface—magnified 300 times—after Treviranus - - - - - - IV.
——— 18. Papillæ of the retina of the frog, seen from the side turned towards the vitreous humor; the four higher rows are seen sideways—magnified 300 times—after Treviranus - - - - - - IV.
——— 19. Front view of the crystalline humor or lens, in the adult - - IV.
——— 20. Side view of the adult lens - - - - - - - IV.
——— 21. Magnified view of the lens of a fœtus of eight months, seen on its anterior face, with the marks of its division into the three pieces that form it at that period - - - - - - - IV.
——— 22. Side view of the vitreous humor and lens of a fœtus at eight months, showing the shape and direction of the canal of Petit - - IV.
——— 23. View of the left eye of a fœtus of six months, magnified two diameters —showing the vessels in the conjunctiva - - - - - IV.

Figure 24. View of the muscles of the eyeball, taken from the outer side of the right orbit, after Wilson - - - - *Plate* V.
—— 25. Posterior view of the eyelids and lachrymal gland - - - V.
—— 26. Posterior view of the eyelids, as seen under the microscope, showing the Meibomian glands - - - - - - - V.
—— 27. Lachrymal passages - - - - - - - V.
—— 28. View of optic nerves, with the origin of seven other pairs of nerves VI.
—— 29. View of the third, fourth, and sixth pairs of nerves - - - VI.
—— 30. Front view of left eye - - - - - - VI.
—— 31. Side view of same eye - - - - - - VI.
—— 32. Tensor tarsi, or muscle of Horner - - - - - VI.
—— 33. Illustration of Adams' operation for ectropium - - *Page* 145
—— 34, 35. Illustration of Dieffenbach's operation for ectropium - - 146
—— 36, 37. Illustration of Ammon's operation for ectropium - - - 148
—— 38, 39. Illustration of Horner's operation for ectropium - - - 149
—— 40. Illustration of Brainard's operation for ectropium - - - 150
—— 41. Illustration of Crampton and Guthrie's operation for entropium - 153
—— 42. Epicanthus, with the operation for its cure - - - - 161
—— 43. Represents purulent ophthalmia with chemosis, after Eble - - 243
—— 44. Represents pustular ophthalmia - - - - - 298
—— 45. Represents pterygium tenue, after Guthrie - - - - 317
—— 46. do. do. crassum, do. - - - - 317
—— 47, 48. Tumors of conjunctiva, with hairs growing from them - - 325
—— 49. Staphyloma scleroticæ - - - - - - - 334
—— 50. Ulcer of cornea - - - - - - - 346
—— 51. Central opacity of cornea concealing the pupil - - - 355
—— 52. The same eye with the pupil dilated by belladonna - - - 355
—— 53. Staphyloma of cornea - - - - - - - 357
—— 54. Total spherical staphyloma - - - - - - 358
—— 55. Partial staphyloma of cornea - - - - - - 358
—— 56. Staphyloma knife - - - - - - - 360
—— 57. Conical cornea, after Demours - - - - - - 363
—— 58. Represents the pupil closed by lymph, the sequel of iritis - - 393
—— 59. Syphilitic iritis, after a drawing by Mr. Partridge - - - 409
—— 60. Coloboma iridis - - - - - - 419
—— 61. Synechia anterior - - - - - - - 422
—— 62 Iridauxesis, after Klemmer - - - - - - 423
—— 63. Cheselden's operation for artificial pupil - - - - 437
—— 64. Wenzel's operation for do. do. - - - - 437
—— 65. Sir W. Adams' iris knife - - - - - - 438
—— 66. Diagram illustrating operation for artificial pupil by incision through the sclerotica - - - - - - - 438
—— 67. Diagram showing the pupil formed by preceding operation - - 439
—— 68. Maunoir's scissors - - - - - - - 440
—— 69. Diagram illustrating Maunoir's operation for artificial pupil - - 441
—— 70. Diagram showing form of pupil resulting from this operation - - 441
—— 71. Diagram showing the form of pupil in Maunoir's first case - - 442
—— 72, 73. Mackenzie's method of dividing the iris, with the shape of pupil resulting therefrom - - - - - - - 443
—— 74. Gibson's forceps for artificial pupil - - - - - - 444
—— 75. do. hook for do. do. - - - - - - 444
—— 76. do. scissors for do. do. - - - - - 444

Figure 77. Mode of holding the curved scissors in operation for artificial pupil, after Jones - - - - - - - *Page* 445
—— 78. Tyrrell's hook for artificial pupil - - - - - - 446
—— 79. Jaeger's keratome - - - - - - - - 450
—— 80, 81, 82, 83, 84. Diagrams illustrating artificial pupil by separation - 450
—— 85. Hook for artificial pupil - - - - - - - 451
—— 86. Illustration of mode of performing operation for artificial pupil by separation and strangulation - - - - - - - 451
—— 87. Reisinger's hooked forceps - - - - - - - 452
—— 88. Pupil obstructed with lymph, and lymph deposited in substance of iris, after a drawing for Editor - - - - - - - 457
—— 89. The same eye after operation for artificial pupil, by distortion, after drawing for Editor - - - - - - - - 457
—— 90. Editor's silver hook for drawing out the iris - - - - - 457
—— 91. Genealogical chart of a family in which many of the members are unable to distinguish colors - - - - - - 590
—— 92, 93, 94. Diagrams illustrating irregular refraction of lens - - 608
—— 95. Represents the shadow thrown by the pupillary margin of the iris on the surface of a cataract - - - - - - - 615
—— 96. Beer's cornea knife - - - - - - - - 637
—— 97, 98. Knives for enlarging the corneal section in operation for extraction of cataract - - - - - - - - - 637
—— 99. Curette - - - - - - - - 637
—— 100. Hook - - - - - - - - - 637
—— 101. Maunoir's scissors - - - - - - - - 637
—— 102. Tyrrell's cornea knife - - - - - - - 638
—— 103. Represents the first step of the operation for extraction of cataract by superior section, the mode of separating the lids, and the puncturation of cornea - - - - - - - - 639
—— 104. Counter puncturation of cornea in same operation - - - 640
—— 105, 106, 107. Diagrams of superior, inferior, and lower and outer sections of cornea - - - - - - - - - 640
—— 108. Faulty section of cornea - - - - - - - 641
—— 109, 110. Daviel's scissors - - - - - - - - 642
—— 111. Instrument for opening the capsule of the lens in operation for extraction - - - - - - - - - 643
—— 112. Daviel's curette or spoon - - - - - - - 643
—— 113. Exterior and inferior section of cornea - - - - - 645
—— 114. Inferior section of cornea - - - - - - - 646
—— 115. Covering for the eye after operation for cataract - - - 647
—— 116. Straight spear-pointed cataract needle - - - - - 652
—— 117. Saunders' cataract needle - - - - - - - 652
—— 118. Scarpa's cataract needle - - - - - - - 652
—— 119. Represents operation for depression - - - - - - 653
—— 120. Diagram illustrating couching of cataract - - - - - 653
—— 121. Diagram representing reclination - - - - - - 653
—— 122. Diagram showing the manner of keeping the lids separated in operations on the eye - - - - - - - - 660
—— 123. Diagram illustrating division of cataract through the cornea - - 663
—— 124, 125. Jacobs' cataract needle - - - - - - - 664
—— 126. Cataract needle for anterior operation - - - - - 665
—— 127, 128. Cysticercus in anterior chamber; in fig. 128 the body and head

are protruded from the tail vesicle; in fig. 127 those parts are retracted - - - - - - - - *Page* 749
Figure 129. Elastic steel wire speculum for separating the lids in operation for strabismus - - - - - - - - 808
—— 130. Toothed forceps - - - - - - - - 809
—— 131. Scissors for dividing the muscle in operation for strabismus - - 809
—— 132. Small knife - - - - - - - - - 810
—— 133. Blunt hook - - - - - - - - - 810
—— 134. Anel's probe - - - - - - - - - 826
—— 134. Dupuytren's tube for insertion in nasal duct - - - - 835
—— 135. Wathen's tube for do. do. - - - - 835
—— 136. Dupuytren's steel stilet for inserting tube, fig. 134 - - - 836
—— 137. Catgut style for dilating the nasal duct - - - - 837
—— 138. Ware's style - - - - - - - - 838
—— 139. Bougie style - - - - - - - - 838
—— 140. Operation for incision of lachrymal sac - - - - 838
—— 141. Lubbock's knife for opening the lachrymal sac - - - 839
—— 142. Operation with Lubbock's knife - - - - - - 839
—— 143. Morgan's curved probe for dilating nasal duct through the nose - 842
—— 144. Blood-vessels of cornea - - - - - - *Plate* VII.
—— 145. Portion of choroid of ox, magnified, after Gerber - - - VII.
—— 146. Magnified view of capillaries in vascular layer of retina, after Berres VII.
—— 147. Portion of retina of sheep, after Treviranus - - - - VII.
—— 148. Portion of retina of crow do. do. - - - - VII.
—— 149. Diagram showing the triple division of the lens, after Brewster - VII.
—— 150. Diagram of serrated margins of fibres of lens do. do. - - VII.
—— 151. Horn spatula - - - - - - - - VIII.
—— 152. Forceps - - - - - - - - VIII.
—— 153. Graefe's entropium forceps - - - - - - VIII.
—— 154. Diagram illustrating the axes of revolution on which the eyeball is moved by its different muscles, after Ruette - - - VIII.
—— 155, 156. Ectropium from caries of the orbit, and Ammon's operation for its cure - - - - - - - - - IX.
—— 157. Illustration of the operation for ectropium by transplantation of the skin - - - - - - - - - IX.
—— 158, 159. Illustration of T. Wharton Jones' operation for ectropium - IX.
—— 160, 161. Illustrations of eversion at the outer angle, and Walther's operation of *tarsoraphia* - - - - - - - X.
—— 162. Trichiasis - - - - - - - - - X.
—— 163. Medullary fungus of eyeball - - - - - - - X.
—— 164. Melanosis of eyeball - - - - - - - - X.
—— 165. Catarrhal inflammation of conjunctiva - - - - - XI.
—— 166. Granular lids - - - - - - - - XI.
—— 167. Dislocation of lens into anterior chamber - - - - XI.
—— 168. Tricosis bulbi - - - - - - - - XI.
—— 169. Phlyctenular ophthalmia - - - - - - - XI.
—— 170. Iris and pupil in their natural state - - - - - XII.
—— 171. Iris inclined towards cornea - - - - - - - XII.
—— 172. Iritis - - - - - - - - - XII.
—— 173. Arthritic iritis - - - - - - - - XII.
—— 174. Arthritic posterior internal ophthalmia - - - - - XII.
—— 175. Cyst in connection with iris - - - - - - - XII.

TREATISE

ON

DISEASES OF THE EYE.

INTRODUCTION.

The object of the following pages is to describe the nature and treatment of diseases of the eye, including under that expression, not only the globe itself, but the several auxiliary parts, called its appendages. The anatomy and physiology of the organs will be considered merely in reference to practical purposes.

It is hardly necessary to enlarge on the importance of the subject, or to prove formally that a knowledge of it is indispensable to medical practitioners. Every one feels that sight is the most valuable of the senses; that it not only is, in itself, the most important inlet of knowledge, the most valuable medium of our communication with surrounding persons and objects, but also that it is essential to the full enjoyment of our other senses; to the free exercise of almost all our other faculties and endowments; so that these lose more than half their value when sight is gone. Hence blindness is one of the greatest calamities that can befal human nature, short of death; and some would perhaps prefer the termination of existence to its continuance in the solitary and dependent state, to which life is reduced by the privation of this precious sense.

Loss of sight is the greatest misfortune even to the rich, who can alleviate it by purchasing the aid and services of others. How much more severely must it be felt by the poor, by the middle and lower classes of society, that is, by the great majority of mankind; who, being rendered incapable of labor, and having their minds uncultivated, find their existence reduced to a dreary blank, dark, solitary, and cheerless, burdensome to themselves and to those around them. Even our great poet, who might have been supposed to find every alleviation and resource that such an affliction admits of, in his highly-gifted mind, and the exhaustless stores of knowledge with which it was furnished, repeatedly reverts to his blindness, and always in a tone of anguish and despondency characteristic of recent misfortune:

"Thus with the year
Seasons return; but not to me returns
Day, or the sweet approach of eve or morn,
Or sight of vernal bloom, or summer's rose,
Or flocks, or herds, or human face divine;
But cloud instead, and ever-during dark
Surround me from the cheerful ways of men
Cut off, and for the book of knowledge fair
Presented with a universal blank
Of Nature's works, to me expunged and rased,
And wisdom at one entrance quite shut out."

It often depends on the surgeon whether the patient shall retain or lose, recover or remain bereft of vision. Common external inflammation of the eye, if neglected or improperly treated, by rendering the transparent anterior portion of the organ more or less opaque, proportionally injures vision; inflammation of the iris, when unchecked, causes contraction of the pupil and effusion of lymph, which prevents the passage of light into the eye. Affection of the nervous structure, if not arrested in its beginning, terminates inevitably in diminution or loss of sight. Such distressing results have too often been promoted by modes of treatment, in favor of which the sanction of names that have enjoyed public confidence might be adduced. The success of operations for cataract, or artificial pupil, depends entirely on the knowledge, discrimination, and dexterity of the operator. The cases now alluded to are matters of daily occurrence, and make up the bulk of ophthalmic practice. The serious responsibility, which this view of the subject unfolds, will impel every conscientious practitioner to turn his anxious attention to the affections of this important organ, and to embrace all opportunities of acquiring that knowledge, which will enable him to act decisively and effectually on occasions of such momentous consequence.

If there are any, to whom the pleasure connected with the acquisition of knowledge, the satisfaction flowing from the consciousness of important duties rightly performed, and the gratitude so warmly expressed for the inestimable benefits of averting blindness or restoring sight, should not prove an incentive sufficiently powerful to the study of ophthalmic medicine and surgery, their case must be deemed desperate; unless, indeed, their minds, insensible to higher feelings and nobler motives, should obey the impulse of self-interest and fear; unless they should be affected by the prospect of disgrace and injury, which ignorance and its inseparable blunders must entail. The consequences of wrong treatment cannot be concealed here, as in the obscure affections of internal organs; the visible changes of structure are obvious to external observation, and the unfortunate individual, whose sight is injured or destroyed by unskilful treatment, serves as a lasting memorial of the incapacity and rashness to which he owes his misfortune. The study of diseases of the eye is therefore now justly regarded as an essential part of general medical education; but it is more particularly so to country practitioners, who are thrown entirely on their own resources; who cannot, as in the metropolis, and some large cities, call in the aid of superior talent and knowledge.

Although the importance of the subject must be admitted, it may be doubted whether the ophthalmic branch ought to be separated from the rest of medicine and surgery, as it must be, to a certain extent, by devoting to it separate courses of lectures and treatises, and by instituting ophthalmic hospitals. The diseases of the eye, in general hospitals, are inadequate, from the smallness of their number, to the purposes of practical study, particularly that of exemplifying the various operations. Thus these institutions have been inefficient in reference to this important department. As the general

body of surgeons did not understand diseases of the eye, the public naturally resorted to oculists, who, seeing such cases in greater numbers, became better acquainted with the symptoms, diagnosis, and treatment; and especially more skilful in the operative department. At the same time, the subject being imperfectly understood, was neglected in the general surgical courses, in which many important affections of the eye were entirely unnoticed, and the whole inadequately explained. Thus students, who resorted to London for the completion of their professional studies, had really no means of learning this important department of the profession, which was tacitly abandoned, even by the hospital surgeons, and turned over to the oculists. The latter, not being conversant with the principles derived from anatomy, physiology, and general pathology, attended merely to the organ, and relied almost exclusively on what is comparatively of little importance, local treatment. Hence ophthalmic surgery, being in a manner dismembered from the general science, was reduced to a very low ebb. Until within a few years, it was, in this country at least, in a state of almost total darkness.

It thus became desirable to establish an express and distinct school for diseases of the eye: not because the principles of treatment differ from those applicable to disease in general; nor because any peculiar mode of study is required; but in order to supply a deficiency in the existing sources of professional instruction; to provide for the affections of this important organ, those means of information, which the general hospitals neither do, nor could afford, consistently with their requisite attention to their other important objects. This proceeding, which at first view seems calculated to complete and perpetuate the separation, was the only rational mode of reuniting ophthalmic practice to general surgery.

It was the object of the London ophthalmic infirmary to apply the general principles of pathology and therapeutics to the elucidation and treatment of diseases of the eye. Hence it is a law of the establishment, that the medical officers of the institution shall be selected from those who have been regularly educated as physicians and surgeons. The great field of observation which it affords has been thrown open to the public; thus enabling the general body of the profession, and particularly medical students, to acquire easily, and in a short time, a full knowledge of this department. The opportunities afforded at this institution are not intended nor calculated to make oculists; but to impart to surgeons and physicians a knowledge of ophthalmic diseases.

Some may doubt whether the affections of this organ afford matter for a separate course of lectures or treatise. The eye, although small in bulk, is complicated in structure. It is made up of several distinct or dissimilar tissues, and it exhibits all the affections to which each of these is liable. Although its component structures are for the most part analogous to what we meet with in other parts of the body, and consequently must be subject to morbid affections essentially similar to those occurring elsewhere, yet the office and form of the organ, the union of its component parts, and the nature of many of them are so peculiar, as to give a strong character of individuality to its diseases. We do not, at the first view, recognize in affections of the eye the same diseased processes with which we are familiar in other parts; we seem to be contemplating something peculiar and unusual, and this more especially in the diseases of the peculiar tissues. This individual and distinct character of ophthalmic diseases both accounts for their having been detached and considered as a separate branch of surgery, and, in conjunction with their number, justifies the appropriating to them distinct courses of lectures and treatises. The extent of the subject may be estimated from the circumstance that Professor Beer, of Vienna, occupied in his course of

instruction ten months, giving five or six lectures weekly. His course, too, seems to have been on the practical part of the subject; for he is styled professor of practical ophthalmology; while another celebrated teacher, PROCHASKA, was professor of general ophthalmology in the same school.

The course of proceeding in learning the diseases of the eye, must be the same as that for diseases in general. The art of treating diseases, or medicine, taken in its most extensive sense, is founded on the sciences of anatomy, physiology, pathology and therapeutics; in other words, a knowledge of the healthy structure and function must be first obtained; then that of diseased structure and function; and, lastly, the external agencies capable of influencing the body, so as to remove disease or restore health, must be studied.

The more thoroughly any organ has been investigated, anatomically, physiologically, and pathologically, the better shall we be prepared to treat its diseases. In this respect the eye is advantageously circumstanced; its anatomy is well known; its physiology clearly made out. A considerable portion of the organ is external, and the transparency of the front enables us to see much of its interior. We can observe the phenomena of disease, and the effects of remedies in some of its internal structures, in such parts as are elsewhere hidden from our view. The observations thus made on the eye are applicable to the illustration of disease and treatment in other organs. Hence if the general principles of medical science throw light on ophthalmic affections, the history and progress of the latter reciprocally afford valuable data for general pathology.

But, can the diseases of any organ be well studied alone? Can they advantageously be made the subject of detached and separate investigation and treatment? The numerous organs which make up the human body, although various in structure and office, are all intimately connected and mutually dependent. They are merely subordinate parts of one machine; and they all concur, each in its own way, in producing one general result, the life of the individual. All the leading arrangements are calculated to give a character of unity to the organization and living actions of our frame. There is a common source of nutrition for the whole body; a single centre of circulation; hence all parts are immediately dependent for their nourishment and growth, and for the materials of their various exertions, on the digestive organs and the circulating system. There is a common place of union for sensations and volitions: the nervous system associates the actions of the various organs, and combines them for the common purposes of the economy; by means of it, the various organs *co-operate* in the healthy state, and suffer together, or *sympathize* in disease. Thus the individual organs are not independent. The causes of their natural functions, and of those deviations which constitute disease, are not to be found within themselves, but mostly in the state of the constitution, or in that of some leading system of organs. Hence, in order to understand any part of the body, we must know the whole; and this holds equally good in disease as in health. Suppose a person complains of weak sight, we shall not be able to remedy the defect if we attend to the eye only, for probably there may be no visible alteration in the organ. We must look to the state of the circulation in the head, to the condition of the digestive organs; we must inquire into the patient's habits, into his diet, into his general mode of living, as well as into the causes which may be acting on the eye. Until this analysis has been made, we cannot know the causes of disease, nor can we arrive at clear grounds of treatment. We ultimately find that the eye must be cured, not by any direct or local measures, but by those of general influence; by loss of blood, purging, change of diet, and of other habits.

In such a system, then, of intricate connection and mutual influence, each

part will be best understood by him who has the clearest notions of the general economy. Even the practical proceedings will be most judiciously conducted by those who are in the habit of treating disease generally; who do not confine their attention to the part. This confinement is prejudicial, by producing and confirming habits of partial and narrow views, by leading to neglect of mutual relations and influences, by encouraging local treatment. Exclusive attention to a small corner of the animal structure causes a confinement of mental vision, analogous to the nearsightedness which mechanics contract by constantly poring over the minute objects of their attention. All the habits of the oculist lead to a separation and insulation of the organ. The part is detached from the system, treated by washes, drops, ointments; and this inefficient trifling impedes the progress of ophthalmic surgery. We want, instead of this, general and comprehensive views, the aid of analogy and contrast; the whole field of medicine and surgery must be laid under contribution for the principles which are to guide us in learning the nature and treatment of ophthalmic disease. Professed oculists have done little for the science, either here or abroad. The only real and valuable improvements have proceeded from men of extensive anatomical knowledge, and of great general insight into disease.

History.—The separation of the ophthalmic department from the rest of surgical practice, has generally been considered of recent occurrence; it is, on the contrary, very ancient, and perhaps coëval with medicine itself. Among the Egyptians, to whom we trace the origin of arts and sciences, each class of diseases had its physician; and we find from Herodotus, that Cyrus sent to Amasis, the king of Egypt, for an oculist. The Greeks and the Romans had their oculists, as is evident, not only from their writings, but from the inscriptions on ancient marbles and seals. That Augustus and Tiberius were thus provided is apparent from the following inscriptions:—*P. Attius Atimetus Augusti medicus ab oculis; Tit. Lyrius Tiberii medicus ocularius.** There is no doubt that oculists were at least as numerous in ancient Rome as in any modern city.

The Greeks, the Romans, and the Arabians were ignorant of anatomy, and could not, therefore, be acquainted with the essential nature of disease, that is, the altered structure of organs; nor connect with those changes, which really constitute disease, their appropriate external signs or symptoms. This disadvantage, however, is not so great in diseases of the eye as in many other affections, because most of them are externally visible, and obvious enough without anatomical knowledge. Hence the Greeks, who were good observers of nature, had noticed most forms of ophthalmic disease, in many instances described them well and distinguished them accurately. The extent of their knowledge is evidenced by the imperishable records of language; for many of the diseases still bear the names given to them by the Greek writers. Celsus contains a summary of all that was known in his time. Although he was ignorant of the seat of cataract, he has described the operation of couching excellently and concisely, not omitting the important subjects of previous preparation and after treatment, for which his directions are judicious.

In the fifteenth, sixteenth, seventeenth, and first half of the eighteenth century, the management of the diseases of the eye was left to quacks, to mountebanks, and itinerant practitioners. There were many of them, both in our own country and on the continent. It is not, however, worth while

* These, and other similar inscriptions, are quoted by Haller from Gruter and other authorities. Walch has collected everything relating to the subject in his Sigillum Medici Ocularii Romani; Jenæ, 1772, 8vo. Haller, Bibl. Chir. v. 1, lib. 1, § 24.

to draw their names and their writings from the oblivion to which they have been quietly consigned. The French writers on this subject, MAITRE-JAN, ST. YVES, and JANIN, were more respectable than their cotemporary brethren in other countries. The anatomy of the organ began to be more carefully cultivated by the Germans about the middle of the eighteenth century, when ZINN, Professor of Anatomy at Göttingen, published his excellent *Descriptio Anatomica Oculi Humani.* At a more recent period, SOEMMERING produced his *Icones Oculi Humani*, a work of unrivalled beauty and accuracy, exhibiting an almost perfect set of engravings. Professor FRED. ARNOLD has lately enriched this department of anatomy with two important works; in one* of which he has considered and examined all the principal points in the structure of the eye, while in the other† he has exhibited its anatomy in a series of new and beautiful figures. This anatomical work may be consulted with interest and instruction, even after that of SOEMMERING: it carries our knowledge farther, especially in the minute composition of the organ. An acquaintance with these works is necessary to those, who wish to understand the subject thoroughly.

The pathology of the eye was in a very imperfect state until within recent times. BOERHAAVE made an attempt on the subject, but his work, *De Morbis Oculorum*, is of no value. Some idea may be formed of the amount of his pathological knowledge, from his assertion about the power of mercury to dissolve cataracts; he says, "*mercurius sæpe perfectas cataractas solvit.*"

The Germans have had the greatest share in advancing our knowledge of ophthalmic diseases. RICHTER, Surgical Professor at Göttingen, deservedly enjoyed the highest reputation in Germany, both for his general knowledge of Surgery, and for his acquaintance with diseases of the eye, to which he paid great attention in his practice and writings. In his *Chirurgische Bibliothek* (*Bibliotheca Chirurgica*), which takes up the subject from the point where HALLER's *Bibliotheca Chirurgica* leaves off, and comes down to 1797, he has carefully analyzed all new publications on ophthalmic disease. The best account of the subject, at the time of its publication, is to be found in his *Anfangsgründe der Wundarzneykunst*, (*Elements of Surgery*,) of which the whole third volume and part of the second are devoted to diseases of the eye.

But the most important era in the history of ophthalmic surgery, is the establishment of the Vienna school of ophthalmology. The Austrians have not only the honor of having instituted the first public establishment expressly appropriated to the advancement of this hitherto neglected branch of the profession, but of having preceded all the rest of Europe by many years. The views which directed the formation of this institution were so judicious, and the persons successively appointed to preside over it showed themselves so well fitted for the task, by their talents and knowledge, that the ophthalmic department of surgery has probably been more improved by this school, than by the previous exertions of all other countries. The establishment owes its origin to JOSEPH BARTH, a native of Malta, who repaired to Vienna, in order to indulge a strong inclination, which he had felt from his earlier years, for the study of anatomy and surgery. His attention was accidentally directed to diseases of the eye, from seeing many persons in a state of hopeless blindness. His proficiency in this department was soon well known; and hence he was appointed lecturer on ophthalmic sur-

* Anatomische und Physiologische Untersuchungen uber das Auge des Menschen; 4to. 1832.

† Tabulæ Anatomicæ; folio, fasciculus II.

gery in the university of Vienna, in 1773. Soon afterwards, certain wards were assigned for ophthalmic patients, in the general civil hospital, and a regular course of oral and clinical instruction was established. BARTH wrote nothing except a short tract on the mode of performing extraction without an assistant; but he is considered to have set the example of those new and more correct views of ophthalmic disease, which are disclosed in the works of various German writers.*

SCHMIDT, who was educated by BARTH, published a work on diseases of the lachrymal organs, and a valuable essay on Iritis. He also edited in conjunction with Professor HIMLY, of Göttingen, an interesting periodical, devoted to ophthalmology (*Ophthalmologische Bibliothek*), of which three volumes appeared, from 1801 to 1807.

BEER is more generally known than either BARTH or SCHMIDT, as he was professor of ophthalmic medicine in the university of Vienna, for many years, at a time when the high reputation of the school attracted students from all parts of Europe, and as he published many works. The last and principal of these,† in 2 vols. 8vo, 1812 and 1817, devoted to the history, pathology, treatment, and operative surgery of the eye, was the most comprehensive work on the subject at the time of its publication. It contains accurate descriptions and histories, and consequently, sound diagnostic precepts; but I cannot speak so favorably of the pathology and treatment. The compendium of WELLER,‡ which was translated by the late Dr. MONTEATH of Glasgow, is chiefly founded on the work of BEER.§

Professor HIMLY published, in 1800, his observations on the effect of certain narcotics in dilating the pupil, and on the advantages to be derived from their use in various diseases and operations on the eye.

LANGENBECK, professor of anatomy and surgery at Göttingen, where he succeeded RICHTER, has kept up the reputation of the university for general and ophthalmic surgery. In his *Chirurgische Bibliothek*, which begins from the termination of RICHTER's, and which, in a second series, under the title of *Neue Chirurgische Bibliothek*, has been continued nearly to the present time, he has noticed and analyzed all new books on diseases of the eye.

The *Journal der Chirurgie und Augen-heilkunde* of GRAEFE and WALTHER, which has been regularly published since 1820, and the *Magazin* of RUST, contain numerous contributions and notices respecting this department of surgery. In 1830, Professor VON AMMON of Dresden, began the public-

* BEER has given a biographical account of BARTH, in the Medicinische Jarbücher, vol. v., p. 169.

† Lehre von den Augenkrankheiten, als Leitfaden zu seiner öffentlichen Vorlesungen.

They who are inclined to study the history of ophthalmology, will find assistance from a work of BEER, on the plan of HALLER's Bibliotheca Chirurgica. It is in German, with a German and a Latin title. The latter is Bibliotheca Ophthalmica, in qua Scripta ad Morbos Oculorum facientia, a rerum initiis usque ad finem anni 1797, breviter recensentur; it is in three thin volumes 4to. In his Syntagma de Ophthalmologia veterum, WALLROTH has brought together, from the earliest writers, all that they have said respecting the anatomy, physiology, and diseases of the eye.

‡ Die Krankheiten des menschlichen Auges, ein praktisches Handbuch fur angehende Aerzte. The third edition, which is considerably enlarged, bears date, Berlin 1826.

§ In the first volume of the Quarterly Journal of Foreign Medicine and Surgery, there is an interesting description of the Medical School of Vienna, in which the arrangements of the ophthalmic department are particularly noticed.

BEER has given a minute account of the ophthalmic clinical department, (Augen clinik,) according to its new arrangement in 1812, in the Medicinische Jarbucher des Kaiserl. Königl. Oesterreichischen Staates; vol. iv. st. 4, pp. 157—173.

ation of a quarterly periodical, devoted to this subject exclusively, under the title of *Zeitschrift für die ophthalmologie:* five volumes had appeared, when the work was discontinued in 1837. Professor Ammon then devoted himself to an undertaking, for which he had been long collecting materials; namely, a large work in folio, entitled *Clinical Representations of the Diseases and Malformations of the Human Eye, Eyelids, and Lachrymal Organs, from Original Observations and Investigations.* The first and second parts were published at Berlin in 1838. The former, on *Diseases of the Eye*, contains twenty-three colored plates, on which three hundred and seventy-seven figures are represented; the latter, on *Diseases of the Eyelids, Orbit, and Lachrymal Apparatus*, has two hundred and ten figures on twelve plates. The third part, which is to exhibit the malformations of the eye and its appendages, has not yet reached this country. The author proposes to publish subsequently a manual of ophthalmic medicine, which will be a scientific and practical commentary on the facts exhibited in the Clinical Representations. These Clinical Representations, which are very creditable to the industry and perseverance of the Author, contain many interesting and instructive facts and delineations. We could not expect to have nearly six hundred figures well executed. It is difficult and costly even to approach to accuracy in colored engravings of morbid changes; and this difficulty is particularly felt in the eye. Accordingly, while many of Von Ammon's figures fail entirely as representations of morbid phenomena, I cannot speak very favorably of their execution generally; they are far too numerous to be done well.

From the sources now mentioned, a knowledge may be obtained of the numerous publications, which have appeared in Germany on this apparently favorite subject. I cannot pretend to notice them in detail; but shall refer to the most useful and interesting, in treating of particular subjects. I will only mention two recently published general and comprehensive works, by authors of experience and reputation; viz., the *Handbuch der Theoretischen und Praktischen Augen-heilkunde*, in 3 vols. 8vo, by A. Rosas, the present professor of ophthalmic medicine in the university of Vienna; and the *Lehre von den Augenkrankheiten* of J. C. Juengken, in one vol. 8vo, of nearly one thousand closely printed pages. The latter author had previously published (in 1829) a volume nearly as large on the operative surgery of the eye.

The first impulse to the scientific study of ophthalmic medicine and surgery in England, was given by the London Ophthalmic Infirmary, which was established in 1804, but not thrown open to students for the purposes of observation and instruction, till 1810. Mr. Saunders, who founded it, in conjunction with Dr. Farre, had received a regular education in anatomy and surgery at St. Thomas' and Guy's Hospitals. We are indebted to him for the important improvement of operating for cataract on infants; and his instructive posthumous observations, edited by his friend and colleague,* leave no doubt that, if his life had been spared, he would have done much more for the improvement of the science.

Dr. Farre set the example, at this infirmary, of applying the general principles of pathology and therapeutics to the elucidation and treatment of ophthalmic diseases. In the clinical illustration of cases, the exposition of curative indications, and simplicity of treatment, he could not be surpassed. All who have had the advantage of his instructions, will remember them with gratitude and respect; and will regret that he has not communicated

* A Treatise on some Practical Points relating to the Diseases of the Eye, by the late J. C. Saunders. Second Edition. 1816.

to the public, through the press, the interesting results of his long practice, his close observation, and mature reflection.

The example of the Vienna Ophthalmic school, has been followed in the principal cities of Germany;* while that of the London Ophthalmic Infirmary has led to the formation of similar institutions in many parts of England, and even in the foreign dependencies of this country, for example in the East Indies. Hence ample opportunities now exist for the study of ophthalmic diseases; while from the knowledge of the subject being generally diffused through the profession, patients afflicted with disorder of this precious organ, may find effectual relief in almost all situations. Of the institutions devoted to diseases of the eye in this kingdom, two deserve particular mention, those of Glasgow and Birmingham; since the intelligent and able surgeons who preside over them, not only lecture regularly on the subject,† but have communicated the results of their observations to the profession in highly interesting and valuable publications.‡

Scarpa's *Observations on the principal Diseases of the Eye*, which have been translated into English by Mr. Briggs, were considered a valuable contribution to surgical literature, when they first appeared (in 1801). They are far behind the present state of knowledge on the subject.

[Ophthalmic Medicine has not received in the United States, the attention bestowed upon it in Europe. It has been cultivated assiduously and successfully by a few practitioners, but the mass of the profession have devoted little or no attention to it. The Treatise of Dr. Frick,§ the Manual of Dr. Littell,‖ the small popular treatise of Dr. Wallace,¶ with some contributions in the medical journals, constitute the whole of our Ophthalmic literature.

This condition of the science must in a great degree be attributed to its not being at present taught in our medical schools. In all of these,** without a single exception, it forms a part of the general surgical course, and is summarily treated, or rather professed to be treated, in three or four lectures. A very creditable effort has, however, been made by the College of Physicians and Surgeons, New York, to afford to students the means of acquiring a knowledge of ophthalmic diseases. Lectures on the subject, with clinical instruction at the New York Infirmary for

* The various clinical institutions established on the continent for the treatment and study of Diseases of the Eye, are enumerated by Dr. Beger in Ammon's Zeitschrift; vol. v. Das Auge vom Standpuncte der Medicinal Polizei betrachtet. In the same volume, the present state of the ophthalmic clinic in Vienna and Prague is described; Ueber eine Ophthalmologische Reise nach Wien und Prag, von Dr. Thune.

[† Dr. Mackenzie is Lecturer on the Eye in the University of Glasgow, and Mr. Middlemore is Professor of Ophthalmic Medicine in the Royal School of Medicine, Birmingham. Lectures on the Eye are also given in the Manchester Royal School of Medicine and Surgery by Mr. Walker, and in Guy's Hospital School London, by Mr. Morgan.]

‡ W. Mackenzie, Practical Treatise on Diseases of the Eye; third edition, 1840. R. Middlemore, Treatise on Diseases of the Eye, and its Appendages; 2 vols. 8vo, 1835.

§ A Treatise on the Diseases of the Eye; including the doctrines and practice of the most eminent modern surgeons, and particularly those of Prof. Beer. By George Frick, M. D., Baltimore, 1823.

‖ A Manual of the Diseases of the Eye, 2d edition. By S. Littell, Jr., M. D., Philadelphia, 1846.

¶ A Treatise on the Eye, containing discoveries of the causes of near and far sightedness, and of the affections of the retina, with remarks on the use of medicines as substitutes for spectacles. By Wm. Clay Wallace, Oculist. New York, 1839.

[** Some years ago a chair of Ophthalmic Medicine and Surgery was established in the Vermont Academy of Medicine, but it has lately been abolished.]

Diseases of the Eye, form part of the Spring course established under the auspices of the school.

This example, it is to be hoped, will be imitated. The means of instruction are ample, a sufficient number of Institutions especially designed for the treatment of those laboring under Ophthalmic diseases, being at the present period in successful operation. Thus in New York, the Eye and Ear Infirmary established in 1820, in Boston, the Massachusetts Charitable Eye and Ear Infirmary, and in Philadelphia the Wills Hospital for the Blind and Lame, a noble charity, afford the amplest means for clinical instruction. Eye Infirmaries have also been established in Albany, Baltimore, Rochester, &c., which, with due encouragement, might be made available for the same purpose.]

Pl. I.

Fig. 2.

Fig. 1.

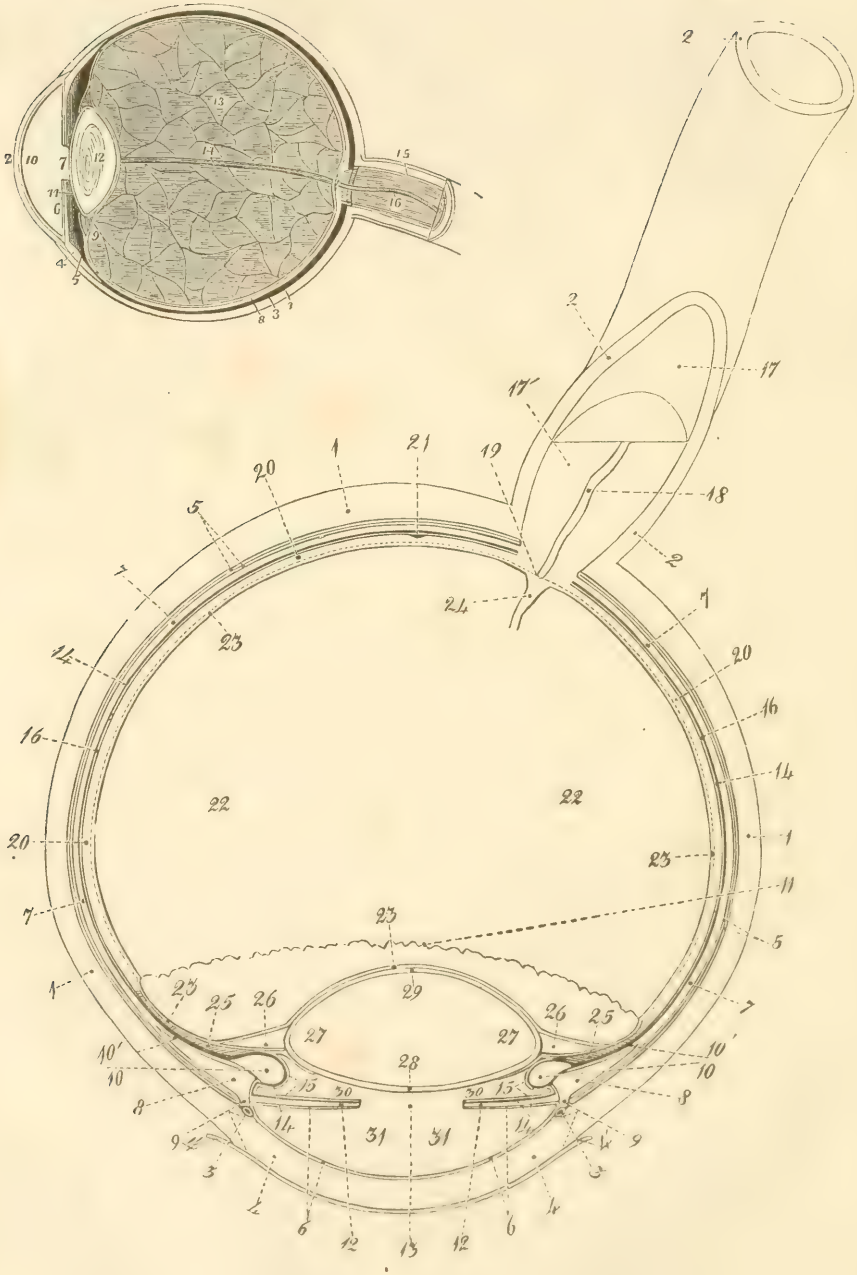

DESCRIPTION OF PLATE I.

Fig. 1.—Horizontal Section of the Eyeball.

1. Sclerotica.
2. Sheath of the optic nerve, or canal of Fontana.
3. Circular venous sinus of the iris.
4. Proper substance of the cornea.
4′. Conjunctiva extending over the cornea.
5. Arachnoidea oculi.
6. Membrane of the anterior chamber of the aqueous humor. Of the two dotted lines, one points to the membrane of Descemet, the other to the supposed continuation of that membrane over the anterior surface of the iris.
7. Choroid.
8. Annulus albidus.
9. Ciliary ligament.
10, 10′. Ciliary body, consisting of (10′) a pars non-fimbriata, and (10) a pars fimbriata formed by the ciliary processes.
11. Ora serrata of the ciliary body.
12. Iris.
13. Pupil.
14. Membrane of the pigment.
15. Delicate membrane lining the posterior chamber of the aqueous humor.
16. Membrane of Jacob.
17. The optic nerve surrounded by its general neurilema.
17′. The fibres of the optic nerve, consisting of fasciculi of primitive tubules.
18. Central artery of the retina.
19. Papilla conica of the optic nerve.
20. Retina. The situation of its vascular layer is indicated by a dotted line.
21. Central transparent point of the retina.
22. Vitreous body.
23. Hyaloid membrane.
24. Canalis hyaloideus.
25. Zonula ciliaris. In the plate, none of its fimbriated part is seen, being concealed by the ciliary processes.
26. Canal of Petit.
27. Crystalline lens.
28. Anterior wall of the capsule of the lens.
29. Posterior wall of the capsule of the lens.
30. Posterior chamber of the aqueous humor.
31. Anterior chamber of the aqueous humor.

Fig. 2.—A Longitudinal Section of the Globe of the Eye.

1. The sclerotic coat.
2. The cornea.
3. The choroid coat.
4. The ciliary ligament.
5. The ciliary processes.
6. The iris.
7. The pupil.
8. The retina.
9. The canal of Petit, which encircles the lens.
10. The anterior chamber of the eye, containing the aqueous humor.
11. The posterior chamber.
12. The lens enclosed in its proper capsule.
13. The vitreous humor enclosed in the hyaloid membrane.
14. A tabular sheath of the hyaloid membrane.
15. The neurilema of the optic nerve.
16. The arteria centralis retina.

Pl. II.

Fig. 3.

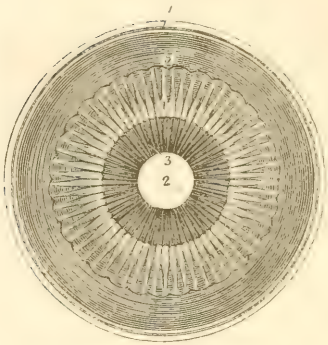

Fig. 7.

Fig. 9.

Fig. 4.

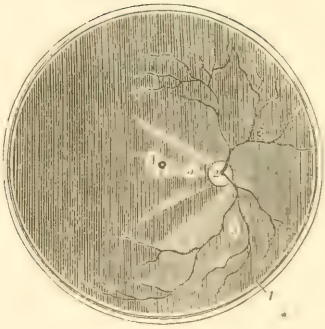

Fig. 5.

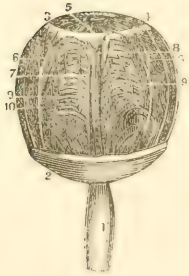

Fig. 6.

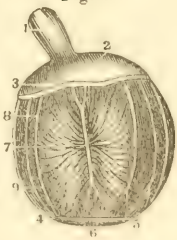

Fig. 8.

DESCRIPTION OF PLATE II.

Fig. 3.—The Anterior Segment of a Transverse Section of the Globe of the Eye, seen from within.

1. The divided edge of the three coats—the sclerotic, choroid and retina.
2. The pupil.
3 The iris; the surface presented to view in this section being the uvea.
4. The ciliary processes.
5. The anterior border of the retina.

Fig. 4.—The Posterior Segment of a Transverse Section of the Globe of the Eye, seen from within.

1. The divided edge of the three coats—the membrane covering the whole internal surface is the retina.
2. The entrance of the optic nerve with the arteria centralis retinæ piercing its centre.
3.3. The ramifications of the arteria centralis.
4. The foramen of Sœmmering; the shade from the sides of the section obscures the limbus luteus which surrounds it.
5. A fold of the retina, which generally obscures the foramen of Sœmmering after the eye has been opened.

Fig. 5.—A View of the Choroid Coat with its Vessels injected.

1. The optic nerve.
2. Posterior portion of the sclerotica, cut off circularly.
3.4. The ciliary ligament.
5. The iris.
6. Ciliary nerves.
7. Long and short arteries of the choroid coat.
8. Long internal ciliary arteries of the choroid coat.
9.10. Vasa vorticosa.

Fig. 6.—A View of the Veins of the Choroid Coat, as distended by Blood.

1. The optic nerve.
2.3. Section of the sclerotic coat.
4.5. The circumference of the iris.
6. The pupil.
7. The veins of the choroid coat:
8.9. The ciliary nerves.

Fig. 7.—An Anterior View of the Iris as attached to the Choroid Coat.

1. The choroid coat.
2.3. The ciliary ligament.
4. The great circumference of the iris.
5. The anterior face of the iris.
6. Its lesser circumference.
7. Shows the striated or ray-like appearance of the iris.
8. The pupil.
9. The ciliary nerves dividing as they penetrate the ciliary ligament.
10.11. The ciliary blood-vessels.

Fig. 8.—An Anterior View of the Choroid, Iris and Membrana Pupillaris of a Fœtus of 7 Months, highly injected and magnified 4 Diameters.

1.2. The choroid coat.
3. The ciliary ligament.
4. The iris.
5. The membrana pupillaris with its vessels minutely injected.
6.6. The long ciliary arteries.
7.7. The vasa vorticosa.

Fig. 9.—A Front View of the Retina, with the Lens in its Capsule.

1.1. The retina.
2.2. Its anterior limits.
3.3. The lens in its capsule
4. The central foramen of the retina, seen through the transparent lens and vitreous humor.

Pl. III.

Fig. 12.

Fig. 14.

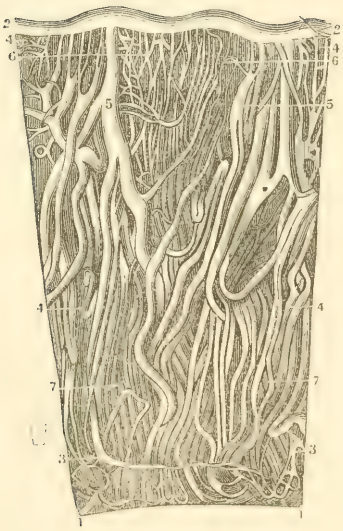

Fig. 13.

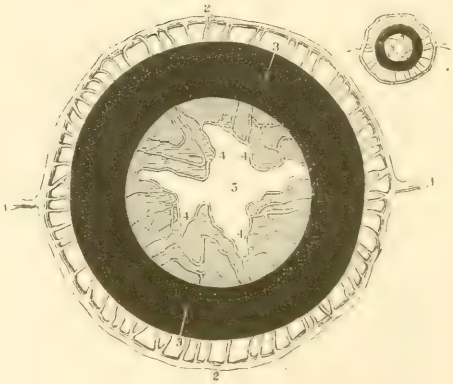

Fig. 10.

Fig. 11.

DESCRIPTION OF PLATE III.

Fig. 10.—An Anterior View of the Iris.

Fig. 11.—A Posterior View of the Iris or Uvea.

Fig. 12.—An Anterior View of the Iris and Membrana Pupillaris of an Infant of 6½ Months, with their Vessels injected—highly magnified.

1.1. The two long ciliary arteries.
2. The circle around the iris, formed by their anastomosing branches.
3. Branches which arise from this circle, and run in front of the iris.
4. Anterior face of the iris.
5. Extremities of the same arteries, forming arches between the two layers of the membrana pupillaris.
6. The centre of the membrana pupillaris, usually free from vessels, where the membrane ruptures spontaneously.

The small figure at the side represents the *natural size* of this piece.

Fig. 13.—A Posterior View of the same, also much magnified, and with the Membrana Pupillaris Ruptured.

1.1. Long ciliary arteries.
2. The greater arterial circle of the iris.
3. The posterior face of the iris covered with pigmentum nigrum.
4. Flaps formed by the remains of the pupillary membrane.
5. The centre of the pupil.

The small figure at the side represents the *natural size* of the piece.

Fig. 14.—A Segment of the Anterior Face of the Iris with its Vessels injected—magnified 25 Diameters.

1.1. A portion of the pupillary circumference of the iris.
2.2. A part of its greater circumference surrounded by a branch of the long ciliary artery.
3. Part of the lesser circle of the iris.
4.4. Part of its greater circle.
5.5. Three arteries which are larger than the others, and coming from the greater circle are lost in the iris.
6. Smaller arteries arising from these.
7. Branches of the larger arteries, which are lost in the smaller circle of the iris.

An outline of the *natural size* of this piece is seen on the side of the figure.

Pl. IV.

Fig. 17.

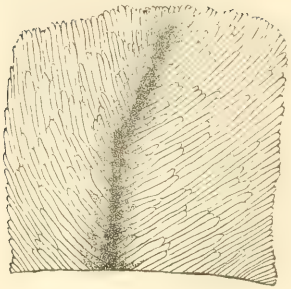

Fig. 19.

Fig. 20.

Fig. 18.

Fig. 15.

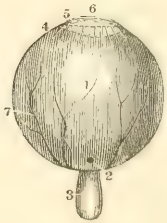

Fig. 21.

Fig. 16.

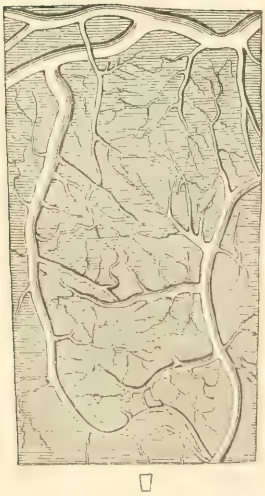

Fig. 22.

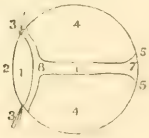

Fig. 23.

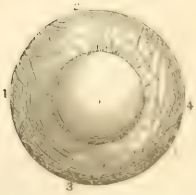

DESCRIPTION OF PLATE IV.

Fig. 15.—The External Face of the Retina, with the Lens attached to it.

1. The retina.
2. Its central foramen.
3. The optic nerve deprived of its sheath.
4. The ciliary body.
5. The distance of this body from the lens.
6. The lens in its capsule.

Fig. 16.—A portion of the Retina of an Infant, with its vessels injected and magnified 25 Diameters.

An outline of the natural size of this piece is seen just below the main cut.

Fig. 17.—Part of the Retina of a Frog, seen from the Outer Surface—Magnified 300 times.

Fig. 18.—Papillæ of the Retina of the Frog, seen from the side turned towards the Vitreous Humor: the four Higher Rows are seen Sideways—Magnified 300 times.

Fig. 19.—A Front View of the Crystalline Humor or Lens, in the Adult.

Fig. 20.—A Side View of the Adult Lens.

1. Its anterior face.
2. Its posterior face.
3.3. Its circumference.

Fig. 21.—A Magnified View of the Lens of a Fœtus of 8 Months, seen on its Anterior Face, with the marks of its Division into the Three Pieces that form it at that period.

Fig. 22.—A Side View of the Vitreous Humor and Lens of a Fœtus at 8 Months, showing the Shape and Direction of the Canal of Petit.

1. The lens.
2. Its anterior face.
3. Filaments which unite the circumference of the lens to the ciliary processes.
4. The hyaloid membrane surrounding the vitreous humor.
5. The reflexions of this membrane at the back of the eyeball.
6. The hyaloid canal for the artery to the lens.
7. Its posterior orifice by which the posterior artery enters.
8. The canal of Petit around the lens.

Fig. 23.—A View of the Left Eye of a Fœtus of 6 Months, magnified 2 Diameters—showing the Vessels in the Conjunctiva.

1.2.3.4. The internal, superior, external and inferior parts of the eyeball, with the blood-vessels injected.
5. The transparent cornea.

Pl. V.

Fig. 25.

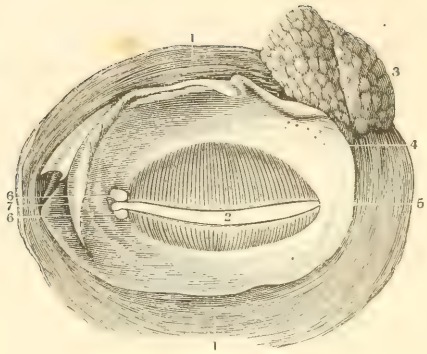

Fig. 27.

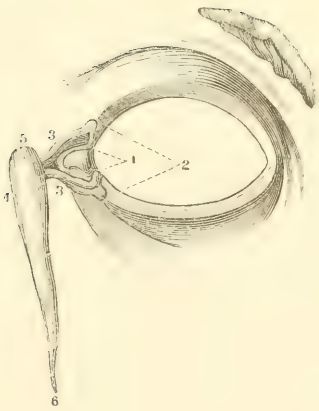

Fig. 24.

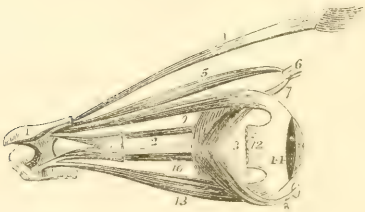

Fig. 26.

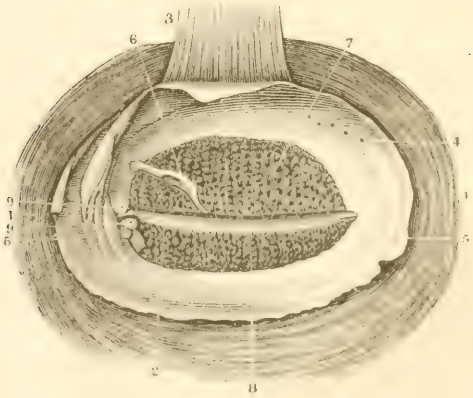

DESCRIPTION OF PLATE V.

Fig. 24.—A View of the Muscles of the Eyeball, taken from the Outer Side of the Right Orbit.

1. A small fragment of the sphenoid bone around the entrance of the optic nerve into the orbit.
2. The optic nerve.
3. The globe of the eye.
4. The levator palpebræ muscle.
5. The superior oblique muscle.
6. Its cartilaginous pulley.
7. Its reflected tendon.
8. The inferior oblique muscle; a piece of its bony origin is broken off.
9. The superior rectus muscle.
10. The internal rectus almost concealed by the optic nerve.
11. Part of the external rectus showing its two heads.
12. The extremity of the external rectus at its insertion; the intermediate portion of the muscle having been removed.
13. The inferior rectus muscle.
14. The sclerotic coat.

Fig. 25.—A Posterior View of the Eyelids and Lachrymal Gland.

1.1. The orbicularis palpebrarum muscle.
2. The borders of the lids.
3. The lachrymal gland.
4. Its ducts opening in the upper lid.
5. The conjunctiva covering the lids.
6. The puncta lachrymalia.
7. The lachrymal caruncle as seen from behind.

Fig. 26.—A Posterior View of the Eyelids, as seen under the Microscope.

1.1. The orbicularis palpebrarum muscle.
2. The opening of the lids, through which are seen the cilia of the upper lid.
3. The levator palpebræ superioris muscle.
4. The openings of the ducts of the lachrymal gland.
5. The conjunctiva of the eyelids.
6. The conjunctiva turned back so as to show the glands which are beneath it.
7. The Meibomian glands of the upper eyelid seen through the conjunctiva.
8. The same glands of the lower lid.
9. The puncta lachrymalia.

Fig. 27.—A View of the Shape and Position of the Lachrymal Canals.

1. The puncta lachrymalia or openings of the lachrymal canals in the lids.
2. The cul de sac at the orbital end of the canal.
3. The course of each canal to the saccus lachrymalis.
4.5. The saccus lachrymalis.
6. The lower part of the ductus ad nasum.

Pl. VI.

Fig. 31.

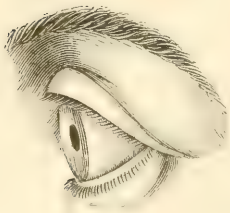

Fig. 30.

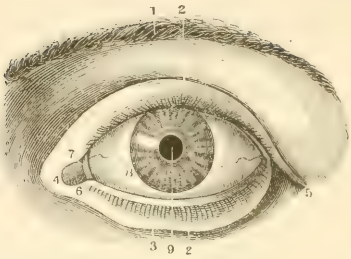

Fig. 32.

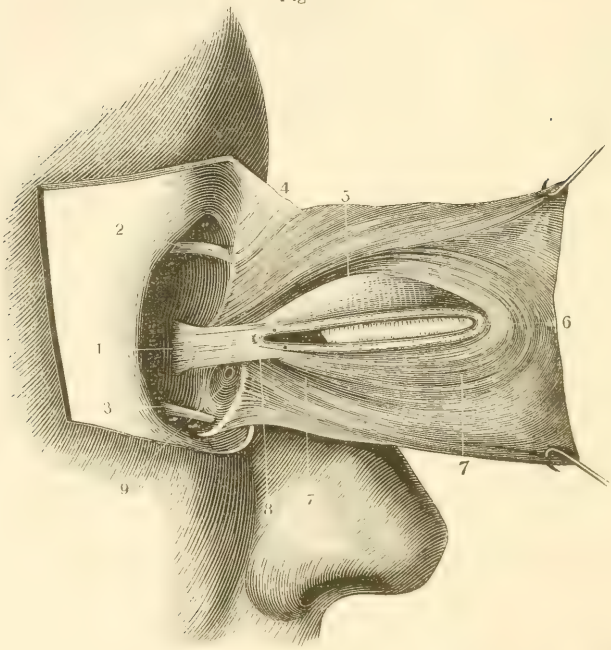

Fig. 29.

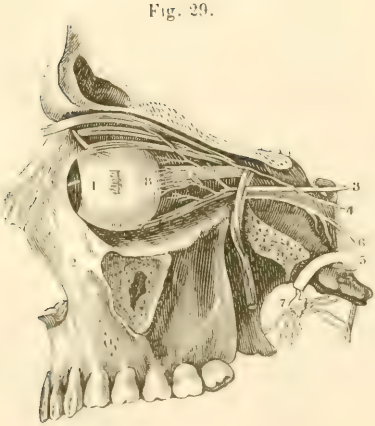

Fig. 28.

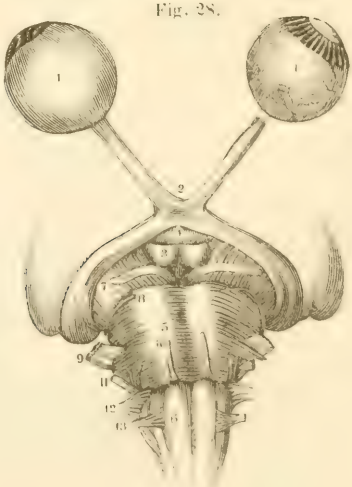

DESCRIPTION OF PLATE VI.

Fig. 28.—A View of the Second Pair or Optic Nerves, with the origin of Seven other Pairs of Nerves.

1.1. Globe of the Eye; the one on the left hand is perfect, but that on the right has the sclerotic and choroid coats removed in order to show the retina.
2. The chiasm of the optic nerves.
3. The corpora albicantia.
4. The infundibulum.
5. The pons varolii.
6. The medulla oblongata.
7. The third pair, motores oculi.
8. Fourth pair, pathetici.
9. Fifth pair, trigemini.
10. Sixth pair, motor externus.
11. Seventh pair, auditory and facial.
12. Eighth pair, pneumogastric, spinal accessory and glosso-pharyngeal.
13. Ninth pair, hypoglossal.

Fig. 29.—A View of the Third, Fourth and Sixth Pairs of Nerves.

1. Ball of the eye and rectus externus muscle.
2. The superior maxilla.
3. The third pair, or motores oculi, distributed to all the muscles of the eye except the superior oblique and external rectus.
4. The fourth pair, or pathetici, going to the superior oblique muscle.
5. One of the branches of the seventh pair.
6. The sixth pair, or motor externus, distributed to the external rectus muscle.
7. Spheno-palatine ganglion and branches.
8. Ciliary nerves from the lenticular ganglion, the short root of which is seen to connect it with the third pair.

Fig. 30.—A Front View of the Left Eye, moderately Opened.

1. The supercilia.
2. The cilia of each eyelid.
3. The inferior palpebra.
4. The internal canthus.
5. The external canthus.
6. The caruncula lachrymalis.
7. The plica semilunaris.
8. The eyeball.
9. The pupil.

Fig. 31.—A Side View of the same Eye, showing that the Cilia of the Upper Lid are Concave upwards, and those of the Lower Lid Concave downwards. The general Convexity of the Eyeball is also seen.

Fig. 32.—A View of the Tensor Tarsi or Muscle of Horner, as shown by a Dissection of the Internal Surface of the Eyelids.

1. Origin of the tensor tarsi muscle, from the superior part of the os unguis, just in advance of the vertical suture, between the os planum and the os unguis.
2. Superior oblique muscle of the eyeball.
3. Inferior oblique muscle of the eyeball.
4. Origin of the orbicularis palpebrarum, from the nasal process of the os maxillare superius, internal angular process of the os frontis and the contiguous part of the os unguis—also along the whole superior margin of the internal palpebral ligament.
5. A portion of the palpebral conjunctiva.
6. External palpebral ligament and canthus of the eyelid.
7.7. Lower portion and terminating fibres of the orbicularis palpebrarum.
8. Bifurcation of the tensor tarsi muscle at the base of the caruncula lachrymalis. The insertions of the muscle near the puncta are also shown.
9. Lachrymal sac.

Pl. VII.

Fig. 144.

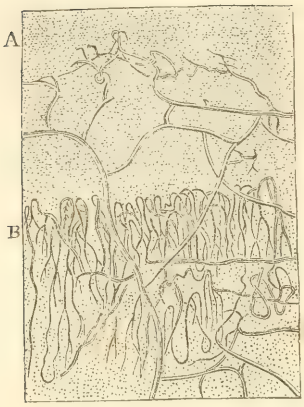

Fig. 146.

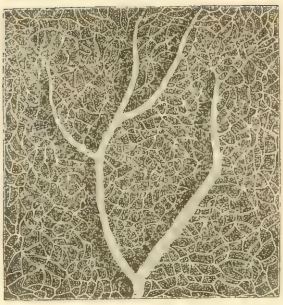

Fig. 147.

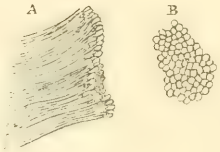

Fig. 145.

Fig. 148.

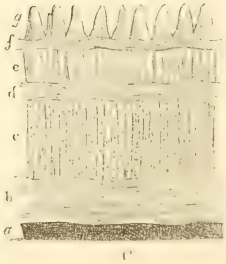

Fig. 150.



Fig. 149.



DESCRIPTION OF PLATE VII.

Fig. 144.—Blood-vessels of the Cornea.

A. Superficial vessels belonging to the conjunctival layer, and continued beyond the margin of the cornea.

B. Vessels of the sclerotic running their course and returning at the margin of the cornea.

Fig. 145.—A portion of the Choroid from the eye of the Ox, magnified 56 diameters.

a a a. Veins covered by a single layer of pigment cells.

b b. Ramifications of the veins near the ciliary ligament, covered with less regular pigment cells.

c c. Intervals between the veins more thickly covered with the pigment cells.

Fig. 146.—Capillaries in Vascular Layer of Retina, largely magnified.

Fig. 147.—A portion of the Retina of the Sheep.

A. The cylindrical fibres, viewed from the outer side; at the right hand border some of the papillæ are seen, in which the fibres terminate on the inner surface of the retina.

B. Papillæ seen on the inner surface of the same retina.

Fig. 148.—A thin Perpendicular Section of the Retina of the Hooded Crow, (Corvus Cornix,) which had been Hardened by Maceration in Spirits.

a. Internal lamina of choroid.

b. Layer of cellular tissue, in which the fibres of the retina radiate out.

c. Perpendicular portion of the fibres of the retina.

d. Second layer of cellular tissue, containing a network formed by branches of the arteria centralis retinæ, and giving a sheath of this vascular layer of retina to the nervous fibres.

e. Larger nervous fibres which have acquired this sheath.

f. Third cellular layer perforated by the papillæ *g.*

Fig. 149.—Represents the Triple Division of the Lens and the Course of its Fibres.

Fig. 150.—Represents the Tooth-like or Serrated Margins of the Fibres of the Lens.

Pl. VIII.

Fig. 151.

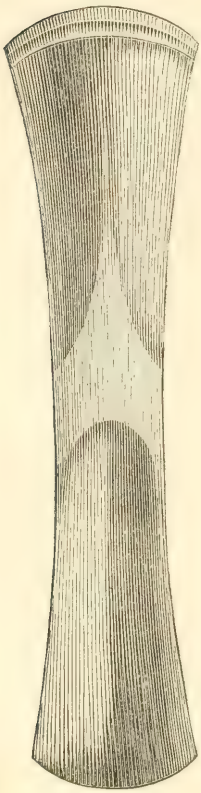

Fig. 152.

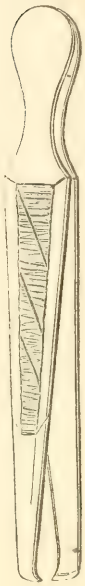

Fig. 153.

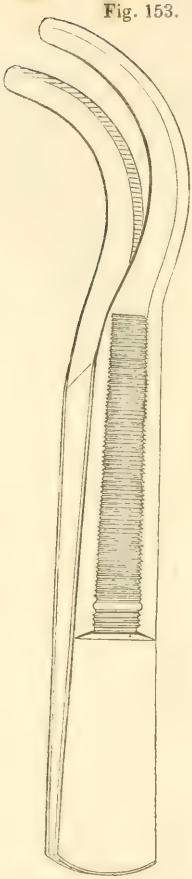

Fig. 154.

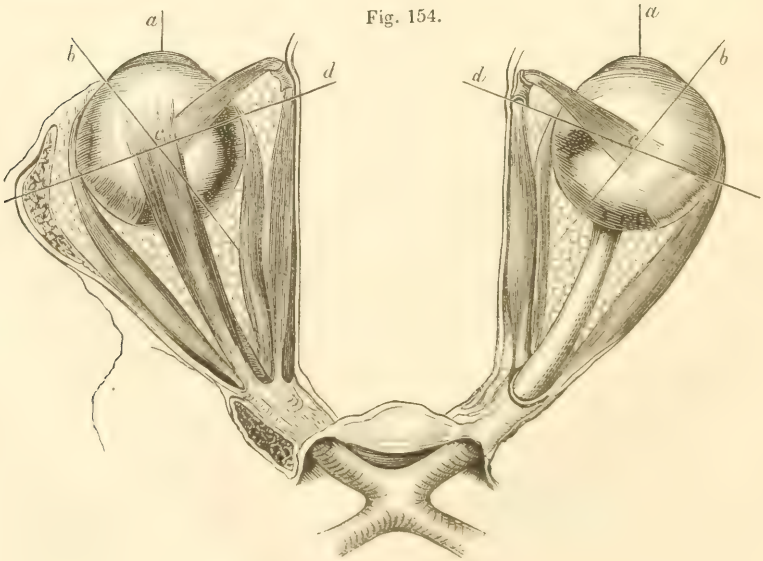

DESCRIPTION OF PLATE VIII.

Fig. 151.—Horn Spatula for introducing behind the Eyelids in operating for Entropium and Trichiasis. (See p. 154.)

Fig. 152.—Forceps for Plucking out Eyelashes.

Fig. 153.—Graefe's Entropium Forceps.

Fig. 154.—Diagram illustrating the Axes of Revolution on which the Eyeball is moved by its different Muscles. The Muscles seen from above are in a state of Equilibrium.

a a. The parallel optic axes.
c c. The centres of revolution.
b b. The axis of revolution for the oblique muscles.
d d. The axis of revolution for the superior and inferior recti.

Pl. IX.

Fig. 155.

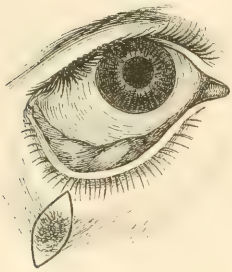

Fig. 156.



Fig. 157.

Fig. 158.

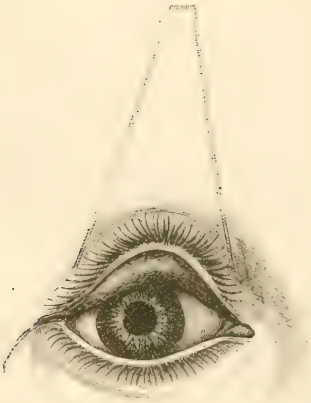

Fig. 159.

DESCRIPTION OF PLATE IX.

Figs. 155, 156.—Represent Ectropium from Caries of the Orbit, and Prof. Ammon's Operation for its Cure. (See p. 146.)

Fig. 157.—Illustration of Fricke's Operation for Ectropium by Transplantation of a portion of Skin. (See p. 147.)

Figs. 158, 159.—Illustration of T. Wharton Jones' Operation for Ectropium. (See Note, p. 147.)

Pl. X.

Fig. 160.

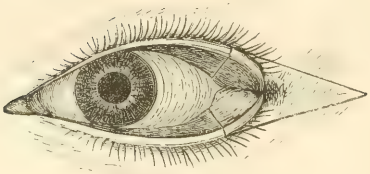

Fig. 161.

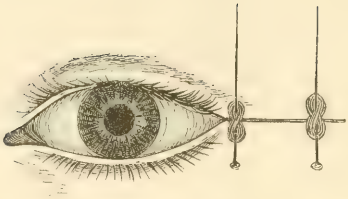

Fig. 162.

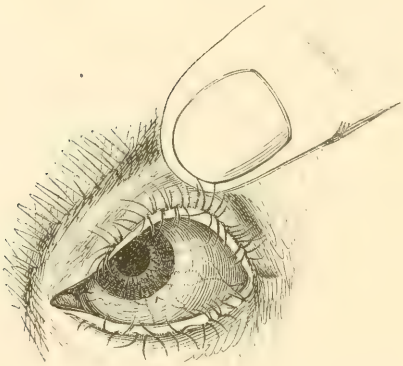

Fig. 163.

Fig. 164.

DESCRIPTION OF PLATE X.

Figs. 160, 161.—Illustration of Eversion at the External Commissure and Outer Parts of the Lids in consequence of Contraction of the Skin of the Temple from bad Cicatrices, and of Walter's Operation of Tarsoraphia. This consists in the Excision of the Tarsal edges of both Eyelids where they are Everted, together with the Commissure, and a Triangular Piece of the neighbouring Integument of the Temple, the Base towards the Eye and the Apex towards the Ear; and then uniting the edges of the wound by two Sutures.

Fig 162.—Trichiasis. (See p. 157.)

Fig. 163.—Medullary Fungus of the Eyeball. (See p. 697, et seq.)

Fig. 164.—Melanosis of Eyeball, in which the Iris has been detached in one part of its Circumference, and the Black Mass is making its appearance from behind, as also through the Sclerotica near the Cornea.

Pl. XI.

Fig. 165.

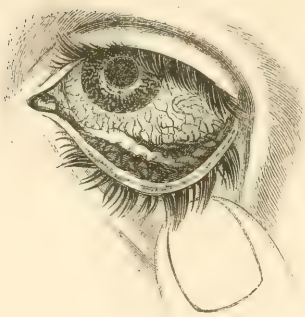

Fig. 166.

Fig. 167.

Fig. 168.

Fig. 169.

DESCRIPTION OF PLATE XI.

Fig. 165.—Represents Catarrhal Inflammation of the Conjunctiva. (See p. 223, et seq.)

Fig. 166.—Represents Granular Conjunctiva of Upper Lid. (See p. 246, et seq.)

Fig. 167.—Represents Dislocation of the Lens into the Anterior Chamber. (See p. 488, et seq.)

Fig. 168.—Represents Trichosis Bulbi. (See pp. 321 and 326.)

Fig. 169.—Phlyctenular or Scrofulous Ophthalmia, and a burst Phlyctenula on the Cornea with Fasciculas of Vessels running from the Conjunctiva into it. (See p. 301, et seq.)

Pl. XII.

Fig. 170.

Fig. 171.

Fig. 174.

Fig. 172.

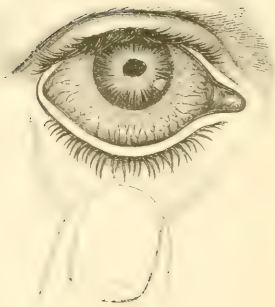

Fig. 173.

Fig. 175.

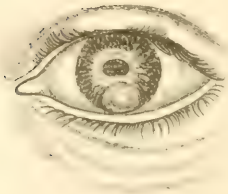

DESCRIPTION OF PLATE XII.

Fig. 170.—Exhibits Natural Appearance of the Iris and Pupil viewed in Profile.

Fig. 171.—Shows the Appearance of the Iris and Pupil in Profile, when the Iris is inclined towards the Cornea.

Fig. 172.—Represents Inflammation of the Iris. (See p. 384.)

Fig. 173.—Represents Arthritic Iritis. (See p. 411.)

Fig. 174.—Represents Arthritic Inflammation of the Internal Tunics. (See p. 474.)

Fig. 175.—Represents a Cyst in connection with the Iris. (See p. 425.)

ANATOMY OF THE EYE-BALL.

The human eye is very nearly spherical, and hence have arisen the expressions applied to it in English, of *globe*, *ball*, and *apple* of the eye, and the corresponding terms in other languages; the Germans speak of the *eye-apple* (*augapfel*,) in the same sense as we use *eye-ball*. When measured on the outside, the antero-posterior and transverse diameters are nearly the same; the former may be a little longer than the latter. The average length of each is somewhat less than an inch, [about 19-20ths of an inch.] A vertical section dividing it into an anterior and a posterior half, presents a circular outline; but a horizontal division into an upper and lower half, exhibits a posterior portion, which is part of a larger sphere, and an anterior, which is a small segment of a smaller sphere. The former of these constitutes five-sixths, the latter, one-sixth, of the eye-ball. The greatest deviation from the spherical figure of the globe occurs where these two portions are united; a slight circular depression being produced where the posterior division or segment of the larger sphere bends inwards to join the anterior, or segment of the smaller sphere.

The real size of the eye varies little in different individuals: the apparent differences depend on the size of the palpebral fissure, and the depth at which the eye-ball is placed in the orbit.

The essential constituents of the eye are, transparent media to refract the rays of light; a nervous expansion to receive the impression produced by the rays thus refracted; and certain membranous opaque coverings, surrounding, connecting, and protecting the foregoing parts, as well as contributing to their more perfect action.

The component textures of the eye-ball are usually arranged under the two-fold division of *coats* and *humours*. The membranous coverings and the nervous expansion, constitute the *coats*, *tunics*, or membranes: the *humours* are the transparent media, with the exception of the cornea, which belongs to the coats. The arrangement, although not founded on the clearest grounds, is convenient enough; and we have the further reason for retaining it, of its being established in the language of anatomy by long and universal usage. We must remember, however, that the word *humour* is used in a merely technical sense, being inapplicable in its ordinary acceptation of fluid, to the crystalline lens and capsule, and to the vitreous body.

The external stratum of the globe is composed of the sclerotica [1. fig. 2.] and cornea [2. fig. 2.]; the latter being the anterior transparent part, and the former covering the rest of the eye. When these are removed, we see a membranous covering, distinguished by its deep brown color, the choroid coat [3. fig. 2 and figs. 5 and 6.], equal in extent to the sclerotica; to this is closely united, in front, the iris, [6. fig. 2 and fig. 7.], which is placed at a short distance behind the cornea, and perforated near its centre by a round opening, called the pupil, [7. fig. 2.], for admitting the light into the interior of the eye; the removal of the choroid exposes the retina, or the nervous expansion. The three coverings just enumerated, i. e. the sclerotica with the cornea, the choroid with the iris, and the retina, are arranged one within the other, concentrically like the layers of an onion: they may be called respectively the fibrous, vascular, and nervous strata of the eye-ball.

The humours are three,—1st, the *vitreous*, [13. fig. 2.], which fills the whole concavity of the retina, and forms about four-fifths of the entire bulk of the globe; 2dly, the *crystalline*, [12. fig. 2.], called also crystalline lens, a nearly spherical body, imbedded in the front of the vitreous humour; 3dly, the *aqueous*, a small quantity of clear water, filling up the space between the cornea and the front of the crystalline lens, in which space the iris is situated.

Only the external or fibrous stratum is complete, that is, closed in all directions; the vascular layer is perforated in front by the pupil; and the nervous leaves a still greater deficiency, which is filled by the crystalline lens.

The membranous layers circumscribe a space, which may be called the cavity of the eye-ball, and which is subdivided into three unequal compartments; the posterior, and largest, bounded by the retina, contains the vitreous humour, with the imbedded lens; the two anterior, called the *chambers* of the eye, are enclosed by the cornea, crystalline, and ciliary processes, separated by the iris, through the pupillary aperture of which they communicate, and filled with the aqueous humour.

Having thus mentioned, in a general way, the parts which make up the globe of the eye, I shall make a few observations on the structure of each, with the view of rendering the description of their morbid affections more intelligible.

Sclerotica.—[1. fig. 1. and 1. fig. 2.] In dissecting and examining the eye-ball, we observe that it does not collapse, but that it retains its figure; this depends on its external investment or sclerotic coat (*Albuginea; tunica fibrosa; Lederhaut, weisse Haut, Germ.*) The word *sclerotica*, which is of Greek extraction, (from σκληρὸς) means hard; the sclerotic coat, therefore, is the firm covering of the eye; it is the most dense, compact, and unyielding texture in the organ. The cornea resembles it in compactness, density, and consequent firmness, though it is perfectly transparent, while the sclerotic is entirely opaque. In the older writers the term cornea is applied to both these structures; the cornea, properly so called, being denominated cornea lucida; and the sclerotic, cornea opaca. The sclerotic covers the posterior five-sixths of the globe, leaving in front a circular vacancy filled by the cornea. Behind, and a little on the inner or nasal side of the axis of the eye-ball, it is perforated by the optic nerve. The long and short ciliary arteries and veins, the venæ vorticosæ, and the ciliary nerves also perforate the membrane.

The firmness of the sclerotic is such that it retains its figure when divided and emptied of its contents; small portions cut out of the membrane preserve their form, and regain it immediately on the pressure being removed, after they have been squeezed together. When this coat is removed, the other component parts of the globe are so much softer and more delicate in their texture, that the ball no longer retains its regular figure.

The sclerotic coat belongs to that class of membranes which anatomists call fibrous, such as the dura mater and periosteum. Like such structures, it is white, or bluish white, somewhat glistening, and possesses some elasticity. It is made up of the same kind of fibres which compose the tendons and ligaments; and these fibres are so closely compacted and interwoven, that, in the ordinary state of the part, they can scarcely be distinguished;*

* Arnold states, as the result of careful microscopical examination, that the sclerotica really consists of condensed cellular texture. He found no appearance of primitive fibres or cylinders, but merely a cellular mass permeated by an extremely fine and close net-work of lymphatics, and he has represented these in the 2d figure of the 1st plate of his instructive and interesting work, *Anatomische und Physiologische Untersu-*

they are much less fibrous than in certain portions of the dura mater, and we might suppose the tunic to be made of condensed cellular texture. If, however, we dissect it carefully, we shall observe, in some parts, the glistening, shining aspect, which denotes a fibrous structure; while in many animals, the fibres being more loosely interwoven, are quite obvious; and in certain forms of disease, when the coat is distended, and rendered thinner, the fibrous structure is very clear. This organization gives the sclerotica that firmness which fits it for covering the softer parts of the globe. It has nothing to do with vision, but is merely subservient to the purpose of supporting, connecting, and protecting the more vascular and delicate structures composing the interior of the eye. The density and resistance of the sclerotic are so considerable, that no force, which can be applied with the fingers or forceps will lacerate it; when, therefore, the vascular parts within the globe are actively inflamed, this coat becomes so tense, as almost to convey the idea of the hardness of stone. The sclerotica is not of uniform thickness throughout. If we divide the globe into an anterior and a posterior half, by a vertical section, the sclerotica will be found much thicker in the latter than in the former division. The thickest part of the membrane is at the entrance of the optic nerve, and on the adjacent posterior aspect of the globe; it is here about one-twentieth of an inch in thickness. Tracing it forwards, we find it becoming gradually thinner, to the extent of one-third or one-half of the measure just mentioned. The thinnest portion of the membrane is at the middle, or greatest diameter of the globe: it becomes again a little thicker where it joins the cornea in front. Thus the combined action of the four recti muscles will produce a pressure on the eye-ball where the sclerotic is thinnest. These anatomical facts have suggested the hypothesis, in which the adaptation of the eye to vision at different distances is explained by changes in the length of its axes. The thinner portion of the sclerotica, however, is sufficiently firm to retain its form when removed from the eye; and we cannot tear it with the fingers or forceps.

The external surface of the sclerotica is rough and cellular. It is covered in front by the conjunctiva. Under this membrane it affords attachment to the tendons of the muscles moving the eye, which are inserted into it in the same way as tendons are attached to bones in other situations. The four recti lie upon the membrane to a considerable extent from before backwards; while, in the space circumscribed by them, it is covered by fat. The internal surface of the membrane is smooth, connected to the choroid by short, soft, and easily lacerated cellular threads, partially tinged by the dark pigment, and hence sometimes called *lamina scleroticæ fusca.*

The opposed surfaces of the sclerotica and choroid have a moist appearance, though we do not observe any distinct fluid.

The external surface and the substance of the membrane are of a pure white color, without any appearance of red vessels. In the healthy state it contains few vessels circulating red blood. It reddens, however, under the excitement of disease, when the vessels are so numerous as to

chungen über das Auge des Menschen. 4to. 1832 Mascagni had already observed and delineated the same facts; *Prodromo della grande Anatomica;* tab. 6 and 14. The microscopical researches of Arnold on the cellular texture, had led him to conclude that it consists of lymphatics, with vesicles of fat in greater or smaller number, and blood-vessels of various size. Mascagni had previously formed the same conclusion, which had been confirmed by Fohmann, from his injections of the lymphatics. The serous and fibrous membranes, being composed of cellular texture, exhibit the same structure, so far as the lymphatics are concerned.—Arnold's *Untersuchungen, Einleitung.*

give the membrane a general red tinge. The *white of the eye* depends on the sclerotica, which is seen through the semi-transparent conjunctiva; in the same way the reddened state of the membrane, when inflamed, or any other morbid changes in its anterior portion are plainly visible externally.

When we trace the optic nerve to the eye-ball, it seems to be implanted in the back of the sclerotica. The fibrous sheath of the nerve and the tunic are continuous at this point; their substance is intimately blended, although the sclerotic is here much thicker than the nervous sheath. The dispute whether the sclerotica is a production or continuation of the dura mater, through the nervous sheath, is merely verbal. The parts in question are closely analogous in structure, and inseparably united. In consequence of this union, the cornea, the sclerotica, the sheath of the optic nerve, the dura mater, and the periosteum of the orbit, constitute a series of continuous fibrous structures, an arrangement which affords explanation of various pathological phenomena. The optic nerve enters the globe by a round aperture in the sclerotica. This has been described as being occupied by a circular portion of membrane perforated by many small openings, and hence called *lamina cribrosa.* This notion has arisen from observing the effect of squeezing the end of the nerve, when the choroid and retina have been removed from the cup of the sclerotic; the medullary matter is then expressed in numerous minute portions. It is forced out from the terminations of the neurilematous tubes; and a careful dissection will show clearly, that the opening in the sclerotica is a simple round foramen.

A circular groove [3. Fig. 1.] is seen in the sclerotica, on its inner surface, at its anterior termination, where it joins the cornea and is connected to the ciliary ligament. It has been called the canal of Fontana, having been pointed out by him in the eye of an ox. It is a venous tube, receiving veins of the iris, called *circulus venosus iridis* by Arnold,* who regards it as a venous sinus, bearing the same relation to the sclerotica that the sinuses of the head do to the dura mater. He says, farther, that this vessel and its nature were well known to Hovius; that it often receives injection through the arteries, but cannot be filled from the veins, probably on account of valves.

Cornea.—[2. fig. 2. and 5. fig. 23.] The *cornea,*† which covers one-sixth of the globe, differs widely in appearance from the sclerotica, but resembles it in the firmness and resistance of its structure. Thus it is fitted to protect the exposed anterior portion of the eye, while its perfect transparency allows the free passage of light into the interior of the globe. No force applied by the fingers or forceps can lacerate it, although, externally, it appears a delicate kind of membrane.

The cornea and sclerotic are so firmly united, that they may, to all intents and purposes, be considered as one continued investment of the eye; as constituting a kind of case for lodging and protecting the more delicate essential structures of the organ. They may, indeed, be separated by long maceration, but in the recent subject, the resistance is as great at the line of junction as at any other part, and we may consider them as consolidated into one substance. The sclerotica is brought to a thin edge at its anterior termination, and the circumference of the cornea ends by a similar margin; but the former is beveled off on the inside, and the latter on the outside,

* *Anatomische und physiologische Untersuchungen*; p. 10—14.

† Chelius *über die durchsichtige Hornhaut*, Carlsruhe, 1818; Clemens, *Tunicæ Corneæ, et Humoris aquei Monographia physiologico-pathologica*, Goetting. 1816. Also in Radius, *Scriptores Ophthal.* v. 1.

so that the sclerotica overlaps the cornea at the point of union. Hence the circumference of the cornea is smaller externally than internally: hence, too, the anterior chamber extends beyond the external circumference of the cornea.

In some points of structure there is a striking difference between the cornea and the sclerotic. The former is composed of several layers, connected by cellular tissue, in the interstices of which there is a small quantity of clear fluid: this can be squeezed out in minute drops, when the cornea of a recent eye is divided. If we make an incision into the substance, we can turn back with the forceps several successive laminæ: these, however, are quite artificial, being more or less numerous, according to the pains we take in the preparation of them. The facility with which the several portions are separated in such a dissection, and the freedom with which they glide over each other, when squeezed between the finger and thumb, show that the component parts of this membrane are loosely connected together. In consequence of this loose and spongy structure, the cornea swells when soaked in water. The texture of the layers, when torn up in the manner described, is fibrous; and we must refer the cornea to that class of structures. Although the sclerotic and cornea are so different in external appearance, and on cursory examination, arguments may be adduced in favor of the opinion formerly entertained, that they are merely parts of one continuous structure. The essential character of the tissue in both is fibrous; the circulating vessels are few and small in both. There is little difference between them in the early periods of fetal existence, when the cornea is opaque. When examined with the microscope, they are nearly alike, both consisting, in great part, of minute lymphatic vessels arranged in the form of a close net-work, and continued from one membrane into the other.* Again, the cornea is frequently so assimilated to the sclerotica by morbid change, that the boundary between them can no longer be traced.

Pressure on the globe, in the dead state, renders the cornea opaque, more or less completely according to the degree of force employed; when the pressure is remitted, it again becomes transparent.

It has not been ascertained whether a similar effect may be produced by analogous causes in the living eye; for example, whether the general tension produced by increase of the contents of the globe, may render the cornea opaque. Mr. Wardrop supposed that this would happen, and hence advised the plan of evacuating the aqueous humour, to diminish tension.

In thickness the cornea is equal to the thickest portion of the sclerotica. In resistance to the knife it may be compared to parts of cartilaginous structure; it is so firm that we are obliged to use some force in penetrating it with a knife or needle. When we first operate on the eye, we find much greater resistance to the entry of an instrument than the transparency of the membrane would have led us to anticipate. The fibrous structure, and the loose connexion of the parts, lead to another risk, namely, that of the point of an instrument passing between, instead of going completely through them. The density and compactness of the cornea, the resistance which it consequently offers, and its being composed of parts in some degree loosely connected, are circumstances which should be constantly borne in mind in operating on this membrane.

The cornea in the human eye forms a pretty regular portion of a sphere, and is of equal thickness [about one-thirtieth of an inch] at the circumference and in the centre; it is consequently convex on its external or ante-

* Arnold's *Untersuchungen*; p. 16 and 23.

rior surface, and concave on its posterior surface. Although it appears like a homogeneous membrane, we consider it to be made up of three different structures. The anterior surface is a mucous membrane, being a continuation of the conjunctiva; [4'. Fig. 1.] the great bulk of the part is made up of the fibrous, or fibro-cartilaginous structure already described, and usually called the *corneal laminæ* [4. fig. 1.]; the internal surface is a firm, cartilaginous, perfectly transparent membrane, adhering closely to the proper corneal substance, and called *membrane of the aqueous humour** [6. Fig. 1.], being supposed to secrete, or to have a share in secreting that fluid. Dr. Jacob† observes, that this membrane preserves its transparency after maceration, or immersion in hot water, acid, or spirit, all which render the corneal laminæ opaque; and that it separates from the latter when the cornea is immersed in any fluid capable of corrugating it, after which it can easily be detached, and exhibited in a distinct state. He adds, that it passes under the sclerotic for a short distance between it and the ciliary ligament, and terminates with a defined edge. According to this representation, the cornea consists of three different structures; the anterior or mucous layer, the fibro-cartilaginous substance in the middle, and the membrane of the aqueous humour lining the internal or posterior surface. These, and especially the first two, are most firmly united, we might say consolidated, into one apparently uniform transparent structure.

Vessels of the cornea.—No blood-vessels can be seen in the normal state of the cornea, even with the assistance of magnifying powers; and it has been found in general equally impracticable to discover them after injection. Both Soemmerring and Eble failed in their attempts. The former has given a beautiful view of the conjunctival vessels in a child six months old, after injection. Numerous arteries come forwards on the conjunctiva scleroticæ in all directions, and ramify in the membrane: they produce, in fact, numerous minute branches, closely arranged and interwoven so as to form an apparently uniform red border round the cornea, on which, however, not a single twig can be traced. These vessels are so minute, that a magnifying power is necessary to prove that the red margin is made up of vessels.‡ Eble gives a magnified view of the conjunctival arteries, delineating clearly the superficial and deeper-seated ramifications in the conjunctiva, and on the sclerotica. From the arterial net-work of the membrane, minute twigs, in countless number, run in straight lines towards the margin of the cornea, and there end abruptly, as if cut off.§

Professor Roemer of Vienna has succeeded better in his injections, having filled the arteries of the conjunctiva corneæ in an infant two months old, he says, that the arteries of the ocular conjunctiva coming from the lachrymal, palpebral, and muscular arteries, form a superficial and deeper-seated net-work on the anterior part of the sclerotica. That the superficial is made up of branches from the palpebral and lachrymal arteries, which take a serpentine course towards the cornea, unite together, and join the more deep-seated plexus. That the latter consists of much slenderer tubes, coming from the muscular and ciliary arteries, uniting round the margin of the cornea with the superficial vessels so as to form a vascular corona or circle (Gefäss-kranz) situated over the circulus venosus. From this circle numerous minute twigs proceed at all points in straight lines towards the

* It was first noticed by Descemet, and is sometimes named after him. *Observations sur la Choroïde* in the *Mém. présentés à l' Acad. des Sc.* tom. v. 1759.

† *Medico. Chir. Trans.* vol. xii. p. 503.

‡ *Icones Oculi humani;* tab. v. fig. 12. The figure is twice the natural size. See also the explanation of the figure at p. 77.

§ *Ueber den Bau und die Krankheiten der Bindehaut des Augapfels;* p. 59. tab. ii. fig. 11.

centre of the cornea, dividing in their course into two or three still finer tubes. At last they bend inwards and seem to enter the substance of the cornea.*

The minute vessels of the cornea are often injected with blood, in great numbers, under inflammation both acute and chronic. From their number, minuteness, and close arrangement, they sometimes give to the membrane a general redness, in which the individual vessels are hardly distinguishable without the aid of a lens. In the injections of Professor Roemer, as well as in the vascularity of inflammatory excitement, the corneal vessels seem to be derived from those of the conjunctiva.

Whether there are others more deeply seated coming from those of the sclerotica, or ramified in the membrane of the aqueous humour, or of both descriptions; and how far the vessels from these different sources, if such exist, communicate together, or otherwise, are points not yet ascertained. We see, however, daily, that the vital processes, whether physiological or pathological, are carried on as rapidly and perfectly in the cornea, as in any of the parts most abundantly supplied with red blood. Wounds of this part unite by adhesion as quickly as in any other part of the frame. It is subject to inflammation, both acute and chronic, with the various results of mortification, suppuration, ulceration, serous effusion, interstitial deposition, and increase in the number and size of vessels.

That the cornea possesses an immense abundance of lymphatic vessels has been proved, both by injections of them with mercury by Fohmann, and by the microscopical examinations of Mascagni and Arnold. The membrane seems almost made up of lymphatic plexuses or net-works, intricately interwoven. These are found in the conjunctival layer, and throughout the corneal substance, being equally abundant in every slice, from whatever part of the membrane it may be taken.† The lymphatic trunks, filled with mercury, and constituting a continuous stratum under the conjunctival covering of the cornea, are represented by Arnold in his *Tabulæ Anatomicæ;* fascic. II. tab. 2, Fig. 10. They terminate in a lymphatic plexus of the conjunctiva scleroticæ, exhibited as injected with mercury in the 7th figure of the same plate. A close net-work of small ramifications surrounds the cornea, while the trunks pass backwards towards the circumference of the globe.

The presence of *nerves* in the cornea has not hitherto been demonstrated. It has been lately asserted by Schlemm,‡ but positively denied by Arnold § after the most careful investigation in the larger animals and man.

[Still more recently, Pappenheim asserts that he has succeeded in tracing nerves from the sclerotica into the substance of the cornea; see *American J. Med. Sc.* Aug. 1840, p. 439. and Parkinje has been equally successful. He says that if the cornea be acted upon by acetic acid, it will, after first appearing rather opalescent, become perfectly transparent, and if then examined from within, a rather complex net-work of nerves will be seen running from the circumference to the centre. None of the filaments seem to be lost in the substance of the cornea, nor to pass into the conjunctiva. *Ibid.* Jan. 1846, 231.]

Choroid coat (*chorioidea vascular membrane, aderhaut*, Germ.) [7. Fig. 2.] This membrane covers the globe from the entrance of the optic nerve, where it is firmly attached to the perforation in the sclerotica, to the anterior termination of the latter, and reaches to the circumference of the crystalline capsule. It is thin, soft, and delicate, remarkable for its dark

* *Bemerkungen über die arteriellen Gefässe der Bindehaut des Augapfels;* in Ammon's *Zeitschrift*, vol. v.

† Arnold's *Untersuchungen;* p. 20—23. pl. I. fig. 2.

‡ *Encyclopædisches Wörterbuch;* b. iv. p. 22, 23.

§ Lib. cit. 27, 28.

color, and great vascularity. Its numerous vessels are often found filled with blood after death, and the membrane acquires a deep red throughout, when they have been successfully injected with size and vermillion. The basis of the membrane is altogether vascular and cellular; microscopical examination, after a successful minute injection, presents to our view a congeries of minute vessels, an intricate vascular net-work, of which the component parts are united by cellular texture, and nothing else. The dark color of the membrane arises from the deposition into its structure of a coloring matter, called *pigmentum nigrum*, which may be considered as adventitious, and not essential to the membrane.

In order to estimate the internal structure of the choroid coat, we must examine it in the injected state. If we then survey it with the aid of magnifying powers, we find that it consists entirely of arterial and venous ramifications, connected by cellular texture: hence it has been sometimes called *tunica vasculosa oculi* [figs. 5. 6.]

Its composition is analogous to that of the pia mater or vascular membrane of the brain, of which it has been sometimes regarded as a continuation, through the vascular investment of the optic nerve. The neurilema, however, is not continued into the choroid, as the fibrous sheath is into the sclerotica; there is no direct connexion between them, and the choroid must therefore be considered as a separate and independent membrane.

The same observations may be made with respect to the iris, a part closely connected with the choroid, though differing very much in other points of structure. The basis, or essential part of its texture is completely vascular. The best views of these parts have been furnished by Soemmerring and Arnold. These consummate anatomists have exhibited in several figures the minute structure of the choroid and iris with the utmost accuracy and fidelity. We perceive at once, upon inspecting their figures, that the objects have been correctly delineated, from the character of truth and nature which distinguishes them, and from the variety and peculiarity in the different details, which are evidently drawn from actual observation, and could not have been supplied by the fancy of the artist. A certain portion of the internal surface of the choroid exhibits a number of radiated folds, called the ciliary processes [4. fig. 3.] One of Soemmerring's engravings represent a portion of the choroid coat, with three ciliary processes, and a portion of the corresponding internal surface of the iris, forming a small segment of the pupillary circle. The beautiful vascular structure of these parts is represented as it appeared under a magnifying power increasing it by twenty-four diameters. Soemmerring mentions that the artist spent six weeks in making the drawing, and nearly put out his eyes in the process. In the second plate of his second fasciculus, Arnold delineates the same parts, as well as the vascular arrangement on the corresponding external surface: he also represents the blood-vessels of these structures, under various aspects, in other figures. It must, I think, be allowed that the work of Arnold carries the minute anatomy of the eye farther than that of Soemmerring, to which it is at the same time equal in execution.

In the recent eye, the pigment sticks fast to the choroid, but if it be allowed to remain some time in water, the coloring matter is easily disengaged from the membrane; it comes off on the hand or linen, and diffuses itself through the water like Indian ink. Longer maceration discharges it entirely, leaving the texture of the choroid uninjured, but altered to a grayish color. After immersion in spirit, the pigment will come off, particularly from the internal surface of the membrane, in masses of different size. This coloring substance is called pigmentum nigrum, a name which is appropriate enough when applied to the eye of the sheep, bullock, and

many other animals, which have it of the deepest jet black; but, in the human eye, the tint of this substance is dark brown, of a deeper shade in some eyes than in others. In fair individuals the choroid coat is of a light brown. In the human subject, therefore, the coloring matter cannot properly be called pigmentum *nigrum*, and it is more correctly termed by foreign anatomists pigmentum *fuscum*.

The pigment, possessing a reddish hue in the fetus, does not attain its full depth of color till after birth, and becomes lighter in old age. In morbid states of the choroid it is changed in color, quantity, or consistence. It seems to be deposited from the vessels of the choroid, without any intermediate structure; nothing like gland can be detected. It has usually been regarded as an inorganic substance spread over the interior of the eye to darken it, and thus render it more perfect as an optical instrument. Some represent it as contained in a membrane or a cellular texture. In opposition to this view, ARNOLD* states that the most careful microscopical examination after minute injection of the eye, detects no blood-vessels, and that no trace of lymphatics can be seen in it. It appears under the microscope as a black granular mass, consisting of globules and a dark substance. The latter may be more or less abundant, and sometimes the globules are found alone. These globules are represented as nearly spherical by ARNOLD † and in some degree transparent in the centre. Mr. JONES ‡ describes and delineates them as minute flat bodies, of hexagonal forms, joined together by their edges, consisting of a transparent nucleus surrounded by coloring matter. [This membrane exists in albinoes, but contains no pigment.]

ARNOLD § represents that the choroid is not covered externally by the pigment, except in cases where the coloring matter is abundant; that in eyes with light irides, and in old subjects, the corresponding surfaces of the choroid and sclerotica are not colored, but clear, smooth, and shining. Hence the internal surface of the latter could not in such cases be called lamina *fusca*.

The whole internal surface of the human choroid is of the brown color; but in the bullock and most quadrupeds, a certain portion of the internal surface possesses tints peculiarly bright and vivid. In the cat it is a bright yellow, in the stag a very beautiful blue, in the sheep a greenish blue. This colored portion of the choroid coat is called the tapetum or carpet; there is no part corresponding to it in the human eye.

RUYSCH, who took much pains to inject the blood-vessels of the eye, and examined the structure of the choroid in man and animals, divided the membrane into two layers, and called the external, choroid, while his son gave the name of *tunica Ruyschiana* to the internal. This separation can be effected, at least partially, in the eyes of animals, more particularly in the situation of the tapetum; and the same thing can be accomplished in the human eye, especially when it has lain a little time in spirit. This separation is quite an artificial affair; the choroid is a single membrane, of which we can form a just notion only in that view. If we take the uninjected membrane we could not distinguish the vascular net-works belonging to the supposed distinct laminæ. When we examine an injected choroid, we immediately perceive that the arteries are distributed on the interior, while the veins occupy the exterior of the membrane, an arrangement cor-

* *Anat. u. physiol. Untersuchungen*, p. 62. † *Tab. Anat.* fasc. II. tab. 2, fig. 24.
‡ MACKENZIE'S *Practical Treatise on Diseases of the Eye.* 3d Edit. Introduction, p. 26. § Lib. cit. p. 60.

responding to the different functions performed by the two orders of vessels. The arteries and veins of the choroid form net-works interwoven with each other, and making up together a single structure. They are principally arterial on the inner surface; the minute arteries and veins are united in the interior, and covered externally by the large venous trunks known by the name of *vasa vorticosa.* [9. 10. fig. 5. and 7. fig. 8.]

The arrangement of the ultimate vascular ramifications of the choroid has been beautifully delineated by Soemmerring in figures illustrating a short paper* in the Memoirs of the Academy of Sciences at Münich, vol. vii. He represents the vessels of the choroid, as they appear under a strong magnifying power in a portion of the membrane of certain size taken from the corresponding part of the globe in an infant and an adult, in the calf, the salamander (water newt,) and the common fowl. He found that the choroid vessels are as large in a small as in a larger eye, so that the choroid of a small animal might be represented as, in a certain sense, a piece or part of the choroid of a large animal; that their distribution is characteristic in each species; that the ciliary arteries, having divided and subdivided, form at last an arrangement of flattened cylindrical vessels, nearly uniform in size, partly communicating together, and forming so close a net-work as to leave no room for finer ramifications, and partly continued into corresponding venous tubes. Hence it appears that the choroid is most richly supplied with blood-vessels, containing nothing in addition to these but cellular texture, and that no secreting or exhaling tubes can be discovered in it.

The arteries [7. fig. 5.] of the membrane are the *posterior ciliary*, which are numerous, and perforate the sclerotica round and near the insertion of the optic nerve; and the *anterior ciliary*, in smaller number, which pass through the fibrous tunic in the situation of the ligamentum ciliare. The former may be regarded as the proper arteries of the choroid; the latter are principally ramified in the ligamentum ciliare, and inosculate freely with the greater arterial circle of the iris. The veins [7. fig. 6.] terminate chiefly in four trunks, which perforate the sclerotica a little behind the greatest transverse diameter of the globe. From each of these trunks, as from a centre, branches, generally describing a more or less arched course, spread in all directions over the choroid, forming so many vascular whorls; hence the appellation of *vasa vorticosa.* There are also posterior and anterior ciliary veins: the vasa vorticosa inosculating freely with both these, and with each other, form a venous net-work, which constitutes the exterior layer of the choroid, while the arterial plexus forms the interior or tunica Ruyschiana. The distribution of these vessels, as well as of those belonging to the iris, is represented with inimitable beauty in six figures of Arnold's second plate, viz. fig. 16—21. *Icones Anat.* Nerves have not been discovered in the choroid.

The external surface of the choroid presents a uniform appearance, excepting a narrow portion in front, forming the ligamentum ciliare, which remains to be described. The internal surface is also uniform until it approaches within two lines and a half of the edge of the cornea: here we observe a dentated line (*ora serrata*) [11. fig. 1.], in front of which the membrane exhibits a number of longitudinal folds, arranged in a radiated manner, and reaching to the circumference of the lens; these are the ciliary processes, and the part in question, taken altogether, is the *ciliary body* (*corpus ciliare.*) [10. fig. 1.] This is best seen when the globe has

* *Ueber das feinste Gefässnetz der Aderhaut im Augapfel.*

been divided by a vertical section into an anterior and a posterior half, the vitreous humour and lens having been left undisturbed. Looking through the former, we see a beautiful deep brown ring, about three lines broad, a little narrower on the nasal side, surrounding the lens. The posterior boundary of this is the *ora serrata;* the back part of the ring is a smooth surface (*pars non fimbriata corporis ciliaris*) [10. fig. 1.]; the anterior portion of it, about a line in breadth (*pars fimbriata*) [10. fig. 1.], presents a series of dark and white folds alternately arranged, which are the *ciliary processes.* The white lines arise by hardly visible striæ, which enlarge as they pass forwards, and form white elongated folds closely arranged, separated by dark intervals, and broader, thicker, and more elevated, the nearer they approach to the lens. The deep color of the corpus ciliare is derived from a thick layer of pigment, which adheres more closely than the corresponding covering of the choroid.

[While the inner surface of the choroid forms the ciliary ring, its outer surface presents the *annulus albidus* or *a. gangliformis* (8. fig. 1.) the anterior edge of which unites to the inner surface of the sclerotica and constitutes the ciliary ligament (9. fig. 1.) Mr. T. W. Jones describes the *annulus albidus* as a body of a peculiar texture, enclosed between the two layers, into which the choroid is divisible anteriorly, and having the form of a flat circular band, about one eighth of an inch broad, thick anteriorly, and thin posteriorly.]

Some have regarded the ciliary body as a peculiar structure, distinct from the choroid. They are, however, perfectly continuous; no distinction is visible externally. In essential circumstances the structure is alike, consisting of a vascular basis, of which the peculiar character in the ciliary processes is represented by Soemmerring and Arnold, with unrivaled beauty, with pigment deposited in the texture.

The notion entertained by Kepler that the ciliary body produces changes in the interior of the eye connected with the adaptation of the organ to vision at different distances, led many anatomists and physiologists to maintain that the ciliary processes are muscular, and capable of moving the crystalline lens. This point was thoroughly examined by the careful and accurate Zinn, who came to the conclusion that the texture of the part is purely vascular, and exhibits nothing like muscular structure. The same view is entertained by Arnold;* who says, "in repeated examinations of the ciliary processes under the microscope, I could never detect any muscular structure, although muscular fibres, however pale, are readily recognized as such in microscopic observations. When uninjected, the ciliary processes appear to consist of cellular texture; but, after successful injection, they are seen to be made up entirely of blood-vessels. Neither have I discovered any nerves in this structure by similar or other modes of investigation."

Iris. (*Regenbogen-haut*, Germ.) [12. fig. 1. and figs. 10 and 11.]—The *iris*, which fills up the circular space left by the anterior termination of the choroid coat, is a part of considerable importance from its situation, and its office of regulating the quantity of light admitted into the eye, from its diseases, and its connexion with most of the important operations performed on the organ; while an equal degree of interest attaches to it physiognomically, from its brilliance, its various tints, and the animation it imparts to the countenance. Its external appearance must be familiar to every one who has looked at the human face; it is the part in which the color of the eye, popularly speaking, resides,—the brilliantly colored portion of the

* *Untersuchungen*, p. 58.

organ situated behind the cornea, and close in front of the crystalline lens, in the midst of the aqueous humour, in which humour it freely moves. The opening in the centre, [2. fig. 3 and 8. fig. 7.] which is circular in the human eye, when in a healthy and natural state, is the *pupil.* In the sheep and bullock it is oblong, and its figure varies in different animals. The term iris, properly speaking, is applied to the anterior surface of the membrane, to that part which is distinguished by the brilliancy of its color; from which attribute, together with the variety of its tints in different individuals, the name seems to have been derived. The color of the iris varies very much in different persons, but in all it is distinguished by a greater or less degree of brilliance. This characteristic belongs only to the anterior surface, for the posterior is covered by pigmentum, indeed by a thick and dark stratum of it, and therefore resembles the surface of the choroid, being black in animals, and dark brown in the human species. This posterior surface is called the *uvea.* In employing the terms *iris and uvea,* we must remember that the membrane is single, and not separable into layers, except by artificial dissection.

It has been disputed whether the iris is flat or convex on its anterior surface. I believe that it is flat in the healthy eye, but would not assert that it may not vary in this respect independently of disease. The Soemmerrings* have represented it as perfectly flat; while the figures of Arnold† give it a slight convexity.

We distinguish two surfaces, an *anterior* [fig. 10.] (iris,) and a *posterior* [fig. 11.](uvea.) On the former, when the part is laid in water, minute flocculi are visible. It also exhibits numerous nearly parallel larger and smaller lines and fibres, proceeding like radii from the circumference towards the centre: these sometimes unite so as to form arches. An irregular line divides this surface more or less distinctly into two portions; an *external,* or larger circle (*annulus externus,* or *ciliaris,*) and an *internal,* or smaller circle, (*annulus internus,* or *pupillaris.*)

The posterior surface of the iris presents a number of faintly marked lines, converging from its circumference towards the pupil. Dr. Jacob considers that its pigment is covered and secured in its situation by a very delicate membrane: it may be easily turned down from the iris as a distinct structure. When this has been removed, and the surface washed, the iris has a grey appearance, and exhibits numerous fibres converging from the ciliary processes towards the pupil. "The latter opening," says Dr. Jacob, "is immediately surrounded by a well defined distinct circle, about the twentieth part of an inch in diameter, of a denser structure than the rest of the iris; this is what has been long described as the orbicular muscle, or constrictor of the pupil."‡

The iris has two margins; an *external* or *ciliary,* attached to the corpus ciliare, an *internal* or *pupillary,* which is the border of the central opening. The situation of this opening, however, is not exactly central; it deviates a little towards the inside, so that the iris is narrower on the nasal than on the temporal side of the pupil. This difference, which was, I believe, first noticed by Soemmerring, is immediately recognizable in the living eye. The ciliary margin is the only fixed part of the iris, all the rest is loose and unconnected, floating in or washed by the aqueous humour. The very edge of the pupil, which is thin and sharply defined, is colored by the pigment; we might say, the pupillary margin is formed by the uvea, rather than the iris. The

* S. T. Soemmerring, *Icones Oculi humani,* tab. 8. W. Soemmerring *de Oculorum &c. Sectione horizontali.*

† Arnold *Untersuchungen,* tab. 3. fig. 2. *Icones Anat.* fasc. II. tab. 2. fig. 4.

‡ *Medico. Chir. Trans.* vol. xii. p. 513, 541.

diameter of the pupil varies in an inverse ratio to the quantity of light to which the eye is exposed: in a strong light it is contracted, and the iris proportionally expanded; when the light is diminished in quantity, the opening is enlarged, and the iris, in a corresponding degree, contracted.

The notion that the iris is a continuation of the choroid, or, in other words, that these two are parts of one and the same continuous structure, is contradicted, not only by the obvious differences between them in organization and function, but also by the mode of union, by the distinct sources of vascular supply in the two cases, and by the total absence of nerves in the one instance, while the other part is furnished with them as abundantly as any organ in the body. The anterior circular edge of the ligamentum ciliare, and of the corpus ciliare, forms a groove or plait, in which the outer or *ciliary edge*, or the *greater circumference* of the iris is set; the union not being firm or intimate, but such, that the iris can be drawn away without injury either to it, or to the ciliary body or ligament. If the cornea and the front of the sclerotica are carefully removed from the human eye, so as to leave the choroid and the ciliary ligament uninjured, the iris can be drawn away easily so as to show that it is connected to the choroid, not by continuity of substance, but merely by the long and anterior ciliary arteries, by the ciliary nerves, and an easily lacerable cellular texture.

Blood-vessels of the iris.—The arteries of the iris are the two *long ciliary* [6. 6. fig. 8., and 1. 1. fig. 12.] (the *external* and *internal*,) and the *anterior ciliary*, about six in number. The long ciliary arteries perforate the sclerotica towards the back of the globe, one on the inner, one on the outer side: they pass forward between the sclerotica and choroid, along the middle of the globe, to the ligamentum ciliare, where each of them divides into two branches, which run round the greater circumference of the iris, and uniting together, constitute the *greater arterial circle* [2. fig. 12.] of the iris. The short ciliary arteries pass through the sclerotica in the front of the eye, and join the circle before described. Numerous branches proceed from this circle, and run in a nearly parallel direction along the iris, inosculating in the situation of the lesser circle, so as to form the *lesser arterial circle* of the iris. [2. fig. 12.] The veins of the iris pour their contents into the circular venous sinus, [3. fig. 1.] situated at the circumference of the cornea, from which anterior ciliary veins proceed.*

Nerves of the iris.—The ciliary nerves, [6. fig. 5., and 8. 9. fig. 6.] proceeding chiefly from the ophthalmic ganglion, penetrate the sclerotica towards the back of the globe, run forwards, under the appearance of larger or smaller white threads, between the sclerotica and choroid, to the ligamentum ciliare, in which they appear to be lost. Soemmerring considers that they really terminate here, and regards the ligamentum ciliare as a kind of ganglion formed by their expansion and union: hence he calls it *annulus gangliformis.*† Arnold‡ says that though he could trace the ciliary nerves through the ligamentum ciliare, and follow them even to the edge of the pupil in animals, for example, in the dog, he could not succeed in fresh human eyes; on the contrary, they became so soft, as if they were resolved into cellular texture, that he could not follow them any farther. He did not succeed better with microscopical examinations: for, although he saw white threads in the iris, looking like nerves, he could not connect them with the ciliary nerves. He accomplished the point at last, in an eye which had been kept in alcohol, and, using a fine needle, followed the

* Arnold, tab. 2, fig. 18 and 19.

† *Icones Oculi humani;* tab. 5, fig. 7 and 9.

‡ *Untersuchungen*, p. 77.

nerves through the ligamentum ciliare, in which they divide and subdivide, ultimately producing small white threads taking a somewhat undulating course, and lost in the iris, where they can be traced nearly to the pupil. He has delineated them in a beautiful figure, where they are seen ending in a close net-work of branches in the ligamentum ciliare, from which the nerves of the iris proceed.*

Not only does the color of this part vary in different individuals, but different hues are found in one and the same iris. Sometimes different tints are intermixed throughout, as in light blue, grey, greenish, and brownish grey eyes. The inner circle is often of a different color from the outer; for example, it may be of an orange or ochery tint in blue or grey eyes. Usually there are three distinct colors in the same iris; the circumference, the middle, and the inner circle exhibiting tints more or less different. Occasionally, the two irides are naturally different; and sometimes one-fourth or one-half is brown, the rest being blue or grey. I saw a gentleman of florid complexion, with much color in the face, and dark hair. His right iris was grey, with a slight blue tinge; the left light brown, except about one-fifth, which was grey like the right. In respect to these varieties there is a marked difference between the human species and animals. It may be said of all animals, in their natural or wild state, that the color of the iris is constant in the same species. Domesticated animals, with greater diversities in the general color of the body, have, in some degree, a corresponding diversity in that of the iris; but in no instances are there such numerous differences as in the human subject.

The color of the iris generally corresponds to that of the integuments: it varies according to the complexion of the individual and the color of the hair. In those of fair complexion and light hair, the iris is either blue or grey, or of some light tint; such persons are said, in common language, to have light eyes. In persons of dark complexion and hair, the iris has a deeper tint, dark grey, brown in various shades, of which the deepest is called black. In the human subject, the iris is never, strictly speaking, black; the eyes, which we call black, are of a dark brown, and they always accompany dark hair, and complexions more or less swarthy.† The individuals of the German race are distinguished by the lightness of their hair, the fairness and ruddiness of their complexion, and by blue or light grey eyes. This combination of physical characters is remarked by Tacitus, in his treatise *De Moribus Germanorum* (rutilæ comæ, cœrulei oculi;) where *rutilæ* probably means the color which we call flaxen; this sort of hair, and light blue eyes, are circumstances which characterize the German race at this day as strongly as at the time when Tacitus described them. All the dark-complexioned races, the Sclavonians, the Celts, the Orientals (as the Turks and the inhabitants of the western parts of Asia) and the dark-colored races, properly so called, have dark hair and the darkest irides. In the Negro this characteristic is most striking, for the iris is so extremely dark that you are obliged to look closely to distinguish between it and the pupil.

In the eye, as well as in the hair and in the skin, the coloring substance seems to be something adventitious, which does not belong to the basis or natural texture of the part: for, when the coloring substance is removed, the fundamental structure remains. This is the case with respect to the individuals called Albinoes, who are distinguished by a peculiar and almost

* *Tab. Anat.* fasc. II. tab. 2, fig. 22.

† [This, though generally, is not invariably, the case. Examples of very dark-brown eyes in persons of fair complexion and flaxen hair, are not very uncommon in the United States.]

morbid kind of whiteness; whose hair has a white, almost satiny appearance, and whose skin is of a dead, sickly white. In these individuals the coloring substance of the choroid coat, and of the iris is deficient; and the pupil, instead of being black, is of a rose or pink color; the iris has the same pink tint in a greater or less degree, but its color is never so deep as that of the pupil. The choroid pigment, and that of the uvea are entirely wanting; but the iris often possesses a little color, light blue or grey; its texture is at the same time so thin, from the absence of the uvea, that the red of the choroid is partially seen through it. The color of the iris and pupil in these cases depends on the multitude of blood-vessels entering into the texture of the former, and of the choroid. If we examine the eyes of such individuals, after the vessels have been injected, the choroid coat presents the appearance of a uniform red membrane without any coloring substance. In the ferret, and in the white rabbit, there is the same deficiency of coloring substance, and the red color of their eyes is well known.

The iris is considerably thicker than the choroid, except at the pupillary ring, which is terminated by a thin and sharp edge. It is soft and loose in texture, being apparently made up of blood-vessels, nerves, and a fine connecting cellular tissue. Whether it has also fibres, and whether these are muscular, are questions which have been long debated, and are not yet decided.

Sir Everard Home not only believed in the muscular structure of the iris, but considered the point so clear as not to admit of dispute. And it might justly be so regarded, if the figures which he has given of the structure, from the observations and drawings of Mr. Bauer could be regarded as accurate.* He admits the radiated fibres of the iris to be vascular, and has represented them† not very correctly. He places the muscular structure on the posterior or uveal aspect, making it to consist of a sphincter round the pupil, and of radiated fibres in the circumference, giving them as obviously muscular a character as could be seen in the orbicular muscle of the mouth or eyelids.‡ Arnold has examined this subject with his usual industry and accuracy. He details the conflicting opinions of many celebrated anatomists and physiologists, and proceeds to the result of his own inquiries, which he prosecuted both in fresh and macerated eyes, without and with injection of the blood-vessels, under various magnifying powers, and with different degrees of light. When a fresh iris, not injected and properly freed from pigment, is magnified thirty, forty-eight, or seventy times in diameter, it appears as a membrane formed of cellular texture, in which numerous fibres are observed running from without inwards in a serpentine course: on careful examination these are found to be vessels. Besides these, and threads, which are recognized as twigs of the ciliary nerves, nothing could be seen in the shape of fibres, such as they have been described by several anatomists, and so plainly delineated by Home. The cellular texture in the greater part of the iris is thin, loose, and spongy, forming on the anterior surface a net-work with meshes of various size; but it becomes condensed towards the pupil, and is compacted into a firm

* *Philos. Transactions*, vol. cxii. pl. 6. fig. 8. *Lectures on Comparative Anatomy*, vol. iv. pl. 86. fig. 8.

† Lib. cit. fig. 7.

‡ The same observation may be made respecting the representation of circular and radiated fibres in the eye of the cobitis anableps; *Phil. Trans.* vol. cxii. pl. 8. fig. 6. *Lectures*, vol. iv. pl. 88. fig. 6. By M. Maunoir of Geneva, also, who strongly advocates the muscularity of the iris, the structure is delineated in such a way as to remove all doubt on the point, if the accuracy of the figures be admitted. *Mémoires sur l'Organization de l' Iris*, &c. Paris, 1812.

ring, which constitutes the pupillary margin. No circular fibres, could be discovered by the most careful and attentive examination. The iris, then, consists of numerous blood-vessels, of many nerves, and of cellular texture, which forms a continuous ring at the pupil. If we cut through the iris, and examine the cut edge with the microscope, we find the cellular texture accumulated in larger quantity round the pupil, so that the iris presents here a tumid ring. The substance is a little thinner in the middle than at the ciliary margin. The same results are obtained by examining the iris after it has been macerated, the cellular nature of the organ being however more apparent, and the blood-vessels less easily recognizable. The latter are more conspicuous after successful injection, when the distention of the vessels renders the cellular texture less conspicuous. If the iris is split into two laminæ, the same results are obtained by examining them.* When examined by the microscope, after successful injection, the iris seems composed almost entirely of vessels; although some of these are not of the smallest size, they do not appear to contain red blood: at least, when the healthy iris is wounded, no blood flows; free bleeding, however, occurs when it is detached from the ciliary body.

[Recent experiments of Prof. Grimelli, of Modena, seem to corroborate Arnold's account of the structure of the iris. Prof. Grimelli found that the substances which answer best for very fine injections of this organ are olive or walnut oil variously colored, which penetrates into the most delicate vascular ramusculi without transuding through their coats, and preserves for a long time the parts which they impregnate. In injecting the bodies of children, Dr. Grimelli observed, that from being soft and much dilated, the iris became turgid, and contracted more than half its diameter, in the same manner as when the retina is affected by light during life. This fact appears to prove that the iris is composed of a union of vessels forming a disc, in the centre of which is the pupillary aperture, and the circumference of which is attached to the ciliary ligament. By the aid of the lens and microscope, we see that the very fine vessels which constitute the iris are disposed between the pupillary and ciliary circles, under the form of rectilinear and curvilinear radii, curved upon themselves and zigzag; agglomerated and united in an inextricable manner. We observe also some ramifications disposed in circles between the pupillary and ciliary circles, more or less near each other, and always few in number. It results from this disposition of the minute vessels, fixed towards the larger circle and movable towards the lesser, that the sanguinous afflux and turgescence unfold the iris and contract the pupil, and that the return of blood and diminution of turgescence, fold again or wrinkle the membrane and dilate the pupillary aperture. Thus, contrary to the generally admitted opinion on the muscularity of the iris, as it appears to the author, this membrane is composed of a turgescible or erectile vascular tissue, in which arterial vessels predominate.

Still more recently, Mr. C. R. Hall (*Edinburgh Med. and Surg. Journ.* July 1844) has examined microscopically, the iris in different animals, and describes muscular fibres as entering into the structure of this part. He considers the radiated plicæ, which are seen in the uvea in the mammalia, as not being muscular; but he agrees with Dr. Jacob in regarding them as being analogous in structure to the ciliary processes. The white lines and elevations apparent on the anterior surface of the human iris he supposes to be formed by the ciliary nerves, which interlace one with another in the form of a plexus. The iris, he states, is composed of two portions; the first consisting of a highly vascular tissue, connected by ves-

* *Untersuchungen*, p. 73, 74.

sels with the choroid, ciliary processes, sclerotica and cornea, and abundantly supplied with nerves, which, in the human iris, appear, in a front view, as thread-like striæ; and which are invested, on both surfaces, by the membrane of the aqueous humour. They are more or less thickly covered with pigment, which, by its varying color, imparts to the iris on the anterior surface its characteristic hue; and, by its darkness on the posterior surface, renders an otherwise semitransparent structure perfectly opaque. The second component portion of the iris consists of a layer of concentric muscular fibres, which fibres, in man, and mammalia generally, are situated on the posterior surface of the pupillary portion of the iris; but which, in birds, extend much nearer to the ciliary margin, and consequently form a much broader layer. In fishes, and in some reptiles, they do not exist at all.]

Membrana pupillaris.—[Fig. 12 and 13.] During a considerable portion of fetal existence, the pupil is occupied by a delicate membrane, which closes the opening, so that the two chambers of the aqueous humour do not communicate. Arnold* states that in the third month, when the eyelids and the conjunctiva are formed, a membrane is developed behind the cornea, and closes the pupillary aperture, then very considerable: that, so long as the spherical lens lies close on the flat cornea, there are no chambers of the eye, but a cellular texture, in which the vessels of the iris ramify, intervenes between the cornea and lens; and that, when the lens becomes flatter, and the cornea more arched, a serous membrane is developed, defining the anterior chamber and continued over the lens and pupil. He represents that the pupillary membrane, at first soft, becomes gradually firmer, and attains its full development in the fifth and sixth months, when it is an extremely thin and delicate, perfectly transparent membrane, divisible into two layers, of which the anterior is part of the membrane of the aqueous humour, and destitute of vessels, while the posterior is a cellular production with numerous vessels. It was observed by Rudolphi that the pupillary membrane is continued over the iris, and that the pupil can be seen behind it with a free edge. The separation into two layers is easy at an early period, but can hardly be accomplished later. The vessels of the iris are not united in the fetus into an inner arterial circle, but run into the pupillary membrane, converging towards the centre, but not crossing it: they inosculate so as to form loops, between which a small portion of the membrane, at its centre, is free from vessels. The iris gradually enlarges, and the membrana pupillaris becomes of course less considerable. In the seventh month its vessels, which were previously numerous and large, are lessened in number and size, and there is a larger transparent portion in the centre. It has been generally supposed to disappear in the seventh month, but Dr. Jacob,† who has minutely investigated this matter, states that it lasts considerably longer. He says that "at the approach of the eighth month, a few vessels cross the pupil, or ramify through the membrane at a short distance from the margin, without at all presenting the looped appearance of the previous period, but admitting a free communication between the vessels of the opposite side of the iris. The pupil is now still more diminished in size, and the iris has assumed its characteristic colored appearance; notwithstanding the absence of vessels, the membrane still preserves its integrity, though perfectly transparent. The period now approaches, when it is to disappear; this occurrence takes place, according to my observations, a short time previous or subsequent to birth. In every instance where I have made the examination, I have found the membrana

* *Untersuchungen*, p. 156. † *Medico-chirurgical Transactions*, vol. xii.

pupillaris existing in a greater or less degree of perfection in the new-born infant; frequently perfect, without the smallest breach, sometimes presenting ragged apertures in several places, and, in other instances, nothing existing but a remnant hanging across the pupil like a cobweb. I have even succeeded in injecting a single vessel in the membrana pupillaris of the ninth month. When I have examined it in subjects who have lived for a week or fortnight after birth, as proved by the umbilicus being healed, I have uniformly found a few shreds still remaining. It is obvious from the preceding observations, that the membrane does not disappear by a rent taking place in the centre, and retraction of the vessels to the iris, as supposed by BLUMENBACH; but that it at first loses its vascularity, then becomes exceedingly thin and delicate, and is finally absorbed." PORTAL* says, that it disappears at the time of birth, or a little later. ARNOLD† states, that he had frequently seen some vascular ramifications in the pupil, remains of the pupillary membrane in the eyes of newly-born infants; and that he once saw, in both eyes of a child at full time, the membrane perfect, excepting a small point in the centre, and well supplied with blood-vessels.

Arachnoid coat of the eye [Membrana Fusca.—5. fig. 1.] Some anatomists have recently described a serous membrane, lining the cornea, spread over the choroid, and bearing the same relation to those tunics that the arachnoid does to the dura and pia mater: hence they have called it *arachnoidea oculi.* It has been observed that there is a fluid between the sclerotica and choroid, giving their surfaces a shining, if not very moist appearance; that minute injections escape here, as they do into serous cavities, and that morbid collections of fluid have been found in this situation.

Zinn‡ expressly compares the space between the two membranes to the serous cavities; and many anatomists have regarded the external surface of the choroid, or the lining of the sclerotica as serous. SCHREIBER says "sclerotica in facie sua interna naturam membranæ serosæ præ se fert, sicut chorioidea in facie sua externa."§ FRAENZEL|| and MECKEL¶ consider the internal surface of the sclerotica to be serous, and analogous to the internal surface of the dura mater, while the latter represents this serous layer of the sclerotica as derived from the arachnoid coat of the brain.

Although the arachnoid of the eye has escaped the notice of ZINN, of SOEMMERRING, and of JACOB,** ARNOLD†† describes it regularly, and introduces it in his view of the vertically divided globe, both in his *Untersuchungen* (tab. 3, fig. 2) and in the *Tabulæ Anatomicæ* (tab. 2, fig. 4.) He says that the arachnoidea oculi can be easily exhibited, by careful dissection, in the eye of the fetus, both on the choroid and the sclerotica; but that it is not so easily seen in the adult. The portion lining the sclerotica is as readily demonstrable as the arachnoid covering the dura mater; but the

* *Mémoires du Museum,* tom. iv.

† Lib. cit. p. 158.—The blood-vessels of the membrana pupillaris have been repeatedly delineated; by BLUMENBACH, *Institutiones Physiologicæ*, tab. 2. SOEMMERRING, *Icones Oculi Humani*, tab. 5. J. CLOQUET, *Mémoire sur la Membrane Pupillaire, et sur la formation du petit cercle arteriel de l'Iris*, Paris, 1818. The best representations of the subject are those of Dr. JACOB, *Medico-chirurgical Transactions*, vol. xii. pl. 10. and of ARNOLD, *Icon. Anat.* fasc. 2, tab. 2. fig. 19.

‡ *Descript. Anat. Oculi Humani*, p. 25.

§ *Radius, Script. Ophthal. minor.* vol. iii. p. 128. See also WARDROP, *Morbid Anatomy of the Human Eye*, vol. ii. ch. 27 and 53.

|| AMMON'S *Zeitschrift*, vol. i. p. 13.

¶ *Handbuch der Mensch. Anat.* b. iv. p. 73.

** Article *Eye* in the *Cyclopædia of Anatomy and Physiology.*

†† *Untersuchungen*, p. 33 et seq.

difficulty is with the other part of the membrane. The eye should be put in spirit, and divided, when sufficiently hardened, into an anterior and posterior half by a vertical incision. The choroid is then to be drawn away from the sclerotica from within; thus the inner layer of the arachnoid remains in contact with the outer, and they can be easily separated in water. Under the microscope, the arachnoidea oculi exhibits the same arrangement of lymphatic vessels as other serous membranes.* The membrane is easily shown in birds, particularly in the falcon, where the choroid and sclerotica have a very slight, if any cellular connexion. In the mammalia, particularly in the sheep and ox, they are closely connected by cellular texture, so that in detaching the sclerotica a portion of the choroid is often carried with it.

It appears to me that the existence of this arachnoid coat in the eye has been rather inferred from analogy than directly demonstrated; while the argument from analogy is not very strong. Organs, or portions of organs, are insulated by serous membranes, where they are liable to change of size, position, or relation to surrounding parts: these points are exemplified in the viscera of the abdomen, in the lungs and heart, in the brain and spinal cord, in the iris. The case of the choroid bears no resemblance to these. The membrane is firmly fixed to the sclerotica at its anterior termination, and at the entrance of the optic nerve. Consider again the mutual connexions of the tunics by soft and short, but numerous cellular threads, and by the passage of the ciliary arteries, veins, and nerves. In these respects the eye, instead of resembling, presents a contrast to the organs furnished with serous investments.

Retina. [20. fig. 1. and 1. fig. 15.] This pulpy, soft, and almost mucilaginous expansion of the optic nerve covers the globe within the choroid, extending, like that membrane, from the insertion of the optic nerve to the circumference of the crystalline. The point, at which it terminates anteriorly, has been and still is a matter of dispute. When we look into the front section of an eye divided vertically into an anterior and posterior half, the retina seems to end abruptly, by a slightly undulated edge (*margo undulato-dentatus*) at the commencement of the ciliary body; and the terminating margin even appears a little elevated. This has generally been considered the anterior end of the membrane. It has, however, been asserted that it continues in a thinner form, between the ciliary processes and the zonula ciliaris to the circumference of the crystalline capsule, and ends there; and this view of the subject is adopted by the most accurate modern inquirers.†

The optic nerve passes through a small opening in the choroid and sclerotic coats; and here a singular circumstance is observed. If we make a section of the optic nerve at the point where it passes through these tunics, we find that it becomes suddenly constricted, and reduced to one-third of its previous diameter. The appearance is the same as would be produced by tying a string tightly round the nerve. Having passed through the aperture of the membranes, it forms a small flattened prominence in the interior of the globe, at its fundus (*papilla conica,*) from which the nervous substance spreads out to form the grayish white pulpy membrane called the retina; which may be considered as a nerve expanded so as to form a membrane. Two different parts may be distinguished in this soft

* Ibid. tab. 1, fig. 4. Fig. 5, *a* and *b*, are two representations of the same part, from the eye of the falcon, under great magnifying powers.

† Schneider, *das Ende der Nervenhaut im menschlichen Auge*, München, 1827, 4to. Huschke, *uber einige Streitpuncte in der Anatomie des menschlichen Auges*, in Ammon's *Zeitschrift*, vol. iii. Arnold's *Untersuchungen*, kap. iv.

texture, an exterior medullary pulp, and an interior vascular membrane. With a camel-hair pencil, after a slight maceration, we can brush away the medullary part of the retina in the form of thin flocculi floating in water: there will remain a vascular basis, of a thin and almost cobweb-like texture, made up of vascular ramifications, divided, subdivided, and united together, so as to form a most delicate membrane. The latter and the medullary pulp are respectively analogous to the pia mater and the substance of the brain; it being understood that the nervous pulp and the vascular portion are completely blended, and form a single membrane, not divisible into layers.

Dr. Jacob,* of Dublin, who has investigated the minute structure of the eye with great patience and success, has lately described a very thin membrane, [16. fig. 1.] thinner, softer and more delicate than the arachnoid coat, on the outer surface of the retina, giving an external covering to the nervous pulp, and separating it from the choroid, while the vascular texture of the retina is in a manner interposed between the pulp and the vitreous humour. The delicacy of this structure, and the consequent difficulty of demonstrating it, will account for differences of opinion respecting its nature. Arnold does not regard it as a membrane, but as a mucous stratum (*schleimschichte*) on the retina; and in another place he calls it a sediment of the pigment, which is removed in water.†

Nearly, if not exactly, in the axis of the eye, and therefore on the temporal side of the papilla conica, we find in the retina of the human eye a fold [5. fig. 4.], a bright yellow spot [4. fig. 4.], and either a hole or a thin place in the membrane [21. fig. 1.]. These parts were discovered by Soemmerring,‡ whose name they bear. The fold begins close to the temporal side of the optic nerve, and runs transversely outwards. Some have supposed that the fold may arise after death; there is, however, a depression in the vitreous humour for lodging it. The yellow spot (*macula lutea*) is at the same place as the fold, and of a bright color in the recent eye. The most exact researches render it probable that the retina is not perforated, but only thinner in this situation.§ The structure in question is peculiar, among the mammalia, to those, in whom, as in man, the optic axes are parallel, viz. the monkey and lemur tribes; and it was supposed to be confined to these until the researches of Dr. Knox|| had demonstrated its existence in several reptiles.

In the living eye the retina is transparent, but after death it becomes opaque. If we examine it in an animal recently dead, we find it transparent, and we can see the choroid coat through it, as if it were not covered by a membrane. Hence the color of the pupil is determined by that of the choroid coat, and is generally black. In certain animals, where a considerable portion of the choroid is otherwise colored, the pupil has a luminous or shining appearance, which is the reflection of light from the choroid coat. Any alteration, which takes place in the color of the human pupil, must be caused by a corresponding change in the choroid, the retina, or the transparent media between the retina and pupil.

The retina has been represented as possessing a fibrous structure, and as

* *Account of a newly discovered Membrane in the Eye*, Philos. Trans. 1819. *Inquiries respecting the Anatomy of the Eye*, Medico-Chir. Trans. vol. xii.

† Lib. cit. p. 6 and 91.

‡ *De Foramine centrali, limbo luteo cincto, Retinæ humanæ*, in Comment. Soc. Gotting. t. xiii.

§ Jacob, loc. cit. p. 508. Ammon, *de Genesi et Usu Maculæ luteæ in Retina Oculi humani obviæ*. 1830. 4to. Huschke, in Ammon's *Zeitschrift*, b. iii. p. 16. Arnold however asserts the existence of the opening, *Untersuchungen*, p. 89.

|| *Transactions of the Wernerian Society.*

composed of the fibres of the optic nerve separated where the nerve enters the eye, and then interwoven. In some animals this fibrous arrangement is distinctly visible, but nothing of the kind can be discerned in man, where the retina presents throughout a soft pulp. ARNOLD found it on microscopical examination, to consist of a congeries of globules* closely arranged, connected and supported by a delicate and transparent cellular texture, in which the minute ramifications of the arteria centralis are distributed.

The continuation of the retina under the ciliary processes, called the ciliary portion of the membrane, is a very thin and delicate structure, concealed by the pigment, and with difficulty discovered by the naked eye, but clearly seen with the aid of the microscope. ARNOLD says that it possesses the same granular texture as the rest of the membrane.

The blood-vessels of the retina are derived from the arteria centralis retinæ [2. 3. fig. 4.], a branch of the ophthalmic. It enters the optic nerve at a short distance from the sclerotica, passes through its centre, [18. fig. 1.], and ramifies on the inner surface of the retina [3. fig. 4.], forming a very minute vascular net-work over the whole membrane; no branches, however, can be seen in the ciliary portion. This artery is accompanied by a corresponding vein. In the eyes of animals recently dead the central vessels are usually found more or less filled with blood. Their distribution is beautifully represented, on a magnified scale, in the 3rd plate of ARNOLD'S *Tabulæ Anatomicæ*, fig. 5, 6, and 7; while the first four figures exhibit the natural appearance of the membrane. In the entire globe, the retina is smoothly expanded over the vitreous humour; but it soon falls into folds on a section of the eye.

Connexions of the Coats.—Having explained the texture and composition of these parts, I proceed to point out the mode in which they are connected with each other. In the first place, the retina covers the external surface of the vitreous humour; the parts lie merely in contact; nothing is interposed between them: there is no cellular connexion, no passage of blood-vessels. In front, however, the retina is firmly connected to the corpus ciliare and the vitreous humour; if we consider the dentated and slightly elevated margin (*margo undulato-dentatus*,) which corresponds to the posterior edge of the ciliary processes (*ora serrata* [11. fig. 1.]) to be the anterior termination of the membrane, it adheres firmly to the vitreous humour. If we adopt the now more generally received notion of the retina being continued to the circumference of the crystalline capsule, the thin anterior or ciliary portion of the membrane, placed between the ciliary body and the *Zonula Zinnii*, adheres most intimately, in its whole breadth, to both these, exhibiting folds and intervening depressions corresponding to those of the parts in question.

The choroid coat lies upon and covers the retina, in the same way as the retina embraces the vitreous humour; being merely contiguous, not actually connected with, or adherent to it, except at the anterior or ciliary portion of the nervous expansion. Its internal surface adheres, in the anterior part of the eye, to the vitreous humour, by means of the ciliary processes. Let me observe, in the first place, that the crystalline lens occupies the middle of the anterior part of the vitreous humour, and that on the latter, round the crystalline, there is a black mark, made by a number of impressions disposed in a radiated form. This mark arises from the adhesion of the ciliary processes, together with the ciliary portion of the retina, to the vitreous humour. If we detach the choroid coat from the latter, we shall observe the adhesion of the ciliary processes giving way, and we may see the defined edge by which the retina seems to terminate.

* *Untersuchungen*, pl. 2, fig. 3.

The external surface of the choroid is connected to the internal surface of the sclerotica, by numerous short and soft cellular threads, so loosely, that we can easily cut the sclerotic round with a pair of scissors, without injuring the choroid. The two coats adhere more firmly in front, where they are closely united by a dense white medium, called the *ciliary ligament* [9. fig. 1.] (*ligamentum sclerotico-choroidale.*) The point of union is just behind the cornea and the ciliary margin of the iris; so that this ciliary ligament, uniting the anterior edges of the sclerotic and choroid corresponds to the boundaries of the iris and cornea. When the sclerotic and choroid have been detached from the front of the eye, the ciliary ligament forms a white circle, marking the distinction between the choroid and iris, and a similar circle defines the boundary of the cornea; hence the expressions of *orbiculus*, *annulus*, or *circulus ciliaris*, as applied to the part in question.

The connexion to which I have just adverted, is an important part of the anatomy of the eye, because it will be seen, that at one and the same point the sclerotic and cornea are united externally, and the choroid and iris internally; while, at the same part, the choroid adheres internally to the vitreous humour, by means of the ciliary processes, the ciliary portion of the retina being included in the same adhesion. Further, the *zonula ciliaris*, to which these processes adhere, is closely connected to the capsule of the lens. We may, therefore, consider this as a common point of union, embracing all the essential constituents of the globe, namely, the sclerotica, cornea, choroid, iris, retina, vitreous humour, and crystalline lens. It is a most important part, in a pathological point of view; for example, in inflammation of the iris, or cornea, peculiar appearances arise in the sclerotic, and the affection easily extends from the iris to the ciliary ligament and processes, and thus reaches the posterior and inner parts of the globe; while inflammatory affections, beginning in the latter, may extend, in the same manner, to the anterior portion of the globe.

The black mark left on the vitreous humour, after the ciliary processes have been detached, is sometimes called the *zona* or *corona ciliaris*, while the ciliary ligament and processes, taken collectively, are spoken of, anatomically, under the denomination of the ciliary body, *corpus ciliare*.

To the same point, where the choroid and sclerotic are united by the ligamentum ciliare, the greater circumference, or ciliary margin of the iris is affixed; thus that ligament not only connects the former two coats, but also joins the iris to them. The iris seems, to use a mechanical phrase, to be set in the ciliary body; it is firmly connected to the boundary between the sclerotic and cornea; hence these parts, more especially the former, almost always participate in its morbid phenomena.

The *vitreous humour* appears, in its natural state, like a portion of perfectly transparent jelly. In the living human eye it is a little more fluid, than we find it in the dead eyes of sheep and bullocks; for when it escapes, as it sometimes does, in the operation for cataract, it runs over the patient's cheek in a continued stream, quite pellucid, and resembling in consistence the white of an egg. We can see no fibres, no vessels, nor any particular arrangement of parts in the vitreous humour; it is transparent, like a lump of clear glass; it is said to be composed of cellular texture, containing water in the interstices; if it be left to itself, and particularly if it be pricked, the fluid drains away; it is smooth and uniform on the surface, where it is in contact with the retina, the cellular substance being condensed externally into a membrane called *membrana hyaloidea*, or *vitrea*. In bulk, it composes four-fifths of the entire globe, occupying the whole cavity formed by the retina; indeed, if we make a vertical section of the

eye, in either direction, the coats represent a thin cup nearly filled with the tremulous vitreous jelly. PETIT found it to weigh 104 grains in an eye, of which the entire weight was 142 grains. Its cellular substance can be demonstrated by inflating and drying it after the fluid has been allowed to drain out; also by freezing the eye and then dividing it, when the figure and size of the cells are shown by the portions of ice which they contain. ARNOLD has represented this cellular structure as it appears in a vertical section of the frozen vitreous body.*

If, after removing the choroid and iris from the front of the vitreous humour, we wash off the pigment, we shall find a thin transparent membrane, extending from the dentated margin of the ciliary body (*ora serrata*) to the crystalline capsule. This is called *zonula ciliaris*, or *zonula* ZINNII [25. fig. 1.]; it is the *strahlenblättchen* of the Germans. It forms a ring of similar breadth to that of the corpus ciliare, and presents radiated grooves and folds running from behind forwards, to which the ciliary portion of the retina and the corpus ciliare are closely connected by means of corresponding folds and grooves. The pigment remains behind, after the choroid has been detached, forming a regular series of dark parallel striæ, arranged in a radiated form round the circumference of the lens. The undulated edge of the retina is attached to the posterior or external edge of the zonula; while the anterior, or internal margin of the latter is firmly attached to the crystalline capsule. The ciliary processes do not reach to the capsule, but leave a small interval between it and their termination; this part of the zonula presents striæ, which are continued on the anterior portion of the capsule.† Between the zonula ciliaris and the tunica vitrea an irregular space is left, which can be inflated by making an opening into the former. When air is impelled, a canal with puckered sides becomes distended, on the anterior surface of the vitreous humour, round the circumference of the lens. This is the *canal godronné*, or canal of PETIT [26. fig. 1.] Some have considered the zonula ciliaris to be a continuation of the vascular layer of the retina; others have represented that the vitreous tunic divides into two layers, and that the canal godronné is left between them. The retina separates easily from the zonula after a short maceration. The latter differs in structure from the tunica vitrea, being thicker, firmer and fibrous, and it may be removed, leaving that tunic entire.

The *crystalline lens*† [27. fig. 1. and figs. 19, 20.] which is imbedded in the cup-like excavation of the vitreous humour (*fossa hyaloidea,*) is a part of firmer consistence. It is retained in its situation by a compact membrane called its capsule, which is closely connected to the membrana vitrea; but is much more firm, dense, and resisting than that membrane. The crystalline lens is an optical instrument for refracting the rays of light, and bringing them to a focus; in its recent state, if it be held towards the flame of a candle, the flame will be seen inverted as with an artificial lens. It is not perfectly spherical, but is composed of portions of two spheres, the posterior half [2. fig. 20.] being more convex than the anterior [1. fig. 20.] The former is completely imbedded in the front of the vitreous humour, while the latter projects on the surface of the humour, being only covered by its capsule. The external part is so soft, that it can only be compared in consistence to soft jelly; but if this be squeezed off, the centre is found to possess the firmness of wax slightly softened: it is, in fact, firm in the

* *Icones Anat.* fasc. 2, tab. 3, fig. 11.

† This appearance is described and figured by AMMON, under the name of *orbiculus capsulo-ciliaris.—Zeitschrift;* vol. i. No. 1.

* See BAERENS *da Systemate Lentis crystallinæ*, and LEIBLEIN *de Syst. lent. cryst. Mammalium atque Avium*, in RADIUS *Script. Ophthalm. minores*, vol. i.

centre, and gradually looser in texture towards the circumference. The firmer central portion is called the *nucleus* of the lens.

How is the crystalline lens, or humour, as it is also called, connected with the other parts? It seems to be no otherwise attached than by the mere mechanical confinement of the capsule. This investment contains, but it cannot be shown to adhere to, the lens; we cannot trace any blood-vessels, any cellular connexion, or any direct adhesion. When the capsule is divided, the lens immediately escapes; if there be any vessels, they are of such extreme tenuity, that we cannot demonstrate them, nor can we show that the crystalline lens is organically connected with the parts immediately surrounding it. When an opening is made into the capsule, a minute portion of water escapes, which is called the *aqua* or *aquula* Morgagni, from the illustrious anatomist who first detected it.

The existence of this fluid has been denied; and Dr. Jacob seems to entertain doubt on the subject. He says, "the fluid called *aqua* Morgagni, supposed to surround the lens, and separate it from its capsule, appears to me, when it does exist, to be confined to the anterior part. I once met with it in the human eye, within five or six hours after death, and at longer periods in a few other instances, but how far the product of disease I cannot determine. In the eyes of sheep and oxen yet warm, I do not perceive the least appearance of such a fluid; after some time, however, has elapsed, it is found in considerable quantity, but evidently in consequence of that change which takes place after death, by which fluids are permitted to escape into situations not formerly occupied by them. Petit found only half a grain of this fluid within the capsule of the human lens, and could not obtain sufficient for analytical experiment from eighteen eyes; he also says he found it in one eye and not in the other."*

Dr. Jacob† also calls in question the commonly received opinion that there is no direct connexion between the lens and capsule. He attempts to show that they are organically connected. He adduces however no direct proof; and the facts on which his arguments are grounded, admit of different explanations from those he has assigned.

In the living animal, and within a short period after death, the lens is perfectly pellucid, like the clearest crystal, an attribute obviously necessary to the perfect execution of its office. It gradually becomes muddy, and the loss of transparency occurs more quickly when it is immersed in water; hot water, alcohol, and acids, render it immediately and densely opaque throughout. The kind of effect is seen in the boiled lens of the fish. In its pellucid state, no fibres, nor other organic arrangement can be observed; but the opaque lens has a fibrous structure, and exhibits some subdivisions of its substance. The entire body is divided into three parts by an equal number of lines meeting in the centre. [fig. 21.] It is made up of layers arranged concentrically like those of an onion, and these are found on microscopical examination to consist of fibres closely aggregated ‡ Arnold found these fibres to be tubular, and believes that they are lymphatics. But can we regard these appearances, thus obviously produced by powerful

* *Mem. de l' Acad. Roy. des Sciences*, 1730, *p.* 445. *Medico-Chirurgical Transactions*, vol. xii. p. 501. † Ibid, p. 499.

‡ Soemmerring has delineated the lens as it is found at the time of birth, the age of six years, and in the adult. Tab. 5, figs. 13, 14, 15. Arnold has figured it in the child, the adult, and the old subject. Tab. 3, figs. 14, 15, 16. It is nearly spherical in the infant, becoming gradually flatter in the progress of age. Arnold has carefully investigated and delineated the minute structure of the lens: *Untersuchungen*, Kap. vi. tab. 2, figs. 8 and 9. *Tab. Anat.* tab. 3, figs. 17—20, and 23—25. Descriptions and figures relating to the same subject are given by Huschke in Ammon's *Zeitschrift*, vol. iii. Heft, 1; and by Werneck, ibid, vol. v.

chemical agency on the dead lens as illustrating its living state? or draw from them any inferences respecting the supposed actions or changes of the living organ? Can we suppose the soft jelly of the lens, or its firmer nucleus, to be muscular, capable of contraction and relaxation, and thus of changing the figure of the organ?

The lens is more or less opaque during fetal existence; after birth it is large, colorless, and perfectly transparent; as age advances, it becomes less, and its nucleus is often amber-colored in old persons, in whom it sometimes becomes more or less opaque.

The capsule of the lens [28, 29, fig. 1.] is a perfectly transparent texture, not rendered opaque by maceration, or slight heat, and only slightly affected by boiling water or strong acids. It is compact, and perhaps cartilaginous; so firm and tough that force is necessary to lacerate it. The anterior portion [28. fig. 1.] is thicker and tougher than the posterior, [29. fig. 2.] and almost retains its figure when detached. The membrana vitrea is connected to it at the circumference of the lens, but can be easily separated; and the two structures are so dissimilar, that there is no ground for representing the capsule as a continuation of that membrane.

Although no vessels can be discerned or demonstrated in the vitreous humour or the crystalline capsule, in their state of perfect transparency after birth, they possess, during the fetal period of existence, arteries and veins, capable of demonstration by injection, and sufficiently large and numerous to impart a reddish tint to the textures. Arnold has delineated the arteries of the vitreous humour in two beautiful figures of his third plate (figs. 12 and 13,) as they appeared after injection in a fetus of four months: they present an elaborate and characteristic net-work spread over the whole vitreous body, forming an arterial circle round the margin of the lens, and then covering the anterior layer of the crystalline capsule with an arterial plexus. The arteries of the crystalline capsule are represented in the 21st and 22d figures of the same plate from a fetus of six months. A branch from the centralis retinæ proceeds straight through the vitreous humour to the centre of the posterior layer of the capsule, dividing then, and spreading its branches in all directions. It covers not only the back, but the sides and front of the capsule with a beautiful and delicate arterial net-work, which communicates in front with the arterial circle of the vitreous humour and with the arteries of the iris.

Arnold* found that these vessels ramify in a cellular layer, which can be stripped off, leaving the capsule entire; he therefore regards the latter to consist of two laminæ, an external *vascular*, and an internal *serous;* the latter being destitute of blood-vessels like other serous structures.

The blood-vessels of the crystalline capsule contain red blood in the fetal state only, or at farthest in the lately born child. They shrink up quickly after birth, so that they can neither be seen nor injected. Walther† says that he succeeded twice in injecting vessels in both parts of the capsule in the adult: they were cases of violently inflamed eyes, and the vessels of the cornea were at the same time successfully filled.

Arnold‡ found, under the microscope, a fine net-work of lymphatics in the inner or serous portion of the capsule.

Aqueous humour.—The last of the humours is the aqueous, consisting of a few drops (three to five grains) of clear watery fluid, filling the interval between the cornea and the crystalline lens, and escaping when the cornea is punctured. The space between the cornea and the crystalline lens is

* *Untersuchungen*, p. 111. † *De Venis Oculi*, p. 18.
‡ Lib. cit. p. 113.

unequally divided by the iris, into two portions, called the *anterior* and *posterior chambers* of the eye, or of the aqueous humour. Of these, which communicate by the pupil, the anterior is the most considerable, and consequently contains the largest quantity of fluid. Its boundaries are the concavity of the cornea and the iris. The posterior chamber is formed by the uvea, the front of the crystalline capsule, and a portion of the zonula; being bounded laterally by the ciliary processes, the points of which project into it. The uvea seems to be in contact with the crystalline capsule, at least it is separated from it by an interval which is not distinguishable by the senses; but if the eye be frozen, a small pellicle of ice will be found between the uvea and the crystalline lens. This contiguity of the parts accounts for the adhesions so often occurring between the pupil or uvea, and the capsule, under inflammation.

Some anatomists believe that the surfaces of the cavity containing the aqueous humour, are covered by a delicate membrane of the serous class, the office of which is to secrete that fluid. On the posterior surface of the cornea it may be detected, but the existence of such a membrane cannot be demonstrated on the iris or crystalline capsule. The iris, uvea, and capsule, forming portions of a cavity containing watery fluid, have smooth, or we might say serous surfaces: the possession of such a surface, however, and probably even the power of serous or other exhalation, does not necessarily imply the existence of a distinct membranous layer admitting of direct demonstration, as we see in the case of the dura mater, and the articular cartilages.*

PHYSIOLOGY OF THE EYE-BALL.

The science of optics, which has for its object the investigation of light and colors, and their relation to the organ of vision, is an extensive branch of natural philosophy, and would occupy a large space if adequately illustrated. I cannot enter at length into such a subject, and shall only make a few remarks respecting the physiology of the eye, confining myself to such topics as are most interesting in reference to disease.

The nature of light has not hitherto been clearly explained; at least among those who have devoted great attention to the subject, diversity of opinion still prevails. For our present purpose it will be sufficient to adopt

* In addition to the writings quoted in the foregoing description, to the well-known standard works of Zinn and Soemmerring, and the recent important publications of Fr. Arnold, the following may be referred to on the anatomy of the eye.

The article *Eye* in the *Cyclopædia* of Dr. Rees, written by Mr. Barnes of Exeter.

Dr. Jacob's article on the Eye, in the *Cyclopædia of Anatomy and Physiology.*

The first volume of the *Handbuch der Theoretischen und Praktischen Augenheilkunde* of Professor Rosas. *Vienna*, 1830.

Dr. W. Soemmerring *de Oculorum Hominis Animaliumque sectione horizontali Commentatio;* cum. fig. Gottingæ, folio, 1818.

Doellinger, *Illustratio Ichnographica Oculi Humani.* Wirceburgi, 1817.

———*Ueber das Strahlen-blättchen*, in the *Acta Novissima Naturæ Curiosorum*, tom. ix.

Salomon, *Beiträge zur Anatomie des Auges;* in Graefe *und* Walther's *Journal* vol. vii.

Weber *in* Graefe *und* Walther's *Journal* vol. ii.; *Ueber die wichtigsten Theile im menschlichen Auge.*

———*de Motu Iridis;* 4to. 1821.

Various Memoirs of Petit, in the Mém. de l'Acad. des Sciences, 1723—1730.

Several papers in Ammon's *Zeitschrift*, Graefe and Walther's *Journal* and other German periodicals.

the generally received notion, that light consists of an extremely subtle matter, emanating in all directions from luminous bodies, or from such as, not being themselves luminous, are illuminated by others, and proceeding in straight lines, to which the name of *rays* is technically given.

A ray of light then is to be regarded as a straight line drawn from any luminous, or illuminated body, to the eye of the observer. We make use of the expression "rays of light," and speak of the various affections which these rays of light undergo so familiarly, that we bring ourselves at last to believe that we are designating some material existence which has been clearly demonstrated. Rays of light are to be considered as emanating in all directions from any luminous body. Thus a candle placed in the centre of a room fills the whole of the room with light, more or less intense; if we take any portion of the rays proceeding from it they will represent a cone, the apex of which is in the flame of the candle: from this central point the rays diverge, separating from each other more and more widely as they proceed to a greater distance. These lines of light continue to diverge to whatever extent they may proceed; however, the divergence is greatest near the luminous body, becomes less and less as the distance increases, and when the source of light is very remote, we are so little sensible of it, that, for all practical calculations, the rays may be regarded as parallel; hence the distinction of divergent and parallel rays.

The extremely subtile nature of light, that is, of the cause of those phenomena and influences which form the subject of optics, make it so different from the ordinary forms of grosser matter, that it is not easy to demonstrate clearly its material nature; yet some of the affections, which light exhibits, bear a strong analogy to what is observed in the other forms of matter. Its reflection is one of these. Light falling on bodies freely permeates some, and these are called transparent. Others, on the contrary, do not admit it to pass through them, but reflect it, and these are called opaque. The light is reflected, or it rebounds from the surface of these opaque substances, and though the comparison may not be scientifically accurate, the occurrence is similar to the rebounding of a ball from a wall. The light strikes against an opaque body; the rays rebound and come back again from the body on which they fell. One of the most familiar instances of the reflection of light is that of a common mirror; the metallic coating behind the glass reflects the rays of light, which come back to the eyes of an individual standing before it, and represent his image as if it were behind the glass.

Another phenomenon exhibited by light is that called refraction, which literally means *breaking*. The rays, under certain circumstances, instead of proceeding in straight lines, are turned aside, and thus, as it were, broken or interrupted. This takes place whenever they pass from one medium into another of different density. If they travel on in one and the same medium, they invariably pursue a straight course through whatever extent of space they may be transmitted to the eye of the observer. But there are media, which, though they agree in the circumstances of being transparent, differ very much in their density; for instance, air, water, and glass. When the light passes from a rarer into a denser medium, it deviates from its straight course, and is drawn towards the perpendicular, or towards a straight line drawn through the two media at right angles to their line of contact. On the other hand, if the ray passes out of a denser into a rarer medium, it is turned away from the perpendicular. A familiar instance of this phenomenon is afforded by the appearance which a straight stick exhibits, when one-half of its length is immersed in water; it appears bent, or broken, at the surface of the water; for the immersed portion is

seen through the medium of refracted light, the rays which, on entering the air, have been drawn away from the perpendicular, making the object appear more elevated than it really is, and causing us to see it in a wrong position, while the portion in the air is seen by direct rays, and therefore in its true position.

It may be stated, generally, that the deviation of light from its straight course is greater in proportion to the density of the medium into which it passes; water refracts more powerfully than air, glass more than water, and the diamond more than glass; but in the case of the diamond, the influence of another principle is observed, viz. the more inflammable the nature of the body, the greater its refraction. Many familiar experiments may be made to illustrate the phenomenon of refraction; one of the most common is that of putting a piece of coin in a basin, on the ground, and retiring to such a distance that the margin of the basin may intercept the direct view of the coin; if the basin be then filled with water, the refraction which the rays of light, proceeding from the coin undergo in passing from the water into the air, will bring the coin, which was before invisible, into view again; we see it by refracted light, and consequently not in its true situation, the effect being exactly the same as in the case of the stick. Light coming to the earth from the heavenly bodies is refracted by the terrestrial atmosphere, and increases the apparent altitude of all these bodies. From this cause we see the sun before it has risen above, and after it has sunk below the horizon; thus the day is lengthened and the night shortened, and the phenomenon of twilight is produced.

When the rays of light fall on a dense, transparent body, of a convex surface, the effect of the refraction which they experienced will be to collect and unite them together into one point, at a certain distance behind the medium, the degree of refraction at each point of the convex surface depending on mathematical rules, calculated from the nature of the curve on which the rays fall. The most familiar instance of this optical law is afforded by a convex glass. As there is a close connexion between light and heat, when luminous rays are thus brought together, considerable heat is produced, sufficient, if the sun's rays be received upon a large convex glass, to burn substances placed at the point of union. Hence arose the first application of the Latin term focus (fire place) to this point; the word is now used generally, whether heat be produced or not. A concave glass has the opposite effect; instead of uniting the rays of light, it separates and disperses them; hence, optically speaking, rays of light are said to be collected or dispersed.

The transparent structures of the eye have the effect of collecting together the rays falling on the surface of the organ, and bringing them to a focus, or point of union, on the retina. The eye may, in this point of view, be regarded as an optical instrument; and as the effect of different transparent media on the rays of light may be calculated mathematically, the density and configuration of the media being previously given, we may, in some degree, imitate the composition of the eye artificially, and by putting together substances of a certain density and configuration, produce an instrument which will refract, collect, and unite the rays of light into a focus, in a manner nearly similar to that of the living eye. When we say that the eye can be imitated artificially, it must of course be understood that this can be effected only imperfectly. It is true that the human eye is an optical instrument, but it is so perfectly constructed, that the most profound theory can scarcely appreciate all the wonders which it exhibits, and the most exquisite art can only arrive at an imperfect imitation of it.

The business of vision is two-fold; consisting, first of the mechanical,

or optical effect, produced by the transparent media on which the rays of light fall; and secondly, of the impressions on the nerve, and through it on the sensorium, by which the mental perception of external objects is produced. If the transparent media possess a given density and a given configuration, and are situated in certain relations to each other and to the retina, the result will be, that the rays of light falling upon the eye, from any object at a certain distance, will be collected together into a focus on the retina, and upon that part of the retina will be represented a miniature picture of the objects placed before the eye; but, in this representation, the objects are inverted, or upside down.

We can prove, by calculation, that the effects of the transparent media of the eye on the rays of light would be such as they are in fact found to be; the results of experiment coincide perfectly with those of calculation, and the proof is easily exhibited, since the phenomena, being purely mechanical, take place in the dead just as perfectly as in the living eye. If we take the eye of an animal recently dead, and dissect away the back parts of the sclerotic and choroid coats, so as to expose, without wounding, the retina, and then hold it up at a certain distance from the candle, we shall see a miniature representation of the candle on the retina, with the apex of the flame downwards. The flame of the candle is seen inverted through the crystalline lens. If an eye prepared in the same way be placed in a hole made in a window shutter, an inverted miniature picture of the external objects is seen on the retina.*

Magendie describes more simple methods of demonstrating the images formed at the back of the globe. If the eye of a rabbit, pigeon, owl, or small dog, in which the choroid and sclerotica are semitransparent, having been cleared of fat and muscle at its posterior part, be held with the cornea towards illuminated objects, the images of such objects will be seen distinctly at the back of the globe. M. Magendie tried the experiment with eyes of the albino variety of animals, such as the white rabbit, pigeon, and mouse, in whom the sclerotica and choroid are very thin and delicate. The images in this case were particularly clear; and he was hence led to make various trials with such eyes, in order to show how the images at the fundus of the globe are affected by various changes in the state of the organ, such as diminished quantity of the aqueous humour or its entire absence, diminution of the vitreous humour, removal of the cornea and crystalline.†

These are the general effects of the action of the eye, considered as an optical instrument. The rays of light fall in the first instance upon the cornea, which, being a convex body, of greater density than air, exerts a refractive force upon them, drawing them together, so that if they were continued in the same direction and medium, they would meet in a focus at a certain distance behind the retina. All the rays falling upon the cornea do not pass through it; in order to permeate it they must strike upon the part within a certain given angle (of about forty-eight degrees.) Those which fall upon it more obliquely, are reflected from it, and produce that sparkling appearance which characterizes the living eye, and which it is necessary to introduce into portraits, in order to give them a character of life. The same reflection produces the image which we see behind the

* As the pictures of external objects on the retina are actually seen in these experiments on *dead* eyes, the notion has been universally received, never, that I know of, having been questioned, that such representations are formed in the retina of the living eye. Dr. Fleming, as quoted by Mr. Walker, rightly observes that as the retina is transparent, the rays of light will pass through it, and consequently no picture can be formed on it. *On the Nervous System*, p. 186.

† *Précis élémentaire de Physiologie*, ed. 2d, p. 70.

cornea, as that of our own countenance, when we are examining the eye, or that of an opposite window. The light, having been refracted by the cornea, passes through the pupillary opening, which, however, transmits that only which is near the centre; the lateral rays striking upon the iris, are reflected from it, and hence the peculiar brilliancy of that part. This is so striking in some individuals, that their eyes are literally, not metaphorically, sparkling. The degree of brilliancy depends upon the nature of the surface on which the rays strike; and this is different in different individuals. When the iris is altered by disease, nothing is more striking than its change in this respect; it no longer reflects light as in the healthy state, and the eye thus acquires a peculiarly dull and dead expression.

The pupil is the opening through which light enters the dark chamber of the eye; it is analogous to the aperture by which light is admitted into the optical instrument called a *camera obscura:* the interior of the eye is a dark chamber like the interior of such an instrument.

The rays of light, after passing through the pupil, strike upon the crystalline lens, where they undergo a powerful refraction; that lens being the principal agent of this process. The light thus refracted is ultimately brought to a focus on the concave surface of the retina. It must be understood that I am speaking of light proceeding from objects placed at a certain distance from the eye, and falling upon it in such a way as to produce distinct vision. The eye is subject, in this respect, to the same laws which are applicable to all optical instruments. It can only distinguish objects with accuracy at a certain distance; and though it may perceive nearer or more remote objects sufficiently for many purposes, vision without or beyond a certain limit ceases to be distinct.

I have stated that the crystalline lens is the principal agent of refraction; consequently when it is lost, as after operations for cataract, the refractive powers of the eye are greatly weakened, and it is necessary to substitute for the lens, which has been removed from the axis of vision by the operation, a glass of considerable convexity, even for the ordinary purposes of vision. It is difficult to appreciate exactly the effect which the crystalline lens produces on the rays of light, in consequence of its peculiar structure, varying in density from the centre to the circumference. Opticians represent that this peculiarity renders the eye achromatic. Achromatic means colorless; and it is a great object to construct optical instruments, such as telescopes, microscopes, &c. in such a way, that after the various reflections and refractions which the light may undergo, the object may be represented clear, well-defined, and uninterrupted by any admixture of prismatic colors. The decomposition of light which leads to this inconvenience, takes place at the surfaces of the glasses, through which it passes. If the lens had been of uniform density throughout, and as firm as its central portion, there must have been a reflection at both its surfaces, rendering the retinal picture indistinct; but, by the softness of its exterior, the density of its surfaces approximates to that of the aqueous and vitreous humours, and it refracts without reflecting or decomposing any of the light which falls on it.

The rays of light, in passing through the crystalline lens, undergo decussation; hence the picture represented on the retina is inverted. This is a mere optical phenomenon, not depending on any vital action, but arising from the mode in which the rays cross each other in their passage through the lens.

The refractive power of the vitreous humour is less than that of the crystalline; hence it gives passage to the converging rays, without altering them.* This structure fills out the globe to the requisite magnitude, affords

* [Theoretically it should slightly increase their convergency, and it is usually supposed to produce this effect.]

a soft medium on which the retina may be expanded, and keeps that nervous expansion at the proper distance from the lens and other parts of the organ, distending it so as to increase its extent, and thus enlarge the field of vision.

The retina is the immediate instrument of vision, its office being to receive impressions from the rays of light, when refracted and collected in the way already described, while the optic nerve conveys these impressions to the sensorium. To accomplish these purposes properly, the light must be applied in a certain degree of strength; when very powerful, as in attempting to look at the sun, a painful impression is produced; the eyes are dazzled, and we see nothing. On the other hand, a feeble light gives us only imperfect vision. If we attempt any occupation requiring accurate sight, with insufficient light, an uneasy sensation like that of fatigue will come on in the eye and brow.

Division of the optic nerve entirely destroys sight. M. Magendie found that the same effect was produced by dividing the fifth pair, so that the exercise of the sense seems to require the combined action of the two nerves. He observed, however, that the retina still remains partially sensible after the section of the fifth nerve, so that the animal closed the lid, when brought from the dark into a strong light.*

The iris can enlarge or contract its pupillary opening, and thus regulate the quantity of light admitted into the dark interior of the eye. When the organ is exposed to a weak light, the pupil is enlarged; when to a strong one, it is diminished; so that, in the living eye, if the quantity of light be altered, corresponding changes will be observed in the dimensions of this opening. These alterations are effected by contraction and dilatation of the iris, the motions of which are performed from the ciliary margin, or greater circumference, as a fixed point. Here the iris is closely attached to the ciliary body, the rest of the membrane being loose and movable. The iris contracts, or is rendered narrower, to dilate the pupil, the pupillary margin being drawn towards the ciliary edge; while the contraction of the aperture is effected by the pupillary margin being carried to a greater distance from the ciliary. These phenomena may be observed by placing a person opposite to a window, and putting the hand between his eye and the light; the iris will contract and dilate according as the light has free access, or is intercepted. If a strong light be suddenly thrown on the eye, the pupil will be considerably contracted; a painful sensation is at first experienced, and the person feels dazzled; but the pupil immediately contracting, shuts out the offensive quantity of light, and thus moderates the effect of its sudden influence upon the organ. When the eye, after having been exposed to a strong light, is suddenly submitted to a much weaker, the opposite changes ensue; the pupil dilates, and the effect upon the individual, when he is first introduced into the less degree of light, is almost to blind him for the moment; the pupil, however, gradually dilates. so as to admit the quantity of light necessary to vision in the new situation, The degree of motion in the iris, and the consequent amount of change in the dimensions of the pupil, vary in different individuals. In some persons, although the sensibility of the optic nerve is unimpaired, and vision is not defective, the mobility of the iris is very slight.

The iris exhibits two kinds of motion; the *independent*, produced by the direct influence of light, in its various degree of intensity, on the eye; and the *associated* or *sympathetic*, which takes place in one eye when not exposed to change, in harmony with the movements produced in the

* *Précis élémentaire*, p. 83.

other iris under alterations in the quantity of light. These are so far distinct, that the latter often continues when the former is at an end. Sometimes the optic nerve is completely insensible in one eye, and light produces no effect whatever on the iris of the diseased eye, if the sound organ be kept carefully closed; but if we produce motion in the iris of the sound eye, by varying the quantity of light, corresponding motion will be observed in the iris of the diseased eye.

The changes in the state of the pupil are not produced by the immediate influence of light upon the iris; for, if we direct a strong light upon that part, taking care that it shall not enter the pupil, no contraction of the aperture takes place. The iris does not move, the pupil is not altered, unless the retina be influenced. FONTANA* bestowed great pains in investigating this point experimentally, both in the human subject and in animals, varying his trials in many ways so as to avoid all sources of fallacy. The result of his experiments clearly establishes the position just laid down.

We are thus led to the conclusion that the motions of the iris are caused indirectly through the influence of light upon the retina. The phenomena of disease accord with this view. When the sensibility of the retina to light is impaired, there is a corresponding imperfection in the movements of the iris, and they cease altogether, when the nervous expansion has become completely insensible. Yet we occasionally meet with exceptions in this respect, which prevent us from laying down the rule that the action of light upon the retina is absolutely necessary to the motions of the iris. In some instances, not merely of partial, but complete amaurosis, not only does the iris retain some power of motion, but occasionally its movements are perfect. I have sometimes seen perfect mobility of the iris in amaurosis caused by hydrocephalus, where the retina has been completely insensible, so that the patient could not distinguish light from darkness. The phenomenon in question is not confined to cases of that description. Farther particulars on this subject will be found in the chapter on amaurosis. In amaurosis from hydrocephalus the cause of blindness is in the sensorium, not in the retina or optic nerve, which retain their perfect structure. Perhaps it may be found that the retina is not the seat of disease in the other instances of amaurosis accompanied by a movable state of the iris.

From experiments on animals we should draw the inference, that the motions of the iris are directly dependent on the effect, which variations in the quantity of light produce on the retina. Division of the optic nerve renders it motionless. MAGENDIE states that the same effect is produced in the dog and cat by dividing the nerve of the fifth pair.†

ARNOLD explains the associated action of the iris by the union that exists between the two nerves of the third pair at their origin. He says that "the nervus oculo-motorius arises not only from the crus cerebri, but also from the mass between the two crura, the substantia perforata media, so that several roots of the two nerves are intimately united at this point. I consider that the corresponding and simultaneous movement of the two irides depends on this union, as the unity of the visual organ is explained by the junction of the two optic nerves in the chiasma."‡

The size of the pupil varies in some degree according to the distance of what we look at. It dilates when the eye is directed to a remote object, in order to admit a greater quantity of light, which reaches the organ in a less intense state; and it contracts when a nearer object is looked at, as

* *Dei moti dell' Iride*, Lucca, 1765, chap. i.
† *Précis élém.* p. 76.
‡ *Untersuchungen* p. 80.

the light then comes in a more powerful form. These alterations, however, according to distance, are irregular and limited, and by no means adequate to account for the adjustment of the eye to different distances. The quantity of light influences these changes as well as the distance, for if the body, although extremely remote, be powerfully luminous, the pupil contracts, as in looking at the sun.

During sleep the pupil is contracted, as we may easily convince ourselves by examining the pupil of a sleeping infant. By gently elevating the upper lid, we can examine the eye, and ascertain the state of the pupil without waking the child. Perhaps we should not have expected *à priori* what we find, namely, that, in this quiescent state of the organ, accompanying the repose of the external senses and of the sensorium, and the relaxation of the voluntary muscles, the pupil is contracted: it is very small, and dilates immediately if the child wakes. This circumstance was particularly noticed by FONTANA, who made observations on the subject, both in man and in the cat: in the latter he sometimes found the pupil quite closed, and representing a mere line.*

When the nerve of the third pair, from which, through the ophthalmic ganglion, the ciliary nerves are principally derived, is paralyzed, the iris is motionless, and the pupil is dilated. I have seen instances, in which there was paralysis of all the parts supplied by the nerve of the third pair, viz. three of the recti muscles, one of the obliqui, and the levator palpebræ superioris, so that the upper lid could not be elevated, and the globe was drawn outwards by the external straight muscle; in these cases the pupil has been largely dilated. It might be suspected that the optic nerve was insensible; but we shall find at least in some of these cases, that, if the patient looks through a minute opening in a card, producing what may be called an artificial contracted pupil, vision is perfect.

Belladonna, and some other narcotics, when applied externally, or taken internally, render the iris motionless, and largely dilate the pupil. This condition of the part, which will be more particularly considered hereafter in treating of internal ophthalmic inflammation, was called paralysis of the iris by HIMLY, who first directed the attention of the profession to the subject.

The pupil is dilated in the complete insensibility of cerebral compression, whether from accident or apoplexy; and it is contracted in the opposite condition of cerebral excitement. In some morbid conditions of the alimentary canal it is enlarged; as in certain cases of worms, or of loaded intestines. It is permanently dilated when the optic nerve is completely insensible, in most cases; it will probably be found in the instances which are exceptions to this rule, that the iris had undergone previous change, rendering it to a greater or less degree insusceptible of dilatation.

The question has been asked, which is the active and which the passive state of the iris? Contraction of the pupil has generally been referred to action of the iris; and dilatation of the opening, taking place under the circumstances just enumerated, has been considered to imply a passive state of the organ. When the motions of the iris are observed in the living eye, we can hardly suppose it to be passive, either in the contracted or dilated state of the pupil; and we are inclined to agree with those,† who have held the opinion that it is active in both conditions of the opening: that the contraction is affected by change in the lesser circle,

* Lib. cit. chap. II.

† RUDOLPHI, *Physiologie*, vol. ii. p 217. ARNOLD, *Untersuchungen*, p. 75.

while dilatation is accomplished by the outer or radiated portion of the membrane. The pupil is found, after death, in the middle state, between contraction and dilatation.

The nature of the motions exhibited by the iris has been a subject of controversy, which is not yet settled; and it is immediately connected with the question respecting the intimate structure of the organ. Motion is generally seen in the animal economy as an attribute of muscular structure: this would account for the opinion entertained by many that the iris is muscular. The question is, in a great measure, a verbal one, and the answer will depend on the notions we affix to the expressions *muscularity* and *muscular motion.* In external appearance, and on the first view, the iris is unlike any other muscle, whether of the voluntary or involuntary kind, though it presents an obvious fibrous arrangement, both on its anterior and posterior surfaces. On the former or colored surface, there are evident fibres or striæ, of a radiated disposition, converging towards the pupil. We observe in this anterior surface an evident division into two parts; an outer or larger, an inner or smaller circle; these are generally different in color, the inner being usually the darkest, and not unfrequently of a different tint. The external circle exhibits an arrangement of radiated fibres, which, arriving at the inner circle, divide into branches uniting together laterally, so as to form an undulated line of division between the two circles: from this line numerous straight and delicate parallel fibres proceed to the pupillary margin. When the dark pigment has been washed off the uvea, it has a whitish or greyish color, and the surface is composed of straight fibres, converging from the ciliary to the pupillary margin, quite unlike those in the anterior surface. The iris resembles muscular organs in its great vascularity and large supply of nerves. The latter, which are very numerous, and as abundant in proportion to the size of the iris, as in any organ of the body, come from the lenticular ganglion, and from the nasal branch of the ophthalmic, and run between the sclerotic and choroid coats, where we meet with them, on cutting round the former, distinguished by the contrast of their whiteness with the dark ground of the choroid.

The muscularity of the iris has certainly not been established by direct anatomical investigation, although much pains have been bestowed on the inquiry, and the aid of magnifying powers has been employed. Indeed, from the delicacy and minuteness of the parts, the subject is a difficult one; and, as the question turns on minute circumstances of color, arrangement, and size, the observer easily succeeds in seeing that which his previous opinions lead him to wish. Thus many feel quite certain that the anterior fibrous arrangement is a radiated muscle, the contractions of which contract the iris and enlarge the pupil; and they are equally positive that the posterior surface of the organ has a circular or sphincter muscle, which antagonises the former. I have already cited the strong negative testimony of Arnold, whose intimate acquaintance with minute structure, and long habit of microscopic observation, give great weight to his opinion.—See *ante*, p. 63. He finds in the iris nothing but blood-vessels and cellular texture, and supposes the latter to possess a contractile power, by means of which the motions of the iris are effected. We see various instances where motion exists independently of muscular structure, as in the integuments generally, and those of the scrotum more particularly, in the ureter, and perhaps the urethra. In reference to this subject it may be observed that the iris does not contract, like other muscles, from the application of galvanism or electricity, or from mechanical or chemical stimuli after death. Nor have we any evidence that it possesses sensibility.

Some have supposed that the movements of the iris may depend on changes in the blood-vessels which enter so largely into its composition; that it may be susceptible of a kind of erection, and of collapse. Not a particle of conclusive and satisfactory evidence has been adduced on this point; while the supposed changes in the blood-vessels are clearly negatived by direct observation of the part in the albino and white rabbit.

As the nerves of the iris are derived principally from the ophthalmic ganglion, its movements are automatic: some ciliary branches, however, are furnished by the nasal branch of the ophthalmic. Certain individuals are said to have had the power of moving the iris voluntarily. The influence in these cases must have been indirect, as in the rare examples where a similar power has been said to exist over the motions of the heart. MAGENDIE mentions an experiment, which shows how the iris may move indirectly, and also exemplifies the contraction of the pupil caused by looking at near objects. Having selected a person with very movable iris, he places a sheet of paper at a certain distance from the eye, and observes the state of the pupil. He then directs the person to read small characters written on the paper, without moving the head or eyes: the pupil immediately contracts, and the state of contraction lasts as long as the effort is continued.*

[Recent investigations relative to the structure and mode of action of the iris, though they have contributed a few facts, furnish nothing to lead to positive conclusions on the subject; and it remains to the present moment an unsolved problem.

M. MAUNOIR† of Geneva to support the view which he has so long maintained of the existence of the sphincter muscle around the pupil, and the radiated muscle in the rest of the iris, states that in a recent case of accident he had an opportunity of observing their antagonist action. A man received a small penetrating wound through the lower part of the cornea, and a point just higher up in the iris. When the cornea healed, a triangular false pupil was found at the wound of the iris. Both this and the natural pupil could contract and dilate; but, on the contact of light, the false pupil dilated and enlarged when the natural one contracted, and the false pupil contracted when, in the absence of light, the natural one was dilated.

The support which this solitary case would seem to give to the theory of M. MAUNOIR, is entirely subverted by the numerous observations made by E. H. WEBER,‡ in cases of artificial pupil wounds of the iris, &c. These observations go to prove, that the movements which occurred could not be explained by supposing that the iris has circular or radiated fibres, or both, but only by believing that its irritable part consists of fibres variously woven together without any definite direction.

The objection long ago, urged by FONTANA§ to the muscular hypothesis that the motion of the iris is too great, to be executed by the contraction and relaxation of radiating muscular fibres seems to us to have much force. The iris when the pupil closes in sleep, he states is thirty times broader than it is when the pupil is in its state of greatest extension. No muscular fibre, he urges, can shorten itself to this extent. In warm-blooded animals, there is no muscle which shortens itself one-half; and

* *Précis élémentaire*, p. 75.
† Acad. des Sc. 19 Feb. Gaz. Med. de Paris 24 Feb. 1844.
‡ Hildebrandt's Anatomie Bd. IV. p. 80.
§ Dei Moti dell' Iride. Lucca, 1765.

even polypi, in their state of greatest length, are never more than twelve times longer than in their state of greatest contraction.*

C. R. HALL† Esqr., whose microscopical examination of the structure of the iris we have already noticed, (see p. 64,) thinks that the phenomena of its motions can receive no satisfactory explanation on the hypothesis of contractility alone, or on that of the antagonism of two sets of muscular fibres, the one dilating, the other of contracting the pupil. He is convinced that the contraction of the pupil is the effect of muscular action; but does not consider the knowledge we at present possess is sufficient to enable us to determine the nature of the agent by which its dilatation is effected. He, however, throws it out as a conjecture, that this latter action may be the result of an unusual degree of vital contractility, residing either in the cellular tissue, or in the minute blood-vessels of the iris. It is from elasticity, he believes, that the iris derives its power of accommodation to changes of size, and its tendency to return to its natural state from extremes, either of dilatation or contraction; but beyond this, elasticity is not concerned in its movements.

Signor GUARINI‡ endeavors to prove that the motions of the iris are the joint result of the contraction of muscular fibres and of vascular turgescence. He believes that it is impossible by mere vascular erethism to account for the extreme rapidity of the motions of the iris. An erectile organ requires a certain time to attain erection, and does not reach that state with the lightning-quickness which characterizes the action of the pupil; motions so instantaneous can only take place through the play of muscular fibres. Again, organs formed of erectile tissue can readily undergo the various gradations between flaccidity and turgescence; but we do not see them pass immediately from one extreme to the other, then return abruptly to their former condition, to reassume not less quickly the second: but the pupil does exhibit all these variations. Thirdly, with erectile organs the state of repose is that of relaxation; but, on the contrary, the passive state, the repose of the pupil, is an extension midway between dilatation and contraction; and lastly, the condition of medium extension is that in which we find the pupil of the dead subject, whilst erectile organs are left by death in complete flaccidity. Signor Guarini, however, does not on these accounts deny the share taken in production of the pupillary movements by turgescence of the iridal vessels; only, in his opinion, the latter exerts but a secondary and accessory influence which he explains in the following manner:—

All the erectile organs of the economy are environed with muscles or contractile fibres, the contraction of which, by pressure on the veins, of which these organs are principally composed, produces a momentary stasis of the blood within them, without compressing them so strongly as to impede the entry of arterial blood.—The vessels of the iris being interlaced with the circular fibres which effect contraction of the pupil, these fibres cannot act without arresting the blood in the vessels; a stagnation which contributes to augment contraction. Signor Guarini then admits the two orders of circular and radiating fibres in the structure of the iris, the former to diminish, the latter to dilate the pupil; and describes that the circular receive their motive power from filaments of the third pair, which emerge from the ophthalmic ganglion; whereas the radiating fibres are supplied by minute branches, which, arising from

* The Physiology of Vision. By W. Mackenzie, p. 205.
† Edinburgh Med. and Surg. Journal. July, 1844.
‡ London Medical Gazette. Sept. 1845.

the superior pair of cervico-spinal nerves, enter the first cervical ganglion of the sympathetic, and, subsequently united with the sixth pair, pass into the orbit.

The following experiments tend to establish this particular distribution. If, as Professor Valentin has shown, we divide the third pair of nerves in a living animal, the pupil dilates; if we remove the first ganglion of the great sympathetic, it contracts. Now, Signor Guarini having observed that in animals killed with strychnine the pupil is dilated, conceived he could make use of this fact to determine the nervous sources of the different iridal movements: so, having extirpated an animal's superior cervical ganglion, and thus produced contraction of the pupil, he administered strychnine. The pupil of the side operated on only dilated a little, for the filaments of the third nerve, now unopposed, maintained its contraction; but the pupil was seen enormously dilated on the other side, as ordinarily occurs in poisoning with strychnine. Again: if, on a body still irritable, we prick the third nerve, or the ophthalmic ganglion, the pupil slowly contracts, and does not afterwards dilate; but if we lay bare the superior cervical ganglion while the animal is alive, then kill it, and irritate the third pair, we shall still observe contraction of the pupil, which will now, however, disappear on irritating the cervical ganglion. "This," says the author, "proves incontestably the existence of muscular fibres in the iris; for muscular tissue alone has the property of contracting after death under the influence of mechanical or chemical irritation. I defy those who admit vascular erethism only as the cause of the motions of the pupil, to produce erection of the penis or clitoris in the dead subject by those means which so unequivocally determine the movements of the iris."

In conclusion, according to Signor Guarini, contraction of the pupil depends not only on the action of the circular fibres, but also on the stasis of the blood within the veins of the iris produced by that muscular action. The reality of the influence of this supplementary cause is placed beyond doubt [?] by the following fact:—In essaying by the strongest stimulation of the third pair in a body yet irritable, to produce contraction of the pupil, one can never succeed in rendering it as circumscribed as in the living; for the circulation having ceased, the blood is not confined in the vessels so as to impart, as during life, the utmost degree of narrowness to that aperture. It appears that the dilatation of the pupil, on the contrary, takes place as the effect entirely of contraction of the radiating fibres; since the enlargement we obtain in the subject by irritating the superior cervical ganglion is quite as considerable as that which ensues on the application of belladonna to the living.

Mr. France,* in commenting on these views, remarks:—The author's endeavor to prove that venous erection is superadded to circulo-muscular contraction, as at once its effect and consummation, appears to me singularly unfortunate; for even if we admit the anatomical relation of vessel to muscular fibre, which he assumes, the hypothesis will be found inadequate to explain what it professes to do. The circular fibres are only supposed to exist at the immediate margin of the pupil, and the flow of venous blood in the iris is necessarily, in general direction, centrifugal; hence, if Signor Guarini's notion were correct, erection by venous obstruction would arise from a mechanical impediment situate at the distal side of the obstructed part, which is impossible. That arterial congestion should result from this mechanism is not, however, unlikely; yet

* London Medical Gaz. Sept. 1845.

either idea derives but little countenance from the inconclusive reasoning with which the author supports his own: for, 1st, equally vigorous contraction of pupil could not be expected in the dead as in the living body; and 2dly, though dilatation is reported to have been disproportionately great, yet the standard of comparison (the effect produced by belladonna in the living) is too variable to allow a legitimate inference to be founded on the observation as thus recorded: the actual and positive degree of dilatation should have been specified.

Valentin's investigations of this subject, referred to by the author, are of course worthy of the highest consideration: he fully confirms the truth of the conclusions arrived at by Mayo, with respect to the powers of the third cerebral nerve over the contractions of the pupil; but he advances further, and claims an active dilating influence for nervous fibrils, originally emerging from the superior cervico-spinal nerves, and after intimate connection with the superior cervical ganglion of the sympathetic, and that of the vagus, reaching ultimately the ganglion ciliare and iris, by means of the carotid plexus or branches of the fifth.

Serres* from a curious property which he observed in the ciliary nerves, has been led to the conclusion that the expansion of the iris was affected by the contraction of those nerves. If we open the eye of an animal, and remove one of the ciliary nerves, which we find between the sclerotica and choroid, as soon as we lay hold of one of its extremities with a pair of forceps, the nerve coils itself up, so that in a few seconds it is reduced to $\frac{1}{20}$ of its natural length. If we now plunge it into water, it resumes its former length; but on lifting it out again, it twists itself together as before. Serres concludes from this observation, that the ciliary nerves being continued into the iris, it is by this contractile power, that the pupil is expanded. In support of this hypothesis, he notices the fact, that those animals in whom the pupil is motionless, as the frog, have no ciliary nerves.†]

Distinct vision requires not only perfectly pellucid humours, and a clear impression of the object on the retina, but also that the interior of the eye should form a perfectly dark chamber, to absorb all the light except that which contributes to form the image on the retina. Hence the dark color of the choroid, ciliary processes, and uvea: hence, in man, where the whole of these are colored by the dark pigment, vision requires much light, and he sees badly in the dark. Animals, on the contrary, have part of the internal surface of the choroid (the tapetum) light, and capable of reflecting the luminous rays. Those rays, which the dark human choroid absorbs, are reflected by the tapetum of the animal, and again strike the retina, thus producing a greater impression with less light, a circumstance of great importance to those which feed, and pursue their prey, by night. The herbivorous tribes, in many cases, go on feeding in the dark; the carnivora are drowsy and inactive by day, and go out to supply themselves with food at night. The reflection of light, from the tapetum, gives a luminous appearance to the eyes of animals in the dark; the pupil is dilated, and the reflected light is of the same color as the tapetum. This is a fact of familiar observation in the cat, where the bright yellow of the tapetum renders the phenomenon very conspicuous. In our own species, individuals with light choroids see in weak light better than those in whom the membrane is dark. The light of day is too powerful for the Albino; it dazzles him and obscures his vision. If he attempts to examine any object in the full glare, he knits and draws down his brows, and keeps his

* Anatomie comparée du cerveau, II. 652. Paris, 1827.

† Mackenzie, Physiology of Vision, p. 205.

lids almost shut. In twilight, however, he sees clearly, and he has tolerable vision even in the dark. The ferret, which has no pigment, is a kind of subterraneous animal, following its prey under ground; and the rabbit, in which the same deficiency so often occurs, requires, from its habits of life, a similar kind of vision. The Albino variety is very common in the domestic mouse, which passes its life almost entirely in the dark.

The situation of the impression on the retina is at the intersection of the optic axis with that nervous expansion. The optic, or visual axis is a straight line drawn through the centre of the cornea, pupil, lens, and vitreous humour, and consequently meeting the retina at the centre of the posterior hemisphere of the globe; the light refracted by the cornea and lens will come to a focus at this point. In order to see an object perfectly, it must be so placed that the rays proceeding from it may be collected in this situation, which seems to be more sensible than the rest of the retina. Under other circumstances an imperfect image is formed, and the farther the objects are placed from the direction of the visual axis, the greater is this imperfection, until at last vision is not affected. The limits of its exercise around the visual axis correspond with the external boundaries formed by the surrounding parts of the face; the greatest scope is outwards, the next downwards, then inwards, and the most confined range is upwards; thus we have the widest extent of vision in those directions in which the greatest number of objects occur. The retina is much more extensive than the field of vision; indeed a considerable portion of it is so placed, that the light going through the transparent media of the eye can never be brought to a focus on it.

The visual axis strikes the retina externally to the termination of the optic nerve, which is placed nearer to the nasal than to the temporal side of the globe. The entrance of the nerve through the choroid, which appears as a small, round, white spot on the interior of the globe, is called porus opticus, and is said to be insensible; if it be so, we understand why the nerve did not penetrate the tunics in the centre. We certainly should not have supposed, *à priori*, that this part could be destitute of sensibility; for the nervous matter which is thinly and widely expanded in the retina, is here concentrated into a small spot. Experiments, however, are cited in proof of the fact, and they show, at all events, that there is an insensible spot not far removed from the axes of vision. Some complicated means of bringing the light to bear on the porus opticus of each eye at the same time are detailed in works on natural philosophy. The fact may, however, be exhibited by a more simple process. Stretch out your arms at full length with your thumbs extended and close together; shut one eye (say the left) and keep the other steadfastly fixed on the left thumb; keeping the left hand steady, and the right eye fixed on it, move away the right hand slowly towards the side; the right thumb will be lost for a moment, at a certain distance, and then come into view again.

Calculations have been made of the size of the retinal picture; that it must be extremely small is obvious. A landscape, of miles in length and breadth, with its hills, woods, rivers, houses, cattle, and all the endless details belonging to these, and a thousand other objects, is painted in a membranous space not larger than the finger nail, by means of light let in at an aperture (the pupil) often not larger than a pin's head. No part of the animal economy is more calculated to excite our surprise and admiration than the contemplation of results so multiplied, varied, and important, produced by means so simple and apparently trivial. In the section of a gilt silver wire we can distinguish the gold, when its thickness does not

exceed the 110,000,000th part of an inch. How shall we calculate the size of the image on the retina?

Physiologists have been much puzzled by the inverted image on the retina, and have endeavored to explain how, in spite of this we see things in their true position. It must be observed, that every thing we see is painted inverted on the retina, and the problem is, to find out how we avoid the error that would apparently be produced from this cause, and see all external objects in their true relation to ourselves. BUFFON, CONDILLAC, and others boldly assert that we actually see them inverted; that they appear at first upside down; that touch corrects the mistake, and that by habit, at last we see them in their true position. Not a single fact can be adduced in proof of this position; on the contrary, all our observations on infants, on persons born blind and restored to sight, on the newly-hatched bird, and the newly-born calf, foal, lamb, and other animals, clearly prove that, in respect of relative position to themselves, their vision leads them into no error. If we see every thing inverted, and have to depend merely on experience and habit for rectifying so essential an error, the correction could apply only to objects seen repeatedly; but we see new objects just as correctly, in relation to ourselves, as those with which we are most familiar. We judge of situation by the direction in which the luminous rays reach the eye; in obedience to this law we shall refer the upper and lower end of an object to their real places, although the rays strike on the respectively opposite parts of the retina. On the same principle we often err in the situation, and no length of experience rectifies the error. We see our own image behind the mirror; we see it lengthened, shortened, inverted, according to the form of the mirror; and we see the stick, which we well know to be straight, crooked when it is half immersed in water. The notion of naturally seeing things inverted arises from a partial view of the subject; as if vision were performed in the orbit; as if the sensorium were just behind the retina. The impression on the retina is only one of many conditions belonging to vision. Consider the long course of the nerve in the orbit; its passage within the skull, and the junction with that of the other side; its complicated connexion with various cerebral parts. The original impression may be modified in many ways that we know nothing of, before the ultimate effect is produced on the sensorium. That an action on the retina should let into our minds all the boundless extent and diversity of visual perceptions, is indeed unintelligible to us as to the mode of accomplishment; but the communication of a knowledge of true position by an inverted retinal image, is neither more nor less difficult to comprehend than the mental perception produced by impression on the nerves of any other sense.

Philosophers have given a similar solution of single vision with the two pictures, one in each eye. The difficulty here has arisen from our tracing the exact impression on the nerve, and finding it to be a picture. Is there not just an equal difficulty in single hearing with two ears? single thinking with a double brain! and the tangible perception of a single object with impressions on thousands of cutaneous nerves! Here again philosophers have confidently asserted that we naturally see double; that touch gradually teaches us that objects are single, and habit at last makes us see them so. We have not a shadow of proof to support so strange an assertion, while we collect clear evidence from infants, cataract cases, and young animals, that they naturally see objects single from the first. Experience is of no use when an error is really made; in sensorial affections, accompanied with strabismus, in displacement of one globe, or by pushing one eye aside with the finger, double vision is produced, and continues as long as the cause

lasts, in spite of our perfect knowledge that the objects thus seen double are really single.

The opinion has been advanced, that, in the attentive exercise of vision, when we look at objects to examine them carefully, one eye only is employed, although both may be open, and apparently directed towards the object thus examined. A familiar experiment is adduced in proof: placing any object, for instance a pencil, between himself and a candle, let a person bring the pencil and flame into a line, with both eyes open; then let him close one eye: if it is the weak eye, the flame and pencil are still seen in a line as before; if it is the stronger, the flame of the candle seems to move aside, and is now seen out of the line with the pencil.

In opposition to this view MAGENDIE mentions an experiment to prove that an object, though it appears single, is seen at the same time by both eyes. Receive the image of the sun in a darkened chamber; take two thick glasses, each of them presenting one of the prismatic colors, and place them before your eyes. If you have good sight, and eyes of equal strength, the image of the sun will appear of a dirty white, whatever may be the color of the glasses. If, on the contrary, one eye be much stronger than the other, the solar image will be of the same color with the glass before the strongest eye.*

The concurrence of the two eyes is generally necessary for accurate vision, and especially for judging of distance. The difficulty of snuffing a candle, when we close one eye, is well known. MAGENDIE mentions that a person whom he knew, and who had lost one eye, was obliged for several months to proceed slowly and in a groping manner to take hold even of objects within his reach. He mentions the following experiment in illustration of the subject: suspend a ring by a thread; take a long rod with a hook at the end; place yourself at a proper distance, and endeavor to carry the hook through the ring. If both eyes are open, you will succeed every time. Shut one eye and you will succeed no longer; the hook will go too far, or not far enough, and you will only accomplish the point in several trials, and with uncertainty. Persons whose eyes are of very unequal power, do not succeed in this experiment even with both eyes open.†

We cannot, therefore, account for the unity of vision on the supposition that one eye only is used, although both are open. The explanation must probably be derived from the union of the two optic nerves within the cranium, which is so arranged as to connect intimately the nervous apparatus of the two organs in every direction. If the fibres of the nerves are carefully traced in the union or *chiasma*,‡ behind and before it, so as to show the course which they severally take, as represented in the eleventh figure of ARNOLD's fourth plate, it will be found that three orders of fibres can be distinguished in each nerve, before and behind the united portion, and in the chiasma itself. Those of the middle and largest division decussate in the chiasma, the fibres of the right tractus opticus going to the left optic nerve, and vice versa. The exterior fibres of each tractus pass along the corresponding sides of the chiasma, and are continued to the outer side of their respective nerves, not joining together in any way. The posterior fibres of the chiasma represent an arch, of which the concavity is turned backwards; they are continued on each side along the inner margins of the tractus optici, thus uniting the cerebral portions of the nerves, without

* *Précis élémentaire* p. 86. † Ibid. p. 87, 88.

‡ Χιασμα and χιασμος are Greek words meaning decussation; the term therefore implies the fact that there is decussation at the union of the optic nerves. On the question of decussation see Metzger *de controversa Nervorum opticorum Decussatione.* Königsberg, 1794.

being connected to the orbital parts (*fibræ arcuatæ cerebrales.*) The front fibres form a similar arch, of which the concavity is forwards, and are then continued along the inner side of the orbital portions of the nerve (*fibræ arcuatæ orbitales;*) so that they unite these parts of the optic nervous apparatus, without going to the brain.

[The eye has been thus far regarded, principally, as a dioptric* instrument, that is, in reference to its power of transmitting the rays of light to the retina and so refracting or collecting them as to form images of external objects on that part. This is undoubtedly its especial function, —that for which it was designed,—nevertheless all the rays of light which impinge upon these transparent textures are not transmitted, some of them are reflected, (see p. 77.) and these catoptric phenomena though merely incidental, are worthy of consideration, inasmuch as they afford important diagnostic signs in certain affections of the organ.

It has been stated (p. 75.) that when light falls upon some surfaces, instead of passing through them, it is reflected or rebounds from their surface. In such cases the angle of reflection is always equal to the angle of incidence, and this is true whether the reflecting surface is plain, convex, or concave.

Images formed by a *plane* reflecting surface, are equal and similar to the objects, and appear at the same distance behind the plane that the objects are before it.

Images formed by a *convex* reflecting surface, always appear behind it, and they are erect and smaller than the objects they represent. The greater the convexity of the mirror† the nearer and smaller appears the image. When the object is moved laterally the image moves in the same direction. As the object is approached to the mirror, the image approaches also, and vice versa; and the nearer the object is approached to the mirror the less is the image diminished.

Images formed by a *concave* reflecting surface, when the object is placed further from it than its principal focus, appears before it, diminished and inverted.

The cornea, and anterior and posterior crystalline capsule reflect images of luminous bodies in accordance with these laws. If a lighted candle be held before a healthy eye, three images of it are visible, two upright and one inverted.

The cornea presenting a regular, polished, *convex* surface, reflects an erect and diminished image which moves in the same direction as the candle when this latter is carried laterally. A reflection takes place from each surface of the cornea, but the thinness of this coat renders the interval between the images so small, that they appear as one. If, however, a candle be held before a common watch glass, the two images may be readily distinguished.

The anterior crystalline capsule having a surface similar to the cornea,‡ reflects a similar image. This image is, however, larger, being magnified by the aqueous humour and cornea through which it is seen. It is also much paler and less distinct, owing to the manner in which the rays

[* Instruments which operate on light by *refraction* are termed *dioptric* from δια through and οπτομαι, I see; those which operate on light by *refraction* are termed *catoptric*, from κατα against and οπτομαι, I see.

† All surfaces of a regular form which reflect images are termed mirrors.

‡ According to Dr. Mackenzie (Physiology of Vision, p. 73.) the curvatures of the anterior surface of the cornea and of the anterior crystalline capsule are the same, the radius of curvature of each being thirteen-fortieths of an inch; other authorities consider the curvatures of the latter rather the smaller. These curvatures, however, vary in different individuals and in the same individual at different periods of life.]

are refracted or dispersed in passing from these denser media into the air.

The posterior crystalline capsule presents a *concave* surface,—the image reflected from it is inverted, diminished, appears before it, and moves in a direction opposite to that of the candle when the latter is carried laterally in front of the eye. This image is the smallest of the three, being reflected from the surface of smallest curvature, its radius of curvature being about $\frac{3}{40}$ths of an inch; whilst that of the other surfaces is $\frac{13}{40}$ths as already stated. This image is very bright and distinct, and appears anterior to that formed by the anterior crystalline capsule, but posterior to the corneal image. The position of these images being so regulated by the curvatures and relative position of the reflecting surfaces.

The images will be seen most distinctly when the pupil is well dilated,* the room darkened, and the observer seated in front of the patient so that he may look down into the eye rather than up. A candle should be used which burns steadily and does not blaze much.

When the curvatures of the reflecting surfaces becomes altered, or the transparency of these or the intervening humours are diminished, corresponding changes take place in these images or they become obliterated, and thus furnish most valuable diagnostic signs as will be more particularly pointed out in the chapters on these affections. To appreciate the changes referred to, it is essential that the observer should be perfectly familiar with the natural appearances of the images, and for this purpose he must carefully study them as seen in the healthy eye.†]

ANATOMY OF THE APPENDAGES OF THE EYE.

The appendages of the eye consist of the parts which move it, the *muscles* of the globe; of those which cover externally and protect it, the *eye-brows*, the *eye-lids*, and their muscles; of the mucous membrane which connects the globe to the eye-lids, the *conjunctiva;* of the organs, which secrete, distribute, and convey away from the surface of the eye such fluids as lubricate it, the *lachrymal organs*, or apparatus. They are sometimes divided into the *orbital* and *facial* appendages, the eye-lids and eye-brows forming part of what is called the face, and the muscles and other parts being contained in the cavity of the orbit.

Muscles. [Pl. V. fig. 24.]—The globe of the eye is moved by six muscles, four of which, namely, the recti or straight muscles, are nearly alike, and very simple in their origin and arrangement. They arise from the margin of the foramen opticum [1. fig. 24.] at the bottom of the orbit, pursue a straight course, and are inserted by broad but thin and flat tendons into the sclerotic coat; they closely embrace the optic nerve at their origin, surround it more loosely in their progress, and include the globe between their tendinous expansions, being situated respectively above, below, on the outside and inside of the nerve and globe. These four muscles move the globe in the four directions of their course, or in the intermediate direction, when the actions of two are combined.

There are two oblique muscles, the superior and inferior. These are situated obliquely with respect to the globe, and give it a rotary motion downwards and outwards, (obliquus superior,) or upwards and inwards,

* This may be effected by the application of belladonna, stramonium, &c.

† See American Journ. Med. Sc. Aug. 1838. p. 494. May, 1839. p. 255, &c.

(obliquus inferior,) acting together, they turn the eye-ball towards the nose.

The use of the recti muscles is obvious: they are voluntary agents connected with the office of the retina. They can move the globe, in obedience to the will, so as to direct the visual axes successively to the various parts of any object which we are desirous of surveying. They can carry the globe into every situation, in which the surrounding bony prominences admit of vision being exercised. When a greater extent of motion is required, we direct the optical axes to the object, by turning the whole head.

The effect of the obliqui is by no means so apparent. They have been called *circumagentes* or *amatorii*, having been probably regarded as muscles of expression, and supposed to be subservient to the motions which take place in ogling. We find them, however, in the eyes of animals, which certainly do not make love in that way.

The physiology of these muscles has been greatly elucidated by Sir Charles Bell,* who has noticed and explained certain movements of the eye, which had hitherto nearly escaped attention. These are involuntary motions by which the globe is rolled upwards, for the purpose of clearing the cornea, or protecting and defending the eye, in ordinary winking, in the closure of the lids when any thing approaches capable of injuring the eye, and in sleep. "There is a motion of the eye-ball," says Sir Charles, "which from its rapidity has escaped observation. At the instant in which the eye-lids are closed, the eye-ball makes a movement which raises the cornea under the upper eye-lid. If we fix one eye upon an object, and close the other with the finger in such a manner as to feel the convexity of the cornea through the eye-lid, when we shut the eye that is open, we shall feel that the cornea, of the other eye is instantly elevated, and that it thus rises and falls in sympathy with the eye that is closed and opened. This change of the position of the eye-ball takes place during the most rapid winking motions of the eye-lids." Sir Charles observes that this movement takes place even when the eye-lids cannot be closed in consequence of contraction from burns or paralysis of the orbicularis. In the latter cases I have repeatedly observed the fact, and pointed it out to others, although I had not reflected, as Sir Charles has done, on the nature and mechanism of the phenomenon. The use of this movement in sweeping and clearing the surface of the cornea is obvious. "By the double motion, the descent of the eye-lid and the ascent of the cornea at the same time, the rapidity with which the eye escapes from injury is increased." The globe is rolled upwards in the same way during sleep, and on the approach of death. The fact had been observed in the former case, and even delineated by Soemmerring in his first plate; but he erroneously ascribes the movement to the rectus superior, which being a voluntary muscle, cannot be in action during sleep. Moreover, when the rectus superior turns the globe upwards, as in contemplating an object placed higher than the head, its action is united with that of the levator palpebræ; while, in the case under consideration, the rolling upwards of the globe is associated with descent of the upper lid. Sir Charles observes further, that this involuntary action of the obliqui is seen in oppression of the brain, in faintness, in debility after fever, in hydrocephalus, and on the approach of death, when the action of the voluntary powers is either greatly enfeebled, or altogether suspended.

[The muscles of the eye and their appendages have lately acquired such

* *On Motions of the Eye; Phil. Trans.* 1823; and in *the Nervous System of the Human Body*, p. 177.

surgical importance, that some further particulars relative to their anatomical relations, seem demanded.

The internal is the shortest and thickest of the recti muscles, whilst its antagonist, the external, is the longest and next to the former in thickness.

The following are the measurements of the tendons of the recti muscles, as given by Dr. Mackenzie,* but they must be regarded as only approximations.

Length of the tendinous portion of inner rectus three lines; of the other recti one line and a-half.

Breadth of the tendons of the internal and external recti at their insertions about four lines; of the superior and inferior recti about three lines and a-half.

Each tendon has a crescent shaped insertion, the convexity being towards the cornea, so that the centre of insertion is nearer the cornea than the edges. This arrangement has doubtless mislead some careless operators into the belief that they have divided the whole of the tendon of the muscle they were operating on, when in fact they had only divided the central part, leaving both edges still attached.

The internal rectus is inserted nearer to the cornea than the external rectus. The distance between the centre of the tendon and the cornea, being in the former about two lines, and in the latter about three lines.

The superior and inferior recti appear to be inserted at equal distances from the cornea, which according to Mr. Lucas is four lines; whilst Dr. Mackenzie represents the latter muscle as inserted nearer the cornea than the former, the respective distances between the centre of their tendons and the cornea being according to him two lines and a-half and three lines and a-half.

It has not yet been satisfactorily determined whether or not the opponent recti muscles are inserted symetrically; though it has seemed to us that such is the case. Dr. Mackenzie states that the internal and external recti are inserted in the same horizontal line, but that the superior and inferior recti are not inserted in the same vertical line, the latter being inserted considerably nearer the nose than the middle line of the eye-ball. To this arrangement he attributes the tendency, so frequent in convergent strabismus of the eye to turn upwards and inwards.†

According to Mr. Lucas the internal rectus is inserted obliquely to the edge of the cornea, its inferior edge being a line more distant from this part than its superior; whilst the other recti muscles are inserted concentrically to the edge of the cornea. Mr. Mackenzie on the contrary states that the internal rectus is inserted concentrically to the edge of the cornea, as well as the external; but that the inferior rectus is not inserted concentrically, and that the superior is inserted still more obliquely in respect to the edge of the cornea. It will require a very careful examination of a great number of cases to determine with precision the general rule as respects the insertion of these muscles; and to avoid being led into error by exceptional cases.

The centre of the tendon of the superior oblique is eleven lines distant from the cornea, and that of the inferior oblique fifteen lines from the same point.‡

The eye-ball is invested with a membranous tunic which separates it

* On the cure of Strabismus by Surgical Operation. London. 1841. p. 12.
† Loc. cit.
‡ Lucas. Practical Treatise on the cure of Strabismus. London. 1840.

from the other structures in the orbit, and forms a smooth hollow surface by which the motions of the eye are facilitated. This investment was described by Tenon in a paper read before the French Institute in 1804,* who styles it *a new tunic* of the eye. It has since been described by Mr. Dalrymple† as the cellular capsule of the eye, by Mr. Bonnet‡ of Lyons, by Mr. Ferral§ of Dublin who proposes for it the name of *tunica vaginalis oculi*, and by Mr. Lucas‖ who terms it the *submuscular fascia*, each of whom seems to consider himself as the discoverer of this structure.

Mr. Lucas¶ recommends the following method of demonstrating this fascia.

"The eye and its appendages, with half an inch of the optic nerve, should be removed from the orbit and placed upon a plate, the cornea being downwards. The masses of fat, together with the loose cellular tissue and blood-vessels, should be carefully dissected away, and the muscles be turned forwards towards their insertions, not dissected as if with a view of exposing their appearance, but merely expanded upon the surface of the plate.

"If the neurilema of the optic nerve be now examined, it will be found covered with a fine fascia, which can be easily raised with a forceps, and with little difficulty can be traced off the neurilema to the sclerotic coat at the point where the nerve enters. It will be now found to cover the posterior aspect of the sclerotica, and to advance as far as the insertions of all the muscles of the eye; at these points it turns upon itself, lines the ocular surfaces of the muscles, and passes backwards along them to where they surround the optic nerve."

This fascia, passes from one muscle to the other, and forms a strong, continuous, double circular membrane behind them; the masses of fat, enveloped with their own proper cells, being placed between its layers.

It offers considerable resistance to the passage of an instrument between the tendons of the muscles, and in operating upon them requires to be fairly divided.

This fascia "possesses a high degree of elasticity, and forms rather a membranous sheath for the sclerotica, that an expansion for the muscles; it takes the form of the eye-ball, and acts the part of a membranous cup for the organ to move in, separating it from the bellies of the recti muscles, and covering the ciliary nerves as they pass onwards to pierce the sclerotica. In the dead eye, more or less fluid will be found to exist between this cuplike membrane and the eye-ball, which always enables the anatomist to separate one from the other with the greatest facility. That effusion to a considerable extent sometimes takes place between this membrane and the eye-ball, there can be little doubt."**

This effusion is apt to accompany rheumatic inflammation of this tunic, and to Mr. Ferral we are indebted for first inviting the attention of practitioners to the existence of that pathological condition as well as for a very interesting account of its phenomena and mode of treatment.

* Mémoires et Observations sur l' Anatomie, la Pathologie et la Chirurgie, et principalement sur l' Organe de l' Oeil, p. 193. Paris, 1816.

† Anatomy of the Human Eye. London, 1834.

‡ Sur l'anatomie des aponéuroses et des muscles de l' œil, letter addressed to the Academy of Sciences and read at their meeting the 1st Feb. 1841. *Gazette Méd. de Paris*, 13 Feb. 1841.

§ Dublin Journal, Med. Sc. July, 1841. ‖ American Journ. Med. Sc. Oct. 1841.

¶ Op. cit. ** Lucas, *loc. cit.*

Mr. Lucas describes as a second fascia, which he names the *subconjunctival** but which Dr. Mackenzie conceives to be a continuation of the ocular capsule, a dense layer of cellular tissue which covers the external surface of the recti muscles. "Behind the conjunctiva," he observes, "there exists a quantity of loose cellular tissue; upon carefully removing which, a denser layer will be found immediately to cover the orbital aspects of the recti muscles, and to pass along their expanded tendons to the sclerotica, with the anterior surface of which it is in intimate contact, and is traceable along it to the circumference of the cornea, becoming thinner and more identified with the sclerotica as it gains this point.

"This subconjunctival fascia, although exceedingly delicate, is sufficiently strong to offer considerable resistance to even a slightly blunted instrument; and as, in addition to its passing from all the recti muscles to the sclerotica, it also passes from the anterior surface of one muscle to another, it is of importance to be aware of its existence in performing an operation for the section of the tendons of the recti muscles. Unless the subconjunctival fascia be torn through or divided, the passage of an instrument beneath any of the tendons will be attended with difficulty."†

This like the submuscular fascia it is less strongly developed in children than in adults. It is sometimes rendered very dense and becomes adherent to the conjunctiva and muscles, from inflammation; and when this condition of the fascia accompanies strabismus, it is sufficient to maintain the deformity after the muscle has been divided, and in such cases it is necessary to freely separate the morbid adhesions.]

Nerves.—The orbit contains several nerves, of which the optic, or nerve of the second pair, is the most considerable. [1. figs. 5 and 6., 3. fig. 15. and fig. 28.]. Its magnitude sufficiently points out the importance of the sense to which it is subservient. In size it is the second of those connected with the basis of the brain, being inferior only to the nerve of the fifth pair. The optic nerves have this singularity, that they converge within the cavity of the skull, all the others diverging to their respective destinations; they meet together, and their respective substances are united into one mass [2. fig. 28.] on the anterior surface of the sphenoid bone. The course, which the various component fibres of the two nerves take in the *chiasma* or junction, as well as before and after it, has been already described; see page 89. This kind of arrangement is found in no other instance. The intermixture of their substance may account for unity of vision, for the intimate sympathy between the two eyes, and for various morbid phenomena. The nerves, having united, separate again, passing each through its respective foramen opticum into the orbit, and terminating in the posterior part of the eye-ball. In the progress from the foramen opticum to the globe, another peculiarity is observed; the nerve is closely invested by a sheath of dura mater, a prolongation of the fibrous membrane which lines the skull.

The function of the optic nerve is entirely confined to the sense of vision. It is even destitute in its healthy state of ordinary sensibility. M. Magendie‡ pushed the opaque lens against the retina in the operation of depression, and not only touched, but punctured it with the cataract needle repeatedly, without causing pain or any sensation to the patient. These

* Dr. Gross in a paper on Strabismus (*Western J. Med. & Surg.*, Ap. 1842) states that this fascia is identical with that described by him in his pathological anatomy published in 1839, with the appellation of the *ocular fascia.*

† *Loc. cit.*

‡ *Sur l' Insensibilité de la Rétine de l'homme; Journal de Physiologie*, t. v. p. 37.

injuries were not followed by any inflammation, or impaired vision. The optic nerve is equally insensible to the mechanical injuries of pricking, cutting, or laceration.

The cavity of the orbit contains further the nerve of the third pair, [3. fig. 29.], which is employed in supplying three of the recti muscles, one of the obliqui, and the levator palpebræ superioris, besides forming the principal origin of the lenticular or ophthalmic ganglion , from which the nerves of the iris proceed: the nerve of the fourth pair, [4. fig. 29.], supplying the trochlearis muscle; the ophthalmic branch of the fifth, which contributes a small branch to the lenticular ganglion, sends off a few small twigs in the orbit, and then leaves the cavity at the supra orbital foramen; and the nerve of the sixth pair, [6. fig. 29.], for the external straight muscle. We cannot hesitate in concluding with Sir Charles Bell,* that the ophthalmic branch of the fifth gives common sensibility to the surface of the eye and the lids, and that the destructive inflammation of the organ, which ensues, when the fifth nerve is destroyed by injury or disease,† arises from the loss of this sensibility. The third and sixth nerves are obviously voluntary; Sir Charles regards the fourth as an involuntary nerve, without considering the point clearly proved.

The cavity of the orbit contains the ophthalmic artery, the various ramifications of which supply the globe of the eye, and the parts belonging to it; and the ophthalmic vein, by which the blood is returned from the orbital veins into the cavernous sinus of the dura mater, through the foramen lacerum orbitale. The orbit also contains the lachrymal gland, [3. fig. 25.] which has its nervous supply from the ophthalmic branch of the fifth. Accurate and beautiful delineations of these several parts are found in the works of Soemmerring and Arnold.

The several parts just enumerated are connected together by a copious and particularly soft adipous substance, which in the living subject is almost fluid, and therefore readily accommodates itself to the different motions of the eye, and to the various changes of position which may occur in the globe.

The bony cavity is lined by a fibrous membrane, which is a direct continuation of the dura mater, and technically called *periorbita*, bearing the same relation to the orbit, as the pericranium does to the skull, or the periosteum to other bones. The peculiarity of the arrangement consists in its being continuous with the dura mater at the foramen opticum, like the fibrous sheath that covers the optic nerve.

The *eyebrow* [1. fig. 30.] is the arched prominence which terminates the forehead and overhangs the eye; it consists partly of bone and partly of muscular and other soft parts. The bone is the superciliary ridge of the os frontis, forming the superior arch of the anterior orbital aperture. Immediately on the surface of the bone lies the corrugator supercilii muscle, which is subservient to the motion of the brow. It derives its origin from the nasal process of the os frontis, turns upwards and outwards in the direction of the eye-brow, and is lost among the fibres of the orbicularis palpebrarum and the occipito frontalis; it consists of a considerable fasciculus of muscular fibres. Its action throws the eye-brow and forehead into those longitudinal folds which are exhibited in frowning; it is, in fact, the muscle of frowning; it is more important as an instrument of expres-

* *On the Nerves of the Orbit; Philos. Trans.* 1823, and in the *Nervous System, &c.* p. 203; also Appendix, No. viii. p. 23 and 103.

† Magendie *de l' Influence de la cinquième Paire des Nerfs sur la nutrition et les fonctions de l' œil*, in the *Journal de Physiologie*, t. iv. p. 176, and *Suite des Expériences, &c.* ibid. p. 302.

sion than in reference to the physiology of vision; its indications are rather of a pathognomic than of a physiological kind, and illustrate the state of feeling or passion in the individual. Hence it is peculiar to the human species, though I am not prepared to say that it may not be found in those of the simiæ, or monkey tribe, which approach the nearest to man.

Over the corrugator supercilii there is a stratum of muscular fibres forming part of the orbicularis palpebrarum; there is, further, a portion of adipose substance, covered by integument similar to that of the face in general, with the exception of the skin, having a number of hairs implanted in it. These hairs are peculiar in their form and arrangement; they do not run lengthwise with respect to the brow, but are short, and form a double series, of which the inferior are directed upwards and outwards, the superior downwards and outwards, and the two orders meet and form a kind of ridge in the middle of the brow.

The *palpebræ*, or *eye-lids*, [figs. 30, 31.], are a thin and movable kind of curtain, closing the anterior aperture of the orbit. The boundaries of the eye-lids are, the eye-brow above, the cheek below, the temple on the outside, and the nose on the inside. The palpebræ are the parts included between these boundaries; when they are approximated to each other, they close the bony opening of the orbit, which is seen in the skeleton. As the eye-lids are adapted to the front of the globe, they are concave on the posterior surface, and proportionally convex on the anterior. They are made up of skin, muscular fibres, cartilage, and mucous membrane. They are separated from each other by a horizontal slit or opening, which is closed when they are completely approximated, and enlarged in various degrees as they are moved apart. The separation of the lids from each other is termed in popular language opening the eye: it exposes the previously concealed anterior surface of the organ. The palpebral aperture or slit is said generally to be horizontal; but it is not strictly so, for the outer or temporal part is a little lower than the inner or nasal portion. The palpebræ are more firmly fixed to the bone at the nose than towards the temple.

Muscles of the Eye-lids.—The motions of the lids are performed by two muscles; one situated in the cavity of the orbit, and the other on the face. The former is the levator palpebræ superioris, [3. fig. 26.], arising close to the superior rectus, from the margin of the foramen opticum, running along the upper part of the orbit, and inserted by a broad expanded tendon into the whole breadth of the upper lid. The other muscle is the orbicularis palpebrarum [1, 1. fig. 25, and 1, 1. fig. 26.]; it consists of a broad stratum of fibres, deriving its origin from a small tendon at the side of the nose. This tendon is placed in front of the excavation which lodges the lachrymal sac. The fibres, which are immediately under the skin, and arranged in a circular or elliptic form round the eye-lids, cover the whole surface of these, reaching to the ciliary margin, and extending over the adjoining part of the eye-brow, temple, and cheek.

When the eye is shut, the levator muscle elevates the upper lid, and draws it away from the lower. In opening the eye, the two lids are not equally moved, the inferior remains nearly at rest; it descends a little, but the separation is chiefly accomplished by motion of the superior lid. The two palpebræ contribute unequally to cover the globe of the eye, the superior being by much the largest or deepest; the line of junction between the two lids does not run along the middle of the anterior surface of the eye, but is situated below the inferior margin of the cornea; and the superior lid, in its closed state, covers the whole of the cornea. Soemmerring, in the first plate of his work, gives a front and side view of the lids as closed

in sleep, and represents the line of junction between them as more than one-eighth of an inch below the inferior margin of the cornea. The levator then, by elevating the upper lid, denudes the anterior surface of the globe: but its continued action is necessary in order to keep the eye open; the weight of the upper lid would carry it down, unless there were some cause to counteract this tendency. Accordingly, when the action of this muscle is suspended, the lid drops of itself in front of the eye. When persons are extremely tired, and incapable of continuing voluntary exertion, the lids descend, or, in popular language, the eyes feel heavy. *A fortiori* this effect will be produced, when the muscle is paralyzed; the power of opening the eye is either impaired or lost according as the paralysis of the levator is partial or complete. Such affections are by no means uncommon: indeed I know no single muscle of the body which is so frequently the subject of paralytic affection independently of all others. May not this arise from the constant duty required from it, and consequent exhaustion of its power? The explanation of the phenomenon must be sought for in some cause affecting the muscle, and not the nervous trunk, since the other muscles supplied by the same nerve are very seldom affected.

Sir Charles Bell has shown that the levator palpebræ not only elevates the upper lid, but that, at the same time, it depresses the lower. "Anatomists," he says, "have sought for a depressor of the inferior eye-lid, seeing that it is depressed, but such a muscle has no existence, and is quite unnecessary. The levator palpebræ superioris opens wide the eye-lid, depressing the lower eye-lid at the same time that it elevates the upper one. If we put the finger upon the lower eye-lid so as to feel the eye-ball when the eye is shut, and then open the eye, we shall feel that during this action the eye-ball is pushed outwards. Now the lower eye-lid is so adapted as to slip off the convex surface of the ball in this action, and to be depressed, whilst the upper eye-lid is elevated."*

The orbicularis palpebrarum is the antagonist of the levator; the contraction of its circular fibres, according to its degree, will either diminish the dimensions of the palpebral aperture, or completely approximate the lids. Sir Charles Bell has observed that the two lids do not move in the same direction when the eye is shut. The upper descends and rises perpendicularly, while the lower plays horizontally like a shuttle, being moved towards the nose, when the eye is closed. He considers this a part of the curious provision for collecting offensive particles towards the inner cornea of the eye.† When the levator is relaxed, the gradual descent of the upper lid, by its own weight, will slowly close the eye; and this may be exemplified by elevating the lid when the muscle is paralyzed. Generally, however, this passive kind of closure does not answer the purpose; we want to shut the lids more quickly, and we employ the active exertion of the orbicularis; its sudden and forcible contraction draws the lids together when a foreign body approaches, or when the organ requires shelter from too strong a light. In these cases the muscle can contract with great force, as we find when we attempt to draw the lids apart, in opposition to the will of the individual. Even in a child, laboring under intolerance of light, we can hardly overcome the violent and spasmodic contraction of the orbicularis. The action of this muscle not only closes the eye, but corrugates the whole integuments of the lids, temples, and surrounding parts. The orbicularis in front, and the orbital muscles behind are antagonist powers, between which the globe is retained in a proper position. When the former is paralyzed, not only are the eye-lids and the surrounding integuments

* *The Nervous System of the Human Body*, p. 186. † Ibid. p. 182.

flabby and folded, but the globe protrudes unnaturally, as if it were pushed forwards by a force acting from behind.

[There is a small muscle [fig. 32.] on the orbital face of the lachrymal sac described by Prof. HORNER of the University of Pennsylvania in 1824, (*Phila. Journ. Med. and Phys. Sc.*) which he has named the *Tensor Tarsi*, and of which it is proper that some account should be here given. The following is the Professor's description of it.

"It arises from the posterior superior part of the os unguis, just in advance of the vertical suture between the os planum and the os unguis. Having advanced three lines, it bifurcates; one bifurcation is inserted along the upper lachrymal duct and terminates at its punctum, or near it; and the lower bifurcation has the same relation to the lower lachrymal duct. The base of the caruncula lachrymalis is placed in the angle of the bifurcation. The superior and the inferior margins of the muscle touch the corresponding fibres of the orbicularis palpebrarum, where the latter is connected with the margin of the internal canthus of the orbit, but may be readily distinguished by their horizontal course. The nasal face of this muscle adheres very closely to that portion of the sac which it covers, and also to the lachrymal ducts. The lachrymal sac rises about a line above its superior margin and extends in the orbit four lines below its inferior margin. The orbital face of the muscle is covered by a lamina of cellular membrane, and between this lamina and the ball of the eye are placed the valvula semilunaris and a considerable quantity of adipose matter.

"As the bifurcated extremities of the muscle follow the course of the lachrymal ducts, they are covered by the tunica conjunctiva. When this muscle is examined from behind, the eye-lids being in situ, it becomes obvious that it is concave on its orbital surface, and, consequently, convex on the nasal; that the muscle is an oblong body, half an inch in length, and about three lines wide, bifurcated at one end: and that it arises much deeper from the orbit than any acknowledged origin of the orbicularis. The superior fork, however, has a few of its fibres blended with the orbicularis.

"In regard to the use of this muscle: its attachment to the posterior face of the sac is such, that it draws the orbital part of the sac away from the nasal, and dilates the sac, from the nasal face of the latter being fixed to the bones. As this muscle is cylindrically concave on its orbital side, it is evident that when it contracts the fibres become straight, or nearly so, like the fibres of the diaphragm, and the cavity of the sac is enlarged after the same manner as the cavity of the thorax. A tendency to a vacuum being thus produced by it, the valves or folds of the internal membrane resist so that the vacuum is filled more readily from the puncta than from the nose; and the puncta being continually bathed in the tears of the lacus lachrymalis, both in the waking and in the sleeping state, the tears are constantly propelled through them by atmospheric pressure. The evacuation of the sac is no doubt accomplished by its own elasticity and by the contraction of the orbicularis; probably in a chief degree by the latter, because in persons who have epiphora or a tendency to obstruction in the nasal duct, the accumulation of tears and matter principally takes place at night, when the action of the orbicularis is suspended by sleep. For these reasons we should argue that this little muscle is active at all times both night and day. To Dr. Physic I am indebted for suggesting another use for it; to wit, that of keeping the lids in contact with the ball of the eye.

"Some persons possess unusual voluntary power over this muscle, of

which I have seen several examples. In each instance the individual could shorten so much the internal angle of the eye-lids, as to conceal it along with the puncta, in the internal canthus of the orbit."]

Component tissues of the eye-lids.—The lids are formed of several different textures, which I shall enumerate in their order. The external surface is skin, peculiarly thin and delicate, so that, in fair persons, we not only see through it the ramifications of the subcutaneous vessels, but can even trace their minute divisions. In young persons, this portion of integument is perfectly smooth, but, as age advances, it loses its elasticity, and falls into wrinkles. When the upper lid is elevated, a deep fold is observable between the lid and the eye-brow; there is no corresponding fold in the lower lid. Immediately under the skin is the stratum of fibres composing the orbicularis palpebrarum. Next, in the upper lid, is the expanded tendon of the levator palpebræ superioris; there is no corresponding part in the lower lid.

The tarsi.—We then come to the part which gives firmness to the lid, extending and supporting the softer textures; it is a thin and flexible, yet firm and elastic cartilage, or rather fibro-cartilage, on which the skin, muscular fibres, and mucous membrane, may be said to be stretched. It can bend, and change its figure, recovering itself again by its elasticity. These cartilages are called *tarsi*, the *superior* and *inferior*. They are convex on the external surface, and concave on the inside; they have a thick margin corresponding to the ciliary edges of the lids, and a thinner turned towards the rim of the orbit. If we evert the upper or lower lid, these fibro-cartilages are easily brought into view. The superior is deeper than the inferior, in correspondence to the difference between the lids; the proportions, in this respect, are about as three to one. The inferior tarsus, like its eye-lid, is nearly of equal breadth throughout; the superior also corresponds in form to its lid, being broadest in the middle, and narrower towards the two extremities. The orbital edges of the tarsi are connected by fibrous expansions to the front of the orbit. These, which are sometimes called the broad ligaments of the tarsi, are firm, distinct fibrous layers near the bone, with the periosteum of which they are continuous, becoming looser and thinner towards the cartilage. The ligament is strongest and most firmly attached to the tarsi on the temporal side of the orbits, where protection is most needed.

Sebaceous glands.—A large number of glands disposed in parallel longitudinal clusters, called the *Meibomian glands*, [7. 8. fig. 26.] is imbedded in the tarsus. The rows or clusters of glands, although principally lodged in the substance of the cartilage, are partially seen on the internal surfaces of the palpebræ, through the thin mucous membrane, and are even conspicuous by their whitish color. When examined by a magnifying glass, each row is found to consist of a central tube with a congeries of minute roundish bodies arranged round it on all sides in successive groups; these, which have been called acini or vesiculæ, are, no doubt, so many glands, each of which pours out its secretion into the excretory tube, running along the centre of the cluster, and terminating by an open orifice on the ciliary margin of the lid. These openings, which, although minute, are distinctly visible in the living eye, corresponding in number to that of the glandular rows, are called the ciliary ducts. If a single duct with its glands be dissected out separately, it represents a slender thread with the minute acini hanging to it all round, something like a rope of onions, except that these little glands are much more numerous, from fifty to more than a hundred connected with each duct. There are two figures in the work of Soemmerring, in which these minute structures are represented,

of the natural size, and magnified with great accuracy and fidelity. ARNOLD has given different and more varied views of the same subject; especially one representing a row of glands dissected out, and another exhibiting the mode in which they are imbedded in the tarsal cartilage.*

The whole number of the Meibomian glands is very considerable. There are between thirty and forty rows in the upper lid, but not quite so many in the lower: these clusters too are much shorter in the latter than in the former, in consequence of the different size of the two lids. The unctuous or sebaceous substance which they secrete anoints the lids, and prevents them from sticking together: after death it congeals into a solid form, and may be expressed from the orifices of the ciliary ducts, like minute white threads.

Next to this arrangement of glands is the mucous membrane or production of conjunctiva, which gives a smooth and polished surface to the interior of the lid, and facilitates the relative motions of the eye and lids.

The eye-lids, although made up of so many distinct structures, are by no means impervious to light. One obvious use of them is to guard the eye from the access of light during sleep; however, so much light passes through them, that we can readily distinguish, in the day-time, whether the light of a window fall on the face or be intercepted, although the lids may be closed; and persons, who usually sleep with their window and bed-curtains drawn, adopt the expedient of leaving them open when they wish to rise early, generally finding the unusual impulse of light on the organs of vision sufficient to awaken them.

Cellular substance of the lids.—The several textures, or strata composing the lid, are connected together by a rather abundant cellular tissue, which contains no fat; the eyes would, in many instances, be permanently closed if the lids were liable, like other parts of the body, to deposition of adipose substance. On the other hand, the cellular texture of the lids is often the seat of inflammation, in erysipelas and other affections: serous effusion takes place, enlarging and distending them so as completely to close the eyes, with great inconvenience and deformity. A similar effect is produced by ecchymosis from blows. Inflammation, when more violent, causes effusion of lymph or formation of pus, with the same effect of closing the lids.

Ciliary margins of the eye-lids.—Surgeons should attend closely to the ciliary margins of the lids, and make themselves well acquainted with their form, structure, and appearances. Here the common integument and the mucous membrane of the eye are continuous. The very edge of the lid is formed by a kind of covering intermediate between the two structures: it is not exactly a mucous membrane, like that which lines the palpebræ, nor integument like the common skin: it is red, thin, yet compact and dense, and adheres closely to the cartilage: this delicate integument has a covering of epithelium. The ciliary margin is the thickest part of the lid: it is a flat surface coming into contact with that of the other lid when the eye is closed; yet the inner edge, or that turned towards the globe, is a little sloped, so that a small channel is formed, in the closed state, between the palpebræ and the globe, for the passage of the tears.

Cilia.—[2. fig. 30.] At the outer edge of the ciliary margin are a number of pores in the integument, in which the cilia or eye-lashes are implanted. The hairs which form the cilia, like those of the supercilia, are peculiar in their form and arrangement; each hair arises from a bulb, like the hairs in

* *Tab. Anat.* fasc. 2, tab. 1, fig. 9—12. This plate exhibits the entire anatomy of the eye-lids and lachrymal organs in a series of beautiful figures.

other parts of the body; it is slender at the origin, increases gradually in thickness, and then tapers off to a fine point; they are all curved, the convexity of the superior cilia being directed downwards, and that of the inferior upwards, so that they cross when the lids are closed. The superior are stronger and longer than the inferior; the middle are the largest and strongest, and they diminish gradually in length and strength towards the angles of the eye.

Just behind the eye-lashes are seen the apertures of the ciliary ducts. Where the series of these openings ends towards the nose, and at the very inner or nasal extremity of the tarsus, there is a slightly prominent kind of papilla, of whitish color, with a round aperture in the centre, called the punctum lacrymale.

The lids, though separated by a transverse slit, are united towards the temple and the nose, and the points of junction are termed the *angles*, or *canthi*, of the eye; the internal and external, or the greater and smaller. The internal, or greater angle, is rather rounded; the external, or smaller, is acute. By the tendon of the orbicularis, the internal angle is closely fixed to the side of the nose; the external is more loosely attached to the orbit by the broad ligament of the tarsi.

The size of the palpebral aperture is different in different individuals; in some persons a greater portion of the globe is habitually exposed than in others, and hence persons are popularly said to have large or small eyes, for the size of the globe varies but little. The organization of the eye-lids, as now described, enables them to execute their various useful purposes, of protecting the eye from violence and accident, of shielding it during sleep, of shutting out the light when it is too powerful, or when disease renders it offensive; of keeping the cornea smooth, moist, and free from impurities, and of disseminating the lachrymal fluids over the organ. The cartilage gives to the lid its uniform smooth surface; the Meibomian secretion anoints their edges, and prevents them from adhering during sleep, or occasional contact; their rapid motion in winking, with the concurrent rolling upwards of the globe, and approximation of the eye-lashes, shuts out extraneous substances, and preserves the cornea constantly clear for the transmission of light, whilst the polished mucous surface glides without the smallest friction over the equally polished globe.

*Conjunctiva.**—The name denotes that it joins or unites the globe to the lids; it is sometimes called *adnata*, from its growing or adhering to the surface of the eye. Indeed, it adheres so closely to the front of the organ, that it ought, strictly speaking, to be enumerated among the tunics belonging to the globe. The line of the cilia, in each lid, may be considered the boundary between the skin and the mucous membrane, the point of union of the two structures. The conjunctiva, then, is perforated at the ciliary margin of the upper lid, by the ciliary ducts; it lines the posterior or inner surface of that lid, extending a little way above the upper or orbital edge of the tarsus; from the lid it turns over the globe, covering two-thirds of the eye, viz. the anterior portion of the sclerotica, and the cornea; it is reflected from the inferior portion of the globe to the posterior surface of the under lid, which it lines: reaching the ciliary margin of the lower lid, it is perforated by the ciliary ducts, and again becomes continuous with the skin.

Thus the membrane is reflected from the palpebræ to the whole circumference of the globe, forming a circular fold, which, at the point of reflexion, corresponds to the fat of the orbit. This angle of reflexion is the

* Eble, *über den Bau und die Krankheiten der Bindehaut des Auges*, with colored plates. Vienna, 1828, 8vo. Arnold, *Untersuchungen*, Kap. I, § 2. Roemer, *Bemerkungen über die arteriellen Gefässe der Bindehaut des Auges*, in Ammon's *Zeitschrift*, vol. v.

boundary between the external surface and the orbital contents; it opposes the passage of an instrument, or any extraneous substance. It is a loose fold, and loosely connected to the surrounding parts, yielding to the motions of the globe with perfect facility, drawn smoothly over the convexity of the sclerotic, when the eye is moved in a contrary direction, and forming two or three loose folds on the opposite side, or that towards which the eye is turned.

The conjunctiva is not only connected with, but constitutes part of the external surface of the body; it is actually exposed to the air when the palpebræ are open, though it is completely shut up when they are closed. It is a mucous membrane, having a polished surface lubricated by a mucous exhalation, and a cellular surface adhering to the parts which it covers. It is one uninterrupted membrane, differing, however, in structure and appearance in its different parts. Hence anatomists have designated that portion which lines the lids as the *conjunctiva palpebralis;* that which covers the eye as the *c. oculi:* the latter part has been further subdivided into the *c. corneæ*, and *c. scleroticæ.* All these, however, agree in the circumstance of having a smooth and polished surface.

The *c. palpebralis* [5. fig. 25. and 5. fig. 26.] is a thin vascular membrane, of reddish color from numerous visible vascular ramifications, and semi-transparent, so that you may see through it the cartilage, and the parallel rows of Meibomian glands; it is consolidated to the ciliary margin of the tarsus, and it adheres closely, but less firmly, to the rest of the cartilage. SOEMMERRING, who has represented the palpebral conjunctiva in the 15th fig. of his second plate, mentions in the description its *silky and as it were warty* structure. MUELLER* says that a great number of mucous glands is scattered over the surface, and that they give to it a somewhat velvety appearance. EBLE† considers that this part of the membrane has a papillary structure, analogous to that of the tongue or the Schneiderian membrane; that this structure is more obvious after death with congestion in the vessels of the head; and that it secretes the mucous which lubricates the surface of the eye. He has given excellent figures of this corpus papillare, as he calls it, both of the natural size and under various degrees of microscopic enlargement. The same parts, and particularly the villous or papillary portion of the conjunctiva, both in its natural appearance and magnified, are beautifully delineated by ARNOLD.‡

The *c. scleroticæ* is of a white color, thick and pulpy in its texture, and, in conjunction with the dead white sclerotica, gives to this part of the eye that appearance which is designated by the popular expression, white of the eye. It is remarkable for the almost entire absence of vessels carrying red blood; in its natural state we see merely a few small red vessels creeping on its circumference from the lid. It is connected to the parts on which it lies by a loose cellular texture; thus it easily falls into folds, and permits the globe of the eye to be moved in all directions. These folds become the seat of serous effusion in certain inflammatory affections of the eye.

The *c. corneæ* differs remarkably from both portions of the membrane just described, so much so, that one doubts, at first, whether it really is a part of the same structure.§ No vascular ramifications are visible in it,

* *Erfahrungs-sätze*, pp. 5 and 6.

† *Ueber den Bau und die Krankheiten der Bindehaut des Auges*, p. 19—29. pl. 1 and 2.

‡ Tab. 1, fig. 13—18.

§ The continuation of the conjunctiva over the cornea is doubted by EBLE, (lib. cit. p. 60;) and denied by MECKEL, (*Handbuch*, b. iv. p. 59.)

In a work recently published on purulent ophthalmia (*die sogennante contagiöse, oder Aegyptische Augenentzündung*, mit 9 colorirten Abbildungen, Stuttgart, 1839) EBLE has given at considerable length the result of his recent inquiries, especially with the aid of

and it is so closely connected to the corneal substance, that it cannot be separated by dissection in the recent eye; we are satisfied, however, that the cornea is covered by a continuation of conjunctiva. In the first place, the anterior surface of the cornea possesses the same acute sensibility as the rest of the conjunctiva. In fact, the sensibility is greater in this than in any other part of the eye, while the proper corneal laminæ appear insensible. Secondly, the vessels of the conjunctiva are continued to the anterior surface of the cornea: this fact, which is difficultly demonstrable in the normal state of the eye, is proved daily by the effects of disease. Changes produced by disease are often continued from the conjunctiva scleroticæ to the cornea. The prolongation of red vessels, the loosening and thickening of texture, and the loss of transparency from interstitial deposition, bring the cornea to such an identity of character with the conjunctiva, that the boundary between them is sometimes hardly distinguishable.

In certain animals a strong proof is afforded that the front of the cornea is formed by a continuation of the palpebral lining. In the serpent tribe, which annually shed their epidermis, the front of the cornea comes off with the rest of the external surface of the body. In the eel the anterior surface of the cornea is often drawn off, when it is skinned. A subterraneous animal (zemni, slepez, mus typhlus, Linn.) whose habits and manner of living are analogous to those of the mole, has the eye covered with hairy integument like the common skin of the body.

The conjunctival layer cannot be dissected off the cornea in the perfectly fresh eye; but, if the organ be previously placed for some time in warm water, or macerated in water for some days, and the conjunctiva be then raised from the sclerotica, the dissection being carefully pursued by small and repeated strokes of the knife, it may be detached sufficiently from the corneal substance to show the continuity of the membrane. Arnold represents that the separation is effected more easily in the sheep, pig, and calf, than in the human subject.

In the normal state of the membrane, the conjunctiva palpebralis has a reddish color, while the conjunctiva oculi is of pearly whiteness with a few slender stragling red vessels towards the angles of the lids. After successful injection, the palpebral linings are deep red and villous, while the conjunctiva scleroticæ has a rose tint: the latter terminates at the border of the cornea, but under favorable circumstances vessels are seen to pass on to that membrane.

I have called the conjunctiva a mucous membrane; and this view of its nature is supported by its analogies of structure and office in the normal state, by the changes which it undergoes in disease, and particularly by the remarkable alterations, which its secreted fluid then undergoes. Some have been inclined to place the conjunctiva, especially where it covers the cornea, among the epidermoid structures, in favor of which its separation with the cuticle in animals which cast their skins may be alleged. Arnold states that the corneal layer of the membrane is most abundantly supplied with lymphatics, while the epidermis possesses no vessels of any kind. Eble considers that the nature of the conjunctiva differs in its different portions; that it is *integumental*, where it lines the tarsi; *mucous* in the angle of reflection from the lids to the globe; and *serous* in the latter. There are remarkable differences of structure between these three parts: the palpebral

the microscope, into the structure of the conjunctiva, p. 124—132. He expresses himself perfectly convinced that the cornea has a conjunctival covering, particularly from finding that its surface presents, under the microscope, appearances analogous to those observed in other parts of the membrane, p. 124.

lining is distinguished by its corpus papillare. Roemer states that the mucous portion is abundantly supplied with mucous glands, which are easily seen after minute injections. In the conjunctiva oculi there is no appearance of villi, papillæ, or mucous glands. The opinion of Eble on this point is adopted by Arnold and Roemer.

Lachrymal organs.—Under particular circumstances the surface of the eye is washed by a more copious secretion, of different character from the mucous conjunctival exhalation, which, not being conveyed away fast enough by the ordinary excretory apparatus, is poured over the lid, taking the name of tears. This fluid is secreted by the *lachrymal gland*, [3. fig. 25.] which is a small body of conglomerate texture, seated in the orbit, within the external angular process of the frontal bone. Its excretory ducts open on the surface of the conjunctiva, above the external angle of the eye; there are about seven ducts, which are scarcely to be seen in the human eye, except under favorable circumstances. In the eye of the horse or bullock they are of sufficient magnitude to admit a small probe. The secretion of the lachrymal gland is a watery fluid, containing a considerable saline impregnation, hence saltish or brackish to the taste, and, when copiously poured out, it produces a temporary irritation and redness. Its discharge is excited by the direct irritation of foreign bodies, particularly those of acrid properties; by various inflammatory affections, especially by strumous ophthalmia, by recent conjunctival inflammation, but more strongly by inflammation of the external proper tunics, and by mental emotion. The fluid which moistens the eye, whether conjunctival or lachrymal, is absorbed by the excretory apparatus, and conveyed into the nose. The *puncta lachrymalia* [1. fig. 27.] already described are the external commencements of two small tubes, which go towards the internal angle of the eye, and there terminate in the lachrymal sac. These tubes are called the *lachrymal canals*, or *ducts;* [3. fig. 27.] they converge, the superior passing inwards and downwards, and the inferior inwards and upwards; they are about a quarter of an inch in length, and open at one and the same point into the *lachrymal sac.* [4. 5. fig. 27.] This *bag*, about the size of a small horsebean, and oval, is seated in the bony excavation on the inner side of the anterior orbital aperture. Its superior end [5. fig. 27.] is rounded; the inferior, slightly contracted, forms a tube half an inch long, and larger than a crow quill, called the nasal duct, [6. fig. 27.] which descends into the nose. The lachrymal bag closely adheres to the bony excavation which lodges it, being covered, on its anterior or exposed surface, by a firm fibrous layer attached to the edges of the bony groove. This anterior surface is further covered by the fibres of the orbicularis and the skin; the tendon of the former crosses it transversely a little above its middle, so that one-third of the bag is above, and two-thirds below the line of the tendon. The lachrymal canals open just behind this tendon, on the outer or ocular side of the bag. The communication with the nasal duct is the inferior extremity of the sac, a slight constriction marking the distinction between the bag and duct. The latter passes from above obliquely downwards, and a little backwards, enclosed in a bony canal, and opens in the inferior meatus narium, on the outer side of the inferior turbinate bone, which must be cut away in the dead body to expose the aperture; the latter is then seen as an oblique slit.

The lachrymal sac and the nasal duct are lined by a thick pulpy mucous membrane, resembling in its structure the Schneiderian membrane of the nose, and containing, like that, numerous small mucous cryptæ. The lachrymal canals, and the puncta lacrymalia, are lined by a thinner and more compact membrane continuous with the conjunctiva. Thus these lacrymal

passages establish a connexion, by continuity of surface, between the eye and nose. The fluid taken up by the puncta lacrymalia is conveyed into the sac, and it then descends into the nose. We do not exactly understand the mode in which the circular orifices of the lachrymal canals suck up the fluid. A small space is seen in the inner angle of the eye, between the two lids, towards which the tears flow, and at which the small triangular canal formed between the closed lids terminates; this is called *lacus lacrymarum*, and the prominent papillæ, in which the puncta lacrymalia are perforated, are turned towards this space. When the secretion of tears is much increased by any of the exciting causes which I have mentioned, the fluid is poured out faster than it can be absorbed by the puncta, and it flows over the surface of the cheeks.

In the internal angle of the eye, near the puncta lacrymalia, is a small prominent body of a reddish color, called the caruncula lachrymalis this part may be better appreciated by looking at it in the living eye, than by examining it in the collapsed and shrivelled state which it exhibits in the dead subject, and in preparations. It is a congeries of glandular bodies, similar in structure to the Meibomian glands. Between the caruncula lacrymalis and the globe of the eye, is a small fold of conjunctiva, called the *semilunar fold*, which appears to be a rudiment or imperfect exhibition of that structure which in quadrupeds constitutes what has been termed a third eye-lid; it is situated vertically between the upper and lower lid.

CHAPTER I.

Pathology of the Eye—Inflammation—Classification of Ophthalmic Diseases.

SECTION I.—PATHOLOGY OF THE EYE.

Within the small compass of the visual apparatus, we meet with a greater variety of structure than in any other part of the body. We have seen, indeed, in the preceding description, that the eye with its appendages exhibits specimens of every animal tissue in the body.* We find it in bone, cellular and adipous substance, and blood-vessels; mucous, fibrous, and serous membranes; the conjunctiva exemplifying the first; the sclerotica, the sheath of the optic nerve, and the lining of the orbit (*periorbita*,) the second; the surfaces containing the aqueous humour the third; muscular, nervous, and glandular parts; common integument and hairs. Besides these it contains several tissues of peculiar nature, to which there is nothing strictly analogous in other parts; these are the iris, the ciliary body, the choroid coat, and the transparent media. Each of the latter has its own

* I conclude that Beer means to express this circumstance in the singular paragraph, with which he begins his work on Diseases of the Eye.

"As man, in relation to the universe, must be regarded as a little world (microcosmus,) so must we consider the eye, in relation to the individual man, as a microcosmus, in which his soul and body are reflected."—*Lehre* vol. i. p. 1.

The same view is given, in nearly the same words, by Professor Rosas.

"By its intimate connexion with the rest of the organization, and their consequent mutual influence, the eye may justly be regarded as the mirror of the soul and the body. Further, as it exhibits in miniature a repetition of the whole bodily structure, it may be considered to bear to the latter the same relation that the body, as a little world, bares to the universe."—*Handbuch*, i. s. 485.

characteristic structure; the cornea, the crystalline lens, and its capsule, the hyaloid membrane, and the vitreous humour, resemble each other only in being transparent. Most of these parts are highly organized, copiously supplied with blood-vessels and nerves.

By the nature of its organization, by its office and its situation, and by its connexions with other parts of the system, the organ of vision is exposed to numerous external and internal sources of disease. The aid of this sense is required on most occasions; hence the eyes are incessantly exercised during our waking hours. In many instances they are excessively exerted, as by the numerous persons engaged in the various mechanical occupations requiring close attention, by artists, students, and literary characters. The situation of the eye lays it open, not only to accidental injury, but to various external influences.

As there is a common source of nutrition and circulation, and one centre of nervous energy, pathological principles must be the same for the whole body. In addition to the mutual dependence and influence resulting from this arrangement, there are numerous and important relations between the organ of vision and other parts of the animal œconomy. The fifth pair of nerves and the excretory part of the lachrymal apparatus connect it with the nose. A close, reciprocal influence is established between this organ and the brain with its membranes, by means of the nerves which enter the orbit, by the fibrous sheath of the optic nerve, and the periorbita. By the connexions of its blood-vessels, it must participate in the determinations of blood to the head. The communications between the great sympathetic and the third, fifth, and sixth cerebral nerves, as well as the continuity of mucous surface, establish a connexion between the abdominal viscera and the eye, capable of explaining many points in pathology and treatment. Again, the eye is a part of the external surface of the body, connected with the integuments through the medium of the conjunctiva, which may be regarded as a modified cutaneous covering. Hence it participates in the various diseases of the skin, not only in the acute affections, such as smallpox, scarlatina, and measles, but also in the more chronic disorders. Hence, too, perhaps, we may explain the advantageous effect, in ophthalmic disease, of cutaneous irritation, and of attention to the condition of the skin generally.

It will be clear, from the preceding considerations, that the affections of the eye, as a part of the organic system, come under the general laws of disease and treatment. We must, however, not lose sight of its peculiar tissues, and of the modifications which fit the organ for its especial office. It would be a most fatal error to insulate the diseases of the eye from the rest of pathology, to consider them as merely local ailments, and treat them only by remedies applied to the part. It would also be a mistake, though much less serious, to overlook the peculiarities of ophthalmic disease, and, trusting entirely to general means, to neglect all applications to the part.

When we consider that the component parts of the eye are so numerous and diversified in organization, and that each of these is subject to the same diseases, and consequent changes, which are incident to analogous structures in other parts; that they are not only liable to common disease with its various results, but that they exhibit important modifications of diseased action, dependent on peculiarity in the exciting causes, or on specific states of constitution, whether original or acquired; and that this complex and delicate organization is exposed to numerous and powerful causes of disturbance, we can easily account for the numerous distinguishable forms of ophthalmic disease. If each of these should be regarded and named as a distinct affection, we need not be surprised at the long catalogue,

which ophthalmic nosology would thus exhibit; that TAYLOR should have given an "*Exact Account of Two Hundred and Forty-three different Diseases to which the Eye and its Coverings are exposed*,"* and that Dr. ROWLEY should have written "*A Treatise on One Hundred and Eighteen principal Diseases of the Eyes and Eyelids.*"† We shall find, however, on closer inquiry, that this numerous offspring belongs, nearly all, to one family; that, although designated by distinct appellations, they are not distinct diseases, but that the great majority are merely forms and results of one morbid affection, viz. inflammation.

SECTION II.—INFLAMMATION.

The question then presents itself, what is inflammation? There ought to be no difficulty in answering it. We are continually talking of inflammation; almost constantly occupied in observing and treating what we call inflammations. The existence of this morbid affection is more and more generally recognized as the source of disease; and it seems likely, in the end, to spread itself over nearly the whole field of nosology. It has been carefully investigated by pathologists and practitioners, and much has been written on it; but the real nature of the process is as yet imperfectly known. If we should ask a surgeon, or look into a book for an explanation, we should learn that inflammation exists when the following changes are seen in a part; viz. redness, heat, swelling, pain, altered secretion, and impaired function. The word inflammation, from *inflammo*, denotes the most striking character of external inflammations; that is, the increased heat of the part. The other items in the nosological description are drawn from the same source, and by no means derived from a general survey of the process as it occurs in all structures. As a mere description, it is not applicable to the eye in many cases. In some conditions of the cornea, the iris, and the crystalline capsule, which are regarded as inflammations, there is no visible swelling, no redness, nor can we detect the existence of heat or pain. Again, in parts removed by their situation from direct observation, as the retina and hyaloid membrane, or the various internal organs of the body, we cannot determine whether the circumstances regarded as criteria of inflammation are present or not.

The question, however, what is inflammation? is not satisfactorily answered by enumerating these changes, even if we admit that their assemblage generally characterizes the process. Redness, swelling, heat, and pain, are the symptoms of the disease, the external signs that denote its presence. We must inquire, therefore, what is the internal change that produces these external signs? what is the alteration in the capillary circulation, that gives rise to redness, swelling, heat, and pain? This is not yet known. We understand something of particular inflammations, as those of the skin, cellular tissue, serous and mucous membranes, &c., because we can both observe their progress, and examine the parts affected; but, when we attempt to explain the nature of inflammation generally, we are investigating an abstract term. In this point of view it is a creation of the mind, not conveying any sensible ideas; its acceptation, therefore, cannot be defined or limited by reference to nature, our only safe guide.

The most general notion that we can form of inflammation, is that of increased activity in the capillary circulation, whether evinced by increased size of vessels and redness, by increased or altered secretions, or by deposition of new matter and consequent visible changes, such as thickening, consolidation, opacity, preternatural adhesions.

* 8vo. Edinburgh, 1759. † London, 1790.

The phenomena of inflammation, when it is seated in an external part of some size, as the hand and fore-arm, for example, show that an increased quantity of blood enters the inflamed part, and circulates through it. The throbbing and the increased size of the arteries, the distension of the venous trunks, with the fulness of the small vessels, as evinced by the external redness, and by the unusual red color of all the textures of the inflamed member, with the obvious increase in the number and size of their capillaries, proves that an increased quantity of blood enters the part. It seems to me equally evident that a larger quantity circulates through it. Blood flows much more freely from an incision into an inflamed part than into a sound one. This is strikingly exemplified in the division of the integuments and cellular membrane in phlegmonous erysipelas; both arteries and veins bleed so freely on such occasions, that twenty or thirty ounces of blood are often lost in a few minutes. When an operation is performed on an inflamed part, or in its immediate neighborhood, the blood is thrown more forcibly from the divided vessels, and we find it necessary to tie a much greater number than under other circumstances. The fulness of the veins in an inflamed limb is another unequivocal proof of the same point: these vessels could not be distended, if the blood sent to the inflamed part stagnated in it, as some have supposed. In a case of inflamed hand and fore-arm, requiring general depletion, I have tried the experiment of opening a vein in each arm at the same moment. Three times more blood flowed from the vein of the inflamed limb, than from that of the sound one, in the same time. We are thus led to regard the phenomena of inflammation, that is, the changes which occur in the part itself, as dependent on an increased activity in the circulating system. But it is not merely increased activity, that would produce increased nutrition, augmentation of bulk, as in the growth of the stag's horn, the enlargement of the uterus and the mammary glands in pregnancy; there must be an alteration in the mode of action; but in what that alteration consists we have hitherto been unable to determine.

The agents of inflammation are the capillary vessels, which carry on the active business of the animal economy, performing the various processes of nutrition, growth, secretion, and excretion. We do not yet know the differences of arrangement or action which lead to the various results of vascular exertion; we cannot tell how it is that the capillaries of one part deposit bone, those of another muscle, of a third membrane; how some secrete bile, others urine or saliva. As we know nothing of the causes which produce these striking differences, it is not surprising that the exact nature of the process called inflammation should still be a mystery to us.

The various inquirers who have investigated the subject experimentally, endeavoring to found a theory of inflammation on observation of the process in living animals, especially with the aid of the microscope, have come to very different, indeed opposite conclusions. Some have seen in inflammation an increased flow of blood to the part, and a more active transmission of it through the vessels; others assert that the circulation is obstructed. That there is increased activity of the capillaries has been generally believed; yet elaborate attempts have been made to show from microscopical observations that these vessels are in a state of debility, and do not exert themselves so much as in the natural condition. These and other similar contradictions must convince us, that the exact nature of that deviation from the normal or healthy state of the capillary circulation, which constitutes inflammation, is as yet unknown; and will save us the trouble of examining the speculations which have been founded on microscopical observations of the circulation in the transparent parts of living animals.

Varieties of iaflammation ; acute and chronic.—Inflammation is not one and the same process under all circumstances ; if it were, pathology and treatment would be very simple. The phenomena, which it exhibits, vary considerably, and the eye, from its position, and peculiar organization, affords the most favorable opportunity in the body for the study of these varieties. In the first place, the affection differs in degree; there may be more or less of the inflammatory disturbance. This distinction is denoted by the terms *acute* and *chronic*. Severity of symptoms and rapidity of progress characterize the former; the opposite attributes of mildness and slowness belong to the latter. I do not mean to represent that there are two degrees and no more: we may have every gradation of the affection, from that in which we barely recognize the existence of increased action, to the violent unnatural exertion, in which all the ordinary functions are perverted or interrupted, and even the very structure changed or destroyed. These diversities are only pointed out in a general way by the epithets acute and chronic, the shades of difference between the two extremes being numerous and indefinite. The terms themselves are not precisely contrasted in meaning; the epithet *acute* marks the violence of the symptoms; while *chronic*, which is equivalent to lasting or enduring (from χρονος, time,) denotes their duration: it is this violence that particularly attracts notice in the former case, while the continuance of disease is the most striking circumstance in the latter. Acute inflammation is also called active, violent, or phlegmonous; the latter term being derived from the Greek φλεγμων, the name given to that active inflammation of the cellular texture and skin, which generally terminates in abscess. Thus acute inflammation is a violent disturbance which cannot last long; unless cut short by proper treatment, it soon produces mortification, suppuration, or effusion; like fire, it soon burns itself out. Chronic inflammation is also called languid, slow, or indolent. Its characteristics differ in several important points from those of the acute kind. The vascular distension and disturbance are not so considerable; the redness much less, often hardly perceptible; the pain is slight or absent. Hence it may arise and proceed for some time, without the patient being aware of its existence. Although in these respects chronic seems a less alarming disturbance than acute inflammation, it is more serious in another point of view: it produces interstitial deposition, and consequent change of structure, which often impair or destroy the functions of the affected part.

Some are of opinion that there is a difference, not only in degree, but in kind, between acute and chronic inflammation. They admit preternatural excitement, and consequently increased exertion, as the essence of the former; but they suppose the latter to be the result of debility, and to consist of a weakened or atonic state of the capillaries. Thus we read and hear of active and passive or atonic, of sthenic and asthenic inflammations. Believing inflammation to be increased activity or exertion of the capillaries, I consider the expressions, passive, atonic, and asthenic inflammation, as applied to the state of the inflamed part, to be contradictory in terms. It is true that inflammation may occur in weak as well as in strong states of body, and that the local phenomena, the sympathetic disturbance of other parts, and the treatment will differ materially in the two instances. Moreover, an unhealthy, and consequently, in a certain sense, weak state of the constitution, may remotely cause many inflammations; but I cannot trace the disturbance, under these circumstances, to weakness of the part, and still less can I refer the phenomena to a weakened or passive state of the vessels. On the contrary, when we observe inflammations occurring in weak individuals, as in the advanced period of typhus, when the patient is

in the lowest condition of debility, we still find the local changes and results, which under other circumstances we refer, without hesitation, to increased vascular action. If there are any inflammations in which the capillaries are less active than in the healthy condition, I am not acquainted with them.

The same observation is equally applicable to the expressions, *arterial* and *venous* inflammation, or congestion. If we trace the arteries and veins of a part, we soon come to a point, at which we can no longer distinguish them. The capillary system, in which inflammation resides, is a net-work of minute ramifications, which we cannot unravel. How then can we ascertain whether arteries or veins are exclusively affected? Can we suppose such exclusive affection probable, or even possible?

The *acute* and *chronic stages* of inflammation are often spoken of. If we survey attentively any particular case, we do not find that it is one and the same process throughout: there is a succession of phenomena. The disturbance commences insensibly, gradually increases till it acquires a certain development, remains for a time at that point, and then gradually recedes, till the part recovers its healthy state. The whole of this course passes under the name of inflammation, though the various parts of it differ considerably from each other. If we were to divide each inflammation into three periods, of *formation*, in which the symptoms arise and proceed to a certain extent, of *full development*, and of *decline*, we should find that the first two are nearly of equal length in most cases of active inflammation; but that the portion of time, between the point at which the symptoms begin to lessen and complete recovery, varies much in its length in different instances. When inflammation has been violent, and allowed to pursue its progress uncontrolled, more particularly if the exciting causes have continued to act, the disturbance lasts in a greater or less degree for a long time, although the more urgent symptoms may have been lessened. The part is still inflamed, but the redness and pain are less, the interruption of function is not so great. This minor degree of inflammation, which may continue for a long time, is called the *chronic stage*, while the former period, in which the symptoms were violent is termed the *acute stage* of an inflammation. If the disease be actively treated, if its progress be arrested by judicious means, the part recovers quickly, and we can hardly say that any chronic stage occurs.

Besides employing these terms to designate the different portions of one and the same inflammation, some have contended that the two periods are totally different in their nature; that increased exertion is the essence of one, weakness of the other; and that a corresponding difference of treatment is necessary, the chronic stage requiring, as they represent, tonic and stimulant means. These views seem to me altogether erroneous. Without asserting that there is no difference between acute and chronic inflammation in general, I have no hesitation in affirming that the acute and chronic stages of one and the same inflammation do not differ in their essential nature. Thus we find that the acute form passes into the chronic, and that the latter may relapse into the acute. When inflammation of the eye has reached the chronic stage, all the phenomena of acute inflammation may be re-produced by exertion of the organ, imprudence in diet, or other causes. Finding that, within a short period, one form can pass into the other, and *vice versa*, how can we admit the notion that the two are opposite in their nature and in the treatment they require?

In a large proportion of cases, the chronic stage of inflammation is merely the continuance, under milder symptoms, of a disorder essentially the same as that which existed in the earlier or acute period. The disease is pro-

tracted by the causes just alluded to, and requires treatment similar in principle to that which we employ in its more active state. In other cases inflammation is obstinate and tedious, often becoming confirmed or chronic, from an unhealthy state of constitution, whether original, as in those of delicate frame, and especially the strumous, or brought on by unwholesome habits, by the various depressing influences, or by the advance of age. Under such circumstances, we adopt a treatment both local and general, different from that employed in the first kind of cases, often finding it necessary to raise and support the general powers by medicines, generous diet, stimuli, and the various invigorating influences. Hence probably has arisen the notion that these chronic inflammations are maintained by weakness, which is correct in the sense thus explained.

Various effects.—Inflammations differ in their effects; these differences depending principally, though not entirely, on differences in the degree of disturbance. *Irritation* and *congestion* or *determination of blood*, may denote the early stages in the deviation from health, before the disturbance has attained such a degree as to warrant us in calling it inflammation. Then come *hemorrhage*, *effusion of serum*, of *lymph*, or of *pus*, *ulceration*, and *mortification*. *Loss of transparency*, *preternatural adhesion*, *thickening*, and *induration*, are changes dependent on effusion, and are observed for the most part, as more remote consequences of inflammation. *Softening* may occur as a primary or secondary effect of the inflammatory process. On the other hand, the disturbance often passes away without any ill consequence to the part, the symptoms either ceasing suddenly, or subsiding more gradually: both these events are called resolution, which may therefore be distinguished as sudden, or gradual; the former is called by the French, *délitescence*.

So much hardness is sometimes produced by interstitial deposition in the inflamed part and its subsequent organization, that the part is said to become *scirrhous*. The production of *scirrhus*, and its subsequent ulceration which constitutes cancer, are mentioned as common consequences of inflammation, even in the modern surgical works of France and Germany.* This seems to me an erroneous view of the subject. The consequence of inflammation is simply induration, often with enlargement: in the part thus altered we can always discern the characters of the natural structure. In scirrhus the natural structure is quite lost, and a new organization substituted. Confining the term scirrhus to that induration which precedes cancer, and terminates in the destruction of the part and of life, I have never seen it as the result of inflammation, either in the eye or any other organ.

Common and specific.—That the state of the constitution should modify inflammation is a circumstance which might be expected. When it occurs in a healthy individual, from an ordinary cause it is called *common* inflammation; this may be exemplified by the effect of a wound on a person in good health. The terms, *true*, *proper*, *simple*, *idiopathic* inflammation are used in the same sense. If the patient be young, strong, and of full habit, the inflammation will be acute, active, or phlegmonous in its character. The terms, *specific*, *sympathetic*, *spurious*, *mixed*, are applied to those modifications which inflammation assumes in various states of constitution, more or less different from the healthy condition. A peculiar character will be given to the inflammatory process by certain differences of organization, or natural defects of constitution, such as the scrofulous and rheumatic, by

* Andral, *Précis d'Anat. pathol.* t. i. p. 501; Broussais, *Examen des doctrines.* Propositions de Médecine, prop. 196. *Dictionnaire de Méd. et de Chir. Pratiques*, t. iv. p. 444. Langenbeck, *Nosologie*, b. i. p. 316—318.

acquired conditions of a morbid kind, as in gout and syphilis, or by the specific influence of the exciting cause, as in smallpox, measles, scarlatina, malignant pustule, and all other contagious diseases. In the instances last mentioned, the disease is produced by one particular cause, and no other. The specific character of the inflammation, therefore, arises from the cause in these instances, while in the others it has its source in peculiarity of constitution in the affected individual. Under these various conditions, the appearances of inflammation will differ very much from those which it exhibits in persons of good natural constitution, and in sound health. Frequently, however, specific is so much like common inflammation, that the distinction is difficult. The extremes are well marked, but they are connected by numerous intermediate gradations.

Varieties from difference of texture.—Inflammations differ according to the texture of the affected part. When we find that inflammation is an increased action of the blood-vessels, that its seat is in the capillaries of a part; when we know, at the same time, that the arrangement of these is peculiar in each tissue and organ, we naturally conclude that the inflammatory process will have its peculiar characters in each structure. From this source we deduce differences, not only in the characters of inflammation, but also in its effects. Hemorrhage occurs frequently in the inflammation of mucous membranes, rarely in other parts; effusion of lymph, adventitious membranes, and adhesions are common in the serous, hardly ever observed in the mucous membranes. Ulceration, which is a frequent result in the skin, the mucous membranes, the articular cartilages, and the cornea, is hardly seen elsewhere.

No organ in the body presents so favorable an opportunity as the eye, for observing the varieties of the inflammatory process, which depend on difference of structure. It contains specimens of all the animal tissues, and these are, for the most part, immediately open to our observation, so that the study of ophthalmic diseases constitutes an epitome of general pathology. In this point of view nothing can be more interesting and instructive than an observation of the varieties presented by inflammation of the conjunctiva, sclerotica, cornea, iris, and retina.

Other modifications.—Inflammation is also modified by many other circumstances, which influence the body more or less powerfully, such as temperament, age, sex; individual constitution; mode of life, as respects air, diet, clothing, exercise, sleep, and other habits; season, climate, state of the weather and atmosphere, and the unknown agencies which produce endemic or epidemic disease.

When we consider the numerous distinct component parts of the eye, the several circumstances which modify the inflammatory process in those structures, and the varied results which it may produce in each, we shall be enabled to account for the great number of ophthalmic diseases. If the length of the list should frighten the student, he must remember that these various affections may, for the most part, be referred to a common origin, that they partake of a common nature, and that, as they are nearly all the offspring of inflammation, so the treatment of them is, in essential circumstances, similar. The more attentively we observe the phenomena of disease, and consider the effects of remedies, the more we shall be led to adopt simplicity of treatment, and the less confidence shall we place in complicated plans, or great diversity of remedial means.

SECTION III.—ARRANGEMENT OF THE SUBJECT.

The arrangement adopted by BEER in his large work, is a simple one. He treats, in the first place, of inflammations, and then of their consequences. However, we cannot refer all the affections of the eye to one or the other of these heads; and thus BEER is obliged to adopt a third, a catalogue of undefined affections, which do not come under either of the preceding divisions. As we do not know the exact nature of the inflammatory process, as the pathology of some parts of the eye is yet in an imperfect state; and as we have seldom an opportunity of examining the results of ophthalmic diseases after death, we are unable to present a classification of them founded on clear and unequivocal principles, and in all respects satisfactory. If it were required to give an arrangement of all diseases and defects of the eye, that is, of all those matters upon which our professional opinion may be required, I should be inclined to adopt a greater number of divisions than BEER has done.

Injuries might be considered first; *inflammations* would occupy the second division, and they might be conveniently distributed, according to their seat, into those of the *orbit*, *lids*, and *globe;* those of the latter being subdivided into the *internal* and *external.* This head would of itself embrace a long catalogue of diseases. Thirdly, I should speak of the *consequences* and *concomitants of inflammation*, as they appear in the individual parts of the apparatus; fourthly of *tumours* in the lids, in the globe, and in the orbit; fifthly, of *malignant affections*, such as scirrhus, cancer, fungus hæmatodes, melanosis; sixthly, of affections not referable to inflammation; and the seventh head might comprise congenital peculiarities or defects. Under these divisions we might conveniently enough arrange every thing which can be the subject of professional consideration respecting the eye.

I propose, in the following sheets, to treat of all these subjects, though not under the same arrangement. I shall consider successively the affections of the eye-lids and eye-brows; of the globe; the orbit; the lachrymal organs. Under the first division, chapters will be devoted to wounds, inflammations and their consequences, ulcerations, changes of figure and position, morbid connexions, tumours. Under the second, after a general view of the causes and treatment of ophthalmic inflammation, I shall describe the inflammations and other changes incidental to each of the parts belonging to the eye-ball; the operation for artificial pupil, cataract, amaurosis, and other defects of sight, malignant affections of the eye, dropsy, and atrophy of the globe will come under this head.

CHAPTER II.

Affections of the Eye-lids.

SECTION I.—INJURIES.

Wounds of the eye-brows and eye-lids.—The ordinary principles of treatment are applicable to wounds of these parts, whether incised, lacerated or contused; the only difference being that it is here more urgently necessary to bring together the sides accurately, and to prevent inflamma-

tion in order to attain that speedy and perfect union, which affords the best security against subsequent deformity. From negligence in this point I have seen in a longitudinal wound of the eye-lid, a permanent slit in the shape of the letter V, like the fissure of hare-lip. Such a fissure has been called *coloboma*. Inversion or eversion of the palpebræ may take place from similar neglect, occasioning serious inconvenience in various ways, as well as great and conspicuous deformity. I saw a case of horizontal wound in the upper lid, which had been grossly neglected; the edges, not having been brought together, had cicatrized separately, so as to form a slit in the lid like a button-hole. The wound had no doubt affected the eye; for the surface of the lid had become preternaturally connected to the globe, so that it could not be raised, but constantly covered the cornea, rendering the eye, of which the vision was perfect, nearly useless.

I was consulted some time ago by a gentleman who had been thrown from his horse, and received a wound of the eye-brow, so that about one-third of it, being the middle portion, was detached and torn down towards the lid. From inattention to the management of the accident, the detached part of the brow healed below the level of the rest; producing a remarkable and by no means becoming appearance. This gentleman, who was handsome, rejected my advice of letting it remain as it was, and wished me to adopt some proceeding for removing the deformity. I made a vertical incision on each side of the displaced part, united the incisions transversely above, and dissected off the portion from its new situation, leaving it adherent below. Of the flap thus made I cut off the upper portion, corresponding to the depth of the eye-brow; and then secured the remainder in its proper position by sutures. It adhered readily, and the operation seemed to have succeeded perfectly, when the patient left England for a long absence on the continent.

Accurate union can scarcely be accomplished in these cases by means of adhesive plaster, especially in the eye-lids. At all events sutures answer the purpose much better. We employ small thin sharp needles, with single silk threads, and place as many sutures as may be necessary to unite the parts in their proper relation to each other. Lay over the part a soft linen rag or a portion of lint dipped in cold water; use this application frequently; keep the patient quiet, and attend to his bowels. Plasters, compresses, and bandages, are not only entirely useless, but by heating the parts, must be injurious. The sutures may be cut out in twelve, eighteen, or twenty-four hours; in that time the edges of the wound will have become agglutinated either by coagulated blood or coagulable lymph, so as to remain subsequently in proper apposition. We thus avoid all irritation from the sutures; it does not come on in so short a time. By these measures the union of the parts is effected speedily and completely. This mode of proceeding is particularly necessary in wounds of the lid, in which it is more difficult to preserve an accurate adjustment than in those of the brow. After wounds in this neighborhood, the lids are often considerably swelled by serous effusion, which is of no consequence. Greater care is necessary to avert inflammation in lacerated wounds of the brow or lid. They should be united by a sufficient number of sutures, and then covered with a soft wet rag, or with the water-dressing according to the plan of Dr. Macartney, or with a soft bread poultice.

In *punctured wounds*, with trivial external mischief, injury may extend deeply, into the orbit, to the bone, through the thin roof of the orbital cavity to the brain. In some instances, where no alarming symptoms have appeared at first, inflammation within the skull has come on in a few days, and has speedily proved fatal. Suppuration in the orbit, although less dan-

gerous, would be a serious occurrence. Injuries of this description should be attentively and cautiously examined in the first instance, to ascertain the extent and nature of the injury. If we find or suspect that the bone has been penetrated, every precaution calculated to keep off inflammation must be adopted, such as quiet, low diet, purgative medicine, and free depletion, if symptoms of cerebral affection or constitutional excitement should arise.

Poisoned wounds.—The eye-lids inflame and swell from the stings of bees and wasps, the bites of gnats and other insects. BEER* mentions that he saw in two cases, where the stings of bees had been left in the wounds, mortification, with danger of life, in a day and a-half.† It would be proper therefore, to extract the sting, and to employ cold applications, as saturnine lotion, or vinegar and water.

I once saw *malignant pustule* on the lower eye-lid, and the contiguous part of the cheek. It occurred in a man about fifty, who had been employed in Leadenhall-market in handling and moving hides brought from South America. They were in a very bad state, one of them accidentally came in contact with his face, but he hardly noticed the circumstance, and did not think it necessary to wipe himself. He came to St. Bartholomew's hospital, with a portion of integument, nearly equal in size to a crown piece, slightly swelled, red, with some heat and pain. The appearance was just like that of incipient erysipelas. The skin thus affected soon became livid, and then mortified. In the process of separation, which went on favorably, it became evident that the soft textures beneath had suffered as well as the skin, and thus a large chasm was left below the eye-lid, when the eschar had separated. Excepting the sloughing, there were no severe local symptoms, nor was there any material constitutional disturbance. The affection of the skin did not extend beyond the part which was red at the time of admission. The only local application was a bread poultice, under which the slough separated, and healthy granulation and cicatrization ensued, with the effect of producing slight eversion of the lower lid. Bark was administered at first, but soon discontinued, because it produced fulness of pulse, thirst, and headache. Simple saline medicines were substituted.

In *scalds* of the eye-lids we use the local means best calculated to lessen inflammation, and recovery takes place without deformity. But in *burns*, with destruction of the integuments, especially if it be extensive, cicatrization is likely to be followed by changes in the figure and position of the palpebræ, with more or less of deformity. The ciliary edges of the palpebræ may be drawn towards the cheek or the forehead and fixed there by the cicatrix, so that the conjunctival surface of the lids is exposed (*eversion* or *ectropium;*) the upper lid may be drawn towards the edge of the orbit, so as to denude the eye partially or completely (*lagophthalmus;*) or the lids may be drawn out of place laterally, towards the temple or the nose. These cases must be carefully watched during granulation and cicatrization, and we must employ all means in our power to prevent changes of figure or position in the lids. Slow healing is favorable, as well as the abundant granulation which generally follows burns where the integument has been entirely destroyed.

Amaurosis from wounds of the eye-brow.—Wounds of the eye-brow, and neighbouring frontal region, are sometimes attended with more serious consequences than mere alterations in form, and the consequent effect on personal appearance. A violent blow in this situation, with or without wound,

* *Lehre*, v. i. p. 234.

[† Dr. Mease has recorded in the *American Journ. Med.* Sc. Nov. 1836. p. 265, a case in which the sting of a bee on the eye-brow, proved fatal in twenty minutes.]

may affect the globe, as well as the external soft parts; may cause serious injury by concussion, without external wound, and thus sight may be impaired or entirely destroyed. I shall speak subsequently of concussion of the retina.

The bone may be fractured, and the anterior cerebral lobes injured: or the fracture may extend along the thin, brittle, orbital process of the frontal bone, reaching to the optic nerve, or to the union of the two nerves. In such cases injury to sight, in various degrees, will probably accompany the external wound, but the state of vision is here a subordinate point; our attention is called to the danger of life, and the means we resort to for averting it will probably be equally advantageous to the eye. It is obviously necessary, in all such accidents, for the surgeon to examine the globe carefully, and to ascertain, as soon as the circumstances will allow, whether vision is injured or lost.

Other cases have been mentioned, where the direct injury has been confined to the soft parts of the brow, without any fracture of the skull, or any concussion of the globe, and yet amaurotic weakness of sight or actual blindness, has supervened sooner or later. Hippocrates has made the remark, that wounds of the eye-brows often cause blindness; several learned men have commented on this remark, but have not attempted to illustrate the point by facts. Beer, however, states that he has had frequent opportunities of accurately observing and curing amblyopia (weakness of sight) and amaurosis (loss of sight) occurring in consequence of wounds of the eye-brows: Mr. Wardrop,* too, speaks as if he had seen such cases. The amaurosis or amblyopia, according to Beer, may immediately follow the injury, or come on soon after; it may occur during the healing, that is, during the process, of cicatrization, or some time after the cicatrix has been completed; or it may be the consequence of simple bruise without wound. The affection may be developed rapidly or slowly.† The instances referred to are incised or lacerated wounds, embracing the trunk or principal branches of the frontal nerve, and Beer regards the injury of this nerve, as the determining cause of the amaurotic affection. However, he applies this explanation to what he represents as the most frequent case, viz. that of the impaired vision coming on during the cicatrization, or after its completion. He says, that where such wounds are judiciously managed and speedily healed by adhesion, no bad consequence ensues; but that when suppuration occurs, followed by the granulating process necessary for secondary union, the divided nerves are involved in the inflammation, and subsequently included in the hard cicatrix, and, as he conceives, compressed and irritated. He observes, that among the numerous cases which he has seen of such wounds, only two instances have occurred of complete amaurotic blindness, in both of which it did not appear till some length of time after the healing of the wound. His treatment, founded on this view of the cause, consists in dividing the nerves included in the cicatrix. He states, that in the two cases just mentioned, the patients were completely restored to sight by cutting down to the bone, close to the supraorbital foramen, so as to divide all the branches of the frontal nerve.

The following case is related by Mr. Middlemore.

"A person received a wound just above the right eye-brow, from a piece of glass, which was removed immediately after the accident, by the patient himself; the wound was then dressed with simple dressing. It healed in a few days, but to the patient's great surprise, the sight of the right eye was

* *Essays*, vol. ii. p. 179.

† *Lehre*, vol. i. § 195.

very nearly lost; he had a painful sensation in the neighborhood of the cicatrix, and a singular sense of creeping, pritching, and quivering of the upper eye-lid, and the integuments of the forehead. The eye was perfectly natural in appearance, except that the action of the iris was sluggish, the pupil dilated, and slightly drawn towards the nose. I made a free incision of the parts in the site of the cicatrix quite down to the bone, and all uneasiness at once ceased, the eye shortly afterwards assumed its healthy character and functions, and vision was permanently restored."*

Some years ago I saw a gentleman, about twenty years of age, ten weeks after he had received a violent blow on the left eye-brow. The skin was divided, but the patient was not stunned, nor did he experience the slightest headache, either at the time or afterwards. The lids were greatly swollen after the injury, probably from ecchymosis, so that he could not open the eye. When he did open it, at the end of a few days, he could see nothing, although the surgeon informed him that there was no perceptible change in the eye. He was bled, purged, and confined to low diet. I found the appearance of the eye quite natural. The pupil contracted and dilated in sympathy with the other, but the independent motion of the iris was completely lost. The pupil dilated when the opposite eye was closed, and remained motionless in that state. Vision was extinct, so that the difference between light and darkness could not be distinguished. There was a small cicatrix on the eye-brow, near the external angle of the eye.

About the same time I was consulted by a young lady, in whom the eye-brow and lid had been much lacerated in consequence of a fall from her horse. There was imperfect amaurosis of the eye, which did not seem to have experienced direct injury. The pupil was moderately dilated.

In some cases, it is doubtful whether the amaurosis following blows on the head is determined by the particular nature or sympathies of the organ or texture immediately injured.

In October 1827, I saw a gentleman, thirty-two years of age, who had been thrown from his gig seven weeks before, and had fallen on the head. He was completely stunned, and remained insensible for some hours. According to the account of the surgeon who attended him after the accident, there were appearances indicating that the head had come in contact with the ground above the right eye-brow, where the skin afterwards exhibited the discoloration of a slight bruise; there was neither bruise, ecchymosis, nor any direct injury to the globe, conjunctiva, upper eye-lid, or eye-brow. The eye, in which vision had before been perfect, was totally blind, and had continued so in spite of the treatment adopted for the accident, as well as in reference to this particular affection. When I saw the patient, there was no trace of injury to the part which had been struck. If both eyes were open, no difference could be observed between them: the pupils were perfectly alike in size, color, and movement. When the left eye was closed, the right pupil dilated moderately, and remained fixed in that state under every variation of light. When the left eye was opened again, the right pupil contracted. When both eyes were open, the right pupil dilated and contracted just as the left. The right eye was absolutely insensible to light; the left suffered a little sympathetically.

A lady was thrown out of a gig, and came to the ground on the head and side; she was stunned, but soon recovered. Bruise and ecchymosis of the right temple and eye-lids were observed; but the latter were not closed. She was confined to bed in consequence of the injury to the side, for five weeks, at the end of which time she found the sight of the right eye affected.

* *Treatise*, vol. ii. p. 364.

I saw her three months after the accident, when the pupil of the right eye was twice as large as that of the left; she said that it had been still more dilated at first. It did not contract on exposure to light; there was confusion of vision.

The blindness occasioned in MAGENDIE's experiment of dividing the nerve of the fifth pair (see *ante*, p. 96,) may be cited in support of the opinion, that the imperfection of sight in the cases now under consideration, arises from injury of the frontal nerve. The influence which morbid conditions of this nerve may exert on the eye, is strikingly evidenced in a case now under my care. It is that of a gentleman with a large cancerous ulcer of the forehead, occupying the right eye-brow in its whole breadth from the root of the nose to the temple, and the right frontal region for about two inches above the brow. In the extent just mentioned, the soft parts have been completely changed in structure by the ulceration, which has been going on for some years, and even the bone has participated in the disease, small fragments having come away from time to time. The eye has lately become the seat of inflammation, with destructive ulceration of the cornea, as in the cases of disease affecting the trunk of the fifth pair.

It is still a matter of doubt, whether injury of the frontal nerve may cause amaurosis. In some of the cases I have mentioned, the external injury was not in the situation of the nerve; while there is no clear evidence of the nerve having really suffered in any instance. Again, I have seen amaurosis of one eye following severe injury of the head, where the frontal region had suffered no direct violence.

During the revision of these sheets I have been consulted by a lady laboring under amaurosis of the right eye, consequent on an injury of the head not involving the superciliary or frontal region. She was thrown from her horse in September, 1839, and the back part of the head towards the right side came to the ground. She rose, remounted, and rode home, a distance of twelve miles. She became ill, and was confined to her room for ten or twelve days. When she came down stairs, the sight was imperfect: it soon recovered in the left eye, but was quite gone in the right. When I saw her (in June, 1840) she could not distinguish objects with the right eye, although it was sensible to light and darkness. The appearance of the organ was perfectly natural, and the movements of the iris both independent and associated, if not in all respects equal to those of the left eye, were very little different.

BEER has strongly recommended a complete division of the nerve by a transverse cut down to the bone, where impaired vision is supposed to arise from injury inflicted on it, and states that he had found the proceeding uniformly successful in restoring sight. It failed invariably with Dr. HENNEN* and Mr. Guthrie,† who tried it in several instances.

If sight may be thus injured or lost by wounds of the frontal nerve, we should infer that similar consequences would arise from injuries of the infra-orbital nerve. BEER says that this is the case, but he does not cite any facts.‡ The latter nerve, however, is more effectually protected than the former, and hence it is rarely wounded.

[Electricity, galvanism, moxas, repeated small blisters, and strychnine, appear to us to be worthy of trial in many cases of this form of amaurosis, before resorting to the division of the supra orbitar nerve, as recommended by Beer.

* *Observations on some points in Military Surgery*, p. 366.
† *On the Operative Surgery of the Eye*, p. 102.
‡ *Lehre*, vol. i. § 205.

[In several cases we have found much benefit from the application of galvanism, one or two of which we will relate.

Imperfect Amaurosis from a blow—Partial recovery.—Abraham Corbit, ætat. 41, native of England; married; scissors grinder; admitted into Willis Hospital, October 5th, 1839. Nine days ago, whilst splitting wood, a piece flew up and struck him over the right eye. He experienced little or no pain from the blow at the time, nor did he suffer from any subsequently. But three days after he found that the sight of the right eye began to fail, and by the seventh day after the accident, he was quite blind in it. Person spare, medium height; irides gray, pupil of right eye rather larger than that of left; in other respects appearance of this eye perfectly natural; health good. Has been blistered over right brow and purged. Can now tell when objects are placed before his right eye, but cannot distinguish their form. Ordered him to be purged every alternate night, with Mass. hydrarg. cum. extr. colocynth comp. āā. gr. iv. The following collyrium to be dropped in his eye daily. ℞ Strychnin gr. ij; Acid. acet. ʒj. Aq: Puræ. ℥j.

October 7th. Sight has improved; can distinguish the sashes of the windows; sees better at midday than in the evening, and near objects better than remote ones. Continue treatment.

9th. Sight continues to improve; can tell how many fingers are held before right eye, and can distinguish a silver pencil case.

11th. Sees distant objects better; distinguishes the window sash distinctly and a pencil case at the distance of two yards; continue treatment, with addition of mustard pediluvia at bed-time.

14th. Can distlnguish some of the large capitals in a primer.

16th. Complains of rheumatic pains in his lower limbs; ℞. pulv. Doveri, gr. x, and mustard pediluvium at bed-time.

17th. Sight diminished. Has headache; rheumatic pains continue. Ordered vin. rad. colchic. gtt. xx. ter. d.; mustard pediluv. at bed-time.

18th. Sight diminishing; rheumatic pains rather less severe; cups to spine; continue colchicum and pediluvium.

19th. Vision improved; rheumatic pains lessened; prevented sleeping by toothache; ordered tooth extracted;* continue treatment.

21st. Sight improving; can distinguish large letters; says objects "appear clearer and more distinct;" continue treatment.

23d. Sight better; rheumatic pains less; bowels costive; sleeps well. Cups to back; senna and salts.

27th. Sees distant objects better; has required purgatives occasionally to remove costiveness; rheumatic pains diminished. Continue treatment; apply galvanism, one pole of the instrument to right brow, the other to mastoid process of same side.

29th. Sight has improved he thinks since application of galvanism; sees objects at the end of the ward; rheumatic pains pretty severe.

31st. Sight about the same; rheumatism much better; sleeps well; bowels regular; galvanism was applied yesterday, but without any perceptible benefit; ordered moxa to brow.

November 3d. No improvement in vision; free from rheumatism; repeat moxa.

6th. No improvement in sight within the last week; sees, however, well enough, he thinks, to weave, which has been his occupation recently, and being desirous of finishing some work for an order, as he has a family to support, he requests to be discharged as an in patient, and to be placed

* This was neglected.

on the out door list. His wishes were gratified, and he was furnished with a box of purgative pills (blue mass and extr. colocynth comp.) and a bottle of Henderson's collyrium.

23*d*. The patient was again admitted into the house. During the interval he had several times received advice, but no change in the treatment worthy of note was made. He had been weaving and the premature use of the eye had impaired its power, and he could not now see sufficiently well to continue his work. The treatment to which he was now subjected, consisted in the frequent use of galvanism, with the addition after a few days of strychnine conveyed into the system by the galvanic current; with mustard pediluvia and tincture of capsicum in frictions to the feet and legs, (the patient suffering much during the first three weeks in December from coldness of extremities,) and a due regulation of the bowels. By these means his sight improved. At night the patient stated that he could see considerably better than previously; though he maintained, contrary, however, to our impressions, that he saw no better by daylight. When my tour of duty expired he was still in the house, and I find by the register that he was discharged February 10, 1840, relieved.

Observations. Whether the amaurosis in the present instance was the result of concussion of the retina, or of injury of the supra orbitar branch of the fifth pair cannot positively be determined, as it was impossible to learn from the patient whether the blow was directly on the eye or on the brow, the injury being so slight as not to have attracted much attention at the time, and the blow had left no mark.

The remedy which was most useful in this case was unquestionably galvanism. We have an evidence of this not only in the improvement which followed its application, but in the still more striking fact, that the patient *actually saw better whilst subjected to the galvanic action.* On the 6th of December, whilst the galvanic current was passing from the mastoid process to the superciliary ridge, I requested my intelligent friend, Dr. John Neill, to hold before the patient some letters; and I asked him if he could distinguish them: he replied, "I see better than I could." The galvanic current was then interrupted by disconnecting one of the wires from the plates, and which was accomplished without the patient's knowing it. The letters being still held up, the patient in a minute or two requested them to be held nearer, then farther off, and finally he observed, "I do not see as well as I did just now." The connexion being again made, the patient almost immediately, and with apparent surprise exclaimed, "I see better now." The patient was not aware of our object in this experiment, and though of course he may have been sensible of a difference in the effect, still he did not know, as the poles were all the time applied to his head, that he was at times freed from the action of the apparatus.

In a case of a similar kind, that of Jos. M. Sutter, a carpenter, ætat. 43, admitted October 18, 1836, a complete cure was effected by galvanism. This man trod upon a log, which tilted up and struck him over one eye. When admitted he had complete amaurosis of that eye. Various remedies were employed, among others moxas, with little benefit. I then resorted to galvanism, the very first application of which was productive of marked improvement, and its employment for an hour, two or three times a week, for five weeks, effected a complete cure. He was discharged January 3, 1837, well.

In Sutter's case, and also for Corbit when he was the first time in the house, the galvanic apparatus employed was a Cruickshank's battery of

twenty pairs of plates one and a-half inches square. Subsequently for Corbit we used one with fifty pairs of plates three inches square. When this was in full activity it was too powerful for our purpose, and only one-half or two-thirds of the plates were then used. The connexion was made by means of leaden wire conductors, to one end of each of which was soldered a slip of copper; and to the other a hemisphere of brass, the flat surface of which was filed into grooves crossing at right angles, so as to form a number of sharp points. Over these were tied thin discs of sponge, which were kept moist with a solution of common salt. When we desired to introduce the strychnine into the system we moistened the sponge attached to the negative pole, and sometimes both, with a solution of this substance. That the strychnine may readily be conveyed into the system by this means would appear to be shown by the experiments of M. Fabre-Palaprat,* and also by the fact that usually much greater twitchings of the muscles were observed when the solution of this substance was employed, that when the sponge was wet merely with the solution of common salt. When the whole force of the battery was not wanted, instead of placing the slips in the extreme cells, they were placed in cells more or less remote, according to the power required: thus the force was easily regulated.

Mr. Hey narrates (*Med. Obs. & Inquiries*, v. i.) a case of amaurosis following a wound of the forehead caused by the patient falling against a chest of drawers, which was cured by Electricity; and Dr. Lichtenstadt† another which seemed to have originated in a wound of the infra-orbitary nerve in which the same application had an equally happy effect.]

Ecchymosis of the eye-lids.—The eye-lids, the eye-brows, and the anterior surface of the eye, are liable to ecchymosis. Effusion of blood into the texture of the part produces those livid, blackish, or bluish marks in the palpebræ and surrounding skin commonly termed a black eye. Much loose cellular texture enters into the composition of the lids, and the effusion which takes place is sometimes considerable. The palpebræ may be distended by a projecting convex swelling, and in pugilistic contests the eyes of the combatants become in this way completely closed. On such occasions the seconds are in the habit of performing a kind of chirurgical operation, without having received any diploma from the college: they make an opening in the skin with a lancet, and squeeze out the blood, by which expedient they enable the combatant to see his way a little longer. Ecchymosis is often occasioned by the application of leeches. In whatever way these external marks are produced, individuals are generally desirous of getting rid of them, and surgical assistance is sometimes sought for that purpose. The external application of cold is usually resorted to in the first instance. The question is, whether we can adopt any means to hasten the removal of this discoloration? Absorption will accomplish the business in a certain time, and it is doubtful whether we can abridge the period by using any of the articles termed discutients. The muriate of ammonia, dissolved in a mixture of vinegar, spirit, and water, is employed for this purpose, and will do as much good as any thing. The liquor ammoniæ acetatis may be used, alone or mixed with rose-water; or the liquor ammoniæ, mixed with soap liniment, may be rubbed on the part after two or three days, as such stimulating applications are supposed to be capable of accelerating the process of absorption. There is a quack preparation, called "pommade divine," composed apparently of unctuous and arromatic ingredients, which is used for this purpose; it is an agreeable sort of salve,

[* See American Journal of the Medical Sciences, for Feb. 1834. p. 561.]
† Mackenzie, Treatise, &c., from Graefe and Walthers Journal.

and unexceptionable as an application. I have fancied that the discoloration of ecchymosis has disappeared sooner under its use.

Mr. TYRRELL recommends a poultice made with the root of the black bryony, finely scraped after being deprived of its external bark, and mixed with crumbs of bread. It should be enclosed in a muslin bag, and renewed every six or eight hours until the absorption of the effused blood is completed, which will take place in forty-eight hours or a little more, even when the ecchymosis is considerable. He adds, "I became acquainted with this remedy, from noticing that some of our celebrated pugilists appeared, a few days after severe encounters, without any disfiguration from ecchymosis; and, on inquiring the reason of this, I found they employed the bryony root, in the manner I have described, to remove such evidence of their occupation."*

[We have known common tallow, thickly applied, over the contused part, employed with the same view, and apparently with the desired result.]

SECTION II.—INFLAMMATIONS OF THE EYE-LIDS AND THEIR CONSEQUENCES.

Inflammation of the cellular texture of the lids; abscess.—The cellular texture is liable here, as in other parts, to inflammation,† which may proceed to suppuration. There is nothing peculiar in the abscess thus formed, nor in the essential points of treatment. The matter may approach to the surface on either aspect of the lid; or it may be present in both situations at once. In order to avoid subsequent deformity, we should endeavor to limit the extent of suppuration as much as possible. An early opening of the abscess is necessary for this purpose; the incision should be transverse, that is, parallel to the natural folds of the integument. If the integuments of the upper lid should be detached from the subjacent parts, and distended by a large collection of matter, the consolidation of the abscess may cause the tarsus to become unnaturally fixed to the superciliary ridge, and lagophthalmus, or ectropium with great deformity may ensue. This point is still more important in scrofulous than in common suppuration, because the matter extends laterally, with little disposition to approach the surface; and consequently, if left alone, will occupy the whole lid. I have seen about half a dozen instances, in which distressing deformity from lagophthalmus, either alone, or in company with eversion of the superior tarsus, has resulted from this cause; the external convexity, or the very ciliary margin of the tarsal cartilage, having become closely attached to the edge of the orbit. In one case, of a young gentleman from Scotland, where the appearance was so very disagreeable that he kept the eye constantly covered by a close green shade, and consequently was prevented from using the organ, I succeeded, by a painful operation, and much subsequent trouble, in removing the deformity entirely, and in restoring the eye. In another instance of a highly scrofulous subject, an abscess was allowed to burst in each upper eye-lid, producing ectropium on both sides, which greatly disfigured the individual, and could be only partially remedied. Fistulous excavations sometimes remain after palpebral abscesses.

[A case, in which inflammation of the cellular tissue of the upper lid terminating in abscess, was mistaken for purulent ophthalmia, and the patient subjected to much alarm and very unnecessarily harsh treatment,

* *Practical Work*, vol. i. p. 436.

† *Blepharophthalmitis idiopathica*, BEER, vol. i. § 291. *Blepharitis idiopathica*, JUENGKEN, p. 144.

came under our observation which we will briefly notice as a caution to practitioners.

We were requested by a medical friend to visit with him a young lady who he stated was laboring under violent purulent ophthalmia which had resisted several large bleedings, and the most active antiphlogistic measures, and he feared that she would lose her eye.

We found the affected lid of a dark red color, greatly swollen, hot, and painful; the lids encrusted with matter and the patient unable to separate them to the smallest extent. At this period there certainly was a sufficient resemblance to purulent ophthalmia to mislead an incautious practitioner. Upon examining the lid, however, fluctuation, was at once detected. An incision was made with a bistoury, about two drachms of pus evacuated, and in a few minutes the patient was able to separate her lids, and to her great delight assure herself of the safety of her eye. With the exception of slight redness, this organ was entirely unaffected. In a few days the abscess healed, and a cure was effected without the least deformity.]

Erysipelatous inflammation of the eye-lids.—In erysipelas the palpebræ suffer in common with the rest of the face; the disease indeed often begins about the eye. The integuments are more or less reddened, and the lids are swelled from serous effusion into the sub-cutaneous cellular tissue. As that tissue is abundant, the swelling is often considerable, so as to close the eyes, with great inconvenience and sometimes alarm to the patient. The disease goes through its course and ends in resolution, with or without the previous formation of bullæ from effusion under the cuticle. The inflammation may be more violent and proceed to suppuration and mortification of the cellular tissue. The purulent fluid, which is sometimes white and thin, sometimes yellowish and thicker, is infiltrated in the cellular tissue, which turns yellow and then loses its vitality.

In ordinary cases of erysipelas no local treatment is necessary for the palpebræ; at least cool or tepid ablution will suffice. If the inflammation should be considerable, with much heat and burning pain, blood may be abstracted locally by minute lancet punctures, the bleeding being encouraged by tepid sponging. The vessels are thus unloaded with considerable relief of the local distress, and the danger of suppuration and mortification is averted. The latter changes, which are attended with great suffering in the part, throbbing pain, and generally considerable constitutional disorder, are best remedied by free transverse incision through the affected textures, which not only immediately arrests the local disturbance, but prevent the extension of mischief by providing a free outlet for matter and slough.

Simple abscess of the eye-lids, which is not unfrequent in the decline of erysipelas, should be opened early by a transverse incision.

[*Carbuncle of the eye-lids.*—"This circumscribed, gangrenous inflammation of the cellular membrane," Dr. Mackenzie remarks, "is occasionally met with in the eye-lids. The swelling is of a dark red, or purple color, extremely hard, and attended by severe burning pain. Vesicles rise on its surface, occasioning intolerable itching. Ichorous matter is discharged, and the affected cellular membrane and skin becoming black and sloughy, at length fall out. The cavity left by the separation of the slough granulates and heals up.

Carbuncle occurs principally in old persons, whose constitutions have suffered from irregularities in diet.

Opium to relieve the pain; bark and wine, to support the strength; laxatives, and gentle diaphoretics, make up the general treatment.

An early and free incision into the tumour, most effectually relieves

the pain, allows the matter to escape, and promotes the separation of the slough. An emollient poultice is to be applied after the incision has been made, and continued till the cavity left by the slough has been filled up by granulation. The sore is then to be dressed with simple cerate."]

Œdema.—Serous effusion takes place into the cellular texture of the eye-lids, when inflammation exists in the neighborhood, either from accident or disease, especially if it proceed to suppuration. The lids sometimes swell considerably from trivial causes, such as the irritation of hordeolum, the bites or stings of insects, and the bites of leeches applied in the neighborhood. They are often enormously enlarged in inflammation of the lachrymal sac: the eyes are closed, as in erysipelas; and patients are sometimes alarmed by the fear of blindness, until the nature of the case is explained. This swelling, which constitutes the *œdema palpebrarum calidum* or *inflammatorium*, goes away as the cause which produced it subsides. The lids are swelled, but not so considerably, in anasarca of the face (*œdema frigidum* or *chronicum.*) If this kind of swelling or the preceding were troublesome, especially by closing the lids, the serous fluid might be let out by a small puncture.

Emphysema of the eye-lids may arise from injury of the lachrymal sac, or from fracture of the bony parietes of the nose or nasal sinuses in the vicinity of the orbit. The swelling has not been considerable in any case within my observation, and has soon disappeared.

Ophthalmia tarsi.—In the cases hitherto described, the integuments and cellular texture of the palpebræ are the seat of disease: in catarrhal inflammation of the lids, which will be next spoken of, the mucous membrane is affected. There is another inflammatory affection of these organs, in which the mucous membrane, the tarsal cartilage and glands, and the ciliary margin are involved, to which the old name of *ophthalmia tarsi* is not inappropriate. The edge and the neighboring part of the lid are swelled, bright red, and extremely painful; the palpebral conjunctiva is of a scarlet color, and villous. If the lids are moved, an acute pricking sensation is experienced, with a sensation as if there were sand in the eye; hence they are kept closed and at rest. There is lachrymation, with more or less intolerance of light, and feverish disturbance of the system. The ciliary margins, at first dry, become moistened by increased mucous secretion, and are more or less firmly agglutinated in the morning. In a severe attack of this disorder, especially if it affect both eyes, active antiphlogistic treatment may be required. I have found cupping, and even venesection, necessary under such circumstances. In the early stage, cold lotions with mild unctuous applications to the ciliary margins are best; sometimes tepid ablution, or steaming the eyes, is found most agreeable. When the active inflammation is subdued, the case must be treated in the same way as lippitudo.

Repeated attacks of this inflammation seriously affect the tarsal cartilages, causing them to contract and turn inwards, and thus sometimes producing trichiasis or entropium.

*Catarrhal inflammation of the eye-lids.**—The propriety of describing this as a distinct affection from the preceding may be doubted. The seat of disease and the symptoms are partly the same in the two cases. In the former, the textures of the lid are more generally involved; while in this affection the disorder is confined to the ciliary margin and the mucous lining.

* Beer calls this affection *Blepharophthalmitis glandulosa idiopathica*, that is, idiopathic inflammation of the glands of the eye-lids. *Lehre*, vol. i. p. 284. It appears to me that the mucous membrane is the primary seat of disease, and that the Meibomian glands are affected secondarily.

In its active form, the catarrhal affection begins with dryness, soreness, smarting, burning of the ciliary margins, which are red, a little swelled, and painful, sometimes acutely so. The angles are generally affected first, or principally; they may suffer alone, or the whole margin may be inflamed, the palpebral conjunctiva is red, perhaps a little thickened and villous. Uneasiness is experienced on motion, with a sense of stiffness or dryness, and the feeling of a foreign body in the eye; hence, in an acute attack, the lids are kept closed and quiet. Employment of the eye, as in reading or writing, particularly before the fire, and exposure to strong light and heat, bring on pain with lachrymation and confusion of sight. Mucous discharge soon takes place from the inflamed membrane, and the pain is then succeeded by itching. The Meibomian glands participate in the affection, which begins on the ciliary margin of the lids, in the thin and delicate skin perforated by the ducts of these glands, which are themselves in close contact with the inflamed membrane. They no longer pour out the mild unctuous matter, which usually smears and softens the edges of the lids, but their secretion is suspended, so that in the morning the ciliary margins are stuck together by the increased conjunctival discharge, which has become incrusted by the evaporation of its watery part during the night. In this way the lids are often so firmly agglutinated as to require bathing with warm water before they can be parted. When the Meibomian secretion is renewed, it is altered in quality, being viscid, and thus assisting in causing the palpebræ to stick together. This morbid secretion, spread over the cornea, affects its polish and transparency, as glass is rendered dull by extraneous impurities; hence vision is impaired, and often considerably, alarming patients for their sight, and making them ask for something to clear it. Hence frequent attempts are made to clear the cornea by moving the lids; hence, too, when vision becomes worse in the evening, exacerbation of the symptoms, rings, haloes, and the irides, are seen round the candle, or its flame splits into stars. At the same time the uneasiness, smarting, or itching, the stiffness, redness, and mucous secretion are increased.

The ciliary margins lose their cuticular covering, and become raw, with further changes of the Meibomian and conjunctival secretions. These irritate the lids and excoriate them externally, particularly towards the angles, and the lower lid more especially, which is often entirely deprived of its cuticle, and even ulcerated. This, which is the chronic form of the complaint, and called *lippitudo*, often lasts for many weeks, months, or even years; recurring on the application of slight causes, whether external or internal; often originating insensibly and advancing slowly, without any marked acute stage; leading to thickening of the lids, especially of the mucous lining of the lower, and consequent ectropium of that lid, and to loss of the cilia. The affection commonly begins, and is usually most conspicuous towards the angles of the eye: hence the expression *lippitudo angularis*. The affection presents no peculiarity of character in elderly persons to justify the appellation of *lippitudo senilis*.

The lower lid suffers more than the upper, especially in the chronic stage; its edge and cutaneous surface being irritated and excoriated by the increased and morbid secretions.

Causes.—Catarrhal affections of the lids are frequent, and easily explicable; beginning in the ciliary margin, where the thin and vascular membrane is constantly exposed to atmospheric influence, and to the irritation of unhealthy secretions lodging and incrusting about the eye. According to Beer, catarrhal inflammation of the lids appears occasionally at Vienna, almost in an epidemic form, under the prevalence of cold drying winds at

a particular season of the year.* Although we do not see cases here in such abundance as he speaks of, they occur in so much greater number in cold and wet weather, particularly in the long prevalence of cold winds, as to indicate their atmospherical origin.

But inflammation of the lids, (*ophthalmia tarsi*,) not essentially distinguishable from the catarrhal, is often produced by other causes; by any irritation applied to the ciliary margins, especially in persons of fair complexion, thin skin, and what is called a lax fibre. Thus it may be caused by residence in close confined air and smoky apartments; by sitting up at night in close chambers; by confinement in-doors; by much employment of the organ by candle-light; by exposure of it to vapor, smoke, and other irritants. The operation of such causes is aided and increased by neglect of personal cleanliness, indulgence in fermented liquors, particularly of the stronger kind, by other imprudences in regimen, and by inattention to the state of the bowels. Hence it is common in nurses, washerwomen, and many of the middling and lower classes, becoming at last, from long exposure to the exciting causes, inveterate and habitual.

The treatment, in the acute or incipient stage, must be of a mild antiphlogistic character. Leeches may be necessary to the lids, with tepid lotions, mild ointments, and active aperients: afterwards alteratives and mild purgatives may be administered. The organ must be rested, and the exciting causes removed.

As soon as the active symptoms are removed, astringents and stimulants are not only advantageous but necessary. Scarification is most applicable to this form of complaint; the lids should be inverted, and the shoulder of the lancet drawn along at a single stroke, from one end to the other. The vinum opii, and the metallic salts in solution may be employed. One grain of the oxymuriate of mercury in eight ounces of rose-water, makes a useful mild collyrium. The liquor aluminis compositus of the London Pharmacopœia, diluted with six, five, or four times its quantity of rose-water; or a solution of the acetate of zinc may be used for the same purpose; but the greatest benefit is derived from stimulating ointments applied to the ciliary margins of the lids. When thus used, they correct the Meibomian secretion, and relieve the patient from the very troublesome agglutination of the lids. The unguentum hydrargyri nitratis, or the citrine ointment, as it is called from its yellow color, is the best of these. Having gently melted it in the flame of a candle, take up a little of it with a small camel-hair pencil; carry the pencil two or three times through the flame of the candle that the ointment may be perfectly liquid; then draw it once along the edge of each lid, taking care that the application shall be confined to the ciliary margin. When applied in this way, the ointment causes a sensation of heat or even burning, with smarting or pain, and a copious flow of tears. The patient cannot open the eye; and he should keep it closed till the effect has completely gone off: he will then feel much relieved. Sometimes it may be advisable to introduce a drop of the vinum opii between the lids previously. The red precipitate ointment (ung. hydrargyri nitrico-oxydi) may be used in the same way. In its mild form, that is with one grain to one dram of spermaceti cerate, this ointment may be applied at night, from the commencement of the affection. If the patient or an ordinary attendant should apply either the citrine or red precipitate ointment, the strength should be reduced one-half, two-thirds, or three-quarters.†

* *Lehre*, vol. i. p. 301.

† The red precipitate ointment of the London Pharmacopœia, containing one dram of the precipitate to one ounce of the vehicle, is too strong for the eyes. Mr. Mackenzie allows only twelve grains to the ounce, increasing it in some cases to twenty.

Much more benefit however, is derived from the citrine ointment of full strength, when used in the way above described by the surgeon, or a person properly instructed. The ointment of JANIN, so much recommended by SCARPA and other foreign writers, is a composition of inferior efficacy; it is made of white precipitate, ʒss; armenian bole and tutty, of each ʒj; lard, ʒij. The active ingredient in SINGLETON's, or the golden ointment, is stated by Dr. PARIS* to be orpiment (*auripigmentum, sulphuret of arsenic.*)

[Iodine and kreasote ointments are useful in some cases but we have found the Ung. hydrargyri rub. of the London Pharmacopiæ of 1787 the most efficacious.]

These stimulating local applications must not be used in an early period of the complaint; they would aggravate the inflammation; nor should they be employed when the eye is inflamed, however long the affection may have lasted. The antiphlogistic treatment must precede in such a case. If our stimuli irritate, they should be laid aside, and mild local applications should be substituted.

The complaint is often tedious, lasting for months, or even years, sometimes better and sometimes worse. It is aggravated by cold and damp weather, and by cold winds; by excessive exertion of the organ, as in reading small print, in writing, particularly by candle-light. They who suffer from it should avoid costiveness, take fermented liquors sparingly, avoid hot rooms, and not expose the eyes to strong lights or large fires.

Inflammation of the eye-lids is sometimes seen in mild degree and chronic form from the commencement. The redness and swelling are inconsiderable; yet there is troublesome tingling and itching, more or less uneasiness, perhaps with redness and watering when the eyes are used at night, and agglutination of the margins in the morning. Mr. WARE called the affection in this form *psorophthalmia;* it has also been called *lippitudo pruriginosa.* The same local treatment must be employed as in lippitudo; and we use the same means when there is a sense of dryness and stiffness in the eye, with uneasiness of the lids at their margin, although there should be neither swelling nor redness.

Scrofulous imflammation of the eye-lids.—Thickening and redness of the ciliary margins are common in the scrofulous, and are habitual in some subjects, so that they are not regarded as disease. Strumous ophthalmia frequently begins with inflammation of the lids; and the latter affection, in a more or less active form, characterized by the symptoms already described, accompanied by the frequent occurrence of hordeola, and often causing, when neglected, ulceration, enlargement, induration, and irregularity in the figure of the affected part, with partial or general loss of the cilia, is common in the scrofulous. It must be treated, locally and generally, according to the principles already explained as applicable to common inflammation of the lids, and strumous ophthalmia.

Inflammation of the eye-lids with ulceration; blepharophthalmia ulcerosa; ophthalmia psorica; tinea of the eye-lids.—The edges of the lids swell and become red in children, with great pain and itching. Pustules like those

(*Practical Treatise*, p. 138.) JUENGKEN considers from one to two grains to two drams of ointment strong enough, when it is to be introduced into the eye; one or two grains may be added, when it is used to the lids only.—*Lehre von den Augenkrankheiten;* p. 936.

The German writers direct the red precipitate to be mixed with fresh butter, which is unfit for the purpose from its soft consistence, and soon turning rancid. JUENGKEN advises a mixture of hog's lard and wax, similar to that directed in the London Pharmacopœia. Ibid. p. 903.

* *Pharmacologia*, vol. ii. p. 99.

of tinea form on the inflamed part, particularly about the roots of the cilia. These break and pour out a yellowish matter, concreting into more or less firm yellow or brownish scabs, which mat together the cilia, and sometimes adhere very closely to the surface. As this affection is seated along the roots of the cilia, it affects their growth, altering their form and direction. The ulcerations extend deeper and deeper, and at last destroy the bulbs of the cilia, which come away with the scabs.*

The Germans regard this disease as itch of the eye-lids, and they employ the terms *psorophthalmy* and *ophthalmia psorica*† in that sense. They consider that it may be produced by immediately applying the contents of the vesicles or pustules of itch to the eye-lids, or that it may come on when itch has been suddenly cured. I do not consider that there is any connexion between this disease and scabies, or that there is any analogy between them, except in the circumstance of itching, which is common to both. I have seen innumerable cases of itch in its most aggravated form, but have never met with inflammation either of the eye or lids in such instances, either during or subsequent to the eruption. When the body has been covered with scabies to the greatest degree, I never saw any kind of ophthalmic disease attributable to this cause; indeed it is well known that the head and face are nearly exempt from this loathsome disorder. Nor has the rapid cure of itch by suitable treatment, in instances of its most extensive prevalence, had any injurious effect within my experience.

Treatment.—Antiphlogistic means and mild local applications are necessary in the first instance; astringents and stimulating ointments, particularly in the latter, are proper subsequently.

[Inflammation of the eye-lids, producing that state termed *blear eyes*, when from neglect or improper treatment it has been allowed to run on until the conjunctiva has become thickened, the edges of the lids ulcerated and thickened, the eye-lashes inverted and misplaced, and especially when it occurs in strumous children and is complicated with *Porrigo larvalis or favosa*, is among the most troublesome and obstinate affections which the practitioner has to treat.

Simple inflammation of the lids, without any disorganization, yields promptly to laxatives, a light, nutritious diet, and the application to the lids of the red precipitate ointment prepared according to the London Pharmacopœia of 1787. The laxative which we have found to answer best, is a mixture of equal parts of rhubarb and prepared oyster shells, given night and morning or every night, in doses sufficient to produce two stools daily. Equal parts of cream of Tartar and milk of Sulphur, forms also an excellent laxative, and we often prescribe this and the former combination alternately, each being continued for a week or two at a time. Under this treatment, cases have been cured in a few weeks which had run on for years,—in one case for nineteen years.

When the conjunctiva is thickened, the lids ulcerated and their margins swollen and rounded off instead of being angular (tylosis,) the Meibomian apertures obliterated, the eye-lashes inverted (trichiasis) or misplaced (distichiasis,) other remedies are required, and in addition to those

* When the ciliary margins are considerably swelled, and numerous pustules have formed on them, the appearance has been compared to that presented by the section of a fig.: hence the terms *sycosis*, *palpebra ficosa*.

† Beer, *Lehre*, vol. i. p. 565. Benedict, *Handbuch*, vol. ii. p. 131. Rosas, *Handbuch*, vol. ii. p. 242. He calls it *conjunctivitis psorica*. Juengken, p. 298. He says, "it is true itch of the eye-lids, fixing its seat particularly in their external surface, and characterized by scabious pustules and ulcers. It is rare, and only seen in the lowest class; in Poland and Lithuania it is more frequent."

recommended by Mr. Lawrence we invite attention to the following measures which we conceive to be of great importance.

1st. The lids, if possible, should be prevented becoming agglutinated during the night, or if this cannot be accomplished, they should never be separated in the morning until the matter by which they are glued together is completely softened. By forcing the lids open, the irritation is kept up and the disease perpetuated and daily aggravated. The first indication may be generally fulfilled by carefully applying to the roots of the eye-lashes at bed-time some mild ointment, as a little spermaceti cerate or weak ung. plumbi: and at the proper stage by the red precipitate or some of the other stimulant ointments. Should these fail, the agglutinating matter ought to be softened in the morning by tepid milk and water, or as recommended by Dr. Mackenzie by gently smearing for some minutes the agglutinated eye-lashes with milk in which a bit of fresh butter has been melted, and then holding to the eye-lids a piece of soft sponge wrung out of warm water. The crust should then be carefully removed.

2d. If the vessels of the thickened conjunctiva are much engorged, occasional scarifications will be useful. After they have been relieved by this treatment, or by leeches to the temples, or behind the ears, not to the lids as usually recommended, the application every four or five days of the sulphate of copper in substance will be found highly useful.

3d. The lids should be carefully examined every few days with a magnifying glass and all inverted hairs removed. The best method of accomplishing this will be described under the head of *Trichiasis*. These hairs are a source of great distress to the patient; they keep up irritation, and if not removed they ultimately induce inflammation and opacity of the cornea.

4th. When the lids are ulcerated, touching them occasionally with solid nitrate of silver promotes the healing of the ulcers. Quadri of Naples recommends, when the lids are greatly thickened and indurated, their edges much incrusted and the roots of the eye-lashes ulcerated, that the eye-lashes be all extracted, and the whole diseased surface then lightly touched with a pencil of lunar caustic. He repeats the caustic in a few days, and in the interval bathes the parts with brandy at first diluted and then undiluted.*

5th. Counter-irritation to the back of the neck, behind the ears, or to the arm, will often be found of great value. It may be effected by repeated blisters, an issue or a seton, croton oil, or tartar emetic ointment.

6th. In strumous patients tonics and alteratives are often demanded. The best are the sulphate of quinine alone or combined with the carbonate of iron, the mineral acids, and what we have used with particular advantage the sirup of hydriodate of iron.

7th. Pure air. This is a most important tonic, and with proper exercise is often essential to a cure. A large and cool sleeping apartment is also of the first importance. The atmosphere of rooms in which many persons are assembled is extremely injurious, and patients should therefore never go to large parties, to the theatre, or similar places, whilst laboring under this affection.

8th. Bathing, warm or cold, as may best agree with the patient, and especially salt baths are very useful.

9th. The diet should be strictly regulated; and should consist of milk with eggs, and the more easily digestible meats once a-day, and care must

* Mackenzie's Treatise, p. 145.

be taken that the evening meal be very light so that the stomach may not be overloaded at bed-time.

10th. The clothing should be attended to and so regulated as to protect the patient from the impression of cold.

Meibomian Calculus.—Calcareous matter is sometimes deposited in the Meibomian glands, forming calculi, which elevate the palpebral conjunctiva, sometimes penetrate it and rubbing against the eye cause inflammation. They may easily be removed by laying open the glands with a knife, and then lifting out the calculus with a probe or cataract needle.*]

Hordeolum, or *stye*, is a small, rather firm, inflammatory tumour, bright red, and generally very painful, formed in the ciliary margin of the lid. It may be situated more towards the external or internal surface, and hence the distinction of *external* and *internal hordeolum*. A small conical elevation takes place, which, after a time, shows a whitish point in the centre; suppuration has occurred; and the contained matter makes its way out. This inflammation is generally attended with the formation of a small slough; it is a boil in miniature. The density of the texture explains the acute pain attendant on this form of disease, and the extension of the redness in some cases over the whole lid. The process of suppuration is not quick, and when it has taken place, ulceration slowly follows, and the slough gradually makes its way out. Some hordeola form more quickly, with greater suppuration and no slough; but, generally speaking, they are slow, and several occur in succession in scrofulous individuals (*hordeolum scrofulosum.*) In such constitutions the inflammatory process is sometimes very chronic, and leads to enlargement and induration, rather than suppuration.

Treatment.—We may perhaps prevent suppuration in the very outset by the use of purgatives and cold lotions to the part. In general, however, the boil goes through its regular course. Tepid fomentation, or the softest bread and milk poultice, will suit best while matter is forming and coming to the surface. Leeches and active aperients may be necessary if the inflammation runs high. If suppuration has decidedly occurred, and the local uneasiness continues, relief may be afforded by puncturing the part. A premature puncture is injurious, as in case of boils; and in general it is best to leave the disease to its natural course. When the inflammation has subsided, a mild course of alterative and aperient medicine, with attention to diet, and the local employment of the citrine or red precipitate ointment, will be advisable in scrofulous subjects, as measures of prevention. If the inflammation is stationary, the removal of the swelling may be hastened by touching it with the nitrate of silver.

Beer mentions that the prognosis is always very unfavorable in scrofulous hordeolum; that it may lead to true carbuncle or anthrax, and thus to destruction of the eyelid, or to scirrhous induration and cancer.† I never saw such effects, and consider these dangers purely imaginary.

Secondary inflammations of the palpebræ.—The eyelids are involved in external inflammation of the globe; that is, in common, catarrhal, purulent and strumous ophthalmiæ. We do not see a severe case of these affections, particularly of the first three, without more or less inflammation of the lids, while in many cases, the redness, swelling, and pain of the latter. Hence, from the condition of the lids we may derive information respecting the state of the eye, where we cannot actually see the latter are considerable. This influence is not reciprocal: the more important organ acts on the subordinate parts, but the latter do not react on it. The conjunctiva is only a little reddened in erysipelatous inflammation of the lids, although they

* Mackenzie's Treatise, p. 150.

† *Lehre*, vol. i. § 585, 586.

are often enormously swollen, or bright red, with the cellular tissue in a state of purulent infiltration and mortification. The same observation holds good in most cases of variolous and traumatic inflammations of the lids. They do not become inflamed in the internal ophthalmiæ; that is, if the disorder is confined to the internal tunics.

*Thickening and induration of the palpebral margins; tylosis.**—The ciliary margins, after long continued slow inflammation, become thickened, indurated, and knotty, especially in the scrofulous. They ulcerate irregularly, and incrustations form about the lashes, which are often partially or generally detached. This swollen and knotty state of the lids, in which their margin often loses altogether its natural figure and appearance has been technically called *tylosis*. In this state, or in aggravated cases of tinea, where the eye-lashes are loosened, and the ulcerated margins of the lids are covered by hard incrustations, which, together with the cilia, prevent the application of remedies to the seat of disease, the best plan of treatment is to extract all the cilia, with a pair of broad forceps, and then touch the thickened and irregular ulcerated surface lightly with a pencil of lunar caustic. This has a great effect in healing the ulcerations and dispersing the swelling. The citrine ointment should be used afterwards, and the caustic may be repeated in a few days, if necessary; a single application, however, is often sufficient.

Loss of the eye-lashes, (*ptilosis, madarosis, alopecia.*)—Destruction of the bulbs by ulceration or by injury causes permanent loss of the cilia, which may be either total or partial. It is a frequent result of smallpox, the pustules of which, besides partially destroying the lashes, leave reddish marks of unpleasant appearance on the margin of the lids, with disposition to inflammation. The loss is irremediable; but when the disorder which caused it has completely ceased, the effect on personal appearance is much less than would have been expected, especially when it has been total: the partial loss is more conspicuous. The entire absence of cilia is sometimes hardly observed, especially in those of light hair; while, at least in many instances, it is not attended with the slightest inconvenience. The latter observation was exemplified in a lady, in whom the eye-lashes had fallen out without disease of the lids, the hair having at the same time disappeared from all parts of the body without any apparent cause.

I saw a young lady in whom the lashes of one upper eye-lid had dropped out without previous inflammation, or any other ascertainable change in the part. My opinion was that they would not be reproduced; but I recommended the trial of a stimulating ointment, and the ung. hydrarg. nitrat. in a dilute form was consequently employed. After the lapse of some months the hair again appeared, and were ultimately restored, of natural size, color, and number.

The cilia are reproduced after being plucked out, and that very speedily; a circumstance which is found very inconvenient by those affected with trichiasis. We may therefore safely remove them in ulcerative affections of the lids. Such removal indeed, by facilitating the application of suitable remedies to the ulcerations, prevents them from proceeding to destruction of the bulbs, and consequent permanent loss of the cilia.

* This word is formed from τυλος, *callosity*. The words *pachyblepharosis*, *pachea*, *blephara*, and *pachytes*, denote the enlarged and thickened state of the lids. *Ptilosis*, which originally means the moulting of birds, has been applied to this disease, which is attended with loss of the cilia.

SECTION III.—ULCERATIONS.

Syphilitic diseases of the palpebræ.—As integument and mucous membrane, the most frequent seats of syphilitic disease, enter into the composition of the eye-lids, we may expect to find these parts often suffering in syphilis. Syphilitic eruptions, particularly the scaly and tubercular, frequently appear on the external surface, and on the ciliary margins of the lids; and the latter are almost always red, excoriated, and sore (*lippitudo syphilitica neonatorum,*) in that form of syphilis, which is imparted to the infant by a diseased mother or nurse, where the disease is almost confined to the skin.

The mucous lining of the palpebræ sometimes participates in the syphilitic eruptions, which affect the surface generally; but this does not happen so often as we might have expected from observing the correspondence in diseased action between the conjunctiva and integuments. In a case of syphilitic iritis, where there was papular eruption, papulæ were observed on the internal surface of the eye-lids. A gentleman was under my care some years ago with papular eruption over the whole body, following chancre. The pimples were large, bright red, and proceeded to suppuration on their summits, then dried up, leaving red marks, which were conspicuous for a long time. There was great feverishness, with pain in the side. The eruption extended to the mucous lining of the palpebræ, in which there were several pustules as large as pins' heads, with swelling and redness of the palpebræ, and considerable local uneasiness. The affection of the lids required merely cooling and tepid lotions. The eruption, which occurred in March, lasted six weeks. The marks of the papula were still very visible in the face in August; at which time some scaly eruptions appeared on the legs, with considerable inflammation. The left upper lid was still red, and rather swelled, the conjunctival lining red and thickened, and the marks of the former papulæ very evident. No other means were employed in this case except active antiphlogistic treatment, including two venesections. This gentleman has continued well to the present time.

In a patient, who was twice in St. Bartholomew's Hospital under my care, first for primary phagedenic ulceration of the labia, and one nympha, and subsequently for tubercular eruption chiefly affecting the face, and node of the tibia, the upper eye-lid of one eye became swelled on the second occasion. It is stated in notes which I have of the case, that an "eruption of small pustules was observed upon the lining of the upper eye-lid, which was swollen." I cannot describe the appearances exactly, not recollecting the particulars of the case, which occurred in 1825 and 1826. She took calomel and opium freely, under which all her symptoms quickly disappeared, and she was discharged cured.

Syphilitic ulceration of the eye-lids.—Although this is not of very rare occurrence, it is not particularly noticed in any of the works on syphilis with which I am acquainted. As it sometimes proceeds to the destruction of the lid, it is of consequence that the character, progress, and treatment of the affection should be understood.

My attention was first attracted to the subject many years ago, by a case which came under my care in St. Bartholomew's Hospital.

A stout red-faced woman, of full habit, who had been long on the town, was admitted on account of an ulcer, which had nearly destroyed the lower eye-lid. The surface was greyish with bloody points, and the edge towards the cheek livid and sloughy; the discharge ichorous. The neighboring integument to a considerable distance was highly inflamed, and the side of

the face was generally swelled. The sore and the surrounding parts were acutely painful, so as entirely to prevent rest. No eruption or ulceration existed in any other part of the body, nor was there any other local affection. Having neither heard nor read of such cases, I did not entertain any suspicion of the disease being venereal, and attempted to arrest its progress by leeches, fomentation, poultice, and opium. During the employment of these measures, which were altogether ineffectual, the destruction of the lid was completed. I now had recourse to the free administration of calomel with opium, which quickly affected the mouth. The pain immediately ceased, the inflammation of the ulcer and of the surrounding parts was arrested: in two or three days the sore acquired a healthy surface, and cicatrization soon followed. Although this patient had no other venereal disease at the time, and said she had not recently been affected with syphilis, I entertain no doubt at present that the ulceration of the eye-lid was syphilitic.

Soon afterwards I had under my care, at the Eye Infirmary, in Charterhouse Square, a youth under twenty years of age, in whom a chronic ulceration had slowly destroyed about one-half of one lower eye-lid, the other being affected on its margin by a smaller superficial ulceration of similar character. In this case there was an excavated ulcer with tawny surface, and no surrounding inflammation, in each tonsil. The characters of the disease were here so strongly marked, that I could give no credit to the representation of the patient that he had never had venereal disease. The compound decoction of sarsaparilla, with the oxymuriate of mercury, was administered in this case. The ulcerations of the throat soon disappeared; but those of the eye-lids were more obstinate, and did not yield till the mouth was affected, when they slowly cicatrized. A relapse of the palpebral affection occurred in this patient, who was a tailor; the use of mercury was again required, and proved effectual.

In the last few years I have met with several instances of syphilitic ulceration affecting the eye-lids, and have thus learned that the character and progress of such sores are various in this as in other parts of the body.

The ulcer, commencing on the ciliary margin, where it is generally described as beginning with a small hardness, supposed to be a stye, may occupy the whole thickness of the lid, involving all its textures. It may have the same origin, and be confined to the external surface of the lid; or it may arise on the mucous surface, and never extend beyond that. In a patient who had syphilitic ulcers in several parts of the body, with periosteal swellings, I observed that the left upper eye-lid was red and swollen, and proceeded to evert it, when I discovered on the inner surface a sore as large as a sixpence, with a tawny surface: it did not reach the edge of the lid. I have also seen several smaller sores at the same time in the mucous lining of both upper lids.

The ulceration is sometimes acute, attended with inflammation and great pain; and it rapidly destroys the affected part. In a case, where the eye-lids were twice affected, two-thirds of the lower lid were destroyed on the second occasion in about five days. On the contrary, in another instance, there was but little inflammation or pain, and although the disease had existed for two months before treatment was begun, the cure was accomplished almost without loss of substance. The characters of the sore will of course be very different in the two instances. The acute ulceration is of the phagedenic character, with red margin, sharp edge, foul unequal surface, on which bloody points are seen, and severe pain. In the chronic, there is swelling and some hardness of the basis of the sore, with expansion of the cutaneous texture instead of loss of substance, and little or no pain.

Ulceration of the eye-lid generally occurs in conjunction with other syphilitic symptoms, such as ulcers in other parts of the body, and swelling of the bones or periosteum. In one patient the affection of the lid was the only secondary symptom for about two months, at the end of which time scaly eruption appeared. In two other instances, the eye-lid was the only part affected. I was consulted some years ago by a gentleman, of whose case I did not make any notes. He had a large ulcer, with dirty whitish surface, on the lining of the upper eye-lid. The character of the sore, and the circumstance of his being otherwise in excellent health, made me conclude that it was venereal, though he had no other symptom, and stated that he had not been affected with syphilis for a long time; if my memory is correct, not for three or four years. The sore healed under the use of mercury and sarsaparilla.

In some instances of entire destruction of the lower eye-lid there has been no conspicuous deformity, and the patients have experienced no inconvenience after cicatrization was completed. The loss could not be discovered without close inspection; and when the eye was shut, the descent of the upper lid covered the globe.

No other ulcerative affection of the palpebræ can be confounded with that now described by any person who pays even slight attention to the character and progress of the disease. The ulcers called cancerous begin, at least in the great majority of instances, in the integument, and are for a long time confined to it, not reaching the ciliary margin or mucous surface until the disease has made some progress. The affection has two stages, the tubercular and the ulcerative. It begins with the formation of small, hard, and scarcely discolored tubercles in the skin; ulceration does not take place till these have existed many months or even some years; it proceeds slowly, the edge of the ulcer being hard, and tuberculated, and several years will elapse without any great progress. The ulcer is superficial, producing in small quantity a thin discharge which forms an adherent scale on the surface. These cancerous ulcerations do not occur until the middle period of life, or after it. Besides the difference of age, and the entirely different origin, development, character, and progress of syphilitic ulceration, the history of the case and the concomitant existence of other syphilitic symptoms would remove all doubt respecting the nature of the affection.

Treatment.—I have found the free use of mercury to be the quickest and most effectual mode of arresting and curing the disease. This remedy has been employed with the best effect in all the cases which have come under my observation. As soon as its influence on the system has been produced, the sores have lost their syphilitic character and then quickly healed. Having found the desired purpose so completely answered by this plan of treatment, I have not been willing to make the experiment, which has been tried with other syphilitic ulcerations, of leaving them to their own progress, or trusting to sarsaparilla and other remedies. The loss of substance which might occur under this mode of proceeding, would be attended with serious deformity in the case of the upper eye-lid.

CANCER OF THE LOWER EYE-LID.

The skin of the face, more particularly of the lower eye-lid, cheek, nose, and lips, is not unfrequently the seat of cancerous disease, which exhibits in this, as in other textures, the successive occurrence and combination of two morbid changes; namely, *induration* and *ulceration*, the

latter being intractable, and little affected by external and internal remedies, if not absolutely incurable by such means. This affection, like others of similar nature, seldom shows itself before the middle period of life. I have seen it affecting the eye-lid only in the male sex: in two out of three cases mentioned by Dr. Jacob, the patients were females.* The same affection, in other parts of the face, has been much less frequent in the female than in the male, within my experience.

A hard knot at first forms in the skin, not discolored, and rising a little above the surface. The patient calls it a wart, but the entire and natural state of the cuticle obviously distinguishes this scirrhous tubercle from warts, of which the cuticular covering is thick, rough, and fissured. The first tubercle is slowly followed by others, which make with it a single small group or mass; they are equal in size to small peas or large pins' heads. The portion of skin, on which they are situated, is somewhat swelled and hard: a few red vessels are sometimes seen on it and on the tubercles, which in other respects present the natural appearance of skin. After some time, superficial ulceration occurs, the denuded surface appears as a mere excoriation, producing a thin yellow fluid in small quantity, which dries into a thin scale. If this is not disturbed, the part will remain for a long time without any apparent change. The disease spreads in the same manner, by the formation of cutaneous tubercles and ulceration, the process being so extremely slow, that many years often elapse without the ulcer exceeding the magnitude of a sixpence or a shilling. In this state it presents a superficial ulceration, smooth, and without granulations, with an irregular knotted margin. It is at first confined to the cutaneous surface of the eye-lid, and it often remains so for several years; in other instances, when it has reached the ciliary margin, it slowly destroys the whole thickness of the lid by ulceration, and makes its way into the orbit between the globe and the bone. In its early period, and indolent state, it causes little or no pain. When the ulcerative process is more active, the complaint is painful; there is often considerable uneasiness from irritation of the globe by the edge of the ulcer when it is destroying the lid. The health does not suffer, being often unimpaired even when the ulcer has attained considerable magnitude.

The lymphatic glands are not affected; nor have I ever seen secondary cancerous affection of other parts.

Although the progress of the disease, taken generally, may be called destructive, there is sometimes partial reparation and cicatrization. The surface thus restored is generally irregular, and not like a healthy cicatrix: and, while cicatrization is proceeding in one part, the disease extends in other directions. I had a patient, about forty years of age, with an ulcer of this kind about one inch and a-half in length, and three-quarters of an inch wide, on the cheek, at the side of the nose. The complaint, which had lasted six years, began on the ala nasi, of which it had destroyed a considerable portion. The part first affected had cicatrized soundly, and the sore still had a healing edge on the side next the nose. The margin in other parts was indurated and irregularly elevated; the surface was not deep; it was smooth, red, without granulations, and it produced, in small quantity, a thin yellow matter, without any offensive odor. When I had extirpated this disease, I found that the basis of the ulcer was the cutaneous texture about twice its ordinary thickness; firm, of greyish color, and with the semi-transparency belonging to scirrhous induration.

* *Observations respecting an Ulcer of peculiar character, which attacks the Eye-lids and other parts of the face; in Dublin Hospital Reports*, vol. v. p. 232.

There can be no danger of confounding this complaint with syphilitic ulceration of the palpebræ, which I have described at p. 133. It is easily distinguished from lupus, which does not affect the eye-lids. The tubercles of lupus are larger, red, and scattered; sometimes the cuticle covering them becomes scaly. In carcinoma, the tubercle is at first single, and subsequently only a single group, unaltered in color, and without change of the cuticle. The ulceration of lupus has a tawny surface, often with bloody points or streaks secreting a yellow matter which forms yellow scabs; the margin is sharp and ragged, and the surrounding skin bright red. The carcinomatous ulcer has a smooth, red surface, and a knotted edge; and the surrounding skin is of the natural color.

Dr. Jacob, who, in a paper already quoted, has described this disease as he had seen it in three instances, considers that it "is peculiar in its nature, and not to be confounded with genuine carcinoma;" from which, he says, "it is distinguished by the absence of lancinating pain, fungous growth, fetor, slough, hemorrhage, or contamination of lymphatics."* If, by genuine carcinoma, Dr. Jacob means that of the female mammary gland, the correctness of his opinion will be allowed, though all the circumstances he has mentioned are not found in every case and stage of that disease. The present affection appears to me to be genuine carcinoma of the skin, and not to differ from the progress of the disease so called in other textures, more than the differences of organization will explain. The phenomena and progress of the affection are even modified in different parts of the integuments; it is different in the hands and in the organs of generation from the course which I have described it to pursue in the face, though it every where exhibits the same leading features of primary scirrhous induration and subsequent intractable ulceration.

Mr. Middlemore† has described this disease under the name of *peculiar ulceration of the eye-lids*, and has detailed some cases. Like Dr. Jacob, he regards it as distinct cancer.

The *causes* of this affection are involved in the same obscurity as those of cancerous diseases generally; we are altogether ignorant of the circumstances which either immediately or remotely give to morbid affections this peculiar character. Within my experience it has always occurred spontaneously in healthy subjects, and almost exclusively in males. Juengken,‡ on the contrary, states that it is more frequent in women than in men; that it is seldom seen as a pure idiopathic affection in individuals otherwise healthy; and in general it occurs only in cachectic subjects, and that a strong predisposition to the complaint is produced by certain cachexiæ and dyscrasiæ, particularly by scrophulosis, arthritis, and syphilis larvata. According to the representations of Beer,§ with whom Juengken,‖ Rosas,¶ and other writers** agree, scirrhus of the eye-lids may proceed from the chronic

* Lib. cit. p. 236, 237.

† *Treatise*, vol. ii. p. 744—755.

‡ *Lehre, von den Augenkrankheiten*, p. 603.

§ *Lehre*, vol. ii. p. 50 and 140.

‖ Loc. cit.

¶ Common warts may become cancerous from the supervention of a morbid state of constitution (*dyscrasia*,) or from mechanical and chemical irritation. *Handbuch*, vol. ii. p. 118. In another place he says, that cancerous ulcers of the lids depend on some hitherto imperfectly known malignant modification of scrofula, gout, or other dyscrasiæ; that they appear as consequences of encysted tumours, warts, or more frequently of scirrhus; and that the occasional causes are accidental, mechanical, or chemical injuries of the lids, or curative attempts with stimulating escharotic or even mechanical means. He adds, that in many cases no such immediate cause can be assigned. *Ibid.* p. 139.

** According to Sabatier, cancer of the lids and globe may arise from scirrhous tubercles, from pimples of dartrous character, from fungous excrescences, and from obstinate ophthalmia, terminating in partial or local abscesses. It is excited by the

swelling consequent on scrofulous inflammation, (*tylosis*, see p. 132,) or from the induration remaining after, hordeolum, especially when injudiciously treated, in scrofulous persons; while this scirrhous induration may degenerate into cancer when the scrofulous subjects laboring under it suffer from other causes, such as syphilis, itch, gout, or scurvy, or when irritating applications are made to the part. He states further, that in individuals who have long been highly scrofulous, destructive cancerous ulceration may attack the eye-lids from the repeated irritation of an encysted tumour by stimulating applications, or from the development and improper treatment of an inflamed, painful, and wart-like tubercle on the ciliary margin, (*papula maligna.**)

If the causes assigned by these writers were capable of producing cancer of the eye and lids, it ought to occur frequently; it is, on the contrary, a rare affection. To account for the wide difference between their statements and my own experience, I must conclude, either that scirrhus and cancer are much more common on the continent than in this country, or that they employ the terms in a more comprehensive sense than we do.

Treatment.—I consider excision to be the proper treatment, whenever the situation and extent of the disease will admit of its complete removal; and that it should embrace, not only all the parts altered in structure, but also, if possible, a portion of the surrounding healthy substance. As the health is undisturbed, no benefit can be expected from internal remedies. External irritating applications often bring on pain, and render ulceration more active. When the disease is of small extent, it may be destroyed by an escharotic sufficiently powerful to kill the whole affected texture; but this process is less satisfactory than excision, as I found in an instance where I destroyed a small growth of this kind on the ala nasi, by means of arsenic.

Dr. Jacob's experience on this point seems to coincide very nearly with my own. "It remains," he says, "to be determined whether this disease can be removed by any other means than the knife or powerful escharotics; and from the experience I have had in those cases, I am inclined to conclude that it bids defiance to all remedies short of extirpation. I have tried internally alterative mercurials, antimony, sarsaparilla, acids, cicuta, arsenic, iron, and other remedies; and locally, simple and compound poultices, ointments, and washes containing mercury, lead, zinc, copper, arsenic, sulphur, tar, cicuta, opium, belladonna, nitrate of silver, and acids, without arresting for a moment the progress of the disease. I have indeed observed that one of these cases which is completely neglected, and left without any other dressing than a piece of rag, is slower in its progress than another which has had all the resources of surgery exhausted upon it. The success even of powerful escharotics is doubtful. Mary Sherlock, the old woman who has labored under the disease for twenty-three years, and who is now in the incurable hospital, says that "a burning cancer plaster" was applied several times, seventeen years ago; and she has lately had the arsenical composition, called Plunkett's powder, applied without any good effect. The gentleman to whose case I have alluded, had the sore healed, when it was very small, by the free application of lunar caustic under the care of

imprudent use of acrid and irritating local applications, especially caustics, but it depends on an internal disposition, which can neither be prevented nor corrected. *De la Médecine opératoire*, 1821; vol. iii. p. 346. Analogous opinions respecting cancer of the eyes are delivered in the *Dictionaire de Méd. et de Chir. pratiques*, tom. iv. p. 536, 537. The writer assigns as causes of cancer of the eye, chronic inflammations, whether external or internal, and protrusions of the globe consequent on disease of the orbit or surrounding parts. * Lib. cit. p. 140—143.

Mr. Travers; it however broke out again and spread without interruption, until it destroyed the lids and globe of the eye, under which circumstances, he, in despair, submitted himself to a popular charlatan, who, bold and fearless from ignorance, gave a full trial to escharotics; he repeatedly applied what I understood to have been a solution of muriate of mercury in strong nitic acid, and in a short time excavated a hideous cavern, extending from the orbitar plate of the frontal bone above, to the floor of the maxillary sinus below, and from the ear on the outside of the septum narium within; yet the unfortunate gentleman survived, but the disease preserved in every respect its original character. Mr. Colles, however, tells me, that in a case which came under his care, before the disease had extended to the lids, he succeeded in establishing a permanent cure by the application of a powerful escharotic, covering up the eye, during the operation of the remedy, with goldbeater's leaf."*

We possess, however, some means of relief, even in the unfortunate cases, where the extent of mischief precludes the effectual remedy of extirpation. Mild antiphlogistic and soothing measures not only alleviate suffering, but sometimes induce restorative efforts more considerable than we could have expected, as will appear from a case subsequently related. (See Case IV.) The observations on the local and internal employment of narcotics, when there is severe pain, in the treatment of carcinoma of the eye, are equally applicable to this affection. The following histories are selected to exemplify the foregoing description and remarks.

Case I. *Carcinoma of the lower eye-lid, of seventeen years duration: extirpation of the disease, and permanent cure.*—A gentleman, between fifty and sixty years of age, employed in painting and drawing, had a disease of the lower eye-lid, which began seventeen years before I saw him, with what he called a small wart. It gave him no trouble, so that he paid little attention to it. Caustic was once applied; it produced a scab, and the surface afterwards became clear again. It had increased, and became troublesome in using the eye. The disease, when I first saw the patient, was about equal to half a large filbert, and occupied the inner two-thirds of the eye-lid. It reached at the internal angle to the root of the nose: the upper edge extended to the margin of the lid, where it seemed inseparably connected to the tarsus; below, it was movable on the subjacent parts. It was a swelling of the skin, knotty at the edge, with a few red vessels ramifying on it, and two or three small smooth ulcerated surfaces towards the centre, producing a clear yellowish fluid, which formed a thin adhering scab. I removed it in April, 1828, and found it easily separable from the tarsus, though they had appeared so closely united; the latter was denuded in its whole depth. The disease was strictly cutaneous, with a regularly defined circumference, not extending into the surrounding textures. Two small smooth cysts were found near the surface of the tumour. The wound was soundly healed in three weeks, without any other inconvenience than a slight degree of ectropium, which continues to the present time, (1840,) the cure in other respects being perfect.

Case II. *Carcinoma of the lower eye-lid, which had existed five years: extirpation, and permanent cure.*—The patient was a gentleman about fifty-five years of age, of sound constitution, and good health. The disease occupied the ciliary margin and the external surface of the lid. It began with the formation of small hard knots, on which a few red vessels ramified; superficial ulceration ensued, without much discharge. It had proceeded very slowly, so that at the end of five years it did not occupy the whole

* Lib. cit. p. 237, 238.

eye-lid. Various local and general means, employed at different times, had no effect in checking the progress of the complaint. He had used calamine cerate spread on thin rag, to cover the ulceration. Carbonate of iron, made into a paste with water, and applied with a fine brush, seemed to have afforded some relief. When I saw him, the disease occupied rather more than the inner two-thirds of the lid, reaching quite to the side of the nose; the inferior punctum lachrymale could not be discovered. The lid, more than twice its natural thickness, was knotted externally and ulcerated; the irregular inner margin of the ulceration occasionally irritated the globe. This was the only inconvenience, for the disease had never given much pain. I removed the parts in December, 1825, cutting quite clear of the disease below, and externally. It was so close, to the bone, on the inside, that I could not feel equally confident of having removed the whole morbid growth. A soft rag doubled and dipped in water was placed over the eye. The wound, although large, healed rapidly; and the patient was able to leave town in ten days. In February, 1826, the cicatrix was firm. Although the lower eye-lid, with its punctum lachrymale, had been removed, there was no deformity, nor any inconvenience from watering of the eye. This gentleman whom I have since seen at various times is perfectly well at present (1840.) No deformity, nor any other unpleasant result, remains from the operation.

Case. III. *Carcinomatous ulceration of the lower eye-lid; entirpation: return of the disease.*—G. S. fifty-five years of age, came under my care, in St. Bartholomew's Hospital, in January, 1829. The complaint, which was an ulceration of the lower eye-lid, with indurated margin, had begun seven years before, in what the patient called a small pimple. The disease extended to the internal angle, where the indurated mass adhered firmly to the bone, and it occupied also the whole external angle of the lids. It had been generally easy, but occasionally painful; various means had been employed without benefit. I removed the whole lower eye-lid with a small portion of the upper at each angle. The disease adhered so closely to the nose on the inside, that I could not feel certain of having removed it effectually. The wound proceeded very favorably. Some inflammation of the conjunctiva occurred, but soon went off, leaving the cornea quite clear. The cicatrix caused contraction of the palpebral slit; but a sufficient opening remained, when he left the hospital, for tolerable use of the eye. The patient remained well until the beginning of 1832, when uneasiness began to be felt in the internal angle of the eye. This gradually increased, and he came to town in the beginning of the summer. There was return of the complaint along the cicatrix, more particularly towards the internal angle. The conjunctiva between the scar and the globe seemed to participate in the affection; it was thickened, preternaturally red, and exhibited granular masses advancing on the cornea, which in other respects was healthy. It appeared to my colleagues and myself that the disease could not be satisfactorily removed without including the globe in the operation; the patient being averse to this proceeding returned to the country.

Case IV. *Carcinomatous ulceration of the lower eye-lid and cheek, healing under the application of leeches.*—A man of spare habit, sixty-four years of age, was for a long time an out-patient of St. Bartholomew's Hospital, on account of a large ulcer with unequal surface, knotted and irregular margin, which had commenced about twenty-four years previously. The boundaries of the ulceration were the bridge of the nose and the left ala nasi, the left angle of the mouth, the left inferior palpebra, which had been nearly destroyed, and the left temple. The eye had been occasionally inflamed, but had not suffered materially. For some months it was dressed

with a lotion of distilled water, and liquor opii sedativus, the latter being in the proportion of one-third or one-half. This eased the pain, which had been considerable: the health was perfectly good. The discharge from the sore was so sparing, that the lint, by means of which the lotion was applied, adhered firmly. The surface used to bleed freely on its removal, which suggested the idea of taking blood by leeches. Six were accordingly applied, and with so much benefit that they were repeated. The progressive improvement in the sore led to two or three further repetitions. In the course of a short time, nearly the whole of this extensive ulcer cicatrized; the surface continuing unequal, and the edge knotted. The only part which did not heal was towards the external angle of the eye, where a portion of skin formed an uneven tuberculated mass with small superficial ulcerations. The neighboring integuments were strongly drawn towards the lower part of the orbit by the contraction of the cicatrix. The opiate lotion was still applied to the part which had not healed. The patient was free from pain and in perfect health. He continued well for about a twelvemonth, when he died, as I was informed, after a short illness, from erysipelas of the head.

While the preceding case was under observation, an old man became my patient in the hospital, with a cancerous sore at the angle of the mouth, of many years duration. It was so considerable, that excision would have been hardly practicable, even if there had not existed a considerable indurated enlargement of the submaxillary absorbent glands. Erysipelas of the face came on, and was severe. As he was recovering, the sore lessened, and its raised edge sunk considerably. It seemed in a fair way for healing when he left the hospital on his return to the country.

SECTION IV.—CHANGES OF FIGURE AND POSITION.

Ptosis; Blepharo-ptosis; lapsus palpebræ superioris.—By these names is designated a falling of the upper eye-lid, with a partial or complete want of power to elevate it. Such a state may exist for a time with enlargement of the part, in consequence of inflammation or injury. It gradually disappears without any local treatment. There seems to be no difference between this state and that which BEER* has spoken of, under the name of *relaxation of the eye-lids*, (*atonia palpebrarum; atoniaton blepharon.*)

JUENGKEN distinguishes four kinds of *blepharo-ptosis;* viz. 1st, *senilis*, generally leading to entropium; 2d, *traumatica*, from wounds; 3d, *symptomatica*, from abscess or tumours; 4th, *congenita.* The latter, he says, sometimes appears in several members of a family.†

[Dr. ALESSI has recorded a very remarkable example of hereditary ptosis. The males alone in this family were affected, and what is still more curious, the deformity changed sides at each generation. Thus in the grandfather it was the right eye that was affected; in his son it was the left one, in his grandson it was again the right, and in his great-grandson it was the left.]

I have seen a few instances of this congenital imperfection. In the case of a gentleman, who consulted me for it, the lids could not be opened, on either side, by voluntary effort, to more than one-third of the usual extent; and when this was accomplished, the upper palpebra was quite smooth, without any fold between it and the eye-brow. It was necessary to throw back the head, in order to see objects above the level of the eye. There was a striking peculiarity in the expression of the countenance. This patient

* *Lehre*, vol. ii. p. 15.

† *Handbuch*, p. 701—704.

derived great advantage from the removal of a portion of skin, as in the operation for entropium. He informed me that he had a sister, in whom the imperfection was greater than in himself. I saw a young girl with one eye in a similar state.

The name *ptosis* is sometimes applied to the falling of the lid, consequent on paralysis of its levator muscle, the *ophthalmoplegia* of some authors. Sometimes the want of power over this muscle is the only disease; the other muscles, supplied by the nerve of the third pair may be also involved; or there may be squinting, double vision, or amaurosis. If the eye-lid be lifted, it slowly falls down again, over the eye, and the patient either is unable to move it by voluntary exertion, or can raise it only partially. This affection, which is not uncommon, is produced by disease within the head, and hence it is sometimes the precursor of apoplexy. It must be treated in the same way as other paralyses consequent on disease of the brain; that is, by abstraction of blood, aperients, low diet, and the administration of mercury. After the former measures, and in conjunction with the latter, counter-irritation is of great service, by blisters to the nape, behind the ear, on the temple or forehead, by the tartar emetic ointment, or by seton. Some have particularly recommended the application of caustic,* or moxa, between the angle of the jaw, and the mastoid process; but I have never found it necessary to have recourse to that measure. To ensure a successful result, it is sometimes necessary to persevere for a long time in the plan of treatment now recommended. If the power of the levator should not return in a few weeks, electricity may be tried.

I subjoin the following case to illustrate the nature and treatment of the affection.

Case.—E. B., forty years of age, came under my care at St. Bartholomew's on the 11th of July, 1827. She was a short thin woman, whose habits of drinking porter and spirits had given her a very sallow, unhealthy countenance. A week before, and three days after having been intoxicated, she felt pain in the head, and giddiness, immediately succeeded by dimness and confusion of vision, which continued to the time of her admission. July 11th. The upper lids hang loosely over the eyes, and she has no power of elevating them. The irides are motionless, the pupils contracted, with a dull and muddy appearance. Vision is dull; best in a weak light. She can make out a large print by looking steadily at it for some time, not otherwise. There are constant pains in the head, and giddiness. The pulse is full, hard, and increased in frequency; the tongue white. (Venesection and an active purgative.) 12th. The patient fainted when six ounces of blood had flowed from the arm; six leeches were therefore applied to each eye. Pain and giddiness lessened; vision improved. Pulse still frequent and hard. Venesection was repeated to twelve ounces, and fainting took place. The patient said that she could see objects more distinctly while the blood was flowing, and that the giddiness had ceased. 13th. Return of pain. (Cupping on the back to fourteen ounces. Pil. hydrarg. gr. v. nocte maneque quotidie.) 15th. The levatores palpebrarum have nearly regained their full power. Vision is distinct in a weak light, but rather confused in the middle of the day; pulse natural, slight pain in the head. (Twelve leeches to the temples; opening medicine.) 19th. The mouth is sore. (Continue the pill at night only.) 30th. Relapse of disease from drinking wine, which had been clandestinely brought by friends. Pulse frequent and hard; tongue white; severe headache; levatores com-

* On a new Method of treating Paralysis and permanent Spasm of the Eye-lids, (*blepharoplegia* and *blepharospasmus tonicus*,) by J. A. Schmidt, in the *Abhandlungen der Med. Chir. Josephs Akademie*, vol. ii.; also in the *Ophthalmol. Bibliothek*, vol. ii. st. 3.

pletely paralyzed, and vision indistinct. (Leeches to the temples, blisters to the nape, opening medicine.) Aug. 20th. Discharged quite well, leeches having been applied again to the temples, and an abscess of considerable size having been formed in the axilla, punctured and healed. She came to the hospital in September in excellent health, and without a trace of the former symptoms.

The position of the lids in respect to the globe may be altered by disease; they may be either turned outwards, so as to expose their mucous lining, or inwards, when the cutaneous surface is directed against the eye. There may be simply this unnatural direction; or it may be accompanied by other alterations in the structure and figure of the upper part.

Permanent elevation of the upper lid (*lagophthalmus, oculus leporinus.*) —The upper lid may be so shortened, as not to cover the globe properly, in consequence of wounds, from the cicatrices consequent on ulceration, or from other causes. It does not descend sufficiently, and thus a portion of the eye-ball is exposed, even during sleep. This state may exist with or without ectropium. The operative proceedings necessary to remedy this condition of the part are considered under the head of ectropium.

Paralysis of the orbicularis palpebrarum.—The upper eye-lid is sometimes in an opposite condition to that of ptosis: it does not descend so as to meet the lower, and the patient cannot close the lids by voluntary effort. This arises from palsy of the orbicularis palpebrarum, which, with a similar affection of the eye-brow, usually accompanies paralysis of the face. The levator palpebræ is sometimes paralyzed alone: I have not seen a corresponding affection of the orbicularis singly. What we observe in the majority of these cases is that the lids do not come together when the patient attempts to shut the eye; the upper lid does not descend in the usual way; we notice no change in the state of the lower. When the palsy is complete, especially in old persons, where it is of long standing, the lower eye-lid is loose and falls away from the globe. Less inconvenience is experienced from this paralysis of the orbicularis than might have been expected: for, although the lids do not come together, the cornea is not exposed. When the patient attempts to close the eye, the globe is involuntarily rolled upwards, so as to place the cornea behind the upper lid.

In the greater number of instances paralysis of the face depends on sensorial affection, and requires the same treatment as the analogous affection of the levator palpebræ. Sometimes it is produced by causes acting on the facial nerve, such as cold, disease of the bony canals through which it passes, pressure on it by morbid growths, injury or division of its trunk by accidental wounds or surgical operations. Hence the affection sometimes admits of relief, sometimes is irremediable.

Spasm of the eye-lids (*Blepharo-spasmus*) generally depends on causes affecting the eyes, such as external irritants, or inflammations. It may occasionally be seen as an obscure nervous affection.

Winking of the lids is produced by external irritations, such as a foreign body in the eye, or a lash turned inwards. This, however, and a quivering motion of the palpebræ may become habitual as an involuntary habit.

Ectropium.—The turning outwards of the lids, which is most frequent in the lower, has both a Latin and Greek name, *ectropium* (εκτροπιον, from εκτρεπω, to turn out) and *eversion.* It is either temporary or permanent.

Temporary ectropium occurs in some inflammations, particularly in the purulent, and is most frequent in the purulent ophthalmia of infants. In the chapter on that subject, the mode in which eversion is produced and the treatment are considered.

Permanent eversion may arise from various causes, and requires corresponding variety of treatment. It is frequent in the lower lid as the result of lippitudo. The palpebral conjunctiva is thickened by repeated inflammations, while the skin, excoriated, or even ulcerated, by the discharge, shrinks, becomes shortened, and thus draws the edge of the lid outwards. The exposure of the mucous membrane to the air and other sources of irritation, increases the inflammation and thickening, until it degenerates at last into a more or less considerable red swelling, the surface of which assumes ultimately a smooth cuticular aspect near the edge of the lid: the case is then called fleshy ectropium (*e. sarcomatosum*,) in contradistinction to the earlier state, before the conjunctiva is swelled, when it is called *ectropium simplex*. It is necessary to remove chronic lippitudo, if it should still exist, and to re-establish a healthy state of the palpebral margin, and Meibomian secretion. No application answers this purpose better than the red precipitate ointment, which may be freely applied to the everted and thickened surface, as well as to the ciliary margin of the lid; it reduces the swelling of the conjunctiva, and rectifies the secretion of the tarsal glands. Ectropium, even when accompanied with much thickening of the conjunctiva, may be remedied in this manner. If the latter affection should be obstinate, the membrane may be lightly touched with the nitrate of silver. The shrinking thus produced on the internal surface draws the edge of the lid into its natural situation. If the sarcomatous growth of the conjunctiva should be too considerable to be reduced by the means just specified, it will be necessary to shave off the thickened membrane; the contraction produced by the cicatrization of the surface will draw the edge of the lid into its proper position.

When the eversion is considerable and of long standing, the tarsus becomes changed in figure, and elongated, so that it is no longer adapted to the convexity of the globe, even if the lid were restored to its proper situation. It may be brought to the proper length by removing a portion of the whole thickness shaped like the letter V; the two oblique incisions beginning at the ciliary margin, will unite in an angle at the orbital edge of the lid. This may be done with a pair of sharp scissors or a knife: the wedge-shaped portion, which is to be removed, having been previously seized, so that it can be held firmly, with Assalini's tenaculum-forceps, or a hook. The sides of the artificial fissure thus made must be accurately united by sutures, which may be removed at the end of twenty-four or forty-eight hours.

Either lid may be everted by the cicatrization of ulcers, consequent on injuries with loss of substance, particularly burns; or after the healing of abscesses, especially when complicated with disease of the bone. In bad cases of this kind, we sometimes see the lower lid drawn away from the globe, and the entire tarsus firmly fixed to the cheek. These are troublesome cases, and we have no effectual remedy for some of them: if the cicatrix be cut through, the healing of the wound reproduces the displacement of the lid. It has been proposed, after liberating by incision the confined lid, to dress the surface of the sore with irritating ointments, such as the unguentum lyttæ, or the yellow basilicon, in order to produce abundant granulations, in the hope of supplying the lost substance.

[Dr. Mackenzie* recommends that the wedged shaped portion should be removed from near the temporal extremity of the lid (see fig. 33.) as the scar is here less apparent and produces less interruption to the motion of the part, than when it is cut out of the middle of the lid. The size

* Treatise, p. 197.

of the piece to be removed must be proportioned to the degree of the transverse elongation of the everted eye-lid. If too large the lid will be so shortened that the edges of the wound will not be brought into contact without stretching them so as to produce ulceration, thereby detaching the stitches before union is accomplished; and if too small the deformity will not be entirely removed.

By the speedy union of the edges of the wound left by the excision of the wedged-shaped portion, the eye-lid, will be retained in its place, and the danger of the integuments re-adhering to the orbit be, in a measure, prevented. To aid, however, in the cure, Dr. Mackenzie* recommends the eye-lid to be covered with a spread pledget, and supported, against the eye-ball, by a compress and roller. The opposite eye should be closed and covered, so that it may be kept at rest.

Fig. 33.

A useful modification of this operation in some cases of eversion of the lower lid has been devised and performed by Professor Graefe. He first cut out a wedge-shaped portion of the eyelid, and united the edges of the wound by means of the hare-lip suture; but just before twisting the thread round the pins, he divided the skin of the cheek to the extent of $1\frac{1}{4}$ inch by an incision concentric with the edge of the orbit. He then twisted the threads, drew the ends of them upwards, and fixed them to the forehead by sticking plaster, so that the edge of the lower eye-lid might be raised sufficiently. The incision through the skin of the cheek was thus made to gape, and in order to heal it with a broad scar, the edges were kept separate by a crescentric plate of lead, which was pressed in between the lips of the wound, and retained by strips of plaster. The wound of the eye-lid was quite united on the third day, and that into which the plate of lead was inserted was cicatrized in the fourth week, the size and situation of the eye-lid appearing natural.†]

Juengken‡ mentions a proceeding as having been employed by Jaeger, of Vienna, and subsequently by himself, with advantage. It consists in detaching the everted lid from the cheek or superciliary ridge, leaving it connected at the angles only. This is accomplished in the lower lid by entering a sharp-pointed double-edged knife through the conjunctival surface, near the inner angle, and bringing it out through the skin on the cheek; it must then be carried on transversely to the outer angle. A sarcomatous growth of the conjunctiva may be previously dissected off, if necessary; and a triangular portion of the lid may be removed after the above-mentioned incision, if such a proceeding be advisable. The detached lid must now be fixed, accurately and firmly, in contact with the globe and the integuments of the cheek must be drawn up towards the eye, and maintained in that position by adhesive straps, compresses and bandage. An analogous proceeding is applicable in the upper lid.

Professor Dieffenbach, of Berlin, performs the following operation for ectropium. He makes an incision through the skin and orbicularis, nearly parallel to the edge of the lower lid. It begins two or three lines

* Op. citat. p. 197. † Ibid. ‡ *Handbuch*, p. 696—700.

from one angle, and ends at the same distance from the other. It is one line from the edge of the lid at its two ends, and two or three lines in the middle. He turns up the small flap of skin thus made, and dissects through the lid to the conjunctiva, which he divides to the extent of the external wound. With forceps he draws the external edge of the divided conjunctiva into the wound of the integuments, and unites by sutures, which pass through the conjunctiva as well as the skin.* A force is thus applied to the ciliary margin of the everted lid, drawing it inwards.

Another proceeding has been employed by DIEFFENBACH in ectropium of the lower lid. He removes the cicatrix by an incision of triangular shape, the basis, of which [see fig. 34. *c. c.*] is towards the ciliary margin, the apex downwards. He then extends the incision which forms the basis of the triangle on each side, [*c. a.*] and raises the lateral portions, forming the sides of the triangle, a little from the subjacent parts. He is thus enabled to bring together the two sides into a perpendicular union, while, by the lateral extensions of the incision above, they can be fastened to the base of the triangular space formed by the removal of the cicatrix.†

Fig. 34.

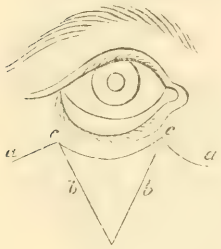

Fig. 35.

[The sides *b. b.* of the triangle are approximated and the two cut margins *a. c*, *c. a.* are connected to the corresponding margin of the lower lid, included between *c. c.* and the edges maintained in contact by sutures as shown in fig. 35.]

Ectropium of either lid may be consequent on the healing of an abscess, especially if it be scrofulous or connected with disease of the bone. In the latter case the integument is drawn in and fixed to the bone at one point. Shortening of the lid is generally combined with the eversion. This shortening, in the case of the upper lid, constitutes the *lagophthalmos* or *oculus leporinus*. The combined shortening and eversion were exemplified in the cases alluded to at p. 123. It has been the practice in such cases to expose, by a transverse incision, the induration extending from the cicatrix to the orbit, to dissect it away, and then to unite the wound. The eye-lid and neighboring integuments must be retained in a suitable position by adhesive strips, compress, and bandage. I adopted this proceeding, together with excision of a triangular portion of the lid in the instances just referred to. Professor AMMON‡ detached the indurated portion from the integument and surrounding soft parts, leaving it adherent to the bone, and closed the external wound over it.

Professor JAEGER of Vienna has employed, in bad cases of lagophthalmos and ectropium an operation, in which he reduces the transverse elongation of the tarsus by taking out a portion of it, and attempts to remedy the shortening of the lid in its perpendicular dimension by bringing down or upwards the integuments of the forehead or cheek. He cuts through the everted or shortened lid in its whole thickness by a transverse incision including its whole thickness; he takes out a piece, so as to bring the lid

* RUST'S *Magazin*, vol. xxx. p. 438. AMMON'S *Zeitschrift*, vol. i. No. 33.

† ZEIS, *Handbuch der Plastischen Chirurgie*, Berlin, 1838. An account of the work will be found in the *British and Foreign Medical Review*, April, 1839.

‡ *Ueber Lagophthalmos und Ectropium a caric marginis orbitalis*; *Zeitschrift*, vol. i. No. 3.

to its proper width; he then loosens the integuments of the forehead or cheek with a double-edged knife carried between the orbicularis muscle and the bone, so that they can be drawn downwards or upwards to a sufficient extent. The perpendicular wound is first united by sutures, and then the transverse wound, an assistant drawing downwards the detached integuments so as to approximate the sides of the wound. The parts are to be supported in their position by adhesive strips, compresses, and bandage.*

In bad cases of lagophthalmos and ectropium, where the superficial textures of the lid have been extensively destroyed, with great displacement and deformity, or where the lid has been altogether lost, reparation may be effected, to a certain extent, by transplanting the neighboring sound skin of the cheek or temple. With this may be combined, in cases of the first description, according to circumstances, the necessary proceedings for detaching adhesions, for shortening the lid when its tarsal edge has become elongated, for removing thickened conjunctiva, and for saving such portion of the membrane, as may be useful in affording a mucous covering to the new lid. This method seems to have been first practised by Dr. Fricke† of Hamburg, who calls it *Blepharoplastick*, and who seems to have transplanted a portion of skin from the forehead or cheek, probably twisting it to bring it into place, as in the operation of making a new nose from the forehead. Two trials of the method, made by Juengken‡ failed entirely.

Greater success has been obtained by following the plan suggested by Dieffenbach for certain autoplastic operations; namely, that of transplanting the sound skin *laterally* without twisting its root, instead of moving it perpendicularly, as in forming a new nose from the forehead, when the portion by which the flap remains attached, is necessarily twisted. Thus, in the lower eye-lid, the cicatrix is removed, and the lid liberated by incisions, which leave a triangular wound. The basis of the triangle is parallel to the tarsal edge of the lid, and the two sides meet at an acute angle on the cheek. An incision is then carried in the same direction with the basis, from its external angle towards the zygoma, while, from the end of this another incision is continued downwards and forwards towards the apex of the triangle. The flap thus marked out is raised from the subjacent parts, except at its lower portion, and moved into the space already prepared under the eye-lid, where it is secured by sutures in the usual manner, while the space left vacant by its removal is dressed as an open wound. The same proceeding, *mutatis mutandis*, is applicable to the upper eye-lid. This method may be employed either in bad cases of lagophthalmos or ectropium, or where the lid has been entirely destroyed, care being taken in the latter instance to preserve the conjunctiva, if possible, and to unite it by sutures to the edge of the transplanted integument, so as to give it a mucous lining.

* This proceeding is described by Dreyer, in an inaugural dissertation, *de nova Blepharoplastices Methodo*, c. tab. 2. Vienna, 1831. An account of the method is given, as an analysis of this dissertation, in Froriep's *Notizen*, vol. xxx. No. 16.

A detailed account of Jaeger's operation is given in the *London Medical Gazette*, vol. xvii. p. 271, by Dr. Brown, of Glasgow, who speaks of it as having been successfully performed.

In the 18th vol. of the *Gazette*, at p. 223. Mr. T. W. Jones offers objections to this proceeding, and proposes another method. The plan of Mr. Jones, which is simple, is illustrated by two figures in Mr. Mackenzie's work, p. 196. Mr. Jones makes an incision on each side of the cicatrix or contracted portion; these incisions meet together at an acute angle about an inch and a half above the orbit. He expects to obtain the necessary elongation of the contracted part by the stretching of the cellular tissue uniting the triangular flap of skin to the subjacent parts. A short reply of Dr. Brown to Mr. Jones will be found in the same volume at p. 485.

† *Die Bildung neuer Augenlieder; Blepharoplastick.* Hamburg, 1829.

‡ *Lehre von den Augenoperationen*, p. 267. Ibid. Preface, p. 9, 10.

Professor Ammon of Dresden has performed this operation successfully in two instances, one of these was a cancerous disease, occupying two-thirds of the lower, and a small portion of the upper lid. Integuments were transplanted to cover the loss of substance occasioned by extirpation of the disease.* The other was an entire loss of the upper lid from syphilitic ulceration.†

[In this case Dr. Ammon began his operation by insulating and separating from the temple the flap of skin, (*b*, *c*, *d*, *e*, *Fig.* 36.) by which the defective upper eye-lid was to be supplied; he then divided all the

Fig. 36.

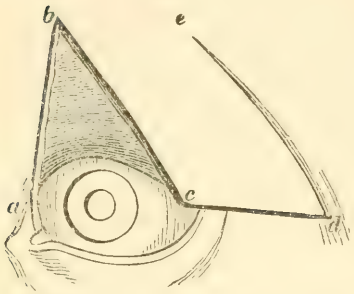

Fig. 37.

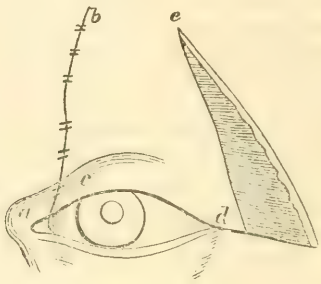

adhesions of the old eye-lid, and prepared the place (*a*, *b*, *c*,) for the reception of the new one. He formed the flap by a horizontal incision (*c*, *d*,) two inches and a-half in length, to which he joined the perpendicular one, (*d*, *e*,) and then dissected it off. He reduced the shrunken remains of the old eye-lid with the bistoury; but unfortunately found it impossible to separate enough of conjunctiva from it, to form a lining membrane for the new eye-lid.

As soon as the bleeding had ceased, the flag forming the new eye-lid having been brought into such a position that it covered the eye, it was secured along its inner edge (*b*, *c*, *Fig.* 37.) by Dieffenbach's suture; and thus ended the formation of the upper eye-lid.‡]

Mr. Tyrrell§ states that he has succeeded in several operations for ectropium, which I conclude were performed on the plan now described.

[My friend Professor Horner, of the University of Pennsylvania, has succeeded in relieving a case of ectropium of the lower lid by an operation founded on the same principle. The subject of his case was a man forty-two years of age, in whom the disease had resulted from a burn two years previously. The whole tarsus was permanently everted, the conjunctiva of the lid exposed nearly half an inch in breadth and inflamed, ulcered and thickened: "An incision, two inches in length and down to the bone was made parallel with and at the inferior margin

* Dr. Dieffenbach's *neue Methode der Blepharoplastik;* Ammon's *Zeitschrift*, vol. iv. p. 428; with five figures to illustrate the mode of proceeding, which is minutely described.

† *Bildung eines oberen Augenlides aus der Schläfenhaut, mit gleich zeitiger Restauration der unteren; Zeitschrift*, vol. v. p. 312. Professor Ammon states that the operation had been successfully performed in the lower eye-lid by Fricke of Hamburg, and Von Ekström of Stockholm; and that Dieffenbach had lately done it in the upper lid, but that the newly-formed part, which he calls a beautiful production of art (schöner kunstproduct) perished by hospital gangrene.

‡ Mackenzie's Treatise, p. 202.

§ *Practical Work*, vol. i. p. 456.—459.

of the orbicularis muscle. The whole thickness of the eye-lid was then dissected up from the adjoining bones. From about the middle of that incision started another, of an inch in length, downwards towards the angle of the jaw. From the termination of the latter another incision of the same length was directed towards the root of the nose. The last two incisions consequently defined an angle of integuments, which, being dissected up as far as its base, was then turned into beginning of the first incision. Diagram fig. 38. will illustrate the operation.

Fig. 38.

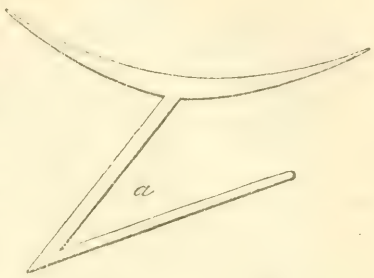

"The angle *a*, *Fig.* 38, taken from the cheek, was inserted into the lower eye-lid, as seen in *Fig.* 39, and a pin fixed at *b*, and another at *c*, so as to keep the parts in place. An almost immediate cor ection of the deformity ensued. Common dressings were put on, and at the end of two weeks the cure was accomplished, with the exception that the margin of the lid was rather loose, but still leaving the prospect of that being corrected by a natural process of shortening in due time. He, in fact, was so far well, that he was discharged from the wards a week or two afterwards.*"

Fig. 39.

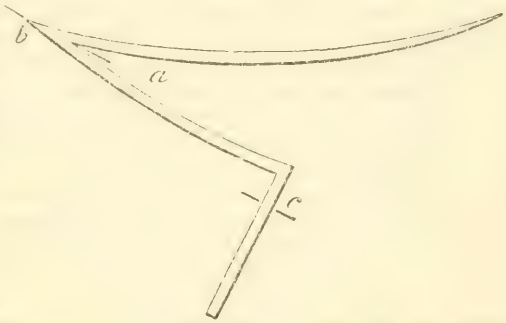

Prof. Brainard of Chicago, has also succeeded in removing the deformity in a case of ectropium by an ingenious modification of the Blepharoplastick method of Dr. Fricke.

The subject of this operation was a young man about 29 years of age, who had received a severe burn from falling upon a bed of burning coals, by which a great part of the left cheek was entirely destroyed, and a cicatrix produced, which, by its contraction, occasioned a complete eversion of the inferior palpebra of that side, and a considerable contraction of the corresponding angle of the mouth.

Five months after the accident, January 2d, 1845, he applied for relief. At this time the eversion of the lid was complete, its ciliary border being firmly adherent to the inferior margin of the orbit, and its inferior edge projecting upwards towards the globe of the eye. The conjunctiva was much inflamed, so as not only to give the eye an unsightly appearance, but also to render it the source of very considerable pain and inconvenience.

To this deformity Prof. B. performed the following operation :—The palpebra was first dissected up, so as to be placed in its natural position, by which a wound was left beneath it, an inch and a half in length by

* American Journal of the Medical Sciences. Nov. 1837.

three-fourths of an inch in breadth. To fill this a flap was formed behind the external angle of the eye of corresponding form, but somewhat larger, to make allowance for contraction, the attachment of which was over the anterior part of the zygomatic arch. This being turned upon its base, was brought into the space left by raising the lid, and retained in that situation by stitches of interrupted suture. The sides of the wound left by the removal of the flap, were then brought together and retained in the same manner, and only simple dressings were applied. The accompanying sketch representing the appearance of the parts when the flap had been fixed in its new situation, will at once render intelligible the above description. Perfect adhesion took place by first intention, and at the end of two weeks, the patient was able to return home, the palpebra having its natural position and both the deformity and inconvenience resulting from it were almost entirely removed.*]

Fig. 40.

Entropium (εντροπιον, Gr. from εντρεπω, to turn in) or inversion of the lids, which may be either temporary or permanent, partial or complete, is more injurious to the eye than ectropium, being often accompanied with great mechanical irritation, from the rubbing of the lashes against the globe of the eye, which produces severe inflammation, with ulceration and opacity of the cornea.

Temporary inversion, particularly of the lower lid, will occur in chronic external ophthalmia, and sometimes even in more acute cases. The ciliary margin is drawn inwards by a spasmodic action of the orbicularis, occasioning constant winking, particularly when attempts are made to use the irritable organ; while the contraction of this muscle forces the eye-lid inwards, and retains it in its unnatural position, the swelling of the inflamed conjunctiva between the globe and the palpebra pushes the opposite margin of the tarsus outwards. The eye-lashes and the cutaneous surface of the lid are directed against the ball with great aggravation of the inflammation. By drawing the skin gently downwards, the lid, which retains its natural figure, may be restored to its proper position, but the patient presently winks, and the orbicularis turns it in again.

Treatment.—We must remove the morbid condition of the conjunctiva; and we shall derive assistance in respect to the inversion by mechanical means. It is sometimes sufficient to put a small compress against the lower portion of the lower lid, and retain it there by a strip or two of sticking plaster placed transversely over it.† Pressure in this situation restores the ciliary edge to its right position, and if it be retained there for twelve or twenty-four hours, the inversion will not be reproduced. It is, however, difficult to retain the compress, on account of the tears flowing over the lid, and loosening the plaster; we may then succeed by employing a piece of double twisted wire, bent into the form of spectacles, so as to fit on the nose, and made to press upon the lower lid. This is easily fastened on the face, and may be used with the addition of a compress, if it should be necessary.

* American Journal of the Medical Sciences. Oct. 1845.

[† A plan, which we have found to answer very well, is to apply one end of a strip of adhesive plaster to near the edge of the lower lid, and then to draw down the lid and apply the other portion to the cheek. This will rarely require adjusting more than once a-day, and often only once every three or four days.]

We are more frequently called on to remedy permanent inversions, accompanied with serious irritation of the eye from the pressure of the cilia against the globe.

There is sometimes in elderly persons a relaxation of the integuments; the skin of the lid loses its elasticity, falls into wrinkles; the fat is absorbed from the surrounding parts; and thus loose folds are formed in the lid. The balance between the external surface and the mucous lining of the lid is lost, and inversion is the consequence. (*Entropium senile.*) The entire lid forms a round roll, the cilia lying in its interior; the essential form is not altered, and there is little or no irritation. I have seen this inversion in the lower lid of both eyes without the patient being aware of its existence. If we take up a fold of integument with the finger and thumb, or with a forceps, and draw it out a little, we shall restore the lid to its proper situation. The surgical remedy for the disorder consists in removing a portion of skin close to the edge of the lid, of such breadth as may be sufficient, when the cicatrix has formed, to bring the part back to its natural direction.

The superfluous portion of integument may be got rid of by the application of a strong escharotic; the concentrated sulphuric acid will answer the purpose.* A small bit of smooth hard wood should be cut flat, and almost brought to a point, then dipped in the acid and drawn gently and repeatedly over the surface of the skin which it is wished to destroy. The greatest caution is necessary to prevent the contact of the acid with the ciliary margin, or the globe. The application must be continued until the proposed object is accomplished, which will generally require about ten minutes or a quarter of an hour. The acid turns the skin at first white and then brown; the skin contracts, shrivels up, and thus draws the ciliary margin of the lid outward. The portion of the integument thus destroyed soon separates and leaves a cicatrix, which is not conspicuous, although it answers the purpose of preventing the lid from rolling inwards.

The most effective mode of proceeding, however, is to remove a portion of skin by the knife or scissors. A fold of integument is to be taken up with a forceps, having small horizontal blades corresponding in length to that of the lid. Before making the incision, it is necessary to ascertain exactly how much skin ought to be removed; this is easily accomplished by taking up a fold with the forceps, and observing the effect on the position of the lid. If too much be removed, eversion is caused; if too little, inversion remains. The integument is sometimes so loose and redundant, that a broad piece must be removed; I have sometimes found it necessary to take away an inch. The incision should be as near as possible to the ciliary margin, just leaving room for the sutures. By this proceeding an elliptical portion of the skin is removed; the broadest part should be at the point of greatest inversion. The forceps are sometimes made with a spring between the handles, so that having opened the extremities and taken hold of skin, the spring retains that hold. I prefer those without a spring, because we can apply with the hand exactly the requisite degree of force. The pressure of the spring is sometimes insufficient, and the fold of skin consequently escapes. After having cut off the fold of skin, the edges should be united by two or three fine silk sutures, which should be cut out

* This proceeding was proposed by HELLING. *Heilungsart d. unkehrung d. Augenlieder nach innen mit concentrirr Schwefelsäure;* in HUFELAND's *Journal*, 1815. st. 4. p. 98. vol. xl. See also his *prakt. Handbuch*, 1821, vol. i. p. 302. It has also been employed by QUADRI, *Annot. pratiche sulle Malattie degli Occhi*, 1818, p. 69. tav. i. iii.

BEER speaks of it in terms of strong commendation, having, as he says, employed it with complete success in cases that appeared almost desperate. *Medicinische Jahrbücher der kaiserl königl. Œsterreichischen staatén*, band. 4. stuck. 4. p. 166.

in about twenty-four hours; I never allow them to remain longer, the degree of adhesion being then sufficient to retain the edges of the wound in apposition. The cicatrization produces a permanent contraction of the part, and consequent restoration of the lid to its natural position. When it has been long inverted, and there is change of figure in the tarsus, with a tumid state of the lid and strong contraction of the orbicularis, it is not sufficient merely to remove a portion of skin. This proceeding remedies the inconvenience for a time, but it is soon reproduced. Therefore, after excising the fold of integument, take up a portion of the orbicularis, and remove it by the scissors. The contraction of this muscle, which has so much influence in causing and keeping up the entropium, is thus weakened; and the subsequent cicatrization, being deeper and firmer, affords a greater security against relapse.

Another form of inversion, of which the cause is found in the tarsus, occurs when the lid has been long the seat of chronic inflammation, or when it has been frequently the subject of inflammatory attacks. The consequence is, that the tarsus becomes corrugated and shortened, the ciliary margin is contracted and presses inwards, and the cilia turned against the globe cause insupportable irritation by rubbing against the cornea, whenever the eye is moved: hence the eye is kept closed, and the patient is nearly deprived of sight, if the disease exists on both sides. The same cause excites and maintains external inflammation of the eye with vascularity and opacity of the cornea, ultimately changing the texture of the latter by rendering it vascular, and converting its mucous surface into a tough, opaque, and almost insensible covering.

In an incipient case it may be sufficient to excise a portion of skin; this remedy will at least answer the purpose for some time. To make the operation more effectual, a portion of the orbicularis should be removed also, that a firm cicatrix may be produced; or the acid may be employed, using it more freely, so that its action may extend deeper, and a solid scar be the result.

If the entropium should be again produced, other means must be resorted to. A mode of operation has been recommended by Mr. Crampton,* of Dublin, and followed with a little modification by Mr. Guthrie;† it consists in a perpendicular division of the lid near to each angle, or on each side of the inverted portion, cutting through its textures longitudinally, when it may be turned up and brought into a state of complete eversion. The whole thickness of the lid is cut through by a strong pair of scissors, so that when you lift it, the mucous or concave surface is fully exposed. The contracted ciliary margin being thus set at liberty, the inversion is remedied at the moment, but in bad cases the tarsus still remains a little bent inwards. A portion of the external skin must be cut out, as in the operation already described, taking up the necessary fold with the forceps, measuring it, removing it with the knife or scissors, and then uniting with two small sutures. A little cut, or nick, should then be made in each edge of the curved tarsal cartilage, so that it may more easily bend outwards in its proper direction. Then, having left the threads of the external sutures of proper length, carry them upwards, and confine them on the brow by sticking plaster, elevating them sufficiently to evert completely the liberated upper eye-lid, and to maintain it everted, with its mucous surface completely exposed. Thus the parts are to be left till the sutures come through by ulceration, and till the granulation of the two longitudinal cuts draws the lids gradually into its natural position. The inverted lid is to be covered by a piece of

* *Essay on the Entropion*, London, 1806.

† *Lectures on the operative Surgery of the Eye*, 1823, p. 31—41.

thin linen spread with spermaceti cerate. The object of the proceeding is to liberate the contracted tarsus, to destroy its unnatural curvature, and thus to prevent renewed inversions. Mr. GUTHRIE represents that it accomplishes these points completely; that it is a perfect remedy for the severe sufferings caused by habitual entropium.

Fig. 41.

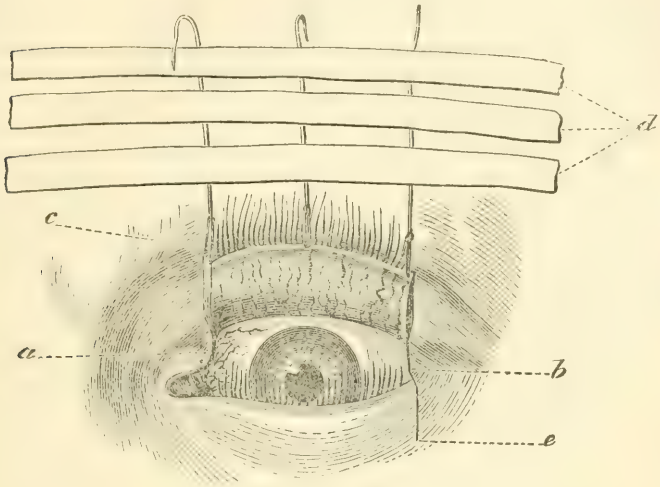

[Fig. 41 represents an eye, the upper lid of which has been operated on for inversion, *a*, the inner incision, close to the punctum lachrymale, which is marked by a black spot, and which incision need never exceed one-third of an inch in length; *b*, the outer incision, of the same length, close to the external canthus, *c*, the ligatures supporting the lid against the eye-brow, and more particularly the inner one, which is passed through the edge of the lid; *d*, strips of adhesive plaster affixing the ligature to the forehead; *e*, line of incision, in a case of inversion of low lid.]

There are objections to this complicated proceeding, in which great liberties are taken with the part; and I believe that the object may be attained more simply. Mr. TYRRELL makes a perpendicular section of the whole substance of the lid, near its center, which in some cases is followed by a rapid removal of the inversion, while in other instances it is necessary in addition to cut out a portion of integument. The section of the lid makes a wound shaped like the letter V, which is afterwards filled by granulations, so that little deformity results. Mr. TYRRELL has found this method invariably successful.*

[Dr. JACOB, of Dublin, has in two cases successfully treated entropion by the following operation, which is a modification of that of Sir P. Crampton.

"The patient being placed in a sitting posture, and the head supported by an assistant, the inverted upper lid was separated from the globe of the eye by means of the finger or a sharp hook, and then with a pair of strong

* Vol. i. p. 447.

scissors two perpendicular incisions were made through the tarsal cartilage, each about a quarter of an inch in length, one upon the temporal, the other upon the nasal side, avoiding the punctum, and including the whole inverted portion of the lid; this part being now everted and held in that position, the two perpendicular incisions were connected by a horizontal incision upon the conjunctival surface close to the ciliary margin by means of a scalpel, cutting through the conjunctiva and tarsal cartilage, and leaving the inverted portion of the margin united to the rest of the lid, *merely by the integuments;* taking care that the knife did not penetrate through the skin. The inverted portion of the lid now no longer turned against the ball of the eye, and as soon as the smarting from the operation subsided, the patient felt relief—a light pledget of lint wet with cold water, or a dilute solution of sulphate of zinc was then laid upon the eye, and moistened occasionally.

"The success of this operation depends in a great measure upon the edges of the incision being prevented from uniting by the first intention, particularly the horizontal incision upon the conjunctival surface; this is effected by everting the lid occasionally during the first few days, and by touching the edges immediately after the operation with the sulphate of copper, so as to cause it to suppurate and fill up by granulation."—*Dublin Medical Press*, 27th July, 1842.]

There is another operation, which is certainly effectual in removing the immediate cause of evil, viz. the irritation caused by the inverted cilia. This is the *excision* of the inverted cilia with that portion of the edge of the lid containing their bulbs, proposed by Professor Jaeger,† of Vienna. In a case of complete inversion, it is difficult, if not imposible, to accomplish a perfect cure; that is, to restore the edge of the lid, with its lashes, to its natural state; the excision of the bulbs sacrifices the lashes, but has the advantage of removing effectually all source of irritation from the eye.

A smooth slightly concave piece of horn, adapted to the size of the lid, is introduced under it as a means of extension and support in the operation: this however is not indispensable. A horizontal incision is then carried through the skin and orbicularis, a line and a-half from the ciliary margin, and continued to that margin at each extremity of the inverted portion. The part thus marked out is to be dissected carefully off by repeated short strokes of the knife carried obliquely, so as to iuclude the bulbs of the inverted lashes, and leave the mucous surface entire. As the integument is redundant, it may sometimes be advantageous to make the first incision further from the margin of the lid then I have mentioned; but in the subsequent dissection, we must not remove more than a line and a-half, which will include the complete ciliary bulbs. The portion to be removed may be held and drawn outwards with forceps; or it may be more completely and conveniently commanded by means of a ligature passed under the skin with a curved needle. A soft rag dipped in cold water may be laid on the eye after the operation, and occasionally renewed. I have adopted this mode of proceeding in many instances with a completely satisfactory result. The patient is immediately relieved from the intolerable irritation caused by the rubbing of the cilia; the eyes and lids can now be moved freely, and thus the use of these important organs is restored. The chronic ophthalmia ceases, the vascularity of the cornea disappears, and opacities are either removed entirely, or greatly lessened in extent and intensity. When the wounded surface of the lid has cicatrized, no deformity remains.

* Hosp. *diss. med. chir. sistens Diagnosin. et Curam radicalem Trichiasis, Distichiasis, necnon Entropii,* Viennæ; also in Radius, *Script. ophthalm, minor.* vol. i.

The excision of the whole tarsus, proposed by Mr. SAUNDERS* is an unnecessarily extensive and severe measure, and is now, I believe, entirely abandoned. Dr. JACOB† cuts away the cilia and their bulbs with scissors, making repeated small incisions until the whole of the inverted portion is removed.

[M. GERDY, in a very interesting essay on the treatment of Entropium and Trichiasis, published in the *Journal de Chirurgie*, states, that he was consulted some years ago by a patient who had tried various means for the relief of a most distressing trichiasis. The skin of the upper lid had been several times excised in a line parallel with the length of the organ; M. Gerdy himself had excised it with as little success as those who had attended the patient previously. He then conceived the idea that it might answer the purpose to remove the whole margin of the upper lid, carrying the excision beyond the bulbs of the eye-lashes. He examined how far these bulbs extended, in order that he need not expose himself to the liability, on the one hand, of removing them but imperfectly, nor, on the other, of excising too large a part of the upper lid, thus leaving the eye exposed. He ascertained that it was only necessary to remove a strip of four millimetres in width, at most, along the free margin of the upper eye-lid, and of three millimetres along that of the lower, if it were also affected. Considering the condition of the lid of his patient, the long duration of the affection, his continual sufferings, and the strong desire he felt to be cured, M. Gerdy decided upon operating, and had reason to congratulate himself upon it. Since that period, other cases have been operated on with success, but the following case will exhibit more satisfactorily the value of this proceeding, which, however, the author does not resort to excepting when it would seem that the excision of the skin of the lid would not answer, or has already failed.

A farmer of Saint-Owen, 42 years of age, entered La Charité on the 8th Feb. This individual had been in the hospital four years before. He had then, two or three lines outside of the external angle of the left eye, a small ulcerated tumour consisting with an inversion of the eye-lashes of both lids. The tumour was removed, and the edge of both lids was excised to an extent which included the ciliary bulbs. The resection had the desired effect; the edges of the lids cicatrized and remained deprived of the lashes; the eye was still sufficiently protected; there was no lachrymation; in short, in this respect, the condition of the patient was all that could be desired. But the tumour which was removed at the same time, and which was a *noli me tangere*, was reproduced in both eye-lids and demanded the entire removal of the superior, and also a portion of the lower lid. This operation was performed on the 8th April 1844. M. Gerdy divided the external commissure of the lids, and then circumscribed the tumour by a semicircular incision of which the concavity was downwards, commencing at three milimetres from the internal angle, beyond the superior lachrymal duct, and ending at the external angle. The operator removed all that was included in this incision, excepting a small portion of the mucous membrane which he reserved towards the external angle for the purpose of covering the edge of the upper lid at the point which should correspond with the external commissure of the lids, and of preventing adhesion of the lids within this point.

* *On the cure of the Inversion of the upper Eye-lid by excision of the tarsus*, in his posthumous work, p. 74.

† *Dublin Hospital Reports*, vol. v. p. 392.

The partial excision of the lower lid presented nothing peculiar in the mode of operating.

This being done, M. Gerdy, in order to satisfy himself as to the necessity of replacing the upper lid by a new one, directed the patient to shut the eye, which was effected completely by the contraction of the eye-brows. This fact rendering the utility of the intended blepharoplastic operation doubtful, the patient was spared the pain of it.

During the first few days succeeding the operation, pledgets saturated with cold water were carefully applied to the eye. After some days the wound commenced suppurating. Granulations sprouted up on the edge of the mucous membrane and of the skin; they were repressed with nitrate of silver, and gradually formed a thin, uniform, shining and firm cicatrix, which constituted the margin of the lid. After the 20th April, the result of the operation was appreciable. At first sight, there was but little difference in appearance between the eyes: the left eye was completely closed by a slightly forced contraction which had the effect of drawing down the eye-brow and subjacent skin. If the contraction was but slight, the eye-lids were not brought perfectly in contact with each other: they remained separated at one point by an interval of about two millimetres. The transparent cornea, however, was protected by a consentaneous upward motion of the eye-ball, so that the sclerotic alone was visible in the interstice of the lids. It must be also noted that the patient had no lachrymation.

Thus, we see, that the most obstinate and complete version of the lids may be overcome by the excision of their entire ciliary margin, without inducing permanent exposure of the globe of the eye, or great deformity, or serious inconvenience, to the patient; that this mode should be resorted to when the removal of the skin has failed, and when a trichiasis occupies the greater part of the palpebral margin.

It is proved, also, that the entire superior lid and a portion of the inferior may be removed or destroyed without its being rendered necessary to replace them by new lids, by means of the painful operation of blepharoplasty; that nature, properly asisted, can cure the patient without the eye remaining exposed to the air and light, without any epiphora existing, notwithstanding that the free orifices of the lachrymal ducts have been very much modified, or perhaps entirely destroyed.

Such are the inferences which M. Gerdy draws from the preceding facts. We quote, in conclusion, a passage from the essay in which the author, with the sarcasm which distinguishes him, expresses his opinion with regard to the restoration of the eye-lids, and autoplastic operations generally.

"The case of Daunay," says he, (the one which we have just quoted,) "is important not only for the practical knowledge which it furnishes as to the radical cure of trichiasis; it is interesting to the surgeon in another respect. It shows that we should not despair of the power of nature even in the most severe lesions of the eye-lids, and that we ought not lightly to decide upon carving out from the forehead, the temple, or the cheek, a miserable flap of skin to usurp the noblest region of the face. The eye-lids are so slight and delicate in their organization, their functions so well adjusted and so beautiful; they are so flexible, susceptible of such motion, and so rapid in their movements; they play so prominent a part in expression, from the manner in which they conceal or expose the eyes, that it is difficult to replace them with any advantage by a flap k en from a neighbouring part. The thing which is thus produced nnot be called an eye-lid, it is a something unpleasant in appearance,

and for which there is no name; it changes entirely the expression of the face, interferes with the vision of the patient, offends the eyes of all who see it, and looks more like a shapeless, ugly plaster than an eye-lid formed to beautify, to protect the eye and to assist it in the performance of its functions.

"Assuredly, if we considered only the deformity, the imperfection, and the defects of these so-called eye-lids, which, from a sort of paternal weakness, we exhibit with so much pride, when we ourselves have been the architect of them; if, above all, we reflected upon the sufferings which these miserable eye-lids cost, we should forever banish blepharoplasty as well as rhinoplasty from operative surgery. But we would not, in the case of a part of less consequence, reject and proscribe the whole class of plastic operation. If, in the sort of patch-work which autoplasty makes, whether well or ill, by dint of needles and pins and waxed or unwaxed threads, blepharoplasty is more nearly allied to a tailor's than a surgeon's work; if it resemble it still more closely, in some instances, from the variety in color of the parts brought together, and which reminds one involuntarily of the contrast produced by patching a piece of new cloth upon a worn out garment, whose poverty it conceals and glosses over; if it lower in some degree our art, it is in a few cases really useful, and must not be discarded."—*Journal de Médecine et de Chirurgie Pratique*, Oct., 1844.]

Trichiasis (from τριχος, genitive of θριξ, hair.)—This word denotes an unnatural direction of the cilia, in which they turn inwards, so as to press against the eye-ball. It generally attends entropium, but not necessarily so; for the lid, when inverted, sometimes forms a roll, the interior of which is occupied by the lashes. On the other hand, the lid retaining its natural direction and position, one or more of the cilia may be turned in so as to press against the globe of the eye. This wrong direction of the cilia is called *trichiasis*. The changes which the form and direction of the ciliary margin undergo in the worst forms of entropium, cause trichiasis, which is then combined with the inversion. Cicatrices of the ciliary margin, or tarsal surface of the lid, will cause partial trichiasis; thus it happens after wounds, injuries from caustic substances, or ulceration from various causes. The trichiasis may be complete, involving the whole row of eye-lashes; there may be only a single hair; or it may exist in any intermediate degree. I have seen patients in whom the entire series in both lids of both eyes has been inverted; so that they have not only been deprived of all useful vision, but rendered miserable by inflammation and pain for many years. When the form of the ciliary margin has been altered by long continued disease, the cilia, instead of projecting nearly horizontally, are placed almost perpendicularly, so that their convexity brushes against the globe. Their points are directed towards the eye, when the inversion proceeds further. Sometimes one or two hairs are inverted without any apparent cause, the lid and the other cilia being quite natural; in this case the wrongly directed hair is usually slender and light colored, so that close examination is necessary to detect the inconvenience. The sensations of the patient, however, are very accurate; the feeling of a foreign body rubbing the eye is almost invariably expressed. This mechanical irritation of the organ produces different effects according to its degree, and other circumstances. Sometimes there is a slight uneasiness without inflammation; and this may exist for a long time without the cause being discovered when there is only a single inverted lash. Inflammation may be caused, with ulceration and opacity of the cornea, severe pain, with intolerance of light and the greatest irritability. Sight may be destroyed by the effects of repeated acute inflammation of the cornea, but

the patient's sufferings are not at an end; they are only alleviated by keeping the eye absolutely at rest; the motion required in using it renews the pain.

Treatment.—The cure of trichiasis is either palliative or radical. The former consists in plucking out the cilia; for which purpose we use forceps with broad ends. The lashes soon grow again, and must be extracted as often as they are reproduced. If the case requires a more effectual remedy, we must have recourse to the operation of extirpating the bulbs of the inverted cilia, as described for entropium.

There is a modification of the affection, called *distichiasis*,* a Greek word meaning double row; not that there is properly a double row, but there is a partial series of cilia produced on the inner margin of the lid, in addition to the natural row.

These pseudo-cilia, which are produced not unfrequently where the lids have long been the seat of irritation, generally turn in against the globe. The palliative measure of eradication must be adopted; its frequent repetition in this, as in other cases, sometimes proves a radical remedy. If this should be insufficient, we must resort to excision.

A triangular portion of the eye-lid has been removed in the case of a small partial trichiasis. I have found excision of the bulbs a sufficient remedy in similar instances.

[The amount of serious injury to the eye and of distress to the patient, often caused by inverted cilia, can scarcely be realized by any one who has not had extensive experience. I have known cases in which inflammation of the eyes was kept up for years by them, and one instance in which the eye was lost from the irritation of a single hair. This occurred in a young gentleman favorably convalescing from an extremely severe attack of purulent conjunctivitis; and who had several times suffered from inversion of his eye-lashes. The hair could not be discovered by the friend whom he requested to extract it, and he was persuaded that the sensation he experienced was delusive. On my visit I readily discovered and extracted the eye-lash, but the eye never recovered the effects of the re-excitement of inflammation in it.

The inverted cilia are sometimes so extremely delicate, and light colored that it is very difficult to detect them. The plan we adopt is to place the patient sideways to the light and to use a magnifying glass of about an inch and a-quarter focus. The best instrument for extracting them is a pair of forceps about two lines broad, and square at their ends, ground flat that their opposite blades may accurately correspond so as to prevent the hairs from slipping out, and without teeth. The hair should be seized near the root and slowly drawn out in a straight direction, by which means they are usually extracted by the roots. When drawn out with a jerk they almost invariably are broken off, and the short portion left, irritates like a short bristle. When the extraction of the hairs does not prove sufficiently efficacious, the application of an irritant to the hair bulbs to destroy their reproductive function, as recommended by Dr. James Hunter, appears to us a much better proceeding than the operation for excision. Dr. Hunter's method of procedure is as follows:—

"1. *To ascertain the presence and position of the inverted eye-lashes.* When they are white colored, and of extreme delicacy, not exceeding $\frac{1}{800}$ of an inch in diameter, as is often the case, it is very difficult to

* *Distichia* and *distichiasis*, are from δις, bis, and στιχος, ordo. *Districhiasis* is from δις and θριξ.

distinguish them; the edge of the lid should be brought in contact with the cornea, so that the pupil or iris may form a good contrasting background, and though they may not be visible at once, the surgeon should look from a variety of positions, and alter the direction of the light till he sees them. A convex lens of two inches focus, and not less than an inch in diameter, should be held by an assistant so as to condense the light on the parts, which is a much better plan than using it as a magnifier. If, in order to make the puncture, the edge of the lid is to be removed from the cornea, it is well first of all to blacken the pale and delicate eye-lashes with any dark extract, such as belladonna, to render them visible, when contrasted with the white sclerotic coat. 2. *The puncturing of the bulbs.*—This should be done with a lancet, or iris knife, entered close to the base of the inverted hairs, *in the direction of their growth*, to the depth of an eighth of an inch, and moved about a little, so as to widen the bottom of the wound, and cut the bulbs. In doing this, it is sometimes advantageous to stretch the part either with a small hook, or over a convex black horn spatula, such as is usually attached to the German wire speculum. 3. *The inoculation.*—This must be deferred till the bleeding has wholly ceased, when the lid being wiped very dry, the drilled end of a darning-needle slightly damped, and dipped in powdered tartrate of antimony, or what answers far better, the tartar emetic point made in the manner to be afterwards described, is to be inserted in the puncture, and held there for a few seconds. 4. *The evulsion of the inverted eye-lashes is the last step.*—They should be seized lengthways close to their roots, and drawn with a slight jerk. When common dissecting forceps are used, they should be held *below* their shoulder, and close to their points, which are apt to separate a little when the fingers are placed high up. The best forceps are those made without teeth; the holding part being merely rough polished, so as not to cut hairs. When the eye-lashes are exquisitely fine, and slip through even the best made forceps, I have found it an infallible plan to damp their points with a saturated solution of shell-lac in alcohol, and to grasp the hairs for a second or two before pulling them.* A momentary, though sharp pain follows the inoculation, and more or less inflammation; but the latter generally subsides in the course of twenty-four hours, and if the operation has been properly done, it recurs in a day or two, in a subacute form, producing a slight pustulation, which, however, is of very limited extent, causing almost no annoyance, but is sufficient to destroy the functions of the bulbs."†

Pseudo-cilia are sometimes met with growing from different parts of the conjunctiva, according to Dr. Mackenzie, the conjunctiva corneæ.‡ Dr. Mouteith§ mentions a case in which one exceedingly strong hair grew from the inner surface of the lower lid. It was directed perpendicularly towards the eye-ball, and irritated. The natural cilia were of a light color, the pseudo-cilium jet black, and double the length of the common cilia. We have met with one case in which a long delicate cilium grew from the surface of the upper lid; it was light colored whilst the natural cilia were black.

Dr. Mackenzie has seen an eye-lash fully an inch in length, soft, and woolly, in a patient who had long suffered from ophthalmia.‖]

* [This is an excellent expedient.]
† Am. J. Med. Sciences, Oct. 1844, from Ed. Month. J. Med. Sc. 1844.
‡ Treatise p. 210. § Translation of Weller's Manual, vol. i, p. 115.
‖ Treatise, p. 210.

SECTION V.—MORBID CONNEXIONS.

Ancyloblepharon is a preternatural union of the two lids. They have been found thus united in some instances, as a congenital malformation; but I have not seen such an occurrence.* It is usually the result of ulceration: if the opposed margins are both ulcerated at the same time, they may grow together. In this way partial union may be produced at the external angle, in old cases of lippitudo, where there have been frequent inflammation and excoriation, shortening the palpebral slit, and inconvenient in the operation of extraction, by preventing a sufficient exposure of the globe. This state cannot be remedied; indeed, I never saw it existing to a degree requiring any remedy. If there were congenital union of the lids, as we sometimes find in the anus and labia pudendi, with no other defect, they ought to be separated by incision, taking the necessary care not to wound the globe.

The term *symblepharon* denotes a connexion of the lid to the globe of the eye. This is generally the consequence of accidents, in which caustic substances, such as lime or mortar, are brought into contact with the surfaces of the lid and the globe; it may take place whenever ulceration of the two opposed conjunctival surfaces takes place, from whatever cause. The granulations, which shoot up from the globe and lid, inosculate, and a permanent adhesion is produced. When the surfaces are extensive, it is impossible to prevent their accretion, even if we see the case from the beginning; at least I failed completely in a case where the lower lid and globe were thus injured by mortar, and where I took every pains to prevent the parts growing together. The accretion varies in extent and firmness; there may be a close and firm union of the entire lid and globe, or merely slender and loose bridles of connexion; or any intermediate degree between these. The slender frena may be divided and dissected off, if there be any useful purpose to be accomplished; and there would be no difficulty in separating the more extensive and close connexion; but the constant apposition of the raw surfaces reproduces the union, so that the inconvenience may be considered irremediable.†

[M. Petrequin says, (*Traité d Anatomié Medico Chirurgicale*) that he has succeeded in curing this most unmanageable deformity, by the following method. He passes a needle, with a double ligature, though the adhesion; he then ties that portion of the ligature next to the eye-lid loosely, and the portion next to the eye-ball very firmly. The consequence is, that the latter ligature rapidly cuts its way through the adhesion and separates, while the former one remains for some days longer: the wound on the eye-ball is thus allowed to cicatrize before the opposed

* Beer says, that the very rare affection, congenital ancyloblepharon, had come under his observation, and that he had operated both with and without successful result. *Lehre*, vol. ii, p. 123, note.

† In case of total symblepharon of both eyes from ill-treated catarrhal blennorrhœa, Beer separated the lids from the globes, and found the latter natural, excepting the opacity of the cornea. The adhesion was partially renewed while Dr. Juengken, who mentions the case in a letter, had the opportunity of seeing the patient.—Graefe und Walther's *Journal*, vol. i, p. 521.

"Quant à l'adhérence des paupières au globe," says Demour's, "je l'ai vu plusieurs fois plutôt augmentée que diminuée, après une opération tentée pour la détruire." "Au rapport de M. Richerand, M. Boyer a vu trois fois cette adhérence se renouveler."—*Traité des Maladies des Yeux*, tom. i, p. 113.

surface of the eye-lid is exposed by the separation of its ligature, and all danger of a relapse by reunion of the divided surfaces is thus prevented.]

Epicanthus.—The present seems the only convenient opportunity for mentioning a congenital peculiarity of structure, which I have seen a few times in infants, consisting of a fold of skin at the side of the nose projecting from one to two lines, covering the internal canthus, and apparently limiting the separation of the lids. The prominent edge of the fold is nearly perpendicular, or it may be a very little concave. The effect on the movement of the lids has not been sufficient in the cases I have seen to require remedy by operation. Professor Ammon,* who has described the case under the name of *epicanthus*, has proposed an operation for it; and Graefe† seems also to have operated in a case.

[*Epicanthus* consists in a fold of skin projecting in such a way from the side of the root of the nose, over the inner angle of the eye, as to cover the caruncula lachrymalis and inner portion of the globe of the eye. The free edge of the fold is somewhat cresentic, and its extremities are continued into the skin of the upper and lower eye-lids. (See fig. 42.) It prevents the eye-lids from being completely opened, and thus interferes with vision. This conformation, has been supposed always to be congenital and to exist on both sides at the same time, but M. Carron du Villards‡ asserts that he has three times seen it spontaneously developed at an advanced age, where there was no congenital trace of it,—twice as a sequel of scrofulous and once of variolous ophthalmia,§—and that he has also seen it on one side only. How those diseases, however, can possibly give rise to this deformity, we must confess ourselves unable to conceive. In the only two examples we have met with of it,—a lady and her child,—it was congenital and existed on both sides.

Fig. 42.

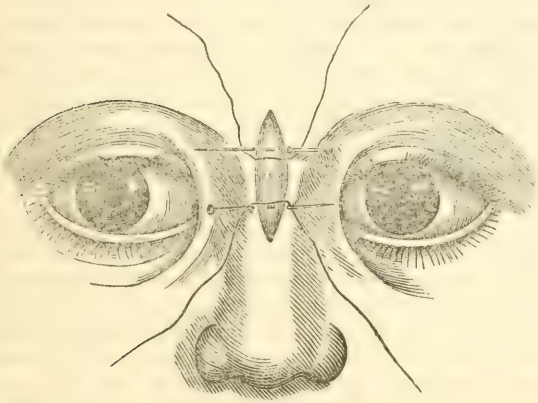

When this deformity is sufficiently great to impede the opening of the lids, it may be removed by pinching up a longitudinal fold of skin of sufficient size to efface the epecanthis, including this fold in two elliptical incisions, removing it and then bringing together the edges of the wound by harelip suture. (See fig. 42.) Dr. Ammon calls this operation *Rhinoraphy*.

Another operation has been tried, which consists in dividing the fold of skin itself transversely and trying to prevent its immediate reunion, but with little or no benefit.

Dr. Mackenzie says if the folds do not exist in any great extent, the

* *Zeitschrift*, vol. i. No. 34. plate 5. † *Ibid.* vol. ii, No. 4, plate 1, fig. 8.
‡ Bulletin Général de Therapeutique, July. 1838, p. 45, 47.
§ Ibid.

rising of the nose, as the person advances in age, may perhaps have the effect of obliterating them.*]

SECTION VI.—TUMOURS.

There is a great variety of these, some of them being analogous to what we meet with in other parts, while others are peculiar to this situation.

Nævi materni occur not unfrequently on the eye-brow or upper lid. In a large one occupying the latter situation, the employment of the knife would be inadmissible, not only on account of dangerous hemorrhage, but also because the cicatrization of the wound might cause shortening or eversion of the lid. In such a case I lately employed the ligature with perfect success; the basis of the growth was so large, that I found it necessary to tie it in three portions.

In an infant of six months, there was a subcutaneous nævus as large as a filbert, occupying the inner half of the upper lid, and its entire thickness. It formed on the conjunctival surface a soft purple prominence, marked by superficial sulci. Through the centre of this growth I passed a seton, which was followed by profuse arterial hemorrhage: pressure soon stopped it. The seton was taken out at the end of a week. The increase of the nævus was arrested; but when the patient left town at the end of five or six weeks its size was not diminished. This operation was performed in the spring of 1832, and I saw the patient again last autumn (1839.) The disease had entirely disappeared, and the only trace of the operation was a slight tuck of the integument not noticeable on superficial inspection.

In newly born children I have frequently seen red marks, sometimes of considerable extent, on the lower part of the forehead, eye-brows, and eyelids. The skin deviates from its normal state, merely in this circumstance of redness, which is owing to an unusual development of its minute vessels. Sometimes the color becomes faint, or even disappears, while it is augmented to a bright scarlet tint on crying or holding the breath. No surgical treatment is required as the preternatural color gradually goes off. Still, for some years, the original situation of these marks is rendered visible when the vessels are distended, as by crying. If it should be necessary to adopt some local treatment, to satisfy the minds of parents, the red parts may be occasionally wetted with an evaporating lotion of rose water with some alcohol; or an astringent might be tried, such as a solution of alum.

Encysted tumours are met with not unfrequently in the neighborhood of the eye-brow and lids. They may be situated under the skin, as in other parts of the body, and may be removed by operation in the usual way.

Another description of these swellings is found in infants and young children, most commonly near the external canthus, on the neighboring surface of the frontal bones; less frequently at the internal or nasal end of the eye-brow. The history given by the mother, leads to the opinion that they are congenital. The swelling, about the size of a pea or a horse bean, is a colorless elevation, with the integuments covering it loosely, so that they can be pinched up into a fold. They increase in size, without attaining considerable magnitude; I have, however, seen in the adult a tumour of this kind, at least an inch in diameter. They must be removed if they cause, or are likely to produce conspicuous deformity. On this account their excision is commonly desired in females. They are sometimes stationary, when, if the swelling be of moderate size, their is no necessity for operation. I am

* Treatise, p. 185.

acquainted with a gentleman, who has had through life a larger growth of this kind; it causes an unnatural fullness near the external angle of the eye, and has never been attended with the slightest uneasiness. Unless examined by the hand, it might be taken for an unusual development of the skull. The disease consists of a thin but compact cyst, with white glistening surface, containing fat, sometimes of oily consistence, sometimes firmer, and short hairs mixed with it in various proportions. If this admixture of hairs, which resemble those of the eye-brow in length, to be regarded as an exemplification of the principle so frequently observed in adventitious structures; viz. that they resemble in nature that of the textures in which they grow, or that of the parts in their immediate vicinity? These cysts, although they seem loose on external examination, are placed under the orbicularis, and adhere more or less firmly to the bone, which is sometimes indented; the smooth lining of the cyst and the hairs, would lead us to consider these cysts as cuticular; we should not have expected to find such a structure under the muscles.

In all operations on this region, the external incision, if circumstances admit, should be parallel to the fibres of the orbicularis. In the case of these cysts, it should also be free, that we may have room enough to expose the cyst clearly, and to dissect it away from the bone, without cutting or breaking it. The removal of the whole cyst must be accomplished, and especially care must be taken to effect this, where it adheres to the bone. If a portion of the bag is left the wound will not close; such an occurrence being annoying to the patient, and discreditable to the operator. I saw a young lady, in whom such a tumour as those I have described had been removed from the root of the nose, at the interval of the eye-brows. She was a handsome person, and had submitted to the operation for the removal of what she deemed a blemish, though it must have been slight, as the tumour was inconsiderable. She was much worse off after the operation than before; for the wound did not heal; at least it sometimes scabbed over, and sometimes discharged. A probe introduced into the opening went down apparently to the bone. Having learned the nature of the swelling, and that the operator had experienced unexpected difficulty in separating it from the bone I concluded that a bit of the cyst had been left behind, and to ascertain that point, I proposed an incision, to which the patient readily assented. I found, closely adhering to the frontal bone, a small strip of the cyst, conspicuous by its white glistening surface, and having a few short hairs on it; this was easily removed, and sound cicatrization quickly followed.

Mr. Tyrrel* recommends that these encysted tumours should not be meddled with, when they are attached to the bone, having seen inflammation with sloughing, exposure, and exfoliation of the bone resulting from such operations. I have never witnessed any thing of this kind.

The lids are subject to the formation of tumours, which may be called half-encysted,† containing a small quantity of white milky matter, in an imperfectly formed cavity. They appear first as a small smooth prominence, with a flattened surface, and a small pin-hole in its centre; they gradually increase in size to that of a pea, a horsebean, or the end of the finger. Pressure will squeeze out a little soft white matter from the central opening. They sometimes inflame; the aperture enlarges, and the cavity of the cyst is exposed, as an irregular fibrous surface, producing a copious discharge, with surrounding inflammation and excoriation. There

* Vol. i, p. 480.

† These growths are called *albuminis tumours* by Mr. Mackenzie, p. 154; *glandiform tumours* by Mr. Tyrrel, vol. i, p. 469.

is generally more than one, and often they are numerous in both lids; they are also seen in other parts of the face, but less frequently. The easiest mode of removing them is to split them in two with a small sharp knife; we may then with a forceps take hold of the divided halves, and pull them gently out; very little force is sufficient to separate the loose cellular adhesions of the tumour to the surrounding parts. The tumour is lobulated and granulated on the surface, soft and whitish, and has a small cavity in the centre. In this mode of proceeding, no skin is removed. Lay a soft rag dipped in cold water over the eye and keep it damp; the part heals readily, and no mark is left. If it should have begun to ulcerate, it will be sufficient to take a caustic pencil and touch the exposed surface; the tumour then drops out in a day or two. Sometimes it is spontaneously detached under the inflammatory action, and the surface heals.

Tarsal tumours.—These, which are of frequent occurrence, grow from the tarsus, to which they firmly adhere, and form small external swellings, sometimes reddish colored, on the lids. They are covered externally by the integuments and the fibres of the orbicularis. They seldom grow larger than a pea or bean, and do not give much trouble, except producing a sense of heaviness in the lid. By inverting the lid, more particularly the upper, the part of the tarsus from which the tumour rises may be distinctly seen: the cartilage is rendered thin at that part, so as to show the size and situation of the base of the tumour. The contents are various; sometimes there is obvious redness, and the production is inflammatory; pus is contained, and the case may be considered as chronic abscess of the lid. Sometimes there is a glairy fluid; sometimes a soft vascular tissue breaking down under the probe. These swellings may probably be diseased Meibomian glands. The general rule given for operating on tumours of the lids, is to cut down through the skin and orbicularis, and dissect them out. This is a painful operation, and cannot be strictly executed, as the basis cannot be insulated from the tarsus; to separate the tumour entire, it would be necessary to cut through the cartilage, and thus make a button-hole in the lid. However, this external incision and dissection are unnecessary; it is sufficient to invert the lid, and to puncture the thinned portion of the tarsus, with a sharp-pointed double-edged knife: the pus, glairy fluid, or whatever else it may contain, escapes; nothing more is necessary, the cavity contracts, and the place soon heals. Supposing the tumour not to contain fluid, but to be of a vascular texture, then a second incision should be made at an acute angle to the former, so that a little triangular flap is produced, which may be cut out with the scissors; then break down the soft texture with a probe. In a few days a soft kind of fungus projects, which we cut off with the scissors, and the part heals.

Tumours sometimes form upon the inner surface of the eye-lid, just at its orbital edge, where they are merely covered by the conjunctiva. If we invert the lid, we can remove them very easily, transfixing them with a hook and drawing them out. It is better to do these little operations on the inside than on the outside, if we can; there is less to be cut through, and less risk of unpleasant scar.

An indurated tumour of undefined margin, occupying the edge of the lid, is described under the name of *chalazion*, or *grando*, which are the Greek and Latin terms for hail: the German gives it the corresponding name of *hagelkorn*. It is said to be the indurated remains of a stye, which has not suppurated regularly: Hence it has been called *hordeolum induratum*. BEER's chapter* on this subject is a most unfortunate speci-

* *Lehre*, vol. ii. p. 139.

men of pathology and treatment. He says, that this indurated stye may assume a scirrhous character in scrofulous subjects, and that if such persons should become affected by any other kind of dyscrasia or cachexia, such as syphilis, itch, gout, scurvy, the complaint may go on to carcinomatous ulceration. Rosas* gives a similar representation. If the complaint should not be removed by the farrago of applications recommended, extirpation is advised. I have never seen the remains of a stye become troublesome, nor found it necessary to cut away such substances as those described by the name of grando. I am quite at a loss to account for the strange notion that hordeola may be metamorphosed into scirrhus and cancer.

Milium and Phlyctenula.—Small white tumours are sometimes seen on the margin of the lids. They are about equal to the head of a large pin or they may be rather larger. They consist of a thin but dense membrane, containing a soft white substance like boiled rice. They are called *milia*; and generally occur in elderly persons. They cause no inconvenience, when they remain stationary, and attain only a limited size. When it is wished to get rid of them, they are easily removed by transfixing them with a hook, and cutting them out with scissors. If they are deeply imbedded, a little nick may be made on each side with the knife, before using the scissors.

The same observations are applicable to watery vesicles of the ciliary margin (*phlyctenula.*) I have seen the edges of both lids on each side studded with a mixture of these milia and phlyctenulæ without any inconvenience to the individual. If patients should object to the use of knife or scissors, these cysts might be got rid of by puncturing then freely, removing the contents, and touching the internal surface with nitrate of silver.

Verrucæ.—Warts are seen occasionally, but not frequently, on the edge of the eye-lid. They may be confined to the ciliary margin, or the integument; or they may occupy both. They are rough or fissured on the surface; sometimes of brownish color, with short stiff hairs: they may be pedunculated, or have a broad basis. They may be snipped off with scissors, or removed by ligature; and the part from which they have grown, may be touched, if necessary, with the nitrate of silver or a particle of strong acid.

[*Horny excrescences on the Eye-lids.*—Dr. F. A. Ammon has twice observed horny growths on the eye-lids. The cases were as follows:—A stocking-maker, forty years old, healthy and strong, had a horny growth, three lines large, on the right upper eye-lid, a few lines from its ciliary margin. It had grown gradually, and turned downwards. The patient believed that it came from a wart; and he came to Dr. A. only because he had lately often struck the growth, and given himself pain. Dr. A. cut it off with scissors, going rather deep into the healthy skin, and the wound bled considerably for some time. When it had ceased bleeding it was touched with nitrate of silver, and in twelve days it was completely healed. Two years have elapsed, and the disease has not reappeared.

The most accurate examination detected nothing more than that the horn was a dark cartilage-like substance, uniform from its apex, and consisting of several close lamellæ. Where it was connected with the skin, there was seen an intermediate substance like a thickened cutaneous gland.

In the second case, Dr. A. observed the disease in a woman fifty years

* *Handbuch*, vol. ii, § 209. Juengken states that cancer of the eye-lids may arise from chalazion or warts badly treated.—*Handbuch, p.* 603.

old, who had ceased menstruating for some time, and had had warts on many parts of her body successively, which, however, were always removed by the remedies she applied. From a wart on the left upper eye-lid, a horny excrescence had gradually formed, which was upwards of four lines high, inclined to one side, and smaller at its apex than at its base. It gave no pain, but it often itched, and when the woman scratched it, it bled. Dr. A. extirpated it with scissors, and it has not been reproduced.

As far as Dr. A. knows, among the cases of horny excrescences decribed by authors, there is none of a *cornu cutaneum* of the eye-lids.—*Monatschrift*, July, 1840.]

Pediculi ciliorum, phtheiriasis.—Foreign writers speak of lice found on the cilia, and occasioning ulceration of the lids, or even external ophthalmia. A child came to the London Ophthalmic Infirmary, complaining of the eyes being sore, and that they itched. I looked at the eye, which did not appear diseased; but I thought that the cilia were thick, and I found, on a closer examination, that there was an infinite number of pediculi sticking over the hairs. I ordered the free application of the citrine ointment, and wished to see its effect; but the mother, who came with the child was not pleased at learning the nature of the complaint, and did not bring the child back again. The mother and child were clean in person and dress, and of respectable appearance. I have seen these vermin on the eye-lashes in one other instance only. In general appearance they resemble the crab-lice (*pediculi pubis*) more than those of the head.*

Loss of the eye-lashes may occur spontaneously; at least without inflammation. I have already alluded to the subject at p. 124.

CHAPTER III.

Injuries of the Eye-ball.

SECTION I.—WOUNDS OF THE GLOBE.

The general principles of treatment are the same for all wounds. They comprise the removal of extraneous substances, keeping the edges of the wound in apposition, and the employment of such local and general means as are best calculated to prevent or lessen inflammation. These are repose of the injured part, and the protection of it from all causes of excitement; rest of the body generally, when the organ is important, or the mischief considerable; evacuation of the alimentary canal in the first instance, and maintaining its regular action subsequently: a mild and unexciting diet. The great importance of the part, and its susceptibility of inflammation,

* Demours states that neither he nor his father had ever seen lice on the cilia. *Traité des Maladies des Yeux*, tom. i. p. 81. Scarpa says that he had seen one instance, and that the pediculi were only discovered by examining the roots of the eye-lashes with a powerful lens. They had occasioned an obstinate affection of the eye, which was speedily removed by applying mercurial ointment to the eye-lids and eye-brow. He observes that a case of the same sort is mentioned at the end of Guillemeau's *Treatise on diseases of the Eyes*, and that similar cases are related in the 24th volume of Corvisart's *Journal*, August, 1812. *Treatise*, &c. translated by Briggs. Ed. 2, p. 173.

require that these circumstances should be attended to, in wounds of the eye and its appendages, more carefully than in many other instances.

Conjunctiva.—Slight injuries of the membrane, such as rubbing by the end of a finger or the edge of a hat, the wounds of scarification, or in removing a pterygium, are unimportant, and require only the simplest management. A considerable laceration of the membrane, if accompanied with separation of the edges, might require a fine ligature, and greater care to guard against the occurrence of inflammation.

Ecchymosis of the conjunctiva, accidental and spontaneous.—External violence may occasion rupture of vessels and consequent effusion of blood into the submucous cellular tissue. The membrane presents a discoloration, of light or deeper tint, as if blood were injected into its texture; and the quantity may be sufficient to raise it from the subjacent parts. The tint is at first a bright red, and it gradually becomes a deep brownish red; the more superficial the effusion, and the smaller in quantity, the more vivid is the color; when it is deeper-seated and abundant, the part has a dark liver color.

This conjunctival ecchymosis may be produced by violent efforts, as in coughing, and it sometimes comes on spontaneously. The patient is frightened when he sees the eye discolored; and the appearance may puzzle a surgeon not conversant with the phenomenon.

Ecchymosis is distinguished from inflammation of the conjunctiva by the entire absence of distended vessels, of pain, and all other inflammatory symptoms; and by the uniform dark reddish brown tint of the discoloration, which continues to the edge of the cornea, and there terminates abruptly. The absorbents will remove the effused blood in a week or two; and I am not aware that its appearance can be materially accelerated by surgical treatment. The application of cold may be resorted to at first; and then a weak solution of sulphate of zinc may be used as a collyrium. I never saw the discoloration last long, nor lead to unpleasant consequences. It may occur in conjunction with more serious injury to the globe; but when it exists alone, it requires no further treatment than what I have specified.

Wounds of the globe.—Its delicate organization, vascular and nervous structure, and great sensibility, render it liable to inflamation; consequently wounds inflicted on it are dangerous. Surgical operations, which are executed with the sharpest and smoothest instruments, and performed with the greatest care and gentleness on persons carefully prepared by previous attention to diet and medicine, often excite serious inflammation; we cannot therefore be surprised at the violent and destructive disturbance caused by wounds made with rough, ragged, or blunt bodies, inflicted violence, and on subjects in a state of body favourable to inflammation.

The extent of the wound, the amount of violence, and the state of the constitution, are the circumstances of chief importance in determining the degree of inflammatory reaction. Small wounds gently inflicted are not dangerous; such as the wound of the cornea in kerato-nyxis, and in the evacuation of the aqueous humour, and the puncture of the tunics in depression. Larger wounds, such as the section of the cornea in extraction, when gently inflicted, often cause no inflammation. The very smallest, when violent, are attended with great danger, from laceration of the delicately organized part, and concussion of the nervous structure. I saw complete amaurosis caused by a single small shot, which struck the sclerotic obliquely and did not enter. The state of health at the time of the occurrence is, however, in most cases, a matter of more consequence than the extent or manner of the injury: in an individual of full habit, or one whose circulation is habitually excited by indulgence in the enjoyments of the ta-

ble, or whose health is disturbed by disorder of the digestive functions, slight injuries may excite considerable inflammation; while under opposite circumstances, we are sometimes surprised to see how much violence is inflicted with impunity on this delicate organization.

In consequence of the serious inflammation they so often excite, inflammation affecting the interior of the organ, penetrating wounds of the globe, that is, such as pass through the cornea or sclerotica, must always be deemed important cases. The patient should remain quiet, and the wounded organ must be kept perfectly at rest; the alimentary canal should be effectually cleared, and low diet strictly enjoined. If the individual be young and robust, or of full habit, or if, from any other circumstances, considerable inflammation may be expected, a full bleeding from the arm should take place; supposing the propriety of this treatment to be doubtful, it will be safer to bleed than to omit it, taking a moderate quantity, and observing the effect on the circulation. In a child, leeches should be applied to the eye-lids; from four to six or eight. If blood should not be taken soon after the accident, the patient must be closely watched, and bleeding, cupping on the temple, or leeching be resorted to, as soon as pain comes on in the part. The cupping or leeches must be repeated until all uneasy sensation shall have subsided.

Extraneous substances are to be removed, if there should be any such in the wound. This rule, however, is not absolute. The point of a cataract knife was broken of in the operation, and remained in the anterior chamber, from which it soon disappeared without any injurious consequences to the organ. I have seen this take place, and think it better to leave a minute particle of steel in the anterior chamber, than to perservere in attempts at removing it, if it should not come out easily.

Cornea.—I saw considerable uneasiness, which lasted for two or three days, from a small and just perceptible scratch of the cornea, by the sharp finger nail of a infant.

A cab driver received a smart blow on the eye, with the lash of a whip, and came to me at St. Bartholomew's a day or two after, with slight redness of the sclerotica, partial nebulous opacity of the cornea, and impaired vision. By bleeding, leeching, and blistering, the opacity was dissipated, and sight completely restored in a week.

Walther mentions, in his interesting tract on hypopyon, the numerous cases of that affection, which occur every year in Bavaria, during harvest, in consequence of wounds of the cornea. The reapers, who pursue their occupation with the body bent forwards, often receive injuries in the eye from the ears or blades of the corn. They are robust men, and generally predisposed to inflammation by their laborious exertions under a hot sun, and the fuller diet and greater supply of beer and brandy which they are enabled to procure at that time. The injury in general, is merely a slight scratch of the cornea. They pursue their labours, and eat and drink as usual, either neglecting the eye, or irritating it by some popular and inappropriate remedy. In the early part of the season patients were seen with small abscesses of the cornea; then they came with matter in the anterior chamber; and after a still longer time, others presented themselves with the cornea destroyed by suppuration, with the chambers full of matter, or the globe burst. Walther found that in the Isar district alone, from fifty to sixty eyes are annually lost in this way during the harvest.*

Wounds of the cornea produced by particles of metal, or other minute substances, cause different degrees of inflammation in different individuals.

* *Merkwürdige Heilung eins Eiterauges*, &c., second edition. p. 25.—27.

In some cases there is neither local disturbance nor uneasiness; at least nothing more than mechanical irritation on motion; while in others, where the person is of full habit, or continues laborious exertion, especially under exposure to heat, and combined with free drinking, severe inflammation of the cornea, sclerotica, and interior chamber generally, with hypopyon, may be the result. When such inflammation begins, a pink zone is first seen in the sclerotic, round the cornea; this redness becomes deeper and more extensive; the cornea loses its transparency, often becoming quite dull and turbid; it ulcerates round the foreign particle, which is loosened and drops out. This state will require vigorous antiphlegistic measures, and unless they are of decided character, and actively pursued, suppuration of the cornea, and extension of inflammation to the chambers of the aqueous humour will result.

[The cornea is somtimes *ruptured* by blows on the eye with the fist or some projectile, though the sclerotica, being less resistant, is more apt to give way from such injuries. A very interesting case of laceration of the cornea, came under our care during the last autumn. A young mechanic struck his right eye with his fist in consequence of the sudden breaking of a cord which he was drawing tight with all his force. The cornea was ruptured about a line from its junction with the sclerotica, for nearly one third of its circumference. When the patient applied to me, a few days after the accident, there was some inflammation of the eye and a considerable staphylomatous protrusion of the iris. The inflammation yielded to antiphlogistic treatment, and the protruded iris was repeatedly touched with solid nitrate of silver which reduced the protrusion and the patient recovered with but slight impairment of vision, though the pupil is, of course, irregular, and there is a dense white cicatrix at the seat of the rupture.]

Foreign bodies in the anterior chamber.—Wounds of the cornea may be complicated by the passage of extraneous substances into the anterior chamber. Such substances may pierce the cornea, without passing through it, and project into the chamber; they may enter the latter completely, and lie in the bottom of it; or they may stick in the iris. Serious inflammation is excited and maintained by their presence. The removal of the foreign body, which seems to be urgently indicated, is not easy, especially in the inflamed state of the organ, and requires incisions with other manipulations, likely to aggravate the inflammation and lead to loss of sight. Thus we have to choose between the two evils, of continued inflammation from the presence of the irritating cause, or danger to the organ from the operation of removing it. It would be right to remove the foreign body, if its presence should keep up inflammation, and we are confident that we can accomplish the object. If doubt exists on the latter point, the attempt should not be made; and we must be satisfied with taking the necessary measures to keep down inflammation; for foreign substances sometimes become enclosed by a covering of lymph, and remain quietly in the eye.

A small shot penetrated the upper lid and entered the globe. The anterior chamber was full of blood. Violent inflammation ensued. When the blood had been absorbed, the shot was seen in the lower part of the anterior chamber, where it became partially enclosed by a whitish deposit. Cataract took place in this case, and the opaque lens was subsequently absorbed. Vision was nearly lost. When the case was described, the shot had been in the eye for six years, without exciting any further mischief after the cessation of the original inflammation.*

* Salomon in Graefe und Walther's Journal, vol. xiv, p. 457, and tab. 4. fig. 1.

Mr. TYRRELL saw a small particle of granite, and in two instances minute portions of copper cap thus encysted.*

By making a small incision near the circumference of the cornea, Mr. MACKENZIE was enabled to remove a fragment of brass, which had been struck off by a workman in chipping that metal, and had entered the anterior chamber twelve days before.†

[By the same method we removed a small fragment of trap rock, which had been projected by a blast through the cornea, and had lodged in the anterior chamber, where it had remained eleven days.]

Professor AMMON opened the cornea in two cases, removing a piece of slate which had been driven into the iris, in one instance; in the other, a piece of sandy matter. Vision was entirely lost in the latter case.‡

A piece of glass, two lines in length, was removed from the anterior chamber at the end of six years, by Dr. C. JAEGER of Vienna. Great and almost constant suffering had been caused by its presence, and the cornea had once been opened for its removal unsuccessfully. After the removal of the foreign body, vision is said to have been nearly perfect.§

[When the foreign body lodged in the anterior chamber is very small, it is sometimes sufficient, for its removal, to make an incision of the cornea as for the extraction of cataract, though smaller, when it will be washed out by the gush of aqueous humour which takes place the moment the incision is completed. More generally, however, especially if of any size, it remains, and its removal with the least possible injury to the surrounding delicate structures is of the utmost importance. If the body is very flat, it may be seized with a pair of delicate forceps, but if cubical or round, it will slip from the grasp of such an instrument, and a curette, or what we have found to answer extremely well, a small Anel's probe, with one end bent in the form of a small hook, should be used.

As a general rule, foreign bodies in the anterior chamber should be removed; but in some cases this cannot be accomplished without certain destruction to the organ, and under such circumstances, especially if the body be small and metallic, we may be satisfied, as recommended by Mr. Lawrence, with taking the necessary measures to keep down inflammation. The safety of such a course is shown by the following case.

A lad, 29 years of age, in firing off a gun, was wounded in his right eye, by a small portion of a percussion cap. The fragment penetrated the cornea about a line from its junction with the sclerotica, at its outer and lower part, and passing upwards lodged in the iris, about a line from its pupillary margin.

Two days afterwards (Sept. 29th, 1842) the patient came to town and placed himself under my care. His eye was considerably inflamed, but not painful; the transparency of the cornea was impaired, presenting the appearance of wrinkled glass; the color of the iris was changed, and the fragment of percussion cap could be indistinctly seen adhering to the last mentioned part.

Antiphlegistic measures were resorted to, consisting of venesection, which was several times repeated, saline purgatives, diet, and nitrous

* Vol. i, p. 367.

† *Practical Treatise*, p. 367.

‡ *Beobachtungen über das Eindringen fremder Körper in die vordere Augen Kammer, in die Iris, Cornea und Conjunctiva Cornea*: in the same Journal, vol. xiii, with figures representing the eyes and the foreign bodies. Colored representations of the first case are also given in the *Klinische Darstellungen*; p. i, tab. 11, fig. 1—3.

§ AMMON'S *Zeitschrift*, vol. iii, p. 103.

powders, the latter being given for the safety of the iris so as to produce ptyalism.

Under this treatment, by the 1st of October the inflammation was entirely subdued; the cornea, except at the seat of the cicatrix, had entirely recovered its transparency; the iris had resumed its natural color except at the point to which the foreign body was attached, and where it was paler and evidently adherent to the anterior capsule of the lens, rendering the pupil slightly irregular. The fragment of the capsule could be distinctly seen; it was angular, about a line in its greatest extent, and presented the characteristic color and bright lustre of copper. Vision was as perfect with this as with the other eye. On the 8th of October, he went home to the country; promising to return should there be any recurrence of inflammation.

I did not see him again until Jan. 1844, nearly a year and a half after the injury, when he informed me that he had not experienced any ill effects from the presence of the foreign body in his eye, and that his sight was unimpaired. A small dark spot on the iris is the only trace now to be discovered of the fragment of copper, it having been either encysted or more probably oxydized, and perhaps in great part absorbed.]

Gun-shot injuries of the eye are generally attended with the passage of a foreign body into the organ. If a small shot, penetrating the external covering, passes deeply into the globe, loss of sight may be expected. Serious concussion is produced at the time, usually with instant loss of sight; severe internal inflammation follows.

A gentleman received a shot in the left eye-ball, causing instant blindness. Severe neuralgic pains came on in a fortnight, affecting the left eye and head, and influencing the right eye so seriously as to interfere greatly with the employment of it, and to make him fear that loss of sight would ensue. At the end of six years, the severity and continuance of his sufferings induced him to have the globe extirpated, which was done by Dr. Butter, of Plymouth. A duck-shot was found in the optic nerve, close to the retina.*

Injuries of the eye by portions of exploded percussion caps are not unfrequent. The metallic particle is sometimes imbedded in the cornea, when it causes inflammation and ulceration. It thus becomes loosened, and is brought into view, if it should have been previously concealed. It should be immediately extracted.

Frequently it passes into the anterior chamber or more deeply, and excites inflammation which proves destructive to vision.†

Mr. Watson‡ mentions two cases, in which blindness followed immediately on accidents of that kind, though there was no apparent wound of the eye.

Mr. Crompton has described the effects of these injuries from cases which he had the opportunity of observing in the practice of Mr. Barton, of Manchester. He preserved notes of seven cases, in each of which the injured eye was destroyed; while in one of them the vision of the other eye was nearly lost from sympathetic inflammation. In these cases, the fragment of the cap was driven into the posterior chamber of the eye; the wound was a clean one and healed readily, so that the entrance of the

* *London Medical Gazette*, vol. xiii, p. 888.

[† An interesting case, in which a fragment of percussion cap which had penetrated the cornea and entered the iris, was removed by Prof. N. R. Smith, and the sight preserved, is recorded by Prof. Sewall in the American Journ. Med. Sc. for Aug. 1850. We have met with several accidents of this description, but they are so common and the treatment is so well established, that it is unnecessary to dwell upon their details.]

‡ *Edinburgh Medical and Surgical Journal*, vol. xliv, p. 106.

foreign body was not known at the time. The cases seemed to proceed favorably for a length of time, varying from a few days to a month, when violent inflammation came on with acute pain, chemosis and haziness of the cornea. The pain would subside and recur, the eye continuing in a state of chronic inflammation, with loss of vision, injured health, and sympathetic affection of the other eye. The latter consisted, in one instance, of iritis with closed pupil. The treatment adopted by Mr. BARTON, in order to remove the painful affection of the wounded eye, and to relieve the other form injurious sympathetic influence, consisted in making a free incision of the cornea, as in the operation of extraction, cutting off the flap with scissors, and covering the eye with a poultice; within a few days after the operation the foreign substance was, in all cases, discharged from the eye.*

[Wounds of the eye by projectiles sometimes occur, in which it is difficult to determine, especially if the patient be not seen until some days after the accident, whether the body has merely ruptured the coats of this organ or has entered deeply and remains buried in the vitreous humour. Several examples of this kind have come under our observation, one of which we will relate.

Michael Mather, aged 37, engineer, was admitted into Wills Hospital Aug. 16th, 1843. The patient states that while at work on the 24th July, repairing a locomotive, in smoothing with a chisel and hammer a part of the engine, a piece of iron flew off and struck his right eye. A physician in the neighbourhood was called, who said the fragment of iron was not in the eye, and this was confirmed by his fellow workmen who asserted that they had seen it fall out. The wound extended from the inner angle to the centre of the cornea. Inmmediately after the accident, he was brought from Parkesburgh, where the accident happened, to the city, and entered the Pennsylvania Hospital, where he remained under treatment for ten days; but at the end of that time, becoming dissatisfied, he returned home. On the 16th Aug. he again came to the city, and was admitted into the Wills Hospital, under the care of my colleague Dr. Littell. At this time all the tissues of the eye were involved in severe inflammation, and active antiphlogistic measures were adopted for relieving this condition. These were only partially successful. The inflammation was subdued but could not be extinguished, and relapses took place without apparent cause. On the 1st of October, when I took charge of the house, he came under my care. The history of the case led me to suspect that the foreign body was still in the eye. This organ being now entirely disorganized, vision wholy extinct, and fearing sympathetic iritis in the other eye, I determined to open the globe. With a view of first reducing the existing inflammation, a small venesection and a dose of salts were directed. The next day the inflammation was so reduced by these measures that the operation was postponed. A few days afterwards, the inflammation was again relighted, and some symptoms of sympathetic iritis appearing, I determined to operate at once. Accordingly on the 10th Oct. I divided the cornea as in the operation for the extraction of cataract. The iris which was closed and its tissue changed by a profuse deposit of lymph was then opened, when a large drop of pus appeared. The foreign body could now be felt with the curette, imbedded in the vitreous humour, and was manifestly too large to be extracted through the opening made. The flap of cornea was therefore removed, and an incision made with the scissors, extending from the cornea to the external angle of

* *London Medical Gazette*, vol. xxi, p. 175.

the eye. The foreign body was then grasped with a pair of forceps and removed, though not without difficulty, from the mass of lymph which had been thrown out around it, and which agglutinated it to the surrounding parts. The patient at once recognized it as a fragment of the head of the iron chisel which he had been using, and which he must have struck off with the hammer. It was of a flattened pyramidal form with a rectangular base, two of the sides being half an inch and the other two seven-twentieths of an inch, and its height five-twentieths of an inch. It weighed fifteen grains. The patient recovered without a bad symptom, and he was discharged on the 28th of October.

The globe has of course collapsed, but it is free from inflammation, and all trace of sympathetic iritis in the other eye has disappeared. I have since frequently seen him, and he informs me that he has had no suffering from his eyes since he left the hospital.

A case very similar to the above is related by M. de Castelnau, in the *Archives Générales de Médecine*, for Oct. 1845.

The foreman of the iron works at the Versailles railway, a man about thirty years of age, was wounded in the right eye on the 29th of June, 1844, by a piece of steel on which the men were at work, and which had been struck off by a heavy hammer. All the symptoms of a foreign body in the eye were immediately manifested, accompained by severe pain and instantaneous loss of vision. M. Sichel, whom he consulted, found a perforation of the cornea, but could not discover the piece of steel; he concluded, therefore, that it had been removed, and directed all his attention to the prevention of inflammatory symptoms, at the same time warning his patient that he must not hope for the restoration of vision. The treatment pursued was sufficiently energetic, but the pain continued very severe, accompanied by an effusion of the aqueous humour, which excoriated the cheek. The wound of the cornea not having been cicatrized at the end of a month, the patient consulted M. Carron du Villards, under whose care it healed in a few days. All the severe symptoms were then gradually relieved, and the man could resume his avocations, but the vision of the injured eye which at first enabled him to distinguish light from darkness, gradually diminished, and was finally quite lost about eighteen months after the accident.

Three years and a half had elapsed when he was seen by M. de Castelnau; he was then suffering from pains in the eye, which were at first dull and slight, but gradually became so severe as at times to prevent his sleeping the conjunctiva was rather red, and the centre of the cornea presented a peculiar conoid appearance, which at once attracted M. de Castelnau's attention, and induced him to ask whether the eye had been struck by a foreign body. He then learned the preceding facts, and was informed that from the appearance of the block of steel whence the piece had been chipped, it must have been of comparatively large size, unless it had been broken into small pieces. The cornea was quite opaque, and the eye shrunk, as if it had lost some of its contents.

A few days afterwards, the pain and inflammation having much increased, a little solid angle was seen projecting at the top of the cone of the cornea, which, by its hardness, was ascertained to be metallic. This was removed a few days afterwards, the operator finding his chief difficulty from the adhesions formed by the posterior part of the steel with the interior organization of the eye. The operation lasted six or seven minutes, and was not very painful. There was not any attack of fever, nor increase of pain afterwards; but, on the contrary, all the symptoms diminished in intensity, and soon after the man returned to his workshop.

The foreign body was a fragment of iron, having the shape of a regular triangular prism, two faces of which being nearly equal, formed a right angle, and all its angles were exceedingly sharp; it weighed fifteen grains, and was six lines and a half long.

Dr. O'Beirne relates (*Dublin Medical Press*) a curious case, in which a small nail was accidentally driven into the eye-ball, and lodged there for some days. The patient, a woman, said that while shaking a carpet, she felt something sharp strike with force against her right eye. She became sick immediately, and shortly afterwards she found on her apron a gelatinous substance, which is supposed to have been the lens. When admitted into the hospital, there was so much tumefaction and ecchymosis of the eye that the cornea could scarcely be perceived, except at one point where there was seen to be a depression, from which a bloody fluid oozed out. There was no appearance of any foreign substance in the eye; and indeed the woman herself said that the nail had been found on the carpet. In spite of the most active antiphlogistic treatment, the inflammation and suffering increased for nearly a fortnight, about the center of the cornea. Upon making a puncture there, a considerable quantity of purulent matter flowed out with decided relief to the symptoms. Dr. O'B. while making the puncture, thought that he felt the point of his lancet strike upon a hard substance, and therefore suspected that something was lodged in the eye-ball. On the following day his suspicions were confirmed; and he then extracted, not without some difficulty, a flat headed nail of about three quarters of an inch in length. The inflammation quickly subsided, but as a matter of course the sight of this eye was irrecoverably lost.]

When the cornea is penetrated, as it is not unfrequently, by sharp or blunt cutting or pointed instruments, or other bodies, the aqueous humour escapes, the cornea and iris coming in contact; but this fluid is soon reproduced, and the corneal wound unites by adhesion. When the wound is large, prolapsus of the iris often follows; the portion which thus escapes cannot be replaced by direct pressure with probe, director, or other similar instrument; at least, I never saw replacement effected. When we consider the irritable condition of a wounded eye, and the spasmodic action of its muscles, even on mere exposure, by opening the lids, we might expect increased suffering with risk of augmented protrusion from such attempts, which, if made at all, must be conducted most gently and cautiously. If the prolapsus embraced the pupillary margin or adjoining portion, the effect of belladonna applied on the brow might be tried; the action of this narcotic on the pupil might liberate the iris, if the prolapsed portion were small, and not tightly embraced by the margin of the wound. When the iris protrudes in the operation of extraction, we can replace it by gentle pressure and slight rubbing with the end of the fore-finger through the closed lids, followed by exposing the organ to light, in order to cause contraction of the pupil. This plan might be tried in the prolapsus from wound. We must treat such cases on the general principles already explained. I shall more particularly consider prolapsus iridis afterwards.

The cornea, and the surface of the eye generally, may be injured by the ignition of gunpowder. Unexploded grains are driven into the conjunctiva and cornea, and are visible by their dark color. The advice usually given, of picking them out, may be followed, if they can be removed easily. I have seen a few grains sticking in the cornea at some length of time after an accident, not exciting the mischief, which they are said to cause, nor injuring sight. Not long ago I saw a youth, in whom one globe was burst, and the other eye much hurt by a gunpowder explosion. On

the side most seriously injured, collapse of the eye-ball, complete symblepharon of both lids took place. Violent inflammation occurred in the other eye, with so much swelling of the lids, that at the end of a few days, when I first saw the patient, I could not ascertain the condition of the cornea. When the lids could be opened, there appeared little irregularities on the surface of the cornea which I supposed to be from grains of the powder. The inflammation and irritability of the eye, would have entirely precluded all attempts at removal, if I had thought of making such an attempt. When the eye had recovered, slight nebulous opacities remained in the cornea; but I could not see any gunpowder grains. The conjunctiva oculi was partially discolored, and presented at its upper part a considerable cicatrix. From the violence of the explosion, I feared that amaurosis from concussion of the retina would be found to have occurred. Vision, however, was nearly perfect.

Mr. Mackenzie* says, "I have repeatedly seen grains of powder propelled through the cornea into the lens, so as to cause cataract. In one case, a grain of powder, propelled through the cornea, traversed also the lower part of the iris, in which it left a considerable opening, and, striking the lens, produced cataract. Gradually the opaque substance cleared away behind the false pupil, and vision was restored. The natural pupil remained much longer cataractous, but at length it cleared also. The patient saw well with a cataract glass."

Metallic and other bodies driven with considerable force may be imbedded in the substance of the cornea, and excite more or less serious inflammation, their presence not being discovered till some time after the injury. Careful examination of the organ is therefore necessary where obstinate inflammation follows such an occurrence. Mr. Wardrop† extracted a portion of gold wire, which had pierced the cornea and reached the iris, fourteen weeks after the accident. Serious and obstinate inflammation had continued for five weeks in this case, and pain had been kept up since. Complete recovery quickly followed the removal of the irritating cause. M. J. Cloquet‡ removed a considerable splinter of iron from the cornea at the end of two months.

[I have extracted a number of chestnut-bur spines, which had penetrated the cornea, six or eight weeks after the accident. The subject of this case was a lad twelve years of age, admitted into Wills hospital, November 10, 1838. He stated that about six weeks previously, he had been engaged with another boy in obtaining chestnuts, and whilst looking up, a bur fell from the tree and struck his eye; some inflammation followed, which not yielding entirely to domestic remedies, and the vision of the eye being impaired, his mother brought him to the hospital. Fourteen or fifteen spines of the chestnut bur were observable in the cornea, through which coat several of them had penetrated. There was slight conjunctival redness, but much less than might be supposed from the presence of so many irritating bodies. With the point of a cataract needle, three of the spines were extracted; the eye then became so irritable, and filled with tears, and the blood vessels injected, that I thought it best to desist, for the present, from further efforts. He was ordered sal. Epsom ℥j, half to be taken at once, and the remainder the next morning. Two days afterwards, the redness and irritability had subsided, and I extracted two more spines; when I thought it prudent to again

* *Practical Treatise*, p. 308.
† Lancet, vol. x, p. 475.
‡ *Pathologie Chirurg.* p. 44.

desist, and salts were prescribed as before. By pursuing this course, all the spines were ultimately extracted. One of these spines penetrated the cornea, and seemed to enter the iris; its extraction was difficult, and I only succeeded after several trials. When removed, a portion of the aqueous humour followed. The wound healed as kindly as any of the others, and it is difficult to discover the points where the spines had pentrated. He was discharged October 29th, 1838, quite well.

Dr. Krieg, of Merzeburg, relates* a curious case of wound of the cornea by the sting of a bee. The subject of this case was a man sixty years of age. The bee had stung him in the centre of the cornea, giving rise to extremely painful inflammation. The physician who first saw him professed to have extracted the sting, but no means afterwards used were capable of subduing the morbid excitement of the organ. When Dr. Kreig saw the patient, five weeks after the accident, the conjunctiva was greatly hypertrophied, and the cornea covered with a dense opaque layer of membrane. There was every reason to believe that the internal structures, also, fully participated in the diseased process. On closely examining the eye with a magnifying glass, a dark and slightly prominent spot was discovered in the center of the cornea, around which much vascular injection was perceptible, and from this spot Dr. Krieg extracted a long filiform body, the remaining part of the sting. The inflammation soon began to subside, and in a month the cornea had partially recovered its transparency, but some striking results became permanent in consequence of the injury. The tint of the iris had changed from its natural grayish blue to a perfect blue, the pupil remained dilated and immovable on the stimulus of light, and the patient, who before his accident was obliged to use convex glasses, now required one concave, being near-sighted, on the left side.]

Sclerotica.—Wounds of the sclerotica are not of consequence in themselves, but they become important from the force which must have been required to effect them, and from the almost inevitable participation of the immediately adjoining internal tunics. A violent blow sometimes burst the sclerotic coat, without dividing the conjunctiva; the hard external covering of the eye is cracked by the injury, and we see the fissure of the sclerotic through the conjunctiva. Concussion of the retina, internal extravasation of blood, and amaurosis, are the almost invariable concomitants of such an injury. The prognosis, therefore, is doubtful, if not absolutely unfavorable in such cases. The result is sometimes more fortunate than we anticipate.

Case.—*Penetrating wounds of the sclerotica; recovery without injury to vision.*—In the month of February, 1829, a boy, ten years old, was brought to me from the distance of fourteen or fifteen miles within three or four hours after meeting with a wound of the eye. It had been inflicted by a wooden arrow, armed with an iron nail which being square, had been ground to a point, not very sharp. It had been thrown against the eye, not shot from a bow. The sclerotica was punctured just where the needle is entered in couching; there were two small divisions of the membrane, meeting at an obtuse angle. The schoolmaster, who accompanied the patient, informed me that immediately after the accident the pupil had been largely dilated, and that the boy could not see. The pupil was still dilated, and vision very confused. I directed antiphlogistic treatment, with rest; and, suspecting either that the retina had suffered by concussion, or that inflammation of the internal tunics would ensue, I gave an unfavorable opin-

* Gaz. des Hôpetaux, June, 27, 1843; from Casper's Wöchenschrift.

ion of the probable result. The patient was brought to me again, at the end of a fortnight; he had been kept on low diet in a darkened room, and leeches had been applied once. There had been no inflammation, nor pain. The pupil was of its natural size, the iris acted perfectly, and vision was good. There was a small transparent vesicle in the situation of the wound. I saw the case again in another fortnight, when vision was perfect: the vesicle remained.

Case.—*Rupture of the sclerotica, with injury of the iris; complete recovery.*—In the summer of 1837, a child, about five years old, was brought to me at St. Bartholomew's, and attended as an out-patient, having received a severe blow on the right eye with a stick. The sclerotica was ruptured near the margin of the cornea, the wound being about one-eighth of an inch in length. The corresponding portion of the iris had disappeared, so that the pupil, opposite to the wound in the sclerotica, was continued to the margin of the cornea. The conjunctiva was slightly elevated, apparently from protrusion of the missing portion of the iris. The accident had occurred three or four days before the case was seen, and nothing had been done for it. There was no inflammation or pain of the eye, the pupil was clear, the iris natural, excepting the changes already mentioned, and vision seemed unaffected. The case required nothing further than care, with a little medicine and cold lotion. The eye remained in the state described; and we ascertained, at some distance of time from the accident, that vision was unimpaired.

Wounds of the sclerotica do not unite; the fissure in the cases just described, is permanent, and the punctured opening made in depression of the cataract is equally so.

Iris.—A wound of the iris is generally an important case; it is a penetrating wound, and usually inflicted with violence. It may be cut or torn; these injuries being generally complicated, not only with wound of the cornea, but also with injury of the crystalline. A simple division of this part is, however, in itself unimportant. Although the iris, when examined microscopically after a successful minute injection, seems to be entirely composed of a vascular net-work, it does not bleed on being cut, nor does a simple division of it lead to any injurious consequences. On the other hand, it is greatly irritated by pressure. In the natural state it is unconfined, freely moving in the aqueous humor; in the condition of prolapsus, the hard edge of the cornea embraces and presses on the neck of the prolapsed portion, while the external tumour is constantly undergoing friction from the eye-lids; thus irritation is produced, which may extend to the whole globe, greatly aggravating the sufferings of the patient.

The iris may be detached by accidental violence at its ciliary margin, thus producing an artificial pupil; according to the extent of the detachment, an alteration of figure in the natural pupil, a diminution, or complete closure of it may ensue. This kind of accident is accompanied with effusion of blood into the anterior chamber.

Case.—John O'Brian, forty years of age, a blacksmith, of robust frame and accustomed to live freely, was admitted into St. Bartholomew's under my care, on the 1st of December, 1830. Two days before, as he was breaking an iron rod with a large hammer, a portion of it about an inch long was detached, and struck him a violent blow in the eye. He experienced great pain in the part after the accident, but was relieved by keeping in bed the following day, applying fomentations, and taking salts, which acted briskly. I found the globe pushed forwards, the conjunctival and sclerotic vessels distended; the anterior chamber more than half full of blood; the iris detached from the corpus ciliare, at the upper and outer part, to the extent

of three lines, so as to form an artificial pupil of elliptical figure; no pain, nor intolerance of light; incomplete amaurosis, so that the divisions of a window or a hand held near to the eye could be seen, although the letters even of large print could not be distinguished. I ordered a large venesection, an active purge, cold lotion to the eye, confinement to bed, and low diet. Dec. 2. The pupil, who performed the bleeding, finding the blood came very freely, allowed it to flow, until fifty ounces had been taken: faintness was not produced. The bowels were freely opened. The patient slept well and feels much better to day. The vascularity of the eye is diminished; vision is improved; the pulse is eighty, and soft; the tongue moist and clean. 3d. Progressive improvement. The natural pupil has assumed an oval shape from the falling down of the detached portion of the iris. The blood is completely removed from the anterior chamber. 6th. Some pain with slight lachrymation and intolerance of light: the vascularity of the conjunctiva is increased. Ten ounces of blood from the temple by cupping. 10th. He feels the eye quite well; the vision is much improved, though not so good as before the accident. The protrusion of the globe has disappeared, and the iris has nearly resumed its ntaural situation. He left the hospital a few days afterwards. I saw this person in the spring of 1832. His vision was good, and the separation of the iris was marked by a very narrow fissure, which could only be detected by close inspection.

Other instances, in which partial separation of the iris from the ciliary ligament, with formation of a new pupillary aperture, was caused by external injury, are mentioned in CHAPTER XVIII, SECTION IV.

CASE—*Effusion of blood into the anterior chamber from a blow.*—A boy, 10 years of age, came under my care at ST. BARTHOLOMEW'S on the 18th of July, 1831, in consequence of injury to the right eye from a blow with a small whip. He was brought to the hospital two hours after the accident, when the anterior chamber was filled with blood, and there was some redness of the eye. Twelve leeches were applied, and the antiphlogistic treatment was adopted in other respects. The blood had nearly disappeared on the evening of the 20th. On the 21st the vascularity of the globe had increased, and the anterior chamber was again filled with blood. (Twelve leeches; aperient medicine.) 22d. Twelve leeches; absorption proceeding rapidly. 23d. The effused blood entirely absorbed and vision perfect. He was kept in the hospital till the 1st of August, and was then discharged quite well.

A severe blow on the eye may occasion excessive partial dilatation of the pupil, the iris being withdrawn and disappearing to a greater or less extent. Such accidents are attended by effusion of blood and impaired sight.*

Discoloration of the iris or aqueous humor?—with slight concussion of the retina from a blow.—On the 7th of January, 1828, a gentleman received a severe blow on the left eye from a piece of wood projected forcibly by the sudden explosion of a fire-work: he paid but little attention to the circumstance, which did not prevent him from joining in the festivities of the occasion—the celebration of a birth-day. He merely used some lotion and took a purgative on the following day, although sight was impaired, and a globe of red appeared before the eye. Finding that he grew worse instead of better, he returned to town, where I saw him on the 11th. There was

* Such an opening, caused by the blow of a whip, is represented by VON AMMON in his *Klinische Darstellungen*; pl. 1, tab. 14, fig. 5. The iris had assumed a blue color since the accident, and the vision was but slightly injured. A similar opening, also caused by the stroke of a whip, is delineated by Mr. WARDROP, *Essays*, pl. 10, fig. 2. Sight was not injured in this case.

An instance of the kind has been figured by Mr. WARDROP, pl. 10, fig. 3.

ecchymosis of the conjunctiva sclerotica in its whole extent. The iris, which is naturally blue, was of a bright yellow, or rather yellowish green; the pupil just like the other, and moving with it. No pain in the eye or head. No increased vascularity of the conjunctiva: no inflammation, either of it, the cornea, or the iris. No inflammation of the sclerotica, which was carefully examined on account of the ecchymosis of the conjunctiva. He could see objects and recognize persons, but could not read ordinary print. (Cupping on the left temple; active aperients; light diet, with exclusion of fermented liquors; rest of the eye.) 14th. Cupping repeated; two grains of calomel night and morning. 26th. The calomel has been continued to this day, with occasional aperients, rest, and low diet. The mouth has not been affected in the slightest degree. The discoloration of the iris has gradually disappeared, and it moves just as well as the other. He can read the smallest print with ease, and is sensible merely of a slight dimness, as if he looked through a thin fog. The ecchymosed blood is nearly absorbed from the conjunctiva. September, 1828. The appearance of the eye is natural; vision is nearly, if not quite perfect.

Was the cause of the phenomena, in this case, a change in the iris, in the aqueous humour, or in the cornea? Mr. Wardrop, to whom I mentioned the case, said that he had seen the occurrence, and had evacuated the aqueous humor, when the natural appearance of the iris returned. The only circumstance which renders this explanation doubtful, is, that the chamber cleared first at the centre, and then gradually towards the circumference. When the principal portion of the iris had appeared of its natural color for some days, a little yellowness was still visible towards each angle of the eye. In a similar case, which was under my care in St. Bartholomew's, the discoloration disappeared spontaneously.

Wounds of the choroid and ciliary body—hemorrhage.—If a penetrating wound of the globe takes place behind the cornea, the ciliary body or choroid coat will probably suffer, wounds of those parts will be attended with extravasation of blood into the chambers of the eye, both anterior and posterior. It has been recommended to open the anterior chamber in order to let out the coagulated blood, and prevent further effusion. This is totally unnecessary, since absorption is very active in this chamber and the blood will be removed in a few days. I have seen it disappear in twenty-four hours. Such a wound in the cornea is not only altogether unnecessary, but must be injurious, adding to the local injury, already considerable, and increasing the chances of inflammation by the exposure of the chambers. The blood does not mix with the aqueous humour or render it turbid, but it sinks to the bottom of the anterior chamber and there remains, and in two instances I found that it retained its fluidity, so that the level was altered on inclining the head to one side: but whether this is always the case I do not know. This effusion of blood into the anterior chamber is not in itself a matter of consequence; but it shows that considerable violence has been inflicted on important textures.

We sometimes see effusion of blood behind the iris: altering the color of the pupil and making it visibly red in a good light; this must always be regarded as a very unfavorable appearance, indicating that the injury extends to the central and most important parts of the eye. Rest, cold applications, and antiphlogistic treatment are proper where blood has been effused before or behind the iris. After it had been speedily and completely absorbed under such management, I have seen a renewal of effusion in consequence of premature exertion.

When the ciliary body, or choroid coat is injured, as is usually the case when the sclerotica is ruptured, the pupil exhibits a remarkable change,

which must be referred to the partial injury of the ciliary nerves necessarily attendant on such an accident. As these nerves, which supply the iris, run between the sclerotic coat and choroid, they must suffer when those tunics are injured. Thus the iris is partially paralyzed, the portion supplied by the injured nerves being contracted to the utmost, and sometimes even disappearing, and the pupil exhibiting a corresponding partial dilatation.

When the sclerotica has been injured near the ciliary body the disappearance of the iris is attended with a dark colored bulging of the former membrane under the conjunctiva, probably produced by a prolapsus iridis in that situation. Such a case has been figured by Von Ammon.*

The *lens and its capsule* are frequently injured, when the cornea and iris are punctured by sharp instruments. As the wound is penetrating, and necessarily inflicted with more or less violence, the case is always important.

Mr. Travers saw after a severe blow on the eye, suppuration within the capsule, which projected through the pupil in a globular form, filled with pus. Absorption took place under the use of mercury, and the case ended in a contracted pupil closed by opaque capsule, and adhesion of the iris to the cornea.†

We find invariably that the lens becomes opaque when it or its capsule is wounded, and the slightest mechanical injury is sufficient to produce that effect, such as a puncture of the part with the finest needle. By introducing such a needle through the centre of the cornea and the pupil, cataract might be artificially produced without any other injury to the organ, without inflammation, and possibly without any appearances from which the maneuver could be discovered. It has been said, that soldiers have had recourse to this proceeding in order to obtain their discharge from the army. We cannot explain how or why wounds of the lens and capsule should thus invariably produce cataract.‡ We can trace no vessels into the lens from its cap-

* *Klinische Darstellungen*, pt. 1, tab. 14, fig. 7.

† *Synopsis*, p. 206.

‡ From trials on animals, made by Dr. Dieterich, it seems probable that the statement in the text respecting the invariable occurrence of cataract after wounds of the lens and capsule, is not correct. He instituted an extensive series of experiments on dogs, in competition for a prize offered by the medical faculty of Tubingen, and published the results as his inaugural dissertation, in 1824: of this there is a copious abstract in the *Archives Générales de Médecine*, Oct. 1826. He wounded the anterior portion of the crystalline capsule with a cataract needle, in various manners, thirty-six times. Opacity of the lens followed in on one case only, probably from its having been unintentionally wounded. The capsule also retained its complete transparency, and the wounds in it healed, even when it had been divided transversely, without leaving a cicatrix.

He punctured the posterior portion af the capsule seven times; lenticular cataract resulted only in one instance: but the last-mentioned effect took place in eleven out of twelve experiments of incision of the capsule. Wounds of the posterior capsule were not followed by opacity of that membrane. The punctures healed with difficulty, and incisions did not unite at all.

In seventeen experiments, the anterior portion of the lens was punctured. No visible change occurred in the eye in twelve of these; in three, lenticular cataract occurred, and in two violent internal ophthalmia. Of nine instances, in which incision was made into the interior part of the lens, four were not followed by any morbid change, while in the five others, where the wounds were deeper, cataract ensued. Superficial injuries of the lens, on its posterior surface, were not followed by cataract. Such wounds whether of the anterior or posterior part, when not accompanied with displacement, produced no change in the eye. In a few days they were completely healed. Wounds extending to the centre of the lens were constantly followed by cataract, iritis, and inflammation of the globe. Of eleven experiments in which the lens were displaced, three were not followed by cataract, while in the others opacity of the crystalline and violent internal ophthalmia ensued.

What I have said in the text respecting the effect of wounds on the lens and capsule, has been deduced from the observation of such injuries in the human subject. Hitherto I have found no reason to alter the statement; nor have I seen in man that union of

sule; its ordinary nutrition is a problem to us, and we are equally in the dark respecting its changes from accident or disease. The alteration in question is independent of inflammation; for it will occur before inflammation comes on, or even when it does not take place at all.

Traumatic cataract, as it is technically called, takes place under various circumstances; 1st. Simple puncture of the lens through the cornea and the pupil; 2dly. Laceration of the capsule, with protrusion through the opening of the exterior soft substance of the lens, in the form of a bluish white jelly;* a portion of this jelly may drop off into the anterior chamber, and be succeeded by a fresh protrusion. 3dly. Puncture or laceration of the capsule, with dislocation of the lens, which may press against the iris, or be wedged into the pupil, or push the iris into close contact with the cornea. 4thly. Passage of the entire lens through the opening of the capsule and the pupil. It may either retain its transparency or become opaque; it may remain in the anterior chamber, or pass backwards and forwards through the pupil. It may pass in the same way into the anterior

wounds of the capsule, which DIETERICH observed so uniformly in his experiments on animals.

Since the preceding remarks were written, I have found in the *Handbuch* of Professor ROSAS, analogous observations on the experiments of DIETERICH. "The result," says he, "of my experience in the human subject have led me to draw opposite conclusions to those which DIETERICH deduced from his experiments on animals. I have seen many cases in which capsulo lenticular cataract has proceeded from inconsiderable wounds of the anterior capsule, although immediately subjected to antiphlogistic treatment. I remember two instances in particular, which occurred in the time of BEER: the anterior capsule was slightly wounded in puncturing the cornea to evacuate the aqueous humour, and cataract followed in both. I have since seen the same result repeatedly from accidental wounds, both in healthy and diseased eyes."—Vol. i, § 421.

[Our own experience is in entire conformity with that of Mr. Lawrence and Prof. ROSAS. We do not remember to have seen a single case of wound of the lens and capsule, in which opacity of these parts did not follow.]

* Dr. DIETERICH* noticed the appearance of a white flocculent substance on the wounds of the capsule in his experiments, in which it soon disappeared by absorption. He observes that this may proceed from the aqua Morgagni, from the exterior semi-fluid stratum of the crystalline, or from the effusion of coagulable lymph; and he is in favor of the first explanation. Mr. WATSON† ascribes the appearance in question to the "effusion of semi-transparent albuminous matter." Mr. WARDROP‡ has given a good figure of it in his ninth plate, over which he has placed the following descriptions, "Albumen effused from a wound of the capsule of the lens." In his description of the plate, he speaks of it as a protrusion of the lenticular substance. "An opaque white matter, resembling a flake of snow, extends from the lens, which is also opaque, through the pupil, and comes nearly in contact with the cornea." "It is probable," he adds, "that in this case, the bristle had penetrated not only the cornea, but also the capsule of the lens, thus allowing the thinner parts of the lens to come through the wound into the anterior chamber."

Having repeatedly observed and carefully inspected these protrusions of bluish white gelatinous substance, not only in accidental injuries of the capsule, but also in wounds made in operations for cataract, I feel quite satisfied that the explanation of the appearance given in the text is the true one. In the human subject it occurs only in conjunction with opacity of the lens, and the flocculent matter protruding through the wound of the capsule is continuous with the opaque lens. In color and consistence it perfectly resembles the fragments of lens, which are sometimes seen in the anterior chamber after operations for cataract, while it is totally different in these respects, from any of the effusions of lymph which are seen in this part of the eye. Lastly, it may take place when no inflammation whatever has occurred in the chambers of the eye; and DIETERICH, who mentions it as a consequence of puncturing the capsule, expressly states that the capsule never inflames after such punctures. I never saw lymph effused from the surface of the crystalline capsule under any circumstances.

* *Archives* vol. xii, p. 299.
† *Edinb. Med. and Surg. Journal*, vol. xxvi, p. 265, fig. 3. *Compendium of the Diseases of the Human Eye*, p. 126, pl. 8, fig. 4.
‡ *Essays*, vol. ii, pl. 9, p, 254.

chamber, still surrounded by its capsule. 5thly. Either of the above circumstances may be combined with wound of the cornea, or of the ciliary body, or with wound or prolapsus of the iris. When the lens is dislocated, and presses against the iris, great irritation and severe inflammation ensue. 6thly. The lens may become opaque, in consequence of a blow or concussion of the eye, without any solution of continuity. I have seen many such instances.

In a patient who had received a violent blow on the eye from the fist, seen by BEER in twenty-four hours after the accident, the capsule was torn, the lens split in two, and quite opaque; there was slight effusion of blood into the anterior chamber, and considerable ecchymosis of the conjunctiva.*

Mr. BILLARD saw a patient brought to the *Hôspital de la Pitié* for a wound of the eye from a blow of the fist. The lower part of the cornea was lacerated, and the crystalline, which had escaped through the opening, was found in the patient's pocket-handkerchief.†

The dislocated lens may retain its transparency and remain behind the pupil, exhibiting a tremulous motion when the eye is moved. More commonly the lens and capsule become opaque, the latter sometimes assuming the yellow color which denotes its conversion into a cretaceous substance. In this state it constitutes a floating cataract, generally sinking below the edge of the pupil when the eye is at rest, but rising more or less considerably when it is moved.‡

The dislocated lens has sometimes been forced through the choroid and sclerotica, so as to lie under the conjunctiva. Mr. MACKENZIE mentions such a case, and delineates the appearance. The patient had recently fallen on the corner of a chair. There was a tumour under the conjunctiva at the upper part of the globe, advancing on the edge of the cornea. On laying open the conjunctiva the crystalline was easily withdrawn. The aperture in the tunics, by which it had escaped, was already closed. The patient was able to read with a cataract glass.§ Mr. MACKENZIE has seen two other cases, in one of which the eye was partially, in the other totally amaurotic.|| Mr. MIDDLEMORE¶ has seen this kind of displacement in five instances. The subject of the first received a severe blow on the eye, followed by pain and a swelling behind the edge of the cornea. After a few days he was seen by Mr. M. who found the iris drawn towards the tumour at the edge of the cornea, so that it had disappeared in that situation. The pupil was unusually clear, the eye inflamed. The tumour, situated towards the inner canthus, was convex and of yellowish color. On dividing the conjunctiva, a moderately firm lens escaped. A slight degree of vision was restored.

When the lens has been rendered opaque by wounds, under any of these circumstances, it begins to be absorbed, and this process of absorption will go on in many cases to the complete removal of the opaque body, leaving the pupil entirely clear, so that the wound is both the cause and the remedy of the cataract. That portion of lens that may be squeezed through the

* *Lehre*, vol. i, p. 218, note.

† The French translation of my lectures, under the title, "*Traité Pratique*," &c., p. 138, note.

‡ Dislocation and opacity of the lens and capsule, which had sunk in the vitreous humour, so that the upper edge only was visible in the pupil, are represented by VON AMMON; the anterior chamber was filled with blood up to the lower edge of the pupil. *Klinische Darstellungen*, pt. 1, tab. 9, fig. 20.

§ *Practical Treatise*, p. 343.

|| *Ibid.* p. 344. Other cases are recorded in F ONSTON's *Treatise*, p. 195, and in the *London Medical Gazette*, vol. ix, p. 178.

¶ *Treatise*, vol. ii, p. 44, note.

opening in the capsule into the anterior chamber undergoes absorption readily, while that which remains within the capsule is absorbed much more slowly. When the lens has been thus removed, a membranous cataract is generally left. In almost all cases of penetrating wounds, considerable inflammation supervenes, in which the capsule participates, being rendered opaque and sometimes thickened, so that when the lens is quite absorbed, a membranous or capsular cataract is seen occupying more or less of the pupil, and sometimes completely filling the opening. The iris is involved in the inflammation, and hence arise adhesions of the pupil.

The treatment of these cases, immediately after the accident, must be managed according to the general rules applicable to penetrating wounds of the globe; we must institute the antiphlogistic plan without delay, and follow it up actively, either until inflammation shall be removed, or the period for its recurrence shall have gone by. It will be right to dilate the pupil by the use of belladonna, and thus expose the lens more freely to the action of the aqueous humour, in order to facilitate its absorption. When the eye has acquired its natural state, excepting the presence of the opaque body in the pupil, the treatment falls under the rules applicable to cataract, which will be considered hereafter.

The opaque capsule does not undergo absorption like the lens; it will remain in the pupil unchanged for any number of years. I doubt whether it is ever absorbed. Beer mentions a case in which the lens had been in the anterior chamber for twenty-six years unreduced in size.* It had been displaced by a violent blow upon the eye. A patient occasionally visited the London Ophthalmic Infirmary, with the lens surrounded by its capsule in the anterior chamber, where it had been twenty-eight years.

When the dislocated lens has passed into the anterior chamber, it acts as a foreign body, irritating the surrounding parts, causing inflammation of the eye, and severe pain in the organ, brow, and head. The inflammation and pain which continue in spite of antiphlogistic treatment, may be most speedily and effectually relieved by removing the irritating cause: that is, by extracting the dislocated lens through an opening made in the cornea with a cataract knife. Sight is not usually restored, the retina having suffered by the original injury, or in conjunction with the iris and internal parts generally, from the inflammation consequent on the accident. The dislocated and injured lens may remain behind the iris, being pushed against it, or protruded into the pupil, and against the cornea. Serious internal inflammation and great pain commonly ensue. Here extraction of the lens is strongly recommended by Mr. Barton,† of Manchester, as the best way, when performed early, of preventing the inflammatory and painful consequences of the injury, or of removing them when it has been delayed to a later period. The result, as regards vision, is rendered doubtful here by the same circumstances as in the preceding case. The removal of the lens, which is usually soft, and sometimes broken up, is accomplished in these cases by a smaller incision than that of extraction. It will be sufficient to divide the cornea in one-fourth, or one-sixth of its circumference: the lens sometimes escapes on the knife, or it may be removed with the scoop.

* *Lehre*, vol. i, p. 220, note.

† *On the treatment of certain injuries of the Eye* in the *London Medical Gazette*, vol. v, p. 784. *Report on the advantages of extracting the lens in severe injuries of the eye*, by Mr. R. T. Hunt, *North of England Medical and Surgical Journal*, vol. i, p. 181: it contains the details of nine cases. In the *London Medical Gazette*, vol. ix, p. 1—4, five cases of dislocated lens are reported by Mr. Mackenzie. Extraction was performed with great advantage in three.

It must be a serious injury to reach the vitreous humour, and occasion any loss of it; we may expect as the result, not only blindness, but change of figure in the globe. The escape of this humour, in the operation of extraction will be considered under the head of cataract.

[Rupture of the capsule with dislocation of the lens, is a more frequent result of blows on the eye than is generally supposed, if we may judge from the number of instances of this accident which have come under our observation, and it is of importance to be aware of this fact, as when the patient is not seen until some time after the accident, and the lens and capsule are absorbed, the cause of the imperfection of vision which results, may not be understood. The only method by which the real condition of things can be determined is by the catoptric examination.

The following cases illustrate the nature of this accident and the value of the catoptric examination.

Case I. Mr. T. a farmer, æt. 30, whilst feeding a threshing machine, was struck in his left eye by a grain of wheat projected from the machine, which made a small wound in the cornea near its nasal margin. Severe inflammation followed, with loss of vision in the injured eye. The former was subdued by a rigid antiphlogistic treatment, followed by an alterative mercurial course, and some time afterwards vision in the eye began to return, and continued to improve until he could distinguish large objects His vision remaining then stationary, and being unable to read large print, he came to the city to consult us.

When we first saw him, which was six months after the accident, the eye was entirely free from inflammation, and the only abnormal appearance we could detect by the ordinary method of examination was a small cicatrix near the nasal margin of the cornea, to which a minute portion of the iris was adherent, with consequently, a slight irregularity of the pupil. This was not sufficient, however, to account for his imperfect vision; and we were at first inclined to attribute that defect to some disorganization of the internal tissues of the eye produced by the injury or the subsequent inflammation.

On making a catoptric examination, we found that but a single image of the candle could be detected; and after the pupil was completely dilated, a small fragment of opaque capsule became apparent. We did not hesitate on this evidence, to assure the patient, that his lens had been injured and afterwards absorbed, and that he required a lens on the outside of his eye to replace that which had been removed. I accordingly accompanied him to an optician's, and having provided him with a suitable glass, he found to his great delight that he could read with perfect facility small print.

Case II. George Haines, æt. 13, was admitted into Wills Hospital, November 2d, 1839. This lad stated that in chopping brush, seven weeks before, a fragment flew up and struck him in the left eye; considerable pain and inflammation followed. He had taken a dose of physic and been blistered by direction of a country practitioner, and his parents finding that he could not see with the eye, he was brought to town and placed under my care. At this time there was still considerable vascular injection of the eye, without much pain, however; there was a dense cicatrix towards the lower and inner margin of the cornea, and the remainder of this coat was so nebulous, that it could merely be perceived that the pupil was filled with an opaque whitish substance, but whether lymph or the capsule or lens became opaque, it was impossible to determine. The patient was ordered to be actively purged, strictly dieted, and to have an ointment composed of equal parts of extract

of beliadonna and mercurial ointment, applied daily around the eye; and when the inflammation was subdued, a collyrium of sulphate of zinc (one grain to the ounce) was employed. Under these means, the pupil became dilated, the dense mass which filled this opening diminished, and in two weeks the cornea had become sufficiently clear to enable us to see distinctly portions of lymph, some floating in the anterior, others in the posterior chamber, and adherent to the iris. The perfectly natural appearance of the iris indicated that this lymph was not the result of iritis; and the inference then was, that it consisted of portions of opaque capsule, which had been ruptured by the fragment of brush. The catoptric examination made at this time, (November 16th,) confirmed this view. But a single image of a candle was reflected; the lens doubtless had been absorbed. The treatment was continued, with the omission of the purgatives, and on the 22d of November, the pupil was sufficiently free of lymph for the patient to read in a testament through a pin hole made in a pill box. Without this aid he could not read, except large capital letters.

On the 21st of December he was discharged cured. At this period his pupil was perfectly clear, as was also the cornea, except a small cicatrix where this coat had been wounded. The perfect regular convexity of the cornea was somewhat impaired, however, by the manner in which the wound had united, but not so much so as materially to affect vision. The pupil is a little irregular, in consequence of the adhesion of the inner edge of the iris to the cornea at the cicatrix. With the aid of a cataract glass the boy could see pretty well, and with such assistance will no doubt in time have nearly perfect vision.

Some weeks after his discharge we saw this lad, at which period the irregularity of the cornea had entirely disappeared. The cicatrix in the cornea had further diminished, and his sight had much improved. With a magnifying glass he read with facility.

In an interesting case, communicated to us by Dr. James W. Kerr, the patient, a stone mason, had been struck in his left eye by a fragment of stone or of the instrument which he was using, after which he was deprived of useful vision. This continued for eighteen years without the real cause of the defective sight being suspected, when it was discovered by Dr. K. by a catoptric examination of the eye. The details of the case were published in the *American Journal of the Medical Sciences*, for May, 1840, p. 245.]

Retina.—A simple puncture of the *retina* is not attended with danger; in fact, this membrane must be frequently wounded in the operation of depression, yet such punctures do not impair its powers; a larger division will cause amaurosis.

The kind of violence most injurious to the retina is the concussion which it suffers from a blow on the eye, and the danger is in a direct ratio to the degree of force. The affection of this membrane, as evinced by the diminution, or loss of sight, is not commensurate with the apparent amount of injury to the organ. The nervous structure of the eye suffers in these cases, as the brain does in many injuries of the head; and the term *concussion* would be equally applicable to both. The employment of this word does not exclude the notion of actual laceration, or vascular rupture in either case; we merely employ it to denote the accidents in which, although the symptoms show the brain or retina to be affected, there is no visible wound. When the sclerotica is ruptured, there is either actual laceration, or concussion of the retina; but the latter kind of injury sometimes occurs from accidents of a more trivial character, in which the

degree of violence might have been deemed too inconsiderable for the effect. This injurious influence on the retina is generally produced by blows on the naked globe; the interposition of the eye-lids is sufficient to protect the eye even from great violence, as the pugilistic contests teach us. The diminution, or loss of sight, is immediately consequent on the accident, and usually accompanied with a fixed state of the pupil, perhaps with some enlargement or change of figure in the opening, and with excessive partial dilatation, where the ciliary nerves are divided or contused. There may be effusion of blood into the anterior chamber, or behind the pupil.

When we first see such a case, we should inquire minutely into the circumstances of the accident; ascertain the nature, degree, and exact situation of the injury; observe the condition of the iris and the pupil, and satisfy ourselves clearly respecting the state of vision. We shall thus be prepared to speak decidedly, not only on the present state of vision, but on the important question of its ultimate loss or recovery. If there be mere concussion of the retina, without other injury of the globe, and if sight be only partially injured, recovery may be expected under prudent management; that is, if the patient and the organ be kept in repose, and the access of inflammation be prevented. Total amaurosis immediately following the injury, is an unfavorable symptom, but does not preclude the chance of recovery under proper treatment, if it be not complicated with other injury to the organ. The addition of considerable change in the pupil, extravasation of blood, and indications of actual laceration of the retina, make the case absolutely hopeless. Under the latter unfavorable circumstances, there is, at the time of the accident, no great pain in the part, nor increased redness, but in a few days the eye becomes painful, and grows red; the pain increases, inflammation commences in the internal tunics, and spreads to the exterior, the sclerotic and conjunctiva becoming red, with pain in the head, intolerance of light, increased lachrymal discharge. The necessity of antiphlogistic treatment is obvious. As the violent symptoms subside, the eye goes into a state of atrophy, the globe becomes soft, diminishes in size, and shrinks into the orbit.

This concussion of the retina, and consequent blindness, sometimes take place from accidents, that we should hardly deem adequate to produce such an effect. I was consulted in the case of a young gentleman in the country, who had merely struck the eye with a pocket knife, when cutting a piece of whipcord; the blade of the knife, which was quite blunt, wounded the lower part of the cornea. The lad was treated very judiciously; the practitioner on the spot applied leeches, and did all that could be done in such a case, but when the eye was opened, after a certain time, the friends were alarmed to find that the patient could not see; and he was consequently brought to town. The pupil was dilated and fixed, but not discolored. The wound seemed to have penetrated the cornea and reached the iris, which adhered to the cicatrix, but it had not extended to the lens; the eye, however, was quite insensible to light. I considered the eye to be lost, and indeed it did not appear to me that any thing could be done. As the parents of the child were very anxious about him, a consultation was held on the case, which terminated in the same opinion. After three or four months, he was brought again to town, when the process of absorption had not only begun, but considerably advanced, so that the bulk of the globe was already considerably reduced.

Not long ago, I had occasion to see another lad from the country, who had received a blow upon the eye with a small stick from one of his companions. It appeared that the eye had been struck on its inner side, but although the injury had produced at the time no visible mark, or external

redness, amaurosis followed, and was permanent. After the lapse of a few weeks, the sight of the other eye became impaired sympathetically, and I was afraid that it would be entirely lost; the retina, however, recovered.

The influence of one eye upon the other is not confined to cases of disease. When an eye has been lost by accident, the other often becomes diseased sooner or later, without any imprudence, or any external influence that would be injurious under ordinary circumstances. This kind of occurrence is so common, that it is necessary to warn those who have lost an eye of their danger, and to point out the necessary precautions for avoiding it. For this affection of the sound eye, if it is not noticed and properly treated in the early stage, often destroys sight. Its most common form is slow inflammation, which may affect the iris, the retina, or the internal tunics generally. Rest of the eye, antiphlogistic means and the use of mercury, are the principal points of treatment.

Our only chance for restoring sight, when the retina has been injured by concussion, is in keeping the organ quiet, in taking blood from the neighborhood by cupping or leeches, and in the general treatment called antiphlogistic. After evacuations, blistering may be resorted to advantageously.

Case.—A boy about six years old was brought to the London Ophthalmic Infirmary, with injury of the eye from the explosion of gunpowder. There was a small extravasation of blood into the anterior chamber, some enlargement of the pupil, which was motionless, and apparently displaced towards the upper part of the eye, and loss of vision. The prognosis was unfavorable; but sight was perfectly restored, the change of figure in the pupil remaining.

Case.—*Effusion of blood into the anterior chamber, and complete amaurosis, from a severe blow: recovery and perfect sight.*—William Kitt, aged eight, was admitted into St. Bartholomew's Hospital on the evening of May 1, 1833, having received a few minutes previously a blow on the right eye from a pellet of clay thrown from a sling. The following symptoms were observed; viz. considerable swelling of the upper lid; great pain in the eye-ball and over the orbit; a small quantity of blood effused into the anterior chamber, at its lower part; complete loss of vision; pupil dilated, and elongated vertically; iris motionless. (Thirty leeches round the eye; opening mixture.) The pain was relieved by the loss of blood, but it returned after a few hours, with violent throbbing; eight ounces of blood were taken from the arm. The patient fainted and the pain was diminished.—May 2; the patient could distinguish light from darkness, or if an object obstructed the light he could detect a change without knowing its cause; blood much diminished in the anterior chamber; other symptoms as in the evening.—May 3; return of throbbing pain; no improvement in the sight; pupil less elongated. (Seven leeches; blisters to the nape.) May 4; sight much improved; the effused blood completely removed; pupil less distorted. From this day, until the 14th of May, when he left the hospital, the vision gradually improved: and with it the pupil acquired its normal shape, size, and motion; the only defect of which the patient complained being an inability to detect a very definite outline of any object. The functions of the left eye were at no time impaired.

I subjoin the following cases to illustrate the nature, treatment, and prognosis of the amaurosis consequent on blows inflicted on the eye, the shrinking of the globe consequent on internal inflammation after such accidents, and the sympathetic effects produced on the other eye.

Incomplete amaurosis of the left eye from concussion of the retina; same affection of the right from chronic internal inflammation.—A gentleman

thirty-eight years of age, whom I saw in January, 1829, had lost the sight of the left eye from a blow on the front of the organ with a stick nine years previously. The right eye began to fail four years ago; he employed no treatment, and was nearly blind with that eye. The pupil of the left eye is large, fixed, and irregular in figure, the iris having been contracted to its utmost on the nasal side. He can discern large objects with this eye, but cannot make out even capital letters. The pupil of the right eye is contracted and partially adherent; vision is about the same as on the other side.

Amaurosis nearly complete from a blow.—A boy eight years old, was struck in the eye with a cricket-bat; there was great swelling of the lids. Leeches and other suitable means were employed. When I saw him some weeks after the accident, all the immediate effects of the injury had disappeared. The pupil was dilated, and capital letters could not be distinguished.

Inflammation and complete amaurosis from a blow.—A boy, twelve years old, whom I saw in April, 1828, had been struck on the eye, four weeks previously, by a stone thrown by a companion in play. He was running away, and was struck as he looked round to see whether his pursuer was reaching him; the blow must therefore have been oblique. Sight was impaired, but there were no external appearances of inflammation; and the proper means were employed to prevent its occurrence. There came on, in a few days, pain and redness of the eye, with pain in the head, and comatous symptoms, for which active treatment was necessary. When I saw the patient, there was external redness from fullness of the sclerotic vessels, extreme dilatation of the pupil, and complete amaurosis. A small opaque mark observed on the cornea, near its margin, towards the external angle of the eye, was supposed to be the effect of the injury, the other eye had not suffered.

Partial amaurosis from concussion of the retina; partial recovery.—A boy, eight years old, received, on the 8th of May, 1828, a violent contusion on the right eye, from falling against the end of the handle of a cricket-bat, which was placed perpendicularly. The accident was followed by great swelling of the lids and surrounding parts, and severe pain. Proper treatment was adopted; and when the subsidence of the swelling allowed the eye to be examined, there was no evidence of direct injury to the globe; but the boy said he was blind. I saw him on the 20th of June, when I found a scar on the under lid, evincing that the accident had been serious. The pupil was dilated, not fully; and vision was very imperfect, but the patient's age did not allow the kind and degree of imperfection to be exactly appreciated. I prescribed the hydrarg. c. creta, with mild aperients, and a succession of blisters. On the 26th of July vision had much improved; the small capitals in the title-page of an octavo book could be readily distinguished. Partial dilatation of the pupil remains. As this patient who lived between twenty and thirty miles from London, was not brought to me again, I think it probable that sight was restored.

Amaurosis from concussion of the retina; internal inflammation; recovery.—A youth of eighteen received a blow on the cornea, of which a mark remained. The symptoms were slight redness of the sclerotica, discoloration of the iris, dilatation of the pupil, which had assumed an oblong figure, and amaurosis nearly complete. Leeches, which were applied three times, aperients, low diet, and repose of the affected organ, were the means employed, under which the patient got well in a month, the color and motions of the iris, the figure of the pupil, and the sensibility of the retina being completely restored.

Atrophy of the globe from a penetrating wound.—In October, 1827, I saw a child in arms, in whom the eye-ball had been wounded by a fork three months previously. The cornea was not more than one-fourth its natural size, and the globe was quite flaccid.

Atrophy of both globes.—A healthy boy, seven or eight years of age, was brought to me in June, 1829, with complete atrophy of both globes. There was in each a clear cornea, about the size and figure of a barleycorn placed horizontally. About fifteen months before one eye had been lost by a penetrating wound. Internal inflammation came on in the other, which seemed to have been incautiously worked. This was stopped, and vision restored; but the eye was again inconsiderately used, and inflammation returned. Afterwards the globe shrunk.

Shrinking of the left eye from a wound; subsequent loss of the right by internal inflammation.—A person, near seventy, who had been accustomed to exert the eyes considerably, as a worker in metal, received a wound of the left cornea in January, 1831, from a particle of metal. It was followed by violent inflammation, suppuration of the globe, and collapse of the tunics. The inflammation subsided in about six weeks. Soon after the right eye became inflamed, with diminution of sight Under active treatment vision was improved, but not completely restored, and he had not been able to resume his occupation. I saw the patient in September, four or five days after the relapse of the inflammation. There was external redness, particularly round the cornea, which was somewhat nebulous in its lower half; the pupil contracted and irregular in figure; pain over the brow, vision very imperfect; he could see the hand, but could not distinguish whether the fingers were open. In spite of active treatment, by cupping, leeching, blistering, and salivation, maintained for some weeks, the inflammation proceeded accompanied with severe pain, and vision was completely lost.

Atrophy from penetrating wound; internal inflammation, and cataract of the other eye.—A boy ten years old had lost one eye from a wound of the globe, followed by atrophy. Slow internal inflammation occurred in the other, and produced change of color in the iris, opacity of the lens and capsule, and general adhesion of the pupil, The operation for cataract was performed, the lens were quite soft and nearly fluid. The pupil became clear, but vision was not improved.

Atrophy of the right eye; iritis in the left.—In December, 1826, I was consulted by a gentleman, who had received a wound of the right cornea, six or eight years before. The eye was now flaccid; the iris altered in color and texture, and the pupil obliterated. A violent attack of iritis had occurred in the left eye; it had been arrested by antiphlogistic means and mercury; and then relapsed. The eye was now slowly recovering.

SECTION II.—INJURIES OF THE EYE FROM FOREIGN SUBSTANCES PASSING BETWEEN THE LIDS.

Extraneous substances getting into the eye irritate the organ, and quickly produce redness of the conjunctiva with increased lachrymal discharge, which is sometimes sufficient to remedy the mischief, as where it is caused by substances in fine powder, or by acid matters, such as snuff, pepper, salt, mustard, smoke, ammoniacal and other vapors.

Chemical agents are generally found to have produced their full effect before we see the patient. Nitrate of silver destroys the surface it touches, but it is so quickly decomposed by the moisture of the organ, that its caus-

tic action is quite superficial. I have seen external inflammation, requiring active antiphlogistic treatment, from a small particle flying into the eye, as a person was scraping a stick of lunar caustic to a point. The introduction into the eye of the lunar caustic ointment often causes active inflammation, while its continued use may give rise to chronic ophthalmia of the most obstinate kind. Similar results are not unfrequently observed from applying to the conjunctiva the sulphate of copper, or other acrid and escharotic substances.

A person employed in a soap manufactory came under my care at St. Barthlomew's for acute external ophthalmia, caused by some strong alkaline liquor which spurted into the eye. The conjunctiva scleroticæ, with which it came in contact, was thickened, elevated, and discolored, and a superficial eschar was separated. The patient was young, robust, and of full habit: a high degree of external inflammation was excited, requiring free depletion, and three weeks elapsed before the organ recovered.

Strong lavender-water thrown incautiously over the face of a gentleman who had fainted, passed into the eyes. When he recovered, he experienced intense burning pain, with redness and spasmodic closure of the lids, and copious lachrymal discharge, especially on any attempt to open them. I found merely general redness of the conjunctiva without any damage of the cornea. The symptoms soon disappeared under leeches and the application of cold.

A gentleman received an alarming injury from the explosion near his face of some fulminating chemical substances. I saw him soon after the accident; he was in great agony from a sensation as if some burning fluid was between the lids and the eye-ball. The eye-lids and neighboring skin were reddened, the former forcibly closed, and any attempt at moving the eye, or exposure to light was attended with intolerable pain. On the temporal side of the cornea, the conjunctiva presented in a small space, a slight greyish discoloration in the shape of small irregular spots. There was general, but not considerable redness of the eye, and profuse lachrymation. Concluding the force of the explosion to have been great, and likely to cause concussion of the retina and amaurosis, I was anxious to ascertain the state of vision. Although the extreme irritability of the organ and its impatience of light prevented me from doing this satisfactorily, I found that vision was not materially impaired. The application of eighteen leeches, followed by an evaporating lotion, relieved the pain considerably; it was necessary to put on twelve more leeches at night, and the patient slept well. On the next day the organ admitted of examination so as to show that vision was uninjured. Confinement to bed, exclusion of light, opening medicine and light diet restored the organ completely in a few days.

Hot water, and heat in other shapes, act on the conjunctiva in the same way as on the integuments. Such injuries are rare, the rapid contraction of the palpebræ preventing the mischief or limiting its extent. I had a patient in St. Bartholomew's in whom melted lead had passed into the eye. A thin concave portion of the metal was removed, which obviously owed its figure to having been in contact while liquid with the eye-ball. The organ sustained no material injury.

Pure lime applied to the cornea turns it of a dead white, and at the same time decomposes the texture, reducing it to a powder, which may be brushed off with a camel-hair pencil. The effect of mortar, which gets into the eye more frequently than lime, is less injurious in degree; it turns the cornea white, but does not decompose it. Lime and mortar exercise a destructive action on the surface of the conjunctiva; the membrane swells and is elevated, with a pulpy coagulated appearance; the portion deprived of

vitality is of a dead white, and as the effect is usually partial, the injured surface appears marbled.* If any particles of these or any other irritating substances should remain in the eye, they should be immediately removed: and if it should seem probable that the caustic action of the lime is not at an end, vinegar and water may be applied to the eye.

The cornea loses its vitality throughout when pure lime is freely applied to it; hence vision is generally lost, as the whole cornea, or the greatest part of it suffers in most cases. When the injury is superficial, the dead part slowly separates, and the transparency of the texture is partially restored. In the case mentioned by Mr. Wardrop,† two-thirds of the cornea were rendered so obscure by the application of lime, as entirely to destroy sight. At the end of five months "the whole of the slough had separated, except some small ragged portions towards the centre of the cornea. There was a degree of obscurity, apparently seated deep in the cornea; but the patient's sight was so much recovered, that with this eye he could distinguish large objects." Where the action of the lime has been superficial, and not intense in degree, I have seen the transparency of the cornea completely restored.

In a person who had contrived to dip his head in a pailful of the liquid used to whiten the walls of a house, there was severe burning pain, with closure of the lids, lachrymation and redness of the conjunctiva. Leeches and cold lotion soon removed these symptoms, and the eyes were not injured.

A detached eye-lash under the upper or lower lid produces an annoying uneasiness. To remove it from the former situation, eversion of the lid is necessary.

The most common cases requiring our assistance are those in which minute particles of dust and other matters are blown into the eye, and either lodge on the external surface of the globe, or stick in the mucous lining of the palpebræ. In either case the organ experiences considerable irritation, for whenever the globe or lids are moved the foreign substance scratches the opposed sensible surface, and causes acute pain; so long as the eye is at rest, the patient does not suffer. In order to discover and remove any minute substance of this kind, we must first look attentively at the exposed surface of the organ in a good light; if we discover nothing there we should proceed to depress the under lid, and bring the lower surface of the globe into view by desiring the patient to look up to the ceiling. If we still find nothing we must direct the patient to look in the opposite direction, and raise the upper lid, so as to bring into view the superior surface of the globe. In most instances these substances stick in the concavity of the upper lid, causing exquisite pain by scratching the very sensible surface of the cornea, whenever the lid is moved; the suffering is much greater than when the substance adheres to the cornea, since the mucous membrane of the lid, which is the suffering part in the latter instance, is not so acutely sensitive as the surface of the cornea. In order to discover and remove them, when thus situated, we must evert the lid, which is very easily accomplished. We take the cilia between the finger and thumb and draw the lid downwards and forwards; press with a probe steadily against its upper part; then carry the ciliary margin upwards and backwards; we thus turn the lid inside out, and immediately see whether any extraneous body lodges there. We usually find a small black particle not larger than

* Mr. Wardrop has delineated very faithfully the effect of lime on the cornea and conjunctiva, in his *Essays on the Morbid Anatomy of the Eye*, vol. i, pl. 5, fig. 5.

† Ibid. p. 161, 162.

the point of a pin, and remove it readily with the blunt end of a probe. This is a simple and perfectly easy mode of examining the lid under various circumstances; it can generally be accomplished without giving pain. When we let go the lid returns of itself; if it should not, we immediately replace it by drawing the ciliary margin downwards.*

The small metallic particles, particularly of iron, which get into the eye in striking a light, in the operations of smiths, cutlers, and other workers in metals, either stick close to the surface, or are imbedded in the substance of the cornea, presenting the appearance of a small shining black or dark point, which cannot be detached with a probe, and is often so small that it might escape notice unless the eye were minutely examined. These particles do not penetrate the cornea by the direct force of the motion; they are ignited and appear as sparks; consequently they burn where they touch, and stick close to the burnt part. We must remove them with the point of a cataract needle. Let the patient sit down opposite a window; then standing behind him, we separate the lids with the fingers of one hand, while we use the needle with the other. When we have a clear view of the particle, we direct the patient to look steadily at one object, so as to fix the eye in that exact position, then bring the point of the needle to the edge of the substance, and passing it under, lift the foreign body out. Sometimes we succeed better with the patient standing, placing ourselves in front. Particles of steel or iron leave a light brown stain on the cornea, which disappears in a day or two. The proceeding enjoined by Beer, of scraping off the stained part with the cataract needle, is quite unnecessary; and fortunately so for the patient, as it could not be executed without a greater injury to the eye than that of the original accident. He seems to contemplate the employment of considerable force, as he adds a caution against penetrating the cornea with the instrument!! When such substances are deeply sunk in the cornea, it is no easy matter to detach them, and the difficulty is increased by irritability of the eye, which is turned away involuntarily when the patient sees an instrument approach. More injury may be produced by persevering in our attempts than by suffering the substance to remain. If it is left, ulceration will take place, loosening and ultimately detaching it. This event is accelerated by the oxydation which the metal undergoes in consequence of which its texture is loosened, and it is partially converted into a powder of a rusty color.

[M. Guepin relates a case in which he hastened this proceess of oxydation by the employment of a collyrium containing acetic acid. The subject of the case was a boy, who had a fragment of iron in his eye, which extended from the cornea to the capsule of the crystalline lens, and almost touched the iris. It was impossible to grasp the fragment and an incision would have been difficult, as it lay upon the upper edge of the pupil. M. Guepin accordingly devised the following remedy. He prescribed a collyrium made with distilled water and acetic acid, being persuaded that if the fragment became oxydized at the corneal extremity, the oxydation would spread over its whole surface, and that the dissolution and absorption of the fragment would follow. The event justified his supposition. At the end of three weeks, the cure was complete, with the exception of an almost imperceptible white point upon the capsule, and a very slight

* [Travelers in steam-boats and on rail-roads often suffer much inconvenience, from particles of cinder blown into their eyes, and frequently still more from the awkward attempts made to discover and remove them. Not a few examples of this have come under our observations; where a careful attention to the directions given by Mr. Lawrence would have saved much suffering to the patient, and great mortification to the practitioner.]

cicatrix on the cornea. In another case, the same collyrium was again used with success to carry off the oxyd of iron left in the substance of the cornea by a fragment of iron which had remained in it a considerable time.*

A German writer has recently proposed the use of a solution of gum arabic for the removal of foreign bodies, such as particles of dust, straw, &c., introduced between the eye-lids and ball of the eye, when they are not impacted in the conjunctiva. In making this application the patient's head should be thrown back, so that the mucilage may be dropt between the lids or be introduced by the aid of a feather, care being taken not to touch the globe with the latter. This solution does not produce any disagreeable sensation: it instantaneously removes the pain and pressure by enveloping the foreign body, softening it, and sliding with it out of the eye. On the whole, the author affirms, that there is no means better or more sure.

Probably the white of egg, more easily procured than mucilage of gum, may afford analogous results.

We have little to say on the employment of this remedy. Most usually in the cases in which it is counseled, the tears alone suffice to remove the foreign body; but there is nothing to prevent its employment, as it is perfectly innocuous. It is not altogether thus with respect to *iodine*, employed by Dr. Reiniger against scales of iron imbedded in the cornea: and it is more simple and more sure to extract at the time the foreign body with the point of a bistoury or of a needle. We have not yet found any case rebellious to this slight operation; and to speak truth, it seems to us difficult to comprehend how an accustomed hand can fail to conquer all obstacles. However, many practitioners find a difficulty in the employment of sharp instruments with the eye, and the resource imagined by M. Reiniger may, therefore, be found very valuable. The following case will be read with interest:—

A cutler had received in the eye, while working, a particle of steel, which became deeply fixed in the thickness of the transparent cornea. It was vainly attempted to extract it by a forceps and needle, and the surgeon who had been first called in, was obliged to renounce the attempt. Eight days afterwards the eye was very red; the bit of steel was visible without the aid of a lens—it had preserved its brilliance. The patient complained of a sensation of itching and heat, and vision was no longer distinct.

It was at this time that M. Reiniger was consulted. This practitioner comenced by applying to the patient's eye a very powerful artificial magnet, but without obtaining any advantageous effect. He now saw no other resource than to employ chemical method for dissolving the particle of steel, which had the dimensions of a needle's point. He could not venture to employ any dilute lotions of hydrochloric acid, recommended for this purpose by MM. Krisner and Andrew, because the patient could not bear the application of mere cold water during entire hours to the open eye. He then resolved to prescribe the following collyrium: —R.—Iodinii, gr. i; Iodid. Potass., gr. x; Mell. Rosarum, ℥ x ss; M. et fiat solutio, S. A.

Upon the first application of this collyrium, the bit of steel became oxydized! and its lustre disappeared. Very soon the redness of the eye diminished, the heat and itching became alleviated: and by continuing the use of the collyrium, the particle of steel diminished to that degree that it was no longer capable of being distinguished without the aid of a lens. The patient finally recovered completely the visual faculty.

* Annales d'Occulistique.

This process has for its object to transform the iron into a soluble iodide; and it appears to be much preferable not only to the employment of diluted hydrochloric acid, but also to acetic acid equally diluted as a collyrium, which was proposed some time ago.—*Journal de Chirurgie par M. Malgaigne*, June, 1845.]

Sometimes foreign substances, particularly if small and smooth on their exposed surface, stick in the cornea for many days, even for weeks or months, without exciting inflammation, or causing much uneasiness. In other instances they bring on inflammation very quickly; ulceration soon occurs, and the irritant is thus removed.

Sometimes foreign bodies of some size get entangled in the loose folds which connect the conjunctiva to the globe, and remain there for a considerable time. I recollect removing a bit of twig, from the bough of a tree, which had lodged in this situation, and remained there for several weeks. The patient was not aware of the existence of any foreign substance in the eye. Swelling of the conjunctiva and something like a fungous growth from the membrane have sometimes occurred from such causes. A gentleman consulted me on account of uneasiness in the eye; he stated that he had been on a journey three or four weeks before, and that in traveling on the road a small insect flew into his eye; he was not, however, disposed to attribute his present suffering to that circumstance. On everting the lower lid, I found the wing cover of a minute species of beetle lying on its inner surface. After this had been removed, he said he still felt something in the upper lid, and upon everting that also, I found the other wing cover of the same insect. We should therefore examine carefully in all doubtful cases, extending our investigation to the reflexions of the conjunctiva from the lids to the globe.

The directions given in books respecting extraneous substances in the eye are in general of little use. Beer is tediously minute in describing every variety of matter by which the eye can be injured, and in laying down rules of treatment; but he does not even mention the simple proceeding of everting the upper eye-lid, which enables us to give the necessary relief in the great majority of cases. Injections of water, milk and water, and mucilaginous fluids under the lids, and over the surface of the eye, are recommended; these are of no use, and indeed can only add to the irritation which already exists. If any injection could remove the foreign body, the flow of tears which its presence excites would be sufficient; when it sticks to the concavity of the upper lid, injections are wholly ineffective.

Many other proceedings advised by Beer, such as the use of variously-shaped forceps and spatulæ, and the introduction under the lids of camel-hair pencils dipped in oil or butter, or of common pins or hair-pins bent near the head, with the view of entangling or hooking out extraneous bodies, seem to me well calculated to give pain and cause inflammation, without the possibility of doing good.—*Lehre*, b. i, § 158.

Removal of the cause, even when of a mechanical description, does not always put a stop to inflammatory action; this, when once begun, often pursues its regular course after the exciting cause has ceased to act; and it must be controlled by the means which will be explained afterwards.

CHAPTER IV.

CAUSES OF OPHTHALMIC INFLAMMATION.

In investigating the origin of disease, inquirers could not fail to distinguish, from the earliest times, those circumstances which produce a state of body favorable to the occurrence of disease, from such as immediately precede and directly excite the morbid phenomena. Hence in medical works causes of disease have been always divided into two classes, the *remote* or *predisposing*, and the *immediate* or *exciting*.

The organization of the body is in relation to the influences, which surround it, and these do not affect it while in a healthy state; but the least of them is capable of producing disease, when the body is prepared for their action by certain previous changes, which, although produced almost insensibly, are of great importance, as constituting the first links in the chain of morbid phenomena, the first steps in the transition from health to disease. A person in sound health encounters wind and weather, not only without harm, but with benefit; he is not injured by atmospherical vicissitudes, by cold, heat, rain, draughts of air; while a little damp or a puff of easterly wind will bring on serious disease in sickly persons. The necessity of closely investigating these predisposing agencies in reference to the important object of preserving or restoring health, and thus preventing disease, is too obvious to require further explanation.

As the eyes are parts of a general organic system, connected with the rest by vessels and supply of blood, by nerves, and by the reciprocal sympathetic influence in health and disease, the remote or predisposing causes must be the same for them, as for the rest of the body, and some of the immediate causes are at all events analogous. I shall first consider the latter, as their agency is the most obvious.

Immediate or exciting causes.—In the first place, inflammation of the eye may be produced by direct injury, such as accidental wounds, or intentional violence inflicted in surgical operations. Such causes always excite inflammation, which will vary in degree according to other concomitant circumstances. This liability to inflammation, after surgical operations, requires our serious consideration in the previous preparation and subsequent management of the patient.

Direct injury to the organ may be produced by various extraneous substances coming in contact with it, or, in popular language, getting into the eye. Minute bodies of all kinds may pass between the lids, and remaining fixed either to them, or to some part of the external surface of the globe, become a source of irritation and inflammation. Some of these may irritate the organ mechanically, as particles of dust, sand, or stone; some may act chemically, such as various acrid substances, particles of snuff, pepper, salt, acrid fumes, and different chemical substances; others may affect the organ both mechanically and chemically, as portions of heated metal.

Under the head of chemical stimuli, or irritants, it would not be proper to omit the mention of numerous matters applied to the eye under the name of remedies. It would seem as if the most delicate and sensible organ of the body had been selected for trying the most violent applications. Powdered glass and sugar, wine and tincture of opium, electricity and gal-

vanism, spirituous and ammoniacal vapors, are the mildest of the ordinary local stimuli. Subacetate of lead, white and red precipitate, nitrate of mercury, oxyd of zinc, alum, the sulphates of zinc and copper, nitrate of silver, and oxymuriate of mercury, are applied daily to the eye, in the form of solution, and various other shapes. The more active escharotics are sometimes resorted to, as the nitrate of silver in substance, and we read even of the kali parum having been used. Pretty strong and almost concentrated nitric and muriatic acid, and the muriate of antimony, have been occasionally employed. The circumstance of these substances being called remedies, does not alter the nature of their action on the organ. A small portion of any of them applied to the sound eye of a healthy person would produce a greater or less degree of inflammation, and there can be no reasonable doubt, that in many instances of their application to the organ, when already inflamed, they aggravate or keep up the disease which they are employed to lessen or remove.

Ophthalmic inflammation may be directly excited by the application of certain contagious substances, for example, gonorrhœal discharge from the urethra, and the puriform discharge of purulent ophthalmia.

The eyes are meant to be used, and although so delicately organized, are capable of great daily exercise for a long course of years. But there are limits to their power of endurance. Excessive exertion on minute and very bright objects, as in microscopic and telescopic pursuits, is sometimes suddenly injurious. They suffer again from habitual daily employment for many hours, continued often by candle-light, in occupations requiring close attention, as in weavers, tailors, shoemakers, milliners, mantua-makers, sempstresses, printers, engravers, painters, draftsmen, law-stationers, clerks, in counting-houses, watchmakers, instrument-makers, working jewelers, and all persons engaged in the various manual crafts; in students and literary persons, especially when they read much small print, or write in small characters. In speaking of use of the eye, we must, however, distinguish between active and passive vision: the impressions of light on the retina are constant during our waking hours; but this merely passive sight is uninjurious. The unnatural excitement of the organ is combined, in many of the previously enumerated instances, with want of exercise, full diet, use of spirituous and other strong liquors, which cause increased determination of blood to the head, and at the same time consequently derange the functions of the digestive organs. The injurious influence of over exertion is shown by the relapses of inflammation caused by returning to such occupations before the organ has completely recovered.

Air and light, the elements for which the eye is created, can hardly ever be injurious to the sound organ of a person in good health; yet, under some circumstances, they are capable of exciting disease. I shall speak more particularly of various atmospherical influences, in considering catarrhal ophthalmia, and merely observe at present that the dense winter fogs of London will cause smarting and soreness of sound eyes in healthy individuals.

The effects of bad air, or noxious effluvia, will be adverted to under the head of purulent ophthalmia; but it may be stated here, without attempting to explain how it occurs, that the air of hospitals, work-houses, close rooms, in confined situations, is injurious to the eyes, favors the continuance of inflammation, and retards recovery from operations. Complaints which have been lingering on, in spite of every effort at cure, in such situations, get well of themselves when the patients are removed into good air. The improvement is often so rapid, that we seem obliged to admit a direct noxious effect of unwholesome air upon the organs in addition to the well-known injurious influence upon the system at large.

Exposure to light may be hurtful, either by the sudden impression of powerfully luminous objects, as a flash of lightning, or looking at the sun in eclipses, or by the longer use of the organ under less intense light, as that of lamps, or gas-lights, or by its employment upon bright metals, or other shining objects. The injurious effects are aggravated, if the exposure to light be accompanied with heat, as in the case of cooks, bakers, workers in glass-houses or iron foundries, or with the excitement of considerable bodily exertion, as in soldiers making long marches under a powerful sun.

Some forms of light irritate the eye more than others; thus, reflected is more powerful than an equal quantity of direct light. The glare from the sea, or extensive sandy surfaces, particularly in warmer climates than our own, is extremely offensive to the eye. Even in this country, where we are not much troubled with the brightness of sunshine, the white roads in chalky soils are sometimes found very trying to the eyes; and the bright white or yellow of houses and walls in some towns distinguished by particular cleanliness and neatness, has been found disagreeable in the same way.

Exposure to light is particularly offensive to individuals laboring under inflammation of the external tunics of the eye-ball. This affection is prevalent among the Esquimaux, and the inhabitants of other high northern latitudes, and is so obviously caused by the powerful reflection of light from the snow, which covers the earth for many months in the year, that it is commonly called *snow blindness*. Some of their contrivances for protecting the organ from this source of irritation are extremely ingenious.

In the affection of the eyes caused by exposure to the glare from snow, there is intolerance of light, with profuse lachrymation, and an uneasy sensation, as if a particle of sand were in the eye, which is aggravated, as the disease advances, to the severe suffering which might be supposed to be produced if snuff were thrown into it. Violent spasm of the eye-lids occurs. The symptoms seldom go off in less than ten days, and often last for weeks. The Tartars protect themselves when they hunt or travel in the winter, by a contrivance analogous to our crape spectacles; that is, by a net-work of black horse-hair, made a little convex in front, so that it may not interfere with the motion of the lids. The *snow-eyes* of the Esquimaux, as they are called by travelers, are a kind of goggles, made of extremely light wood, resting by a bridge on the nose like spectacles. It is excavated on each side, so as to allow free motion of the lids. The excavations are stained black with soot. A long narrow slit is made in the wood opposite each eye, corresponding exactly to the fissure between the lids, when they are nearly closed in looking at an object under a strong light. Blumenbach, who has described and figured these Esquimaux spectacles, says, "I was unfortunate enough lately, having been affected for several months with tonic spasm of the eye-lids, to have repeated occasion to make use of this excellent and simple contrivance. Whenever I wanted to examine anatomical preparations, or objects of natural history in a clear light, no other assistance answered my purpose so well as the snow eyes of these rude people. It also serves for a telescope, as all the visitors of my museum who have tried it can testify; and we find that the Esquimaux use it for the purpose of discerning distant objects more distinctly, when they are not troubled by the reflected glare from the snow."—*Blumenbach, Specimen Historiæ Naturalis, &c. Goetting*, 1816, 4to.

Particular colors, and combinations of color, are found to be painful to the eyes; thus it is well known that red is offensive, and green agreeable to them. Variegated surfaces, presenting a variety of colors, are sometimes annoying; thus persons who are obliged to look much at patterns of

articles in linen and calico, often complain of their painful effect on the eye.

The causes above enumerated admit of being divided into two classes. Some of them, such as external injuries, chemical substances, or morbid animal poisons, will necessarily produce more or less inflammation: one case may be serious, another slight. If we extract a cataract from an individual in good health, and whom we have carefully prepared for the operation, hardly any perceptible inflammation occurs; but, if we operate on a person of gross habit, without the requisite preliminary cautions, such inflammation may ensue, as entirely to frustrate the object of the proceeding. The other agencies, such as the application of cold and moisture, and excessive exertion of the organ, do not produce inflammation invariably. Many persons may be exposed to cold, wind, rain, or snow, and most of them will suffer no injurious consequences, but one may be attacked with sore throat, another with catarrh, a third with inflammation of the eye. Out of a large party sitting down to a feast and indulging equally, one individual will have an attack of apoplexy. A person in good health receives a slight blow on the foot, or a twist of the ankle, and experiences a merely temporary inconvenience; while in a person of full habit the same causes will bring on an attack of the gout. To produce disease, therefore, it is necessary, not only that an exciting cause should be applied to the eye, but that either the part, or the individual, or both, should be in a state susceptible of the action of that cause. The same exposure or employment of the organ, which would produce no inflammation in the sound eye of a healthy person, will, under certain conditions of constitution, excite inflammation. We must, therefore, inquire into those predisposing circumstances, which, though they do not immediately affect the organ, render the body susceptible of disease. In investigating these causes, we find the evidence much less clear than in the other cases. Those alterations in the constitution, which bring individuals from perfect health into a state susceptible of disease, are produced in a length of years, and by the continued application of influences, which do not act immediately or visibly at any one time. We cannot trace their direct influence, as we cannot see the hour-hand of a watch move; but we judge of it by the effects which are sensible after a considerable lapse of time.

Remote or predisposing causes.—Among the predisposing causes of disease, the following are the principal. First, natural peculiarities of organization, either such as are common to many persons, and called *temperaments*, or those, which being confined to the individual, are called *idiosyncrasies*. The law of nature, by which the progeny resembles the parents, extends to these diversities. Thus temperaments and idiosyncrasies, and consequent disposition to certain diseases, run in families, like particular forms of the features.

Here the question naturally occurs, whether light or dark eyes are the most susceptible of disease. It has often been supposed that the former are the most prone; but this is doubtful. Dr. Smith, an army surgeon, found that of 176 diseased eyes, 116 were light and 60 dark, which is about two to one. But in 2,163 sound eyes, there were 1,500 light, and 663 dark, which is nearly five to two.—*Edinburgh Medical and Surgical Journal*, No. 68, p. 351.

2dly. Morbid dispositions, such as scrofula, gout, and rheumatism. These, is some persons, depend merely on the original nature of the constitution derived from the parents; but, in others, they consist in certain states of the frame, which may be produced by external agents, in individuals who are supposed to be born healthy. Morbid dispositions, therefore,

or as they are sometimes called, diatheses, are either hereditary or acquired.

3dly. Age and sex, climate and situation, often have a marked influence in favoring the occurrence of disease, and impressing on it a peculiar form. The influence of the latter is exemplified in the frequent occurrence and severity of erysipelas and hepatic inflammation in hot countries, and in the numerous and serious inflammations of the eye in Egypt and other similar situations.

4thly. I have mentioned excessive exertion of the eye among the circumstances capable of immediately exciting disease. When it is habitual, it is a powerful predisposing cause, by keeping up an unnatural excitement of the organ, and thus it often lays the foundation of chronic internal inflammation, especially where the digestive organs and vascular system are constantly stimulated by imprudent habits of diet, and the free use of fermented liquors. In the year 1839, I was consulted within the same week by two naturally healthy young men from the country, who had followed the occupation of wool-sorting, which is very trying to the eyes, and in both of whom slow inflammation of the retina had occurred, with loss of vision in one instance, and serious injury of sight in the other. One of them, thirty years of age, used to work twelve hours a day in summer, eight in winter. He ate animal food three times a day, drank three pints of ale daily, and spirits occasionally. In his right eye there was a little external redness and slight haziness of the cornea, dilated and motionless pupil. Vision was nearly extinct; he could just discern my hand when held towards the light, but he could not distinguish whether the fingers were open or shut. By cupping, purging, reduced diet, and the use of mercury, he recovered in a month, so as to be able to read the leading article of a newspaper.

The other, a very stout man, with large head and full face, was about forty. He had always lived well, but, as he stated, not intemperately. He had lost the sight of his right eye three or four years: there were two adhesions of the pupil and no other appearance of disease. Two similar adhesions were found in the left eye, of which the sight had recently become dim and imperfect.

5thly. Unhealthy states of constitution, however produced. Perhaps the most powerful and general of the remote causes of inflammation, whether we consider the *accidental* form of the disease, arising from the immediate application of the agencies already enumerated, or the *spontaneous cases* which are said in common language to come of themselves, the causes escaping our observation, is fulness of habit, or technically, general plethora. Many persons introduce into the system a much greater quantity of food than the wants of the economy require; they sin both in amount and quality, especially in the two articles of animal food and fermented liquors. This excessive nutrition is attended, in the first instance, with a more vigorous exertion of the various organs; there is an apparent increase of health and strength, the person looks florid and robust, and seems to be in high health. Sooner or later a condition of body results, bordering on disease. There is a full and strong pulse, a disposition to heat of skin, thirst and headach; or these are produced by slight exertions. The tongue is whitish. The state, in short, is closely allied to disease, although it is still called health; it is a condition in which disease will easily be induced, and in which, when it occurs, it assumes the active inflammatory character. It is pure, simple, or common inflammation, which occurs under such circumstances; that is, inflammation arising from the excess of nutrition in an individual otherwise healthy.

It has been questioned whether the quantity of blood is increased in

these cases, that is, whether the expression *plethora*, or *fulness*, is literally applicable to the state of the vascular system. It is difficult to determine the point. We do not know the regular or normal quantity of blood, and we cannot ascertain the quantity which the vessels of an individual contain at a given time; thus we want both terms of comparison. Under the circumstances described, we often find an unnatural fulness and strength of pulse: and the blood drawn from such persons frequently presents the inflammatory character. They are in a state very similar to that of females, in whom the catamenia have been suspended, where we see flushing of the countenance, pain of the head, and determination of blood to some part. The same circumstances are observed in persons, in whom large old ulcers have been rapidly healed. I am inclined to believe that there is an unnatural quantity of blood in such cases, and that the expression of plethora is literally correct.

Individuals are not aware of the effects of the habits in which they indulge until at length symptoms of derangement and disease manifest themselves in various parts of the animal economy. The subject will be best understood by adverting to cases, in which such practices have been carried to a great degree. We have the opportunity in London of making such observations on an extensive scale. A large proportion of the individuals who follow certain laborious occupations, obtain high wages, which they spend chiefly in direct sensual gratification of the grossest kind. It is no uncommon circumstance for men employed in the coal business, brewers' servants, draymen, porters, and others, who are, generally speaking, fine robust men from the country, to consume from four to twelve pots of porter a day, besides gin, and a full allowance of animal food. We certainly see many of these who, if we regard fulness of flesh and ruddiness of complexion as signs of health, may be considered as fine specimens. But these persons are subject to inflammatory attacks of the most violent kind, which they bear very ill. Slight injuries, which in others would be wholly unimportant, produce in them severe inflammation, often terminating in gangrene and death. I have seen the whole lower extremity mortified up to the groin, in thirty-six hours, from a simple scratch of the skin, in a drayman. They live, in fact, on the brink of disease; the slightest accident may carry them off, and if they escape casualties, the continuance of their intemperate habits leads to inflammation of some of the thoracic or abdominal viscera, which either proves fatal in its active stage, or, by causing dropsy, leads more slowly, but with equal certainty, to dissolution. The majority do not survive the age of fifty; hundreds of them die in our hospitals from disease of the viscera, and afford us ample opportunities of investigating the changes consequent on inflammation, and of demonstrating, in its fatal termination, the effects of such a mode of life. In the natives of India we may contemplate the effects resulting from opposite habits. The religious notions of the Hindoos induce them to abstain from animal food, and they live almost entirely on rice and other vegetables. They are small in stature, slender limbed and very well formed; the symmetry of their figures not being impaired by any superfluous fat; yet, in active exertion, fine, well-fed Englishmen, are quite unable to compete with these slender Indians, who greatly surpass us in all feats of activity, such as running or walking great distances, &c. Accidents or operations, which in full-fed Europeans would be attended with dangerous inflammatory excitement, produce trivial effects on the natives of Hindostan. Severe injuries cause but little febrile disturbance, and they recover commonly under circumstances which would be considered desperate in individuals of different habits.

Although robust constitution, fulness of habit, and youth, predispose powerfully to acute inflammation, whether of the eye or other parts, they are not essential conditions to the production of such disease, which often arises in weakened states of body, and sometimes where the debility is great. Strength, instead of favoring the occurrence of inflammation, resists its development most effectually. I mean by strength the healthy condition of the frame, in which all the functions are carried on perfectly, and in which there is the greatest power of regular and continued bodily and mental exertion. Such are not the attributes of plethora, in which the appearances of strength are fallacious, and accidental inflammations are easily produced. The numerous class of spontaneous inflammations, however, occurs in subjects of unhealthy or impaired constitutions; often in those who may be considered naturally weak, as the scrofulous, and sometimes where extreme debility has been produced by disease, as in typhus fever. "I have often," says P. F. WALTHER, (*Abhandlungen*, p. 397-8) "seen acute ophthalmitis, requiring the most powerful antiphlogistic treatment, in weak, badly organized subjects. Lately I had occasion to treat such an affection in a person recovering from typhus, which had left him so weak that he could not stand without support. He refused to submit to my recommendation of venesection; and in the course of seven days, the disease advanced so considerably, that the pupil of the right eye was nearly closed, and the left eye had become attacked by very active and painful inflammation. He was bled on the eighth day, and again on the ninth, when leeches were also applied. The abstractions of blood gave sudden and permanent relief, both in regard to the pain and state of vision; but the latter remained imperfect in the right eye in consequence of a thin adventitious production in the pupil.

Habitual excess, particularly in the use of fermented liquors, not only produces general fulness and excitement, but more especially affects the head, causing increased activity of circulation, in which the eyes participate. A single hearty meal will cause visible vascular fulness, redness, heat, flushing of the face, beating and throbbing of the head; these phenomena being followed by headach, drowsiness, and more or less incapacity for mental exertion. Can we suppose that the daily repetition of these causes will fail to produce ultimately the most serious consequences? The mischief is aggravated when the return of blood from the head suffers any impediment. In this way tight neckerchiefs and the stiff stocks of the military have been prejudicial.

The suppression of habitual discharges will obviously favor the occurrence of general plethora; thus ophthalmic disease, as well as other local affections, often owes its origin to the interruption, or the cessation of menstruation, sometimes to its non-occurrence at the usual period.

If the causes, which have originally produced plethora continue to operate; that is, if into the system, which is already overloaded, excessive and unwholesome supplies are continually introduced, the functions of the organs begin to be disturbed; they are unable to dispose of what is thus poured in upon them. Digestion is first deranged; the associated and subsequent processes of chylification, absorption, fecal and urinary excretion are necessarily perverted. The secretions of the alimentary canal, and of its subsidiary organs, particularly the liver and kidneys, become vitiated, the contractions are impaired, and thus the regular course of its functions is interrupted. The digestive organs perform the important office of preparing the supply of new materials for the growth and repair of the body; they also remove from the system the residue of the alimentary matter, after the nutriment has been extracted from it. If healthy supplies of new matter are introduced into the frame, all the animal actions, whether bodily or mental, are carried on with vigor;

the body is active, the mind is alert; and a general feeling of health pervades the whole frame. But if the nutritive system is disturbed, if the alimentary canal is loaded with undigested matters and unhealthy secretions, then materials of disease rather than of health are distributed over the body; under such circumstances, any organ may become diseased, any mental function deranged. The unhealthy condition of the constitution is now evinced by changes too obvious to escape observation; the characters of plethora are succeeded by a state of defective excretion. There is a foul tongue, deficient, or sometimes unnaturally voracious appetite; costiveness; the motions, when procured, being unnatural in color and consistence. The urine is deficient in quantity, high-colored and turbid; the skin is sallow, harsh, and dry; the pulse feeble, compressible, and sometimes irregular.

Although the most common cause of this condition is excessive nutrition, it may occur independently of this, without intemperance, even without imprudence in diet. It may take place in consequence of circumstances which act immediately on the nervous system, and which affect the digestive organs secondarily. Among the causes referable to this head may be mentioned indolent habits, sedentary occupations, making people neglect the advantages of air and exercise, which are as necessary to health as food is to existence, residence in the impure air of confined and crowded dwellings, excessive mental exertion, long continued anxiety and affliction. Such causes impair the energy of the nervous system, rendering it weak and irritable; this again disturbs the functions of the digestive organs, producing indigestion, costiveness, andall their attendant train of evils. The effects of impaired nervous energy and defective assimilation must be felt over the whole body, lowering constitutional power, and causing a state of general debility, in which the frame yields more readily to morbific influences and disease, when once excited, is difficult of control, and lasts for a long time.

Again the origin and protraction of disease often depend on constitutional weakness, arising from direct debilitating influences, such as deficiency of food, clothing, or rest, singly or combined, or various other depressing agencies.

When we consider that, in a large portion of the community, the predisposing causes, which have been now explained, are united with the direct exciting influence of excessive exertion of the organ, we shall cease to wonder at the numerous instances of inflammation in all the textures of the eye, that daily present themselves to our observation.

From these considerations it is obvious, that in many cases we ought to direct our attention not so much to the organ which is the immediate seat of disease, as to the influence of certain circumstances and habits on the constitution. At all events, if, under the immediate urgency of active disease, the state of the suffering part should require our first care, the prevention of future disorder cannot be accomplished without such an investigation as I have just pointed out.

In the various cases which I have now considered, we see the effect of some direct agency on the disordered part, either such as necessarily excites inflammation in some degree, or such as will cause it in individuals who are predisposed. There are other and numerous instances in which we can trace no direct application to the inflamed part; but we discover the existence of disturbance in other quarters, and we find that the removal of those disturbances in many cases either accomplishes, or essentially assists the cure of the inflammation. The former are called *idiopathic*, the latter *sympathetic* inflammations. The conjunctiva may be inflamed by the application of gonorrhœal matter, or gonorrhœal ophthalmia may come on, without any such direct cause, merely in consequence of the previous dis-

ease of the urethra. The iris inflames from injury, or it may suffer from infection of the constitution by venereal disease. Inflammation of the testicle in gonorrhœa is a sympathetic affection.

The cases to which I have cursorily alluded, under the head of spontaneous inflammations, belong to the sympathetic class. It is difficult to determine whether their occurrence is owing to the unhealthy states of constitution already described, or to the influence of disturbance in some particular organ; whether they take place through the medium of the vascular or of the nervous system. That the former has an important share in the affair in many instances cannot, I think, be doubted. Under the constitutional disturbance which follow serious local injury, such as compound fracture or other extensive wound, laceration, or bruise, inflammation may arise in various important organs, as in the peritoneum, pleura, or pericardium, in the lungs, heart, liver, or spleen, as well as in the joints and the muscular system. If the active disorder excited in the constitution in this way can produce such local effects, we may easily suppose that the less violent disturbance which constitutes plethora, or the constitutional unhealthiness caused by diminished nervous energy and impaired digestion, may lead directly or remotely to the various local inflammations, the ulcerations, thickenings, indurations, enlargements, which are said in common language to originate spontaneously, or of themselves, and which have so much puzzled nosologists in the attempt to account for their causes and mode of production.

CHAPTER V.

TREATMENT OF OPHTHALMIC INFLAMMATION.

It is a trite maxim in the treatment of disease to begin by removing the cause; and the propriety of this course is particularly obvious where that cause is mechanical, as in the case of extraneous substances getting into the eye. This subject has been considered in Chapter III.

SECTION I.—TREATMENT OF ACUTE INFLAMMATION.

Protection of the organ from external influences.—Whatever further measures we may adopt, the eye must be protected from injurious external influences. Exertion of the inflamed part increases the disturbance and aggravates the patient's sufferings. In serious cases, therefore, the eye must not be employed; nor must the sound eye be used, when one only is the seat of acute inflammation. In less severe affections passive exercise of sight may be allowed, although active exertion of the organ would be improper, such as in needle-work, writing, reading, particularly small print and by candle-light, employment before fire, or on bright or minute objects.

Exposure to light is generally painful, so that patients are disposed to avoid it. The necessary protection is obtained, in the worst cases, by darkening the chamber and closing the bed-curtains. This is not often necessary; in general it is sufficient to exclude strong light by window-blinds, and to protect the eyes by the common pasteboard shade covered

with green or black silk, by a shade of such silk stretched on wire, by green or black crape or gauze hanging over the face, or by colored spectacles. These means of protection may be required only when there is much light; not in twilight, or in dull days.

It would be obviously injurious to expose an inflamed eye to the air in cold or rainy weather; and great vicissitudes of temperature should be avoided: but exclusion of air is not necessary in favorable states of the atmosphere. A warm, mild air, so far from being injurious to the organ, is grateful to the feelings of the patient, and beneficial to his general health; there is hardly any state of the eye in which it could be prejudicial.

[Our experience has led us to go even further than Mr. Lawrence, in dispensing with bandages and all kinds of shades to the eyes. Such coverings always increase the heat of these organs, as well as render them more irritable, and favor the persistence of the inflammation. In hospital as well as in private practice, we have long discarded their use, except as a temporary protection, in cases of photophobia, when the patient goes out of doors. In the house, the degree of light can always be regulated by closing the blinds during the day. The free access of air to the eyes, not only when the weather is warm, but even when cool, if the temperature be not very low, and the atmosphere damp and raw, is agreeable to the patient and usually very beneficial.]

General indications.—The measures already pointed out, of removing the exciting causes, and of protecting the organ against the injurious influence of exertion, light, and air, are only to be considered as preliminary, and auxiliary to the main object, that of arresting inflammation by appropriate means. Although the process of inflammation is in many cases very violent, and though the sufferings which attend it are often extremely acute, yet its tendency and effect, with reference to the termination of the disturbance, are upon the whole restorative. Within certain limits, it does not tend to disorganize and destroy the part; but is rather calculated to bring it back to a healthy state. Thus it may arise, become fully developed, and decline in an organ, without any medical treatment, leaving the part as healthy as it was before. When violent, however, it suspends the functions of a part; hence, in organs, whose constant exertions are necessary to the continuance of life, it must be speedily arrested, or life will be lost. But the eye does not belong to this class, and we are guided by other views in the treatment of ophthalmic inflammation. Its various effects, particularly mortification, suppuration, and effusion, may render the organ more or less incapable of executing its office after the inflammatory disturbance has ceased. Even the least important of these, interstitial deposition, may seriously and permanently impair the function of a delicately organized part like the eye. It will enlarge, thicken, and harden a part; it consolidates and unites structures which were previously loose and separate; it renders parts, which were naturally transparent, opaque. These various changes may result, not only from violent inflammation, but from such a degree of it, as in most other instances would be deemed unimportant. Supposing the cornea, iris, or retina to be affected, the case may present no serious symptoms; there may be no sympathetic disturbance of other parts. Yet, in the first instance, the texture may be rendered impermeable to light by interstitial deposition; in the second, effusion may obstruct the pupil, preventing or impeding the passage of light into the interior of the eye; and the third may be thickened so as to become insensible to luminous impressions. By either of these changes, according to its degree, vision may be either impaired or destroyed. It becomes necessary, therefore, to institute early, and to follow up steadily, effective antiphlogistic treatment, not with a view of removing danger to

life, nor on account of the sufferings of the patient, which may not be great, but to prevent injurious changes in an organ, the perfect state of which is essential to the comfort and enjoyment of life. There is yet another reason why inflammation should be speedily arrested. The longer the vessels of a part remain distended, the more difficultly do they contract to their natural dimensions, the more readily do they yield to any new excitement. Thus the continuance of inflammation increases the difficulty of recovery, and the liability to relapse. The probability of subsequent inflammation is in proportion to the degree of disease that occurred in the first instance, and to the length of time it was allowed to continue.

Another consideration must not be overlooked; that is, the relief of the patient from the local suffering, and the general disturbance caused by active inflammation of an important organ.

Loss of blood.—Of the means for reducing inflammation, abstraction of blood is the most powerful. Blood is the material by which the increased action of the part is maintained. In the figurative language, which the obviously increased heat has suggested, we may say that it is the fuel by which the fire is kept up. If we could completely command the supply of blood, the increased action might be effectually controlled or arrested. In comparison with the loss of blood, other means are of minor importance in lessening the local disorder and quieting the general disturbance, when acute inflammation exists.

General bleeding.—We have to consider, in the present instance, whether it is necessary to take blood from the system generally, or whether local depletion will answer the purpose. Medical writers and practitioners have been usually satisfied with the latter; they do not seem to suspect that an inflamed eye can require more than the application of a few leeches. But we must act more vigorously if we mean to prevent all danger of those structural changes which inflammation may cause in a part. We shall sometimes find it necessary to bleed from the arm, and often to take blood by cupping.

We might at first suppose that the best way of reducing increased action in any organ would be to draw blood from the part itself, to take away from it the material which keeps up the excitement. This, however, would be an erroneous conclusion. We can take blood out of a part, but a fresh supply is still poured in. General bleeding is the only mode by which the supply can be cut off. The external situation of the eye enables us to see the decided effect which a large bleeding has on the capillaries of the inflamed part; and I know no other example in which the efficacy of the measure is so clearly demonstrated. We see a person with the eye bright red, and very painful; he cannot face the light, and tears gush out with great suffering if he attempts to do so. We bleed to fainting, and immediately the capillaries are emptied, so that the organ resumes its natural paleness; the pain is gone, the eye is opened without difficulty, and the full influx of light can be borne without an uneasy sensation. For the time the part has passed from violent inflammation to a nearly natural state; and we cannot doubt that the change thus produced must have a powerful effect in arresting the disturbance. With the restoration of the circulation, the inflammation will recur after this temporary suspension; but its violence is diminished, and it often gradually subsides. General bleeding then is necessary in inflammation of the eye, to prevent the changes of structure that would subsequently impair the functions of the part.

I know of no criterion by which we can determine in all cases, whether general or local bleeding should be employed. If inflammatory fever

co-exist with the local disorder, we should abstract blood from the system: but we cannot say conversely, that if such fever be absent we ought to be content with local depletion; an inflammation of the eye, for example, may require general depletion, although it should not be attended with fever.

The quantity of blood to be drawn from the arm must be such as will decidedly influence the circulation. We cannot determine the amount beforehand; we cannot decide that ten, twelve, or sixteen ounces will be sufficient; it may be necessary to take twenty, thirty, or more ounces, or to produce syncope, if we cannot otherwise make the requisite impression on the vascular system. Professor JOHN THOMSON* says, that from twelve to twenty ounces may be taken, and that the depletion may be repeated two or three times in the twenty-four hours, if the case should require it. LANGENBECK† after quoting this statement, adds, "this would be too much in our country. I usually take from eight to ten ounces, and repeat the depletion according to circumstances." If he can arrest active inflammation by venesections of this amount, his patients must be very differently constituted from the inhabitants of this country. I believe that it is the usual practice in France, Italy, and Germany, to take a small quantity of blood at a time, and to repeat the bleeding frequently; thus, venesection is not unfrequently performed night and morning for several successive days. This plan, which is adopted from the fear of injuring the patient by a large bleeding, drains the circulating system almost to the last drop, brings on excessive debility, and is less efficacious in arresting the local disorder. I have no hesitation in stating, that the object last mentioned is effected much more certainly by a large bleeding in the outset, and that this method accomplishes it at less expense to the constitution. I never saw a person injured by a single large bleeding performed for an active inflammation; while generally the strength is completely restored in twelve or twenty-four hours, even after bleeding to syncope. On the contrary, weeks and months often elapse before patients, who have been drained by repeated bleedings, recover their strength.

As the restoration of the digestive functions and the secretions diminishes the symptoms, where inflammatory fever is present, they who are afraid of weakening by loss of blood, recommend in preference aperient and diaphoretic medicines. If we examine the history of cases treated in this way, we find that two, three, or more days are employed in these indirect attempts. Purgatives are given which do not operate; diaphoretics are tried, which bring on no discharge from the skin; the local inflammation increases, the general disturbance is aggravated, until the fever comes to an end, when the secretions and digestive functions are consequently restored. Abstraction of blood to a proper amount accomplishes the desired objects at once. When you have thus removed the load that oppresses the system, the suspended secretions are restored, evacuation of the bowels takes place speedily, and the patient breaks out into a profuse perspiration. Thus the sufferings of the patient are materially abridged, while the duration of the local disturbance is shortened; the latter being a very important point in the case of the eye.

A notion has prevailed that persons who live in London, or in other large towns, do not bear depletion well, and consequently that the loss of blood, which would be necessary in those who live in the country, would be improper in the inhabitants of the metropolis or extensive cities. I consider that this opinion is supported neither by experience nor argument. The

* Lectures on Inflammation, p. 166. † Nosologie, vol. i. p. 266.

inhabitants of London, from the highest to the lowest, with few exceptions, indulge their appetites freely; there are no small towns, nor any parts of the country, in which the consumption of animal food and stimulating liquors is more general. These habits, of which the injurious effects are aggravated in many instances by sedentary occupations or indolence, produce their natural consequences, namely, a plethoric state of the system, and an abundance of inflammatory disease, both of which circumstances will be immediately recognized, on attentive observation, whether among the higher or lower classes. I have not the least doubt that inflammations are as common and as violent among Londoners as among countrymen; and that they require the same treatment in both instances. The dread of depletion has been transmitted from one writer to another without examination or inquiry, and has led to an inert practice, under which disease has too often been suffered to proceed almost uncontrolled.

In acute inflammation affecting the entire globe of the eye, in inflammation of the conjunctiva or of the external proper tunics affecting both eyes, or where it is very severe in one, in inflammations of the internal tunics, general bleeding should be resorted to, unless contra-indicated by the patient's age or constitution, or by an impaired state of general power. A large bleeding will be proper when the circulation is excited; at all events the blood should flow until an impression is made on the pulse. A repetition of the measure will probably not be required. This free depletion will be advantageous in young and robust persons, where the inflammation is acute, and especially if seated in an important texture. In older subjects, and under doubtful circumstances, we proceed cautiously, taking a small quantity of blood, and repeating the abstraction if the patient bear it well. Bleeding to syncope is seldom necessary. In states of constitutional unhealthiness, marked by general debility, venesection would be obviously improper; it might be admissible under peculiar circumstances, as for the purpose of preserving an important organ when endangered by the degree of local excitement.

Local bleeding.—The next mode of taking blood in point of efficacy is by cupping either from the back of the neck or the temple, especially the latter, from which part blood can be obtained quickly and in large quantity. Branches of the temporal artery are commonly wounded in this operation, facilitating the abstraction of the blood, and causing neither danger nor inconvenience. I have constantly been in the habit of taking away blood in this way with the best effect.

Opening the temporal artery is, I think, less advantageous and convenient than cupping. We sometimes do not get blood enough, and sometimes there is either a difficulty in stopping the bleeding, or it breaks out again. To prevent this, compresses are placed on the artery, and secured by a bandage encircling the head, the pressure of which on the brow and forehead often renews and aggravates the sufferings of the patient. The subsequent formation of a small aneurism is not a very uncommon consequence of arteriotomy; it requires an operation for its cure. Under many circumstances cupping on the temple cannot be effectively accomplished; arteriotomy might then be resorted to. Opening the jugular vein is a troublesome and inconvenient operation; and we are frequently unable to get the required quantity of blood in this way: it is now seldom resorted to, at least in ophthalmic cases.

Blood may be drawn from the eye by the application of leeches, and these should be applied near to the part affected. The best situation is immediately above or below the upper or lower lid respectively, or near the external angle, avoiding the lids themselves on account of the ecchymosis and subsequent discoloration, which they cause here. These effects, how-

ever, cause only a temporary inconvenience, as they disappear in a few days.* It has been proposed to apply them to the mucous lining of the lower lid, that they may draw blood directly from the conjunctiva; they are easily put there, but the application of them to the external surface of the palpebra will answer the same purpose. It is a common error here, as in other inflammations, to apply them in too small a number; if the disease be active and the patient adult, it will seldom be proper to put on fewer than from eight to twelve, while a larger number will frequently be necessary, in order to produce decided benefit.

The continental practitioners apply leeches, in certain cases, not to the eye, but to other parts. They lay great stress on the influence of suppressed hemorrhage in causing ophthalmia, and consider that the organ will be most naturally relieved by reproducing the bleeding, or by drawing blood from the part which has usually poured it out. They accordingly recommend the application of leeches to the labia pudendi, to the anus, and to the ala nasi, when the ophthalmia is supposed to arise from the suppression of menstruation, hemorrhoidal discharge, or epistaxis; and they put them on the feet in disorders of the head and upper parts of the body. This course of proceeding may often be resorted to with advantage, though it is not applicable in acute inflammations. I have sometimes seen great benefit in affections of the eyes, head, and chest, from putting three or four leeches on each instep, in cases where larger quantities of blood taken in other ways near to the seat of disease have failed to relieve.

Scarification of the conjunctiva used to be very common, and it is still employed more frequently than it ought to be. Can we expect to diminish inflammation by making a number of wounds in the inflamed part? Can we doubt that such a proceeding would increase the mischief? It gives considerable pain, and causes but little discharge of blood. In active inflammation, therefore, scarification of the conjunctiva must be absolutely proscribed; there are, however, cases of chronic ophthalmia in which it is beneficial. Bleeding from the frontal vein, or from the facial at the inner corner of the eye, has deservedly passed into disuse. But little blood can be procured in these situations; leeching is therefore more efficacious.

Local bleeding may be resorted to with advantage, when the urgent symptoms have been subdued by general depletion; or it may be employed alone in cases of a less serious description. Cupping is a kind of intermediate measure, although the blood is taken from the capillaries. An expert cupper will draw twenty ounces from the back nearly as soon as we can take it from the arm: we cannot therefore suppose that there is any material difference in the effect upon the system in the two cases.

The foregoing observations are applicable to the treatment of inflammation, especially in the eye, when it is acute, so as to endanger the organ, and when the patient is strong. Of these two circumstances, however, the condition of the organ is, in the case of the eye, the most important. I do not recommend that general bleeding should be adapted in all inflammations. In some cases it is necessary to abstract blood both generally and locally; in others, local bleeding alone will be sufficient; while in some

* [We have so frequently seen the application of leeches to the lids followed, not merely by the "temporary inconvenience" noticed by Mr. Lawrence, but by actual ill effects, as great swelling and stiffness of the lids, productive of great discomfort to the patient; and erysipelatous inflammation, sometimes involving the whole face —that we no longer direct their application to those parts. The situations we prefer are, the spaces above the eyebrows, the temples, and the mastoid processes. We believe that when there applied, leeches are productive of all the good, without any of the ill effects which follow their application to the lids.]

it is not necessary to take blood at all. The state of the part, more especially as regards the probability that the continuance of inflammation may produce effects capable of impeding its functions, that of the constitution and the age of the patient must be considered.

Purgatives and diet.—It is not sufficient in the treatment of inflammation to diminish the quantity of the circulating fluids by the abstraction of blood; we must prevent the introduction of further supplies into the vascular system by the use of purgatives and the regulation of diet. We employ purgatives in the first instance, to clear out the alimentary canal, and this in general gives considerable relief. For this purpose we may administer a dose of calomel, alone, or combined with jalap, rhubarb, or the compound extract of colocynth; and follow it in a few hours by the common aperient draught of infusion of senna, with Epsom salt and manna, or a dose of castor oil. We then give neutral salts in small doses at regular intervals, so as to keep up a regular action of the alimentary canal, or a more active purge from time to time.

In the worst cases of inflammation, the diet should consist chiefly of fluids, those of a diluent, slightly mucilaginous or acidulated kind. Simple water, toast-water, barley-water, apple-water, lemonade, tea, thin gruel; such is the bill of fare for a patient laboring under a serious local inflammation, with febrile disturbance of the system. It is seldom necessary to restrict the patient to this kind of fever diet in cases of ophthalmic inflammation. In less important instances, with tea or gruel, a little toasted bread or biscuit may be allowed; also ripe fruits or roasted apples. In still milder cases, fermented liquors or solid animal food ought not to be allowed: the use of these would be quite inconsistent with active antiphlogistic treatment; we should not go beyond broths, milk and farinaceous articles, vegetables, light puddings.

Other internal remedies.—Loss of blood, purging, and abstinence, are the three great means of reducing inflammation; but there are other auxiliary measures. Nitre, the liquor ammoniæ acetatis, and the alkaline salts neutralized by lemon juice or the citric acid, are called refrigerants or cooling medicines. If not very efficacious they are agreeable to the patient; and the latter are a pleasant vehicle for aperient salts, antimony, digitalis, or colchicum.

Antimony is one of the most powerful internal remedies of the antiphlogistic kind; especially two of its preparations, the tartrite and James' powder. According to the amount of its dose, emetic tartar excites perspiration, nausea, or vomiting. For the first purpose it is given in a saline draught in the dose of one-eighth or a quarter of a grain; a quarter or half a grain repeated at short intervals, will excite and keep up nausea. In doses of a grain or a grain and a half, it produces sickness. When this is kept up by repeated doses of the medicine, the action of the vascular system is speedily and rapidly reduced; and, perhaps, we have no other single medicine capable of acting more powerfully in this way. The employment of the remedy, so as to keep up full vomiting for some hours, has been recommended with the view of cutting short acute ophthalmia. By diminishing the heart's action, by lessening the force and frequency of the pulse, it will certainly reduce local inflammation. But, severe as this treatment is, it will not cut short inflammation of the eye. Moreover, the congestion in the head, caused by the violent straining in vomiting, acts unfavorably on the inflamed organ. When a foul and loaded state of the tongue, bad taste in the mouth, and nausea indicate a disordered stomach, an ordinary emetic may be used. If this condition of the stomach, with costiveness, should be the only obvious cause of the inflammation, as it

sometimes is where the mucous membrane is the seat of disorder, and the disturbance should not be very violent, the emetic followed by an active purgative, may be employed without loss of blood. Ipecacuanha and the tartrite of antimony may be given in the usual combination; or a grain of the latter may be administered in solution every half hour, till the requisite effect is produced. The latter remedy generally purges as well as vomits.

The Italian physicians class emetic tartar among the most powerful contra-stimulants, or means of combating inflammation; ascribing to it in this respect an efficacy independent of its action on the skin or alimentary canal. With this view they give it in large doses, sometimes as much as a drachm in twenty-four hours. I have used it frequently with great benefit, in doses of a grain or a grain and a half every four or six hours, and sometimes oftener, in internal inflammations, particularly of the chest; but I have not employed it in this way in ophthalmic inflammations.

Mercury is another antiphlogistic remedy of considerable power. It has long been observed that the free exhibition of calomel, after direct depletion, has a very favorable effect in preventing the changes of structure so frequently produced by inflammation, and in expediting recovery. After the abstraction of blood, and the evacuation of the alimentary canal, calomel may be given in doses of from two to five grains, alone, or combined with a small quantity of opium, and repeated every six or eight hours. Affection of the mouth has rather accelerated than retarded recovery. I shall consider at greater length the use and action of this remedy, when I come to the internal inflammations of the eye. Its employment may be begun as soon as the violence of the symptoms shall have been lessened by the general antiphlogistic means.

I have mentioned the use of colchicum in the subsequent parts of this work, which relate to *rheumatic ophthalmia*, and *rheumatic iritis*.

Counter-irritation.—When inflammation has been checked by the means already specified, counter-irritation by blisters may hasten its removal, may prevent it from going into the chronic stage. An active inflammation in its full development, with all its sympathetic consequences, cannot be stopped in this way. Blistering under such circumstances, only adds to the existing irritation, and increases the patient's sufferings. The blisters should be applied at the back of the neck, or behind the ears: in active inflammation they should never be placed nearer to the eye than these situations. When they are applied to the forehead, temple, or side of the cheek, the inflamed organ may be included within the sphere of their irritation, with aggravation of the local symptoms: in this way I have often seen them decidedly injurious.

In treating diseases of the eye, we may avail ourselves of counter-irritation in other shapes, such as ammoniacal ointment or liniment, mustard poultice, tartar-emetic ointment, of which the first two may be applied either on the forehead or the back of the neck, while the use of the third must be confined to the latter situation. We can vary the strength of the mustard poultice according to circumstances, making it with flour of mustard, either alone, or mixed with a portion of linseed meal.

In like manner the ammoniacal application may be made of various strengths. The *pommade ammoniacal de* Gondret, much used by the French, is made of mutton suet and olive oil, each one part; liquor ammoniæ, two parts. This removes the cuticle very quickly.* A liniment made

* [Granville's lotion, which has had some celebrity lately as a counter-irritant, and which is a mere modification of the *pommade* of Gondret, answers equally well.]

with oil and lard, in which the liquor ammoniæ constitutes one-fourth of the composition, is strong enough for ordinary purposes. A portion is to be smeared on the part, and left there till a sufficient effect is produced, when it must be wiped off.

The emetic tartar ointment of the last London Pharmacopœia is made by mixing one part of the emetic tartar with four of lard. This is a proper strength for ordinary purposes. It may be employed in the way of friction, by rubbing a portion for a few minutes on the back of the neck once or twice in twenty-four hours; or by spreading it thickly on lint, and confining it on the part by adhesive plasters.

The measures now detailed, which, taken collectively, constitute the antiphlogistic plan of treatment, are necessary when acute inflammation of the eye exists in conjunction with excitement of the vascular system, as marked by a full and strong, or at least a firm pulse, or with an unimpaired state of health and general power. But inflammation of the eye, more or less active, may occur in weaker constitutions, where the powers of the system are lowered in the way explained in the foregoing chapter. This constitutional debility may have caused, remotely, the local inflammation, which is more difficult of cure under such circumstances. If we were to reduce the patient's strength further, we should increase instead of removing the local mischief. Under such circumstances we must take a different, and in some respects opposite course to that now described. The digestive organs and the secretions must be brought into a healthy state; we must attend to any part or system of which the action is disturbed or deficient, as, for instance, the uterine system in the female. We must raise the general powers by nutritious diet, with or without fermented liquors, by strengthening and restorative medicines, such as the vegetable tonics and bitters, the mineral acids, steel, sarsaparilla; by exercise, and residence in pure air, change of air, and scene. An improved state of constitutional power, brought about by such means, often acts most beneficially on the local complaint. The progress of that must, however, be controlled, if necessary, by local antiphlogistic means, the use of which is not at all incompatible with the general treatment now recommended.

Local applications.—The measures which I have now pointed out, namely, antiphlogistic treatment in most instances, and the somewhat opposite or restorative plan in other cases, with protection of the organ from injurious external influences, are those on which we confidently rely for subduing ophthalmic inflammation. They must be continued and repeated, according to the exigencies of the case, until the inflammation is removed, and the natural state of the part is restored.

Although it may be stated generally that local applications are of much less importance than general means in the treatment of inflammation, whether of the eye or of other parts, they are often useful auxiliaries. At least, they relieve uneasiness, and patients have much faith in them: they wish for something to be done to the part, and while they persuade themselves that they derive benefit from washes, fomentations, &c., they induce medical men to place more confidence in them than they really deserve.

The local application of cold by means of evaporating lotions, has a powerful influence in reducing increased action. For this purpose we may use cold water, rose water, iced water, saturnine lotion; the latter or rose water may be used with a little spirit to increase the evaporation; for example, one ounce of proof spirit, with half an ounce of vinegar, in eight ounces of rose water. Cold applications diminish the heat of the part, and lessen the burning sensation which is felt under acute inflammation; but

they often cause a chilled and aching feel, after they have been used for some time, in which case the wash may be warmed before it is applied, or it may be discontinued.

In many instances of ophthalmic inflammation patients find warm applications more agreeable than cold; and we of course comply with their feelings. We may employ warm water, the decoction of the poppy, or of chamomile flowers, or the stream of hot water.

We are hitherto unable to lay down any precise rule to determine the choice between warm or cold applications in particular instances. The latter are best in diseases which are superficial and in the incipient stage: they may cause contraction of the vessels, and thus restore the part to its healthy state. Warmth is found more advantageous when the inflammation is fully developed, or when it is seated deeply.

The preference of cold or warm applications, and the discrimination of the cases, to which they are respectively applicable, have long been debated points in therapeutics. I recollect when cold washes were used almost exclusively in inflammation; now, the warm are more in fashion.

Some employ a greater variety of local applications than I have mentioned; thus emollient and narcotic fomentations have been recommended; but I doubt whether these substances produce the effects which their names imply; whether, for instance, the skin can be softened by a decoction of marshmallow, and whether opium and other analogous remedies, in the form of lotion, act through the entire cuticle. Opium will exert its particular influence when well rubbed on the surface of the body, and it has a decided sedative effect when applied to an ulcer, in the form either of ointment, powder, or lotion; belladonna and hyoscyamus exert their singular property of dilating the pupil, when applied to the skin; but I have never seen any reason to believe that the aqueous solution of opium, used as a wash to the eye, or the addition of laudanum to other washes, has exerted any sedative influence on the part;* nor do I believe that poppy fomentation, or the other herbaceous infusions which have been used in inflammations of the eye, have any effect beyond that of simple warm water. As this want of faith has been pointedly rebuked by my friend Mr. James, in the recent edition of his instructive work on inflammation, (p. 190,) I will only observe that the substances above alluded to are very different from ammonia, tobacco, and lunar caustic, the local agency of which is too obvious to be doubted; but that the efficacy of vinegar, applied to the temples and pit of the stomach, in restoring a person from syncope, is not so unequivocal as he seems to imagine.

Other local applications, although recommended from sources of high authority, hardly require notice. The Germans use various herbs and other vegetable substances in a dried form, enclosing them in muslin or linen bags, and placing them over the eye.† They change these herbs at dif-

* In a valuable "*Report of cases treated at the ophthalmic hospital, Chatham,*" contained in the 68th number of the *Edinburgh Medical and Surgical Journal*, the author Dr. Smith says, "In several cases in which the pain was very severe, and not alleviated either by blood-letting, or the use of anodyne fomentations, considerable and lasting relief was often procured by exposing the affected parts to the steam arising from the following mixture, brought to a boiling heat, for ten minutes two or three times a day. ℞.—Mist. camph. f℥ij; tinct. opii. f℥ss; liquor ammon. acetat. f℥ij; aqua ros. f℥iv. M."

† Benedict mentions among the ingredients with which these herb-bags are to be filled, elder-flowers, and *dried emollient?* herbs, mixed with bran, flour! (particularly bean flower,) and chamomile powder. When the state of the eye requires means of a more exciting character, the bags are to be filled with chamomile flowers, sage, rosemary, thyme, and the resolvent species of the dispensatories; to which, if the organ

ferent stages of the complaint, according to their supposed properties and the condition of the organ. I am at a loss to conceive how persons who know so much of this part of medicine, should persist in such ridiculous trifling.

Scarpa uses bags of mallows boiled in fresh milk, poultice of bread and milk with saffron, emollient and anodyne vapors conveyed to the eye with a funnel, and introduces white of egg and vegetable mucilage under the eyelids! I cannot conceive any application more unsuited to an inflamed eye than a poultice; nor can I view the practice above mentioned with any greater respect than the vulgar one of plastering the inflamed eye with conserve of roses, which is quite as scientific and judicious. The pulp of roasted apple, which is a popular application for an inflamed eye, is the lightest substance in a pulpy form; and retains heat and moisture well. A slice of bread, soaked in cold water, is sometimes found an agreeable application; and a thin soft bread poultice gives ease in some ophthalmic inflammations, more particularly where the palpebræ are involved.

If the antiphlogistic treatment, which I have already pointed out, be instituted early, and followed up properly, it will cut short ophthalmic inflammation in forty-nine cases out of fifty; and, if it does not fully accomplish this, it will so moderate the inflammatory excitement, as to prevent any alteration of structure capable of injuring sight. Long and uniform experience has shown me the decided advantage of employing the antiphlogistic plan under the restrictions and cautions previously pointed out in the treatment of ophthalmic inflammation. Fear may be entertained that the loss of blood may debilitate the patient; and it may be supposed that these powerful measures are not necessary for inflammations of the eye: but, when the case requires depletion, it is better, not only on account of the local affection, but even with reference to the patient's general health, to cut short the disorder at once by active treatment, than to allow it to go lingering on for three or four weeks, by resorting to less vigorous means. Active measures possess the additional advantage of quickly restoring the functions of the eye. The great error has consisted in treating ophthalmic inflammation too much as a local affection, and relying accordingly on inefficacious local means. In a severe case, after taking blood from the arm, if the disposition to inflammatory congestion in the vessels of the organ should continue, venesection may be repeated, or we may find it advantageous to cup on the temple, or to apply a considerable number of leeches round the eye. After bleeding the patient freely, and evacuating the bowels in the morning, and applying leeches or cupping, if necessary, in the evening, we shall generally find the patient greatly relieved on the following day. It will seldom be necessary to repeat the bleeding from the arm, but this does occasionally happen, and the repetition of cupping or leeches is often required. When the inflammation is subdued, a milder course of proceeding may be pursued until the powers of the organ are completely restored. For a few days it is necessary to attend to the state of the bowels, and to regulate the diet. Most persons have a great delight in eating and drinking; thus, when these enjoyments have been abridged by illness, they are anxious to return to their practice of stuffing. We must check this inclination, the indulgence of which is the most frequent cause of relapse.

should be still more torpid!! camphor is to be added.—*Handbuch der prakt. Augenheilkunde*, vol. i. p. 40, 41.

SECTION II.—TREATMENT OF CHRONIC OPHTHALMIA.

Inflammation of the eye is not always characterized by the same violent symptoms, nor does it always require the active treatment which I have just described. We often meet with cases in which there is preternatural redness of the globe and lids, without much pain as long as the eye is at rest. Active exertion of it, or exposure to strong light, will occasion painful sensations, and produce lachrymal discharge. Diminished transparency of the cornea, and more or less impaired vision, are sometimes joined to these symptoms. The organ may continue long in this state, and when it has existed for some time, the affection has been distinguished by the name of *chronic ophthalmia.*

If the acute stage of inflammation should have been inertly treated; if the patient should have conducted himself imprudently by continuing to use the organ, or by not submitting to the necessary restrictions in diet; or if, after the inflammation has been in a great measure subdued, he should have begun to use the eye too soon, or have indulged in drinking or other imprudences, the chronic stage of inflammation may be prolonged indefinitely; the vessels continue preternaturally distended, the organ is in an irritable state, and easily excited into active and painful disease.

In individuals of weak and unhealthy constitution, the acute stage of inflammation is short, the violent symptoms soon disappear; the chronic period then comes on and lasts for a considerable time. In old persons of unsound habit there is sometimes hardly any well-marked acute stage, but the inflammation exhibits a languid chronic character from the beginning.

Scarpa (*Treatise*, &c., chap. vii.) represents the matter as if there were necessarily an acute and a chronic stage in all ophthalmiæ; he considers these as opposite in their nature and causes, and he prescribes opposite modes of treatment; namely the antiphlogistic plan for the acute, and tonics, combined with local astringents and stimulants, for the chronic.—With this view he regards it as a matter of great importance to mark the precise period at which the acute inflammation ends, and the chronic commences. I consider this view of the subject altogether erroneous both in principle and practice. The shorter the period of violent inflammatory congestion in any part, the sooner will the vessels recover. Hence if you treat acute inflammation according to the principles I have laid down, the local disturbance is removed, and the part never passes into the condition of chronic or protracted inflammation. But if persons through fear of debility are averse to letting out a little blood, and thus allow the disorder to take its course, the acute symptoms will very commonly be succeeded by chronic inflammation. If from this, or any other causes, chronic inflammation has supervened, the question arises, how are we to treat it? Are we with Scarpa to adopt the tonic plan, accompanied with local applications of an astringent or stimulating kind? Certainly not. We must look at the symptoms of the particular case, and regulate our treatment by them, not by the length of time the complaint may have continued.

Treatment of chronic ophthalmia; general means.—Since chronic inflammation is the same as acute in its essential nature, the difference being only in degree, it must be treated on the same principles. The local symptoms being less violent, and the sympathetic disturbances slight or altogether absent, it is not so often necessary to take blood generally as in acute inflammation; but the general abstraction of blood is by no means inapplicable or unnecessary in all the cases technically called chronic.—We can sometimes take blood from the arm with advantage after the lapse

of many days, or even weeks, as in a robust and plethoric person with a chronic inflammation affecting important parts of the eye. It is sometimes advantageous to take blood in moderate quantity in those states of plethora which I have mentioned as constituting the remote or predisposing cause of so many local diseases, and where no inflammation may yet have been excited in any organ. The local loss of blood by cupping on the temple or back of the neck, or by leeches, is frequently necessary, and that repeatedly in chronic cases. The antiphlogistic treatment, in short, must be continued, but in a less active manner.

The regulation of the digestive organs is a matter of considerable importance. In the first place, the alimentary canal should be cleared, as in a case of acute inflammation; then means should be adopted to ensure the regular action of the bowels without purging. The substances which stimulate the large intestines, such as aloes and colocynth, are the best for this purpose. We may combine with them mercurial medicines, when unnatural color of the fecal evacuations indicates an unhealthy state of the secretions into the alimentary canal. In this way blue pill may be given with aloes, compound extract of colocynth, or extract of rhubarb: or calomel may be employed in similar combinations.

If the tongue should be foul and loaded, with nausea, and want of appetite, the alvine discharges being at the same time unnatural, dark and slimy, it may be necessary to clear the stomach by an emetic, or to administer calomel with James's powder and extract of colocynth, following it after some hours with the ordinary purging draught of infusion of senna with Epsom salt. When the alimentary canal has been cleared, mercury may be given in the alterative form, mild aperients being occasionally resorted to. The compound decoction of aloes with infusion of rhubarb, or with infusion or tincture of senna, are suitable forms.

Careful attention to diet is still required, although the inflammation is called chronic. This point indeed is just as important as the more strictly professional treatment. If we content ourselves with directing the medical or surgical means, and leave the patient to his own course in diet, we shall do little good. Even in the milder forms of inflammation, animal food should be taken only in moderate quantity, and fermented liquors are, generally, inadmissible. Tea, milk, gruel, broths, bread, and the various farinaceous articles, vegetables, and fruits, will supply sufficient gradations between the scanty fare of fever, and the full diet which is taken in health. When the local excitement is completely stopped, and the general disturbance has ceased, when the tongue is moist and clean, when, in short, the patient is well, he may return to common diet, but not before.

Chronic inflammation occurs, still more frequently than acute, in conjunction with debility, either existing from the beginning, as in persons of the strumous or otherwise delicate constitution, or induced or aggravated by the means employed in combating the acute stage. Perseverance in antiphlogistic treatment under a misapprehension of the local symptoms, which are apparently those of increased action, and a mistaken view of the case generally, increases the mischief. All our efforts must be directed here to strengthen the constitution, by nutritious diet with fermented liquors according to the powers of the digestive organs, by stimuli, cordials, and tonics, combining and varying these according to the circumstances of individual cases. The stores of the materia medica, however, are often insufficient when the nervous system has been considerably weakened by sedentary habits, excessive mental exertion, care and distress, residence in bad air and other depressing influences, and when the circulation and the restorative powers of the system have been consequently enfeebled. Here we must

restore nervous energy, strengthen the system by residence in pure air, especially at the sea-side, by exercise in the open air, by suspension of serious avocations, and the substitution of amusing occupations, by change of scene and everything that can promote tranquillity of mind.

When acute ophthalmia has been arrested by active treatment, it may be well to rest a little, and not to proceed immediately to new measures in order to guard against the imaginary evil of weakness. Allow an opportunity for the restorative powers of the part, and the constitution, to exert themselves. It is not necessary in medicine and surgery to be always doing something; to keep up an incessant fire of medicines and local applications. Nature will not stand still, even if the surgeon allows himself a little leisure: she proceeds, although the treatment be intermitted, in restoring the part to its healthy state.

If the powers of the system should be really reduced by the long continuance of disease, and the necessary treatment, it may be expedient to adopt direct measures for invigorating the system. Nutritious diet, fermented liquors in moderate quantity, good air and exercise, are the best restoratives: these should be combined with cautious use of the organ, which should be freely exposed to the air, and as much to the light as its irritability will allow. If the debility should seem to require, and more particularly if the patient should think that it calls for, the aid of the materia medica, we must employ the vegetable tonics and mineral acids.

Local measures; counter-irritation.—This is more applicable to chronic than acute inflammation; and we select in the former those means which have a more powerful and permanent action. Blisters are sometimes used, and afterwards the savine ointment. This produces great local irritation, which sometimes acts injuriously on the constitution. It is even dangerous in children, where it has caused sloughing. It is better to repeat the blister, than to keep up a discharge by irritating applications. A fresh blister, of moderate size, may be applied about once a week, behind the ear, at the side or back of the neck, sometimes to the temple or forehead. The tartar emetic ointment may be used in either of the modes already described. There is a third method in which it may be employed conveniently. A few grains of emetic tartar in powder are sprinkled over the surface of a Burgundy pitch plaster, which is applied and left on the back of the neck.

The permanent counter-irritation of seton or issue is an efficacious remedy in obstinate chronic ophthalmia. No other plan will more decidedly arrest chronic inflammation, and at the same time put a stop to incipient changes of structure, than this artificial discharge in the neighborhood of the eye, combined with the general treatment already described.

The integuments of the temple may be pinched up into a fold, so as to allow an elastic gum-seton, tape, or a piece of cotton wick, to be introduced in the usual way. Or an oblique incision may be made in the fold of skin with a double-edged knife, so as to turn up a little flap, under which two or three peas may be placed. It should be made as far back as may be convenient, that the scar may be less conspicuous.

There are, however, objections to the issue and seton in this situation; first, as they involve the existence of a discharging sore in a conspicuous part; and secondly, from the cicatrix which remains after they have healed. We generally, therefore, endeavor to accomplish our object in other ways. This objection does not apply to an issue in the arm, which may be employed with great advantage in chronic ophthalmia, as well as with a view to prevention, where recurrence of disease might be anticipated.

The most troublesome examples of chronic ophthalmia are those in which acute inflammation has been totally neglected, or very inefficiently

treated. Among the poor we see many such cases, in which the vessels have become permanently enlarged, and changes of structure have occurred in the surface of the organ from the long time which has been suffered to elapse without resorting to effectual means. This chronic excitement, probably kept up and aggravated by the patient pursuing his ordinary occupation and mode of living, is very difficult to remove, either by local or general treatment. Steady attention to diet, the regular use of aperients, repeated applications of leeches, combined with counter-irritation, are the most essential points of treatment. To these may be added the local application of stimuli and astringents in the manner which I shall proceed to describe.

Use of stimuli and astringents.—The points which remain to be considered in the treatment of chronic ophthalmia are, the question as to the use of local stimulants and astringents; the time and circumstances under which, if useful, they are to be employed; and the particular remedies of this kind which are preferable. When the eye is preternaturally red, when it is weak and irritable, when exertion of it or exposure to light causes watering and pain, though it may be easy while at rest, stimulants and astringents are resorted to with the view of causing the distended vessels to contract, and thus removing what remains of inflammatory excitement.

Of stimulants, the vinum opii, or vinous tincture of opium, has been much employed, both in this country and on the continent, in consequence of the recommendation of it by the late Mr. Ware;* I do not know whether it was first introduced into practice by himself or his partner, Mr. Wathen.† The mode of employing it is to introduce half a drop, a drop, or two drops, between the palpebræ, so as to bring it into contact with the surface of the conjunctiva. The fluid may be taken up with a quill or a director, and while the patient rests his head back, it may be dropped into the internal angle of the eye, so that when the lids are separated it may be diffused over the globe. The first effect is a sharp, smarting sensation, accompanied with a discharge of tears; but when this has gone off the patient generally feels relieved. The stimulus applied to the distended vessels is supposed to promote their contraction, and thus facilitate the recovery of their natural dimensions. It is employed once or twice a day. The vinum opii is the *tinctura thebaica* of the old London Pharmacopœia, often called by the continental authors, *liquid laudanum of* Sydenham; in which, however, half an ounce of saffron is added to the ingredients employed in making a pint. The ingredients were, an ounce of opium, half a drachm of cinnamon and of cloves, and half a pint of sherry wine. The opium and aromatics were macerated for eight days in the wine, and the tincture was then strained. In the modern pharmacopœias the tinctura thebaica was omitted, and a spirituous tincture, the present tinctura opii, substituted for it. Mr. Ware ascribed a peculiar virtue to the combination of ingredients in the old preparation; he thought the spirituous tincture had not the same effect, and he found that opium alone, or wine alone, would not accomplish the purpose. I believe it was in consequence of Mr. Ware's recommendation, and the general use of the remedy in ophthalmia, that the College of Physicians again introduced the vinum opii into their pharmacopœia: but it is singular that, as the efficacy of the remedy was so pointedly ascribed to the precise combination of ingredients in the old formula, it should have seemed fit to that learned body to diminish the quantity of opium one-half. Mr. Ware informs us in a subsequent edition of his treatise, that this new form is just as efficacious as the old, in which

* Remarks on Ophthalmy, &c.; 1780. † Ibid. Preface, and p. 53.

opinion I quite agree with him. According to Mr. WARE's representations, it is a remedy of sovereign virtue. He seems to have used it indiscriminately in all cases of ophthalmia, both acute and chronic; in acute, combined with leeches, blistering, purging, and the treatment ordinarily called antiphlogistic. Without specifying cases, he directs that the vinum opii should be dropped into the eye two or three times a-day; and he employs other treatment at the same time. I should never think of using it in acute ophthalmia; it would rather increase the inflammatory disturbance, though I must observe, at the same time, that it is not a very active remedy, and that it cannot do much mischief. Its employment should be restricted to cases of chronic inflammation, in which patients often express that they derive much advantage from its employment. I hardly remember, however, any case of a serious or obstinate kind, in which it has been decidedly effectual in arresting the disorder when employed alone.

Weak brandy and water is a popular remedy for bad eyes, and is used without any discrimination of the nature or period of the affection. However, being applied externally, it is only to be considered as a cooling wash.

Various astringent salts are employed in chronic ophthalmia, in the form of solution. Alum, in the proportion of two to ten grains to an ounce of distilled water; sulphate of zinc or copper, from one to six or eight grains; nitrate of silver, one to six grains; bichloride of mercury, from one-eighth of a grain to one or two grains in the ounce of water. These solutions must be introduced between the palpebræ so as to come in contact with the diseased surface. Their efficacy in common inflammation seems to be about equal to that of the vinum opii. In cases of purulent ophthalmia they have a more decided effect, as I shall have occasion to mention hereafter. The liquor plumbi diacetatis, undiluted, is used as an astringent. It might seem at first that it could not be safely applied to the eye in this state; but it is by no means an irritating application, though powerfully astringent.

A French oculist, M. ST. IVES, proposed a remedy, which has been much employed on the continent under the name of lapis divinus. It consists of a singular mixture: an ounce of alum, nitre, and sulphate of copper, respectively, are fused together in a crucible: half a drachm of camphor is added towards the end of the process. A solution is made containing ten grains of the mixture in six ounces of water, the strength of which is to be increased according to circumstances. Such a mixture cannot have any effect differing from that of simple solutions of the salts.

A German writer, CONRADI, has recommended a collyrium, which is often mentioned in the writings of his countrymen; it is composed of one grain of oxymuriate of mercury, six ounces of rose-water, one drachm of mucilage of quince seeds, and half a drachm or a drachm of the liquid laudanum of SYDENHAM.

It may be observed generally, with respect to all these proposed remedies, that if active treatment be resorted to in the first instance, and followed up steadily, they are not wanted; and if insufficient means have been employed, so that a state of chronic inflammation is produced, this is a complaint which it is extremely difficult to remove, and which is not likely to yield to the vinum opii, or any remedies of that class.

The use of strong astringents, more particularly the nitrate of silver, which has been found advantageous in inflammations of the conjunctiva, has been extended by Mr. GUTHRIE to other forms of ophthalmic inflammation, both acute and chronic. He proceeds on the principle "of exciting an action greater, and of a different nature, to that already existing in the part." He prefers the form of ointment to that of solution, on account of

its more permanent action: and he has recommended the two following formula: viz.

1. ℞.—Argenti nitratis gr. ij. ad x; liq. plumbi diacet. gtt. xv; ung. cetacei ʒj.

2. ℞.—Hydrarg. bichlorid. gr. iij. ad iv; liq. plumbi diacet. gtt. xv; ung. cetacei ʒj.

The saline substances must be reduced to an impalpable powder, then mixed with the ointment on a slab, and the liquor plumbi added. It may be done in a glass mortar. These ointments are most stimulating when first made; they gradually become less so; but weeks elapse before they are inert.

"The manner of using either ointment is by introducing between the lids a portion, larger or smaller as the case may seem to require it, from the size of a large pin's head to that of a garden pea. The eyelids being closed, are to be rubbed gently with the finger, so as to diffuse the dissolving ointment over the whole surface of the conjunctiva: a part of it usually, however, works out by the motion of the lids, and should be wiped off (if the nitrate of silver) to prevent its staining the skin. Both ointments cause pain: in some persons it is considerable, in others less so, lasting from half an hour to an hour and a half; and, when the ointment is newly made, sometimes for four hours, and even until the next day. On the subsidence of the pain caused by the ointment, that which previously existed is found to be relieved, if not entirely removed; and on the subsequent day, the patient usually acknowledges the benefit he has received with regard to all the symptoms. When the application has been severe, and the patient very irritable, a state resembling white chemosis occasionally takes place, and appears formidable to a person unacquainted with the effect of the remedy; it soon, however, subsides. The eye should be fermented with warm anodyne fomentations. I rarely repeat the application until the third day; but the feelings of the patient are the best guide, the return of some of the old sensations indicating the necessity for its use, which should be, if possible, anticipated. In some cases of acute inflammation, two or three applications will arrest the progress of a serious inflammation, and effect a cure. In chronic cases the ointment must be continued for a considerable time, and occasionally alternated with other remedies. Where it creates a state of regularly increased irritation, as it sometimes will do, cupping, purgatives, &c., are of service; when the remedies may be again resorted to." Mr. Guthrie has generally used purgatives, but has sometimes found the ointments successful in serious complaints without any internal medicine. Sometimes they have disagreed altogether. In the *London Medical and Physical Journal*, New Series, No. 27, from which the preceding account is derived, as well as in the 31st number of the same work, numerous cases are recited in illustration of the treatment. They are chiefly instances of chronic inflammation, purulent, common, and strumous, with thickening of the conjunctiva, opacity, vascularity, and ulcers of the cornea. At present, Mr. Guthrie seems to employ almost exclusively the ten grain nitrate of silver ointment.*

Experience must decide on the merits of the local treatment just described, and determine whether agents so powerful can be safely and advantageously applied to the organ in the various stages and forms of ophthalmic inflammation, for which they have been advised. The necessity of proceeding cautiously with these strong applications to a part so highly organized and easily irritated, if not obvious of itself, would appear from what has been stated by Mr. Guthrie; viz., that they are sometimes hurtful, and occa-

* London Medical and Surgical Journal, vol. i. p. 265.

sionally cause so much inflammation as to render the loss of blood by cupping and leeches, and other antiphlogistic treatment necessary.

When the nitrate of silver is to be employed, the form of solution is preferable in my opinion, to that of ointment; since the latter, in which the caustic is applied in substance, necessarily involves the risk of excessive partial action. This is one reason why I have never used these ointments; another is, that I have seen many persons, in whom, from their employment, inflammation had become aggravated and rendered so obstinate as to be removed with great difficulty. The value of any practical proceeding, in cases of common occurrence, is soon determined by general experience; and this I believe is to be decidedly unfavorable to the plan of treatment now under consideration.

Astringent and stimulating remedies, such as the nitrate of silver and the oxymuriate of mercury, when employed of proper strength and in suitable form, are most serviceable in a conjunctival inflammation; they are not only less adapted to inflammations of the external proper tunics, but often very injurious in such cases.

General summary of treatment in ophthalmic inflammation.—If I were to sum up generally the directions for treating ophthalmic inflammation, I should say, that in the young and strong, in persons of full habit, and in those individuals whose circumstances give them a command, not only of the necessaries, but of the comforts and luxuries of life, we should arrest inflammation by active antiphlogistic treatment; and then there will be no chronic stage, but the healthy structure and functions will be restored by the natural powers of the system.

In older and feebler subjects, especially in females, in those whose constitution is debilitated by excessive labor, by scanty, unwholesome nutriment, exposure to cold, and deficiency of clothing—by a want, in short, of the domestic comforts of life—we should be careful not to depress the general powers of the system. In addition to a milder and particularly local antiphlogistic treatment, we should invigorate the system by a better diet, by the moderate use of fermented liquors, by change of air, if it can be accomplished: to these means may be added the use of tonic medicines, and of local astringents in a suitable period of the complaint. We must bear in mind, however, that active local inflammation may take place in weak states of constitution; we may meet, in old and feeble persons, with such a degree of ophthalmic inflammation, as will require considerable depletion. On the other hand, local disturbance is sometimes rendered more obstinate by depression of general power; here depletion aggravates the mischief, and recovery of the part is promoted by general measures of strengthening and restorative character.

CHAPTER VI.

DIVISIONS AND CLASSIFICATION OF OPHTHALMIC INFLAMMATION. SIMPLE AND CATARRHAL INFLAMMATION OF THE CONJUNCTIVA.

Divisions and classification of ophthalmic inflammation.—Until a recent period inflammation of the eye has been treated of in too general a point of view, especially by the writers of France and England: it has been spoken of as a single affection under the term *ophthalmia*. The sub-

ject is thus considered in the *Treatise on the Ophthalmy* of the late Mr. WARE, in the work of SCARPA, and by his French translators, although it had been much better understood long before by the Germans, as will be clearly seen in the excellent essay on Iritis of J. A. SCHMIDT, and in the *Ophthalmologische Bibliothek*, which he edited in the very beginning of the present century in conjunction with Professor HIMLY.

The term *ophthalmia*, according to its etymological import, would embrace all inflammations of the eye. It is, however, evidently impossible to comprehend in one description the various inflammations affecting the very dissimilar structures, which enter into the composition of this complicated organ. Between many of these, the points of resemblance are few. What common characters could we expect to find in inflammations of the conjunctiva, sclerotica, cornea, iris, retina? Inflammatory affections of the external and internal tunics differ widely in their symptoms. Hence the attempt to embrace all these affections under one description must lead to obscurity and confusion. It produces an incoherent jumble of symptoms belonging to affections essentially distinct, where the general description is overpowered by the numerous limitations and exceptions, so that no part of the subject is clearly seen. The general descriptions of ophthalmia are usually applicable to external inflammation of the eye only, more particularly that of the conjunctiva, while the other forms of the affection are in great measure neglected. The important internal inflammations were entirely overlooked by English writers until within a few years: the subject is not mentioned by Mr. WARE.

Another reason why the inflammations affecting the several component parts of the eyeball should be described separately, is, that there are essential differences in their treatment. To a certain extent general therapeutic principles are applicable to all inflammations; but the general means must be employed in particular inflammations under various modifications; and there are important differences in the local measures; so that those which are advantageous in inflammatory affections of the conjunctiva would be inappropriate or hurtful where the sclerotica or the internal structures are the seat of disorder.

The whole globe may be inflamed at once, but this is a rare occurrence. In general, inflammation affects only the external or the internal tunics; and most frequently it attacks only one structure at a time.

We might class ophthalmic inflammations according either to the structure in which they are seated, or to the nature of the inflammation itself. In the latter case it is divided into *idiopathic* or *common*, and *sympathetic* or *specific:* syphilitic gonorrhœal, gouty, rheumatic, scrofulous ophthalmia, with some others, would come under the last division. The arrangement according to the seat of disturbance is preferable, as being the most natural and simple, and certainly the least liable to mistake or controversy. Indeed, the true nature of disease is not sufficiently understood in this or in other organs, to allow of our constructing a nosological arrangement on that basis: at least the opinions of pathologists and practitioners are not sufficiently settled on this point.

Inflammation of the eye is usually limited in its origin, and becomes more general in its progress. Commencing in one structure, it is at first confined to that, and does not extend beyond its original seat, if judiciously treated. But, if suitable means are not adopted to check its progress at an early period, it readily extends to the neighboring and connected parts, and perhaps ultimately embraces the whole organ. Mr. WARDROP, in his *Essays on the Morbid Anatomy of the Eye*, takes up each of the component structures, and gives an account of the changes which may be observed in it. This course is necessary in a work illustrating the morbid anatomy of the

organ; and I have adopted it as the best suited to the present occasion, though it cannot be followed up strictly, since we find it necessary, for practical purposes, instead of insulating the affections and changes occurring in each tissue, to attend to those aggregates of phenomena, which most commonly appear in practice.

I now proceed to describe the diseases incidental to each of the parts, which enter into the composition of the eyeball, taking them in their natural order from without inwards; and considering in each texture, the inflammations, the changes produced by the inflammatory process, and other alterations or peculiarities that may require professional notice.

SIMPLE INFLAMMATION OF THE CONJUNCTIVA.

The conjunctiva may be the seat of common inflammation, which is mentioned under the various names of *ophthalmia, simple* or *common ophthalmia, conjunctivitis simplex.* It is produced by common causes; being directly excited by various external irritations, such as injuries, extraneous substances, inverted eyelashes, tumors or other changes in the palpebræ; or arising indirectly from unhealthy states of constitution or derangement of particular systems or organs. It comes on also in consequence of inflammatory affections in other parts of the eyeball. The phenomena, progress, and effects do not differ, in any essential circumstances, from those of catarrhal ophthalmia, so that it is unnecessary to describe them separately. The treatment too, whether in the acute or chronic form, is nearly the same, and falls under the general rules applicable to the management of acute and chronic ophthalmia.

CATARRHAL OPHTHALMIA.

Synonymes. Conjunctivitis catarrhalis. Conjunctivitis puro-mucosa catarrhalis; ophthalmia purulenta mitior—MACKENZIE. The distinct nature of this affection, and its origin from atmospheric causes or peculiarities, are denoted in the terms *cold* or *blight*, under which it is often popularly mentioned; while the expression *ophthalmia mucosa* designates the increased mucous discharge, which is one of its most striking characters. It is inflammation of the conjunctiva, either of the globe, or of the lids, or of both caused by cold; and it corresponds to catarrhal affections of other mucous membranes, as those of the nose and its sinuses, of the fauces, trachea, and lungs. Catarrhal inflammation frequently goes through all these parts, and commonly so in influenzas.

This kind of ophthalmic disease has sometimes attacked numerous individuals, so as to have assumed a somewhat epidemic form.

Causes.—I do not use the term *cold* in the sense of diminished temperature, but to denote what is commonly called catching, or taking cold, *i. e.*, an injurious influence of cold or moisture applied to the surface, exciting disease either in the system generally, in the part chilled or wetted, or in some distant part of the body. What is the nature of this influence; and how are the effects produced? Everybody knows the effect, because everybody has experienced it; but the cause, or rather the chain of causes, connecting the external agency of cold or wet on the skin, with the production of morbid phenomena in a distant part, seems equally unknown to the ignorant and the learned. Why should mucous membranes so frequently suffer from this particular influence? Some of them are constantly and

freely exposed to the atmosphere, and therefore directly influenced by its changes and peculiarities: such as the Schneiderian membrane, that of the fauces, mouth, trachea, and lungs; and these are accordingly most susceptible of such influences. The mucous membrane of the eye is open externally, yet the whole surface is not so completely and constantly exposed to atmospherical contact as that of the membranes just enumerated. Catarrhal inflammation of the eye, therefore, is second in point of frequency. All mucous membranes are continuous, directly or indirectly with the skin; and, like the latter, secrete freely from their surface; these circumstances probably explain why they suffer so frequently from causes acting merely on the integuments. The conjunctiva is a part of the external superficies of our frame, and its connection with the common integuments is more extensive in proportion to its entire expanse, than in the case of any other mucous membrane.

Direct exposure of the part to cold and wet is the most frequent and powerful cause of catarrhal inflammation; exposure to cold winds, especially if combined with fog, rain, snow, or sleet. Particular winds are more capable than others of producing this effect, independently of the actual degree of cold; such is the case with east and north winds in this country. In individuals predisposed to the affection, being out in an east wind for a quarter of an hour, or half an hour, will sometimes infallibly bring on an attack. Length of exposure without exercise favors the action of the cause; hence soldiers and sailors on watch, or in camp, very often suffer. Great changes in the atmosphere from heat to cold, within a short period, bring on catarrhal affections. These vicissitudes are most common in hot climates, where the burning heat of day is succeeded by a chilly night air, often combined with heavy dews, to which persons frequently expose themselves by sleeping in the open air. Officers, being less exposed than soldiers, suffer less under such circumstances. Change of clothing and consequent chill of the surface, especially in variable climates; partial exposure to cold air, or, in common language, to draughts of air; and the application of moisture in partial or general wetting, which most effectually chills the body, are other modes of the same unwholesome influence. The application of these causes to the head, or in the immediate neighborhood of the eye, will most probably bring on catarrhal ophthalmia, when aided by original constitutional peculiarity, or by the general remote causes of disease. Atmospherical influences, of which the nature is entirely unknown, will operate powerfully on the mucous membranes, producing epidemic influenzas; but in these the conjunctiva merely suffers with the other mucous membranes: we have no epidemic ophthalmiæ extending over large districts, kingdoms, and even continents.

Catarrhal ophthalmia is seated in the conjunctiva, seldom going deeper, and therefore not dangerous; it may be confined to the lids, or may affect the globe also. The continental writers call the former *blepharo-conjunctivitis catarrhalis*, and the latter, *ophthalmo-conjunctivitis catarrhalis*.

Symptoms of catarrhal ophthalmia.—Stiffness and smarting, some uneasiness on exposure to light, watering, and external redness usher in the attack. When fully developed, it is characterized by redness, and increased *mucous* not *lachrymal* discharge: the pain is inconsiderable, and there is little or no intolerance of light.

The redness in catarrhal inflammation is superficial, and of bright scarlet color, forming a striking contrast to the rose or pink tint, which belongs to inflammation seated in the proper external coat of the eye. The distended vessels are quite superficial, and of scarlet color; they may be readily pushed aside by moving the lids. The trunks are seen at the circumfe-

rence of the globe; they run forwards in a tortuous course, subdividing and inosculating as they approach the cornea. The redness is generally irregular, in patches, some fasciculi of vessels being more filled than others; hence the membrane has a mottled appearance: however in the fullest development of this affection, the whole surface becomes of a bright red. The redness begins at the circumference of the globe, and gradually advances towards the cornea; but in the commencement it is confined to the palpebral conjunctiva, or to the angle of reflexion. Sometimes, besides the redness resulting from vascular congestion, especially if the inflammation be severe, we see red patches in the conjunctiva; these are spots of ecchymosis, small quantities of extravasated blood, and such appearances denote activity of the inflammation. Sometimes there are little vesicles, called pustules, on the conjunctiva, slight elevations of the membrane, containing a serous fluid, and usually appearing about the margin of the cornea.

Unless the affection be severe, with general redness and some thickening, the sclerotica may be seen through the inflamed conjunctiva, especially round the cornea, of its natural white color.

Catarrhal inflammation seldom produces much swelling of the conjunctiva, nothing like the state of chemosis incidental to the more acute inflammations of the membrane. The only approach to such an appearance is a slight serous effusion, raising the mucous membrane from the sclerotica into a loose elevation.

The pain in the commencement of the affection is not considerable, except in severe cases, the patient complaining rather of stiffness, dryness, or sensation as if sand or gravel had got into the eye. The intolerance of light is slight at first, and after a time the patient hardly complains of uneasiness, and opens the eye freely to the light even when there is considerable redness. The feeling as if a foreign body were in the eye, which is commonly experienced in conjunctival inflammation, appears to be produced by the partial vascular distension, and consequent inequality of surface and mechanical irritation on motion. If the fullness of the vessels is lessened by bleeding, the sensation subsides.

When the lachrymal discharge observed in the commencement stops, its place is supplied by increased secretion of mucus from the inflamed membrane itself; this is at first thin, and as the inflammation goes through certain changes, it becomes thicker, assuming a whitish or yellowish appearance, and sometimes putting on a character approximating to that of pus. This increased mucous discharge distinguishes the catarrhal form of inflammation. Its quantity will depend on the degree and extent of inflammation. It may be just sufficient to collect in small quantity at the corners of the eye; a whitish streak may be seen on the inside of the lower lid at the angle of reflexion; there may be enough to form more or less copious incrustations about the cilia, and to agglutinate the edges of the lids at night, or it may constitute a copious muco-purulent discharge, hardly distinguishable from that of mild purulent ophthalmia. The eyelids participate, more or less, whenever there is active catarrhal inflammation of the eye.

Other mucous membranes suffer when there is a severe attack of this inflammation; hence pain and sense of weight about the frontal sinuses and antrum. Under such circumstances there is more or less of catarrhal fever, chills, heat, headache, disordered stomach, and foul tongue, with impaired appetite or sickness. Such a state of stomach may cause inflammation of the conjunctiva, bearing all the marks of catarrhal character, without any atmospherical influence.

The symptoms of catarrhal ophthalmia, both local and general, remit by day, and undergo exacerbation at night. During day the redness is less; there is no pain, nor intolerance of light; the eyes become sore and uneasy in the evening, smarting and burning, with increased redness and mucous secretion.

Termination and prognosis.—The affection is seated in and originally confined to the mucous membrane; it passes through a certain course, and then subsides; it yields readily to treatment, and therefore, generally speaking, is free from danger. If the inflammation be violent, and either totally neglected or improperly treated, it may extend to the sclerotica and cornea, causing ulceration and opacity of the latter, and thus seriously injuring the organ. The affection is still manageable, if no mischief has actually occurred to the cornea.

Diagnosis.—Its catarrhal origin, the diurnal remission and nocturnal exacerbation of the symptoms, the absence of pain and intolerance of light, even when there is great general redness, the bright red tint of the membrane and of the distended vessels, and the superficial position of the latter, the natural state of the sclerotica and its vessels, and the mucous discharge, distinguish the catarrhal from common inflammation of the external tunics. It must, however, be remembered, that from the same exposure to cold, which causes inflammation of the conjunctiva, the sclerotica also may suffer; that the affection, which is then called *catarrhal-rheumatic ophthalmia* by some writers, is more dangerous under such circumstances; and that the symptoms differ in important points, being those described in the account of inflammation affecting the sclerotica. From purulent ophthalmia it is distinguished by its much milder character, as will be understood better when that affection is described. Yet the characters of the two affections approximate, particularly when we compare the severest catarrhal with the mildest purulent inflammation. On the whole, the difference is rather in degree than in kind; unless it should be established, which it is not at present, that the latter always is, and the former always is not contagious.

Treatment.—Catarrhal inflammation of the eye requires antiphlogistic treatment; but as the affection is not a serious one, and does not produce injurious consequences to the organ, mild measures will be found sufficient. Venesection is not in general necessary; but in a young subject of full habit, with catarrhal inflammation in both eyes, and that severe, a full blood-letting would be proper; in ordinary cases, cupping or leeching will suffice; and sometimes abstraction of blood is not necessary, the general treatment being sufficient. The bowels should be freely evacuated by an active aperient, or if the tongue be foul, an emetic may advantageously follow the loss of blood. Saline sudorific medicines may then be given, such as the liquor ammoniæ acetatis, with nitre, or tartrate of antimony, and occasional purgatives. The patient should be kept warm, taking plentifully of warm diluent drinks, and no animal food, nor fermented liquor.—If blood should have been taken by venesection or cupping in the morning, and the alimentary canal should have been subsequently cleared by an emetic and purgative, the warm bath, or warm pediluvium may be used at night, and a full dose of Dover's powder (from ten to twenty grains), given at bed-time. The patient will be nearly recovered the next day, or it may be necessary to repeat cupping or leeches, to persevere in low diet, diaphoretics, and purgatives for a few days, and perhaps to apply a blister to the nape. In cases where the inflammatory affection is not considerable, and seems entirely referable to a disordered state of the alimentary canal, it may not be necessary to take blood from the part. An emetic, and an

active aperient containing calomel, or the latter alone, may be administered, and followed by mild purgatives, the diet being light.

The best local application in these cases is warm water, or poppy fomentation; these are better than cold lotions in catarrhal inflammation. The Germans are anxious to prevent the application of cold and moisture to the eye, when laboring under catarrhal inflammation; they think that cold, which has originally caused, must aggravate the disorder, and hence they are very particular in their directions to use everything warm, and to dry the surface carefully afterwards. However, patients often find cold washes comfortable, and they are certainly not injurious. The sticking of the lids together during the night may be prevented by inserting a little mild ointment between the tarsal edges in the evening; a little fresh butter, a bit of lard, or the spermaceti ointment, will answer the purpose. After employing these means until the inflammation has somewhat given way, we may resort to counter-irritation by blisters; but the other treatment which I have recommended, will in most cases put a stop to the inflammation.

I subjoin the following case to exemplify the characters and treatment of a case, simply catarrhal, but rather severe.

J. C., fifty-six years of age, of full habit, was seen on the 4th of July, 1826, with inflammation of the right eye, which had commenced the day before. The symptoms were, general bright scarlet redness of the eyeball, deep red color of the palpebral conjunctiva, with some thickening of the ciliary margins and mucous secretion on them, a little mucus lying in the fold between the lower eyelid and the globe, pain in the eye and head, but no intolerance of light. The case of a boy, who was seen at the same time with inflammation of the sclerotica consequent on injury of the cornea, presented a striking contrast to the preceding description. In the latter, the redness was pink, with a violet or dilute claret tint; in the former, bright scarlet: the sclerotica was the seat of redness in one, the conjunctiva in the other. The vessels were large, superficial, and tortuous in the former; small, straight, and covered by the conjunctiva, in the latter; the redness covered the whole globe in one; it was confined to the neighborhood of the cornea in the other. There was no uneasiness on exposure to light where the whole eyeball was of a bright scarlet; great sensibility to light, with copious lachrymation, in the other case where the redness was comparatively trifling. The treatment consisted of venesection to sixteen ounces, purging, abstinence from meat and fermented liquor, and saturnine lotion. On the 8th the patient was nearly well. He came again on the 13th with a relapse. There was acute catarrhal inflammation of both eyes, with foul tongue. (Venesection to sixteen ounces, to be followed by an emetic of ipecacuanha and tartrate of antimony, and an aperient the next morning.) Saturnine lotion. 15th. Pain gone; considerable redness and mucous secretion. (A blister to the nape; one drachm of magnes. sulph. in the infus. ros. every six hours. Saturnine lotion. Cerat. cetacei to the eyelids.) 18th. The patient is free from complaint, but the redness is not quite gone. 22d. No trace of disorder is left.

Catarrhal ophthalmia, especially when the inflammation does not extend beyond the mucous membrane, is one of the cases to which the use of astringents is more particularly applicable. In the opinion of those who have tried it extensively, this local treatment may advantageously supersede the general means, particularly loss of blood. Mr. Melin proposed the employment of a strong astringent in the very commencement of the affection, as a means of cutting it short, and preventing the development of the inflammation. He adopted this proceeding in ordinary conjunctival inflammation, having considered that acute ophthalmia was in general

treated too actively, and that a mere local disorder could not require such extensive depletion as was usually practised and recommended. He was further induced to try the practice, from having witnessed the good effects of a solution of lunar caustic, in some cases of gonorrhœa, both in allaying the pain and suppressing the discharge. The strength of the solution employed was four grains to the ounce of distilled water, which was dropped into the eyes twice a day; it excited pain and a sensation of roughness, with an increased flow of tears for about twenty minutes, after which the eyes felt much relieved, and in a few days the cure was effected. "Since that period," says Mr. MELIN, "I have treated nearly three hundred cases of acute ophthalmia, some of them of a severe nature, in a similar manner, without either local or general bleeding, and I have had ample opportunities of proving its efficacy."* Mr. BACOT informs us that this plan of treating ophthalmia originated with Dr. RIDGWAY, who uses a solution of lunar caustic, in the proportion of ten grains to the ounce, and has employed it in gonorrhœal as well as in common conjunctival inflammation."†

Mr. MACKENZIE trusts to simple treatment, chiefly by local stimuli, which he saw employed with great advantage by BEER in 1817. He uses a solution of nitrate of silver, containing from two to four grains in the ounce, and applies to the eye a large drop once a day. He foments the eye thrice daily with a collyrium of one grain of corrosive sublimate in eight ounces of water, lukewarm. And he applies to the edges of the lids at night a small portion of ointment containing one grain and a half of red precipitate to the drachm.‡ "I have treated," says Mr. MACKENZIE, "many hundred cases of catarrhal ophthalmia according to the plan above detailed, and with uniform success. In almost no case, (indeed I may say in no case in which struma did not modify the symptoms,) in which the above simple remedies were had recourse to previously to ulcer or opacity of the cornea, did any ulcer or opacity ever occur; nor did the symptoms ever fail speedily to subside."

Mr. GUTHRIE uses his ten grain nitrate of silver ointment, see p. 201.

The utility of astringents, in the treatment of catarrhal ophthalmia, is now established by general experience. When employed at an early period, they often cut short the complaint; and they abridge its duration at whatever time they may be used. I employ the solution of nitrate of silver, in the proportion of two to four grains in the ounce of water; a drop should be introduced between the lids once, twice, or oftener in the twenty-four hours. Previously to the use of this remedy, or in conjunction with it, I employ such other means as are required to fulfil the indications already pointed out, namely abstraction of blood, or at all events the means necessary for acting on the alimentary canal and the secretions.

It is not necessary to cover or shade the eye, unless as a protection from strong light, if it should be offensive; when the common pasteboard, covered with green silk, may be used. We generally find that cool air is pleasant to the feelings of the patient; that it will remove the sensation of sand in the eye. It is not necessary to confine the patient to the house unless the weather be cold, windy, or rainy. Free exposure to a mild atmosphere is advantageous.

When catarrhal ophthalmia has been violent and long continued, more especially when there have been repeated attacks, the palpebral conjunctiva undergoes change of structure, becoming thickened, and exhibiting on its

* Report of Ocular Diseases at the General Hospital, Fort Pitt; London Medical and Physical Journal, vol. liii. p. 184.

† Treatise on Syphilis, p. 136—140.

‡ Practical Treatise, p. 334, 335.

surface the elevations called granulations. For a more particular account of this change, and its treatment, I must refer to CHAPTER VIII. on *purulent ophthalmia.* EBLE* has observed, that the lower eyelid suffers most in catarrhal ophthalmia, and that the granulations take place rather in the conjunctival folds between the lid and the globe, than on the lid itself.

When the eye remains weak after inflammation of the conjunctiva, whether of the common or catarrhal kind, the vinum opii is often employed with advantage.

If the complaint should continue in the chronic form, and be found obstinate, in conjunction with general debility, the constitution being naturally weak, or lowered by the continuance of disease and the treatment, or impaired by the various circumstances which are calculated to depress nervous energy, strengthening and restorative measures will be necessary, such as good diet with stimuli, tonic medicines, residence in pure air, change of air, and sometimes even of climate. In some cases the changes of air and scene in traveling, and the agreeable occupation of the mind with the various objects of interest met with on such occasions, have a beneficial influence on health not attainable in any other way. If local treatment were necessary under such circumstances, it would consist in mild stimuli and astringents, and mild counter-irritation.

Catarrhal inflammation of the eyelids has been already considered in CHAPTER II. SECTION II.

CHAPTER VII.

PURULENT OPHTHALMIA—PURULENT OPHTHALMIA OF NEWLY-BORN INFANTS.

CATARRHAL ophthalmia forms a connecting link between common or simple, and purulent inflammation of the eye, in which the character of the conjunctiva as a mucous membrane is most strongly marked. Purulent ophthalmia is inflammation of the most acute kind, attended with an increased secretion, which in all its sensible properties, especially color and consistence, so strongly resembles pus, that the name of the affection has been hence derived. This name is the best, being founded on the most obvious and striking character of the complaint; the term *blennorrhœa*, derived from the Greek, and generally employed by the continental writers, is equivalent. *Ophthalmia mucosa* is a name already occasionally given to the catarrhal inflammation of the eye. *Suppurative* ophthalmia is an objectionable expression, because the discharge, although resembling pus in color, is not the product of suppuration.

The affection begins in the linings of the lids, extends to the mucous surface of the globe; when violent and not checked, it soon attacks the cornea, which it either entirely disorganizes, or so considerably changes in structure, as frequently either to destroy, or seriously injure, sight. The whole texture of the membrane swells, and becomes thicker; its vascular tissue is developed, the blood-vessels being distended to the highest degree, and the surface acquiring an intense bright red. The membrane is rendered villous, pulpy, granular; in short, like that which lines some parts of the alimentary canal; and from the secreting surface, thus developed, flows the puriform discharge: but this is a secretion, or rather an exhalation, and

* Ueber den Bau und die Krankheiten der Bindehaut, §§ 75, 76, pl. 3, fig. 13.

hence the epithet *suppurative* is inappropriate. Indeed, this form of disease does not, like some others, produce suppuration of the eye. The changes in the cornea are sloughing, suppuration, ulceration, interstitial deposition, causing opacity, and enlargement of vessels or vascularity. The sloughing, ulceration, and suppuration, often expose the anterior chamber, causing prolapsus of the iris, and may, by giving rise to escape of the humors and collapse of the tunics, not only destroy the function, but also the very form of the eye.

Purulent ophthalmia is originally seated in and confined to the mucous membrane, and often goes through its course without extending further: if it goes deeper, it is by the propagation of inflammation through the medium of continuous textures, and especially by the progress of ulceration.

It attacks at all ages, and under all circumstances, and seems to be always essentially the same; yet there are modifications. I shall describe three forms of it, viz.

1. *Purulent ophthalmia* of newly-born infants.
2. *Purulent ophthalmia* after infancy.
3. *Acute gonorrhœal ophthalmia.*

The first two are unquestionably the same affection, distinguished only by circumstances arising out of the age of the patient. There are some peculiarities in the latter, referable probably to the specific nature of the cause.

PURULENT OPHTHALMIA OF INFANTS.

This is the *purulent ophthalmia of newly-born infants; ophthalmia neonatorum;* the "*purulent eye*" of children of Mr. WARE. I do not know that any other person has used the latter term, and I see no good reason why it should be adopted, as the proper tunics of the eye are not necessarily involved in the affection.* BEER uses the name *blephar-ophthalmitis glandulosa*, as if the disease had its origin or seat in the Meibomian glands. I am quite at a loss to account for such an opinion; though I do not doubt that the glands may be involved.

Symptoms and progress.—This disease is one of considerable consequence, and the more so from its commencing in a way not calculated to excite the attention, or alarm the fears of the mother or nurse. The child cannot express its sensations, and the concomitant swelling conceals the progress of disease so that serious mischief is often done before we see the patient. In the first place the inflammation is not immediately noticed, and in the second, the measures employed are frequently insufficient to check its progress: hence it causes more blindness than any other inflammatory disorder that happens to the eye; and the number of children is very considerable, whose sight is partially or completely destroyed by it. They are frequently brought to us with staphyloma, opacities of the cornea, and prolapsus of the iris; or with the tunics collapsed, and the very form of the eye destroyed. Mr. RYALL, of Dublin, mentions that a woman brought to him in a wine-glass both the lenses of her infant's eyes, with part of the vitreous humor, which had escaped before application was made for relief.† The parents and attendants are apt to suppose, when this inflammation first appears, that it is merely a cold in the eye, which

* Lehre, vol. i. §§ 304 and 323.

† Transactions of the Association of Fellows, &c., of the College of Physicians in Ireland; vol. iv. p. 343.

will go off; and the consequences just mentioned take place, in many cases, before they are aware of the danger, and before they resort to surgical assistance.

The inflammation commonly comes on about three days after birth, but it may take place at a later period. In the first stage, it is confined to the mucous lining of the palpebræ. It is observed that the lids stick together a little when the child wakes from sleep; their edges are redder than natural;* and especially at the corners; the child experiences pain from the access of light, and therefore keeps the eye closed. If the lids are inverted, their linings are found red and villous, and a little white mucus is seen on the inside of the lower. The globe is in a natural state. This first stage of the complaint is the *blepharo-blennorrhœa* of the nosologists; that is, purulent inflammation of the palpebral conjunctiva.

In the second stage, all the symptoms are increased; the inflammation extends from the conjunctiva of the lids to that covering the globe; the vascular congestion and redness are much augmented; the lids swell and become red even externally; there is a copious secretion of purulent fluid from the inflamed membrane, which agglutinates the edges of the palpebræ, and then accumulates between the lids, or pours over the face, staining the cap and linen. Exposure to light becomes very painful, and the child turns away its head and contracts its brow, keeping the eye constantly shut, even if the swelling of the lids should not close them. The case now becomes *ophthalmo-blennorrhœa.*

The inflammation, the redness, and the tumefaction of the conjunctiva are carried to the highest pitch in the second stage of the complaint; the whole of the conjunctiva, both palpebral and ocular, is swollen, and of a uniform bright scarlet color. The surface at the same time assumes a villous character, resembling in the latter respect, and in its color, the appearance of the internal surface of the fœtal stomach, after a successful injection with size and vermilion.

The close adhesion of the membrane to the tarsi prevents the palpebral conjunctiva from swelling much; but the loose folds between the lid and the globe become greatly enlarged, forming red tumid rolls, finely granulated. These folds, pressed on by the orbicularis, evert the tarsi, causing ectropium of either or both lids. This eversion takes place when we attempt to examine the eye by separating the lids, or it will be produced even by crying. It is generally temporary, subsiding when the cause ceases to act; but it may be more permanent. If the case be neglected, no attention being paid to replacement of the everted lid, the protruded conjunctiva swells still more, and experiences pressure from the ciliary margin of the tarsus, which causes a kind of strangulation, and increases the difficulty of restoring the parts to their natural position.

There is general, and often very considerable tumefaction of the lids from serous effusion into their cellular texture; they become red externally, and in cases of the severest inflammation, the upper lid presents a smooth convexity of bright red color. When thus swollen, the upper lid hangs over the lower. The redness and swelling are increased by crying, when the whole globe is pushed forwards.

A profuse discharge takes place from the eye, and pours over the face of the child in crying, or when the lids are opened. The latter are aggluti-

* Mons. Billard, in a note to his translation of my lectures, says, "External redness of the eyelids often occurs at the outset of the inflammation. I have seen in infants a transverse red line on the eyelid before the puriform secretion began. From this redness Mons. Baron has often prognosticated, at the Foundling Hospital, the approaching attack of ophthalmia."—*Traité Pratique*, p. 160, note.

nated by the drying of the discharge, and then become distended with the puriform secretion, which issues in a stream on opening the eye. During the night the eyelids become so firmly stuck together, that they must be carefully moistened and soaked with warm water, or milk and water, to open them. When they are separated, the eye is concealed by the discharge; we wipe it away with a soft rag, and there is still enough to cover the globe and hide the cornea, and ultimately we find the latter frequently covered by a kind of coagulated layer which must be removed by syringing. The discharge may be whitish, like the pus secreted by a healthy ulcer, and it then is generally small in quantity. More commonly it is yellow in various tints, and more copious; it is straw or lemon-colored, or it stains linen yellow, like the yellowest gonorrhœal discharge. This yellow tint is very deep in unhealthy jaundiced children, sometimes being of a yellowish green. It may be thinner and of a reddish color; that is, ichorous or sanious. Sometimes there is an admixture of actual blood.

Effects.—In this second stage, the inflammation has passed from the palpebral lining to the surface of the globe; the conjunctiva scleroticæ is found red, and it may be elevated by serous effusion. If the inflammation should continue, and not be checked by suitable treatment, it extends to the cornea, and thus may reach the interior of the globe. Some one or more of the following changes are now produced.

1. *Sloughing* of the cornea, general or partial. When this change is about to take place, the cornea is at first whitish and dusky, then loses its polish and firmness of texture, being converted into a dirty grayish or brownish slough, in which the loss of vitality is immediately obvious; a line of separation takes place at the margin, and the dead part is soon cast off. The entire cornea may thus perish and separate, when the iris protrudes through the aperture, presenting an irregular dirty brownish prominence. Under such circumstances, the iris may either be nakedly exposed, and the humors escape, or it may be covered by a thin pellicle, by what is called the membrane of the aqueous humor. This, however, generally gives way, so as to lead ultimately to collapse of the globe. The separation of a partial slough leaves a whitish flocculent and ragged ulcer, which, unless its character be soon changed, speedily makes its way into the anterior chamber, and causes prolapsus iridis.

2. *Ulceration* may take place in the cornea, more or less considerable in extent or depth; it may affect nearly the whole surface, or it may penetrate the cornea, and lead to prolapsus iridis. The latter part may adhere to the ulcerated aperture, and the ulcerative process stop, or it may go on, and extend to the interior of the globe.

3. *Opacity* of the cornea from interstitial deposition, either into the texture of the corneal conjunctiva, causing a thin external bluish-gray film, or into the corneal substance, producing dense total opacity. These changes may be confined to a small portion, or may affect the entire cornea.

4. *Adhesion* of the iris to the inflamed or ulcerated cornea. Such are the principal, more or less serious, visible alterations in the cornea, anterior chamber, and iris, which take place when severe purulent ophthalmia extends from the mucous membrane, in which it commences, to the globe; the last of these, however, although it occurs at this period, is not discoverable till afterwards, being concealed by the almost invariable concomitant opaque state of the cornea. These several diseased processes occur very quickly, and go on rapidly, as we might expect, *à priori*, from the great activity of the capillary circulation in infants, and the acute character of the inflammation.

Examination of the eye is difficult from the swollen state of the lids,

and the smallness of the palpebral aperture; but it is important, particularly in the first instance, that we should ascertain the exact state of the organ, the seat and extent of the mischief, and thus be enabled to form our prognosis. The painful impression of light causes the infant to resist any attempt at exposing the cornea, and the ectropium immediately produced by the forcible action of the orbicularis completely obstructs our view. The best and easiest mode of examining the eye of an infant is to open the lids while it is asleep; if the attempt be made lightly and gently, we generally succeed in obtaining a clear view of the cornea without awakening the patient. If it be awake, we should take the opportunity when it is quiet, and separate the lids quickly before the muscles can resist. If the child be crying when the attempt is made, it is scarcely possible to obtain a view of the cornea, on account of the violent contraction of the orbicularis; and the force uselessly employed in attempting to do so cannot but be injurious. In opening the lids, if the upper be raised by the skin merely, the action of the orbicularis will produce an eversion of the tarsus, and hinder us from seeing the cornea; but if the tarsus itself be pushed upwards and backwards, the accident will be prevented. If the lid should be everted, it may be easily restored by drawing the tarsus gently downwards. If we meet with much difficulty, it will be best to discontinue our attempts, and renew them at a more favorable opportunity. Forcible and long-continued efforts will aggravate the inflammation; and incautious proceedings of this kind, when the cornea is seriously involved, might cause it to give way, and even lead to escape of the humors.

In the third stage of the complaint, there are a gradual abatement and cessation of all the symptoms; the redness, swelling and discharge are diminished; the child bears the light better, and, when the increased discharge is removed, it opens the eyes spontaneously in the evening, or in a dull light. No ectropium takes place on crying, or when the eye is examined. We now see clearly the changes that have occurred under the active inflammation, and we have the opportunity of tracing the progress of these towards recovery.

When the entire cornea has sloughed, and the humors have been evacuated, the tunics collapse, and the globe shrinks to one-third of its original size, appearing as an opaque, somewhat flattened tubercle. If the humors have not escaped, the projecting iris recedes again, and becomes covered by an opaque pellicle, the front of the eye being flattened.

In the case of large sloughing, or extensive ulceration, the iris falls against the cornea, becomes adherent to it, and partial or general staphyloma ultimately ensues. If prolapsus iridis has taken place through the opening caused by partial sloughing or ulceration, the brownish tumor gradually subsides, and at last disappears; we then see a small dark point in the cornea, surrounded with a white circle, which is the cicatrix of the corneal ulceration. The iris adheres firmly to the internal surface of the cornea at this part, and there is usually change of figure, with more or less contraction of the pupil. According to the situation and extent of these changes, vision may be either impaired or lost.

The ulcers of the cornea, while spreading, are of a dusky white, yellowish, or light reddish color, irregular in their surface, and often with a ragged edge; they are surrounded by a dusky white halo. When they begin to heal, they have a grayish or bluish aspect, become smoother, have a soft gelatinous appearance from deposition of the substance which is to repair the breach, and red vessels pass to them from the conjunctiva, through the intervening transparent portion of the cornea. They heal, leaving a permanent opaque cicatrix; and this opacity will be of more or less

importance as it is situated in front of the pupil, or at a distance from it. The red vessels, having fulfilled their office of depositing the materials necessary to repair the breach, shrink and disappear.

Interstitial deposition into the texture of the cornea leaves permanent opacity of various extent and density. When it is dense (*leucoma, albugo,*) and when consequently the cornea has been inflamed throughout, the inflammation will readily pass to the iris; that two inflamed parts brought into contact should adhere might be expected. This preternatural connection is technically called *synechia anterior.*

No doubt in these cases the surfaces containing the aqueous humor are generally inflamed, and it is not uncommon to find a central opaque spot on the capsule of the lens, with the leucoma and synechia anterior: such an opacity may, however, be produced without the two other changes.

Superficial opacity, caused by effusion into the corneal conjunctiva, and the slighter degrees of impaired transparency from interstitial deposition into the corneal laminæ, will disappear spontaneously, sooner or later.

In milder cases none of these consequences are produced; the tumefaction of the conjunctiva gradually subsides; the discharge is lessened, but in a whitish form it continues for some time, and the conjunctiva slowly returns to its healthy state.

When the complaint is severe, infants suffer constitutionally; they become restless and debilitated; the tongue is white, and the bowels are irregular. They become pale and feeble when sloughing has occurred.

Both eyes are usually affected, but the complaint does not commence in both at the same time; there is generally an interval of a few days.

Causes.—In a great proportion of cases there is a vaginal discharge from the mother, leucorrhœa, and sometimes gonorrhœa. The eyes of the infant are exposed to the contact of these morbid secretions in passing through the vagina; hence has arisen the natural inference that they are affected from the actual contact of this matter, and the tolerably regular appearance of the disease on the third day corroborates this notion of contagious origin from direct application of the morbid matter.* I was acquainted with a case, in which a married gentleman contracted gonorrhœa, and communicated the disease to his wife then pregnant. The infant, which I did not see till four months after birth, had been affected with purulent ophthalmia; one of its eyes was staphylomatous, and the cornea of the other was inconsiderably nebulous. The affection had been totally neglected, even the attendant accoucheur having stated that it was merely a cold in the eye, which would do well of itself. I have seen some cases of rapidly destructive purulent ophthalmia in infants, when the mother has had gonorrhœa at the time of parturition. Sloughing of the cornea, with extensive ulceration spreading to the interior, and consequent evacuation of the globe, had occurred in these instances before I have seen them. An example of purulent ophthalmia in an infant, where the communication of gonorrhœa to the mother, and the infection of the child's eyes by the vaginal discharge were unequivocal, is related towards the end of this chapter. Although the inflammation was severe, it did not produce the serious effects just alluded to.

If the purulent ophthalmia of infants arises, as I believe that it does,

* "I will not maintain," says SCHMIDT, "that blepharo-blennorrhœa of those new-born infants, whose mothers have leucorrhœa, is produced by direct contagion, like gonorrhœa; but I have ascertained clearly that in many such cases, discharge from the vagina exists in the mother. And I have further discovered, not unfrequently, in the case of female infants, that the mucous membrane of the female organs was affected as if they had a clap."—Ophthalmelogische Bibliothek, v. ii. st. 2, p. 125.

from the direct contact of infectious matter, we should expect that the discharge from the eye would again communicate the disease. This has occurred in some instances from the discharge spirting out of the eye under syringing; and Mr. MACKENZIE saw an instance, in which a grandfather was inoculated from an infant. "Both were so severely affected, that the infant had one eye left in a state of total, and the other of partial staphyloma; while in each eye of the old man, the greater part of the cornea remained opaque, and adhered to the iris."*

Again, purulent ophthalmia is often seen in the children of healthy mothers, at least, of such as appear perfectly healthy, and deny, when questioned, the existence of vaginal discharge in any shape. As we cannot carry the investigation further, the source of the complaint must remain at least doubtful in such cases, and consequently the contagious origin of the disorder is still open to dispute.

However we may settle the question of contagion, considered as the direct or exciting cause of purulent ophthalmia in infants, numerous facts show that certain circumstances have a great influence in favoring its occurrence; so that, if the application of matter secreted in the vagina immediately excite the disorder in some, there are others in whom we can only trace the influence of ordinary causes, and we are thus led to conclude that the same kind of agencies, which produce other inflammations, may also excite this particular form. All the influences which depress the system, are favorable to the appearance of purulent ophthalmia. It is most frequent and destructive in weakly children, in those who are most exposed to the various debilitating causes of bad air, cold, insufficient clothing, and deficient nutriment. Purulent ophthalmia is more frequent in premature infants than in those born at full time; in twins than in single children. It is much more common among newly-born infants than in children; in children than in adults; it thus appears that as the powers of the system become more fully developed, the susceptibility to this complaint is lessened. It is more frequent in damp and cold than in dry and warm weather, and among the children of the poor and necessitous than in those of the higher classes. It is particularly prevalent, unmanageable, and destructive or injurious to the organ, in foundling hospitals, where infants are collected in great numbers, and deprived of what seems essential to their existence, the incessant care and watchfulness of the mother. I do not speak of such institutions as the foundling hospital of London, which does not receive infants; but of the foundling hospitals of Paris, Petersburgh, Moscow, and Vienna, which receive all the infants that are presented. The mortality in these establishments is enormous: the infants suffer from various diseases, and among them from purulent ophthalmia. It is of essential consequence to the well-being of the child at this tender age, that it should receive that constant attention and affectionate care which a mother only can supply. Although the institutions in question are admirably conducted, they can never make up for this deficiency. LANGENBECK observes that in the lying-in hospital of Vienna, where the women admitted are of the lowest class, and almost universally laboring under gonorrhœa or other vaginal discharge, but where the infants remain with their mothers, purulent ophthalmia is not common; while in the foundling hospital, where the children have not the advantage of maternal care, and where they are generally half dead from starvation and cold before they are received, the affection is very frequent.—(*Neue Chir. Bibliothek*, vol. iii. p. 208.)

Prognosis.—There is a singular contrast between the violence of this

* Practical Treatise, 3d edition, p. 402.

disorder in newly-born children, and the serious consequences to which the inflammation so rapidly leads, and the readiness with which it yields to suitable treatment. Hence, if we see a case of purulent ophthalmia before any injury is done to the cornea, we may assure the parents, and it gives us great pleasure to be able to do so, that sight will not suffer. If the inflammation be confined to the palpebræ, or even if it has extended to the globe, provided the cornea remains clear, it cannot be considered as attended with risk; for by the adoption of proper means, all injurious consequences to the organ will be averted; even the most violent form is easily manageable, and will do well when properly treated. But if the disease has advanced so far, that the cornea has sloughed, or extensively ulcerated, loss of sight is unavoidable. Even if the cornea be of a dull white, or has begun to lose its transparency, injury or loss of vision is probable; it is most likely that ulceration, prolapsus of the iris, or permanent opacity will follow. General superficial opacity from thickening of the corneal conjunctiva, and even a general whiteness so dense as to conceal the iris and pupil, will disappear.

The appearance of the discharge affords some information; the whiter and the smaller in quantity, the lower is the degree of inflammation. The yellower and more copious the discharge, the more active is the disorder. If it should be thin, ichorous, or sanious, we conclude that sloughing has occurred, and that spreading and destructive ulceration is going on. The admixture of blood shows a violent degree of action in the part, but it is not in itself dangerous, although it alarms the female attendants. It often relieves the overloaded vessels of the conjunctiva, and is thus attended with benefit to the organ.

Treatment.—In the most acute form of the disease, when the conjunctiva oculi is bright red, and swollen, more especially when the cornea has begun to look hazy; or if the palpebræ are much swollen and bright red, though we may not be able to see the eye itself, it will be necessary to take blood from the part by leeches. The superior palpebra is the best situation for the application; and a single leech may be placed in the middle of the red swelling which it forms. From the vascularity of the skin, leech-bites bleed very freely in these young subjects; one leech thus applied will almost invariably remove the redness and swelling of the lid, and this favorable external change is attended with corresponding diminution of the conjunctival inflammation. I have seldom seen it necessary to use more than one leech, and even this sometimes renders the infant quite pale; in the most robust children I should not advise more than two, one to each lid, or one to the upper lid of each eye.

If the state of the cornea should be doubtful, with congestion still active in the conjunctiva, although the palpebræ should not be much swollen, it is better to apply the leech. On the occasions I have described saturnine lotion made with rose-water may be used. The bowels should be opened, and kept open by castor oil or magnesia; when the inflammation is active, with a white state of the tongue, a grain or two of calomel may be given previous to the administration of the purgative. The use of blisters has been recommended; but I am unwilling to employ them in infants and children; unless, therefore, such counter-irritation is absolutely necessary, I consider it better to be avoided. A physician of the lying-in hospital of Vienna recommends the constant application of cloths dipped in cold water, and uses no other means, external or internal. Knowing the violent nature of the inflammation, and the serious injury it is capable of producing, I should not feel contented to rely upon such a plan.

We must prevent the agglutination of the lids, and favor the ready escape

of the discharge, by frequently bathing with tepid water or milk, and using a little lard or fresh butter; we do this, not because the discharge possesses the power which Mr. WARE supposed it to have, of corroding or ulcerating the cornea; but in order to prevent irritation from distension of the lids, when glued together, and to obviate excoriation of them or the surrounding parts.

Having diminished the violence of the inflammation by the antiphlogistic means just described, we immediately proceed to employ astringents; I may observe, however, that the use of such applications is both safer and more advantageous in this form of ophthalmic inflammation than in any other. We generally use a simple solution of alum, in the proportion of two grains sometimes, generally of four grains, which may be increased to six grains, in the ounce of distilled water. This solution may be carefully injected between the palpebræ, so as to cleanse out all the purulent secretion, three or four times in the twenty-four hours. The use of the syringe, however, is not free from risk, especially in the hands of nurses: the object may be accomplished by frequently cleansing the lids with a soft rag dipped in the solution, and afterwards laying it over the eye for a short time. With the continued employment of this astringent solution, an occasional dose of some mild aperient may be combined; and usually nothing more is required. The swelling and redness of the membrane are lessened, the discharge abates, and the organ recovers its natural appearance, some congestion and thickening of the palpebral conjunctiva, and some increased mucous secretion often continuing for a considerable time.

In the great majority of cases, and in all those where the conjunctiva oculi does not yet participate in the inflammation, the astringent may be employed at once. Such was the treatment in forty-nine cases out of fifty at the London Ophthalmic Infirmary: using no other means than magnesia internally, and the solution of alum locally; and out of many hundred instances, I hardly recollect one where the eye suffered in any respect, if the cornea was clear when the infant was first seen. When there is occasion to change the lotion, from the eye being accustomed to the stimulus of the alum, we may advantageously resort to the nitrate of silver, beginning with one grain to the ounce, and doubling the strength if necessary. This solution may be dropped between the lids two or three times a day.

Mr. WARE, whom I should have mentioned, as having given the first express description of this complaint in our own, or I believe in any language, particularly recommends an astringent solution of rather complicated preparation and composition, called BATES's camphorated water.—It may be made by pouring eight ounces of boiling water on eight grains of the sulphate of copper, the same quantity of Armenian bole, and two grains of camphor: let it stand till cold, and then pour off the clear liquor for a lotion. This composition has no superiority over the solution of sulphate of copper or alum; indeed, I consider the latter, and the lunar caustic, the best astringents, and a solution of them in distilled water the best form of the remedy.

The lotion used by SCHMIDT (lib. cit. p. 141) was composed of zinci sulph. gr. ij; liq. plumbi diacet. gtt. iij; spirit. vin. camph. gtt. xij; in aq. distil. ℥j.

Mr. MACKENZIE* employs the collyrium of corrosive sublimate (gr. j ad ℥viij.) three or four times in the twenty-four hours. He applies once, or at most, twice a day, to the conjunctiva, previously cleared by the former collyrium, a solution of lunar caustic, (gr. iv ad ℥j.) or sulphate of

* Practical Treatise, p. 363, 364.

copper, (gr. vj ad ℥j) by means of a camel-hair pencil. And he prevents the adhesion of the lids during the night by smearing their edges at bed-time with the mild red precipitate ointment. (See p. 127.)

Mr. GUTHRIE* uses his nitrate of silver ointment (see p. 219,) applying it with a brush all over the inside of the lids.

[Dr. VARLEZ, of the Military Hospital of Brussels, in a letter to Mr. Guthrie, (*Lond. Med. and Phys. Journ.*, Nov. 1827, p. 386,) extols the *chloride of lime* as nearly a specific in purulent ophthalmia. In the same journal, (p. 389,) Mr. GUTHRIE relates three cases in which he resorted to the remedy with advantage. It is applied in solution, in the proportion of one scruple to an ounce of distilled water, and the strength may be increased to four drachms to the ounce of water. (See *Am. Journ. Med. Sci.*, Feb. 1828, p. 459.)

Dr. HERZBERG, of Berlin, has also employed this remedy, and reports favorably of its use; (see *Am. Journ. Med. Sci.*, Feb. 1832, p. 518.)

Recently, Dr. RADCLYFFE HALL has adopted the use of this article, and speaks favorably of it, in purulent ophthalmia, both in the adult and in children. He employs a saturated solution, and his mode of using it is as follows:—

"The eyelids are slowly and gently separated until the cornea can be seen, when that is manageable, and all secretion wiped away with a fine soft sponge. A large bushy camel-hair pencil, charged with the strong solution, is then insinuated beneath the upper eyelid and swept round the front of the eye; the pencil is again charged with the solution and applied to the everted lower lid. Unless plenty of the fluid be thus applied, the application will be equally painful but less effectual. There is considerable pain, of a smarting, burning character, for half an hour or longer, and the already swollen eyelids become still more tumid and prominent. This tumefaction is œdematous in character, the skin losing in some measure its peculiar redness, and becoming more transparent. In a few hours, a serous discharge oozes out from between the eyelids, and the swelling partially subsides. This is followed by secretion of matter, but after two or three applications of the chloride, in perceptibly diminished quantity, the discharge gradually loses its characteristic yellow color, and is seen in flakes on opening the eyelids. After three or more applications, the eyelids no longer swell as they did after the first, and the pain is much less. As the inflammation lessens, the lids assume a shriveled, wrinkled, yellowish appearance, and the patient can open his eyes without touching them. The eyes are kept clean with warm water, matter never being suffered to collect beneath the upper lid, a little spermaceti ointment is smeared on the edges of the eyelids, and the strong solution is applied once in every twenty-four hours, until the secretion ceases to be in the least degree puriform. No other treatment whatever is necessary. The longest period required for cure has been a month: the shortest four days."†

Our experience with this article does not confirm these favorable reports of its efficacy. Fifteen years ago we employed it, but with results so little satisfactory, that of late years we have not resorted to it.]

In cases of ectropium, the lids should be restored to their proper position as soon as possible, and this should be repeated as often as the eversion is renewed. If replacement should be prevented by strangulation and swell-

* Lectures at the College of Surgeons, in the London Med. and Surg. Journal, vol. i. p. 297.

† Provincial Med. and Surg. Journal, Dec. 18, 1844.

ing, the conjunctiva may be scarified, and solutions of alum or the nitrate of silver should be afterwards applied. A light application of the latter in substance might be necessary in an obstinate case.

When the cornea has sloughed, the violence of the inflammation abates, being succeeded by an unhealthy and destructive ulcerative process, which, if unchecked, soon penetrates the cornea, and exposes the interior of the organ. The separation of the slough leaves a white flocculent ragged ulcer, in which there is no disposition to reparation. The constitutional symptoms undergo a corresponding change, the infant becoming pale, weak, restless, and irritable. Under these circumstances the powers of the system must be supported by tonics, of which bark is the best. The most convenient form for administering the remedy, is that of the resinous extract, which the infant will take easily, when broken down and blended with milk: from four to ten grains may be given in this way every four or six hours. It speedily renovates the powers of the system, and produces an equally beneficial local influence. The sulphate of quinine might also be employed, rubbed down with sugar. The solutions of alum and nitrate of silver may be used to the eye.

I relate the following case to illustrate some interesting points in the disease. A gentleman, under my care for gonorrhœa, communicated the disease to his wife, who had it severely. Although she used various means, the discharge continued, and was still copious when the infant was born, on the 12th day of the month. On the 15th, the infant's eyes, which had been remarked as clear, strong, and beautiful immediately after birth, were observed to be rather gummy and sore, and they began to run on the next day. I saw it on the 21st, when there was inflammation of the conjunctiva, both palpebral and ocular, with bright redness, moderate swelling of the lids, and copious yellow discharge; (castor oil and alum lotion gr. iij ad ℥j.) It went on favorably, and I heard nothing more of the case till the 28th, when I saw the child under a great increase of the inflammation. The palpebræ were bright red, and so swollen, that it was difficult to get a view of the eyes. The left cornea was now so opaque, that I could not distinguish the color of the iris; the right was also opaque throughout, but in a slighter degree. (One leech to each upper lid.) 29th. Much relieved by the leeches, which caused free bleeding; the right cornea is clear. (One leech to the left upper lid.) 1st July. The left cornea is nearly clear. (Alum lotion; solution of lunar caustic gr. ij—iij ad ℥j dropped in once daily.) 19th. Both eyes are perfectly recovered.

Monsieur Billard has mentioned, in his translation of my lectures, (p. 170, 171,) an instance of spontaneous recovery from opacities of the cornea, which had been considered hopeless. "At the Foundling Hospital at Paris I saw a child completely blind after purulent ophthalmia: the cornea was opaque throughout in both eyes. The child remained in the infirmary for a year, without any attention being paid to the eyes. The opacities gradually lessened, and sight was restored."

[We have seen some striking examples of the same character, and have often surprised our friends who have called us in consultation, by prognosticating a restoration of sight in cases which seemed to them utterly hopeless. The absorbent process in infancy is extremely active, and the powers of nature alone, or assisted by gentle stimulants, will often remove very extensive deposits of lymph in the cornea. In January of the present year we were called to an infant, both of whose corneæ were opaque in the greater part of their extent, and now after the lapse of only five months the opacity has so far diminished that the

cornea of one eye is transparent over three-fourths of the pupil, and of the other over about one-third. The infant's sight is consequently good; and strabismus and great unsteadiness of the eyes which existed at an early stage of convalescence, have now entirely disappeared. A collyrium of one to two grains of sulphate of cadmium in an ounce of water has been daily used since the inflammation was cured, and the clearing of the corneæ which has been progressive will doubtless continue still further.]

Purulent ophthalmia in children.—The foregoing observations, although directly referring to the purulent ophthalmia of newly-born children, are applicable to the treatment of the affection in those of one, two, or three years old, except that depletion must be more active. When the eye is bright red and painful, so as to prevent rest, two, three, or four leeches should be applied; one application is usually sufficient. Cold lotions are to be used; and purgatives of calomel, with rhubarb or jalap, or followed by castor oil. In older subjects, up to the time of puberty, leeches suffice, as a means of depletion; they may be employed more freely in proportion as the patient is older, and should be quickly repeated if the symptoms are not checked. Active treatment by leeches, purgatives, and blisters, cuts short the inflammation, and astringents finish the cure. In a few instances of acute local congestion in a full habit I have deemed cupping or venesection necessary before puberty.

Mr. Macgregor has given an interesting account of the rise, progress, symptoms, and treatment of the purulent ophthalmia, which prevailed extensively for some years among the children of the Royal Military Asylum at Chelsea, where many hundred cases came under his notice. "A considerable degree of itching was first felt in the evening; this was succeeded by a sticking together of the eyelids, principally complained of by the patient on waking in the morning. The eyelids appeared fuller externally than they naturally are; and on examining their internal surface, this was found inflamed. In twenty-four or thirty hours after the appearance of the above-mentioned symptoms, a viscid mucous discharge took place from the internal surface of each eyelid, and lodged at the inner canthus, till the quantity was sufficient to be pressed over the cheek by the motion of the eye. The inflammation then extended to the conjunctiva oculi, which became red and raised, so as to form an elevated border round the cornea. This was often accompanied by redness of the skin round the eye, sometimes extending to a considerable distance.

"The disease evidently began and terminated in the eyelids; and the surface of the eyeball seemed only to be affected from its proximity; for they were often in a diseased state for weeks, nay, even for months, after every symptom of the disease, in the membranes covering the eyeball, had completely disappeared.

Mr. Macgregor employed general bleeding, leeching, saline aperients, reduced diet, cold lotions, and blisters behind the ears, or to the nape. After reducing the inflammation by these means, astringents were used with great advantage, particularly the solution of lunar caustic, from gr. ss to gr. ij to the ounce. The ung. hydrarg. nitratis was found the most frequently successful of all the remedies that were employed. It was applied to the lids by means of a camel-hair pencil, at first mixed with twice its quantity of lard, but afterwards of the full strength. The red precipitate ointment was useful when the citrine ointment had failed. The golden ointment was also used with advantage; but it was injurious if employed while the conjunctiva was inflamed and irritable. "The vinous tincture of opium, which has been so highly recommended of late years, was

largely tried, but did by no means answer the expectations I had formed of it."

Mr. MACGREGOR observed, "that the disease is invariably more severe and protracted in persons having red hair and in such as are of a scrofulous habit, than in others. In proof of this I may mention that two-thirds of those who lost the sight of one eye, or both eyes, either had red hair, or had the glands of the neck enlarged, or had some other marks of scrofula existing in their habit."*

M. GUERSENT states that purulent ophthalmia constantly exists sporadically in the Hôpital des Enfans at Paris, and that it is sometimes epidemic. It is most destructive in the wards destined to the youngest children, which are extremely unwholesome, insomuch that there is a constant mortality of at least seventy-five per cent (*à peine si en parvient à sauver un sur quartre.*) In an epidemic which prevailed during February and March, 1835, all the children were attacked in the ward devoted to the youngest subjects, and some of those more advanced in age. Complete evacuation of the eye occurred in some cases, particularly in several children affected with other serious diseases. M. GUERSENT, who has witnessed several such epidemics, has found the antiphlogistic method, followed by astringents, the most serviceable. Cauterization of the mucous membrane of the palpebræ with nitrate of silver failed completely.†

[Purulent ophthalmia has prevailed, at times, in all the large institutions for children in Philadelphia. The children's asylum, under the care of the guardians of the poor, has never been wholly exempt from the disease since its establishment, and at periods it has been epidemic and destructive to vision. In the St. John's, St. Joseph's and Philadelphia Orphan Asylums it has also prevailed epidemically. In the latter institution it appeared in that form in the winter of 1839–40, and of 97 children in the asylum 95 were affected. During the first quarter of 1840, 108 cases, occurring in 77 children, came under our care.

The treatment consisted in the daily application to the eyes of a solution of nitrate of silver, of the strength of from two to eight grains to the ounce of water; laxatives; occasionally blisters to the nucha and behind the ears; and as the disease abated, in strumous children especially, the administration of Lugol's strong solution of iodine. Bleeding was resorted to in but five cases and in but one of them twice.

The result of this treatment was most gratifying. In no case was vision injured, although many of the children were strumous and several of them were predisposed to ophthalmia. In two cases only was the disease followed by granular lids, one a girl who was bound out before the disease had been entirely cured, and the other one of the elder girls employed as a servant, who was attacked only a few days before our term of service expired.]

* Transactions of a Society for the Improvement of Medical and Chirurgical Knowledge, vol. iii.

† Note sur une ophthalmie purulente épidémique, qui a régné à l'hôpital des enfans pendant les mois de Fevrier et Mars. *Bulletin generale de thérapeutique*, April, 1835.

CHAPTER VIII.

PURULENT OPHTHALMIA IN THE ADULT.

Synonymes: *Oph. purulenta*, or *puriformis; Egyptian oph.; suppurative ophthalmia; ophthalmo* and *blepharo-blennorrhœa; oph. contagiosa; epidemic-contagious oph.* Rosas. *Conjunctivitis puro-mucosa contagiosa vel Egyptiaca.* Mackenzie. *Oph. catarrhalis bellica; blepharotis glandularis contagiosa; adenitis palpebrarum contagiosa.*

Purulent ophthalmia in subjects beyond the age of infancy, is the same affection as that last described, only modified in its course, duration, and effects, by age; and requiring corresponding modifications in treatment. It is originally and essentialy an affection of the mucous membrane of the eyelids: that is, inflammation with puriform discharge. It may be confined throughout to its original seat; more generally it extends to the conjunctiva oculi, when, if neglected or improperly treated, and sometimes in spite of all the means that can be employed, it reaches the globe itself, producing in the cornea and iris injurious and destructive effects similar to those which take place in newly-born children.

When we consider its marked character and serious consequences, it seems strange that it should so long have escaped notice. Yet our knowledge of it is subsequent to that more extensive intercourse with Egypt which took place during the contest for its possession between France and this country. I know of no clear description of the complaint previous to this epoch. Scarpa does not mention it in his first edition bearing date 1801, and has only a single paragraph on it, an additional one, in his last (or 5th) edition of 1818. Mr. Ware does not allude to it, until long after the publications by the English army surgeons, subsequently to the evacuation of Egypt by our troops. Richter, who seems to have observed diseases of the eye with the greatest attention, for a long series of years, and who has described them with great fidelity, has not noticed this affection, which is not mentioned by Beer, nor by others of the Vienna school. Beer has entirely passed it over in his first edition of 1793: in the second edition of 1812–1816, he only alludes to it in a paragraph, in which he mentions that he had been long anxious to procure accurate information on the subject, and that his wishes had at last been gratified by a work of Assalini,* which had convinced him that the complaint was merely inflammation of the glands of the eyelids, (*blephar-ophthalmitis glandulosa*, that is, catarrhal inflammation of the lids,) rendered violent by the peculiar local circumstances, and passing quickly, in consequence of the unsuitable treatment of the natives, and of the French and English army surgeons, into blepharo-blennorrhœa and ophthalmo-blennorrhœa.†

The following circumstances will sufficiently prove the importance of the subject.

Assalini states, that two-thirds of the French army were affected with the complaint at one time.

Dr. Vetch informs us, in his interesting *Account of the ophthalmia,*

* Observations sur la Peste, l'Ophthalmie d'Egypte, &c., Paris; an 9.

† Lehre, vol. i., p. 321.

which has appeared in England since the return of the British army from Egypt, (p. 69,) that "the total strength of the second battalion of the 52d was somewhat above seven hundred men; six hundred and thirty-six cases of ophthalmia, including relapses, were admitted into the hospital, from August 1805, when the disease commenced, till the same month in 1806; of these fifty were dismissed with the loss of both eyes, and forty with that of one."

The ophthalmia depôt, under the care of this able physician, contained in the summer of 1808, upwards of nine hundred cases from more than forty different corps.*

Cases of purulent ophthalmia had occurred in the first battalion of the 52d, when it went to Sicily, in 1806. It continued to suffer there. A part of the army of Sicily, which had been detached to Egypt, brought back with it fresh infection. From this station more than one hundred and thirty men were sent home totally blind.†

"It appears from the returns of Chelsea and Kilmainham hospitals, that 2317 soldiers were, on the 1st of December, 1810, a burden upon the public from blindness in consequence of ophthalmia. Those soldiers, who have lost the sight of one eye, are not included in the number above stated."‡

In 1804, within nine months, from April to December inclusive, nearly four hundred cases of purulent ophthalmia occurred at the Royal Military Asylum; and from that time to the end of 1810, upwards of nine hundred additional cases had taken place in the same establishment, without including relapses.§

Some years ago this alarming complaint broke out in a large boys' school in Yorkshire. Blindness of one or both eyes, or serious injury to sight from corneal opacities or other causes, took place in nearly twenty instances. We cannot suppose that the proportion of unfavorable results would have been so considerable, if proper treatment had been adopted; for, in the Military Asylum, where the cases were so numerous, only six lost the sight of both eyes, and twelve the sight of one eye.‖

Fifteen hundred cases occurred in the garrison of Ancona in 1812; in ninety-seven of these one eye was lost, in forty-nine both.¶

Muller treated 1604 cases, including two hundred relapses, in the Prussian garrison of Mentz, in three years and a half; 1344 were restored to the service perfectly well; fifteen became blind with both eyes, ten by staphyloma, three by entire suppuration of the cornea, one by leucoma, one by dropsy of the globe. Eighteen remained with impaired vision of both eyes; six by leucoma, four by cicatrix of the cornea with synechia anterior; six by suppuration of the cornea and opacities; one by pannus. Twenty-six remained blind of one eye; fifteen by staphyloma; one by cicatrix of the cornea, with synechia anterior; nine by opacities; one by pterygium.**

It has been asserted that 30,000 cases occurred in the Prussian army, from 1813 to 1821, and that blindness followed in 1100.††

[In the Belgian Army the disease appeared in 1814, but was restricted to four garrisons until 1830, when it spread very generally, affecting in-

* Practical Treatise on Diseases of the Eye, 184. † Ibid., p. 183.

‡ P. Macgregor, in An account of an Ophthalmia which prevailed in the Royal Military Asylum; Trans. of a Society, &c., vol. iii., p. 50.

§ P. Macgregor, ibid., vol. iii. pp. 44 and 45. ‖ Ibid., p. 49.

¶ Omodei Cenni sull' Oftallmia Contagiosa d'Egitto.

** Erfahrungssäte, p. 159, and following.

†† Baltz, Preisschrift über die Entstehung, &c. der Augenentzündung, welche unter den Soldaten einiger Europäischen Armeen geherrscht hat. Utrecht, 1824, p. 57, 58.

deed, one-eighth of the whole army, and in some regiments half of the soldiers. In 1840 there were 5000 cases in the army which consisted of 50,000 men, and upwards of 100,000 cases had occurred since the first appearance of the disease.*]

Symptoms and progress.—In the first stage there is redness of the palpebral conjunctiva, with watering of the eye and some stiffness of the lids; a little whitish mucus is observed on the membrane. It is not generally seen by the surgeon in this stage, and often is hardly noticed by the patient. The disease soon extends to the globe, in what may be called its second stage; and now we see it marked by high vascular action and bright redness, great tumefaction of the membrane, and profuse discharge. The redness is uniform and bright; and there are often red patches apparently of ecchymosis. The swelling of the membrane on the globe raises it into the elevation called chemosis, which is often so considerable as to overlap and nearly cover the cornea; at this period of the complaint the palpebræ swell from serous effusion into their cellular texture [fig. 43]. In this way they often form two large convex, colorless, or slightly red protuberances, which meet and entirely close the eye, preventing, in conjunction with the chemosis, all satisfactory examination of the cornea. The extent to which swelling of the conjunctiva proceeds in these cases is evidenced by the preternatural adhesions found after inflammation has subsided. I have seen the conjunctiva of the upper part of the sclerotica adhering, in the form of a broad triangular band, somewhat like pterygium, to the inferior part of the cornea, after sloughing; and a similar broad adhesion between the orbital margin of the superior tarsus and the lower edge of the cornea.

Fig. 43.

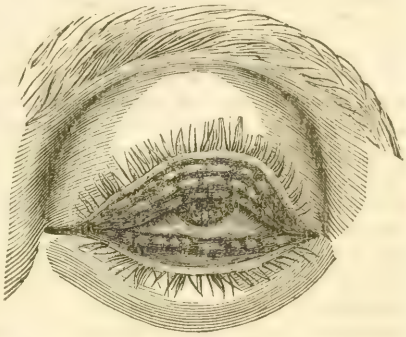

The nature of the swelling in chemosis is explained in the next chapter, on gonorrhœal ophthalmia.

The patient at first complains of stiffness in the eyelids and globe; and then experiences a sensation as if sand or gravel were in the organ. There is at first, lachrymation, then abundant purulent discharge, not only covering the edges of the lids, and the cilia, but pouring out over the face, and dropping on the clothes. The chambers of the aqueous humor may be distended by an increased exhalation of that fluid; but there is no formation of pus. Dr. Vetch† expressly mentions that he never saw the latter occurrence, nor effusion of lymph into the chambers, and Mueller‡ observes that hypopion never took place under his observation.

In the natural state of the disease, before blood-letting had been adopted, Dr. Vetch§ states that the quantity of matter discharged in the day must have amounted to several ounces.

As the inflammation extends to the globe, the pain is greatly increased; it becomes severe and excruciating: it is deep-seated in the eye, often with fullness and throbbing of the temples, and headache. There are remissions

[* Caffe, Journal de Connaiss. Med., July, 1840, p. 290.]
† Book before quoted, p. 64.
‡ Erfahrungssätze, p. 68.
§ Account of the Ophthalmia, &c., p. 54, note.

and exacerbations of suffering, which are sometimes periodical. The pain often returns, and particularly the sensation of a foreign body in the eye, after it has been removed for a time by treatment.

In the early stage the constitutional affection is slight; the pulse not affected, the tongue not much altered, nor the appetite impaired. When the inflammation extends to the globe, the circulation is excited, and general feverishness ensues.

Serious affections of the cornea take place analogous to those which occur in infants, but the swelling of the palpebra and conjunctiva conceals them, unless the eye be carefully examined.

In the third stage there is a gradual remission of the symptoms; the swelling, pain and discharge are lessened; the external œdema ceases, and the swelling of the conjunctiva being no longer counterbalanced, the palpebræ are everted, especially the lower.

Purulent ophthalmia in its milder form.—The foregoing account depicts the features of the disease in its most violent degree, as it prevailed in the British army, and has been so well described by Dr. Vetch. The severity of the inflammation, and the destructive effects on the eyeball, would naturally fix attention in these cases, and lead to the description of the affection as being essentially inflammation in its fullest development. In many instances, however, the disorder does not exhibit these strongly marked characters. It begins almost imperceptibly, and continues in a form so chronic, as hardly to excite attention. Its seat in these cases is the mucous lining of the eyelids. Mr. Macgregor observes, that "the disease evidently began and terminated in the eyelids, and the surface of the eyeball seemed to be only affected by its proximity; for they were often in a diseased state for weeks, nay, even for months after every symptom of the disease, in the membranes covering the eyeball, had completely disappeared."* He also observed "that the sebaceous glands of the tarsi were considerably enlarged, and of a redder color than usual."† Dr. Vetch repeatedly insists on the diseased condition of the palpebral linings, showing that it remains for an indefinite time after the inflammatory symptoms have been subdued; that it may lead, under occasional excitement, to the production of the disorder in all its violence; that no case can be considered cured until this state of the conjunctiva shall have been removed; and arguing that so long as it lasts the power of infection continues.

The milder form of the complaint seems to have constituted a far greater proportion of the cases in Germany, not only in civil life, where we have had but little opportunity of observing it in England, but also in the army. It has been carefully investigated by the German surgeons, who have thus been led to the discovery, that a certain change of structure in the palpebral conjunctiva is the primary and characteristic effect of this contagious ophthalmia; that the alteration in question, which has heretofore been regarded as an effect of active inflammation, is, on the contrary, the first manifestation of disease, and the cause of inflammation when the disorder spreads to the globe of the eye; and that, in many instances, the complaint arising from contagion, and possessing the power of infection, is confined to its original seat, appearing as a slow, chronic affection, giving the patient but little trouble, and often unnoticed by him or the surgeon.

Professor Walther, who observed the disorder in the prison of Brauweiler, and the neighboring country, represents that "the proper seat, the birthplace, the nest of the disease, is always, and in all its degrees, the conjunctiva of the eyelids. Here the disorder strikes its roots, and

* Lib. cit., p. 41. † Lib. cit., p. 38.

hence extends its destructive operation, partly into the substance of the eyelid, partly to the eyeball, the conjunctiva oculi being the medium by which the disorder is conveyed to the proper tunics of the globe."* He says that the complaint is characterized, in the first and slight degree, by its obstinacy, and by the gradual change of structure of the palpebral conjunctiva, especially in the lower lid, which after several weeks or months appears merely loosened in texture, reddish, velvety, and granular. With the aid of a glass, or even with the naked eye, we may discover small phlyctenæ, and an exanthematous structure which it is difficult to describe. This change is particularly observable at the reflexion of the conjunctiva from the eyelid to the globe, where we see in the membrane a crowd of yellowish red grains, something like the ova in the roe of a fish. Fissures and grooves are seen in the velvety lining of the lids, entirely destroying its natural smoothness. Thus the palpebral conjunctiva is gradually changed into a fleshy, sarcomatous, sometimes condylomatous mass, from the uneven surface of which an abundant muco-purulent discharge proceeds.†

Respecting the nature of the complaint, Professor WALTHER‡ expresses the opinion that, although it is an inflammation, the inflammatory symptoms are inconsiderable in its first degree. The peculiar change of structure in the palpebral conjunctiva, its morbid swelling, is the principal and constant phenomenon. Antiphlogistic treatment is by no means so serviceable as might be expected, if inflammation constituted the essential character of the disease. There is indeed high inflammation in the more severe cases, attended with chemosis: but this inflammation may be prevented by proper treatment; when present, it may be checked, and brought back within the limits of the first degree. The complaint still proceeds in its course, the change of structure goes on, although the inflammation may have been reduced. Moreover, where the inflammatory symptoms have been inconsiderable, we often see abundant granulations and vegetations of the conjunctiva. "Since further observations have confirmed the truth, that an eruption of small vesicles on the surface of the palpebral conjunctiva is always present in contagious ophthalmia, I should have no scruple in pronouncing the disorder to be of exanthematous character, and in considering it not so much an inflammation as an exanthema, or rather a chronic impetigo of the conjunctiva."

MUELLER, the Prussian army surgeon, considers the term ophthalmia inappropriate, because the complaint may exist without inflammation of the eye, which is merely one of its occasional effects. "Of many hundred patients," says he, "who at various times came under my daily observation, it often happened that the half were free from all affection of the globe, or impaired sight; in part, indeed, they could not be said to suffer from true inflammation of the eyelids; nevertheless, the disease existed in each under the eyelids, often for months, and in a state capable of infecting whole companies." He considers the characteristic circumstance to be a morbid state of the palpebral conjunctiva, in which part of the membrane he believes that an apparatus of mucous glands exists.§ He had an opportunity of examining the parts in a patient, who had long labored under purulent ophthalmia, with ulcer of the cornea, and prolapsus iridis, and in whom, under suitable treatment, the purulent discharge had ceased, and the affection of the eye was proceeding most favorably when death occurred from disease of the chest. Although the disorder had here become reduced to its slightest

* Die contagiöse Augenentzündung am Niederrhein, &c., in GRAEFE und WALTHER's Journal, vol. ii., p. 69.

† Ibid. ‡ Ibid., pp. 89—91. § Erfahrungssätze, p. 4.

degree, I found that portion of the membrane which I have designated as the seat of the mucous glands in both eyelids, altogether pale, but uniformly overspread with innumerable small papillæ; they did not exist in the rest of the membrane, which presented a perfectly normal structure. Under the membrane thus altered lay the Meibomian glands quite healthy." P. 21, 22.

Mueller describes three gradations of the complaint. The first is inconsiderable. It is found where the person, without any redness of the eye or lids, has experienced for a few days a sense of pressure, or an uneasiness, as if a particle of dust or sand had got into the eye. The conjunctiva lining the tarsi has a villous appearance, and darkish-red color; these changes extending for about a line beyond the orbital edges of the cartilages. The continuation of the membrane towards the globe has its natural smoothness, but its vessels are distended. There may be congestion in the conjunctiva oculi. There are increased flow of tears and mucous secretion; and irritated appearance of the eyeball; little or no pain. The disease may prevail extensively in this mild form; it may become more serious, or it may end, under proper treatment, within two or three weeks. P. 25—28.

The second degree is either an aggravation of the first, or exhibits its more serious character from the commencement. The conjunctiva of the eyelids now looks as if strewed with coarse sand; it has a more granular appearance, this character being more conspicuous when the general inflammatory tension has abated. The conjunctiva is more swollen, dark red, and covered by a puriform discharge. Particular vessels are not to be distinguished, but the membrane generally is passing into a deep red aggregation of granulations. The surrounding parts suffer more seriously; hence the general swelling of the lids. The pain is more considerable, but still resembles that caused by a foreign body in the eye. In this form the complaint is disposed to become inveterate; to go on for weeks or months; and to pass into the third more serious gradation, especially in particular conditions of the atmosphere. P. 29—31.

The third degree, which is the most alarming in its appearance and consequences, sometimes comes on at once in all its violence; but more commonly it supervenes suddenly on the second, after a longer or shorter time. It may be fatal to the organ in twenty-four or thirty-six hours. The peculiar disorder here affects the portion of membrane already indicated; but the disturbance is of the most violent kind, and its consequences are luxuriant morbid growths of granulations and warty elevations, the most profuse blennorrhœa, enormous swelling of the lids, ectropia, &c. P. 31—33.

Mueller then proceeds to give the following general description of the alteration which the conjunctiva undergoes in this disorder, observing that it is the constant circumstance of the complaint, showing itself most decidedly after the cessation or removal of active inflammation. "In the lowest degree the palpebral conjunctiva appears like velvet, or as if covered with dust: in the higher gradations, like thickly strewn millet seeds or rough sand, or the granulations of a healing wound, these vegetations sometimes equaling a large lentil, which is their utmost size. They exist in great number, arising from the membrane by a broad basis, being rounded on their prominent part at first, but subsequently becoming flattened by angular pressure against the globe. The largest are towards the middle; the smaller, which are more closely arranged, are towards the margins of the lids and the angles, especially the outer. Sometimes they lie so close together, that they seem to form one mass; but close examination will discover the fissures, sometimes tolerably deep, which separate them.

This structure is more developed under the upper than the lower eyelid, the wider surface of the former possessing a greater extent of mucous glands, and being less exposed to the air or the contact of remedies. The substance of these bodies is firm, and they run together at their bases, where the membrane generally is of the same morbid structure. The smaller prominences, examined with a magnifying glass, appear like an aggregation of hydatids, or the surface of a ripe mulberry. Their color varies according to the degree of inflammation or vascular turgescence. Hence we see all gradations, from the darkest blood red to the palest brick color.

"The prominence of these characteristic granulations is generally, but not constantly, in proportion to the degree or intensity of the inflammation, but by no means to its extent. I have often seen them comparatively small after the most acute inflammation, which had spread with great danger over the eyeball; and much more luxuriant under a slower and more confined inflammation. Whence we may conclude, that the peculiar inflammatory disturbance in the focus of the complaint, although less obvious to the observer, had acted more powerfully on the affected parts.

"Where this change of structure has become established, we need not expect to accomplish its sudden removal, although there are certain limits to its progress. We must not regard it as a mere effect of inflammation, like ordinary thickening, induration, or loosening of structure; but rather as the proper organ of the disease, which required an inflammatory impulse for its development and establishment, but may then become habitual, lasting for months or years, and constantly producing a contagion, capable, under certain conditions, of propagating itself by the infection of others.

"Although sight is generally impaired by the long continuance of this morbid change, there are other cases, or at least periods in these cases, when, after the removal of the symptomatic affections, the eyeball is perfectly free, and yet the disease continues under the eyelids in its full luxuriance. We can often, indeed, discover externally, from the swelling of the eyelids, the irritated appearance of the eye, the narrowing of the palpebral fissure, together with, in some instances, a slight gaping of the ciliary margins, that there must be something wrong under the lids; and we find, on everting them, the above-described changes in their linings. The state of the weather has a marked influence on the complaint, even in its chronic form. The disease, which seems nearly removed and quiet to day, may be much more considerable to-morrow, and *vice versa*. Yet the morbid structure shows but little sensibility to the touch or other external irritants. No ulceration follows excision or cauterization of the granulations. Abscesses or phlyctenæ do not take place, as in the conjunctiva oculi." P. 36—41.

"The disease begins at the inner edge of the ciliary margin, not including the puncta lachrymalia, occupies the lining of the tarsi, and ends one line beyond these cartilages. Everything beyond these limits is symptomatic affection, to which head we must refer the very frequent participations of the rest of the mucous membrane. The latter frequently displays increased redness, chronic swelling, thickened folds, &c., but never granulations."

Eble, an army surgeon in the Austrian service, and prosector at the Josephine Academy, had ample opportunities of observing the contagious ophthalmia in the military hospital of Vienna, where he had the charge of the ophthalmic patients. His account corresponds nearly to that of Mueller. He establishes two principal divisions of the disease, the

acute and chronic; describing the latter first, because it exhibits the peculiar character of the disorder, and because the acute is generally ingrafted on the previously existing, though not always recognized, chronic form of the disease. At the earliest period of the latter, when the individual has not complained, and is not aware that any disease exists, and when therefore it very rarely comes under the observation of the surgeon, he has found small serous cysts or phlyctenulæ on the surface of the conjunctiva; these are soon lost in the subsequent thickening and granulation of the membrane."*

Effects of the Inflammation.—1. *Sloughing of the Cornea, general or partial?* This, which is not an unfrequent result of acute gonorrhœal ophthalmia, has not occurred within my observation, in the contagious purulent disease; nor have I found it mentioned in the writings of those who have seen the disorder extensively prevalent among large bodies of men.

2. *Bursting of the cornea.*—In this disease, and in acute gonorrhœal ophthalmia, the eye is sometimes said to *burst.* A paroxysm of excruciating pain is suddenly terminated by a sensation of something giving way; a little hot fluid runs down the cheek, and great relief is experienced. When the subsidence of the palpebral swelling allows the eye to be examined, we always find, in such cases, that the anterior chamber has been penetrated, that there is extensive disorganization of the cornea by suppuration or ulceration, and that vision is lost. I have considered this occurrence to be the result of an ulcerative process, consequent on sloughing, or suppuration of the cornea. Dr. Vetch,† however, represents the matter in a different light. In one case he saw the cornea shortly before it burst, and it exhibited no perceptible alteration. He examined it again soon after, and found it presenting so natural an appearance, that he doubted the accuracy of the sensation. He at last discovered a small line, extending across the lower segment of the cornea, and remaining unaltered after the eye had been washed with tepid water. The next day a slight opacity appeared along the line, and increased daily till the greater part of the cornea was not only opaque, but projected in an irregular cone. He adds, "Other cases have occurred, which, by corresponding with the above, confirm the account I have now given; from which it appears that the aqueous humor escapes by a division of the cornea, nearly as clean as if cut by a knife; and that it is to the attempts of the part to effect a reunion under the presence of disease, that the future deformity is owing."—p. 64.

3. *Suppuration of the cornea,* and its subsequent destruction by ulceration.—In the progress of the latter, the lens may become exposed, so that

* Ueber den Bau und die Krankheiten der Bindehaut des Auges, mit besonderem Bezuge auf die contagiöse Augen Entzündung.—Vienna, 1828.

The serous vesicles of the conjunctiva are represented in Plate III., fig. 15. This, and the other figures of the same plate, which are colored and highly finished, represent faithfully and beautifully the various stages and forms of the structural change in the palpebral conjunctiva.

Eble has lately published an express tract on purulent ophthalmia: Die sogenannte contagiöse oder Aegyptische Augen-Entzündung; mit 9 colorirten Abbildungen. Stuttgart, 1839. The figures are designed to illustrate the changes which the conjunctiva undergoes in purulent ophthalmia, and are well executed.

Mueller has devoted two colored plates to the same subject in his Neuesten Resultate; the figures are expressive, though much inferior in execution to those of Eble.

Other representations may be seen in Graefe, Augen-Blennorrhöe, &c., Tab. 1, 3, and 4, and in two works of Vetch.

† Account of the Ophthalmia, &c., p. 60, and following.

the patient recovers for a short time tolerable sight, which, however, is soon lost again, as the progress of disease leads to the escape of the humors, and collapse of the globe.

4. *Ulceration of the cornea.*—This may occupy a considerable portion of the surface, or it may be smaller. Sometimes it forms a deep groove along the margin of the cornea, occupying one half of its circumference or more. The ulceration may extend in surface, or it may become deep, and penetrate the anterior chamber.

5. *Interstitial deposition*, either into the conjunctival covering, or throughout the corneal laminæ, occupying a portion only, or the whole cornea, and causing opacity, in every degree, from the thinnest film to the most dense leucoma.

6. *Opacity* from cicatrization of ulcers.

7. *Prolapsus iridis*, total (*staphyloma racemosum*) or partial.

8. *Adhesion of the iris to the cornea* (*synechia anterior*) in various extent, consequent on prolapsus, or occurring when the cornea is violently inflamed, and therefore seen in conjunction with the various effects of such inflammation.

9. *Loosening and thickening of the mucous membrane* covering the cornea, with enlargement of its vessels, and more or less diminution of its transparency. This change occurs in various degrees from slight vascularity to pannus.

10. *Staphyloma*, general or partial, dropsical enlargement of the globe, or collapse of its tunics, are more remote effects produced by some of the changes just enumerated.

11. A weak and irritable state of the eye, with want of power to bear even slight exertion. This, which disappears sooner or later, is a less serious affair than a degree of impaired vision (*amblyopia*), which has sometimes remained, even in cases of the milder description, without any change in the transparent media of the eye. The latter circumstance is explained by appearances observed after death in the examination of persons who had been affected with this disease. The dissections in question, which were made by Professor MAYER of Bonn, are detailed in the paper of WALTHER.* He found turgidity of the vessels in the orbit, and distended vessels surrounding the optic nerve; the choroid deprived of its pigment almost entirely, or partially, and red, or violet red, instead of its natural brown color; the retina, in one case firmer, and adhering to the choroid; the lens, in one case, and the vitreous humor in another, yellow, like gold; the vessels of the brain and its membranes turgid, with increased secretion into the ventricles, and serous effusion under the arachnoid. The changes in the choroid were seen in three out of five examinations; and in two of these the affection of the eye had been mild.

12. Although change of structure in the palpebral conjunctiva is the commencement of the complaint, and the cause of the more general inflammation, the latter aggravates the primary affection; so that the considerable thickening and induration of the membrane, with the roughening of its surface by large folds and masses of granulation, must be regarded as consequences of inflammation.

13. *Temporary and permanent ectropium and entropium.* Some redness of the membrane, with slight swelling and a little discharge, often continue for a long time.

There is great tendency to relapse, especially when the conjunctiva has not been restored to a healthy state; and inflammation may be renewed

* GRAEFE und WALTHER's Journal, vol. ii. pp. 100--108.

by slight exciting causes. I have known the complaint to return, in a strongly marked form, many years after its first appearance. Hence, when we consider the difficulty of restoring to its healthy state a part which has undergone a change of structure so serious as that which the palpebral conjunctiva experiences in this disorder, we shall not be surprised at hearing that patients may suffer from it for ten years or more, and that WALTHER doubts whether the conjunctiva ever completely regains its normal state of nutrition and secretion. (*Lib. cit.*, pp. 37 and 96.)

Diagnosis.—The characters of the complaint are so strongly marked, that it is not necessary to enlarge on this part of the subject. Catarrhal ophthalmia is the only affection liable to be confounded with it. The peculiar change of structure in the palpebral conjunctiva, the long continuance of the complaint, and the relapses, the great swelling, chemotic and palpebral, the violent vascular congestion and general bright red of the membrane, with the profuse purulent discharge, are sufficient distinctions.

In catarrhal ophthalmia, the affection begins in the conjunctiva oculi; or, at least appears at once over the whole membrane: in the purulent inflammation it commences in, and is often confined for a long time to, the palpebral conjunctiva. The affections of the cornea, which are very uncommon in catarrhal ophthalmia, afford an additional ground of discrimination.

The two diseases, however, if we look merely to an attack of the contagious disorder, without embracing the whole history, differ more in degree than in kind: the distinction between a mild catarrhal, and an acute purulent case is obvious enough; but we might not be able to distinguish between a mild purulent, and a severe catarrhal ophthalmia. There would be no difference in treatment.

Prognosis.—The affection is much more formidable, the danger to the eye is greater, than in infants or children. The complaint is less manageable, and therefore the issue is more uncertain. If the cornea retain its natural transparency, we may expect to arrest the inflammation by vigorous treatment; if it be dull, and deep-seated pain of the eye and head announce extension of inflammation to the globe, the event is doubtful. After partial suppuration, considerable ulceration, interstitial deposition, recovery of sight may take place, particularly in habits not very plethoric. Much will depend on the position of these changes in the cornea; if they should be towards the circumference, they may not interfere with vision.

Causes of Purulent Ophthalmia.—Opposite opinions have been entertained, and continue to be held, respecting the origin and nature of this affection.

Some consider it a specific disease, only communicable by contact of the puriform discharge; endemic in Egypt, and brought to Europe by the French and English troops: hence the name of *Egyptian ophthalmia.* Others regard it merely as a catarrhal inflammation of the eye, and consider that the severity of the disease in Egypt is attributable to the peculiar circumstances of that country, which are calculated to favor the production of catarrhal complaints, and to render them severe. Although it seems to involve merely a question of fact, we have not as yet the means of determining which is the correct view. If the disease be contagious, is it excited by direct application of the morbid secretion, as in gonorrhœa and syphilis? Can the morbific influence be conveyed by the atmosphere as in measles and scarlet fever, or in both ways, as in small-pox? In order to settle the point, we ought to institute experiments, which, for obvious reasons, we cannot do. We want to apply discharge from the diseased to healthy eyes, and to observe the effect of such application; but this proceeding cannot be adopted. With respect, therefore, to the question, whe-

ther the disease can be produced by the direct application of matter to the eye, we must content ourselves with a few facts presented by casual observation, and with indirect arguments.

Mr. MACGREGOR, in the account which he has given of this affection, as it occurred in the Royal Military Asylum, mentions three instances, in which the origin of the complaint from direct infection was unequivocal. The cases are interesting not only in this respect, but as they show how quickly the application of the cause is followed by the development of the morbid phenomena. About four o'clock, P. M., a nurse, in syringing the eyes of a boy, in whom there was much purulent discharge, found some of the matter spirt into her right eye. She felt little or no smarting at the time; but towards nine o'clock in the evening the eye became red, and somewhat painful. When she awoke the next morning the eyelids were swelled, there was purulent discharge, and she complained of pain in the eyeball. The usual remedies were employed, and she got well in three weeks or a month. The left eye did not suffer.

Matter was applied in the same manner to the left eye of another nurse at nine, A. M. By direction of Mr. MACGREGOR, who was immediately informed of the occurrence, the eye was bathed for several minutes with lukewarm water. About seven in the evening, the eye began to itch violently. When she awoke next morning, the eye was considerably inflamed; the lids were swelled, and she had a sensation as if sand were lodged under the eyelid. In the course of this day, purulent fluid issued from the eye. The disorder subsided in fourteen days, the right eye having remained sound.

Another nurse, who had been sponging with warm water the eyes of a boy suffering severely from purulent ophthalmia, inadvertently applied the sponge to her right eye about eight in the morning, and took no means to prevent infection. Between three and four P. M., great itching of the eye took place, and before she went to bed it was considerably inflamed. Next morning all the symptoms of purulent ophthalmia were completely developed; they increased in severity in spite of all the means employed to check them, and the eyeball burst on the fourth day; the inflammation continued for three months: the left eye did not suffer.*

Dr. GUILLIE, of Paris, has shown that the disease may be communicated by the direct application of the puriform secretion to a sound eye. He introduced under the eyelids of four blind children, the discharge from the eyes of children laboring under purulent ophthalmia; and the disease was produced in each instance.†

[Dr. de KIRCKHOFF inoculated different individuals with matter flowing from the eyes of patients afflicted with ophthalmia, and although in so doing, he states that he scarcely touched the edges of the eyelids, and in such a manner, that it could not act as a foreign body, ophthalmia followed in one, two or three days.‡

M. HUPSCH, who disbelieved in the contagiousness of the disease, submitted to be inoculated, and in 24 hours he was attacked with an inflammation so violent as to endanger his sight.§

M. CUNIER mixed some pus with 240 parts of water, and applied some of it to the eye of a dog, which produced an inflammation which destroyed the right eye.‖]

* Page 51—54. † Bibliothèque ophthalmologique, vol. i., p. 81.

[‡ Memoir upon the ophthalmia which prevailed in the army of the Netherlands. New York Med. and Phys. Journal, 1825, vol. iv., p. 292.]

[§ Ibid.] [‖ Observateur Med. Belge, Ap. 1834.]

Mr. MACKENZIE believes that the ordinary catarrhal ophthalmia is contagious. "I regard it," he says, "as scarcely admitting of doubt, that the discharge in catarrhal ophthalmia, especially when distinctly puriform, if conveyed from the eyes of the patient to those of others, by the fingers, or by the use of towels and the like in common, will excite a conjunctivitis still more severe, more distinctly puriform, and more dangerous in its effects on the transparent parts of the eye, than was the original ophthalmia. This is the conclusion at which I have arrived, from the observation of many instances, in which, as far as it was possible to come to the facts, this disease having arisen in one member of a family from atmospheric exposure, several others of the family have become affected without any such exposure that could be ascertained; and while, in the first affected, the disease was comparatively moderate, and scarcely puriform, in the latter the symptoms were more violent, and the discharge thick, abundant, and opaque."* He also considers it extremely probable that the discharge from the conjunctiva in catarrho-rheumatic ophthalmia would excite disease in the same way if applied to a sound eye.† Dr. VETCH entertains the same opinion as Mr. MACKENZIE respecting the contagiousness of the ophthalmiæ which are attended with puriform discharge. "From whatever cause," says he, "inflammation of the conjunctiva may originate, when the action is of that nature or degree of violence, as to produce a puriform or purulent discharge (ophthalmo-blennorrhœa), the discharge so produced operates as an animal virus when applied to the conjunctiva of a healthy eye."‡

Various attempts have been made to illustrate the question of contagion by experiments on animals. Dr. VETCH§ applied the puriform secretion of the conjunctiva to the eye of a dog, in which it soon produced considerable irritation; but the animal was lost, so that the result of the experiment could not be ascertained. VASANI‖ communicated the disease to dogs by applying to the mucous lining of the eyelids recent matter from the eyes of patients laboring under the disease, or matter which had been dried on linen. One dog contracted the disorder by being dipped in a vessel of water, in which the eyes of two other dogs laboring under the complaint had been frequently washed. In these experiments the inflammation appeared four days after the application of matter. GRAEFE¶ produced the disease in dogs and cats repeatedly by the application of matter to their eyes. On the other hand, no infection took place in numerous experiments very carefully performed by MUELLER.** He inoculated five cats, ten dogs, two rabbits, two squirrels, two blackbirds, a starling, a yellowhammer, and a cock. He took matter from the eye early in the morning before the patients had washed their eyes, collected it with a camel-hair pencil, and introduced it under the upper and lower lid in each eye, leaving the pencil quietly for a few seconds, and then pressing it so as to squeeze out the matter effectually. He also smeared the matter copiously and repeatedly

* Practical Treatise, p. 333. † Ibid., p. 415.

‡ Ibid., p. 175. § Account of Ophthalmia, &c., p. 13.

‖ Storia dell' ottalmia contagiosa dello spedale militare d'Ancona. Verona, 1816, p. 40, and following. According to OMODEI, Cenni sull' ottalmia contagiosa, p. 101, RIMA had already performed similar experiments.

¶ Die epid. contag. Augenblennorrhöe, p. 35. He mentions that a similar experiment was performed on a dog and a cat by another surgeon; that inflammation with serous discharge followed in both animals on the third day; on the fourth and fifth there was swelling of the palpebral conjunctiva, with copious mucous discharge, which lasted till the fourteenth. Ibid., p. 36.

** Erfahrungssätze über die contagiöse oder Aegyptische Augenentzündung; Mainz, 1821, p. 102.

along the edges of the lids. Not the slightest effect was produced in any one instance.

The idea of contagion is strongly supported, though not absolutely proved, by a general view of the origin and progress of the complaint, as it appeared in Europe. We know that it had not been noticed prior to the occurrence of the contest in Egypt; that the French and English armies suffered from it severely in that country; that in Sicily, Malta, and Gibraltar, places at which detachments of the army sojourned on their return from Egypt, numerous cases occurred: and that in various portions of the army, in this country, the disease has prevailed extensively; the complaint having broken out first among those troops who had formerly been in Egypt, or in such corps as had had direct communication with regiments returned from Egypt. The progress of this complaint has been traced, in all such cases, by the intercourse of fresh troops with the infected. The conclusion of its contagious nature suggests itself very forcibly to the mind, on reading the narrative of the gradual development and progress of the complaint in particular instances. The account given by Mr. EDMONSTONE* of the disorder as it appeared in the Argyleshire Fencibles, published in 1802; the excellent description of Dr. VETCH,† in a pamphlet published in 1807, and the interesting narrative of Mr. MACGREGOR, already quoted, may be consulted on this point.

The manner in which the disease spreads, leads us, *prima facie*, to the conclusion that it is contagious. It extends very rapidly, when persons are crowded together in great numbers, as among common soldiers in barracks, where many are obliged to use the same utensils and the same linen; whilst the officers, who have better ventilated, and more capacious apartments, and live separately, generally escape. In the town of Mentz, which was garrisoned by Prussians and Austrians, the complaint broke out and spread extensively among the Prussian soldiers, whilst the Austrians, who inhabited another part of the town, and were in separate barracks from the Prussians, entirely escaped.‡ We see instances in which the affection has attacked several individuals of the same family—the father, mother, and several children—appearing to have spread from one to the other. Again, when the disease has prevailed among bodies of men, it has been successfully extirpated by separating the affected from the healthy, and confining each individual to his own clothes, sponges, and utensils. These general views of the subject seem to have been strongly impressed on the minds of those who have seen the complaint extensively prevalent, and have led them to believe that it is contagious: the opinions of Mr. MACGREGOR, Mr. EDMONSTONE, Dr. VETCH, and other army surgeons in this country, may be quoted. The same opinion has been held and defended on the continent by RUST.§

* Account of an ophthalmia which appeared in the 2d regiment of Argyleshire Fencibles, &c.; also in a Treatise on the varieties and consequences of ophthalmia, p. 13, and following.

† Account of the ophthalmia which has appeared in England since the return of the British army from Egypt. Also Practical treatise on diseases of the eye, part ii. chap. iii.

‡ RUST, in the work next quoted, p. 14. MUELLER, Neusten Resultate, &c., p. 21.

§ Die Aegyptische Augenentzündung unter der königl, Preuss. Besatzung in Mainz. Berlin, 1820.

Within a few months every third man in the garrison had been affected; and RUST found the disease then spreading rapidly, p. 21. From June, 1818, to April, 1819, the whole number of cases, including 250 relapses, was 1798, without including a regimental surgeon, two hospital surgeons, and twelve nurses, who took the disease.—p. 44.

WALTHER,* MUELLER,† GRAEFE,‡ and OMODEI,§ who have seen purulent ophthalmia on a large scale. WALTHER is so strongly convinced, that he calls it ophthalmia contagiosa, and compares it, in this respect, to the exanthemata. He considers the little granular bodies which appear on the conjunctiva to be analogous to the eruptions on the skin in the exanthemata. I do not doubt this view, but mention it merely to show how strongly the minds of accurate observers have been impressed with the contagious nature of the complaint.

Although the evidence afforded by Mr. MACGREGOR proves satisfactorily the contagious nature of the disease, it does not show so clearly the mode in which the communication is effected. He says, indeed, that "the disorder appears to be communicated by the purulent matter of a diseased eye being applied to that of a sound person;" and he mentions no other mode of infection. Yet we cannot help concluding from the facts he has furnished, that this is not the only way in which the disease may be produced. If he had traced the actual application of matter in many out of the hundreds of cases which came under his observation, he would hardly have related in detail the three instances already quoted. It will be observed, too, that in each of these one eye only suffered, that to which the morbific matter was applied. Not only were the children of the institution affected, but various other persons who had communication with them; these must have been aware of the circumstance, if matter had been applied to their eyes, and would no doubt have mentioned it, when the contagious nature of the complaint was so well known. In May, 1804, several bad cases of ophthalmia were admitted into the infirmary. On the morning of the fourth day after their admission, two boys in the same ward laboring under other complaints were attacked with inflammation of the eyes, and in the course of that week the nurse took the disease. Her son, who had been in attendance on the sick, and in a few days after her two younger children, were

* Die contagiöse Augenentzündung der Niederrhein, besonders in der Arbeitsanstalt Brauweiler, in ihrem Zusammenhange mit der Aegyptischen Ophthalmie Betrachtet; GRAEFE und WALTHER's Journal, vol. ii.

This is a very interesting account of the disease as it prevailed for some years in a prison, where the inmates were kept to hard labor, at Brauweiler, and in the neighboring country of the lower Rhine. Professor WALTHER describes minutely the phenomena of the complaint, and the points of distinction between it and the other affections of the eye, particularly the catarrhal and gonorrhœal ophthalmia, and the inflammatory chemosis. After the disorder had existed in the prison for some years, appearing like an epidemic, declining and re-appearing, affecting the keepers and attendants as well as the prisoners, it had become nearly general in 1819, so that when a careful examination was made in 1820, scarcely a single prisoner was found in whom the eyes were not either diseased or in a suspicious state.—p. 43.

The disorder, as it appeared in this prison and the neighborhood, had a less acute character than it has shown in the English army.

† Erfahrungssätze über die contagiöse oder Aegyptische Augenentzündung. Mainz, 1821.

Die neusten Resultate über das Vorkommen, die Form und Behandlung einer ansteckenden Augenliederkrankheit unter den Bewohnern des Niederrheins. Leipzig, 1832.

Of these pamphlets, the first gives an excellent account of the subject, drawn chiefly from observation of the disease in the Prussian garrison of Mentz; the latter is principally occupied in showing its extension, and delineating its forms and treatment in some districts of the Prussian provinces on the Rhine. The former, and the paper of WALTHER already quoted, contain perhaps the best accounts that we possess of the nature and treatment of this formidable disease.

‡ Die epidemisch-contagiöse Augenblennorrhöe Aegyptens in den Europäischen Befreiungsheeren; ihre Entstehung, Erkenntniss, Vorbeugung und Heilart, während der Feldzüge 1813, 1814 und 1815, beobachtet. Folio. Berlin, 1823.

§ Cenni sull' ottalmia contagiosa d'Egitto. Milano, 1815.

attacked, as were several of the sick in the same ward. In the course of June, in which ninety fresh cases occurred, the nurse of the girls' hospital caught it, and her husband, an in-pensioner of Chelsea Hospital, who came daily to see her, was also seized with it, as likewise were two occasional nurses. No other person was at the same time affected with ophthalmia in Chelsea Hospital. The wife of a field officer was at this time on a visit at the Military Asylum. She had a son between five and six years of age, who used to play with the other boys. He caught the ophthalmia, and on the fourth or fifth day after it appeared, his sister, two years old, was seized, and some days after this the lady herself took it. Great attention was now paid to the immediate separation of the diseased from the healthy, and all other means of checking contagion were adopted: yet the disease continued to spread, for ninety-five cases occurred in July, and ninety in August. A boy and a girl, brought from Scotland, arrived at the Asylum one evening in the end of this month. They were inadvertently put into a ward occupied by ophthalmic patients, but immediately removed when the circumstance was observed by Mr. Macgregor next forenoon; on the third morning after their arrival both the children had the complaint. "All the boys from five to six and a half years of age are formed into one company. It was observed that in the course of the last and present month, almost the whole of this company took the ophthalmia. Its progress could in their dormitories be traced from one bed to another, in the order in which they were placed, until nearly the whole were affected. The two nurses attached to this company always slept in their wards, and were the only nurses belonging to the institution (those connected with the Infirmary excepted) that suffered from the disease. About the middle of this month I caught it myself; and though the inflammatory symptoms subsided in ten days, I did not recover from its effects for five or six weeks."

The disease was less prevalent in the Asylum in 1805 and the three following years; but the number of cases was considerable in the summers of 1808 and 9, and the spring of 1810. As it was spreading rapidly in April and May of the latter year, all the affected children were removed into a detached building, so as to cut off the communication entirely between the healthy and the diseased. From that time the disorder gradually declined.

In proof that the disease did not depend on a peculiar state of the atmosphere, or any other general cause, Mr. Macgregor observes that the disease had prevailed for nearly a month among the boys before the girls were attacked; and all the adults, who did not mix with the sick, escaped it, while those who were connected with them all suffered, the assistant surgeon excepted.

Dr. Vetch* is decidedly of opinion that the disease in not communicable by contagion operating through the medium of the atmosphere; he thinks direct application of matter necessary to its propagation.

Mueller, on the contrary, who seems to have employed most diligently his extensive opportunities of observation, thinks that the contagion is generally conveyed by the atmosphere. He concludes from this circumstance that it could also be propagated by contact; but his experience had furnished him with no direct proofs.† He never saw an instance in which the occurrence of the disease could be traced to the contact of matter, by smearing, injection, or evaporation, unless the infected person had been exposed for a considerable time, and repeatedly, particularly in the night,

* Account of the Ophthalmia, &c., p. 10, and following. Practical Treatise, p. 179.
† Erfahrungssätze, p. 77.

to an atmosphere rendered impure by an assemblage of patients. Relations were allowed to visit the sick, such visits taking place in a separate apartment, and being limited to half an hour; disease was never communicated on such occasions, in spite of the close contact in embracing and caressing, which would necessarily occur in the meetings of parents and children, brothers and sisters, husbands and wives. He knew no instance of infection by means of clothes, bedding, or the washing or cleansing of linen or other articles.*

In proof of his opinion that the contagion does not act through the medium of the atmosphere, Dr. Vetch alleges that the medical attendants on the sick were never infected. Walther,† on the contrary, states that the nurses and attendants of every description, and the physician, contracted the disease at Brauweiler. Mueller‡ also informs us, that at Mentz many nurses and medical attendants suffered, as well as the president of the hospital commission, and an inspector, who, in the assiduous exercise of their duties, passed much time in the wards.

[M. Vansevendonck exposed himself to what was called the sphere of contagion; applied his forehead to that of the soldiers afflicted, but did not contract the disease, (*Specimen Politico Medicum*, p. 51.) He subsequently applied the matter taken from one of their eyes to his own, and the disease was promptly excited in them.

Mr. Delamarre, one of the most distinguished surgeons of the army of the Low Countries, was hospital surgeon at Ath in 1817-1818, and had constantly under treatment from 20 to 35 cases of ophthalmia, in a small hospital which could scarcely contain 45 men; and during the course of two years, he says, "there was not a single individual attacked in the building." If we consider that the establishment was formed in a private house, it appears incontestable, he adds, "that if the disease was contagious, it would have spread among the individuals, whom the smallness of the building did not permit being separated, and where I often found it necessary to lodge those afflicted with ophthalmia, the less violent, with those laboring under other diseases." (Vleminckx & Van Mons, *Essai sur l'Ophthalmie de l'armée des Pays-Bas*, p. 41.)

Dr. Kirckhoff says, that he has often made those affected with ophthalmia sleep with the wounded, and with those suffering under venereal and other diseases, but never saw it communicated. (O. c. p. 292.)]

Several arguments have been adduced against the contagious nature of the affection, such as, in the opinion of some, to leave the point still in a state of doubt. In the first place, the country in which this contagion is supposed to have originated, and where it still remains endemic, is one which has attracted the attention of philosophic observers in all ages. If it be not the birth-place, it must be deemed the cradle of the arts and sciences: we trace them back to Egypt, as the earliest place of their distinctly recognized existence. We find that at a very remote period the Egyptians had made great advancement in sculpture, architecture, and painting; we find that the same prodigious remains which still astonish us, existed, nearly in their present state, more than two thousand years ago. Egypt was resorted to by the philosophers of Greece; and Herodotus, who traveled in the country for scientific purposes, and who has presented us with an accurate description of it, notices, even in his time, the great prevalence of diseases of the eye. Volney§ mentions, that in the streets

* Erfahrungssätze, p. 80, 81.

† Graefe und Walther's Journal, vol. ii., p. 113.

‡ Erfahrungssätze, p. 82.

§ Voyage en Syrie et en Egypte, vol. i.

of Cairo, where the disorder prevails throughout the year, but is more prevalent at the vernal equinox, you may find, out of one hundred persons whom you meet accidentally, twenty blind, ten with only one eye, and twenty more whose eyes are red, purulent, or covered with films. SAVARY* says, that in the grand mosque of Cairo there were eight thousand blind persons. HALLER, in his *Bibliotheca Chirurgica*, calls Egypt "Cæcorum in omni tempore fæcunda nutrix." None of the ancient travelers had any idea that the disease was contagious; and the Egyptians themselves, at the present day, have never entertained such a notion. None of the English or French army surgeons or physicians, who saw and treated the disease in this reputed source of infection, supposed the complaint to be contagious.

This notion of a specific contagion, imported from Egypt, originated in Europe, never having occurred in the supposed birth-place of the virus. ASSALINI, who accompanied the French army into Egypt, as surgeon to the viceroy of Italy, expressly denies the existence of contagion. He, and the other medical observers who actually witnessed the affection in Egypt, refer it to the ordinary causes of ophthalmic disease. They observe, that the atmospheric influences capable of producing catarrhal affections, are very powerful here. The intolerable heat of the day is followed by night chills and heavy dews; the land is periodically inundated and covered with water, which remains to be evaporated by the heat of the sun. Such causes act on the eyes, already predisposed to disease by a combination of injurious influences: such as the great heat of the country; the powerful light: the great glare from the sandy surface; the atmosphere of dust caused by the light sand composing the soil, being raised into the air by the least breath of wind. Hence ASSALINI, and other direct observers in Egypt, regard the disease as acute catarrhal inflammation, principally affecting those much exposed to the exciting causes, as soldiers and the lower orders, while officers and the wealthier escaped.

In corroboration of the non-contagious nature of the affection, I may observe, that in all cases where collections of individuals, laboring under it, have been separated and dispersed, as when troops are disbanded and go into civil life, the complaint does not extend. If it were contagious and capable of producing a like disease in others, we should suppose that this would be the very way to spread it all over the country; but we find it the most effectual mode of putting a stop to the disorder. There is no dissemination of the complaint in the families, or districts, to which the soldiers or other persons so afflicted return.

WALTHER† observed, that the complaint seemed to lose its contagious property when single patients lived in their families, under the ordinary domestic relations, even in confined dwellings, whatever the stage of the complaint might be, and however long it lasted. He only saw one exception to this observation.‡ Patients laboring under the contagious ophthalmia were received into the clinical hospital of Bonn, and at first carefully separated from the others: but the separation was not continued, and no infection ensued, either of the other patients or attendants. It must be observed, that all the arrangements of this institution are particularly calculated to secure the health of the inmates.

In investigating the contagious or non-contagious nature of this complaint by direct experience, there is a great difficulty, and one not likely to

* Lettres sur l'Egypte, vol. iii. † Lib. cit., p. 119, 120.

‡ [MM. Fallot and Varlez, in their "Recherches sur les causes de l'Ophthalmie," &c., Bruxelles, 1829, have collected many exceptions to this observation.]

be soon removed. However, we know that individuals have not been wanting who, from their desire of determining certain points of pathology, have inoculated themselves with matter supposed to be most infectious and dangerous. This has been done with the matter of buboes in the plague; and therefore we need not be surprised if somebody has been found to try the application of the puriform discharge to his own eyes. One such experiment is recorded in the 12th volume of the *Edinburgh Medical and Surgical Journal.* Mr. Mackesy, who had been with his regiment in Egypt, where it had suffered much from purulent ophthalmia, determined, whilst staying on its return at Messina, in Sicily, to make a decided experiment. He soaked a rag in the purulent secretion of the eyes of three patients, and then applied it for more than an hour to his own eyes, and pressed it repeatedly against the lids, to introduce the matter between them, which produced a slight smarting pain. He then went out and walked a mile, a sirocco wind prevailing and blowing dust in all directions. He put the rag again on the eyes at night, and wore it through the night; he moistened it in the morning, and applied it again, when moist, to the conjunctiva; no inflammation ensued.

Eble* mentions some other instances, in which the puriform discharge has been applied to healthy eyes without producing any effect.

Perhaps the apparently contradictory opinions which have been entertained on the subject may be in some measure reconciled. I cannot agree with Dr. Vetch, in supposing that the smallest particle of the purulent secretion may give the disease, and that the contagious property remains as long as any purulent fluid is secreted, that is, often for many months or years. At least there is, as yet, no sufficient evidence to establish those points. If contagion exists, it must be very different from that of small-pox, scarlet-fever, or measles; much less active and certain. At the same time, when I look to the instances in which the affection has prevailed extensively; when I see how the disease has gradually spread through large bodies of men, and how effectually its progress has been arrested in so many cases by insulating the disease, and preventing all intercourse between them and the healthy, I feel fully satisfied that the disease is contagious, under certain circumstances and conditions, although I cannot assimilate it to the well-known contagions. We see small-pox, measles, and scarlet-fever extend themselves in a fixed, regular, and determined matter, to which there is no analogy in purulent ophthalmia.

If the accounts of patients themselves can be at all relied on, respecting a fact which they can have no interest in concealing or misrepresenting, there is abundant evidence that the disease arises from other causes than from the application of matter from the eyes of one individual to those of another. I frequently saw, at the London Ophthalmic Infirmary, patients laboring under purulent ophthalmia, in whom no communication could be traced with others similarly affected. I should therefore say that this disease may be produced by common causes, without the application of morbific matter to the eye. But, when once excited, it appears capable of propagating itself, under particular circumstances, in a way which we cannot distinguish from a contagious propagation. When individuals are crowded together in great numbers in confined habitations, sleeping in the same rooms, using the same linen and the same utensils, and not carefully attending to personal cleanliness, deleterious influences on human health are produced from the bad air, noxious effluvia, and close personal intercourse inseparable from such states. The injurious operation of such

* Die sogenannte contagiöse Augenentzündung, p. 164.

causes is notorious, though their nature and mode of action are obscure. It is augmented by the addition of unwholesome diet, insufficient clothing, and bad ventilation. Hence the only instances of extensive spreading and great virulency of purulent ophthalmia have occurred in barracks, transports, and other ships, in schools, prisons, and work-houses.

In the doubt which still exists respecting its contagious nature, there is an analogy between this affection and typhus; the contagion in both, if we admit its existence, only shows itself under peculiar local circumstances, such as an atmosphere vitiated by human effluvia, crowded and confined dwellings, and want of domestic comforts. When we see that the question of contagion is not yet settled in typhus, we need not be ashamed nor surprised at the uncertainty on the same point in purulent ophthalmia. That all who are exposed do not become affected with purulent ophthalmia, is a circumstance common to it with other contagions, none of which act uniformly and invariably on all who come within their range. The presence of the contagion is one only out of several conditions necessary to the production of the morbid phenomena: the state of health and of the particular organ in the exposed individual, and the surrounding influences, atmospherical and others, are equally important, but as yet imperfectly understood. Mr. Macgregor observes that purulent ophthalmia was influenced by the state of the atmosphere, being much more severe in its attacks, and of longer duration, in hot and sultry, than in cold weather.* Thus, in the first year of its appearance at the Military Asylum, it ceased in the winter, although measures of separation had not been adopted.† In the four following years some cases occurred in the spring, summer, and autumn, but none in the winter. In the winter and spring of 1808, the asylum was free from the disease, which broke out again in June, when the weather was extremely hot. In January, February, and March, 1809, those previously affected recovered; but the disorder reappeared in the spring, and became very violent in the summer.‡

Dr. Vetch§ found that the state of the weather and local peculiarities were capable of seriously aggravating the symptoms: a humid atmosphere and marshy soil were particularly unfavorable. "The disease first assumed its violent and characteristic symptoms in barracks, either in or on the borders of Romney Marsh. Its next appearance under this form was at Feversham and Hilsea, both of them low situations and surrounded by ditches, and till very lately proverbial for the production of ague. Some of the worst cases were also received into the depot from low situations in Essex. The disease presented itself in the first regiment of foot, stationed in the Castle of Edinburgh, but no instance of particular severity occurred, although a considerable number were admitted into the hospital. The high and salubrious situation of that place is sufficiently known. The disease, however, still existing in the regiment, it afterwards broke out at Maldon in Essex, and since its first appearance, in 1805, it has nowhere produced such cruel ravages, or sent so many objects of its violence to the hospitals." "At the barracks at Aldwick, which formed one of the stations of the ophthalmic hospitals, and the situation of which is particularly damp, ten cases of relapse occurred for one at Selsea. In many instances, when the disease has evinced little disposition to assume its characteristic violence, and when its nature has been consequently doubted, on the setting in of wet weather the suppurative form of inflammation has come on with the utmost severity."

That certain conditions of the atmosphere, and other external causes, are

* Lib. cit., p. 37. † P. 35. ‡ P. 46, 47.
§ Practical Treatise, p. 189, and following.

necessary to the propagation or increase of purulent ophthalmia, may be inferred from what I have already mentioned; and that a disorder of the eyes may arise and spread, as if by contagion, without any reference to Egyptian origin, or any application of purulent matter, has been evidenced in various instances. Dr. EDMONSTONE* quotes a narrative of the casual development of ophthalmia, in an English ship of war in the West Indies. This ship, the Albemarle, being off the coast of St. Domingo, met a slave-ship, from which three sailors were taken on board. These had inflamed eyes, and when interrogated respecting the disorder, they said they were getting well from a most painful complaint, which had affected nearly all the persons on board the slave-ship. On the fourth day after their reception two sailors of the Albemarle were affected with inflammation of the eyes; the next day, several more were seized; and by the seventh morning twenty-two had become unfit for duty from this cause. The captain now adopted the expedient of separating the diseased from the healthy, and thus stopped the progress of the disorder.

A more remarkable example has happened of late years, on board a French ship, which left Africa with its crew and cargo quite healthy, and free from all affections of the eyes. During the voyage to the West Indies, and fifteen days after leaving the coast of Africa, a severe inflammation of the eyes broke out amongst them, accompanied by puriform discharge. It made its appearance first among the slaves, and then extended to the crew; and by the time the ship arrived in the West Indies, there was barely a sufficient number of individuals retaining their sight to work the ship into the harbor. Of the crew, who were in number twenty-two, twelve lost their sight; five lost one eye; and four had opacities of the cornea. Of one hundred and sixty negroes, thirty-nine lost their sight completely, twelve lost one eye each, and fourteen had more or less considerable opacities.† Here was a case in which no previous contact with infected persons could be traced; yet an apparently genuine purulent ophthalmia made its appearance, and spread with the greatest rapidity. We may fairly conclude that the vitiated atmosphere which these persons breathed, the depression of spirits, the bad food, and the want of attention to cleanliness, are sufficient to account for it.

In the limited sense to which I have now adverted, purulent ophthalmia may be considered contagious; but I do not believe that it is an active, virulent, or certain poison; and still less that it is a specific contagion of Egyptian, African, or Asiatic origin. The term *Egyptian* is improperly applied to it, inasmuch as the disease has appeared in various countries without any suspicion of contagion derived from Egypt. I cannot help thinking that it has existed in this country long before our intercourse with Egypt. Its not having been described does not prove its non-existence; the distinction between small-pox and measles, and between the latter and scarlet fever, is not of old date.

In practice, it is the safest course to proceed upon the notion of the complaint being contagious; and, acting upon that notion, to prohibit the use of the same sponges, utensils, or linen, or any other thing capable of communicating the disease from one to the other, just as if the contagious nature were decidedly proved.

Treatment of purulent ophthalmia.—The violent inflammation which frequently accompanies the disease, and the consequent serious danger of the organ, have naturally influenced the indications of treatment, which have been founded too much on this partial view of the subject. Antiphlo-

* Treatise, &c., p. 9.

† GUILLE, Bibliothèque Ophthalmologique, vol. i.

gistic measures, although capable of removing the inflammatory symptoms, which are present in some instances, cannot remedy the affection of the palpebral conjunctiva, which is the source of those symptoms. The latter object must be accomplished by other means. I shall consider separately the violent and the milder forms of the complaint, as different therapeutic principles are applicable in the two instances.

Treatment of acute purulent ophthalmia.—Our object is to arrest the violent inflammation of the conjunctiva, and to prevent its extension from that membrane to the cornea. Blood should be taken from the arm, and in large quantity, so as either to influence the circulation decidedly, or to produce syncope. More benefit will be derived from one venesection of this kind than from the repetition of smaller ones. Bleeding in the ordinary quantity, and that repeatedly, had been extensively employed in the British army without any decided benefit, when the increased prevalence of the disorder, together with its violent nature and destructive consequences, rendered it necessary to adopt measures of greater efficacy. General depletion was now employed much more freely, and with corresponding advantage. It was resorted to in the early stage of the disease, and the quantity was regulated by the effects produced on the system. "The diminished vascularity," says Dr. Vetch, "is the first effect which ensues, and before the end of the operation the eye will often become nearly of its natural appearance. The cessation of all uneasiness should be the *sine qua non* of stopping the flow of blood. This, in a robust man, will often not be obtained until thirty or forty ounces have been taken away; and in a few deliquium will take place before this is effected; one or other of these effects should always be procured." If, which rarely happened, the disease assumed its violent form in spite of this treatment, the same means were repeated. In this state, fifty or sixty ounces must be taken away to relieve the pain or bring on syncope; "but we can always rely with certainty on the benefit which will ensue when either of these effects is produced. In every case where such practice is employed, however violent the tendency of the disease may be, its destructive termination will infallibly be prevented, and with much less expense to the patient, than by smaller and more frequent bleedings."*

Dr. Vetch observes further, that this plan of free depletion had a remarkable influence over the symptoms of the second stage. "The palpebræ were no longer subject to the same degree of eversion, the quantity of pus was diminished, and in no case did granulation become a troublesome symptom. The swelling of the conjunctiva was less vascular, and appeared like watery vesication; the attacks of pain were shortened, and less regular in their recurrence." Besides, therefore, the actual reduction of the numbers in which the disease advanced to the second stage, the symptoms were also rendered less violent by the early adoption of the treatment recommended. This practice, which has so fully met the exigency of the case, has not, perhaps, for its decision and efficacy, a parallel in the practice of medicine; and every person who has seen it employed, is sufficiently convinced of its propriety; but those who have experienced the mortification of seeing every other means unequal to combat the disease, are best able to express a just sense of its benefits."†

Rust, who, like Dr. Vetch, had soldiers for his patients, a circumstance that must be borne in mind when the amount of depletion is considered, found it necessary to take two or three pounds of blood in order to produce the requisite effect. He also insists on the importance of resorting to this

* Account, &c., p. 100, 101.

† Lib. cit., p. 104, 105.

active treatment as early as possible.* MUELLER† observes to the same effect, that the quantity of blood to be drawn must be determined by individual circumstances; that pain, so far as it depends simply on inflammation, should be removed; and that vascular turgescence of the eye and lids should be visibly reduced: that these objects may be accomplished in one individual by taking a pint, while in others it may be necessary to take two or three pints, or even more. It may be necessary to repeat the venesection; and if the symptoms continue urgent, it should be done without delay.

RUST‡ speaks favorably of temporal arteriotomy, which was performed with the most advantageous results more than a hundred times during the epidemic in Mentz. I agree with WALTHER§ in the opinion that venesection will do all the good that loss of blood can accomplish; and I consider it preferable to arteriotomy for obvious reasons. In the practice of Dr. VETCH,‖ "the blood was sometimes taken from the jugular vein and temporal arteries, without any superior advantage. From the great ease with which the quantity of blood can always be obtained from the veins of the arm in a given time, they were generally resorted to."

After venesection, cupping from the temple and leeching may be employed. In a severe case, after bleeding the patient largely from the arm, apply twenty or thirty leeches round the eye, and repeat them quickly.

Scarifications, whether superficial or deeper, are objectionable, as in all cases of acute ophthalmia. The wounds thus inflicted increase the local irritation; and the quantity of blood furnished by them is too inconsiderable to compensate this disadvantage.

WALTHER recommends very strongly the practice of cutting out a large piece of the swollen conjunctiva, either from the eyelid or the globe, after general bleeding.¶ Several drachms of blood will flow from such an incision with great relief of the local symptoms. He recommends the removal of as large a piece as can conveniently be cut out, observing, that although such a wound is large when first made, it appears as a mere line after the inflammatory tumefaction of the membrane has subsided.** He equally approves of this proceeding in the subsequent stages of the complaint.

Active purgatives in the first instance, and afterwards milder aperients, with reduced diet and rest, must accompany the measures just described. After general depletion, the tartrate of antimony may be administered with advantage in nauseating doses; and mercury may be given for two or three days, as we administer it in other inflammations after bleeding, to quiet that disturbance of the capillaries which might lead to effusion. Calomel alone, or combined with opium, in small doses, every four or six hours, will answer the purpose.

After depletion blisters may be applied to the nape; and the blistered surface may be dressed with savine cerate.

The active antiphlogistic treatment, and particularly the large and repeated

* Die Aegyptische Augenentzündung, p. 212, 216.

† Erfahrungssätze, p. 122.

‡ Lib. cit., p. 213.

§ Lib. cit., p. 124.

‖ Lib. cit., p. 102.

¶ An analogous proceeding is advised by SCARPA in cases of chemosis generally, with the view of letting out that supposed effusion of blood under the conjunctiva, which he regards as the cause of the chemosis. The operation "consists in the circular excision of the projecting portion of the conjunctiva with the curved scissors, at the part where the cornea and sclerotica unite; by means of which, not only the whole of the blood which is extravasated under the conjunctiva is discharged, and with immediate relief to the patient, but also that which, notwithstanding the abundant general evacuations of blood, might still greatly distend the vessels of this membrane." —Mr. BRIGGS' *Translation*, p. 148.

** Lib. cit., p. 126—130.

bleedings, which have just been spoken of, have been employed in army practice, where the patients are generally in the vigor of life, robust, and in high condition. Such means are not necessary, nor would they be admissible in the less vigorous or even sometimes enfeebled subjects, in whom the complaint may be seen in civil life. In the early period of the disease, before chemosis has occurred, the cornea being clear, moderate antiphlogistic treatment will be sufficient to check the inflammation, and prevent danger to the eye. According to the age and strength of the patient, and the state of the circulation, blood may be taken, either by venesection, or by cupping or leeches: aperients, antimonials carried to the extent of nauseating, and a short use of mercury, may be added. If the conjunctiva has begun to swell, and danger to the cornea is apprehended, especially in a young and strong subject, it will be necessary to proceed more actively. If chemosis has been established, and unfavorable change has already occurred in the cornea, extensive depletion would only weaken the patient, without chance of corresponding advantage.

Local applications.—From the well-known efficacy of cold in reducing vascular action, and consequently lessening effusion and swelling, applications of this kind may be expected to prove most advantageous in purulent ophthalmia; and that they are so is proved by the concurrent testimony of those who have treated the complaint most extensively. I believe, with Rust* and Mueller,† that nothing answers the purpose better than cold spring or river water, with which the eyes may be frequently cleansed: it may be used, too, if it is found comfortable, more or less constantly as a lotion, by means of light linen rags dipped in it, and frequently renewed; they should cover the forehead as well as the eyes. Mueller too employed with advantage, in the very commencement of active inflammation, water rendered still colder by putting pieces of ice into it. A fresh portion of water should be used for each cleansing of the eyes.

Walther‡ also extols highly the beneficial effects of cold water. "In the severer forms of the disease we apply cloths dipped in cold water, not only to the eyes and forehead, but also to the entire head. This plan is continued in some cases from fourteen to twenty-one days with the best result; with great alleviation of the pain, rapid subsidence of the swelling, and diminution of the puriform discharge." In several obstinate cases I have had could water poured over the head once or twice a day with good effect. "The cold douche has also been used in some instances with surprising benefit." Dr. Gericke, who had the charge of an ophthalmia hospital, gives the following account. "The cold douche was resorted to in conjunction with powerful antiphlogistic means. It was used in all cases attended with chemosis, and it never failed to give immediate relief. When the affection was obstinate, it was often repeated. The patient was seated in a bathing-tub half full of warm or cold water; perhaps the former is preferable. Cold water was then poured over the head from a height of five feet: it produced a great shock. The douche was repeated three or four times; the patient was then put to bed; considerable perspiration ensued, with relief from pain." Cold affusion was resorted to with considerable success by Mr. Peach,§ when the ophthalmia prevailed in the second battalion of the fifty-second. "In some cases where, after the very free use of the lancet, the patients felt hot and restless, and in a very few cases where these symptoms occurred in the first instance, the usual benefits resulted from its employment."

* Lib. cit., p. 211.
† Lib. cit., p. 128—130.
‡ Lib. cit., p. 130—133.
§ Dr. Vetch, *Account, &c.*, p. 115.

Warm fluids, fomentations, poultices, and steam, increase the heat, and thus augment the vascular disturbance. When, under the continued progress of the inflammation, the application of cold becomes painful, the water may be used tepid for cleansing the eye. Unless there should be spasm of the lids, warm fomentations should not be employed; though I have known instances in which patients have found them agreeable. If the continuation of cold cannot be borne, let local means be laid aside, except for ablution; it is not absolutely indispensable to keep the affected organ constantly covered with wash or fomentations.

The free use of mercury is recommended by RUST,* when the inflammation is advancing in spite of active antiphlogistic treatment. My experience corresponds with that of VETCH† and WALTHER,‡ who have seen salivation produced in many instances without the smallest advantage. I have already recommended the use of calomel, for a limited period, in order to prevent effusion of lymph.

The means before recommended must be continued and repeated till the bright redness of the conjunctiva and its tumefaction are lessened, and till the pain is gone.

The membrane will now be paler, with a relaxed and flabby appearance, the discharge still continuing abundant; we must alter the plan of treatment, and use astringents, allowing better diet, and perhaps tonic medicine. By the judicious employment of such means, after the violent inflammation has been subdued, we shall remove that diseased condition of the conjunctiva which causes so much inconvenience to the patient, so much trouble and perplexity to the practitioner. Of astringents, the solution of alum comes the first in order, being employed in the same way as in the infant. The oxymuriate of mercury may be used (gr. j—ii ad ℥j). MUELLER§ particularly recommends two formulæ; 1st, one, two, or three drops of sulphuric acid in an ounce of water; 2dly, two or three grains of acetate of copper in the same quantity.

The preceding milder applications may be followed by solutions of the nitrate of silver or sulphate of copper (gr. ij—vj ad ℥j), or the undiluted liquor plumbi. Of these fluids, one, two, or three drops should be carefully introduced between the lids, once or oftener in the day, the eye being still occasionally cleansed and bathed with the alum lotion. The citrine, or red precipitate ointment, may be applied to the edge of the lids at night.

Mr. BRIGGS‖ has found the oleum turbinthinæ to be the most effectual means of checking the profuse discharge in purulent ophthalmia. He introduces "a minute quantity of it, proportioned to the age and sensibility of the patient, on the point of a camel-hair pencil between the eyelids every morning, the eye being immediately afterwards immersed or bathed freely with cold water and a sponge, until the uneasiness and sense of heat which it produces in the eye and surrounding parts are allayed, which usually continue for some minutes."

We must carefully observe the effects of astringents in the first instance; they cause more or less pain, which goes off, leaving the eye relieved and stronger. But if the pain should continue, and the redness be increased, we must leave them off and return to the antiphlogistic means; for the same reason we must suspend them at any period, if relapse of inflammation should occur.

Better diet, exposure of the organ to light, as much as it will bear, and exercise in the open air, may be combined with this change of local mea-

* Lib. cit., p. 219.
† Lib. cit., p. 88.
‡ Lib. cit., p. 138.
§ Erfahrungssätze, p. 143.
‖ Note to his translation of SCARPA, p. 170.

sures. Confinement to the house does not seem advantageous at any period of the complaint, while free exposure of the inflamed eye to cool air, and even exercise, instead of being hurtful, as patients and their friends suppose, have generally been found decidedly beneficial. Dr. VETCH is even disposed to recommend the trial of a journey, in the commencement of the disease, if the eye be freely exposed to the air, and the weather favorable. He says that when the second stage has commenced with chemosis and purulent secretion, he has never seen any but the best effects from change of place. "Soldiers, who have commenced a march with the disease completely formed, though exposed to heat, dust and fatigue, and not abstaining even from intoxication, are invariably better at the end of the journey than when they set out. The instances of this fact, which I could adduce from my own observation, are innumerable; and I am informed by Mr. MURRAY, surgeon to the forces, that so strongly did he observe the beneficial effects of exposure to the air, when a great number of men affected with the disease were sent under his care to the interior of Sicily, that he was induced to march them from one place to another, with a view solely to the good effects which he saw to result from it."*

If the patient is weakened, we allow a good diet, with stimuli, and we may have recourse to bark, cascarilla, and the mineral acids. In the irritable state, which remains after considerable depletion, with the eye suffused and intolerant of light, with considerable pain not referable to inflammation, and often periodical, MUELLER† employed the remedy first mentioned in substance, repeating it at short intervals: he used it generally in the treatment of the contagious ophthalmia, after depletion, if there was no decided contra-indication. Improved diet should be combined with the bark.

The internal use of opium has been resorted to as a remedy for pain; and it may sometimes be used with advantage after depletion, either alone or in the combination of Dover's powder. Some have considered its local use advantageous before proceeding to astringents, or when they cannot be borne. The forms employed have been the aqueous solution as a collyrium; vinum opii dropped into the eye; and the substance alone, or combined with mercurial ointment, rubbed over the brow.

Spreading ulceration of the cornea, attended with debility, will require a decided tonic and stimulating treatment; that is, good diet with porter, or wine, bark, or the sulphate of quinine, and local astringents.

In that peculiar kind of ulceration, where there is a deep groove in the margin of the cornea, after stopping the inflammation, raise the general powers by good diet and tonics, and leave the ulcer to nature. The very diligent use of astringents and stimuli, particularly the stronger ones, often does mischief. The most rapid recoveries I have seen in extensive ulcers of this kind, have been where no local means but simple tepid ablutions have been employed.

In that ectropium of the lower lid, which remains after the inflammation is gone, and presents a large red fleshy mass, without much sensibility, the nitrate of silver in substance may be freely used. A few applications of it soon remove the swelling and restore the lid to its natural position.

There are, in short, two points for us to bear in mind in treating acute purulent ophthalmia; first, to check inflammation by antiphlogistic means, and then to employ astringents. If we proceed on this plan, we shall prevent that chronic thickening and granulation which are so obstinate and troublesome.

* *Practical Treatise*, p. 208. † Lib. cit., p. 137–141.

The free use of powerful astringents, such as the sulphate of copper, the diacetate of lead, and a strong solution of nitrate of silver, or an ointment containing the same substance, has been recommended in the commencement of purulent inflammation, to cut short the complaint. The remedies thus employed come into contact with the very seat of disease, and act directly on the vessels, which are in a state of disturbance; hence we derive a rational explanation of their beneficial operation when the disorder is confined to the mucous lining of the palpebræ, or in its first degree of extension to the conjunctiva of the globe.

I have already quoted (p. 226) the experience of Mr. Melin on this subject.

Very strong testimony in favor of the astringent plan of treatment in ordinary purulent ophthalmia is given by Dr. O'Halloran,* who had enjoyed ample opportunities of observing the disease, as an army surgeon, for many years, and in various climates. He had become dissatisfied with the antiphlogistic treatment, from having found it frequently either insufficient or injurious, and was hence led to use astringents, not only in the early stage of the disease, but when the purulent discharge and chemosis were fully established. He employed the sulphate of copper in substance, rubbing with it the inner surface of the eyelids after everting them, or he dropped into the eye the ten grain solution of nitrate of silver; and generally used one or the other once a day. He gave purgatives and applied fomentations. If the symptoms indicated that the internal parts of the organ were affected, he directed the application of leeches. After mentioning a case treated successfully with the sulphate of copper and the caustic solution, he adds, "The foregoing case, with some hundreds on record, of the different varieties, show with what efficacy and safety blue-stone may be applied to the eyes when under disease: its effects in removing the affection of the parts and allaying the irritation are remarkable. I can safely say, that abstraction of blood will be rarely necessary in this disease, if the plan recommended be strictly attended to; and I moreover am of opinion, that if any inquiry be instituted amongst the army surgeons, it will be found that those who used the greatest depletion, were the least successful practitioners, and that sloughing, ulcers, &c., more frequently succeeded the evacuating plan, than when the patient was partly left to nature."

[Our views with regard to the detraction of blood in purulent ophthalmia, coincide entirely with those of Mr. Lawrence; but our experience leads us to ascribe greater remedial powers to the nitrate of silver than is done by him, and also to employ it earlier and of greater strength. We resort to it at once, if there be no great heat and pain in the eyes, with inflammatory excitement in the system; and if these symptoms be present, we only delay the application until they are abated by free venesection; and we afterwards continue its employment, conjointly with topical depletion, purgatives, diaphoretics, counter-irritants, &c. We graduate the strength of the solution to the profuseness of the purulent discharge; when the latter is great, using a solution of from thirty to forty grains of the salt to one ounce of distilled water. Generally, however, a solution of from ten to fifteen grains to the ounce will be sufficient, and its strength must be diminished as the discharge abates; for patients who have used the strongest solution when the disease is at its height, will experience severe pain from a far weaker one, even of four grains to the ounce, at an advanced stage of convalescence. We apply this solution but once a day,

* Practical Remarks on Acute and Chronic Ophthalmia, and on Remittent Fever; London, 8vo. 1824. Part 1, ch. 1.

and then only two or three drops at a time, which is to be dropped on the eye from a quill or glass tube. Either of these may be introduced into the solution so as to allow the requisite quantity to pass into the tube, the upper end of which is then to be closed with the fore-finger, and the lids being separated, and the tube held over the eye, the finger is to be raised when the fluid will flow out. By this means the application may be best made to the eye, and the quantity may be most accurately graduated. To cleanse the eye we ordinarily employ pure water, or a collyrium consisting of one grain of corrosive sublimate in six ounces of water; its temperature to be regulated by the feelings of the patient.

We attach much importance also to the use of mustard pediluvia at night, with a full dose of Dover's powder. These means tend greatly to the comfort of the patient, by abating the pain, giving a good night's rest, whilst, by determining to the extremities and surface, they act as revulsives.]

The treatment proposed by Mr. TYRRELL, of incisions through the chemosed conjunctiva, and first employed by him in acute gonorrhœal ophthalmia, is equally applicable to the common purulent form of the complaint. It is fully described in the next chapter, at the end of the first section.

Treatment of purulent ophthalmia in its milder form.—If inflammation, although not considerable, should have occurred in the conjunctiva oculi, or if we think its occurrence probable, it will be proper to employ moderate antiphlogistic treatment, such as abstraction of blood by cupping or leeches, cold washes, regulated diet, and aperients. When active disturbance is subdued by these means, the local use of astringents to the diseased palpebral linings is necessary, and must be continued until the morbid change already described shall have been completely removed. The solutions of alum, sulphate of copper, and nitrate of silver, at first in a weak form, and gradually increased in strength if necessary, dropped into the eye once or twice a day, and the red precipitate or citrine ointments to the ciliary margins, are the best remedies for this purpose. The liquor plumbi diacetatis, undiluted, may be used, if the complaint should be tedious, and a stronger astringent be consequently required. Confinement within doors is not necessary; on the contrary, exercise in the open air, and exposure of the eyes to it for some hours in the day, particularly in warm or mild weather, is decidedly advantageous. The protection of a shade must be used, if the light should be too powerful. The army-surgeons have found that this inflammation, even in its more active form, instead of being aggravated, has been decidedly checked by free exposure to the air; and thus that patients have been much better after marches, even in bad weather.

MUELLER strongly recommends, from long experience, mercurial applications in the form of ointment, which I have not seen employed. These are the hydrargyrum oxydulatum nigrum,* which seems to be a mild dark gray or blackish oxyd of mercury, in the proportion of four or six grains to one drachm of lard; the white precipitate,† in the proportion of seven or eight grains to the drachm; or the red precipitate. These ointments are to be smeared over the diseased surface once or twice daily. If the eye does not bear their application in that manner, we are advised to rub the former, sometimes with the addition of opium, into the eyebrow, forehead, or cheek; or to apply over the lids a piece of linen thickly spread with it.‡

As the complaint is now strictly local, the above-described topical measures are the best calculated to remedy it. That MUELLER§ should have found blisters, issues and setons unavailing, need not surprise us.

* Neueste Resultate, p. 50. † Ibid., p. 42. ‡ Ibid., p. 52. § Ibid., p. 63.

Treatment of the diseased palpebral conjunctiva in the chronic state.—When purulent ophthalmia has been neglected or inefficiently treated, and when the eye has consequently been repeatedly inflamed, the palpebral linings become thoroughly altered in structure, and we cannot be surprised that it should be difficult, and indeed hardly possible, to restore their healthy state. For this purpose the use of local means still more active than those already specified, has been recommended. This condition of the parts has been called by English writers, the granulated state of the eyelids. It is hardly necessary to observe that this phrase, and the term granulations, which is so frequently employed in the account of purulent ophthalmia, merely denote the external resemblance of the morbid structure to the surface of a healing ulcer, without indicating any affinity in origin and nature.

A very important effect produced by this state of the lids is vascularity and opacity of the cornea. The mechanical friction of the granulations on the surface of the cornea causes its vessels to be enlarged, so that the texture of its conjunctival layer is loosened and thickened; hence haziness, a nebulous state, or more considerable opacity is produced. This change must be distinguished from the effects of active inflammation. In the present instance, the following is the order of events:—1st. Disease of the palpebral lining; 2dly. Acute inflammation of the conjunctiva; 3dly. Full development of the granular surface, with thickening and hardening of the membrane; 4thly. Vascularity and opacity of the cornea.

The morbid change is frequently confined to the upper half of the cornea; that is, to the portion over which the rough surface of the upper eyelid moves; while the lower half remains transparent. Granulations are hardly developed on the narrower surface of the lower lid, which has a much less range of motion than the upper. Hence the lower part of the cornea escapes the irritation, which affects the upper so injuriously. The vascularity may proceed to the extent of covering the cornea with a network of red vessels; and its mucous covering may be so loosened and thickened as to exhibit the state, technically called *pannus*, in which the boundary of the cornea can hardly be seen.

With these changes may be combined the results of severe inflammation; viz., leucoma, synechia anterior, prolapsus iridis, staphyloma, amblyopia. Sometimes there is active inflammation of the membrane, with blennorrhœa; for the eye is weak and irritable, and subject to relapse of inflammation from slight causes.

In the first place, we must remove inflammation by suitable means. The eye should be protected from external excitement without constantly covering it, and certainly without confining the patient to the house, which would be decidedly prejudicial.

Excision of the granulations, either by knife or scissors, was practised at one time; and a dispute arose which method deserved the preference. This was terminated by the entire abandonment of the proceeding, which had been found injurious.

Walther,* however, still advocates the plan of excision as the most effectual means for removing the preternatural growth of the conjunctiva, to which purpose he has found caustics inefficient. He observes, that the granulations will be reproduced, and that it will be necessary to repeat the operation, which causes no local excitement, so that it may be speedily followed by the use of astringents or escharotics.

Supposing the eye to be free from irritation, and the disease thus reduced within its original boundaries, we may try, even in these chronic cases, the

* Lib. cit., p. 128, 129.

astringents already specified, such as the solutions of alum, nitrate of silver, or bichloride of mercury. The liquor plumbi diacetatis undiluted, and the citrine or red precipitate ointments to the ciliary margins, are among the most serviceable local remedies.

If these means should not be sufficient, the use of escharotics has been recommended. In resorting to them we should always bear in mind the powerful action of such substances, and the delicate organization of the part to which they are to be applied. We should begin with the weaker, and proceed to the stronger applications. To prevent their injurious action on the healthy conjunctiva, we should take care that they touch only the diseased part. We should therefore evert the lids, and keep them everted until the effect of the application is produced. The surface, when thus exposed, may be freed from moisture before the escharotic is applied; when its action is over, the membrane should be carefully washed to remove any remaining portion of the application, before the lid is restored to its natural position. The smearing with oil, which has been adopted for the same purpose, is not more efficacious than ablution with a soft sponge and simple water. The substances may be applied in solution, in powder, or in substance; the first and last forms are the best. Change of application is often advantageous.

The acetate of copper in concentrated solution, or in powder, is one of the weaker means. The sulphate of copper has been used in powder and in substance; in the latter form it is one of the best remedies of this kind. The whole of the granulated surface should be gently rubbed until it assumes a dirty bluish tinge; after waiting a minute or two, the lid should be carefully washed and restored.

The nitrate of silver has been employed in solutions of various strength, sometimes even saturated, or in substance. The prominent points of the morbid surface should be lightly touched in the latter case; in the former the palpebræ must be everted, and the liquid applied with a camel-hair pencil to the granular surface. In Belgium, where the affection has prevailed extensively in the army for a long time, the nitrate of silver has been relied on principally as a remedy for the granulated state of the lids, and has been principally used in substance. They have rubbed the diseased surface freely, then passed over a brush dipped in oil, and restored the lid to its place. Mr. Gouzee, at the head of the military hospital at Antwerp, says, "that this proceeding may be safely employed in the lower lid; but that he has often found it, when used to the upper, produce very serious symptoms, such as ulcerations and greenish-yellow spots." The pain is so great, that patients often refuse to submit to a repetition of the application. Hence he has left off this method, and employs instead a solution of the caustic in an equal quantity of water. He applies this by means of a camel-hair pencil, not taking up much of the liquid, then touches the surface with another pencil dipped in oil. Two or three cauterizations are sufficient to remove the inequalities of surface, but the thickening of the membrane cannot be got rid of without a greater number. One upper lid only should be touched with the pencil at a time; both lower palpebræ may be cauterized at once with the stick of nitrate of silver. Mr. Gouzee adds, "that the nitrate of silver is the most efficacious remedy in these cases; that the sulphate of copper is not sufficiently powerful; and that, when the granulations are large, especially in the upper lid, it is advantageous to excise, in the first instance, the most prominent portions with curved scissors."*

* Des Granulations des Paupières, et de leur Traitement. Journal des Connaissances Mèdico-Chirurgicales, July, 1839.

The nitric and muriatic acids, diluted with three parts of water, have been recommended. These may be applied, like the solution of lunar caustic, with a camel-hair brush.

These strong applications, as might be expected, produce and aggravate local excitement, causing pain, often very severe, redness, swelling and increased discharge. They must not be repeated, until these effects have gone off, that is, until the third or fourth, or from that to the sixth or eighth day. Longer delay, and antiphlogistic treatment are sometimes necessary. In the interval of the escharotics, some of the astringent solutions already mentioned may be employed.

I could not adduce much personal experience in favor of this escharotic treatment; having found more benefit from antiphlogistic means in the first instance, and the subsequent use of mild astringents, such as the solutions of alum, sulphate of copper, or lunar caustic, and the liquor plumbi, with regulation of diet, and the digestive organs, residence in pure air, exercise, repose, or moderate use of the organ. With such means I have sometimes advantageously combined issue in the temple. Great and rapid improvement has occasionally been observed when the general plan above mentioned, with merely soothing local applications, has been substituted for strong astringents and escharotics. The latter should not, I think, be employed, until the gentler measures have been tried, and then very cautiously. The great tendency to relapse must be borne in mind; should active mischief return, the escharotics must be laid aside, and the milder plan resumed.

Walther,* whose experience in this complaint has been much more extensive than mine, has come to the same conclusion respecting the use of escharotics. "The benefit derived from them," he says, "is on the whole inconsiderable; even when methodically and cautiously employed, they either do not effect a complete cure, or bring it about very slowly. I used, in the ophthalmic hospital of Bedburg, the means recommended by Rust, which are chiefly of a powerful escharotic kind, in numerous cases, according to the rules he has laid down, but without the expected benefit. Most of them are so strong that the eye, even in its relaxed state, will not bear them without experiencing inflammatory reaction. We therefore again reduced our ophthalmic formulary into a small compass, after having enlarged it without advantage. I am indeed astonished when I see one of the most delicate organs attacked with a series of applications so powerful and destructive, from corrosive sublimate to arsenic. The number of these local remedies is calculated to excite distrust. When a disease can be easily and safely cured, the remedies are few, simple, and recommended by reason and experience. They become multiplied in proportion to the obstinacy and tediousness of the complaint."

Mr. Tyrrell has also objected strongly to the escharotic plan in the chronic stage of purulent ophthalmia, accompanied with the granular state of the conjunctiva, having generally found it unsuccessful. He takes a little blood, by a leech or two on the lid, when the membrane is bright red and turgid; at other times he uses mild astringents, of which he has found the undiluted liquor plumbi diacetatis, applied to the morbid surface with a camel-hair pencil, the most useful; sometimes he draws blood from the membrane by two or more transverse incisions; and he occasionally employs counter-irritation by blistering.†

The presence of various changes produced by previous active inflammation, such as ulcer, opacity, nebula, vascularity of the cornea, pannus,

* Lib. cit., p. 148, 149.

† Vol. i., p. 132—138.

prolapsus iridis, partial staphyloma, affords no contra-indication to the use of escharotics or astringents. On the contrary, when these affections have long resisted other means, they often are either greatly improved, or rapidly disappear under the treatment above described.

After the use of escharotics, the conjunctiva does not regain its normal state; it exhibits traces of the former affection, which, however, do not interfere with its function. It is thicker, and has a leathery appearance, with a darker red color than in the natural state, and sometimes we observe whitish cicatrices.

[The morbid condition of the palpebral conjunctiva termed granular lids, is a most troublesome affection—extremely obstinate—subject to sudden and violent exacerbation from the slightest causes, and therefore demanding the incessant attention of the practitioner—and when allowed to continue, tending surely to the impairment, and most generally, indeed, the total destruction of vision. A very large proportion of the applicants for admission into Wills Hospital, labor under this disease, and the treatment which they represent themselves to have undergone, as well as the statements of private patients, leads us to infer that physicians generally are not as well acquainted with the complaint as it is desirable they should be. Some brief additional remarks, and a few cases illustrating the character of the affection and the means of cure, may be therefore useful to American practitioners.

The abnormal condition of the palpebral conjunctiva, termed granulations, presents several different appearances; the chief we have observed are the following:—1st. The conjunctiva instead of its natural smooth polished surface, becomes villous. 2d. It resembles an ulcerated surface, the granulations exhibiting most of the phases presented by such a sore; sometimes being small and pale, at others large and flabby, and bleeding on the slightest touch. 3d. The granulations have a warty appearance, are firm, pale, cut like cartilage and yield little blood. 4th. The conjunctiva is thickened and fissured something like the surface of a mulberry, and this appearance we have observed most frequently on the fold of the conjunctiva where it passes from the lower lid to the eyeball.

The situations in which these granulations are most generally found are the conjunctiva lining the upper palpebra, and that of the lower where it passes from the lid to the globe, and especially towards the external angle of the eye. To see these granulations, it is of course necessary to evert the lids.

In the selection, and mode of application of local remedies to these granulations, great judgment and care are required.

When the granulations are very vascular and spongy, scarifications will be beneficial.

Of the local applications, the sulphate of copper is the one which is most generally found advantageous. In some cases this is not sufficiently active, and then the nitrate of silver or the dilute nitric acid may be employed.

Two years ago we were led, by the favorable reports of the efficacy of the iodide of zinc in reducing enlargement of the tonsils, to try this application in a case of greatly thickened conjunctiva of long standing, which had proved rebellious to various remedies. The result was so satisfactory that we have since employed it in a few similar cases, and our experience thus far authorizes us to recommend this remedy to the attention of the profession.

In making these applications, the lids must be everted, and a basin

of tepid water and a very soft sponge should be within the surgeon's reach.

When the sulphate of copper is to be used, a clear crystal should be selected, which should be fixed in a quill and then cut into a wedge shape. This is to be passed a few times over the granulated surface, which is then to be freely washed, before the lid is restored to its natural position.

The nitrate of silver ought also to be fixed in a quill and cut into a conical form. This is to be passed lightly over the granulated surface, which is to be immediately washed as just directed.

The nitric acid is to be applied by means of a camel-hair brush, and in the same manner as the last-mentioned remedy.

The first effect of the last two applications is to produce a puffiness of the lids, with increased lachrymation, and some burning, which subside in a few hours, and a purulent discharge takes place. In some cases, the symptoms just indicated become excessive, and persist for several days; arising either from the remedy having been too freely applied, or to the wrong one being selected, and a change must consequently be made, either in the remedy or the freedom of applying it. A common error is the too frequent repetition of local applications. The sulphate of copper should not be used oftener than once in two, three, or four days, the nitrate of silver and nitric acid, only once in four, five, or six days.

Where the eye is very irritable, with injection of the ocular conjunctiva and lachrymation, the most prompt and marked relief is afforded by a cold salt water bath to the eyes.

We first called attention to this remedy, some years ago, in a report of cases treated in Wills Hospital, and it has since been used by others, who confirm all that I have there said of its remedial virtues.

M. Tavignot has recently made extensive use of this salt, as a local application, in different forms of inflammation of the eye, and more particularly, in ulcerations of the cornea, and he recommends it as being not only as efficacious, but even more so than nitrate of silver, and other substances commonly applied in such cases. At the same time, it is less likely, he says, to produce permanent irritation, or act as an escharotic. He has employed it, 1st. In the *solid* form. The crystals of common salt are ill adapted for this purpose, from their want of cohesion; but with a little practice a piece may be obtained capable of being filled into a caustic-holder, and used in the same manner. Another way of applying the substance is in the form of a fine powder introduced into the eye; its action will then become prolonged, and as a consequence, be more energetic. This, however, might be an advantage in various cases, not readily yielding to other modes of treatment, as, for example, purulent ophthalmia. As compared with the nitrate of silver, or sulphate of copper, the use of the chloride of sodium in the solid form, is preferable, M. T. says, because there is no danger, as with these substances, of its destroying the tissues, its action being merely irritant. The application of chloride of sodium causes pretty smart pain at the instant, but this soon subsides. 2d. In the form of *ointment*. This may be made in the proportions of from 1 to 4 drachms of powdered common salt, to the ounce of lard. It is best to begin with the weakest form, and afterwards gradually to augment its strength. In granular conjunctivitis, and inflammation of the ciliary margins,—affections, it is well known, of a very obstinate character,—it has been a signal benefit. 3d. As a *collyrium*. This is the best form, M. T. thinks, of using the applica-

tion. Several cases are given of its success in ophthalmia, and ulcerations of the cornea. The strength of the solution he uses, varies from 1 to 3 drachms to the ounce of water. One drachm to the ounce will be found sufficiently strong, he says, for most slight cases. We usually employ a saturated solution.

Sea-air often produces the most beneficial effects in this disease. We have seen some very remarkable instances illustrative of the benefits derived from a sea-voyage.

We add the following cases, to show the plan of treatment we have found most successful in this affection.

Case I.—Terence Hagan, ætat. 30, admitted into Wills Hospital, September 30th, 1837.—This man stated that he had been attacked in November, 1836, with inflammation of both eyes, accompanied with discharge of matter; that after having been some time treated by a physician in New Jersey, finding his disease not abating, he went, the following March, to the city of New York, where he was treated by scarifications of the lower lids, repeated cupping from the head, and took pills which made his mouth sore. Being dissatisfied with the result of this treatment, he came on to Philadelphia.

When he applied at the hospital, the propriety of granting him a certificate that he was not incurable, which is necessary for admission, seemed to me doubtful. At this time, his cornea was so completely opaque, that he could barely distinguish day from night; his ocular conjunctiva was a mass of red vessels, through which the natural color of the sclerotica could not be seen; the palpebral conjunctiva of the upper lids were covered with large, firm, wart-like looking granulations; and that of the lower lids showed numerous cicatrices, resulting from deep scarifications. There was some intolerance to light, with cephalalgia, and sense of weight in the head; pulse moderately active.

The day he was admitted, ten or twelve ounces of blood were taken, by cups applied to his head, and an active purgative was prescribed. These remedies relieved his headache, and abated the intolerance of light. He was then subjected to the following treatment, which was persevered in with little variation during the three months he continued under our care. Cups were applied to his head every few days, the period determined by the recurrence of the headache, which was frequent, and by the increase in the injection of the conjunctival vessels; purgatives were given as revulsives, and to correct the torpid state of the bowels; a mild, light diet, principally vegetable, was directed; and the solid sulphate of copper applied every two or three days, to conjunctiva of upper lids, and occasionally to that of the lower. This local application was made with difficulty in this case, inasmuch as the upper evelids were so dense and rigid that it was impossible to evert them. The only way in which the sulphate of copper could be applied, was by drawing the lid from the ball, inserting a thin piece of the salt, fixed in a quill, between the lid and ball, and then rubbing it against the former. Under this treatment, the granulations diminished, as also the injection of the ocular conjunctiva, and absorption of the lymph in the cornea commenced.

The treatment was continued by my colleagues, modified occasionally to suit varying circumstances or in conformity to peculiar views. The only change, however, we need notice is the administration of iodine, which was given partly to promote absorption and partly to relieve scrofulous swellings of the glands of his neck, which occurred and proved troublesome; suppurating and causing much discomfort to the patient.

On the 1st of October, 1838, Hagan again came under our care. His eyes, during the interval, had much improved. Distinct vessels could now be seen on the ocular conjunctiva, between which the natural color of the sclerotica was visible. The granulations had nearly disappeared, and a large portion of the lymph on the cornea had been removed.

The upper lids could now be everted and the sulphate of copper was occasionally applied to them. Hagan still suffered at times from headache, from which he was always relieved by cups to the head, and this remedy also served to diminish the injection of the conjunctival vessels. The shower bath was also directed as long as the weather permitted, and as his bowels were still inactive, the pil. cathart. comp. two or three at bed-time. The glands of his neck, particularly of his right side, were swollen, indurated and occasionally discharged pus. To correct this condition, which we suspected might have some dependence on a syphilitic taint, we ordered, on the 10th of October, the syrup of sarsaparilla ℥j three times a day, with one-tenth of a grain of corrosive sublimate. The latter was given as follows:—℞. corros. sub. g. j; spt. vin. ʒj; solv. et add. aq. puræ ℥v. M. liq. A tablespoonful with the syr. sars. three times a day.

This was continued for a month, at the end of which the swelling of the glands had diminished, and also the injection of the eyes. A seton was then inserted in his neck, and a few drops of vin. opii placed daily on his eye, and mustard pediluvia were ordered twice a week at bed-time. Cups were still occasionally required, and also the sulphate of copper.

Early in December (5th) Hagan complained much of nausea, loss of appetite, and general feelings of malaise. His diet was then changed. Soups, which had previously constituted the principal part of his food, were forbidden, and a little meat allowed daily, with soft boiled eggs, rice, and milk. The following pills were also prescribed. ℞. pulv. rhei ʒj; bicarb. sodæ ℈ij; extr. gent. ʒss. M. Ft. pilul. xl, three to be taken morning and evening. These pills were continued for several days, when he was given the sulphate of quinine in small doses. Under this treatment, his stomach recovered its tone. The vinum opii was continued.

By the 1st January, 1839, when my term of service expired, Hagan was able to distinguish the different persons in the house. The granulations had entirely disappeared; there were but few red vessels in the conjunctiva, and the color of the iris could be distinguished around the circumference of the cornea.

During the month of May, 1839, we had charge of the house in consequence of the indisposition of our colleague, Dr. Fox, when we found Hagan still there, and with improved vision. My immediate successor, Dr. Isaac Parrish, had removed portions of the conjunctiva around the cornea which seemed to have promoted absorption of the lymph on the cornea.

Hagan could now see sufficiently well to make himself useful by working in the garden. The seton was still in his neck and discharging freely. A drop or two of the undiluted liquor plumb. subacet. L. P. was directed to be placed on his eyes every two days, and iodine to be given internally. In a couple of weeks his mouth became sore, which was, he says, the case when he took the last previously, and it was discontinued, and an astringent wash was directed for his mouth, under which the ulceration began to heal.

The most rapid improvement took place during this month, principally

attributable, I think, to the use of the liq. plumb. subacet., and on the first of June, when Dr. Fox resumed the service of the hospital, Hagan was able to read large letters—as the heading of a newspaper.

He was soon afterwards discharged.

Case II. *Conjunctivitis with Granular Lids and Opacity of the Cornea.*—Bernard M'Crossin, ætat. 25, a native of Ireland, laborer, admitted July 14th, 1839. The principal facts which we have been able to gather of the early history of this case, are, that the patient was first admitted into Wills' Hospital, on the 9th of March, with acute catarrhal conjunctivitis, accompanied with considerable swelling of the lids, and great photophobia. By the latter end of the month, he was convalescent, but had a very severe relapse about the 1st of April. Convalescence was again established, but was followed by another relapse on the 1st of May, and this was repeated twice during the following month, (1st and 14th June.) On the 13th of July, the patient was discharged well. Four days afterwards he was re-admitted with a relapse; and during this and the two succeeding months, the same disposition to aggravation of the disease, as soon as its violence was conquered, manifested itself. Three or four relapses occurred within this period; the last, on the 9th of September, was a severe one, and proved very intractable.

On the 1st of October, the patient came under my care, at which period his eyes were in the following condition. *Right eye*—ocular conjunctiva injected, vessels distinct; palpebral conjunctiva thickened, that of the upper lid granulated; granulations rather pale, firm; cornea nebulous, a few red vessels running over the margin.

Left eye. Ocular conjunctiva similar to that of the right; palpebral conjunctiva thickened, that of the upper lip granulated; granulations firm, very red, larger than those of the other eye. Cornea, whole surface nebulous, of a dark color.

Excessive photophobia, vision being imperfect, most so in the left eye, pain in the head, pulse hard.

October 14th. Scarified left upper lip; conjunctiva cut like cartilage. Applied solid sulphate of copper to the right upper lid. Ordered ten ounces of blood to be drawn from back of the neck and temples by cups.

7th. Eyes much improved; injection and photophobia diminished; vision better. Applied solid sulphate of copper to both superior palpebræ.

9th. Yesterday was better. To-day there is increased photophobia, heat of the head and cephalalgia; ordered cups to back of the neck and temples.

11th. Better. Cupping relieved the head. Applied solid sulphate of copper to both upper lids, and introduced a seton into the back of the neck.

14th. Photophobia and injection diminishing; and vision improving. Dropped in the eyes solution of nitrate of silver, one grain to the ounce.

16th. Yesterday there was increase of photophobia and injection, with cephalalgia. Cups were applied to the head, and though little blood was obtained, it afforded relief to the latter symptom; the others remain the same. Ordered vin. rad. colchic. gtt. xx, morning, noon, and bed-time; to take with the last dose 25 drops of solution of sulphate of morphium.

18th. Photophobia and injection diminished. Vision with the left eye better than for a long time; can distinguish large letters; slept well. Applied sulphate of copper to upper palpebræ.

21*st*. Photophobia and injection continue to diminish; conjunctiva of upper palpebræ paler and smoother; no headache; seton discharging freely.

23*d*. Palpebral conjunctiva paler and smoother; some return of headache with active pulse; venesection ℥xij; liquor plumb. subacet. to eyes.

25*th*. Granulations of lids diminishing, few remaining at present, except near the edges of the tarsi; two ulcers on superior palpebral conjunctiva, which bleed freely on being touched; eyes free from pain; sight continues to improve. Applied sulphate of copper to the granulations.

28*th*. The eyes continue to improve until to-day. This morning his right eye became somewhat painful, and the lids are thicker, more granulated, and injected; pulse active; venesection ℥xij. Solid nitrate of silver to both upper lids.

30*th*. Eyes have continued painful ever since the application of nitrate of silver; lids tumefied; great photophobia; griping pain in the bowels; head feels light. ℞. Sulph. zinci gr. i; Aq. puræ ℥i. M. Ft. collyr. A few drops to the eye twice a day.

November 1*st*. Eyes easier; tumefaction and redness of the lids diminished; ulcer on left palpebral conjunctiva not so deep, does not bleed when touched; right upper palpebræ thick, and firm; did not sleep well last night. Bowels loose; pulse rather feeble. Applied solid sulphate of copper to both upper lids. Ordered the following to be given three times a day: ℞. Sulph. quinin. gr. i; hydrarg. c. creta gr. ii. M. And the face to be dipped daily in a basin containing a saturated lotion of common salt in water, with the eyelids open.

4*th*. Continued improvement; lids less thickened, granulations diminishing, ulcers healing; sleeps pretty well. Continue powders, and salt bath to eyes. Applied sulphate of copper to lids.

6*th*. Eyes feel and look better; photophobia diminished; sight improving daily; thinks he derives great benefit from the salt water; right upper palpebræ smooth, though still thickened. Applied liquor plumb. subacet. to eyes. Continue powders.

8*th*. Yesterday there were increased intolerance, and some pain in left eye; did not sleep well; bowels rather loose, for which last he was given an ounce of the spiced syrup of rhubarb. To-day there is less intolerance; his bowels are less deranged; slept well; sight improves. Applied solid sulphate of copper to both upper lids, and ordered a solution of the same, one grain to the ounce of water, as a collyrium.

11*th*. During the past two days the photophobia diminished; to-day there is an increase of it, and greater injection of the eyes; mouth quite sore from mercurial action. Discontinue powders. Applied solid sulphate of copper to both upper lids, and ordered tonic infusion.

15*th*. Not so well; granulations increased. Applied solid nitrate of silver very lightly to both upper lids.

17*th*. Lids have been swollen, with some purulent discharge, since last application; intolerance continues. Ordered infusion of chamomile flowers with a small portion of opium dissolved in it, to be applied warm to the eyes. Vin. rad. colchic., thirty drops three times a day.

18*th*. Eyes better, lids less swollen. Applied nitric acid, diluted with four parts of water, to conjunctiva of upper lids.

22*d*. Eyes much improved; less photophobia; palpebral conjunctiva smoother. Applied dilute nitric acid.

25*th*. Eyes were much better yesterday; seems to have taken cold last evening, and to-day they are worse. Left eye quite sore; palpebræ

swollen; purulent discharge; photophobia; cephalalgia. Ordered six grains of tartarized antimony, to be taken in divided doses, to-morrow morning.

27*th*. Head is much relieved since operation of emetic; feels more comfortable than it has done for three months past. There is great photophobia; cornea more opaque; slight catarrh. Liquor plumb. subacet. to eyes.

29*th*. Eyes free from pain, but intolerant of light. Right eye much improved; left cornea very opaque and vascular. Feels very weak; no appetite, quite feeble; skin cool. Ordered one grain of sulphate of quinine, four times a day, with tonic infusion.

December 1*st*. Considerable diminution of intolerance; cornea clearing. Salt water to eyes.

4*th*. Better; eyes improving; bowels costive. Liquor plumb. subacet. Continue salt water. ℞. Hydrarg. c. cret. gr. ii; pulv. rhei gr. iv three times a day. Discontinue quinine.

6*th*. Much better; free from headache or pain in eyes; bowels open; less injection and photophobia. Says his eyes always feel better and has less photophobia after use of salt water. Applied solut. nit. argent. gr. viij to ℥i, to the eyes.

9*th*. Sight improved; can now open his lids wide; conjunctiva of upper palpebræ not yet quite free from granulations. Applied dilute nitric acid to granulations. Continue salt water.

13*th*. Dilute nitric acid was applied to upper lids, on the 11th. Eyes have continued to improve; at present very little photophobia; sight improved. Left upper lid pale, with a few granulations; right injected. Applied diluted nitric acid to left upper lid, and scarified right.

16*th*. Granulations on left upper lid have been diminished by application of nitric acid. Right upper lid quite pale and tumefaction has disappeared since scarification. Liquor plumb. subacet. Continue salt water.

From this period the patient steadily convalesced. Liquor plumb. subacet. was applied every alternate day to his eyes, and after that period, every night, and the salt water once or twice a day.

30*th*. The redness and thickening and granulations of the conjunctiva have entirely gone; not the least photophobia; right cornea clear with the exception of a small speck below the centre; left cornea not perfectly clear and polished, but having something of the appearance of greenish glass. I advised the patient to remain in the house a month or six weeks to confirm his convalescence; but he considered himself as quite cured, and begged me to discharge him at the conclusion of my term of service. He was accordingly discharged.

Case III. *Chronic Conjunctivitis—Granular Lids—Opacity of Cornea.* James Murphy, ætat. 43, native of Ireland, admitted September 7th. This man's eyes had been inflamed for nearly a year before his admission. The treatment to which he was subjected after his entrance, consisted principally in the application of solid sulphate of copper to his palpebral conjunctiva, blistering behind the ears, and purgatives, under which he improved. When he came under my care on the 1st of October, his condition was as follows: Skin pale—relaxed; hair light; irides pale blue; pulse rather feeble; stature short, thin; constitution apparently not robust; eyes feel very sore and uneasy; lachrymation; some photophobia; lids tumefied and puffy. *Right eye*—ocular conjunctiva slightly injected; palpebral conjunctiva very red, thickened, spongy, that of the upper lid granulated; granulations large, very vascular

and flabby; cornea slightly nebulous at the centre, remaining portion clear. *Left eye*—similar to right, except that the granulations are not so large, and cornea was nebulous to a greater extent. I scarified the conjunctiva of both upper lids; the right bled very freely, the left less so. A sufficient quantity of blood was obtained to color deeply a large basin of water.

October 5th. Eyes feel much better; granulations diminished. Ordered the following collyrium to be used warm. ℞. Corros. sub. gr. i; aq. puræ ℥vj.

7th. Eyes more injected; collyrium causes much irritation; bowels costive. Discontinue collyrium; scarified both upper lids; senna and salts.

9th. Left eye much improved, less injected; right eye also better. Applied solid nitrate of silver to both upper lids.

21st. Since last report, the lids have been once scarified; the solid nitrate of silver has been twice applied, and a few drops of a solution of this salt (one grain to the ounce) have been occasionally applied to the eye. To-day the eyes feel much easier; the thickening of the conjunctiva is diminishing; conjunctiva of the left upper lid is now pale and smooth, that of the right less red than it was, but still injected; bowels open, sleeps well. Applied solid sulphate of copper to both upper lids.

23d. Eyes free from uneasiness; intolerance diminished; lids less flabby. *Left eye*—conjunctiva of the upper lid almost free from granulations except near the outer margin of the tarsus. *Right eye*—less improved than left; still granulations on the conjunctiva of upper lid; conjunctiva of both palpebræ injected and flabby. Applied solid sulphate of copper over the conjunctiva of both lids of the right eye, and to the margin of the upper lid of the left eye.

November 16th. The treatment since the preceding date has consisted in the application to the left eye, every two or three days, of the solid sulphate of copper, and occasionally the nitrate of silver, when the former failed to keep down the granulations; and of the latter salt to the right eye. As a collyrium, he finds tepid water the most agreeable. Three days since he had a blister to the back of his neck. To-day his eyes are greatly improved, particularly the right one, the lids of which are now less puffy and vascular; cornea clearer; sight improved.

December 1st. Has had the solid nitrate of silver applied twice, and once the diluted nitric acid since last report. Has also used the solution of nitrate of silver (four grains to the ounce) as a collyrium; and has taken for a few days, sulphate of quinine and hydrarg. c. creta, one grain of the former to one and a half of the latter, four times daily; and latterly the quinine with carbonate of iron. He has also been occasionally purged. His eyes now appear better, conjunctiva less flaccid and more polished; opacity diminishing; two red vessels still on the left cornea. Guthrie's ointment applied to the eye; continue quinine and carbonate of iron.

10th. Guthrie's ointment has been applied but once, as it did not produce as much improvement as I anticipated, and the solution of nitrate of silver (eight grains to the ounce) was substituted. A fomentation of chamomile tea, with opium, has also been used, and yesterday diluted nitric acid was applied to the lids. To-day the eyes are less injected; photophobia diminished; conjunctiva less watery and flabby; portions of the conjunctiva palpebralis perfectly natural in appearance.

20th. Diluted nitric acid was applied on the 11th and 13th inst., since which period the applications have been salt water and a few drops of

liquor plumb. on the 16th and 18th, with ung. hyd. rub. to the tarsi at bed-time. These applications seemed to be productive of much benefit, especially the former; but three days since, without any well ascertainable cause, his eyes became more injected and watery, though the lids remained smooth. His pulse was also rather fuller. The tonics were discontinued two days since; and to-day some blood was drawn from his head by cups, which was followed by considerable diminution of injection and lachrymation. The liquor plumb. subacet. was employed every two or three days; a blister was kept open on his arm; and he was occasionally purged. Under this treatment he improved so rapidly, that I hoped to be able to discharge him cured by the end of the month. Three days, however, before this period, both eyes became irritated and injected, and he complained of the sensation of a foreign body in his eye. I found that this was caused by some inverted eyelashes. These were immediately extracted.

31*st*. The removal yesterday of the hairs afforded prompt relief. The injection of the eyes has much decreased, and also the lachrymation; both upper palpebræ are entirely free from granulations; conjunctiva smooth and pale. As there seemed to be a disposition in the ciliæ to grow irregularly, and the patient's eyes had been long affected, I feared a relapse might be induced from this cause, and he was transferred to the care of my successor. I learn that his right eye continued well, but that he subsequently had a slight relapse of inflammation in his left. Various remedies were employed, but none seemed to afford him so much relief as the salt water bath to the eyes, and the liquor plumb. subacet.]

CHAPTER IX.

GONORRHŒAL OPHTHALMIA.

THREE distinct forms of ophthalmic inflammation occur in conjunction with, or dependence on, gonorrhœa; namely, 1st. *Acute inflammation of the conjunctiva;* 2d. *Mild inflammation of that membrane;* and 3d. *Inflammation of the sclerotic coat*, sometimes extending to the iris.

SECTION I.

I. *Acute gonorrhœal inflammation of the conjunctiva; gonorrhœal ophthalmia; blepharophthalmia*, and *ophthalmia gonorrhoica vera* of BEER.

The name of this affection sufficiently indicates its nature. It is a violent inflammation of the mucous membrane of the eyeball and lids, attended with a profuse discharge of fluid, closely resembling in all its sensible characters that which issues from the inflamed urethra in gonorrhœa, and occurring in some kind of connection with that complaint. It is the most violent and rapidly destructive inflammation to which the eye is subject; and, fortunately, it is comparatively rare. It sometimes destroys the eye within a very short time; and the organ is often irreparably injured before the patient seeks for surgical relief, especially when the affection occurs in the lower classes.

Symptoms and progress of acute gonorrhœal ophthalmia.—This affec-

tion presents all the characters of purulent ophthalmia in their fullest development. There is the greatest degree of vascular congestion, the most intense and general external redness; excessive tumefaction of the conjunctiva; great chemosis, with corresponding swelling of the palpebræ; and profuse yellow discharge. In the first stage of the disease, which is short, the inflammation is confined to the conjunctiva, and is attended with soreness and stiffness, with the sensation of sand or dirt in the eye, and with more or less uneasiness on exposure to light or using the organ. The affection soon extends to the cornea with severe and agonizing pain in the globe, orbit, or head, augmented to intolerable suffering on exposure to light, and with febrile disturbance of the system of inflammatory character. The danger to the organ is now most serious and imminent; indeed, when the disease has thus advanced, from the mucous membrane to the globe itself, we can hardly expect by any kind of treatment, to avert entirely its destructive consequences. The violent inflammation, which causes the yellow puriform discharge from the mucous surface of the conjunctiva, produces effusion into the cellular texture connecting it to the surrounding parts. Hence the general swelling of the membrane, and that more considerable tumefaction on the front of the sclerotica, round the cornea, which is called chemosis. The latter is often so considerable, that the swelled conjunctiva overlaps the cornea all round, so as nearly to hide it. Similar effusion takes place into the cellular texture of the eyelids, enlarging them considerably, more particularly the upper, which hangs over and sometimes completely covers the lower. This palpebral swelling is sometimes œdematous, with the integuments but little redder than natural; in other instances it is firmer, with the skin, particularly of the upper eyelid, bright red. The latter state denotes more active inflammation, and greater danger to the organ. The chemosis, and the swelling of the lids, make it often difficult, and sometimes impossible to get a clear view of the cornea. Although it is desirable to do this, in reference to prognosis, when we first see the case, we should not persist in our efforts at the risk of augmenting the inflammaton, or the patient's sufferings. The œdema of the eyelids declines in the progress of the affection, and then one or both of them may become everted, the convex edge of the tarsal cartilage being pushed forwards by the swollen conjunctiva.

The chemosis and the tumefaction of the eyelids are analogous in their nature and mode of production to that swelling which takes place in the neighborhood of any active inflammation: they owe their origin to that interstitial deposition, which is a general attendant on such violent vascular disturbance. The effusion may be either fibrinous or serous, the tumefaction being firmer in the former, looser in the latter instance. Fibrine is effused under the highest inflammatory action, in a strong subject; serum, when the inflammation is less violent, and the constitution weaker.

That the chemosis should have been referred heretofore* to the deposition of venereal matter in the cells of the part, and that incisions should have been recommended for its evacuation, will not surprise us; but we could hardly have expected to find such a mode of accounting for the phenomenon adopted by Beer and Richter. The swelling of the chemosis, according to the former, arises from the effusion of gonorrhœal matter under the conjunctiva; he mentions the practice of making incisions for the discharge of this matter, and represents that from such incisions there flows out a purulent fluid, or a yellowish acrimonious ichor. He says that gonorrhœal matter is sometimes seen at the very beginning in the cham-

* Astruc, lib. iii. c. 3. Camerer, Dissert. de Ophthalmia Venereâ.

bers.* "Sometimes," says RICHTER,† "the conjunctiva swells up round the cornea, as in chemosis; this swelling depends entirely on an effusion of true gonorrhœal matter into the cellular texture and the conjunctiva, and the matter flows out on making incisions through that membrane. Sometimes gonorrhœal matter is found in the anterior chamber."

The inflamed membrane exhales at first a thin whitish mucus in small quantity; as the inflammation proceeds to its full development, the discharge becomes thicker, yellow, and abundant; the yellow tint and the quantity of the exhalation being in proportion to the violence of the inflammation. When the latter is at its height, the discharge closely resembles in its appearance, and in the stain communicated to linen, that which proceeds from the urethra in venereal gonorrhœa.

Although the pain is generally most severe, both in the eye and in the head, as in other instances where the dense and unyielding texture of the cornea is the seat of inflammation, and although patients often complain of burning pain, of tension as if the eye would burst, of deep-seated and intense agony, with extension of these distressing and almost intolerable sensations to the brow, forehead, and head generally, there are some instances in which little or no pain is experienced.

The symptoms of acute gonorrhœal ophthalmia are not equally violent through the whole course of the affection: it begins with swelling and increased redness of the conjunctiva, and some pain in the organ: then the puriform discharge takes place, with increased uneasiness; and lastly, the inflammation extends to the cornea, with great aggravation of suffering. Thus the course of the affection may be divided into three stages, of which the limits cannot be marked very accurately. In the first, there are vascular distension and swelling of the membrane, with swelling of the lids: the commencement of the second is marked by the occurrence of the puriform discharge, and that of the third by extension of the inflammation to the cornea. The duration of each of these varies in different instances according to the constitution and state of health of the individual, and, perhaps, still more according to the nature of the treatment adopted. This variety, however, is observed less in the first and second than in the third stage; the two former, and more particularly the first, usually passing off very rapidly. In one case, the second stage may be said to have begun in twenty-four hours from the first perception of uneasiness: the lids were red and swollen at that time, and there was thin puriform discharge. In thirty-six hours the swelling was so great, that the eye could not be seen, and there was profuse yellow discharge, while severe pain of the eye and head denoted clearly extension of the disease to the cornea. In another instance, the first stage occupied about thirty-six hours, and the second between three and four days. In a third, pain and weakness were first felt in the eye on the 1st of November, and on the 6th I found the cornea had sloughed.

Effects of the inflammation.—The immediate effects of the inflammation on the cornea are sloughing, suppuration, ulceration, and interstitial deposition; while the consequences, to which these changes lead more remotely, are, escape of the humors and collapse of the globe, obliteration of the anterior chamber and flattening of the front of the eye, staphyloma, prolapsus iridis, obliteration of the pupil, corneal opacity, and anterior adhesion of the iris.

I have spoken of the cases in which the *cornea* is said to *burst* under purulent ophthalmia, see p. 248.

The cornea becomes dull and hazy before it sloughs, or indeed before

* Lehre der Augen-krankheiten, 1st edition, vol. i. p. 294, 295.
† Anfangs-grunde, vol. iii. p. 63.

undergoing any of the changes just enumerated. Its transparency and polish are completely destroyed, when it has sloughed; and it is converted into a dirty yellowish, or brownish opaque substance, which is immediately recognized as deprived of life. At first it looks like a portion of wetted leather; it is soon separated from the living parts, when it has a loose, soft, and ragged appearance. As the lens and capsule, which are exposed by this separation, are transparent, the patient sometimes recovers, for a short period, tolerably good vision. After the slough is detached, the chambers of the aqueous humor may be exposed by ulceration; the humors will then escape, the emptied coats will collapse, and the globe remain permanently shrunk in the socket. More commonly, although the whole cornea seems to slough, the entire thickness does not separate, and the anterior chamber is not exposed. The interior layer of the cornea, or the membrane of the aqueous humor is left, and is soon pushed forwards by the iris, which forms an irregular brownish, and dirty-looking protuberance on the front of the eye. As the inflammation declines, this protuberance recedes, until it disappears altogether, the front of the eye remaining flattened, and being formed by the iris, covered by a thin, smooth, and more or less opaque pellicle, through which the fibres of the iris may be partially seen, giving it a somewhat streaked appearance. Sometimes the iris is permanently protruded, and forms a dark, more or less smooth, protuberance, partially subdivided on the surface (*staphyloma racemosum*).

The separation of the slough when it has been partial, leaves an ulcerated surface, which is soon raised into a vesicular protuberance consisting of the membrane of the aqueous humor, with the iris, which has become adherent during the previous inflammation of the cornea (*prolapsus iridis*). This shrinks as the inflammation declines, and the regular figure of the cornea is restored; but the iridis remains adherent, and is covered only by a thin pellicle, which is partially opaque, while the boundary of the adhesion presents a deeper opacity in the cicatrix of the corneal laminæ. If a considerable portion, such as one-half or one-third of the cornea, should have perished, a permanent tumor is sometimes formed, consisting externally of an opaque covering, and internally of the adherent iris; its cavity, which is an extension of the anterior chamber, being filled with aqueous humor: this is termed *partial staphyloma*, and differs from prolapsus iridis, or complete staphyloma, only in size. I have seen it occur in both eyes of the same individual, with little injury to the sight, as the protrusion of the iris hardly interfered with the pupil.

Suppuration of the cornea may be general or partial: it is usually the former. The cornea first becomes white, and then assumes a yellow color. The effused substance is not a fluid, nor is it collected into a cavity; it is a thick, viscid matter deposited in the texture of the cornea. Ulceration takes place, and exposes an opaque yellow substance, which looks like ordinary matter, but it cannot be wiped off. The ulcerative process extends until this is removed. If the whole cornea should be destroyed, the humors may escape, and the globe will shrink. Or, the humors may remain, and the tumid conjunctiva sclerotica contract from the circumference towards the centre of the space left vacant by the cornea, until it completely fills that space, when the eye appears like a red fleshy mass, in which even the original situation of the cornea cannot be distinguished. The ulceration of the suppurated cornea may penetrate the anterior chamber at different parts at each of which the iris may protrude, the front of the organ remaining ultimately flattened.

When ulceration takes place without previous suppuration, it generally attacks the margin of the cornea, and extends rapidly through the laminæ.

so as to form a deep trench, seldom occupying less than one-third, often one-half, or two-thirds of the circumference, and sometimes extending round the whole circle. In the latter case, the portion insulated by the ulcerative process sloughs. On the sides of this ulcerated trench, the laminæ of the cornea may be often seen very distinctly. BEER says that they turn up like the leaves of a book, which has been much read. If the ulceration should not occupy more than two-thirds of the margin, the vascular supply of the cornea will still be carried on, and the mischief may be repaired. As the margin of the cornea is covered by the swollen conjunctiva, these ulcers are at first concealed from view, and we do not know of their existence until the chemosis begins to subside. When the ulcer has gone through the corneal laminæ, the membrane of the aqueous humor may rise as a transparent vesicle in the cavity (*ceratocele, hernia corneæ*), or it may be pushed forwards by a protruding portion of the iris. The ulcerative process may penetrate the anterior chamber, when the iris will either fall against the opening, or be pushed into it and block it up. If the ulcer, whether it should have arisen from the separation of a slough, or have occurred in the manner just described, should be spreading, the inflammation remaining unchecked, its surface is whitish, and ragged, or flocculent; or of a dirty yellowish cast, with surrounding haziness. When the inflammation subsides, it becomes transparent. The commencement of the restorative process is marked by the surface of the excavation assuming a light grayish tint, with a jelly-like appearance. A soft semi-opaque substance slowly fills up the breach, when the surface becomes smooth, and the regular figure of the cornea is restored. No secretion of pus is observed, either during the stage of ulceration or that of reparation; the latter process is slow, several days often elapsing without any sensible change in the size or appearance of the ulcer. The same process of contraction takes place here, as after the cicatrization of other ulcers, so that the size of the opaque cicatrix is less than that of the previous corneal ulcer; and as these ulcerations take place on the circumference of the part, one that has been of considerable size leaves a mark that is only observable on close inspection, while, where the ulceration has extended over the edge of the pupil, the cicatrix may leave that aperture quite unobstructed.

The existence of the ulcer makes no difference in the kind or degree of pain during the active period of the disease; no pain is felt when the inflammation is stopped, although a large ulcer may still exist.

When interstitial deposition takes place, the corneal laminæ are the seat of the mischief; and the opacity thus produced is of the dense kind called *leucoma* or *albugo*. It is usually accompanied with anterior adhesion of the iris (*synechia anterior*).

Contraction or obliteration of the pupil may occur in consequence of protrusion of the iris in partial staphyloma, or at the smaller apertures produced by ulceration; or of its adhesion to a leucomatous portion of the cornea.

When the cornea has been weakened by extensive sloughing, or ulceration, the iris having previously become adherent to it during the active period of the inflammation, the conditions necessary to the formation of total staphyloma exist; and this accordingly is one of the ultimate consequences of gonorrhœal ophthalmia.

Diagnosis.—Between the highest degree of purulent inflammation, and acute gonorrhœal ophthalmia, there is a near resemblance in the local symptoms. The discharge may be more abundant and thicker in the latter, in which the conjunctiva oculi is more swelled, while the swelling of the eyelids is more considerable in the former. The peculiar change of structure

in the palpebral conjunctiva, that is, the formation of phlyctenæ and of granular irregularities in the early stage, and the tedious and obstinate state of granulation in the chronic form, are an especial character of the contagious ophthalmia; at least, I have not seen them in the gonorrhœal. The latter occurs in single instances, and is uncommon; the other affects great numbers of individuals who are living together. The one takes place in persons who have had, or still have gonorrhœa, the other in those free from such complaint, but who have been exposed to the contagion of purulent ophthalmia. That the discharge of gonorrhœal ophthalmia will affect the eye of a sound person if applied to it, is well known; but it certainly possesses no indirectly contagious property. In purulent ophthalmia, the lining of the palpebræ is first affected, and the disease extends to the mucous membrane of the globe. In a case of gonorrhœal ophthalmia, which I saw at the very outset, the complaint began at once in the conjunctiva oculi. The latter comes on suddenly with the utmost violence, and proceeds with the greatest rapidity, coming to an end in a few days, either by recovery, or more commonly by destruction of the organ. In the contagious disease there is a milder period at the beginning; the disease is in general less rapid and destructive; it goes off and returns again, and thus may last for months or years. In general, gonorrhœal ophthalmia attacks only one eye, while the purulent disease affects both.* The latter may, however, be confined to one eye, as is proved by the cases quoted at p. 250–1, while the gonorrhœal form of the disease often attacks the second eye, after a short interval. One eye only was affected in nine out of the fourteen cases, which I have recorded in my *Treatise on the Venereal Diseases of the Eye.* In this disease the cornea is frequently destroyed by sloughing, which does not take place in the contagious ophthalmia. The latter is characterized by the peculiar change of structure in the conjunctiva, and by frightful ectropia consequent on it.

Prognosis.—The violence of the inflammation, its rapid course, and the disorganization or changes of structure, which it quickly produces in the cornea, are attended, under all circumstances, with the greatest danger to sight, which, in a large proportion of these cases, is either lost, or seriously injured. Thus of the fourteen cases which I have related in my treatise, loss of vision took place in nine from sloughing, suppuration, or opacity of the cornea. In two of these one eye was lost, and the other recovered. Sight was restored in the other five, with partial opacity of the cornea, and anterior adhesion of the iris in three of the number. So short a period intervenes between the commencement and the full development of the complaint, that in many instances irreparable mischief is done to the eye before our assistance is required. If we see the complaint in the first or second stage, we may expect to arrest its progress by active treatment; but success does not invariably attend our efforts even under such favorable circumstances. Our prognosis will principally turn on the state of the cornea; if that should possess its natural clearness, the eye may be saved. If it should be hazy and dull, and more particularly if it should have assumed a white nebulous appearance, consequences more or less serious will inevitably ensue. Great swelling of the conjunctiva, more particularly great chemosis, profuse discharge of a yellow color, and bright redness of the swollen

* Dr. Vetch says, "there is not one case in a thousand in which one eye only becomes affected."—*Practical Treatise*, p. 195.

Walther observes that contagious ophthalmia almost always appears in both eyes together, but not in the same degree.—Lib. cit., p. 83.

Erle states that the contagious ophthalmia has not confined itself to one eye in any instance.—*Ueber den Bau*, &c., p. 215.

upper eyelid, are unfavorable circumstances, as indicating a high degree of inflammation. The changes, to which the cornea is liable, do not always destroy sight: their effect depends on their extent and situation. Sight may be restored after partial sloughing of the cornea; and extensive ulceration may occur in its circumference without injury to vision.

The inflammation is not equally violent in all cases; and, of course, the prognosis will be less serious in proportion to its comparative mildness.

When both eyes are attacked in succession, the disease is less severe in the second, which, therefore, is usually saved. Sometimes, however, the inflammation is equally violent and destructive in both, and total blindness ensues.

Causes.—In investigating this part of the subject, we have to inquire what is the nature of the connection between this inflammation of the eye and gonorrhœa? whether the former can be produced by the application of gonorrhœal matter to the organ? If so, whether an individual can infect himself? whether the application of matter from another source be necessary? or whether the infection may occur in both ways? Whether, on the other hand, gonorrhœal ophthalmia may be an example of that peculiar transference of diseased action, which is called metastasis? To some it may appear necessary to examine a previous question; viz., whether there is any connection at all between the inflammation of the urethra and that of the eye? For Mr. PEARSON* directly denies the existence of such a connection, on the ground that, in many thousand cases of gonorrhœa, he had not seen one instance of inflammation of the eye that could be ascribed to the gonorrhœa.

From this statement we can merely infer that Mr. PEARSON had not seen gonorrhœal ophthalmia, which is very strange, when we consider, as he informs us that many thousand cases of gonorrhœa had fallen under his notice. I may oppose to his negative testimony the positive experience of many competent observers, and the evidence of numerous facts which have come under my own observation.

Whether this dangerous ophthalmia can be produced by the application of gonorrhœal matter to the organ, is a more doubtful point, which the nature of the subject prevents us from settling in the only satisfactory way, that is, by direct experiment.

It is stated incidentally by BEER,† and in the same kind of way by SCARPA,‡ that, if gonorrhœal matter be applied to the eye, it excites only a slight degree of inflammation. These statements are not accompanied by any narratives of cases, or other detailed illustrations, so that we do not know on what kind of proof the assertions rest, nor how the application of the morbid secretion to the eye was ascertained.

Since infectious matter does not produce disease in the same individual, although it is capable of affecting others, analogy would lead us to infer that gonorrhœal discharge applied to the eye of the same person would not cause gonorrhœal ophthalmia. This conclusion is supported by the result of experiments made by Dr. VETCH.§ He took matter from the eyes of persons laboring under acute purulent ophthalmia, and applied it in each case to the urethra of the same individual; no disease was excited. But, when he applied the same matter to the urethra of a different individual, it produced a very virulent gonorrhœa. He infers from these experiments, that

* In a letter to Mr. BRIGGS, printed in his translation of SCARPA's Treatise, p. 164—166, note.

† Lehre, vol. i. § 540.

‡ Treatise, &c., 2d edit., p. 164.

§ Practical Treatise, p. 242.

gonorrhœal matter taken from the urethra and applied to the eye of the same individual would excite no inflammation of the eye. The inference is probable, but not necessary. Because the purulent secretion of the eye does not affect the urethra, we cannot conclude that the gonorrhœal secretion of the urethra will not affect the eye. These morbific influences are not in all instances reciprocal; inflammation of the urethra often causes inflammation of the testicle, but the latter seldom or never produces the first. Dr. VETCH further mentions, that an hospital assistant, named SMITH, applied gonorrhœal matter to his own eyes, with impunity. When we consider how this matter is diffused over the linen of patients, both male and female, how often the fingers must be smeared with it, and how inattentive to cleanliness the lower classes, are, we cannot help concluding that gonorrhœal discharge must be often applied to the eyes of the same individual; yet gonorrhœal ophthalmia is comparatively rare.

Although these various considerations would lead us to expect that gonorrhœal discharge would not affect the eyes of the same individual, we meet in practice with cases, from which there is every reason to draw the contrary conclusion. It is a well known popular remedy for sore eyes to wash them with one's own urine; and persons laboring under gonorrhœa are sometimes so thoughtless as to resort to this practice. Experience teaches us that this direct application of infectious matter is capable of producing, not such a slight inflammation as BEER and SCARPA speak of, but acute gonorrhœal ophthalmia in its most destructive form. This is fully proved by CASE IV. of my treatise,* where both eyes were lost, and CASE XIV.† in which the vision of one was destroyed. In CASE VIII.,‡ in which partial sloughing of one cornea occurred, the patient had used to his eyes a towel soiled with gonorrhœal discharge from his own urethra. Mr. WARDROP communicated to me two cases which occurred under his own observation. In one of them, that of a young gentleman laboring under gonorrhœa, who had inadvertently touched his eyes when his fingers were contaminated with the discharge, violent puriform ophthalmia occurred and ended in the suppuration and collapse of both eyeballs. A soldier, who had gonorrhœa, was advised to bathe his eyes in his own urine, as a remedy for a slight affection of the lids: purulent ophthalmia seized one eye, which suppurated and burst. ASTRUC§ saw a case in which both eyes became inflamed from this cause; but the affection does not seem to have been very severe. Another instance is detailed by Mr. FOOT;‖ the ophthalmia, which was of the most acute kind, ended in opacity of the cornea and loss of vision.

[We have met with several cases in which this disease was produced by the patient washing his eyes in his urine whilst laboring under gonorrhœa.]

Experience clearly proves, that we should have expected *à priori*, that gonorrhœal ophthalmia may be produced by the application of gonorrhœal matter from another individual. This cannot be a very frequent occurrence, for obvious reasons; and I have seen no instance of the kind. Mr. WARDROP has furnished me with two examples. An old lady went into the dressing-room of her son, who had gonorrhœa, and washed her face with a towel which he had been recently making use of. Purulent ophthalmia quickly supervened, and destroyed the eye in a few days. A washerwoman, who had been employed in cleansing foul linen, was seized in a few hours with puriform ophthalmia, which terminated in the

* Page 69. † Page 101. ‡ Page 85.
§ Vol. i. p. 295. ‖ Treatise on Lues Venerea, 1820, p. 98.

suppuration and collapse of both eyeballs. DELPECH* mentions the instance of a young and healthy woman, who washed her eyes with goulard-water and a sponge, which had been used by a young man affected with gonorrhœa. Violent ophthalmia came on, and quickly terminated in loss of the eye. Mr. BACOT† distinctly traced the origin of the disease to infection, by means of matter from another individual, in three instances, two of which were washerwomen.

In a great proportion, however, of these gonorrhœal ophthalmiæ, we cannot trace the disease of the eye to the application of infectious matter, either from the same or another individual. The eyes are said to suffer by metastasis; it is stated that the gonorrhœal discharge is suppressed, and that the inflammation of the eyes occurs in consequence of that suppression. Such is the representation of RICHTER,‡ SCARPA,§ and BEER,‖ who accordingly consider the restoration of the discharge from the urethra a principal indication in the treatment of the disease. In none of the cases, which have come under my own observation, has the urethral discharge been stopped; although it has generally been lessened, it has continued in some with little diminution.¶ If, therefore, the notion of metastasis includes the cessation of disease in its original seat, gonorrhœal ophthalmia cannot, according to my experience, be deemed metastatic in any cases. On the other hand, the sudden stoppage of gonorrhœa, when effected by surgical treatment, is not followed by inflammation of the eyes. Since, then, gonorrhœal ophthalmia may occur, while the discharge from the urethra continues, and since it does not take place when that discharge is stopped, we cannot admit that the affection of the eye owes its origin to the cessation of disease in the urethra.

I am inclined to refer its occurrence to the state of the constitution, without being able to point out in what that state consists; and to regard it as a pathological phenomenon analogous to those successive attacks of different parts which are observed in gout and rheumatism. The two other forms of ophthalmic inflammation, which take place in conjunction with gonorrhœa, show themselves only in rheumatic subjects, and generally in connection with other arthritic sufferings; and the difference between one of these and the affection now under consideration is only in degree. This view of the subject may throw some light on the circumstance that, though direct infection operates equally on the eyes of both sexes, the gonorrhœal ophthalmia, said to originate in metastasis, seems to be confined to the male. I have never seen it in the female; and BEER, in the passage last quoted, says, that he has observed it only in young, robust, and plethoric men. The state of constitution, whether hereditary or acquired, which leads to gout and similar affections, is much less common in women than in men; and will hardly be found at all among those young and previously healthy females, who are the principal subjects of gonorrhœa. Again, the morbid influences, which are experienced and exerted by the male urethra, are different from those of the vagina.

* Chirurgie Clinique, t. i. p. 318.

† Treatise on Syphilis, p. 132.

‡ Anfangs-gründe, vol. iii. § 57.

§ Treatise, &c., p. 162, 63.

‖ Lehre, vol. i. § 533. "In all the instances," says BEER, "which I have seen, this ophthalmia has occurred in young, plethoric, robust, and truly athletic men; and it has always taken place in a very short time, generally in a few hours, after the suppression of gonorrhœal discharge from the urethra."

¶ DELPECH gives nearly a similar statement. "Il est bien reconnu que l'écoulement ne cesse pas toujours en pareil cas; que quelquefois, et même assez souvent, il subsiste dans toute sa force."—Chirurgie Clinique, vol. i. p. 319.

[Our experience is to the same effect. We have seen the discharge from the urethra continue most profuse during the greatest violence of the ophthalmia.]

Treatment.—The antiphlogistic plan, and particularly the general and local abstraction of blood, have been carried to their utmost extent; sometimes with complete, in other instances with only partial success. In many cases, the result must be unfavorable whatever treatment is adopted, because, from the rapidity and violence of the disorder, irreparable mischief has been done before our assistance is required. Of six cases seen at an early period, and treated by extensive depletion, loss of the eye occurred in one only;* these persons were not seriously weakened by the measures adopted for them.

It has been represented that the complaint may be stopped in its outset by applying strong astringents or escharotics to the eye; such as a ten-grain solution or the ointment of lunar caustic; (see pages 219 and 266.) Destructive or injurious consequences have so frequently resulted under the usual management of the disease, that the local measures just mentioned ought to be adopted in any favorable case; that is, where the affection has not extended beyond the conjunctiva. Blood-letting might precede or accompany the topical application. The propriety of this treatment is more questionable, if the cornea has begun to suffer; but the usual results of such cases are so unfavorable, that they could hardly be aggravated by the plan now proposed, which, therefore, deserves trial in a doubtful case.

For reasons already stated I should use the solution in preference to the ointment of lunar caustic; and I should not employ it at first of greater strength than four grains to the ounce. Even in this milder form I have seen it cause so much excitement, with increased redness, discharge, and pain, that the patients and myself have agreed in regarding it as injurious.

[The solution of the nitrate of silver, of the strength recommended by Mr. Lawrence, our experience leads us to believe to be entirely too feeble. The necessity for the most prompt, decisive, and active treatment, in severe cases of this disease, is imperious, and the only application we have found equal to the emergency, is the solid nitrate of silver, or a very strong solution of this salt. The lids being everted, a small cylinder of the nitrate of silver should be freely passed over the whole surface of the swollen conjunctiva, and then the parts freely washed with tepid water, before the lids are returned. After the tumefaction and other primary effects of this application subside, a solution of ℈j to ℈ij of the same salt to an ounce of water should be daily dropped on the eye, the strength of the solution to be diminished as the puriform discharge decreases.

In all cases where the general condition of the patient will admit of it, a copious bleeding should be practised previous to the local application, and general or local depletion, with a general antiphlogistic course should be afterwards employed concomitantly with the local remedies. Opium, especially in the form of Dover's powder given at night, will conduce much to alleviate the sufferings of the patient and also to ameliorate the disease.

In the advanced stages, and perhaps in some cases from the commencement, tonics are required. The infusion of Cascarilla, and Quinine are those we have usually employed.]

I have seen mercury employed in these cases without any advantage.

I can place no reliance on the means advised by Richter, Beer, and Scarpa, for reproducing the urethral discharge, which has not been suppressed in the cases under my observation.

If the antiphlogistic treatment be preferred, it must be pursued according to the principles laid down under the head of purulent ophthalmia. Blood

* Treatise on the Venereal Disease of the Eye, p. 46.

must be taken from the arm largely, and perhaps a repetition of the venesection may be necessary. For the slighter symptoms which may remain after the inflammatory action has been subdued, local bleeding will suffice. The more vigorous depletion is recommended where the inflammation is fully developed, without the cornea being yet affected, or where the condition of the cornea may be doubtful; that is, where we may entertain the expectation of saving the organ from injurious change; and where the patient is young and strong, with a good constitution and unbroken health. Under the opposite circumstances of a weak constitution and bad health, where the powers of the system are impaired by the various depressing influences, general abstraction of blood would be out of the question; and it may be necessary to proceed cautiously even with local bleeding.

If sloughing or suppuration should have already occurred, it will be of no use to pursue this active treatment, although more moderate depletion may still be necessary. General sloughing, or general suppuration of the cornea, is usually attended by diminution of the inflammation, and cessation of pain, or at least comparative ease; the loss of blood therefore is no longer required for the relief of suffering; and it would be without an object, as vision is irreparably destroyed. On the contrary, a tonic and restorative plan, both in medicine and diet, may be advisable.

But inflammation may continue with undiminished violence after the occurrence of partial sloughing; and active depletion may still be necessary, both to limit the extent of the mischief, and to favor the process of separation and restoration. In two cases,* free depletion, both general and local, was employed after the cornea had suffered partially in this way; and the treatment was completely successful in preserving sight. In a third, where one cornea had sloughed entirely, and the other eye was actively inflamed, the venesection and local bleeding employed on account of the latter had no prejudicial effect on the former.

Experience does not warrant us in ascribing much efficacy to blisters: they are only to be regarded as an auxiliary measure, and may be resorted to after antiphlogistic means.

The ordinary local applications are only to be considered as means of lessening suffering, and thus contributing to the patient's comfort; not as having the power of checking this violent disorder. They possess in fact so little decided efficacy, that some patients find the warm most beneficial, others cold. The latter seem to me the best, at least in the early period of the affection; and I should be unwilling to employ the former for the reasons mentioned at page 261. Of warm applications, none is better than the poppy fomentation, which may be rendered astringent by the addition of alum, in the proportion of two or three scruples to the pint. The eyelids and cheek must be frequently cleaned, particular care being taken to prevent accumulation of the discharge and incrustation on the edges of the former; for which purpose, it may be necessary sometimes to smear them with some mild unctuous substance.

Although we may succeed in checking the inflammation by the means just specified, its effects are not immediately removed; some time is required for the restoration of the membrane to its natural state. The swelling of the conjunctiva and of the eyelids is lessened, the membrane becomes paler with a somewhat flabby appearance, and the purulent discharge is still abundant. The patient is probably pale and weak. Under these circumstances it is advisable to change the treatment; to administer tonics internally, and to employ astringents locally. When the inflammatory symptoms

* Treatise on the Venereal Diseases of the Eye, p. 86 and 90.

have been quickly and completely subdued in a healthy and strong subject, the effects of the disturbance will pass off in a little time, as in other inflammations, without the aid of astringents and tonics. It will be sufficient to remove the restrictions in diet, and to regulate the bowels.

There is a marked change, both in the local and general symptoms, when sloughing, suppuration, or extensive ulceration has occurred. The swelling is lessened, the conjunctiva is paler, the discharge thinner, the upper eyelid less tumid, and perhaps of a dull red or somewhat livid color. The pulse is quick and feeble, the surface pale, the extremities cold; there is great general debility with sense of weakness. Such symptoms may occur in conjunction with an unfavorable state of the corneal ulceration, in which, although the swelling and redness of the conjunctiva are diminished, the ulcer spreads with a ragged surface, and irregular edge. This condition, both of the part and system, will take place more particularly in those of delicate constitution, and after the active means employed to combat the disease in its acute stage. Here the combined effect of good diet, tonic medicines, and other restorative influences, with local astringents, such as the solutions of alum and nitrate of silver, is obviously required.

Astringent lotions may be safely employed whenever the inflammation has been checked: although they may not accelerate, they will not under such circumstances materially retard recovery. Sometimes, however, they act as stimuli, and cause renewal of inflammation. This relapse is what we have principally to guard against: the best mode of averting it will be to avoid local excitement, and to regulate constitutional power either by mild antiphlogistic means, or by tonic and restorative measures, according to circumstances.

The best forms of astringent applications are the solution of alum, from two to ten grains to the ounce of water, the solution of the nitrate of silver, and the undiluted liquor plumbi diacetatis.

Local means of this kind, especially the nitrate of silver, have been thought advisable in ulcers of the cornea, particularly those accompanied with protrusion of the iris; and, in the latter case, the remedy has been used in substance. I have found recovery to take place most speedily where none of these means have been employed.

TREATMENT OF GONORRHŒAL OPHTHALMIA BY INCISION OF THE SCLEROTIC CONJUNCTIVA.

Mr. Tyrrell* has lately proposed to employ this proceeding in purulent ophthalmia, whether gonorrhœal, or of the ordinary kind, when chemosis is fully established, and imminent danger consequently exists of destructive changes in the cornea.

In acute ophthalmia, attended with chemosis, Scarpa recommended "circular excision of the projecting portion of the conjunctiva with curved scissors, at the part where the cornea and sclerotica unite; by means of which, not only the whole of the blood which is extravasated under the conjunctiva is discharged, and with immediate relief to the patient, but also that which, notwithstanding the abundant general evacuations of blood, might still greatly distend the vessels of this membrane."†

This mode of proceeding has been employed for some years by Mr. San-

* On a successful plan of arresting the Destruction of the transparent Cornea from acute purulent Inflammation of the Conjunctiva; Medico-Chirurgical Transactions; vol. xxi. A practical Work on Diseases of the Eye: vol. i. p. 72-95.

† Treatise; translated by Briggs, 2d edition, p. 148.

son* at the Hôtel Dieu, in cases of gonorrhœal ophthalmia. The eyelids being separated and everted, the tumid conjunctiva is seized with a pair of dissecting forceps, and removed with curved scissors. The whole of the swelled membrane should be excised, if possible: when the blood has ceased to flow, the everted surfaces of both lids are to be rubbed freely with lunar caustic.

In entertaining the notion that the swelling of the conjunctiva arises from the effusion of blood, SCARPA confounds chemosis with ecchymosis; an error which I have adverted to in another place. (See chap. xxii. § 1.)

It would be always difficult, in many cases impossible, to procure a sufficient exposure of the organ for the purpose of this circular excision; and I do not understand how complete eversion of the lids is to be accomplished, either alone, or in conjunction with exposure of the globe.

Mr. TYRRELL mentions that he had tried the method of depletion fully and fairly in many cases where the disease had advanced to the state of complete chemosis, and generally with unfavorable result. "I have tried also," he says, "locally, strong solution of nitrate of silver, and the undiluted solution of the diacetate of lead; but I have never seen the slighest advantage gained by such remedies, in the state of the disease in which complete chemosis existed: in the early stage, I grant that powerful astringents are sometimes of much service, as they are in the catarrhal affection; but I consider their employment to be more frequently prejudicial than beneficial, adding, as it were, fuel to the fire, and do not therefore recommend their use, because the first stage of this disease is always curable by simple means.†

The treatment by incisions was adopted by Mr. TYRRELL, from considering the mode in which the cornea is destroyed in purulent ophthalmia. He says "the principal supply of blood to this texture, is through the vessels of its conjunctival covering, as may be distinctly seen in some morbid conditions of these structures: for the larger vessels ramify in the conjunctiva layer, and send minute branches to the texture of the cornea. The occurrence of chemosis, or elevation of the conjunctiva covering the sclerotic, around the margin of the cornea, by rapid deposition in the sub-conjunctival cellular membrane first impedes, and then altogether interrupts the circulation in the corneal portion of the membrane; and this arises from the pressure, at the margin of the cornea, by the deposition, and from the tension and displacement of the membrane; for the attachment of the conjunctiva, over the junction of the cornea and sclerotic, is so firm, that it undergoes little or no change, whilst rapid and extensive alteration takes place in the membrane around, but its organization is so delicate, that the circulation is easily interrupted by the combined efforts of pressure and tension. The cornea does not mortify from an extension of inflammatory action to it, but solely from interruption to its supply of nutritious fluid."‡

"The remedy that suggested itself to me, under these circumstances, was free division of the chemosed part, so as to relieve the tension of the conjunctiva, and to allow of the escape of fluid from the subjacent cellular tissue, and thus get rid of a great deal of that which I conceived to operate mechanically, in obstructing the circulation of the cornea. My opinion of

* De l'Emploi de l'Excision, &c., dans l'Ophthalmie Blennorrhagique, par E. F. JULLIARD. Paris, 1835; quoted in the *London Medical Gazette*, vol. xxiii. p. 595.

† Practical Work, vol. i. p. 72. Mr. MIDDLEMORE gives an equally unfavorable opinion of this practice in the early stage of the disease, which he had tried in many instances, with every disposition to adopt the practice generally, if it had been found successful. Treatise, vol. i. p. 215.

‡ Ibid., p. 54.

the probable efficacy of this proceeding, was heightened by a knowledge of the excellent effect of a similar plan of treatment in cases which I consider somewhat analogous; viz., in cases of severe phlegmonous inflammation of cellular tissue, in other parts of the body; having often witnessed the arrest of gangrene and mortification, by making free incisions in such cases, through the skin and cellular membrane; which no doubt acts beneficially by relieving the tension of the former, and by partially including the latter, and thus taking off a pressure, which impedes or arrests the circulation."*

The attempts at relief by circular excision, were considered by Mr. Tyrrell more likely to be injurious than useful, by dividing totally or partially, the vessels passing to the corneal portion of the conjunctiva. The plan that he proposed was to make incisions through the sclerotic portion of the conjunctiva, and its subjacent cellular tissue, beginning at the margin of the cornea, and extending towards the edge of the orbit, but avoiding the transverse and perpendicular diameters of the globe, that the larger vessels passing to the cornea might not be injured. "The patient was seated in a low chair, and I stood behind him, so as to receive his head when inclined backwards, against the lower part of my chest; I then carefully, and with as little force as possible, elevated the superior palpebra with the point of the forefinger, (as in the operation of extracting a cataract,) having the finger covered with a piece of fine linen to prevent its slipping; one of my pupils depressed the lower lid: next with a fine cataract knife I divided the conjunctiva and the subjacent cellular membrane from the margin of the cornea, in a direction between the attachment of the recti muscles; making two incisions in each of these positions, or eight in all; in passing the knife, its point was made to penetrate the membrane, just over the junction of the cornea and sclerotic, and the back or blunt part of the instrument was opposed first to the cornea, and afterwards, as the incision was extended, to the sclerotic."†

Mr. Tyrrell states that his plan, in numerous trials, has proved more successful than he could have expected; that it prevents the necessity of severe general depletion, and saves the patient from the injurious and long continued effects of such treatment. He adds that it has been found equally successful by his colleagues and many others; and he says, "from my present experience in the plan of treatment, I feel satisfied that its adoption will certainly save the cornea, which has not already become affected, whatever may be the extent and violence of the surrounding conjunctival disease; that when the cornea has become hazy, but still retains its brilliancy, or property of reflecting light, the operation will prevent further mischief, and that the cornea will probably be entirely restored to its original integrity; at all events, in such a case submitted to this treatment, the cornea will suffer but triflingly; that when part of the cornea has lost vitality, which is indicated by its perfectly opaque state and dullness, or loss of reflective property, the division of the chemosis will prevent the extension of the mortification, and save that part of the cornea which may still retain life; that the effect of the operation is not promoted by any means which tend much to depress the general power, nor is it frustrated by a tolerably full action of the heart and arteries; that its influence is purely local, and its beneficial operation not likely to be interfered with, unless by two extremes, viz., great excess of arterial action, with fever; or extreme feebleness of vascular power. It is only, therefore, in cases in which such extremes exist, that I now deem it requisite to adopt other than simple and ordinary treatment generally, such as regulating the secretions,

* Ibid., p. 73. ‡ Ibid., p. 75.

and allowing a diet adapted to the power and age of the patient, excepting when the chemosis is unusually firm or fibrinous, when I give mercurials to check such deposit."*

The swelling of the ocular conjunctiva and of the palpebræ may make it difficult to obtain an exposure of the globe sufficient for making these incisions. It may be necessary to elevate the upper lid with the elevator of PELLIER. Perhaps we shall not be able to make so many incisions, nor to carry them far from the edge of the cornea. Under such circumstances, the plan may be pursued as far as the case will admit.

Warm fomentation should be employed immediately after the incisions, and may be continued for twenty-four hours or longer: the use of astringents may then be begun.

After the incisions, the case must be treated in other respects according to the general indications; by abstraction of blood generally, locally, or both in succession; by good diet, tonic and restorative means; or by simple regulation of the diet and alimentary canal. The exhibition of mercury may be useful here, as in other cases, after the disease has been checked by antiphlogistic means: it will not be necessary to continue it longer than two, three, or four days.

This proposal of Mr. TYRRELL presents two points for our consideration; the practical proceeding, and the pathological views by which it was suggested and is explained. In the former respect nothing can be more satisfactory than the testimony adduced by Mr. TYRRELL, from his own experience, and that of others, to the advantages resulting from these incisions. If these favorable results should be confirmed, as they no doubt will be by general experience, the treatment will constitute a valuable addition to our means of contending with a violent, rapidly destructive, and most alarming disorder.

Difference of opinion may be expected on the theoretical part of the subject, on which indeed a slight controversy has already occurred.† We have at present no direct proof that the death of the cornea in purulent ophthalmia is caused by strangulation of the conjunctiva, and consequent interruption of vascular supply; nor do we see how direct proof is to be attained.

If the cornea perishes, as the strangulated intestine does in hernia, a complete interruption of the circulation should be shown in the former, as in the latter case. In this respect the two instances seem widely different. We do not easily comprehend how the deposition of fibrine and the tension of the membrane, can act so equally and efficiently on the whole circumference of the cornea, as to produce an effect analogous to that of the stricture on a strangulated bowel.

That the cornea derives its principal supply of blood from the vessels of the conjunctiva, is rightly stated by Mr. TYRRELL. Yet the corneal vessels from this source may be distinguished into two orders, a superficial, and a more deeply seated one. Strangulation, if it exist at all, may be supposed to act on the former. The latter are derived from the trunks, situated between the conjunctiva and the sclerotica, and adhere closely to the latter membrane. They are not affected when the conjunctiva is pushed from side to side, or when a fold of the membrane is drawn up. They do not seem, properly speaking, to belong to the conjunctiva. What proof is there that these vessels, thus adhering to the sclerotica, are

* Ibid., p. 92.

† Remarks on Mr. TYRRELL's Paper on the Treatment of acute purulent Ophthalmia, by Mr. T. W. JONES. London Medical Gazette, vol. xxiii. p. 591. Reply by Mr. TYRRELL, ibid., p. 702. Further Remarks on Mr. TYRRELL's Rationale of his Operation in the purulent Ophthalmy, by Mr. JONES, ibid., p. 815.

involved in the chemosis, so as to partake in the strangulation which may affect the superficial order? Again, vessels enter the cornea on its posterior surface; and it may be presumed, on the analogy of all similar instances, that they communicate with those derived from the conjunctiva. No change in the state of that membrane could affect this source of supply.

If the circulation of the cornea be interrupted, the whole structure should perish, as the entire fold of constricted intestine does. The sloughing of the cornea is frequently partial; and the part not included in the mischief recovers its normal state.

Chemosis happens frequently in acute purulent ophthalmia; sloughing of the cornea is a comparatively rare occurrence. I have seen it in the adult, only in cases of gonorrhœal ophthalmia; nor do I find it mentioned as an effect of the common disease by those who have seen and treated it most extensively. The swelling and tension of the conjunctiva are apparently as considerable where sloughing of the cornea does not take place, as where it does.

Although the interception of vascular supply might account for sloughing of the cornea, it will not explain the other morbid changes which occur in conjunction with the complete chemosis. Under a tumefaction of the conjunctiva, apparently as considerable and complete as that which accompanies sloughing, we may have suppuration of the cornea, or interstitial deposition, clear proofs of increased vascular activity. Ulceration, which may occur under the like circumstances, is also an effect of inflammation generally; and it is thus seen on other occasions, in the cornea.

Mr. Middlemore* believes that sloughing of the cornea may proceed "either from an excessively inflamed state of that portion of the conjunctiva which covers and supports it, or from the strangulation of those vessels, which pass to that part and thence to the cornea." He adduces no proof on the latter point, which he speaks of in this as well as in other passages of his book, as if it were an ascertained matter; nor does he mention any circumstances by which the two kinds of cases may be distinguished. Mr. M. also strongly recommends free scarification of the chemosed conjunctiva, making very numerous incisions, and carrying them deeply, so as to let out the fluid effused into the subjacent tissue. "You would also freely scarify the conjunctiva; having selected for this purpose the instrument previously described, (a narrow lancet terminating in a rounded cutting edge,) draw it firmly and steadily along first the sclerotic, and afterwards the palpebral portions of the conjunctiva, at distances of half a line from each other, taking care to divide the texture of the conjunctiva at each sweep of the knife, so as to penetrate as far as the fluid effused into the sub-conjunctival cellular membrane."† The directions of the incisions is not mentioned.

SECTION II.—MILD GONORRHŒAL INFLAMMATION OF THE CONJUNCTIVA.

External redness of a bright scarlet tint, from distension of the superficial vessels of the globe, and increased mucous secretion, are the principal symptoms of this complaint. In slighter attacks the redness is not deep or general; the membrane is not swollen; there is little if any pain; and the increased secretion consists merely in a few streaks of whitish mucus lying between the eyelids and globe, or adhering to the margins of the for-

* Treatise on the Diseases of the Eye, vol. i. p. 61. † Ibid., vol. i. p. 207.

mer. The characters of the affection, when more severe, approach to those of acute purulent ophthalmia. The conjunctiva swells, becomes bright red throughout, and secretes a yellow mucus, which is discharged copiously from the eye. The complaint yields readily to antiphlogistic treatment, and is not attended with danger to the organ, if properly managed. In its more violent form, it requires active measures; and, if not checked by their timely adoption, it may cause ulceration or opacity of the cornea, with serious injury of sight.

This mild gonorrhœal inflammation of the conjunctiva may be safely and advantageously treated on the astringent plan, particularly by the solution of lunar caustic, the use of which may be preceded by antiphlogistic means in patients of full habit, or where we fear that the organ is in danger from probable extension of inflammation to the cornea.

SECTION III.—GONORRHŒAL INFLAMMATION OF THE EXTERNAL TUNICS AND IRIS.

The vascular trunks lying between the conjunctiva and sclerotica are distended, and the anterior portion of the latter membrane becomes pink or purplish red. As the conjunctiva participates but slightly in the affection, these changes are distinctly seen through it. There is increased lachrymal secretion, severe pain in the eye with sense of tension, intolerance of light with discharge of tears on the slightest exposure. The pain and intolerance are sometimes excessive, so that the smallest access of light cannot be borne.

The inflammation soon extends to the iris, which loses its brilliancy, assuming a dull and deeper hue. The pupil contracts, and lymph is effused from its margin. The external redness is increased, the vessels of the conjunctiva being more distended. The cornea at the same time becomes hazy, and vision is more or less impaired. Nebulous opacity and speck of the cornea are sometimes produced. As the inflammation subsides, the iris recovers its natural color, and vision is restored.

If the inflammation be considerable, it may cause adhesions of the pupil, with contraction of the aperture; and the adhesions thus formed are sometimes white as in arthritic iritis. Even permanent dimness of sight may be produced. Sometimes repeated attacks of the disease occur, each of which causes fresh adhesion, so that at last the pupils are fixed in their whole circumference and considerably contracted.

This affection must be treated by the abstraction of blood, general or local, and by other corresponding measures. If the inflammation be considerable, if it should occupy both eyes, and the patient should be young, robust, and plethoric, general bleeding will be required. Cupping and leeches will suffice in the milder instances. Warm local applications are generally the most agreeable to the patient's feelings: the poppy fomentation answers the purpose very well. Exclusion of light is absolutely necessary so long as the intolerance continues. When the inflammation is checked by these measures, blisters may be advantageously applied, and the cure may be completed by the administration of Plummer's pill once or twice a day, with mild aperients and a regulated diet. If the iris should be involved in the affection, mercury should be administered after depletion.

Colchicum is often used with advantage on account of the rheumatic symptoms which accompany this affection; and the eye may be expected to participate in the benefit, although the remedy cannot be depended on as a means of counteracting dangerous inflammation of the organ. The

same observation is applicable to residence at the sea-side and warm bathing, which are more advantageous to the lingering arthritic ailments, under which patients frequently suffer so long in these cases, than to the ophthalmic affection.

It is not uncommon for the same individual to experience at different times, in consequence of or in connection with gonorrhœa, both this inflammation of the external tunics and iris, and mild inflammation of the conjunctiva. Some cases recorded in my *Treatise on the Venereal Diseases of the Eye*,* exemplify this circumstance, which was also observed in two of the cases related by Sir Benjamin Brodie.†

Rheumatic inflammation of the joints accompanies both these forms of ophthalmic disease, when they take place in consequence either of gonorrhœa or of other discharge from the urethra. All the cases of these affections related in my treatise, except one, exemplify this combination. Sir B. Brodie has mentioned five cases of this description, in all of which the disease of the eyes was that which I have called mild gonorrhœal inflammation of the conjunctiva; while in two of them, although the conjunctiva had been affected on one occasion, the sclerotica and iris suffered on another.‡ Inflammation of the joints occurred in all.

Dr. Vetch§ relates the case of an officer, who had contracted gonorrhœa, of which the symptoms were well marked and violent, having been attended in the first instance with hernia humoralis. Rheumatic inflammation of the joints and inflammation of the external proper tunics of the eye followed on each occasion. After the second attack, Dr. Vetch found an "irregular and contracted pupil, with some opacity of the capsule of the lens, and adhesion between it and the iris; and on causing him to shut the sound eye, the vision of the left eye was found very much impaired."

Inflammation sometimes exists at the same time in the urethra, the eyes, and the joints; in other instances these parts are affected successively.

The affection of the eye last described is exactly the same as rheumatic inflammation of the sclerotica and iris occurring independently of gonorrhœa. Both this and the mild purulent inflammation of the conjunctiva are to be regarded as rheumatic affections of the organ excited by gonorrhœa; that is, they take place in individuals, in whom this constitutional disposition is shown by inflammation affecting either the synovial membranes or the fibrous structures of several joints. Although the organs seem at first view very dissimilar, there is an analogy of structure between the parts which suffer in the two instances; that is, between the synovial membranes and the conjunctiva, and between the ligaments and fibrous sheaths and the sclerotica. Hence we need not be surprised at finding that the eyes suffer under the influence of that unsound state of constitution, which leads to these affections of the joints. The structure originally affected, the lining of the urethra, is also a mucous membrane, which sometimes becomes inflamed, and pours out a puriform discharge, in gouty and rheumatic subjects, from internal causes.

That the essential source of this combination of morbid phenomena is peculiarity of constitution, may be inferred from the repetition of attacks, and the length of time for which some individuals are harassed by successive appearances of disease in various parts. In one patient rather severe purulent ophthalmia occurred in August, 1822, and a similar affection followed soon after; from that time to the present, six attacks of rheumatic iritis have taken

* Cases xvi., xix., and xxi.

† Pathological and Surgical Observations on Diseases of the Joints, p. 55 and 60.

‡ Pathological and Surgical Observations, p. 55—63.

§ Practical Treatise, &c., p. 161.

place. In another, discharge from the urethra without infection occurred four times; then inflammation of the foot; three years after, severe inflammation of the chambers of the aqueous humor; then gonorrhœa and mild purulent inflammation of the conjunctiva, followed by rheumatic inflammation of various joints; and afterwards severe rheumatic inflammation of the sclerotica and iris. In a third, violent gonorrhœa was followed by acute inflammation of the external tunics; a second gonorrhœa excited, first purulent ophthalmia, then acute inflammation of the external tunics, and subsequently rheumatic inflammation of various joints. Two years after, severe rheumatism was brought on by cold. I lately saw a gentleman with gonorrhœa, mild purulent inflammation of the eye, and rheumatic affection of the foot and back: it was the fourth attack he had experienced of the same combination of symptoms. One patient seen by Sir B. Brodie had undergone four attacks, all of which began with gonorrhœa; it was followed, first by purulent ophthalmia, and then by inflammation of the synovial membranes of several joints.* In another there had been eight attacks at various intervals during a period of seventeen years.†

In the *London Medical Gazette*‡ I have related a case of acute gonorrhœal ophthalmia with rheumatic affection of various joints; also, another instance of a gentleman, thirty-six years old, who has suffered repeatedly, during the last twenty years, from gonorrhœa, inflammation of the joints, and ophthalmia, excited and maintained by all kinds of irregularity. I saw him under the eighth or ninth attack of inflammation of the external tunics and iris. This had appeared on the cessation of discharge from the urethra following the use of copaiba. Both knee-joints were swollen, the right enormously, from effusion into the cavity; and had been so for a long time.§

As the train of diseases just described must be referred principally to peculiarity of constitution, gonorrhœal infection is not essential to their production; it is only to be regarded as one of the exciting causes, and perhaps the most frequent. There could be no doubt that gonorrhœa had been contracted in several cases of which I investigated the history. In another instance the patient was convinced that he had not received infection; and, according to his description, the usual characteristics of gonorrhœa virulenta had been wanting. Sir B. Brodie seems to have considered that the discharge from the urethra, in some of the instances which he had seen, was not caused by infection. In the case of the gentleman who had had eight attacks, inflammation of the urethra with discharge was the first symptom, and occurred before the age of twenty; he believed, however, that he had not been exposed to the risk of infection. In three of the attacks, purulent ophthalmia was the first symptom, being followed by discharge from the urethra and inflammation of the synovial membranes. In the other four attacks, inflammation of those membranes occurred without any previous disease of the eye or urethra.‖ In another case discharge from the urethra brought on by use of a bougie was the first symptom.¶

* Pathological and Surgical Observations, &c., p. 63. † P. 60.
‡ Vol xxiii. p. 509. § London Medical Gazette, vol. xxiii. p. 511.
‖ Pathological and Surgical Observations, &c., p. 60. ¶ Ibid. p. 63.

CHAPTER X.

ERYSIPELATOUS OPHTHALMIA; PUSTULAR OPHTHALMIA; STRUMOUS OR SCROFULOUS OPHTHALMIA.

SECTION I.—ERYSIPELATOUS OPHTHALMIA

The external inflammations of the eye exemplify the great variety in local and general symptoms, which diversities of organization, habits, age, sex, and all other contingent circumstances are capable of producing in the phenomena of disease; and they illustrate not less strongly the essential similarity of these apparently different processes, and of the means necessary for their treatment. Under the denomination of *erysipelatous ophthalmia*, the Germans have described a modification of conjunctival inflammation, which is occasionally seen, but which is neither sufficiently peculiar nor important to require any long consideration. The vascular congestion in the conjunctiva is not considerable, nor does the patient usually experience much inconvenience. There is watery effusion into the subjacent cellular tissue, making the membrane appear œdematous; this fluid gravitates towards the lower part of the globe, so that the conjunctiva projects a little at the edge of the lid, with a watery, or jelly-like appearance. The eye has altogether a watery look, which might justify the term *ophthalmia serosa* or *humida*. Sometimes the sclerotica participates, and there is greater redness, with more or less pain, and sensibility to light. In these severer cases, the palpebræ and surrounding parts exhibit some erysipelatous redness and swelling; there is pain in the head, with furred tongue, nausea, and general feverishness. The affection is seen in persons of, or after, middle age, and generally of an unhealthy constitution.—An active aperient, which may be preceded in some cases by an emetic, will remove the complaint in its slighter forms. When the excitement is more considerable, local bleeding and blistering may be required. Warm fomentations are the most agreeable application to the eye.

SECTION II.—PUSTULAR OPHTHALMIA.

Aphthous inflammation of the conjunctiva; Morgan.—This is an inflammation of the mucous membrane, constituting an intermediate link between catarrhal and strumous inflammation. The small elevations called pustules are occasionally seen in catarrhal inflammation of the membrane, and they occur frequently in strumous ophthalmia, but we designate by the epithet *pustular* an inflammation seated in the conjunctiva and confined to it, occurring in young subjects, and attended with the formation of pustules, but not exhibiting

Fig. 44.

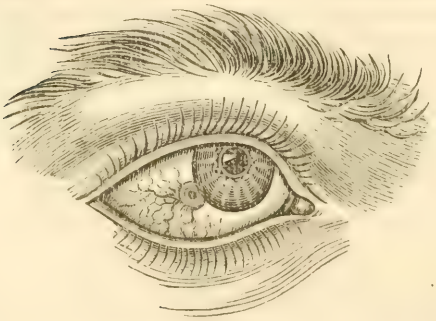

the other symptoms of catarrhal or strumous inflammation. Like strumous ophthalmia, it is an affection of young persons; we rarely see it after puberty. We observe a distended fasciculus of vessels upon the conjunctiva, running towards the cornea and terminating just at its margin in a small flattened, reddish or whitish elevation, called a *pustule* rather improperly, inasmuch as it does not contain pus. Sometimes the vessels extend over the boundary, and advance for a short distance on the cornea, the pustule then being formed on the latter part. The pustules contain at first a kind of watery fluid, and therefore they have been called *phlyctænæ* or *phlyctænulæ*. Sometimes we find only one, sometimes more, in different parts of the conjunctiva, and sometimes there is a great number of them, extending completely round the margin of the cornea. They vary in size, being sometimes small, at other times large; when only one pustule forms, it may be as large as the half of a pea, but in proportion to the number are they smaller. In this affection there is scarcely any pain and no intolerance of light, and were it not for the appearance of the pustule and the redness, the patient would hardly think there was anything the matter with the eye. Under a proper treatment it does not extend to the sclerotic coat; but if neglected, and especially if there be any scrofulous disposition, it may be more serious. If the complaint continues, and the inflammation proceeds, the pustules, whether situated over the sclerotica or on the cornea, ulcerate; the ulcer being rather disposed to spread. Under proper treatment they disperse without ulcerating. Mild aperients and saturnine lotion are generally sufficient. More acute cases may require leeches and blisters. If the complaint should be protracted, in a weak constitution, vegetable tonics or bitters may be required.

SECTION III.—SCROFULOUS OR STRUMOUS OPHTHALMIA.

Conjunctivitis scrofulosa; Phlyctenular ophthalmia; MACKENZIE.—This is an external inflammation of the eye, exhibiting modifications in its symptoms, progress, and consequences, derivable from peculiarities of constitution in the individuals whom it affects, and requiring corresponding modifications of treatment. We may therefore say that scrofulous ophthalmia is inflammation of the eye occurring in scrofulous subjects.

Scrofulous constitution.—All mankind are not formed after one pattern; if it had been so, the business of the physician and surgeon would have been much more simple than it is. There are diversities of natural organization, and analogous varieties in the forms of disease. Each individual has something peculiar in constitution, as well as in form and features. But the peculiarities, with which it is more important that we should become acquainted medically, are those which distinguish classes more or less numerous; and of these none is more common than the scrofulous.

The word *scrofula* is used in two senses; either to designate that assemblage of characters which mark a particular disease; or to denote the peculiarity of constitution, generally original or connate, from which such distinctive characters are derived. In the former sense, *scrofula* is equivalent to *scrofulous disease;* in the latter, to *scrofulous constitution.* We can point out certain external marks of scrofula; but we have not yet discovered the differences in the elementary composition of the frame, on which the characteristic peculiarities of scrofulous disease depend. The morbid disposition, however, is strongly marked: certain forms of disease are so easily excited, and return so readily, that it is almost impossible to keep them off. The absorbent glands, and some other organs of glandular

structure, the mucous membranes and skin, the lungs, bones, and joints, are the parts most liable to scrofula. Of the membranes, such as are exposed to the external air suffer most; for instance, those of the eyes, nose, and lungs.

Two kinds of constitution, differing considerably in some respects, are observed in persons called scrofulous. In one there is a pale and bloated countenance, a swelling of the upper lip and septum of the nose, and a tumid abdomen. The mucous membrane of the stomach and bowels is easily disordered by errors of diet, or by trifling causes, which would have little or no effect on other persons. When these important organs are disturbed, the nutrition of the entire body is more or less impaired. There is a languid state of circulation, so that the skin is pale and rough, and the extremities are cold; the muscular flesh is loose and flabby; and there is a kind of torpor in all the functions, bodily and mental. In the other set of subjects the integuments are thin, and the ramifications of the cutaneous veins are distinctly seen; there is an almost unnatural color in the cheeks. The circulation is rapid, the nervous system irritable, and both are easily excited. The various functions of body and mind are performed quickly. A premature development of intellect is often observed in such children, and they are affected powerfully by all external influences. We cannot suppose that the phenomena and treatment of disease will be the same in the two kinds of constitution just described, though the term scrofulous is used in both instances.

Exciting causes of scrofula.—Of these, cold is the most powerful, especially when combined with moisture. Hence scrofulous disease is most prevalent in countries with a moist and damp atmosphere, such as Great Britain, the north of Germany, and of France; but it is found elsewhere, and that in extensive prevalence. BEER states, that nine-tenths of the ophthalmic inflammations in children at Vienna are strumous.* BENEDICT considers that in Breslau the proportion is greater; he says 95 in 100.† The late Dr. GREGORY, of Edinburgh, used to say that there was not a single family in Scotland free from scrofula. Dr. JOHN THOMSON even represents that "it is rare to meet with an individual who has not at some period of life, experienced disease in some shape or other belonging to one of the several forms of scrofula."‡

The next in order of the direct causes is insufficient or unwholesome food, excess, or irregularity of diet. The effect of this cause is aggravated by sedentary habits, neglect of exercise, and residence in an impure atmosphere. Parents are often over anxious that children should begin their studies, that they should employ themselves in acquiring learning and accomplishments. Thus young persons are compelled to devote to sedentary pursuits many hours which they would otherwise occupy, and probably with greater advantage to mind as well as body, in active exercises.

The combined action of several direct causes, such as insufficient and unwholesome food, deficient clothing, the want of domestic comforts generally, sedentary occupations, the impure atmosphere of crowded dwellings in the confined parts of large cities, is capable of producing in those originally

* Lehre, vol. i. p. 588, note. He adds, that there are few families in Vienna, in which some of the children do not exhibit the scrofulous diathesis.

† "Of one hundred cases of ophthalmia in children, ninety-five or more are scrofulous."—Handbuch, vol. ii. p. 165. He assigns as reasons for this great prevalence of scrofula, the marshiness of the ground on which Breslau stands, the narrowness and filthiness of the streets, and the use by the poorer families of unwholesome food, such as dumplings, potatoes, black bread, and bad beer.

‡ Lectures on Inflammation, p. 163.

healthy, a state of constitution hardly distinguishable from the scrofulous, as we frequently see in the poor inhabitants of towns. This acquired morbid disposition is marked by disordered digestive organs, perhaps by a tumid belly, by pallid and unhealthy skin, cold extremities, and flaccidity of muscle; that is, by the same characters which belong to congenital scrofula.

The liability to scrofula does not extend equally through the whole of life. Disease of this character generally, and strumous ophthalmia in particular, are not seen in infants at the breast, which, being kept warm, and having a supply of wholesome food prepared by nature, escape the two great exciting causes. They prevail, however, extensively from the end of suckling to the age of puberty, in which period the processes of nutrition and growth are going on actively, and easily disturbed by the circumstances already alluded to. Strumous ophthalmia is seldom seen after puberty; but other forms of ophthalmic inflammation are often found more obstinate in persons of scrofulous constitution.

Strumous individuals are liable to inflammations of the lids, which take on the form of induration and thickening, or of hordeolum. The lachrymal sac and nasal duct also frequently suffer in such habits. These subjects I shall not advert to at the present, meaning to describe an external inflammation of the eye, originally seated in the conjunctiva, often affecting the sclerotic coat and cornea, seldom going deeper, but occasionally extending even to the iris.

Symptoms and course.—The external redness, which is often inconsiderable, and sometimes more apparent in the lining of the lids than in the eye, is partial in the latter situation. Particular vessels, or fasciculi of vessels, are distended on the surface of the membrane, run towards the cornea, and extend over its margin, or stop short at the boundary between it and the sclerotica. Where these fasciculi terminate, we observe the small elevations, called pustules or phlyctænæ. These, which may have a whitish appearance, or contain a little clear or yellowish fluid, may be single, or in greater number, situated on the cornea or sclerotica, or (which is most frequent) on the boundary between them. The occurrence of these elevations, which is characteristic, though not belonging exclusively to the present affection, has led Mr. Mackenzie to regard strumous ophthalmia as "an eruptive disease, affecting the conjunctiva, not as a mucous membrane, but as a continuation of the skin over the eye;" (p. 382,) and to call it *phlyctenular ophthalmia.* These phlyctænæ, however, although generally present, are not a constant symptom.

The access of light to the eye is painful, and the uneasiness produced by this cause is carried to an extreme degree, so as to constitute a distinguishing symptom of the complaint. The head is always held down in strumous ophthalmia to avoid the light. The lids are spasmodically closed, and a powerful contraction of the orbicularis palpebrarum offers an effectual obstacle to any attempt at opening them. If they are forced open, the cornea is turned up under the edge of the orbit, away from the light. The spasmodic action of the orbicularis, excited by exposure to light, causes actual pressure on the eye, and makes the child scream with pain. This action of the muscle makes the lids look as if they were swollen, but they are not so. The child makes every effort to protect the organ from the painful impression of light, contracts the brows, throws the integuments between them into wrinkles, draws down the skin of the forehead, elevates the lips and alæ of the nose, and in short puts into action all the muscles of the face to protect the suffering organ. Hence arises a peculiar and characteristic physiognomy of the disease, so that we can easily determine its nature on

the first sight of the patient. The painful impression of light upon the organ, in severe cases, is such, that the child seeks the very darkest corner of the room, to escape from the light, and if in bed, it will turn the face against the pillow, or hide it under the clothes, to accomplish the same purpose. For the same reason, if brought into the light, it presses the hand against the eyes and holds the head down; great irritation, redness, and eruption being often produced upon the forehead and nose by this cause. This position of the head produces determination of blood to the affected parts, aggravating the disease in the eye. If the patient comes to the light, to have the eye examined, the head is held down involuntarily; if he raises it, the eyes are immediately closed; or, if opened for a moment, they are instantly shut again more firmly. The attempt to open them causes a working of the alæ nasi, the brows, cheeks, and upper lip.

The great sensibility of the retina (*photophobia scrofulosa*) is not the result of inflammation, nor is it in a direct proportion to the increased redness, being often excessive where the eye appears almost natural; indeed, redness is not essential to the disease. It is a sympathetic or functional affection. In such cases as I am now describing, there is no immediate disorder of the retina; the child will be able to open its eyes, and to see as well as if there was nothing the matter with them, towards dusk. It is a disordered sensibility of the retina, dependent on the state of the alimentary canal. This symptom need not excite any fear of injury to vision. If the inflammatory symptoms are active, with much external redness, there may be considerable pain; but under other circumstances the patients do not suffer much, so long as light is excluded.

There is a copious flow of tears when the affection begins; the external surface of the organ suffers great irritation; the lachrymal gland sympathizes with that irritation, so that when we attempt to examine the eye, a quantity of clear fluid, which seems hot to the patient, runs out from between the lids. When the eye is exposed to light, a copious discharge of these scalding tears takes place; the passage of them into the nose excites sneezing, often for several times in succession. These irritation tears produce redness of the lids, and excoriate the palpebræ and face. They cause itching and soreness in the parts over which they flow, and aggravate the original complaint; the child rubs and scratches the lids and face, which become red, sore, and pimply. Small yellow pustules form on this inflamed skin, and produce a discharge which incrusts. The affection extends on the forehead, temples, and face, the pustules and incrustations increasing; in its worst form it is called *crusta*, or *porrigo larvalis*, from its coating the face like a mask. The term *porrigo* is inappropriate; the disease not resembling that pustular inflammation of the hairy scalp, but presenting all the characters of impetigo. An eruption of this kind, commencing in the lids and spreading over the face and head, will sometimes extend over the body.

The affection of the eyes is accompanied by disorder of the stomach and bowels. There is costiveness, with white or furred tongue; often fetid breath, distended abdomen, morbid appetite, grinding of the teeth during sleep. The head is hot in the beginning; sometimes there is also heat of skin, especially at night, with restlessness; but, in the progress of the complaint, the surface becomes pallid, and feels dry and harsh.

The edges of the lids are often red, swollen, and painful. The mucous membrane of the nose is frequently affected; there is an acrid secretion with excoriation of the nostrils, with swelling and redness of the alæ nasi, and often of the upper lip. The ears are red and sore, and excoriated behind; and the absorbent glands of the neck are frequently swelled.

The symptoms are worse during the day; there is a remission when the sun has descended below the horizon. Children, who have hid themselves in the dark all day, recover their activity at night and open their eyes without pain.*

Generally both eyes are affected, though not in an equal degree. The disease may begin in one, and pass to the other; or they may suffer alternately.

The inflammation of the eye may suddenly get better, and will return as suddenly. There are often repeated attacks at longer or shorter intervals, and slight exciting causes will renew disorder where the disposition is strong. In this way the affection lasts for months or years, and it is difficult to say when the patient is permanently recovered. The affection of the eye often alternates with other symptoms; the ears become worse, and the eyes get better, or *vice versa.*

Effects.—Scrofulous inflammation of the eye often produces serious changes, particularly in the cornea; and this may happen, although external redness does not exist in a great degree. We are accustomed to measure the violence of inflammation and to judge of its probable consequences, in other forms of external ophthalmia, by the extent of redness; but in strumous inflammation, the progress of the complaint is insidious, and we may have changes of structure produced in the cornea, when the visible symptoms are not alarming. The elevations of the conjunctiva previously mentioned under the names of pustule and phlyctæna may subside, leaving a thin opacity, which gradually disappears. Sometimes there are a considerable thickening and elevation of the corneal conjunctiva of a white color, with a fasciculus of red vessels passing to it: this leaves an opacity, which becomes diminished, but does not disappear. The pustules and phlyctænæ more commonly ulcerate. The ulcers, which are irregular in figure, and have a rather ragged edge, may either extend superficially, or make their way into the corneal substance; in the latter case, they may penetrate into the anterior chamber, and thus lead to prolapsus iridis.

The vessels, which pass from the conjunctiva over the cornea, instead of forming pustules, may extend latterly, and unite by their ramifications, the texture of the corneal conjunctiva becoming at the same time thickened, and more or less opaque. These changes may go to the extent of making the whole corneal covering thick and vascular (*pannus*).

There is often general dullness of the cornea from interstitial deposition; this may be accompanied by enlargement of the proper corneal vessels, giving to the part a red color. This discoloration is sometimes of a dull brownish red tint, and apparently caused by interstitial effusion of blood.†

In such a great and serious affection of the cornea, the iris will occasionally become adherent to it; and as the texture of the cornea is weakened, it may yield to the pressure from within, and be enlarged into the external protuberance called *staphyloma.*

These are the changes effected in the external parts of the eye by strumous inflammation; and the alterations of structure are generally limited to the exterior of the organ. Occasionally the effects of strumous inflammation extend to the sclerotic coat and iris, and even to the parts seated behind them. We have seldom an opportunity of observing the first stage of this iritis, on account of the changes going on in the cornea. When scrofulous ophthalmia has existed a long time, or when the patient has had repeated

* [We have not found this to occur in all cases. Children, sometimes, will not raise their heads from their pillow, even at night.]

† See the work of Dr. R. Froriep next quoted, fig. 1 and 2.

and severe attacks, the sclerotica and the more deeply seated parts may be so much changed in structure, that the form of the eye may be altered; the external coat may yield to the pressure of the contained parts. A greater secretion of the humors taking place, the eyeball gradually enlarges, and hydrophthalmia is produced. The sclerotica may give way partially to the pressure from within, when staphyloma scleroticæ takes place. Sometimes there is a general bulging of the sclerotica round the cornea, apparently from morbid enlargement of the corpus ciliare.*

Diagnosis.—Strumous ophthalmia is distinguished by the characters I have mentioned; by the intolerance of light combined with trifling external redness and copious lachrymal secretion, and by the pustular elevations of the conjunctiva. These symptoms frequently co-existing with strumous inflammation in the lips, the nostrils, behind the ears, and in glandular structures in other parts of the body, form altogether so well marked an affection, that it can hardly be confounded with others.

Prognosis.—The prognosis is favorable so long as the cornea remains clear. It is still favorable if the cornea should be opaque, provided the opacity be only superficial, or if it appear to be owing to deposition between the laminæ of the cornea; for we generally succeed in removing it by suitable treatment. Ulceration leaves behind a permanent opacity, which seriously injures vision when it is opposite the pupil. Should it be attended with prolapsus iridis, the consequences are worse, but much depends on the position and extent of the protrusion. Vascularity of the cornea, even when considerable, will disappear when the inflammation is removed; but restoration of the natural smoothness and transparency can hardly be expected, if the change of structure should have attained the extent of pannus. If ulcers should have extended deeply, if the cornea should have become generally opaque, and if there should be also affection of the iris, or change of structure in the sclerotica, the prospect is most unfavorable.

In describing diseases, we find it necessary to select the instances in which the characters are best marked. We do not find them exactly as they are described in books and lectures; and they, who are only acquainted with them from such sources, discover when they have to examine the sick, that several morbid affections are not so clearly characterized as they expected. We give names to such forms of disease as are clearly marked; but we see many cases which do not come under our descriptions. There is an insensible gradation from one form to another, so that we cannot draw an accurate boundary between them. This is the case with strumous and common ophthalmia. If we find the nosologies imperfect, we must recollect that they are not the productions of nature, but the work of man.

A troublesome inflammation occurs in the eyes of children, which is referable to the state of the skin, stomach, and bowels, but does not present all the characters of the strumous affection just described. There is more external redness; not so much intolerance of light; nor so many marks of strumous disposition in the system.

In some instances of delicate strumous children, we have intolerance of light without any other symptom, and we find that this has sometimes received a distinct name, having been called *photophobia scrofulosa*, or scrofulous intolerance of light. Between this simple intolerance on one hand, and acute external inflammation with general and vivid redness on the other,

* This is called by Dr. R. Froriep, *staphyloma corporis ciliaris. Diss. Med. de Corneitide scrofulosa*, Jena, 1830, 4to. fig. 8. In the same work, the author has described and delineated the various changes which scrofulous inflammation may cause in the cornea and in the more deeply seated textures of the eye. The figures are also published in the *Chirurgische Kupfertafeln*, part 53.

there is every possible intermediate degree. In infants who are the subjects of *crusta lactea*, the eye suffers sometimes from the extension of the cutaneous affection. These various disorders may be considered, in point of pathology and treatment, as coming under the head of strumous ophthalmia.

Causes.—Exposure to cold and wet favors the occurrence of strumous affections generally, and not less so that of scrofulous ophthalmia. Hence children suffer much, especially when insufficiently clothed, from cold winds, and from sudden changes in the weather. The complaint may depend on disorder of the digestive organs, on an inactive state of the skin, or a sluggish condition of the uterine system. The disposition to strumous inflammation will be called into action by any circumstances which weaken the constitution; it occurs frequently after measles, small-pox,* hooping-cough, scarlet fever,† in short, after the operation of any causes which may have reduced constitutional power.

Treatment.—We must endeavor, in the first instance, to remove that unhealthy condition of the digestive organs and skin, which is so prominent a feature in the complaint, and consequently to invigorate the constitution. Unless these objects can be accomplished, means applied to the eye will be of little service. Hence the general treatment is more important than the local. The state of the alimentary canal must be attended to. The use of purgatives is generally necessary; and those of an active kind are often required, even in young children. We should begin by giving a dose of calomel with jalap or rhubarb, or calomel followed by the senna draught, or by castor oil; and it may be necessary to repeat these purgatives two or three times, so that the canal may be completely cleared from the accumulated load of ill-digested food and unhealthy secretions. The administration of two or three such doses often produces the greatest relief to the sufferings of the child. When this has been accomplished, a mild course of alterative and aperient medicines will be useful; such as calomel and rhubarb in small doses, every second or third day, calomel with antimony, or the hydrarg. c. creta with some gentle aperient. When the tongue is clear, and the motions of natural consistence and color, mercurial medicines are no longer necessary. Rhubarb, magnesia, sulphate of potash, senna, castor oil, and the compound decoction of aloes, are the best medicines for regulating the bowels; and these or some other aperients must be employed whenever they do not act naturally.

[For regulating the bowels, we have found no medicine so useful, as a combination of equal parts of rhubarb and prepared chalk. This should be given morning and evening, or only at night, in sufficient doses to produce

* Juengken represents vaccination as one of the most frequent causes of scrofulous ophthalmia. He considers that a certain degree of energy is required, in order to remove from the system the poison introduced by the inoculation:—"If the child is too weak or too young, some of the morbific matter remains behind, and calls into action the scrofulous diathesis. Hence the practice of vaccinating children as early as possible cannot be approved: for the greater number of those who are vaccinated in the first year, become affected afterwards with scrofulous ophthalmia."—Lehre von den Augen Krankheiten, p. 218.

† The disease described by Mr. Wardrop, in his "Account of the Exanthematous Ophthalmia, with Observations on its Treatment," contained in the Transactions of the Medico-Chirurgical Society of Edinburgh, vol ii., and that to which Mr. Christian has given the name of porriginous ophthalmia in his "Observations on a particular species of Ophthalmia, occurring in connection with Porrigo, and usually termed Scrofulous Ophthalmia," contained in the Glasgow Medical Journal, vol. i., do not seem to me to differ in any essential respect from strumous ophthalmia, nor to require separate notice. I will only observe, that Mr. Christian ascribes the occurrence of the ophthalmic affection in the cases to which he alludes, to infection of the eye by the discharge of the porriginous pustules conveyed by the fingers of the patient.

two alvinee vacuations daily. Milk of sulphur and cream of tartar form also an excellent combination which may be used in the same way as the preceding one.]

In the state of debility to which the young sufferers are frequently reduced by this painful and obstinate complaint, tonic medicines may be employed advantageously after the alimentary canal is cleared; of these bark is the best, and the sulphate of quinine the most efficacious form. Mr. Mackenzie has commended this remedy strongly, and I agree with him to the full extent of his statement. "After a trial of numerous and various internal remedies in this disease, I have found none so useful as the sulphate of quina. It exercises a remarkable power over the constitutional disorder which attends this ophthalmia, and thereby over the local complaint. The dose which I employ is generally a grain thrice a day, rubbed up with a little sugar; in very young children half a grain; and in adolescents or adults two grains." He adds, that its powers in all other forms "are insignificant in comparison to those of the sulphate of quina. In most instances, its effects are very remarkable; and, indeed, (although I have met with a few cases, which have appeared to resist its beneficial influence,) in most of the little patients, to whom I have administered it, it has acted like a charm; abating, commonly in a few days, the excessive intolerance of light and profuse epiphora, promoting the absorption of pustules, and hastening the cicatrization of ulcers of the cornea. The use of this medicine may be begun as soon as the stomach has been cleared by an emetic, and the bowels put to rights by repeated doses of calomel with rhubarb, or some other such purgative, unless the pulse is very quick, when small doses of tartar emetic will be preferable, or when an impetiginous eruption is observed on the surface of the body, in which case a course of purgatives ought to be adopted." Op. cit., p. 393, 394.

Steel may be given with advantage to pallid and languid patients. The carbonate of iron, the ferrum tartarisatum, the tinct. ferri ammon., and the vinum ferri are eligible forms.

[The best of the preparations of iron in these cases is the syrup of ioduret of iron prepared according to the following formula. Take of pure iodine one hundred grains; iron filings fifty grains; distilled water one ounce. Digest these for some time; filter and wash the ferruginous mass with a little distilled water; unite the fluids and add half an ounce of sugar; then evaporate down to one ounce. Four parts of this syrup contain one part of ioduret of iron. Two to six drops of this may be given three times a day according to the age of the child.

It is often very advantageous to give it in combination with the compound syrup of sarsaparilla.]

The dilute sulphuric acid is a good tonic for scrofulous subjects, and may be combined with the vinum ferri.

It is of great importance in these cases to regulate the diet, both in respect to the quantity and quality of food, and the number of meals. Errors are often committed on these points, not only by patients, but even by their medical attendants. The notion has been entertained that scrofula consists in debility; and hence the inference has been drawn, that it is to be remedied by the free use of animal food and fermented liquors, of tonic and stimulating medicines. These views seem to me altogether erroneous, and the practice is decidedly pernicious. Scrofulous subjects are weak in one sense; they are imperfectly organized, and they cannot do and bear many things which others can. External agents affect them more powerfully; their organs are more easily excited, and this is particularly the case with the alimentary canal. Can we, then, expect that they should bear a quantity

of meat, of stimulating liquors, and of tonics, that would surely disorder the stomach of a healthy and strong individual? The diet of the scrofulous, and indeed of young persons generally, should be nutritious, but not stimulating. The attempt to strengthen them by making the diet chiefly animal, will never succeed. The mixture of animal and vegetable food has been found by the experience of all ages and countries, to be the best suited to the human organization. I see no reason whatever for prohibiting scrofulous subjects from taking vegetables; a moderate portion of animal food may be allowed once a day; and the rest of the diet may consist of well-dressed vegetables, of milk, bread, and other farinaceous articles, of ripe fruit. Some of the more excitable scrofulous subjects cannot bear animal food daily; in such instances it may be allowed every second day. Fermented liquors, as wine or beer, may sometimes be allowed to children in small quantity, and for a short time; but they are not always admissible, even in the apparently weak subjects of struma, as they easily excite the circulation. The proper beverage for children, generally, is pure water. Many scrofulous subjects will not bear excitement either by food or medicine; tonics are injurious to them in all shapes. The quantity of food must be carefully attended to, especially where, in conjunction with disordered stomach and bowels, there is an unnatural appetite. Three or four meals may be taken daily, and nothing should be allowed in the intervals; particular care should be taken to keep off the unwholesome trash so frequently given to children by kind but injudicious friends.

When the skin is pallid, dry, and harsh, and its capillary circulation and secretions are imperfectly performed, we cannot expect an individual to be well—we cannot doubt that the restoration of this extensive surface to its proper state will materially conduce to the recovery of health and strength.

Under such circumstances, small doses of the hydrarg. c. creta may be given in conjunction with James's powder. Warm bathing is advantageous; where this cannot be accomplished, washing the body once daily with warm water, and rubbing it dry, may be substituted. Some salt may be added to the water; and its temperature may be gradually diminished till the cold or shower-bath can be borne. The skin should be well rubbed daily, more particularly after the bath.

Scrofulous subjects should be warmly clothed, especially in the colder part of the year. The attempt at hardening these weak beings by exposing them to cold and atmospherical vicissitudes, especially if they are lightly clad, is very dangerous. The animal powers, being naturally defective, cannot withstand these agencies. It is found, by experiments on animals, that the power of generating heat is less in young subjects than in adults, and it is less in proportion to the early age of the individual.

It is always desirable that scrofulous subjects should take exercise; and I would by no means confine them to the house, even in cold weather, but allow them to go out, protected by sufficient clothing. If children are left to themselves, they naturally engage in a variety of active sports, which sufficiently exercise their muscular system.

When scrofulous disease exists, the principal object should be to re-establish and secure health; education should be considered as a matter of secondary importance, especially in those points which afford sedentary occupation.

Residence in pure air is of great importance to the scrofulous, and they often recover from serious disease, merely by being removed from large towns to the country or the sea-side. The air of the coast during the milder months of the year is advantageous to such constitutions. But the glare of light from the water and the sand is offensive to the eyes, so long as the

intolerance continues; and a morbid sensibility, or, as it is called, weakness of the organ, often lasts after the other symptoms have been removed. A healthy inland situation is preferable to the coast under such circumstances. When, however, this particular source of inconvenience no longer exists, the air of the sea-side will be beneficial.

[We have seen surprisingly rapid recoveries from scrofulous ophthalmia, effected solely by a removal to the country or to the sea-side.]

Local treatment, and other measures required by the state of the organ.—In the early period of the complaint, especially in cases which approach to common inflammation, and are attended with considerable redness and pain, a white tongue, and hot skin; or at any time when such symptoms may supervene, abstraction of blood by leeches, and their repeated application, may be necessary. In a severe attack, about or soon after puberty, cupping on the temple might be advisable. It may be expedient to administer an active aperient before leeching. Afterwards tartar emetic may be employed, either alone, or in combination with calomel or sulphate of magnesia. This remedy, given so as to produce vomiting or nausea, may sometimes supersede the abstraction of blood. The intolerance of light is not an indication for the use or repetition of leeches. This symptom has sometimes been regarded as a sign of inflammation, and hence depletion has been carried to unnecessary and injurious lengths. It increases the irritability of the organ, and aggravates the local symptoms, which are lessened by tonics and good diet. Abstraction of blood should be avoided, as much as possible, in strumous ophthalmia; and it should not be carried beyond the amount just necessary to accomplish the temporary purpose.

Scarification has been recommended; but I have not practised it in these cases.

In the commencement of the affection, when the neighborhood of the organ and the head generally are hot, cold may be applied to the eye with advantage. But in most cases warm water or poppy fomentation is more comfortable to the patient's feelings. When the intolerance of light and spasm of the lids are considerable, they may be relieved by applying a bit of soft flannel wrung out of a strong decoction of poppies and chamomile-flowers, as warm as it can be borne.

The local employment of opium is resorted to when the last-mentioned symptoms are severe. The liquor opii sedativus of Mr. Battley, is an eligible form. A drachm of it may be added to an ounce of water, to be used tepid; a few drops may be allowed to pass between the lids. The steam of a mixture of tinct. opii ʒß, with mist. camphoræ ʒßvii, may be applied to the organ.

Dr. Seeds has recommended rubbing round the eye in various ophthalmiæ, a composition of spirit. ether. sulph. comp. and spirit. ammon. aromat. āā ℥j; spirit. vin. camph. ʒj.* The vinum opii has not been found of much service.

[Dr. Deval reports some cases of scrofulous ophthalmia with extreme photophobia, promptly relieved by a poultice of chervil (*anthriscus cerefolium*), to the eyes, or a saturated decoction of the plant employed as a wash.]

Benefit may be derived from local stimuli after the inflammatory symptoms have been removed, and the alimentary canal has been brought into a healthy state. The solution of lunar caustic, from one to four grains to the ounce, dropped between the lids is the best, and has great influence in diminishing the irritability of the eye, and promoting the cicatrization of ulcers.

* London Medical and Surgical Journal, vol. i., pp. 550 and 700.

Opinions are divided respecting the utility of these applications; some practitioners reject them altogether, as being more likely to be injurious than serviceable. I have seen strumous ophthalmia recover as favorably and speedily without as with them.

The red precipitate ointment may be usefully applied to the lids when their edges are red and swollen.

Counter-irritation is very useful in strumous ophthalmia in conjunction with, or rather after depletion, where that has been required, and together with the means necessary to remove disorder of the digestive organs, and improve the general powers of the system. It is, indeed, an imitation of what we observe in the natural course of the affection, where the inflammation of the eye will cease on the appearance of disease in some other quarter, or *vice versa*. We may apply blisters behind the ears or to the nape; but we must proceed cautiously, as they may cause excessive irritation in weak unhealthy subjects. They should not be left on longer than four, six, or eight hours; nor is it safe to keep up a discharge by irritating applications to the blistered surface. I have seen great mischief, and even fatal mortification, ensue from the neglect of these precautions. A safer mode of employing blister is to take a portion of cotton wick, or a few worsted threads, cover them with the lytta ointment, and place them, during the night, in the fold between the ear and the head. A decided but mild irritation is excited in this way; not requiring dressings.

I prefer tartar-emetic ointment, rubbed on the back and shoulders, to blistering, as a more manageable and effectual means of accomplishing the object. The ammoniacal liniment answers the purpose very well. An issue in the arm has an excellent effect, both in arresting the disease, and in preventing the relapses, which are so frequent and troublesome.

As a general plan of treatment, I find none more successful, after putting the alimentary canal in proper order, than the use of the tartar-emetic ointment, with the sulphate of quinine internally, tepid fomentation, and regulation of the bowels by means of rhubarb.

If disorganizing inflammation is going on in the cornea, or in the more deep-seated structures of the eye, we must resort to mercury, proceeding cautiously, so as not to depress the already feeble powers of these subjects. The *hydrarg. c. creta* may be employed in small doses, in combination with James's powder, or the pulv. ipecacuanhæ comp. Strengthening medicines, such as bark and steel, may be given at the same time, with good diet. When the general powers are thus supported, the mercurial remedy may, if necessary, be carried so far as to affect the mouth; this, however, may be accomplished by small and what may to some appear minute doses of the medicine. If it should exert an injurious action on the system, it must be given up, as the local mischief will be aggravated under such circumstances. Under the general treatment which I have recommended, the intolerance of light, and spasmodic closure of the lids, which cause so much suffering and annoyance in strumous ophthalmia, are soon alleviated. The use of belladonna has been strongly recommended as a remedy for these symptoms. The Baron Dupuytren says that he has employed the powder and extract with great advantage. Mr. Arnott, *London Medical Gazette*, vol. xxiv., p. 23, introduced between the lids a solution of the extract, twice a day, in a case of great obstinacy; in two days the eyes could be opened freely. The editor of the *Lancette Française*, June, 1839, quotes Mr. Arnott's case, and observes that belladonna, occupying the first rank among remedies capable of lowering the action of the brain (*remèdes hyposthénisans céphaliques*), is well suited to states of over-excitement in the retina (*sur-excitation de la rétine*); but that the remedy is more active, when ad-

ministered by the mouth. He gives half a grain of the freshly prepared powder of the leaves twice or oftener in the day, and says that the dose may be increased until dilatation of the pupil is produced, when the photophobia invariably disappears.

[We have employed with the same view the extract of cicuta, and have found it in some cases productive of the best effects.]

The treatment of the crusta lactea requires, in the inflammatory stage, aperients, and mild local applications; such as tepid ablution, spermaceti cerate, elder-flower ointment; afterwards, the oxyd of zinc, one drachm to one ounce of rose-water, will soon dry up the pustules. The incrustations present at first a formidable appearance; but the complaint is quite superficial, and leaves no marks behind. Apprehensions of ill consequences have sometimes been entertained from the sudden removal of such an eruption; and these apprehensions are not groundless. It would be imprudent to stop the crusta lactea suddenly in the inflammatory stage, even if we could accomplish it; but when the excitement of this period has been removed by suitable internal and external remedies, there is no danger in the use of mild astringents.

CHAPTER XI.

VARIOLOUS, MORBILLOUS, AND SCARLATINOUS OPHTHALMIA.

Analogies between the skin or common integuments of the body and the conjunctiva are observable in the natural structure of the parts, as well as in their common office of constituting the superficial covering of the frame. The conjunctiva of the negro has a dull, muddy hue; and it often displays a dark brown or black color round the cornea, which is gradually shaded off. The separation of the surface of the eye with the epidermis generally, when that covering is annually renewed in the serpent tribe and other reptiles, and the actual growth of hair from this membrane in the zemni, or mus typhlus, are further striking points of analogy. Hence we shall not be surprised at finding the conjunctiva participate in diseases of the skin, and at observing some of its morbid phenomena, which are only explicable when it is regarded as a part of the common integument.

The infantile eruption called *crusta lactea* extends from the face to the surface of the eye. The eyelids often suffer in venereal disease, as is more particularly explained in Chapter II. § 3. I have seen tubercles form on the conjunctiva oculi, and extend partially over the edge of the cornea in the tubercular elephantiasis. The analogy to the common integuments even shows itself as deep as the iris, the colors of which follow the same laws as those of the skin and hair: thus we have iritis accompanying some cutaneous affections. In no instance is the participation of the eye in diseases of the skin more strongly marked than in the contagious *exanthemata*, in all of which the eye suffers, sometimes very severely.

VARIOLOUS OPHTHALMIA.

Small-pox is very injurious to the organ of vision, affecting different parts of the apparatus, and in various ways. It causes inflammation of the lids, of the eye, and of the lachrymal sac during the active period of the erup-

tion; it produces an inflammation of the eye after the eruption has dried up; and it gives origin to chronic inflammation of the lids and of the nasal duct, and to strumous ophthalmia. Thus, from this single source of mischief arise active inflammations, which often destroy or impair sight, and chronic affections, which not only disfigure the individual, but continue more or less troublesome for many years.

Variolous pustules form on the external surface of the lids and on their ciliary margins. When they are numerous, as in bad cases, especially of confluent small-pox, they cause great swelling, and completely close the eyes. The oozing of matter and its incrustation, the agglutination of the palpebræ, and the confinement of the conjunctival and pustular secretions, irritate the eye, produce increased lachrymal discharge, and add to the sufferings of the patient. As the complaint declines the swelling subsides, the lids are opened, and the eye is found uninjured: thus we hear of persons being blind in small-pox for so many days, and then recovering their sight perfectly. They have been blind only as a person is who has a bandage tied over the eyes.

Although the globe may not have suffered, the lids are often greatly injured. The pustules on the ciliary margins partially destroyed the cilia, alter the form of the part, making it uneven, and leave behind red marks, which are permanent through life. Eyelids thus affected are liable to inflammation and excoriation from slight causes.

In addition to the general treatment, which the state of the patient may require, we should use such local means as may lessen irritation. We may evacuate the matter by pricking the pustules; we may carefully remove incrustations, after softening them with some mild unctuous applications; enjoin frequent ablution with tepid milk and water, and lessen inflammation by the application of soft rags moistened with cool or tepid washes.

It might be advantageous to adopt the proceeding recommended by M. Velpeau, for the purpose of checking the development of the variolous pustule; this consists in touching the eruption in its early stage with a strong solution of nitrate of silver, or with the caustic in substance. If effusion should have already begun, the cuticle may be punctured or snipped off before the caustic is applied.

The greatest danger is to be apprehended when the inflammation affects the conjunctiva and cornea, constituting *variolous ophthalmia*, properly so called, (*ophthalmia externa variolosa*,) that is, acute external inflammation of the eye. The essential nature of the disease is the same in the cornea as in the skin; it is inflammation, so violent as quickly to produce suppuration, or even sloughing. This disorder, however acute and extensive, is of little consequence in the skin, so far as the organ itself is concerned, but its effects on the cornea are most destructive and serious. Suppuration and sloughing of this part are attended with severe external inflammation of the eye, probably affecting the sclerotica as well as the conjunctiva, and the ultimate condition of the organ presents those changes which sufficiently prove the previous existence of such violent disturbance. Evacuation of the humors and collapse of the globe, staphyloma, prolapsus iridis, synechia anterior, contracted or closed pupil, opacities in various degree, blindness or injured sight, are the frequent consequences of this variolous ophthalmia.

The opinion has generally prevailed that the injurious and destructive changes, which affect the eye in small-pox, are owing to the formation of variolous pustules on the cornea; and I represented the matter in this light, in the former edition of my treatise, following the received notions on a point in which I had no experience, except of the permanent mischiefs to the eye; these being such as accord very well with the prevalent doctrine

respecting the nature of the complaint in its early stage. It now appears that the generally received notion on this subject is incorrect.

Dr. George Gregory says that the eye in small-pox suffers from common inflammation only, "the pustule on the cornea not appearing till the eruption is on the decline, and therefore not being a primary or essential feature of the disease."*

M. Guersent, physician to the hospital for children at Paris, says that "variolous ophthalmia is an inflammation without pustules, which appears during the variolous eruption, and often after the complete desiccation of the pustules on the skin;" and he denies that small-pox pustules ever form on the cornea.†

Dr. J. F. Marson, the able surgeon of the small-pox hospital, has given an interesting account of the subject in the *London Medical Gazette*, vol. xxiv. He says, "I have never seen a small-pox pustule formed on the eye. The eye itself appears to me to possess complete immunity from the eruption of small-pox. It remains uninjured all through the eruptive stage of this disease." He says, however, that common inflammation sometimes attacks the conjunctiva during the first five or six days: that the occurrence is unfrequent, and not dangerous.

He then proceeds, "the common abscess of small-pox, familiar to all practical men, forms on the eye between the conjunctival membrane and sclerotic coat, and also between the layers of the cornea, of which I may have seen five or six cases in the treatment of 1500." "These abscesses were small, took place cotemporaneously with abscesses in other parts of the body, and the eyes recovered unimpaired."

He further mentions a deep-seated inflammation, occupying the internal structures, and occurring in those who have small-pox in a very severe form, and who die on the seventh or eighth day.

The more common and so frequently destructive disease occurs in the proportion of one in thirty-nine.

Dr. Marson found that there were twenty-six cases of variolous ophthalmia in a thousand; and of these eleven lost an eye. It begins on the eleventh or twelfth day, or later, from the first appearance of the eruption. "It comes on after the secondary fever has commenced, with redness and slight pain in the part affected, and very soon an ulcer is formed, having its seat almost invariably at the margin of the cornea: this continues to spread with more or less rapidity, according to the degree of secondary fever present; in the more violent cases an ulcer being formed on each side of the cornea at the same time, showing the disease to be advancing with great severity, and presenting a tolerably certain indication, that the eye will be entirely lost. The ulceration passes through the different layers of the cornea, until the aqueous humor escapes, extending itself too laterally, and if the part of the cornea destroyed be large, the iris will protrude through the opening. In the worst cases there is usually suppuration, and when the matter is discharged, the crystaline lens and vitreous humor escape; or the humors may escape from deep and extensive sloughing in the first instance, without the formation of matter; this being succeeded of course by the total annihilation of the form of the eye, as well as the sight."

Dr. Marson has seen more than once the entire cornea swept away within forty-eight hours; and this may happen without pain: and he lately saw ulceration extend completely round the margin of the cornea, so as to

* London Medical Gazette, vol. v., p. 222.

† Mr. Middlemore's Treatise, vol. i., pp. 311 and 313. A regular small-pox pustule on the cornea is delineated by Beer, Leitfaden; vol. i., tab. 1, fig. 2.

loosen three or four layers, which came away almost in an entire state. He considers this sloughing and ulceration to be analogous to the abscess and mortification of the cellular membrane and skin, which occur in small-pox about the same period, and to similar occurrences taking place after measles, scarlatina, erysipelas, and typhus. The treatment will consist in antiphlogistic means, such as venesection, cupping, or leeches, where the state of the constitution and strength will allow, with mild aperients, and warm ablution of the organ. In debilitated subjects, good diet, with cordials and tonics, must be resorted to. If the effect on the cornea produced by the disease should consist simply of interstitial deposition, we may expect great improvement, when the inflammation has come to an end by the natural powers of restoration. A patient seven years old, who had recently gone through small-pox, the eyes having been inflamed, was brought to me at St. Bartholomew's. The whole cornea was opaque, so that the iris and pupil could not be seen; there was slight external redness, and no pain. The child was emaciated and very feeble. She was treated by tonics with nutritious diet, and simple tepid ablution locally. The cornea rapidly regained its transparency, so that in three months hardly a trace of opacity remained, and vision was perfect.

As the eyes are closed by tumefaction of the lids, and consequently cannot be immediately inspected, it is difficult to determine whether the globe is inflamed or not, and to give an opinion on the important question of danger to sight. If the patient feels pain in the ball itself, with dryness, stiffness, and the sensation of sand or gravel in the eye, if the uneasiness be increased on attempting to move the eyeball, and especially if it be aggravated on exposure to light, which will affect the organ powerfully even through the swelled palpebræ; and if, in addition to the purulent secretion of the pustules on the ciliary margins of the lids, there be increased lachrymal discharge, we may conclude that acute variolous inflammation exists, and that the organ is in the greatest danger. The absence of the symptoms just recited shows the affection to be confined to the lids.

The only ophthalmic inflammation connected with small-pox, that I have seen in its active state, is what I should call *secondary variolous ophthalmia*, that is, inflammation of the cornea, and other coverings of the eye, coming on after the desiccation of the pustules, when the scabs have fallen off, and the patient is convalescent, that is, two, three, or four weeks after the apparent termination of the complaint. I do not know whether Dr. Marson considers these cases as included in his account of the affection, nor whether he would regard the appearances in the cornea as variolous pustules. It seems to me that, allowing for difference of structure, the affection is essentially the same in the cornea as in the skin: we could not expect that the appearances should correspond exactly in two textures so very different from each other. This secondary variolous ophthalmia is a milder and less dangerous complaint than the primary disease. We have the advantage of seeing its origin and progress, and of being unfettered in its treatment by difficulties connected with the serious, if not dangerous general condition of the patient. A whitish opaque spot, with a more or less considerable dusky halo, forms on the cornea, and is attended with external inflammation of the eye, embracing both the cornea and the sclerotica. The white appearance becomes more extensive, and the part turns yellow. If two or more such white spots should appear, the whole cornea will be rendered nebulous, or the same effect may be produced from a single large one. Redness of the sclerotica and conjunctiva, pain, increased sensibility to light, and lachrymation are present.

If the complaint has been allowed to take its natural course, the occurrence of suppuration will be quite unequivocal. The part where the matter has been deposited subsequently ulcerates, as in common inflammation of the cornea; or, by arresting inflammation, this ulceration may be prevented, and the matter may be absorbed. A permanent white cicatrix remains after ulceration, and some degree of opacity will continue after absorption of the matter has occurred.

I have not seen sloughing, in this form of the disease, as an effect of acute inflammation; but I have known the ulcerated surface to lose its vitality from the great general weakness of the subject. I have related a case of this kind, and mentioned some other examples of the secondary affection, in the *London Medical Gazette*, vol. xxiii., p. 507.

In the active inflammatory complaint now described, our object will be to check the local excitement, so as to prevent suppuration of the cornea; or if this should have occurred already, to prevent ulceration.

In two cases which came under my care at St. Bartholomew's, the disease of the eye began just as the skin had become cleared of the scabs. A white spot showed itself on the cornea, in each, surrounded by nebulous opacity. There were redness of the sclerotica, severe pain, increased lachrymation, and feverishness. By active antiphlogistic treatment, the inflammatory disturbance was lessened; suppuration did not occur, and the opacity disappeared almost entirely during the employment of counter-irritation by friction of the tartar-emetic ointment on the nape. As the corneal affection was seated in both these instances nearer to the circumference than to the centre of the membrane, the slight remaining opacity, which was only discoverable on close inspection, did not interfere with sight.

If the disease should occur in a debilitated subject, and the corneal affection should be seen in a state of ulceration spreading from weakness, or even proceeding to sloughing, the eye will be in the greatest danger, and the only chance of benefit, either locally or generally, will be afforded by generous diet, stimuli, and tonics.

MORBILLOUS AND SCARLATINOUS OPHTHALMIA.

In measles and scarlet fever an external inflammation of the eye is common, but it is less severe in its nature, and less injurious in its consequences, than the variolous. There is the same relation in point of degree between the *ophthalmia morbillosa* and *scarlatinosa*, and the variolous ophthalmia, as there is between the cutaneous inflammation in these several exanthemata. In measles and scarlet fever, the change which the skin undergoes amounts to little more than vascular congestion; and so in the inflammation of the eye, we have merely exterior redness of the organ, and vascular congestion of the conjunctiva and sclerotica, with pain, increased lachrymal discharge, and uneasiness on exposure to light. Sometimes pustules and ulcers form on the cornea; the vessels of the latter may enlarge and produce interstitial deposition into its texture.

Together with the other symptoms there is, particularly in measles, catarrhal affection of the lining membrane of the nose and air-passages, with sneezing and cough. The ophthalmic affection arises and proceeds with the cutaneous disorder. It is generally a companion of measles, although we may have the disorder of the skin without any affection of the eyes; there are instances of *rubeola sine catarrho*, as they have been termed. Inflammation of the eye is not so common in scarlet fever as in measles

The conjunctiva is affected alone, or together with the sclerotica. A severe inflammation of the external tunics, with ulceration of the cornea, sometimes follows these exanthemata.

The affection of the eye in these cases does not usually require active treatment. Protection from light, if it should be offensive, a cool or tepid wash, and aperient medicine, will generally suffice. If, however, the inflammation should be more severe, a few leeches may be applied, and afterwards a blister behind the ear, or at the back of the neck. We are not to suppose that because the ophthalmic affection occurs in measles, it requires no local means: we must observe the state of the organ and of the constitution, and regulate our proceedings accordingly. Ulceration and opacity of the cornea, with injury or loss of sight, may ensue from negligence. I have seen extensive ulceration and staphyloma, with blindness, in the ophthalmia following scarlatina.

CHAPTER XII.

VARIOUS AFFECTIONS OF THE CONJUNCTIVA.

THE thickened and granulated state of the conjunctiva has been noticed in the description of purulent ophthalmia. (See page 246.)

Ulcers.—The elevations called pustules frequently ulcerate, forming small sores, which soon heal. Syphilitic ulceration of the conjunctiva has been described in Chapter II., § 2.

I have seen a few instances of conjunctival ulceration not referable to any specific cause. A gentleman, about thirty years of age, of good constitution, consulted me for inflammation of one eye. It was a smart attack of external ophthalmia. I found an ulcer, with whitish surface, about three-quarters of an inch long, and one-quarter wide, on the conjunctiva scleroticæ, below the cornea. The circumstances of the case afforded no explanation of the appearance. It was necessary to take blood by cupping and leeches: the inflammation was soon removed, and the ulcer healed quickly. In the case of another young man, more severe and obstinate external ophthalmia existed in conjunction with ulcer of the conjunctiva. Within a few weeks I have seen a patient under thirty, with a small ulcer on the conjunctiva oculi of one eye, and on the semilunar membrane of the other. There was considerable surrounding inflammation, with pustules of the ciliary margins. The complaint soon disappeared under mild antiphlogistic treatment.

*Pterygium.**—In the affection thus designated, (see figs. 45, 46, p. 317,) a portion of the conjunctiva, of triangular figure, belonging partly to the sclerotic, partly to the corneal division of the membrane, becomes thickened or otherwise altered, with enlargement of its vessels and increased redness. The basis and the larger part of the pterygium lie upon the sclerotica, the basis being towards the circumference of the globe; the narrower portion is

* Greek πτερυγιον, diminutive of πτερυξ, a wing: the name having probably been given from the shape of the affected portion. SYNONYMES. Lat. *unguis*, or *ungula*; Eng. *web*; Fr. *taie*, or *onglet*; German, *Nagelfell*; *Flügelfell*.

An elaborate account of Pterygium, including the nature and treatment of the disease, and the opinions of various authors, will be found in Mr. MIDDLEMORE's Treatise, vol. i., chap. 2, § 4.

situated upon the cornea, on which the apex gradually advances. Mr. Tyrrell, (op. cit., vol. i., p. 187,) however, mentions that he has seen some few cases, in which the usual position of pterygium has been reversed, the basis having been at the margin of the cornea, and the apex directed towards the circumference of the globe.* We do not usually see it in the early stage, as it causes neither pain nor inconvenience, and the patient is not aware of its existence until the altered appearance of the membrane is noticed by himself or others. Sometimes, however, we have the opportunity of observing the development of pterygium in one eye when it exists in a more advanced stage in the other. It begins with the appearance, in the conjunctiva scleroticæ, of a few vessels rather larger than natural, and running from behind forwards nearly parallel to each other. After some time, the membrane is found, on accurate inspection, to be a little raised; but the surface is smooth and entire. It gradually assumes the triangular shape, the basis extending towards the circumference of the eye, while the apex passes over the junction of the sclerotica and cornea, and advances on the latter. In proportion as it increases, it becomes thicker and redder: hence it is raised above the natural level of the membrane, both on the sclerotica and cornea; and red vessels are seen in the latter situation, on a more or less opaque ground and bounded by slightly raised opaque margin. The thickening and vascularity are greatest at the base, where the conjunctiva and the subjacent cellular texture are loose: near the anterior boundary of the sclerotica, and on the cornea, the increased density and closer adhesion of the membrane to the parts below afford a greater resistance to the change of structure. Hence we explain the triangular or wing-like figure which the disease always assumes, and constantly preserves, as the apex slowly makes its way towards the centre of the cornea. It must, however, be observed that the end of the narrower corneal portion is rather obtuse than pointed. The texture of the membrane is not simply thickened; it assumes a fibrous aspect, which is often strongly marked, so as to produce a tendinous appearance, and sometimes, in conjunction with the increased redness, to give on first view an almost muscular character to the diseased part. It is loosely connected to the conjunctiva and cornea, so that we can easily raise it from the subjacent parts: this circumstance, in conjunction with its rising a little above the general surface of the membrane, gives it, in some degree, the appearance of an adventitious growth.

From observation of the disease, in the living eye, and of the appearances presented on operation, I should conclude that pterygium consists in a morbid change of the conjunctiva, in which the affected portion of the membrane is thickened, rendered firmer and more vascular, and assumes a fibrous character. Mr. Middlemore (p. 369) considers that there is a deposition beneath the membrane, which raises it in the manner already mentioned.

Pterygium is most frequently seated at the inner canthus, and seems to proceed from the semilunar fold of the conjunctiva; at least its thick basis is connected to this part, when the growth is fully formed, though at an earlier period there is no such connection. It is less commonly seen at the external canthus; its appearance on the upper part of the globe is still more rare, and it is most uncommon on the lower aspect.† It may be formed on

* In the fourth plate, figs. 21 and 22 of his *Klinische Darstellungen*, pt. 1, Ammon has represented two examples of what he calls *peculiar excrescences of the sclerotica*. In appearance, he says, they resemble inverted pterygium, but are quite different in their nature from that disease. They have a broad basis corresponding to the edge of the cornea, on the outer side in one, on the inner in the other; and they proceed outwards, gradually tapering off. They are yellow, like pingueculæ, and considerably elevated.

† A membranous pterygium on the upper part of the globe (*p. tenue superius*) is deli-

the internal side of one eye or both; or on the inner and outer side of the same eye. Mr. MIDDLEMORE (p. 366) says that instances are not wanting of four pterygia formed on one eye, so that the points have met upon the cornea and completely obscured the pupil. I have not seen this, nor the occurrence of the disease at the upper and under part of the eye at the same time.

Pterygium comes on quite insensibly, and grows very slowly. The patient experiences no uneasiness, and is not aware that the disease exists till it has made some progress. Its slow increase is a distinguishing character of the affection: it will exist for many years without making much advance. Yet it gradually proceeds towards the center of the cornea, and the advance of the opaque body in this direction naturally excites apprehension that it may ultimately interfere with vision, especially if there should be one on each side of the eye. I have seen instances, in which it has been apparently stationary for a very long time, so that at the end of from ten to twenty years it has not enlarged so as to affect sight.

It occurs about the middle period of life; I have never seen true pterygium in young persons. It has been most frequent, within my experience, in those who had passed much time in hot climates, particularly the East or West Indies.

The formation of pterygium has been referred to inflammation of the conjunctiva; on what grounds, I do not know. The diseased change begins and proceeds without the presence of the circumstances generally admitted to constitute proof of inflammation; while the whole course of the affection, and especially its long duration, are totally different from what we see in inflammatory affections. Individuals laboring under pterygium are not even found to have been previously subject to inflammation of the eyes.

Pterygium presents itself under various forms, which have been designated by particular epithets. Thin or membranous pterygium, (*p. tenue*,) fig. 45, appears on the cornea as a thin and often very delicate fibrous and vascular layer, through which we can see the transparent cornea. The growth may

Fig. 45.

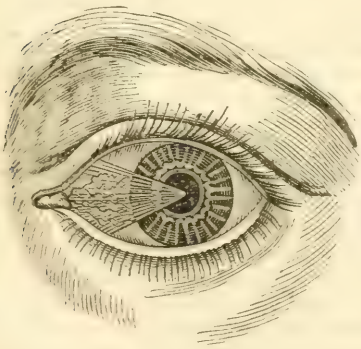

Fig. 46.

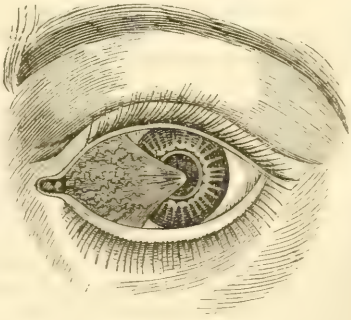

neated by AMMON, Klinische Darstellungen, pt. 1, tab. 1, fig. 12. In Mr. WARDROP's Essays, vol. i. pl. 3, there is a representation of an inferior pterygium. In this figure, which, like all the rest in the same work, is admirably executed, the characters of true pterygium are wanting. The case appears clearly from the engraving, as well as from its explanations (p. 153) to have been a thickening and increased vascularity of the conjunctiva scleroticæ and corneæ caused by repeated inflammations.

be thick and compact like a dense membrane, but still with more or less of fibrous character it forms a thick and opaque layer on the cornea, becoming thinner at the margin. [Fig. 46.] This is thick pterygium, (*p. crassum,*) of which the fleshy kind (*p. sarcomatosum* or *carnosum*) is only a more strongly marked form.

A peculiar kind of thick or fleshy pterygium is sometimes seen on the upper surface of the globe, where it forms a preternatural connection between the upper lid and the cornea. The basis occupies the upper or orbital edge of the tarsus in its whole breadth, and the narrower part, which however is not pointed, adheres to the lower portion of the cornea. The production itself is an elongated portion of conjunctiva, not connected to the globe except at its lower end: it can therefore be raised by passing a probe or director under it. I have mentioned it as an effect of purulent ophthalmia, (see p. 243) and have only seen it as a consequence of that disorder. The union between the conjunctiva of the upper eyelid and the cornea takes place during the great swelling of the former, in consequence of which it hangs over the lower lid. If the surface of the swollen membrane should be ulcerated, we can understand how accretion of it to the ulcerated cornea may take place. When the swelling of the eyelid has gone, and the tarsus has resumed its natural position, the conjunctiva will be drawn into a triangular fold, as we see in these cases. Two pterygia of this kind are figured by Mr. Travers.* I have seen the same kind of pterygium under another modification; the conjunctiva of the upper part of the globe having become adherent to an ulcer at the lower part of the cornea. The cases now described are totally different in nature from true pterygium, resembling it merely in their triangular form, in their position on the globe, and attachment to the cornea. I suspect that the pterygia said to have been seen on the upper part of the globe, were examples of the change now described; as I have never seen true pterygium in that situation.

A malignant or cancerous pterygium has also been mentioned. I have never seen such an affection; and I suspect that the appearances which have given rise to the description, may have arisen from the injudicious use of the stimulant and escharotic applications which have been recommended for pterygia of the common kind. Mr. Wardrop† has represented, under the name of fleshy pterygium, a diseased state of the conjunctiva, in which it formed a thick mass, covering the inner part of the cornea, involving the caruncula and semilunar membrane, and separating the two lids, without, however, the triangular shape and regular surface of pterygium. He says that it occurred in "the eye of a young gentleman, who had the common triangular-shaped pterygium from early life. Its growth having become rapid, a surgeon employed repeated scarifications; but these instead of causing it to diminish, made it grow more rapidly."

Diagnosis.—The insensible origin, the very slow growth, the triangular figure, the peculiar vascular and fibrous change of the membrane, its loose connection with the surface of the globe, and the absence of previous or concomitant inflammation or uneasiness, sufficiently distinguish true pterygium from thickening, swelling, and increased vascularity of the conjunctiva, and from opacity and vascularity of the cornea dependent on inflammation. If the term pterygium be confined to a change of texture thus characterized, it will not, I think, be seen before the middle period of life.

Treatment.—So long as the disease remains in the quiet stationary con-

* Synopsis, pl. 6, figs. 3 and 4. See also Ammon's Klinische Darstellungen, pt. 1, tab. 1, fig. 14.

† Essays on the Morbid Anatomy of the Eye, vol. i., p. 155, pl. 3, fig. 3.

dition I have described, neither interfering nor seeming likely to interfere with vision, it should be left alone.* The astringents, and stimuli, the escharotics, the scarifications and incisions which have been recommended for its treatment, seem to be more likely to accelerate than retard the progress of the mischief.

Extirpation of the morbid growth has been recommended, if it should have advanced on the cornea so as to impede vision, which I have never seen, or if it should threaten such an impediment. It may be easily cut away either with a knife or scissors. The eye being a little turned in the direction of the disease, the pterygium should be seized with forceps and raised a little. A pointed narrow-bladed knife is passed under it with the flat surface towards the globe, and carried forwards so as to shave off the thickened membrane as far as the edge of the cornea. The basis may afterwards be detached, being raised by the forceps and cut away by the knife or scissors. The surface heals readily; nothing is required except cold or tepid water to the eye; stimulating applications would be injurious; the portion of the growth left on the cornea will shrink and disappear. This mode of proceeding is applicable both to the thin and the thick pterygium.

[We must caution the practitioner against the extirpation of the entire basis of the pterygium, especially when it proceeds from the internal angle of the eye. Instances have come under our notice, in which very great inconveniences to the patient followed a neglect of this caution. In 1841, we removed a pterygium which had extended so far over the cornea as almost to cover the pupil, in the hopes of preventing its further growth, and a consequent entire loss of vision. After the wound healed, some red vessels occupied the site of the pterygium; but, believing that in time these might contract, and at all events that it was not prudent to again resort to the knife, we recommended a mild astringent wash, and that no further operation should be attempted. The patient not being quite satisfied, sought other advice, and was persuaded to have the enlarged vessels excised, and the whole base of the pterygium completely extirpated. Red vessels were, however, speedily reproduced, and caustics were then applied. Some months afterwards, he again applied to me when I found that bands of adhesion had formed between the ball and the eyelids at the inner angle of the eye, which much impeded the motions of the ball, and proved very distressing to the patient,—a result which we had predicted. His sight was also worse, and he bitterly lamented not having followed our advice.]

The immediate effect of the operation seems favorable in getting rid of the complaint. We have not any satisfactory evidence respecting the more important point of its ultimate result. I was consulted two or three years ago by a gentleman from the north of England, who said that he wished me to remove a pterygium from his eye. I found that the complaint had existed for many years without causing any inconvenience, that it had been removed some time previously by his medical attendant in the country, and that various applications had since been made to the part. I found that the pterygium was reproduced: the patient said it was larger than before the operation, and troublesome, which it had not been before. I advised that all local means should be discontinued, and that no operation should be performed, unless circumstances should arise actually calling for it. Having

* "The fleshy pterygium is sometimes a chronic and even stationary condition of disease, producing no inconvenience, nor threatening to interfere with vision. Whenever this is the case, I am decidedly of opinion it should be let alone."—Mr. Travers' *Synopsis of Diseases of the Eye*, p. 274.

heard nothing of this patient since, I conclude that the complaint has become stationary.

If a case were seen, exhibiting the characters supposed to indicate malignity, all sources of irritation should be removed; so that the eye may be brought into a quiet state before we decide on the real nature of the disease.

In that condition of the eye, in which the conjunctiva of the upper eyelid has become adherent to the cornea, it would be easy to separate the adhesion; but the success of the operation in respect to sight would probably be frustrated by the state of the cornea, which must have suffered greatly before such adhesion could have been established. Mr. MIDDLEMORE operated without any advantage on a case, which was apparently of this description. (*Treatise*, vol. i., p. 379.)

Pterygium pingue, or *pinguecula*, is badly named, being altogether different from pterygium, which it resembles only in situation. It is not a morbid change, but a natural alteration in the part, coming on at or after the middle period of life. It consists of a few little yellow granules, supposed from their color to be adipose, as the name expresses, appearing under the conjunctiva, which retains its normal structure, just behind the margin of the cornea, and sometimes almost encroaching on that membrane, at the lateral aspect of the globe, on one, but more frequently on both sides. This deposit is sometimes large enough to be rather conspicuous; and hence we are consulted on the subject. It attains a certain magnitude, never such as to cause inconvenience, and then is stationary. I never advised nor performed the removal, which is quite unnecessary. If, however, a person disliking the appearance, should wish to get rid of it, nothing could be easier than to raise the part with forceps, and then snip it off with the convex scissors.

Dry, or cuticular conjunctiva; xerosis, or xeroma conjunctivæ (from ξηρος, dry).—We meet occasionally with a singular change in the state of the membrane, for which we possess no remedy, the pathology being at the same time quite obscure. The conjunctiva loses its character of a mucous membrane, and no longer secretes; the surface of the eye has a rough cuticular appearance, and the cornea is dry and dusky.* The lids become gradually adherent to the globe, producing symblepharon. I have seen it a few times in young subjects, in whom I could neither obtain any clear account of its history, nor render service by medical or surgical treatment. In these instances, the affection had been of long standing, and the changes in the organ so considerable, as to render curative efforts hopeless.

Professor VON AMMON has given a good account of this singular and rare affection, under the name of *xerosis conjunctivæ*, in the first volume of his *Zeitschrift für die Ophthalmologie*, accompained with a detailed history and description of some cases which had come under his observation.† His attention was first directed to it by Professor JAEGER of Erlangen, who called the disease *Ueberhäutung der conjunctiva*, that is, *skinning over of the conjunctiva*.‡ The resemblance which the surface of the membrane

* The first figure in the seventh plate of Mr. WARDROP's Essays, vol. i., represents very well the dry dead appearance of the eye.

VON AMMON has also delineated the appearances of the disease in its various stages, in his Klinische Darstellungen, pt. i. pl. 1, figs. 16 and 19—21.

† Beobachtungun, Ansichten und Zweifel über die Entstehung der Xerosis conjunctivæ, art. vi., p. 65.

‡ Bericht über die chirurgisch augenärztliche Klinick von Jahre 1828—1829: in the Medicinisch chirurgische Zeitung, 1830, vol. i., p. 31. The inaugural dissertation of Dr. KLINGSOHR, die Ueberhautungder Bindehaut, with a colored plate, Erlangen, 8vo. 1830, was written at the suggestion of Professor JAEGER; see AMMON's Zeitschrift.

presents to that of the cuticle is denoted in the name employed by Mr. TRAVERS, of *cuticular conjunctiva.**

In a patient, who has had the complaint some years, there is partial symblepharon, especially at the internal canthus, where the lids adhere to the caruncula, and to each other. In one eye both puncta lachrymalia are closed; the lower punctum is obliterated in the other eye. The lids cannot be shut on account of the symblepharon. Contraction of the tarsus, with partial trichiasis, exists in both upper lids. The palpebræ cannot be drawn away from the globe, on account of the symblepharon. When an attempt is made to raise the upper, the conjunctiva is drawn into folds below the cornea. The conjunctiva oculi is quite dry, and of a dirty white dead appearance, which is particularly remarkable over the cornea. The form of the latter is regular, and the blue iris can be distinguished through it, though the outline of the pupil is not seen clearly. The eyes are so insensible, that they can be rubbed pretty strongly with the finger without exciting pain. Warm water is used to the eyes, and agrees with them better than cold. In former time this patient had suffered much from inflammation of the eyes, connected with entropium of the upper lids. Another patient, forty-seven years of age, had experienced in childhood repeated attacks of strumous ophthalmia, and had suffered much from inflammation of the eyes, with entropium, in the last twenty years. In the left eye, the lids adhere to each other and to the caruncula at the internal canthus. The puncta are closed: their situation being visible. Partial trichiasis exists in both lids; the upper is so shortened, that the eye cannot be shut, producing the state of lagophthalmos. When the globe or lids are moved, the conjunctiva oculi is thrown into folds. The latter membrane is dry, dirty, and as if covered with dust: it is white, and firm, but moist at the angle of reflection from the globe to the lids. No vessels are perceptible in the membrane. No moisture is perceived on rubbing the cornea. The iris can just be distinguished; but the margin of the pupil is not perceptible. The patient can see objects with this eye; but they appear enveloped in a thick cloud. She sees better in moonlight than in sunshine. If she weeps, no tears flow on this side; but the eye becomes prominent, blood red, and painful, and copious lachrymation occurs on the other side. The eye does not bear cold, nor cold with moisture; but washing with warm water is agreeable. The patient often feels a dryness, as if sand were between the lids. In the right eye the tarsi are contracted, and the cilia inverted; the conjunctiva round the cornea is partially elevated, and forms folds; the cornea obscure. The lachrymal secretion is natural.

Professor VON AMMON has some further observations on the subject in the second volume of his *Zeitschrift*, p. 381. He relates a case, of which the principal circumstances correspond to those of the preceding instances. The patient, a female, twenty-seven years old, had suffered in her early years from strumous ophthalmia, for which no other remedy but the ointment of red precipitate had been employed. When grown up, she labored under chronic ophthalmia with trichiasis. The puncta are closed, the palpebræ and caruncula grown together; the conjunctiva dry, and almost scaly over the cornea, which is so obscure that the color of the iris and the state of the pupil could not be distinguished. Painful pressure is experienced in the eyes, with redness in weeping, but no tears flow. The patient is most comfortable in cold weather, and most uneasy in the heat of summer. Bathing with clear water and milk agrees best with the eyes.†

* Synopsis of the Diseases of the Eye, p. 120.

† A case of the affection, in a less advanced state, is related by Mr. MACKENZIE in the London Medical Gazette, vol. xii., p. 44, under the name of Xeroma conjunctivæ.

[A well-marked example of this rare disease is recorded by M. VELPEAU in the *Gazette Médicale de Paris*. See *Am. Journ. Med. Sci.*, Aug., 1838, p. 495.]

Discoloration of the conjunctiva by nitrate of silver.—The conjunctiva sometimes acquires a livid or olive tint in persons who have long employed the nitrate of silver locally; and, as far as I know, the change of color is permanent. The long-continued internal use of the same remedy produces a similar effect on the integuments generally, giving them a dirty appearance, with a livid or bronzed tint; and this change seems permanent.

Dr. JACOB, of Dublin, who has observed and described this change of color in the conjunctiva, has remarked, as I have found, that it is owing, not to the strength, but to the long-continued employment of the caustic solution. He considers it analogous to the effect of coloring matters on the skin, in tattooing, and, consequently, as an additional proof of the identity of the two structures.*

[We have seen several examples of this discoloration. One was a young lady, who had used for a long time, as she informed us, a solution of nitrate of silver dropped on the eye, for the cure of an obstruction of the lachrymal passage of one side. The whole conjunctiva of the corresponding eye was of a brownish color, which will doubtless be permanent. We have at present under our care in Wills Hospital, a man, both of whose eyes are of an olive tint from the same cause.

Mr. GUTHRIE, in one of his clinical lectures, states that a solution of the cyanuret of potassium (three to six grains to the ounce of distilled water) applied by drops every other day, is an admirable remedy for removing this olive color. Mr. BROCK is said to have first proposed this remedy.

Copper-colored syphilitic eruption affecting the conjunctiva.—ALFRED SMEE, Esq., relates, in the *London Medical Gazette*, (13 Dec., 1844,) a case in which a copper-colored eruption appeared on the conjunctiva. The subject of the case was a respectable married female, who applied at the Central London Ophthalmic Hospital to be relieved of a small ulcer which existed at the edge of the eyelid. From its appearance, Mr. S. immediately recognized its specific character, and upon inquiry, learnt that both husband and wife had labored under syphilis for a period of two or three years. At that time under the antimonial treatment the ulceration speedily healed. At this period there were also numerous copper-colored spots over the skin.

After a short interval she returned, and stated that her eye was somewhat uneasy, and that she feared a return of the malady: on examination the conjunctiva below the cornea presented a spot a little smaller than a silver penny-piece. This spot appeared formed by the conjunctiva itself at that point being swollen; in fact the surface was obviously raised, and the color changed to that of a cupreous hue, somewhat similar to the color of the spots of the skin, but considerably lighter: this spot was not absolutely opaque, but semi-transparent, and it gave the idea that the conjunctiva at that part was swollen in its substance, and tinged of a copper color. It presented no unusual vascularity; in fact, Mr. S. does not know that he should be justified in asserting that there was a single vessel either increased in size or added in number to those existing in the normal state. The copper color, then, had no immediate reference to the vessels, and was due to the part exhibiting the syphilitic stain; a phenomenon by no means understood.]

Polypi, warts, and other excrescences of the conjunctiva.—I have seen

* Dublin Hospital Reports, vol. v., p. 366, plate 1, fig. 1.

small polypi, analogous to the innocent or mucous polypus of the nose, growing from the palpebral conjunctiva, and the fold between the lids and globe. Excision is the obvious and easy remedy.

I met with a tumor, growing from the tarsal surface of the upper eyelid, equal in size to a large pea, and connected by a slender stalk. It had a smooth mucous surface, and I considered it to be polypus. In snipping it off, I found the peduncle hard, so as to require some force in dividing it. It was found to be fibro-cartilaginous and thoroughly hard internally, conjunctival externally; it had probably grown from the tarsus, to the orbital edge of which it had been attached. The complaint had existed fifteen years, and had caused trichiasis of one quarter of the upper eyelid.

Vascular excrescences, in the shape of warts or fungus, may be thrown out by the membrane in other situations, in consequence of irritation. They may occur in the fold of the membrane, or on the anterior part of the globe. They are red, soft, fissured, or granulated on the surface, which is otherwise smooth, sometimes pedunculated, and sometimes growing by a broad basis. They may acquire such size as to irritate the globe and lids, or to cover the cornea inconveniently. They should be seized with forceps or hook, and cut off with the convex scissors.

A singular example of peculiar morbid growth, resembling a congeries of dark purple roundish masses like black currants, proceeding from and covering the cornea, has been described and delineated by Mr. Travers. He says, "I excised the anterior hemisphere of the eyeball in an elderly lady, in whom the cornea was concealed by a tumor, of a dark purple color, protruding to such an extent between the eyelids, as to occasion great inconvenience and deformity. It had the appearance of being disposed in lobes, somewhat resembling a bunch of currants of unequal size. On dissection, the cornea and sclerotica proved to be entire, and the morbid growth, lying upon and adhering to the corneal and a small portion of the sclerotic surface, had acquired the lobulated appearance, as if by degeneration of the covering conjunctiva; for delicate white bands, the only vestiges of this membrane, were seen intersecting the lobules at irregular distances, in the form of septa. The substance, in section, was firm, of a dark color, here and there mottled with white, and measured a quarter of an inch in thickness from the external surface of the cornea." "It was not characterized by any symptom of malignity: neither pain in the ball nor in the head worthy of notice, nor any affection of the constitution. The deformity and the fear of its increase were the inducements to the operation, which was done about a twelvemonth ago. This was attended by no untoward symptom, and up to this time the subject of the disease has continued well." (*Lib. cit.*, pp. 102 and 427.)

In the description of the figures, Mr. Travers says, that the substance of the growth was in some parts pulpy, in others firm; that there was at one part, near the surface, a whitish spot of cartilaginous hardness: that the fungus was covered by a thin membrane easily torn, supposed to be the conjunctiva: he concludes that the disease originated from the latter membrane, and supposes, from its lobular arrangement, that the morbid growth occupied the cells of the substance connecting the conjunctiva to the cornea.

[Dr. Jacob removed an eye on account of a large vascular bleeding tumor, the size of a walnut, which grew from the surface of the cornea and a small portion of the sclerotic, or rather from the conjunctiva covering them. It was of a deep blue color, and not irregular or lobulated on the surface like the tumor, apparently of the same nature removed by Mr. Travers from the same situation. On cutting into it, the structure appeared to be altogether vascular or cellular without tubercle or deposit,

organized or unorganized. The eyeball was shrunk, and the sclerotic irregularly contracted; the choroid scarcely to be recognized, presenting a gray-blue flocculent mass, in the centre of which, instead of hyaloid membrane and vitreous humor, was a cell the size of a large pea filled with a kind of cellular substance of a yellow color of exactly the same tint as the stain which rust of iron leaves on linen. The external growth did not communicate with or originate from this internal disorganization. The optic nerve was not implicated in the disease: it was merely flaccid and destitute of medullary fibre, as in eyes destroyed by inflammation. The parts healed readily after the operation, and the disease has not returned. (*Dublin Med. Press*, Nov. 30, 1842.)]

Mr. Wardrop has delineated two growths, covering each of them, about half of the cornea, and being apparently change of structure in the corneal conjunctiva. One was of flesh color, and in its firm granulated texture, very much resembled some of the warty excrescences which are formed on other mucous surfaces: it had grown very slowly on the eye of a patient sixty years of age. The other was thick, of peculiar brown color, and was first observed after an attack of inflammation. The surface was irregular, the mass being composed of several smaller swellings, and it was plentifully supplied with red vessels. (*Essays*, vol. i., pl. 4, figs. 2 and 1.)

Cartilaginous formations in the conjunctiva.—I once saw, in a young lady, several cartilaginous bodies, about the size of pins' heads, in the substance of the conjunctiva sclerotica. They were imbedded in the membrane, which was otherwise normal, projecting on the surface sufficiently to be seen and felt. As uneasiness was experienced in the eye, which the lady referred to this peculiar condition of the mucous membrane, I removed a few of the bodies, using a small hook and scissors. The patient left London after this slight operation, and I have not seen or heard anything more of the case.

Tumors of the conjunctiva.—I have seen examples of conjunctival swellings existing at the time of birth. They have been soft white masses, the size of a pea or horse-bean, smooth on the surface like the rest of the conjunctiva, and connected rather loosely to the subjacent parts. They have been seated on the boundary between the sclerotica and cornea, but covering the former principally. No inconvenience has been caused by the disease, which has not increased so as to require surgical treatment.

Mr. Wardrop saw a congenital case of this kind. On the left eye of a girl there was a conical mass growing from two-thirds of the cornea and a small portion of the adjoining sclerotic coat. It was firm and immovable, and had a granulated surface. It was small when first observed, and increased in size in proportion with other parts of the body.*

Tumors with hairs growing from them.—Congenital swellings of whitish color, and softish consistence, with smooth mucous surface, from some part of which hairs proceed, have been met with on the sclerotica, or between it and the lower eyelid. Such growths have been described by Wardrop, Mackenzie, Himly, Graefe, and Ammon.†

The patient, whose disease is described and delineated by Mr. Wardrop, was more than fifty years of age. The tumor which had existed from birth, was about the bulk of a horse-bean, situated on the sclerotica, and covering a small portion of the cornea, next the external canthus. Its sur-

* Ibid., p. 32. Mr. Tyrrell has delineated two small congenital tumors, seated over the junction of the sclerotica and cornea; one on each side of the eye. Vol. i., pl. 8, fig. 4.

† Klinische Darstellungen, pt. 2, tab. 1, figs. 8 and 9. In these, as in all the other quoted instances, the swelling was seated on the external aspect of the globe.

face was smooth, presenting the color and appearance of the conjunctiva. Upwards of twelve long and strong hairs grew from its middle, passed between the eyelids, and hung over the cheek.*

In a boy of fifteen there was a flat white tumor, with circular base, situated partly on the cornea, partly on the sclerotica, towards the external angle of the eye. Two hairs, similar to those of the tarsus, grew from its centre.†

[Dr. W. T. Taliaferro, formerly of Maysville, Ky., now of Cincinnati, Ohio, relates an interesting case, in which there was a congenital tumor on each eye of a young lady 15 years of age, arising from the subconjunctival coat. The tumors were of a delicate pink at their base, becoming brownish at their apices. They were discovered immediately after birth, and had had a steady gradual growth. When she applied to Dr. T., the tumor of the left eye (see fig. 47), covered an oval base, about five lines in its long, and three and a half in its short diameter, and rose in a flattened conoidal shape to about six lines in height. Its long diameter ran nearly parallel with a line drawn from the inner to the outer canthus of the eye. It covered nearly the lower two-thirds of the pupil in a pleasantly shaded light. From the apex grew some ten or twelve hairs, about sixteen lines in length, a shade darker than the cilia. As the tumor grew from the outer and lower part of the cornea perpendicular to the globe, it bore the lower lid far downward and outward. The upper lid was drawn down and could be elevated but very slightly; the cilia of the upper lid came in contact with the globe and the tumor. Exposure to the wind or light, produced a free and slightly purulent discharge, rendering her situation exceedingly distressing. The tumor occupying the two lower thirds, and the superior lid the upper third of the pupil, she could distinguish no object clearly with this eye. The tumor of the right eye, (see fig. 48,) in shape and situation relative to the globe, was like to the left; its size about half that of the left, covering about the lower sixth of the pupil. The vision of this eye was good on a horizontal line and upward. The pupils of both eyes were larger than natural; the left about a third larger than the right. Her education had been impossible, and her situation altogether was most deplorable. "Always advised never to disturb the tumor, or the eyes would be inevitably destroyed."

Fig. 47.

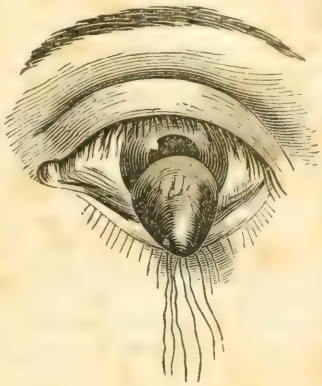

Fig. 48.

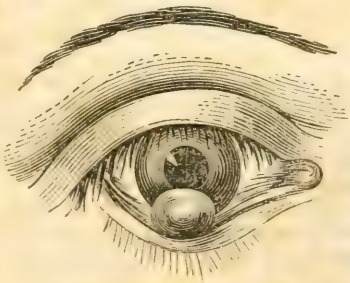

* Essays, p. 32, pl. 4, fig. 3.

† Ibid., p. 33.

After having reduced the activity of the circulation by medicine and diet, Dr. T. removed the tumor of the left eye on the 1st of June, with *Charière's* delicate cornea knife, curved scissors and hooked forceps. "The operation was rendered tedious from the exceeding vascularity of that portion of the conjunctiva reflected over the tumor, which was supplied with numerous large tortuous vessels converging from either canthus. In its texture the tumor seemed as if composed of lamina, far separated by spongy cellular substance. It was very tough. From the pressure, probably, the external lamina of the cornea were almost entirely absorbed at the lower part, and greatly thinned and softened throughout the extent occupied by the tumor. In fact it was quite impossible to distinguish where the tumor ended and the cornea began; of course, therefore, the corneal texture was much encroached on. The treatment was a dressing of light pledgets, kept constantly wet with cold water, to the eye; aperients, and a gruel diet, &c. &c. In eight or ten days, an evident discharge was begun from the wound, as if for a reproduction of the tumor. This was again dissected off; cold applications made as before growth began again: argent. nitrat. two grs., aq. distillat. ℥j, M., was used. Growth not checked; the solution of nitrate of silver was increased in strength to twenty grains to the ounce with little improvement; the solid argent. nit. was resorted to, and sulphate of copper alternated; healthful healing began and continued steadily till the wound was well."

In the latter part of June, Dr. T. removed the tumor of the right eye. Treated for a few days with pledgets wetted with cold water, and followed by the application of the solid nitrate of silver. "Not a single bad symptom supervened. An opacity is left on each eye equal in extent to the bases of the tumors. The patient was kept in a pleasantly shaded chamber for about eight weeks, and restricted to a vegetable diet. One or two drops of a solution of ten grains of nitrate of silver in one ounce of water was daily applied to each eye. At the termination of the period just named, the sight of both eyes was perfect. The opacity in the right eye is scarcely perceptible, and in the left is only visible when the eye is turned upwards. The lids have resumed their normal position."

A similar case is recorded by Mr. W. W. Cooper in the *London Medical Gazette*, for November, 1841, p. 278, with a figure.]

Swellings of this kind may be safely extirpated if they should cause irritation or inconvenience of any kind by their bulk, position, or the hairs growing from them. Mr. Mackenzie removed one of these tumors, seated towards the external angle of the eye. "It was firm and white, and had a number of fine hairs growing from it. It had long kept up an inflamed state of the conjunctiva, which entirely subsided after the tumor was removed. It was so incorporated with the sclerotica, that its root was left, but died away under the use of nitrate of silver solution."*

Himly† excised one of these tumors with four black hairs growing out of it, from the external side of the eye, in a girl of twenty. It was easily removed. It contained fat, so that the hairs grew in the same soil as in other parts.

Graefe‡ removed a small one, which had two hairs growing out of its centre, from the boundary between the cornea and sclerotica, on the temporal side of the eye. The interior consisted of fat, the surface being con-

* Practical Treatise, p. 237. † Ophthalmolog. Bibliothek, vol. ii., p. 200.
‡ Journal, vol. iv., p. 134. A front and side view of the swelling are given in tab. 2. He proposes to call the disease *trichosis bulbi.*

junctival. GRAEFE conjectures that these growths will be found generally to be adipose; considering, in conformity with the observation of HIMLY, that the presence of fat is necessary to the development of the hairs. AMMON calls these growths adipose (lipomatöse.)

Encysted tumors.—Cysts may be developed in the subconjunctival cellular tissue, but they are uncommon. AMMON has delineated one, which grew on the internal surface of the lower lid near the external canthus. It was equal in size to a large horse-bean, and though projecting by two-thirds of its surface, completely covered by the lid. On excision it was found to adhere closely to the tarsus. It was a thick white sac, containing a honey-like substance.

CHAPTER XIII.

DISEASES OF THE SCLEROTICA.

SECTION I.—INFLAMMATION OF THE SCLEROTICA.

Synonymes: *Sclerotitis; ophthalmia sclerotica*, or *sclerotic inflammation*. VETCH. *Rheumatic ophthalmia. Inflammation of the external proper tunics of the globe.* The *ophthalmitis externa idiopathica* of BEER is inflammation affecting the conjunctiva, sclerotica, and cornea.

EXTERNAL inflammation of the eye may be seated in the conjunctiva only, or in the sclerotica; the cornea being usually more or less implicated in the latter case. Both diseases are included under the vague general term ophthalmia. Although both may, without impropriety, be called external inflammations of the eye, they are very different in their symptoms, progress, termination, and treatment. In the latter instance, or that of inflammation, originating in the sclerotica, the conjunctiva will be soon involved, if the affection be acute.

Simple inflammation of the conjunctiva is, generally speaking, an unimportant affection. In consequence of its loose texture, the vessels of the membrane yield readily; there is little pain or inconvenience, and no danger to the organ. The firmer textures of the sclerotica and cornea do not give way unless the excitement be more powerful; they yield to distension slowly and with pain; their vessels do not easily recover, so that inflammation is with more difficulty subdued; and the implication of the cornea, with the ready transition of inflammation to the iris, exposes the organ to serious danger.

I have mentioned the intimate connection between the sclerotica, cornea, and iris. We cannot in the natural state trace the actual passage of vessels carrying red blood from the sclerotica to the iris and cornea; but there must be a close vascular intercourse between them, for the iris and cornea are never inflamed without the sclerotica becoming red. On the other hand, when inflammation affects the external proper tunics of the globe, it readily passes to the iris, and thus may extend to the internal structures of the eye.

Symptoms and progress.—The symptoms of inflammation affecting the sclerotica, are, external redness, pain, intolerance of light, increased lachrymal discharge, with more or less febrile disturbance of the constitution.

The external redness begins on the anterior part of the globe, immediately round the cornea, where it forms a red zone. If we examine the circum-

ference of the globe, we shall find distended blood-vessels advancing from the posterior part upon the sclerotica, following a rather straight course, and branching out into numerous ramifications, which are at length lost in the red zone that surrounds the cornea. In inflammation of the conjunctiva the redness commences in the circumference, the anterior part being at first comparatively free, and the sclerotica retaining its natural white appearance. The character of the red tint differs remarkably in the two cases. The vessels distended in sclerotic inflammation are those seated immediately upon the sclerotic coat; they are therefore covered externally by the conjunctiva, and being seen through that membrane, appear of a pink, or rose red, and sometimes almost of a violet hue, which forms a striking contrast to the bright scarlet of the vessels distended in conjunctival inflammation. The redness of the inflamed sclerotica is a rose or pink tint, being seen through the conjunctiva, and such is the color of the red zone which surrounds the cornea in the early period of the affection. The redness is uniformly diffused through the sclerotica, as if it had been tinged by some coloring substance; thus we find that this membrane is copiously supplied with vessels, although they do not, in the natural state, circulate red blood. This diffused rose or pink redness is confined in the beginning, and in milder cases, to the anterior portion of the membrane, being at the same time of a light tint; in severer attacks, and in the progress of the affection, the color is deeper and more general. Small vessels containing red blood are sometimes seen advancing on the cornea.

When the inflammation is considerable, a dense arrangement of vessels may be seen lying under the conjunctiva, and occupying the whole surface of the sclerotic coat; in short, the inflammatory affection seems to produce a kind of new vascular creation, enlarging, and thus rendering visible, a vascular plexus, of which we see nothing in the natural state of the part. In inflammation of the conjunctiva, the vessels are not only of a bright scarlet color, but lie nakedly on the surface of the membrane. When inflammation, without being very violent, is seated in the conjunctiva and sclerotica at the same time, we may observe the marked difference in situation and tint between the two orders of vessels. They also differ in their course, those of the sclerotica running in straight lines from behind forwards, while the vessels of the conjunctiva are irregular and tortuous.

The conjunctiva soon participates in the affection, if it is acute; its vessels become distended, and partake the inflammatory disturbance. The cornea assumes a dull appearance; it is not actually nebulous or opaque, but its transparency and polish are impaired.

The patient complains of stiffness and dryness in the eye; frequently he feels a sort of stinging, burning, or aching pain; sometimes there is a sense of fullness, tension, or pressure; and occasionally a throbbing sensation. The uneasiness is increased by warmth, and the parts around the eye are even warmer to the touch. As the inflammation proceeds, the pain increases, and extends to the back of the orbit, to the neighboring parts, and more or less to the corresponding side of the head. Not unfrequently the eye is comparatively easy, and the patient complains of pain in the brow, temples, cheek, or side of the nose. Often the suffering increases towards night, becomes so much aggravated as to prevent sleep, and abates considerably in the morning. It is worse in a cold, windy, and wet state of the atmosphere, and relieved by mild and warm weather.

Intolerance of light is a marked symptom from the commencement; the pupil contracts to exclude the light, and the patient avoids exposure to it. Here is another striking contrast between this affection and conjunctival inflammation; for in the latter the patient generally opens the eye freely, and

experiences no pain from the access of light. We naturally inquire what cause can be assigned for this striking difference in the phenomena attending inflammation of the two textures so contiguous to each other. Considerable inflammation may exist in the mucous membrane of the eye, without any affection of the globe; thus the disturbance does not approach the retina. But inflammation of the sclerotica and cornea requires for its production a more serious exciting cause; and this disturbance, being seated in the globe itself, must affect, more or less, the internal tunics generally, and the retina in particular. Hence the intolerance of light accompanying inflammation of the sclerotica and cornea, which is often observed where the transparency of the latter is impaired; a circumstance which, if the internal tunics were unaffected, might, *à priori*, be supposed calculated to lessen the impression of light on the organ. This intolerance, even when excessive, is a strictly functional affection; it does not depend on disease of the retina, or lead to any suspicion of internal inflammation.

The pain and the intolerance of light depend on the degree of inflammatory disturbance, and on the stage of the disease. In slight cases, or when the disorder has lasted for some time, they may be trivial, or altogether wanting. At the commencement of this affection the eye feels dry and stiff (*xerophthalmia o. sicca*), there is an interruption of the ordinary exhalation; but this is soon re-established, and an increased lachrymal secretion takes place, from the sympathetic influence of the inflammatory excitement on the lachrymal gland; so that whenever the patient opens the eye, especially in a strong light, there is a copious flow of tears.

A general disturbance exists, varying in character and degree, according to the patient's constitution, age, and health, and to the amount of the local disorder. There may be a frequent and full pulse, with white tongue and general headache; or a disturbance of the digestive organs, marked by foul tongue, deficient appetite, and costiveness, with sallow countenance, dry and inactive skin.

Diagnosis.—Inflammation of the sclerotica is distinguished from that of the conjunctiva by the redness being originally seated in and confined to the former membrane; by its being of a pink, and sometimes even light violet tint; by the distended vascular trunks being of the same tint, deep-seated, straight, and not tortuous, and connected with the sclerotica, so that they do not move with the conjunctiva; by the increased lachrymal secretion, and the absence of mucous discharge; by the pain, which is so frequently circumorbital, and by the intolerance of light. The eyelids participate in conjunctivitis, not so in sclerotitis. The latter is distinguished from internal ophthalmia by the natural state of the iris and pupil, and the unimpaired vision. However, sight is affected if the cornea should be involved in the mischief; and still more if the disorder should extend to the iris.

The sclerotica participates in inflammatory affections of the cornea, iris, and other internal tunics, whether accidental or spontaneous. Sclerotitis may be directly induced by atmospherical causes, or other external agencies; or it may arise indirectly from unhealthy states of constitution, or from disturbance in some organ or system.

Inflammation of the sclerotica, considered in itself, is not a dangerous affection. It is frequently obstinate, but it yields sooner or later to proper treatment. Of the other affections, with which it may be associated, several are of serious character, and may lead to injury or loss of sight.

The observations on treatment, in the following section, comprise all that is necessary to be said on this subject in addition to the general remarks in Chapter V.

SECTION II.—RHEUMATIC OPHTHALMIA; CATARRHO-RHEUMATIC OPHTHALMIA.

RHEUMATIC OPHTHALMIA.—Although many points in the pathology of gout and rheumatism are obscure, we know that these diseases particularly affect the fibrous structures, such as enter into the composition of joints, and are found in their neighborhood, and the synovial membranes. When any morbid affection is the result of a particular constitutional disposition, there is a tendency in all the structures of the same kind to be affected under certain circumstances; accordingly those textures of the eye, which resemble the fibrous, as the sclerotic and cornea with the closely connected iris, and the mucous membrane of the eye, which is analogous to the synovial membrane of the joints, frequently suffer under the same state of constitution, which gives rise to rheumatic inflammation of similar structures in other parts of the body. The urethra often participates in the affection, and a discharge, like that of gonorrhœa, takes place from the canal. These remarks are exemplified in the affections last described, of which the two latter might with as much propriety be called *rheumatic* as *gonorrhœal* inflammations; for they are seen to occur in instances, where the patients are not aware of having contracted infection; and when they result from gonorrhœa, that is only to be regarded as their occasional or exciting cause.

The name of *rheumatic ophthalmia* (*Sclerotitis Rheumatica* vel *Atmospherica*.—MACKENZIE), is, however, applied more particularly to an inflammation of the sclerotica, caused by exposure to cold, and presenting the general characters already described. The local symptoms are not of a violent kind, as the disorder is chiefly confined to the sclerotica. It is usually accompanied with haziness and dullness of the cornea, and corresponding indistinctness of vision; but it does not often lead to any serious change in that part. I have not seen interstitial deposition with opacity, nor suppuration of the cornea in the cases which I have regarded as rheumatic. The disease may slowly creep on to the iris. The conjunctiva is not affected, or only slightly; and the same remark may be applied to the eyelids. There is a dull aching pain, with sense of tightness; and often more serious pain around the eye, as in the brow, temple, cheek, nose, and side of the head, than in the eye itself. This pain becomes worse at night. Exposure to light is not found very troublesome: this, however, as well as the watering of the eye, depends on the degree of the inflammation. There is more or less constitutional disturbance of a febrile character.

The *treatment* must be regulated according to the degree of inflammation, the great object being to lessen that, and guard against its effects. Venesection is necessary if the patient be plethoric, the pulse full and hard, and the tongue white. Cupping from the temple, and leeches may follow, or be sufficient alone. The bowels should be opened by calomel and James's powder combined with extract of colocynth, and followed by an aperient draught. Care must be taken afterwards to insure their regular action. Diaphoretics and warm pediluvia may be serviceable. The diet should be light, without solid animal food or fermented liquors.

Calomel and opium in a nightly dose, or in a smaller quantity two or three times in the day, after the more active antiphlogistic treatment, relieve the pain, and soon remove the other symptoms. Mercury is more especially required, when extension of disease to the iris is apprehended. Affection of the mouth is not necessary, but when it occurs, seems rather advantageous than otherwise. If the pain at night should be considerable, and the use of

mercury is not indicated, opium may be given alone, or in the form of Dover's powder.

The well-known efficacy of colchicum, in the treatment of certain rheumatic affections, has led to its employment in this form of ophthalmic disease; and it has sometimes proved very efficacious. Twenty or thirty minims, or even a larger dose, of the wine of the seeds may be given in combination with carbonate of soda or potash, and some rhubarb, if an aperient is advisable, three times a day; or, two or three grains of the acetous extract of colchicum may be administered, once, twice, or three times in the twenty-four hours. If colchicum affords relief at all, it does so quickly. Blister to the nape, or mustard poultice may be employed with advantage after depletion.

Local applications are not of much avail in this affection. The warm are preferable, such as poppy fomentation, and steaming with hot water, alone, or with the addition of tinctura opii. If the nocturnal pain should be troublesome, a grain or two of opium mixed with a few grains of mercurial ointment, may be rubbed on the forehead, previously to the time at which the pain usually begins. Simple opiate frictions may be tried, either with powdered opium combined with lard, or in the fluid form as liniment. The extract of belladonna, either alone or in conjunction with opium, has also been recommended for rubbing over the brow. It would be beneficial if affection of the iris had commenced. When the eye remains weak and irritable, after the treatment now pointed out, the vinum opii may be dropped in with advantage once or twice in twenty-four hours.

In *chronic rheumatic ophthalmia*, at least in certain instances, the affection is confined to the sclerotica; the conjunctiva, cornea, and iris, not being at all involved, and the complaint is very obstinate. The following was a well-marked example.

I was sent for to a gentleman, who labored under severe rheumatic affection of one foot and knee, and one hand, with pains in the back, and great constitutional excitement; the parts were swollen, slightly red, and very painful: it was one of the cases commonly called rheumatic gout. Active antiphlogistic treatment, followed by colchicum and other means, removed the rheumatic affection, and the patient considered himself well. After a short interval, I called to inquire about his health, when he said that something was the matter with his eyes, and wished me to examine them. I looked at them hastily; the room was dark, and the day dull; and I saw no appearance of disease. When I called again, after a few days, as the complaint was repeated, I examined more attentively. On bringing him towards the window, he obviously felt the light troublesome; he drew down the eyebrows, and half closed the lids to avoid it. The conjunctiva was natural, but the whole of the sclerotica had a livid red and mottled appearance, which might have been called dull, or almost dirty, in comparison with the red color of common active inflammation. The sclerotic vessels were partially distended; the redness terminated short of the cornea, so that there was a distinct white rim round the latter, as if it had been drawn with a compass. Vision was perfect: there was no pain, so long as the eye remained at rest, but exertion of the organ, particularly under strong light, brought on uneasiness. The nature of this gentleman's occupations, and of his tastes, which were literary, prevented him from giving his eye the necessary rest; and the above described condition of the sclerotica lasted for three or four months, making me apprehensive that some serious mischief to the organ would ensue. The affection, however, was confined to its original seat, merely exhibiting the obstinate nature which belongs to disorders of such structures; and it at last disappeared completely, leaving

the eyes with their organization and powers unimpaired. Cupping, leeches, and blistering were employed, with regulated diet, and occasional aperients. Plummer's pill was taken daily, or twice a day, for about three months. Bark was tried without any advantage.

I saw a case, which lasted nearly a year, the disease having been confined to the sclerotica, with greater redness than in the preceding instance, but without any change in the cornea, or diminution of vision. Sometimes the symptoms nearly disappeared, and then came on again unexpectedly. Quinine, colchicum, and sarsaparilla, were fairly tried with doubtful benefit. More advantage resulted from cupping on the temple, the tartar emetic ointment on the nape, Plummer's pill with aperients, and the exchange of country air, with free exposure to it in exercise, for a more sedentary life in the atmosphere of London.

Foreign writers, particularly the Germans, lay great stress on that peculiar state of constitution, which gives rise to these affections, and prefer the employment of such measures as they consider calculated to remove that state, to the use of means strictly antiphlogistic. They enumerate a variety of remedies, which they suppose to be *antiarthritic*, such as decoctions of bark, and other tonics, guaiacum, antimony, Dover's powder, &c. In the first place, it is doubtful whether these remedies are specifically antiarthritic; and we know from experience that it is difficult to remove such a condition of the system. In the second place, the exclusive reliance on such measures appears to me to compromise the safety of the organ, when it is laboring under active inflammation. Perhaps the mild antiphlogistic treatment which the eye may require, may be the most effectual means of removing that state of the system called arthritic, or rheumatic; since in many such cases there is either general plethora, or local inflammation. Colchicum, however, possesses decided antiarthritic influence; hence, as well as from its well-known general antiphlogistic power, it may become a useful auxiliary in rheumatic affections of the eye, whether of the more acute or chronic form. I have seen its rather free employment of decided advantage in the former.

[The colchicum is of unquestionable efficacy in rheumatic affections of the eye; and we have seen it display its best powers in the form of Scudamore's mixture, to which a portion of oil of turpentine is added. Our formula is the following:—℞. Magnes. sulph. ℥vj; magnes. carb. ℥ij; vin. rad. colchic. ʒj—ʒij; ol. terebinth. ʒj—ʒij; aq. puræ ℥vj. Of this a tablespoonful may be given every two, three, or four hours, according to circumstances.

The iodide of potassum is also a very valuable remedy in these affections. It may be given in the dose of five grains three times a day. Sometimes we prescribe this and the preceding combination, at the same time, administering the former after each meal, and a wineglassful of the latter at bed-time, to keep the bowels open.

We have also used, with benefit, the corrosive sublimate, combined with the compound syrup of sarsaparilla, one-tenth of a grain of the former, with an ounce of the latter, three times a day.]

Bark is sometimes serviceable in articular rheumatism, and it has been used with advantage in rheumatic ophthalmia. Mr. Wardrop* has strongly

* Medico-Chirurgical Transactions, vol. x., p. 14. Mr. Wardrop says that bark seems to possess as specific an effect in rheumatic ophthalmia as in ague; and he mentions the dose of five to eight grains in a little warm water, every two hours, or as often as the stomach can bear it. He also recommends the mineral acids, which, he says, may be freely used while the patient is taking cinchona. He has, however, subsequently been in the habit of using the bark with the alkaline carbonate, as mentioned in the text.

recommended it, particularly in small doses. He gives five grains of powdered bark with the same quantity of carbonate of soda every three or four hours. Mr. TYRRELL has often found this plan successful after the useless trial of other means: and that these small doses will be of service, when no good has been derived from larger quantities. (Vol. i., p. 297.)

In persons of weak constitution or impaired health, lowering treatment must be used cautiously; while benefit will be derived from bark, from other tonics, from good diet, and the general restorative influences. I have often employed the small doses of bark and soda, recommended by Mr. WARDROP, with the best effect. If the local symptoms and the general disturbance should be of active inflammatory character, general depletion and the use of mercury will be necessary: the bark and soda will come in with advantage subsequently. They are, however, often used with decided benefit where the state of the eye, especially in respect to redness, might lead us to suppose that antiphlogistic treatment would be more advisable.

Much cannot be expected from local means in such cases as those now described. The vinum opii is the most likely to be of service.

Catarrho-rheumatic ophthalmia.—The conjunctiva and the sclerotica may be inflamed at one and the same time, when we shall have a combination of the appearances and symptoms already described as belonging to conjunctivitis and sclerotitis respectively. In the early stage of the affection, we distinguish easily the characteristic tints of the inflamed conjunctiva and sclerotica, as well as the position and color of the superficial and deep-seated order of distended vessels. There may be the sensation of sand or gravel in the eye, with pain in the globe, and in the parts around the orbit. There is constitutional disturbance, often to a considerable extent.

If we follow some writers in employing the term *catarrho-rheumatic*, we must not take it in its literal sense, as implying that the patient labors under both catarrhal and rheumatic affection, but only as denoting the coexistence of affection in the mucous and fibrous membranes of the eye. This inflammation, which is indeed of serious character, is the consequence, or at least concomitant, of active and serious disease in the cornea, without any apparent dependence, in many instances, on the influences which produce, or are supposed to produce, catarrhal or rheumatic affections of the eye.

The inflammation may predominate in the mucous or fibrous structure; most frequently in the latter. It proceeds to chemosis in the former, when the corneal affection is violent.

The treatment falls entirely under the general rules detailed in Chapter V.

SECTION III.—STAPHYLOMA SCLEROTICÆ.

The sclerotica is sometimes thinned, and raised into prominences of various magnitude. This altered state of the membrane, having been considered analogous to the thin and expanded state of the cornea in staphyloma, has received the name of staphyloma scleroticæ. The change may affect the anterior, lateral, or posterior portion of the membrane. It is not a primary affection, nor a consequence of any primary disease of the sclerotica; but it is a secondary effect of inflammation seated in the interior of the globe, more particularly in the choroid coat. Vascular congestion in these parts, when violent and long continued, powerfully distends the scle-

rotica from within, while the resistance of the membrane is probably lessened by its participation in the inflammation. The elevations of the sclerotica continue, and are indeed permanent, after the inflammation has ceased. The violent internal inflammation, of which this change is a consequence, destroys sight; I have never seen it preserved in a case of staphyloma scleroticæ.

The morbid prominence of the membrane is readily recognized in the anterior staphyloma scleroticæ, unless it should be very small. It may consist of one or more elevations, varying in size from that of a small pea to a large bean or filbert, the rest of the membrane being healthy; or the whole anterior portion of the membrane may be raised into a circular elevation round the cornea. The surface of the altered portion is uneven, raised into irregular prominences. Hence anterior staphyloma scleroticæ [fig. 49], is distinguished into *partial*, and *total* or *circular*. The latter is sometimes called staphyloma of the corpus ciliare. As the conjunctiva and the sclerotica are both distended and thinned, the affected portion of the eyeball has a dark color, and sometimes a decided blue appearance. The cornea and iris are found in a nearly normal state. Sometimes they participate in the affection, and the front of the eye presents an irregular or tuberculated enlargement, partially opaque and white, in other situations thinner and semi-transparent or blue; in which the boundary of the sclerotica and cornea is sometimes hardly to be traced.*

Fig. 49.

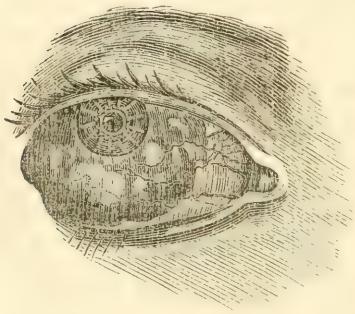

Mr. Briggs† has mentioned an interesting case of partial anterior staphyloma scleroticæ in a patient thirty-two years of age. There was a dark purple tumor on the upper and outer part of each eyeball behind the edge of the cornea, producing a slight elevation in the corresponding portion of the upper lid. The disease has been increasing during ten years, with slight pain only at intervals; and on one side no pain had been experienced. Sight was very imperfect, and the pupil was irregular in one eye. The part was punctured on one side with a fine needle; a considerable quantity of limpid fluid escaped, and the part became flaccid and paler. Mr. B. did not see the case again.

The existence of lateral and posterior staphyloma scleroticæ is only detected on dissection. An example of the former is delineated by Ammon, (tab. 7, fig. 7 and 12. Another delineation will be found in Froriep,

* Representations of anterior staphyloma scleroticæ may be seen in Ammon's Klinische Darstellungen, pt. 1. Fig. 20, tab. 4, is a view of the affection when the sclerotica is uniformly enlarged in front, the cornea and iris being normal. From various views of the same eye dissected, in tab. 7, figs. 8, 9, 10 and 11, the disease appears to have been general dropsical enlargement of the globe, the choroid, retina and iris not being much altered. Tab. 4, fig. 21, and tab. 5, fig. 17, are other views of the disease; in the first of which the whole anterior portion of the sclerotica forms a large tubercular prominence. In tab. 7, fig. 6, we have a view of the entire globe, where the anterior half of the sclerotica was involved: while in fig. 5, a circular staphyloma is represented, occupying the middle portion of the membrane, the anterior and posterior parts not having suffered. An anterior staphyloma scleroticæ is represented by Froriep *de corneitide scrofulosa;* fig. 8, and by Mr. Tyrrell, vol. i. pl. 2, fig. 6.

† Translation of Scarpa, p. 399, note.

fig. 7.) He had the opportunity of examining the eye, and found the sclerotic enlargement filled with fluid, which had pressed the choroid inwards.

SCARPA has described and figured two cases of posterior staphyloma sclerotiçæ, which he dissected. The enlargement occupied in both, as in all the other recorded instances, the temporal side of the optic nerve. The swelling was formed by the sclerotica and choroid, rendered extremely thin; the retina did not enter the enlarged part. The vitreous humor was of watery consistence. In one of the cases it was known that sight had been lost some years before from an obstinate ophthalmia attended with most acute habitual pain in the head.*

Two examples of posterior staphyloma are represented by AMMON; a small one in an early stage, where the swelling was lined by the choroid and retina (tab. 7, fig. 14 and 15); a larger, in which the distended tunic had yielded, the retina was in a partially collapsed state from fluid effused between it and the choroid, and the crystaline had passed backwards into the middle of the globe. (Tab. 7, fig. 7.)

SECTION IV.—CYSTS AND TUMORS OF THE SCLEROTICA.

CASE I.—*Small watery cyst in the sclerotica of a child; successfully treated by cutting away the prominent portion of the cyst.*—A child, ten years old, had a semi-transparent firm oval swelling, as large as a small pea, on the sclerotica, close to the margin of the cornea, where its existence had been noticed for some years. There was no change in the conjunctiva. It had been punctured; watery fluid escaped, and the accumulation was soon renewed. Two or three gentlemen, who had seen the case, advised that no further proceeding should be resorted to. As the swelling already constituted a slight blemish, and was increasing in size, my recommendation of an operation was readily adopted. I punctured the cyst, and then cut away its prominent portion with curved scissors. It was thin but tough, the sides being firm enough to retain the figure of the swelling after it had been opened. The interior was smooth, and a small round aperture was seen in the middle of the basis, apparently passing through the sclerotica. The surface exposed by the operation slowly healed over without any unpleasant symptom, and the blemish was completely removed. At the distance of two years from the operation, the eye continued perfectly well.

CASE II.—*Larger cyst of the sclerotica; excision of its prominent portion.*—A gentleman, about thirty years of age, of robust frame and full habit had lost one eye by violent inflammation, which had caused extensive opacity of the cornea, with adhesion of the iris. A cyst formed in the sclerotica, and slowly acquired the size of an almond, not only increasing the deformity, but also causing irritation in the motions of the globe and lids. I removed the exterior portion of this bag, as in the last case; but I did not see the patient again.

Scrofulous tumors on the sclerotica.—"I have seen," says Mr. MACKENZIE, "several cases of albuminous or scrofulous tumors, originating from the sclerotica, sometimes single, sometimes in clusters, soft in some cases, firm in others, but with little or no vascularity. The subjects of such affections were always cachectic children, and the affected eyes had generally suffered from internal scrofulous ophthalmia before the appearance of the tumors. Several of the patients died of chronic disease of the lungs." Op. cit., p. 601.

* Translation by BRIGGS, p. 400. Pl. 2, figs. 9 and 10.

A short notice of three cases is subjoined.

Von Ammon has delineated a dark-colored excrescence slightly lobulated, with smooth surface, growing from the sclerotica near the margin of the cornea, which it overlapped. It was equal in size to a large filbert, and the eyelids scarcely covered it; occasionally it bled a little. In appearance it might have been considered melanotic; but the normal condition of the iris, and other internal structures, rendered this supposition inadmissible. It had been treated with escharotics. It was removed by the knife, leaving behind merely a slight mark, showing where it had grown from the sclerotica.*

I have referred to two figures, representing a morbid condition of the sclerotica in a note to p. 316.

CHAPTER XIV.

DISEASES OF THE CORNEA.

SECTION I.—INFLAMMATION OF THE CORNEA.

Although the vessels of the cornea are not visible in the normal and perfectly transparent state of the texture, they become enlarged under inflammatory excitement, whether acute or chronic, and admit red blood; and they are sufficiently numerous to allow of the part becoming generally red under active or long-continued congestion. The various results of disturbed vascular action, such as union by adhesion, interstitial deposition, softening, thickening, induration, ulceration, cicatrization, suppuration, mortification, occur in the cornea as rapidly and perfectly as in structures of which the vessels are larger, and apparently more numerous.

Inflammation of the cornea may be either acute or chronic; but its course and character are most frequently of the latter description; at least it produces interstitial deposition and opacity, or ulceration, much more frequently than the more serious results of suppuration and mortification. In general the appearances commence gradually and proceed slowly. The vessels of so dense a texture do not easily become enlarged; considerable excitement is necessary to produce this effect; hence the uneasiness is greater than the mere degree of visible change would lead us to expect. For the same reason recovery is tedious.

The affection of the cornea may be primary or idiopathic; the inflammation, excited by causes acting directly on the part, beginning in the cornea, and extending more or less seriously, according to its degree, to the neighboring and connected parts; viz., the sclerotica, conjunctiva, and surface of the anterior chamber; or, the disorder may commence in the conjunctiva and sclerotica, more particularly in the former, and spread to the cornea, the latter suffering as a part of the external coverings of the globe.

I have already shown how the cornea is involved in external inflammations of the eye, particularly in the purulent, scrofulous, and various ophthalmiæ, and have described in the chapters devoted to those subjects, (chapters vii., viii., ix. and x.,) the phenomena and results of its mortification, suppuration, and ulceration, as well as those of effusion into its texture and consequent opacity.

Sloughing of the cornea may occur in consequence of acute inflammation

* Klinische Darstellungen, pt. 1, tab. 21, figs. 12—15.

of the conjunctiva. In this shape I have seen it only in the purulent ophthalmia of newly-born infants (see p. 231), and in gonorrhœal ophthalmia (see p. 281), or it may be seen in conjunction with great general weakness, and reduced local action, as in some cases of variolous ophthalmia (see p. 312). Mr. MIDDLEMORE says that old persons are sometimes affected with gangrene of the cornea from a very slight degree of inflammation, and occasionally without any previous inflammation whatever. The loss of vitality in the cornea, under such circumstances, has been considered analogous to the mortification of the toes in old persons.

In cases of this description, the strength must be supported by good diet with a proper allowance of beer, wine, or both. Mild astringents, such as solution of alum, sulphate of zinc, nitrate of silver, may be used locally.

Suppuration of the cornea has been already spoken of at pages 168, 248, 282, and 314; and some further remarks on the subject will be found in a future part of this chapter.

The vessels of the cornea may become enlarged, so as to admit red blood, under the influence of direct excitement in external inflammation. This is most frequently seen in young subjects. The vessels are so minute, that close observation, or the use of a glass, is sometimes necessary to show that the red appearance is vascular. They are closely arranged, and form, on the margin of the cornea, a band, which gradually becomes broader. These vessels are obviously derived from those of the conjunctiva. Whether they are derived from vessels belonging to the surface of the membrane, or from those situated between the conjunctiva and the sclerotica, are questions which we cannot as yet satisfactorily answer. In a child, eight years of age, laboring under an attack of external ophthalmia, this state of the cornea was strongly marked. By two applications of leeches, and other antiphlogistic measures, the eye became well in a week. The distended vessels contracted, and the portion of cornea, which had been reddened, was again quite transparent.

When the inflammation begins in the cornea, the case is properly termed inflammation of that membrane (*corneitis*, *ceratitis*, or *keratitis*).

Acute corneitis with suppuration.—I suspect that the variolous ophthalmia, in its secondary form, commences with affection of the cornea, that is, with the development of an inflammation analogous to the variolous pustule of the skin: the inflammation, which is of acute character, soon extends to the sclerotica, so that when our attention is drawn to the case, it appears as an inflammation of the external tunics generally. See p. 313.

In the THIRD CHAPTER, *on wounds of the eye*, at page 168, I have spoken of inflammation of the cornea as the consequence of mechanical injury, and have described both the milder form of the affection, and the more serious degree, which proceeds to suppuration and hypopyon.

When active inflammation of the cornea causes suppuration, the sclerotica and conjunctiva participate in the local excitement, the latter often passing into the state of chemosis. The cornea becomes dull, then grayish; it turns white, cloudy, and then yellow, as if pus were deposited in its texture. In fact, we may say that the cornea has suppurated; the only objection to such an expression being that the matter thus deposited, though yellow like pus, is not fluid, but of a thick consistence, viscid, and apparently infiltrated, in the corneal texture.* If we puncture the part, matter does not escape; it does not make its way to the surface, point, and discharge, like the contents of an abscess; but the cornea ulcerates; the newly deposited yellow substance is exposed, and gradually removed by ulceration. A similar process

* Mr. MIDDLEMORE states that the effused matter is either lymph, or a somewhat consistent and tenacious substance, which he calls *puro-lymphatic;* vol. i., p. 459.

seems to occur internally, at least an effusion takes place into the anterior chamber, and a yellowish substance falls down to the bottom of it, producing the phenomenon of hypopyon. We can sometimes distinguish the ragged opening, by which the yellow substance has escaped, and we even see small yellow shreds hanging from it. Corneal suppuration is discharged into the anterior chamber more frequently than externally.

The cornea sometimes bulges where suppuration has taken place; but more frequently its figure is unaltered. The matter formed in the cornea may be more fluid and constitute a small abscess.

When the cornea suppurates generally, ulceration may extend into the anterior chamber at more than one place, the aqueous humor escapes, the iris comes in contact with the inflamed and ulcerated cornea, and is often protruded at one or more points. When the inflammation subsides, the cornea is opaque, the iris adherent to it, and the anterior chamber abolished; in short, the eye, so far as the purposes of vision are concerned, is lost. Sometimes matter is only deposited in one point of the cornea; there is a yellowish appearance at this spot, and a general nebulous whiteness pervades the rest of the structure. In this case, if the ulcerative process has taken place, its further progress may be checked, and the ulcer may heal; or, by active treatment, ulceration may be altogether prevented: the matter will be absorbed, the cornea nearly regain its natural appearance, and vision be restored entirely, or with little defect.

It has been commonly represented that when the cornea suppurates, the effused matter insinuates itself between the laminæ, finds its way to the bottom, and accumulating at the lower edge, produces there an appearance which has been called *onyx* or *unguis*, from its resemblance to the mark at the root of the nails. I believe that the cornea is too dense to admit of this mechanical sinking of the matter, and cannot say that I ever saw onyx in this sense. I believe that the matter remains in any part of the cornea, in which it may have been deposited.

The appearance similar to the white mark at the root of the nail takes place where matter is effused into the anterior chamber, that is, in *hypopyon*, rather than in suppuration of the cornea or onyx.*

As the suppuration of the cornea frequently makes its way into the anterior chamber, onyx and hypopyon will be seen together in many instances. In other cases they occur separately; the corneal suppuration may break externally, or the effused matter may be absorbed under proper treatment, so that hypopyon does not take place. Again, hypopyon occurs in inflammatory affections of the eye, not involving the corneal substance. See the chapter on inflammation of the aqueous membrane. The two cases might be confounded on superficial inspection: it is important to distinguish them, since the violence of the malady, and the danger to the organ, are much greater in suppuration of the cornea than in hypopyon, and a more active treatment is required in the former case. In onyx the inflammation of the sclerotica and conjunctiva is of the most acute character, proceeding commonly to chemosis, which is firm from the effusion of fibrine. The other local symptoms and the constitutional disturbance correspond. The general inflammatory affection is much milder, and often inconsiderable in hypopyon. In the latter, the yellow appearance is of definite form, and confined

* As these terms are often employed incorrectly, I subjoin the explanation of them from Lexicon Medicum of Blancard, edited by Kuhn.

Onyx; abscessus inter lamellas corneæ.

Hypopyon; puris sub tunica cornea in cameris oculi collectio.

Blancard defines *hypopyon*, a word employed by Galen, "Sugillatio, sive sanguinis effusio sub palpebris et adnata oculi, aut sub palpebra inferiore."

to the bottom of the anterior chamber, while in onyx the figure is irregular, the outline indefinite, and the appearance may be found in any part of the cornea. In hypopyon the cornea generally may be little altered, or merely exhibit a dullness or slight grayish cloud; the matter, on careful examination, will be seen behind it. In onyx a more or less dense whiteness surrounds the yellow effusion, often occupying the entire cornea, while the suppuration comes to its very surface, so that we cannot discern a nearly healthy cornea covering the matter. The level of the matter is changed when the position of the eye is altered in hypopyon; no such change is seen in onyx.

Suppuration produces ultimate changes in the cornea and iris, which are often destructive, almost always more or less injurious to vision. These are, destruction of the corneal substance by ulceration; adhesion of the iris, and extension of the weakened and adhering structures into the opaque swelling of staphyloma; abolition of the anterior chamber, and flattening of the front of the eye; opacity of the cornea in various degree and extent, with or without adhesion of the iris (*synechia anterior*), or prolapsus iridis, and consequent displacement or contraction of the pupil. The corneal opacity, the adhesion of the iris, and the changes in the iris and pupil, may be variously combined; they may be so related to each other as to intercept the passage of light, to impair vision, or to leave it uninjured. In the most favorable termination of the disorder, some opacity of the cornea will remain.

The indications of treatment are, to arrest the local disturbance, or diminish its violence; to prevent effusion, and to promote absorption of what has been already poured out. Free depletion and other antiphlogistic measures are required in the outset; these means are to be followed by the use of mercury.

Regarding the suppuration of the cornea in the light of a common abscess, some have advised puncture to let out its contents. As the effused matter is thick and viscid, and usually infiltrated, it does not escape on puncture, so that the proceeding fails so far as the object of discharging the contents of the corneal abscess is concerned. I have not seen any advantage from such punctures. Mr. Middlemore states that he has been compelled to puncture on many occasions in order to relieve pain, but without any expectation of saving the cornea. He adds that he has seen many bad cases recovered by the use of mercury; but that the same fortunate result has not been obtained in similar cases, where the incision alone has been made.* Mr. Tyrrell says, "When the abscess is extensive, and the pain severe, with a distressing sensation of tension, I consider it proper to puncture the cornea, more with a view to relieve the suffering than to hasten the cure; for the matter is rarely so fluid as to escape by a small aperture, but the larger part appears to be removed by absorbents."† Mr. Mackenzie‡ observes that it is a rule generally agreed on not to meddle with small effusions; that he has frequently punctured larger ones with the lancet, and staphyloma has always resulted, while the eye has sometimes recovered almost perfectly, where he had left large collections untouched. He states afterwards that large abscesses must be punctured in order to relieve the pain, but that the puncture must be repeated several times. If the suppuration be extensive, and the pain very great, puncture of the suppurated portion may be tried; the eye will probably be irreparably injured by the progress of the malady. The evacuation of the aqueous humor would probably afford more effectual relief.

By the inflammation, which produces suppuration of the cornea, its tex-

* Vol. i., p. 462, 463.

† Practical Work, vol. i., p. 236.

‡ Practical Treatise, p. 539, 540.

ture is softened; thus it is found flabby, and does not resist the knife when an attempt is made to puncture it after ulceration has taken place externally, or after the escape of the matter into the anterior chamber.

If suppuration of the cornea should assume the chronic form, and occur in an unhealthy or enfeebled constitution, a different course of treatment must be pursued. Direct depletion must be avoided altogether, or employed sparingly and cautiously; local bleeding will suffice. Mild counter-irritation will be useful. We must endeavor to restore and maintain general strength by suitable regimen and tonic medicines, with which the milder mercurials may be combined.

Inflammation of the cornea, especially when spontaneous, causes in the great majority of instances enlargement of the vessels, so that they carry red blood, and interstitial deposition, rendering the membrane opaque. On the first view the inflammation might be considered chronic, but the local and general symptoms mark an acute affection; and its particular characters, the enlargement and distension of vessels, and the opaque change in the part, arise from its peculiar structure.

The complaint begins with dullness of vision, the cornea being at the same time hazy. It loses its transparency, and exhibits a general cloudiness, with increasing imperfection of sight, objects appearing as if seen through a cloud or mist. This nebulous condition of the cornea, as it is frequently called, may be general or partial: in the latter case it is continued insensibly into the healthy structure. The cornea may be generally of a dull gray color, or like ground glass; it may exhibit the various degrees of change from haziness to nebula, or to opacity so dense as to conceal the iris and pupil, or to render them quite invisible. The opacity, which begins at the circumference, and gradually extends, is generally unequal, so as to give a cloudy or smoky appearance, clearer portions being interspersed among the more opaque parts, and vision being more perfect than the general appearance of the cornea would have led us to expect. The opaque spots are sometimes of a yellowish color, as if something like matter had been deposited; perhaps there is a kind of suppuration in such cases. The surface of the cornea loses its polish, assuming a finely granulated appearance, as if it were covered with fine sand, or minute drops of dew. This change, which commences in the onset of the affection, with cloudiness or mistiness of vision, gives the eye a very dull appearance, even before there is much general opacity. Is this irregularity of surface caused by minute vesicles of the corneal conjunctiva, by expansion of its texture, or by effusion under it?

While these changes are proceeding, we shall usually observe an alteration in the external vessels of the eye. A few distended trunks may be seen in the conjunctiva, running towards the margin of the cornea; but we find more constantly distension of the deeper trunks lying on the sclerotica. Their small and straight branches run forwards and are continued into the substance of the cornea. When the opacity is partial or unequal, this distinction of the deeper vessels is observed where the change has gone to the greatest extent. As the affection proceeds, the opacity becomes more considerable while the apparent number and the distension of the vessels are increased. The circumference of the membrane assumes a brownish-red tint, and appears on first view to be discolored throughout its texture. Closer examination shows this apparent discoloration, which represents a band round the cornea, seldom complete, to arise from a countless multitude of minute vessels. The edge of the discolored part is sometimes regularly defined, sometimes not; it may be broader at one part than at another. It is sometimes slightly elevated. It may be partial, and, as it follows the

edge of the cornea, it has a crescent shape. The blood-vessels ramifying in the cornea are obviously derived from the trunks lying on the sclerotica. The dull brownish-red color of the vessels shows that they are not superficial. The conjunctiva often retains its natural paleness, while the vessels under it are turgid and the whole sclerotica is covered by a plexus of distended ramifications, which form a pink zone round the cornea. There is a singular contrast in these cases, between the brownish-red circumference and the opaque interior of the cornea.

In the more acute cases the conjunctival vessels are distended; not, however, so as to conceal the changes which have occurred in the more deep-seated plexus; and the sclerotica generally has a rose or pink tint. A slight cloudiness of cornea may be produced and continue without visible increase of vascularity.

Considerable pain and sense of tightness in the eye, and pain in the brow or forehead, often accompany the affection, especially in its early stage, in which we find white tongue, headache, and general feverishness. There is increased sensibility to light, which is the more remarkable, as the changes in the cornea must diminish the quantity admitted into the eye; it must be remembered, that the sclerotica is involved in the inflammation, and that intolerance of light usually occurs when that membrane suffers. These symptoms are attended with lachrymation, especially on exposure to light.

The inflammation may proceed with some rapidity, and be attended with feverishness. On the other hand, it is often of long duration, continuing for many months; and it does not proceed to suppuration. Often, after going through an acute stage, with pain and feverishness, it assumes a more indolent character and is protracted indefinitely: the disease lasts, but the patient does not suffer.

Corneitis may be brought on by external agencies, by cold, damp, or atmospherical vicissitudes. More commonly it owes its origin to internal causes, seeming to come on spontaneously. It is most frequent in the young, and seldom seen after the middle period of life. It occurs in those of unhealthy constitutions, especially the strumous; or where the general powers have been considerably reduced.

The iris is generally involved, to a greater or less degree, in corneitis; it may suffer considerably if the inflammation be active, and allowed to proceed unchecked. Hence arise contraction of the pupil, effusion of lymph, and consequent permanent adhesion of its margin to the crystaline capsule, and discoloration of the iris.

Prognosis.—Under proper treatment, the interstitial effusion of the cornea is removed, the membrane regains its transparency, and vision is completely restored. The iris, however, sometimes exhibits, after such recovery, a darker tint, with a little loss of brilliance; and thus the eye has a somewhat dull appearance. Under less favorable circumstances the cornea loses its transparency, and becomes changed in various degrees from leucoma to slight nebula. The iris is dull, and dark colored, the pupil adherent, and there may be opacity in the opening.*

Treatment.—When acute, corneitis requires pretty active antiphlogistic measures. If stimulants and astringents are employed, as they sometimes have been, on account of the opacity, without proper consideration of the other circumstances, the symptoms are aggravated, and the recovery is rendered difficult. The local abstraction of blood by cupping on the temples, and by leeches, or other antiphlogistic means are necessary. The loss of

* Ammon has represented, in numerous figures, the principal appearances and effects of corneitis. *Klinische Darstellungen*, pt. 1, tab. 3.

blood may be repeated from time to time if the symptoms should require. Subsequently, the use of mercury, perhaps carried to the length of slightly affecting the mouth, is the most efficacious means of checking the inflammation, and restoring the transparency of the part. The occasional use of leeches might be combined with this plan. Counter-irritation by blistering or by the emetic tartar ointment will be a useful auxiliary measure.

As the complaint is formed and proceeds slowly, the influence of treatment is gradual, and steady perseverance is necessary to insure success. When the treatment takes effect, and especially when the mercury acts decidedly, the vessels of the cornea contract, and the newly-deposited matter is absorbed, the cornea regaining its transparency, even where it had become generally and rather densely opaque. It clears first in the circumference, the favorable change gradually advancing towards the centre.

If the iris should participate in the affection, there is an additional reason for the use of mercury. When the constitution is naturally delicate, as it commonly is in those affected with corneitis, or where its powers have been reduced by disease and treatment, all measures of depressing influence must be avoided as much as possible. Even leeches to the eye would not be admissible, unless strongly required by the local symptoms. Mercury must be cautiously employed in small doses, and combined with tonic and strengthening medicines, such as bark or steel, with good diet and the other restorative influences.

Case.—A young woman, of pallid countenance and delicate frame, about twenty years of age, came to the London Ophthalmic Infirmary, complaining of loss of sight in the right eye. There was considerable general opacity of the cornea, which had destroyed all useful vision, redness of the sclerotic coat, uneasiness on exposure to light, and increased lachrymation. She said that she had been ill six weeks; that she had been under the care of a surgeon in her neighborhood, and that by his direction she had been putting drops into her eye, which made it very sore and painful; however, as she was directed to do so, she persevered in using them. When she showed me the prescription, I found that these drops were a solution of the oxymuriate of mercury. In this case it was necessary to take blood by cupping repeatedly, to apply leeches several times, to use mercury freely, to put an issue in the temple, and to persevere in these measures, variously combined and repeated, for a long time before the inflammatory action was removed. The cornea has not completely regained its transparency, nor was the sight fully restored until nearly the end of a year, during the greater part of which time she was using mercury more or less actively. In a few months she came again to the infirmary, and said that she had the same complaint coming on in the left eye; she found the sight dim, and had considerable pain in the head; in short, the same symptoms which she had before complained of in the other eye. We had an opportunity of treating this eye from the first. We took blood from the temple by cupping, and employed the other treatment I have just particularized, and in six or eight weeks the complaint was completely put a stop to, although the cornea was generally nebulous when she came. The difference of treatment was very striking, and the results were equally so.

Partial inflammation of the cornea.—Most frequently inflammation affects the entire cornea, especially in young persons. Sometimes, however, about or after the time of puberty, the affection commences in one spot; other points become affected in succession, and thus disease may gradually extend over the whole. Pain has been felt in the eye; partial dullness is found at one point near the edge of the cornea; a little redness is seen on the external surface of the eye, corresponding to the nebula

corneæ. On close inspection, this redness proves to be seated in the sclerotica, and the conjunctiva is unaltered; enlarged vessels are seen on the sclerotica, and we find minute ramifications extending from them on the cornea. Another patch of nebula occurs, and ultimately the whole cornea, or the greater part of it, is affected.

Case.—A young lady, about sixteen, of florid complexion and full habit, had an attack of external inflammation in the left eye, from which she had recovered under active treatment. She began to complain of the right eye; some of the sclerotic vessels were enlarged, and the corresponding portion of the cornea, near its margin, was nebulous. Active antiphlogistic treatment did not prevent the progress of the inflammation, and its extension into general inflammation of the cornea, for which a long-continued course of treatment, by purgatives, mercury, and issue, was required.

In a young boy, of rather pale and languid appearance, the same progress was observed. He had an attack of external inflammation, which got well, when partial corneitis came on, and gradually extended over nearly the whole cornea. It was accompanied with chronic iritis, and partial adhesion of the pupil took place. Issue in the temple, and mercury, ultimately removed the affection, but not till after a long time.

In another patient, nearly thirty years of age, of light complexion and pallid appearance, partial inflammation of the cornea showed itself first, and fresh portions of nebula appeared successively, till the affection became general. But in this, and in the last case, the inflammation was in roundish patches, the intervening portions being comparatively transparent. The central and most opaque part of these patches had a slight yellowish cast. Here too the iris was involved. The same treatment was successful.

In a young lady of delicate habit, about twenty-four, patches of opacity showed themselves in the lower half of the cornea. They were small, roundish, dense, and yellowish in the centre, and shaded off at the circumference. After antiphlogistic treatment, mercury and issue were employed. Considerable benefit was produced, when the mouth became affected. The treatment was interrupted, and relapse occurred; it was resumed, the mouth was again affected, and the influence was kept up for some weeks without much benefit. The affection, indeed, began to show itself in the upper portion of the cornea, which had been previously clear. I did not witness the termination of the case.

Local applications are not of much advantage. In the inflammatory period, and when intolerance exists, fomentations are most comfortable to the patient. Stimuli and astringents are hurtful so long as active inflammation exists. When that is removed, and the complaint is beginning to yield, the vinum opii, or the four grain solution of lunar caustic, may be tried, and a small portion of the mild red precipitate ointment may be introduced between the lids at night.

*Strumous inflammation of the cornea** (*corneitis scrofulosa* or *strumosa*).—Inflammation of the cornea frequently occurs in scrofulous persons; its local characters and its real nature do not differ essentially from the description already given; it cannot, therefore, be regarded as a peculiar or distinct affection. The entire cornea becomes dull and hazy, and then exhibits a more or less deep nebulous opacity, the surface having the sanded appearance already described. The conjunctival vessels are not much

* Remarks on Strumous Corneitis and Iritis, by Mr. James Guthrie, Edinb. Med. and Surg. Journal, vol. xxix., p. 315. The Dissertatio Medica de Corneitide Scrofulosa of Dr. R. Fhorief, Jenæ, 1830, contains a good description of the affection, with some of its consequences, and some excellent figures.

distended; but there is a deep-seated pink redness, from fullness of the trunks on the sclerotica, the minute straight branches of which form a zone round the cornea: when the affection is very active, minute twigs of the conjunctival vessels join the zone, which has a bright redness round the cornea. A dull reddish-brown discoloration is seen in the cornea, at its circumference, generally partial. This depends on an aggregation of minute vessels filled with blood, and ramifications are easily distinguished, proceeding from the red zone to such discolorations. That the latter are owing to stagnation of blood in the minute vessels of the cornea is an opinion expressed by Dr. Froriep, for which I see no sufficient ground.

Lachrymation and intolerance of light are common to this affection with ordinary strumous ophthalmia; and it is not usually attended with pain in the eye or head.

The constitution suffers; the pulse being quick, the skin hot and dry, the tongue white, the appetite deficient, and the bowels costive.

The opacity of the cornea varies in degree. The pupil can be seen through it more or less clearly in some cases; in others the iris and pupil are entirely concealed.

Like other strumous affections, this is obstinate, yielding difficultly to treatment, and liable to relapse.

The iris probably suffers with the cornea, though its condition is concealed by the changes going on in the latter membrane.

Formidable as this affection appears, when fully developed, it yields to treatment, and the normal condition of the inflamed textures is restored. It may however terminate in leucoma, contracted and adherent pupil, which may be closed more or less completely by an opaque adventitious membrane, disorganization of the iris, and diminution or loss of sight. Under long continuance of the affection, which must no doubt be attended with increased secretion of the aqueous humor, the anterior chamber is enlarged, and the cornea may be even altered in figure.*

Treatment.—Abstraction of blood is generally inadmissible, as in strumous inflammation of the conjunctiva. The alimentary canal should be cleared; and the sulphate of quinine may then be administered with great advantage. Mercury may be combined with this remedy, if the opacity of the cornea does not give way. The moistened extract of belladonna may be smeared on the brow, to prevent contraction of the pupil, and lessen the irritability of the eye. Tepid fomentations are the most agreeable local application; a little laudanum may be added to the liquid. Mild counter-irritation may be employed, if the disease does not yield to the means already specified. Under such circumstances a local stimulus may be tried, such as the vinum opii, or a two grain solution of the nitrate of silver.

[Mr. Obre has treated two cases successfully with turpentine, in doses of from half a drachm to a drachm three times a day, (*Am. Journ. Med. Sci.*, July 1842, p. 205.) We have used the syrup of iodide of iron and also the iodide of potassium, in some cases with advantage. But we have found no remedy to exert so complete a control over the disease as mercury, and in some cases we have resorted to it successfully after all other measures were found ineffectual. It was given in small doses continued for a considerable time; the remedy being stopt as soon as any symptoms of

* A slight change of this kind is exhibited in Froriep's Dissertatio, fig. 5. He also enumerates staphyloma corneæ among the consequences of the disease, as well as staphyloma scleroticæ, and staphyloma corporis ciliaris. The latter changes must be consequences of an affection more general than corneitis. Considerable enlargements of the cornea, with and without partial opacity, are delineated by Ammon, Klinische Darstellungen, pt. 1, tab. 3, figs. 18—21.

ptyalism manifested themselves and resumed again when these had disappeared.]

In the observations already quoted, Mr. J. GUTHRIE recommends emetics and Dover's powder, to remove the constitutional irritability, which in general is strongly marked.

Inflammation of the cornea with vesication.—Under this name Mr. TYRRELL (vol. i., p. 241), describes an external inflammation attended with great irritability of the eye, with the troublesome symptoms coming on in paroxysms, occurring in adults whose general health has been impaired. "A partial nebulous condition of the cornea exists, in the centre of which a small vesicle distended with fluid may be perceived, if the eye be examined during the paroxysm; otherwise a thin portion of loose membrane, which is partially separated, much as the cuticle is after puncture of a cutaneous vesicle." Local applications are unavailing, and we must depend on general means, among which the warm bath has been found particularly beneficial.

[*A peculiar affection of the cornea in nurses.*—Professor NASSE describes an affection of the cornea, which he says is peculiar to nurses, is not of a malignant nature, and appears at any time during the whole period of nursing, from a month after delivery to a year and a half, if the child be suckled so long. The eye is felt irritable, and the conjunctiva is seen injected with blood. Occasionally the catarrhal symptoms attend the complaint; at other times little vesicles appear over the surface of the conjunctiva. Sometimes rheumatic symptoms are present, at other times it comes on with a vesicular cutaneous eruption over the face. The conjunctival inflammation rapidly passes to the cornea, and is accompanied by the usual darting pains in the eye and margin of the orbit. From the third to the eighth day an abscess forms within the layers of the cornea, when the inflammatory symptoms diminish, and, if nothing be done to put an end to the complaint, it bursts into the anterior chamber and occasions hypopyon.

The disease is not peculiar to any age, constitution, or season; but it is in every case preceded by great lassitude, debility, and leanness, brought on by excessive lactation, in fact, seems to be a disease of debility. Blood-letting is consequently never indicated, but blisters behind the ears, diaphoretics combined with bitter infusions, quinine and sulphuric acid, a tonic diet, and, above all, the giving up suckling the child, generally effect a cure in about three weeks. It is mentioned that the separation of the child is the most important part of the treatment; and cases are related where the child being allowed to suckle before the cure was completed, brought it back with increased severity, and could not be stopped till the child was again removed, when the disease rapidly gave way.—AMMON's *Monatschrift fur Medicin.*, Nov., 1841.]

SECTION II.—VASCULARITY OF THE CORNEA.

The nutrient vessels of the cornea become enlarged in disease, so as to convey red blood, the state thus produced being called vascularity of the cornea. The enlarged vessels may be those of the conjunctival layer, and consequently superficial; or they may be more deeply seated, perhaps in the corneal laminæ. A few vessels or fasciculi may be visible, or the whole texture may be reddened by a countless multitude of ramifications. This unnatural vascularity may result from the direct excitement of active inflammation; and the change in question has been already mentioned among the effects of common external inflammation, (see p. 336,) of strumous

ophthalmia, (CHAPTER X,) and of inflammation of the cornea, (CHAPTER XIV.) The enlarged vessels contract, and the vascularity disappears under the influence of the means by which inflammation is reduced. Vascularity of the cornea is seen more frequently as the slow consequence of chronic irritation. This is the case in purulent ophthalmia, where it is produced by the mechanical irritation of the diseased palpebral conjunctiva, (see CHAPTER VIII, p. 268,) and in strumous ophthalmia (see CHAPTER X, p. 308,) where the enlargement of vessels, and the loosening of texture, proceed occasionally to such an extent, that the corneal conjunctiva can hardly be distinguished from that of the sclerotic.

The only question which remains for consideration is, whether the effect of the treatment elsewhere described, can be assisted by the operation of dividing the vessels; for example, by cutting out a piece of the conjunctiva round the margin of the cornea in pannus. The deep-seated vessels cannot be divided; the proceeding, therefore, could only be beneficial where the enlargement is confined to those of the mucous surface. I have seen no decided benefit from it; but there can be no objection to trying it in a suitable case, which remains unrelieved by a sufficient perseverance in other measures.

SECTION III.—ULCERATION OF THE CORNEA.

In its natural structure, consisting of cartilaginous laminæ and mucous membrane, the cornea is analogous to the articular ends of bones, in which the dense cartilage is covered by synovial membrane. Both are prone to ulceration, and the process in both exhibits this peculiarity, that no granulations are seen and no pus is formed. It appears as a simple process of absorption.

Fig. 50.

Ulcers of the cornea occur frequently in inflammation of the external tunics; in the purulent and strumous ophthalmiæ; and I have described their phenomena, progress, effects, treatment, and mode of reparation in the chapters on those subjects.*

Ulcers of the cornea may be small or large; superficial, and confined to the conjunctival layer, deeper, and affecting the corneal texture, or even penetrating the anterior chamber; inflamed and spreading, stationary, or healing.

In the superficial ulcer there is a mere removal of the thin conjunctival layer, producing an appearance like that of excoriation in the integuments.

When the loss of substance extends more deeply, the excavation is more or less funnel-shaped.

The figure of the ulcer may be regular or irregular; its surface and edge smooth or unequal.

The state of surface left by the separation of a slough, the characters of the ulcers while spreading, and their appearance under the process of repair, are mentioned at pages 232, 281, and 283.

The ulcerative process in the cornea, as in other textures, is an effect of inflammation, at least in the great majority of instances: to represent the latter, as produced by the irritation of the former, would be to invert the order of occurrences. The ulcer, however, being attended with inequality

* See CHAP. VII. p. 232; CHAP. VIII. p. 249; CHAP. IX. p. 283; CHAP. X. p. 303; CHAP. XI. p. 312.

of surface, may be a source of irritation to the eye, in the movements of the globe and lids. We employ the same treatment that we should for an inflammation not attended with ulcer; and, if we succeed in arresting the inflammatory disturbance, the ulcer will soon heal: no particular local treatment is required for this symptom.

[The preparations of hydrocyanic acid have great efficacy, according to M. Cabrier, in promoting cicatrization of the cornea. He employs the cyanide of zinc in the form of ointment, in the proportion of one part of the salt to twenty-five of lard.*]

When the ulcer is healing, we shall find it the best course to leave the case to its natural progress, employing merely tepid ablution. See pages 265 and 289. The notion that ulcers of the cornea require the use of lunar caustic has prevailed generally, and led to injurious practice. In the inflamed and spreading state of the sore, such treatment would be most mischievous: when the process of repair is going on properly, it is, at the least, unnecessary. Dr. Jacob† says that the caustic sometimes becomes perfectly fixed, and constitutes an indelible dark speck; an effect which I have not seen. Generally speaking I have found ulcers of the cornea go on most favorably under the usual antiphlogistic treatment, or such other general measures as circumstances might require, without the use of local stimuli or astringents.

When the ulcer is stationary, the affected part has its natural transparency; it may be difficult to discover it when small. By placing the eye so that the light shall fall on the part, the inequality of surface is soon recognized. It is sometimes seen as a small round or oval dimple. The appearance is just as if a small bit had been shaved off with a knife; and it resembles exactly the dent in marbles that children play with. Strengthening treatment may be required, when the healthy processes of repair are thus deficient. It may be useful at the same time to use mild astringents in solution, such as the sulphate of zinc or nitrate of silver, not stronger at first than in the proportion of two grains to the ounce. I never apply the caustic in substance.

When the ulcerative breach has been filled up, and the surface is restored, the cicatrix presents a glistening chalky white opacity, which is indelible. The ulcer may be surrounded by a more or less considerable opaque halo, which gradually disappears, diminishing the extent of the opacity. If the ulceration have been confined to the conjunctival layer, the surface will be restored without any diminution of transparency; should it affect the corneal substance superficially, the opacity will be nebulous; it is dense and leucomatous when the cornea has suffered in its whole thickness, either by ulceration or penetrating wound. If the latter has been a clean cut, and united by adhesion, as in the operation by extraction, union may take place without opacity, so that we cannot discern the course of the incision.

I have found cases of corneal ulceration peculiarly obstinate and intractable, when the surface of the ulcer has presented, generally or partially, an opaque white color, as if it had been covered by wetted chalk, the attendant ophthalmia not being considerable. Sometimes such ulcers have continued for weeks or months, in spite of every treatment. I do not know what the peculiarity depends on, but Dr. Jacob ascribes it to the application of the acetate of lead, which, he says, "is decomposed, and a white precipitate is deposited in the ulcer, to which it adheres tenaciously, and in the healing becomes permanently and indelibly imbedded in the structure of the cornea."

* Bouchardat, Annuaire de Thérapeutique, 1844.
† Dublin Hospital Reports, vol. v., p. 367.

I conclude that Mr. TYRRELL alludes to cases of the same kind in speaking of *inflammation of the cornea with deposition of earthy matter.* He shows clearly that the appearance cannot be explained by the use of lead lotion, and he recommends a weak solution of acetic or hydrochloric acid. He represents strongly the intractable nature of the affection in some cases. (Vol. i., p. 246.)

In obstinate cases of chronic ulceration, which, with little inflammation, will sometimes creep slowly over the cornea, healing on one side, while it advances on the other, I have found great benefit from issue in the temple.

The appearance called *hernia corneæ*, or *ceratocele*, sometimes attendant on ulceration of the part, has been noticed in the description of gonorrhœal ophthalmia, at page 283. The hernial protrusion of the membrane of the aqueous humor forms a transparent vesicle in the bottom of the corneal ulcer; this rises or protrudes when the muscles of the globe act, and subsides when that action ceases.

I have not considered it necessary or advisable to snip away this vesicle with scissors, or to apply the nitrate of silver in substance to the ulcerated excavation, having found the restorative process to go on quite favorably without such means. The application of belladonna might be useful to prevent the iris from becoming involved in the mischief.

A minute opening in the cornea has sometimes remained after ulcer or wound, giving issue occasionally to the aqueous humor. It is called *fistula corneæ*. Mr. MIDDLEMORE (vol. ii., p. 492,) has seen it as a congenital malformation.

SECTION IV.—OPACITY OF THE CORNEA.

The edge of the cornea frequently loses its transparency, throughout the whole, or in a part of its circumference, in elderly persons, at least in those past the middle period of life; and the opaque circle, or half-circle, thus formed, is called *arcus senilis*, or *gerontoxon.** The change comes on without any redness, pain, uneasiness, or the slightest impediment of function, and proceeds at length to render the cornea, in the part which it occupies, entirely impervious to light. The opaque circle is not situated at the very margin of the cornea; there is generally a comparatively transparent rim between it and the sclerotic coat. In some cases the opacity is very narrow, in others much broader; but I have never seen it interfere with vision. Although it has occupied a considerable portion of the cornea, enough of the central part has been left clear for the transmission of light. The color is at first bluish-white, and the opacity slight; it becomes more dense, and chalky white; at last the loss of transparency is complete, and the affected circle is a yellowish or grayish white, the tint being deeper towards the circumference, and gradually shaded off towards the centre of the cornea. Often it occurs on the lower half only; and sometimes it exists only in one eye, or is more considerable in one than in the other. It occurs much earlier in some individuals than in others, being occasionally seen between thirty and forty, but usually not until after the latter age. No essential difference has been found in the structure of the part;† there is no new growth,

* From γηρων, an old man, and τοξον, a bow.

† "I have often," says Dr. SCHON of Hamburgh, "examined anatomically, corneæ affected with arcus senilis, and found the affected portion changed into a homogeneous, sometimes fat-like (speckartige) mass, often of considerable firmness. The laminated structure had entirely disappeared, the laminæ being consolidated into one mass; this was more particularly the case with the external than the internal laminæ. I never

nor any deficiency of its usual density. I can only compare it to the change which takes place in the internal coat of the larger arteries in old persons. We see opaque spots and patches in the lining membrane of those vessels, although no disease has been apparent during life. In the same way this opacity of the cornea occurs without any evidence of disease, but merely as a change incidental to advancing age. BEER would call it *marasmus senilis corneæ*, a name which is objectionable, as implying the presence of disease, and inappropriate to a change of which I have seen an example, while these sheets are passing through the press, at the age of thirty-three. A puncture or incision in the arcus senilis heals just as well as in any other situation.

In the dissection of eyes affected with arcus senilis, a corresponding opaque change has been found in the circumference of the lens or capsule, more frequently of the latter. When the lower half only of the cornea has been affected, the internal opacity has been confined to the inferior portion of the lens or capsule.*

The cornea may be rendered opaque by the application of the chemical agents called escharotics, such as lime. This subject is considered in CHAPTER III, SECTION II.

OPACITY.

Opacities of the cornea are generally the result of disease, being produced by inflammation. New matter is deposited during inflammation, and becomes organized, thus causing the opaque change. Therefore when we see opacity, we infer that inflammation has preceded: and, generally speaking, the intensity of the opacity is in proportion to the violence of the preceding inflammation, as is exemplified in the purulent ophthalmiæ, and in the acute corneitis, proceeding to suppuration. This, however, is not necessarily the case, as certain inflammations of the cornea are characterized rather by the deposition of new matter, than by vascular congestion; so that considerable general opacity may be produced without much external redness of the eye, and a nebulous state of the membrane is sometimes seen without any other evidence of increased vascular activity.

The term opacity is a general one, including all the changes which affect the transparency of the cornea, from a difficultly perceptible film, to whiteness like that of marble or chalk. Opacity in its slighter form is called *nebula*, haziness, or dullness; there is a milky, cloudy, or smoky appearance of the part; a state in which the transmission of light is only partially impeded. The more dense opacities extending through the laminæ, are called *leucoma* or *albugo*.† The term *macula* is applied to small patches or specks. The popular word for opacity is *film*. The color of the opaque part is different in different instances; generally speaking, it is

found any alteration in the neighboring portion of the sclerotica. When the opacity has been inconsiderable, it has been confined to the conjunctival layer."—AMMON's Zeitschrift, vol. i. p. 162.

* Ueber den Marasmus senilis der Kapsel und Linse im menschlichen Auge, von Dr. M. S. A. SCHON; in AMMON's Zeitschrift, vol. i. No. 10.

This change in the capsule has been delineated by VON AMMON in his Klinische Darstellungen, part i. tab. 11, fig. 1 and 2, of which the former represents an opaque half circle in the anterior, and the latter a nearly complete circle in the posterior portion of the capsule.

† *Leucoma* and *albugo*, derived respectively from the Greek and Latin languages, are synonymous terms. *Leucoma* is from λευκος, white, and *albugo* from albus.

bluish white like milk, or gray; it may be pearly or silvery, even with a metallic lustre, or it may be dull. It may be a dense white, like that of marble; there is sometimes a yellowish, and occasionally a reddish tint. Permanent enlargement of vessels is sometimes conjoined with opacity of the cornea, and we see one or more trunks containing red blood ramifying on the part.

The effect of this morbid condition on vision will vary according to the density and position of the opacity. The slightest film or cloud opposite the pupil will interfere with vision materially, while the most dense leucoma near the circumference is uninjurious to sight. Dimness is sometimes caused by a central cloudiness, so faint that it can only be detected by close inspection of the organ in various positions.

Opacity may be confined to the external or mucous layer; it may be seated in the corneal substance, or in the internal serous membrane; or it may extend through the whole texture. The opacity is partial in degree in the first of these cases; it may be general or partial in extent; in the third, it is generally partial both in degree and extent. Opaque change of the corneal laminæ may vary from slight nebula to dense leucoma; and opacity of the entire structure may vary in the same way.

Treatment.—Our first object is to arrest inflammation, where that is still present. If we do this, and wait a little, the opacity will diminish of itself: the newly-deposited matter, which has caused the opaque change, being absorbed, as inflammatory interstitial effusion is removed in other textures. In children the processes of nutrition and absorption are vigorous; there is an active removal and deposition of materials, and the changes which the cornea undergoes are very striking; although the membrane should be so opaque in a child as to render the iris invisible, it will completely recover its transparency, as in the cases related at pages 238 and 239. After reducing the inflammation, and removing all irritation, after waiting to see what can be done by the natural process of absorption, we may adopt further measures for lessening the opacity. The effect of counter-irritation, with attention to diet, and to the state of the stomach and bowels, will often be very considerable. The absorption of the newly-deposited matter may be assisted, after these means have been put in force, by the employment of stimulants or astringents; the best of which is a solution of the nitrate of silver, commencing with gr. ii to the ounce of water, and gradually increasing its strength. This may either be dropped into the eye, or applied to the opaque part by means of a camel-hair brush.

Mr. Middlemore (op. cit., vol. i. p. 450) recommends the solution of the oxymuriate of mercury, in the strength of two grains to one ounce of water, in the treatment of corneal opacity; also solution of the nitrate of silver, three grains to the ounce, the vinum opii, and an ointment containing one part of the citrine ointment in three. He considers it advantageous to use these several applications in succession, each being employed for a week at a time.

[A very great number of stimulants and astringents have been recommended for the removal of corneal opacity. In addition to those mentioned by Mr. Lawrence, we have used with much advantage, solutions of the sulphate of cadmium (gr. i—iv to the oz.), and of the sulphate of zinc; the liquor plumb. subacet. of the old London Pharmacopœia, diluted acetic acid, red precipitate and iodine ointments, diluted creasote, and finely powdered loaf sugar and calomel applied to the part with a camel-hair brush, molasses, honey, &c.

Dupuytren is said to have been extremely successful with a mixture of equal parts of prepared tutty, sugar-candy, and calomel, reduced

to an impalpable powder and blown into the eye from a quill. When the opacity was large and of long standing, he introduced a seton in the back of the neck.

Red precipitate and loaf sugar, (one part of the former to eight of the latter,) powdered glass and white sugar, solutions of ammoniuret of copper, carbonate of potassium, hydriodate of potassium, the bile of various animals, walnut oil, oil of lemon peel, cyanide of zinc, cod-liver oil, have each been extolled by different writers for their efficacy.

Dr. Ruschenberger, U. S. N., informs us that he has found the saturated tincture of the root of aconite remarkably efficacious in the removal of opacities of the cornea.

Experiments have likewise been made on the eyes of animals, by Dr. Bigger, to ascertain whether the opaque cornea might not be completely removed, and replaced by a transparent one, obtained from another animal, on the principle of the Taliacotian operation. This operation has been termed keratoplastic. It is almost unnecessary to add that the results afford no encouragement to a repetition of the expedient.

M. Plouviez, of Lisle, in a communication to the French Academy of Sciences, in which he gives the results of his numerous researches relative to keratoplastic, states that he has been six years engaged in this investigation, during which period he has performed numerous operations, without, in a single case, succeeding in obtaining perfect transparency of the transplanted cornea. In the most successful operations the new cornea always continued more or less opalescent; vision, however, was several times re-established partially, but *partially only*. Among the cases related, is one of a girl, aged 23, who was blind from three years of age, in consequence of small-pox. M. Plouviez, after removing the opaque cornea, which was effected with great difficulty, because of its great density and thickness, replaced it with the cornea of a young dog which was killed at the moment. The sole result of the operation was, that the patient could better distinguish day from night, and could discern a strong light and the sun, but she could not guide herself without help.

The following are the conclusions of M. Plouviez's note:—

1st. The cornea of one animal can be transplanted to the eye of another animal.

2d. The human cornea can retain its vitality when transplanted to the eye of a rabbit.

3d. A cornea taken from a body five days dead can be grafted on, and become attached to the eye of a living animal.

4th. A cornea may adhere, when attached with one, two, or three sutures; but four are usually necessary.

5th. Flax or silk sutures are the best.

6th. Life is communicated to a dead cornea by means of a plastic fluid, which becomes gradually organized on the iris, and between the edges of the dead and living corneas.

7th. Reunion by the first intention never occurs.

8th. A transplanted cornea always shrinks considerably—generally one-half.

9th. The remaining portion of the old cornea is always elongated concentrically towards the end of the process, and retains its transparency.

10th. Complete transparency of the transparent cornea has not been obtained by any mode of operation hitherto employed.

The attention of the profession has been within a few years called to

an operation for the cure of opacity of the cornea, which was formerly practised, but which has been latterly abandoned, except, perhaps, by a few charlatans. This consists in excision of the superficial opaque laminæ of the cornea. M. MALGAIGNE has published in the *Journal de Chirurgie* for April, 1844, an elaborate paper on this subject. A note by him was also read to the French Academy of Sciences in March, 1843, which has drawn forth communications from several of his colleagues. M. BLANDIN states that a couple of travelling oculists in France, have, for fourteen years, been in the habit of performing this operation, with varying success. Three memoirs have also been published on this subject,—one by M. ROGNETTA, in *Les Annales de Thérapeutique*, another by M. DESMARRES in *Les Annales d'Oculistique*, and the third by Dr. HAMILTON in the *Monthly Journal of Medical Science* for March, 1844; in the last two of which the practice, in certain circumstances, is advocated, whilst in the first it is strongly condemned.

M. MALGAIGNE ascribes the first notice of this operation, in medical records, to Saint Ives in the year 1722. This eminent man disapproved of the practice for the usual run of opacities of the cornea; but recommended it in those cases where the opacity was due to the sequela of a small-pox pustule.

Dr. MEAD is the next author who alludes to the subject, in the few words so often quoted, viz., "he had only once or twice employed the partial excision with success."

There follows next the opinion of the German, ESCHEBACH, in 1651. A regular practitioner himself, he had opportunities of becoming acquainted with the misdoings of some wandering and unprincipled quacks, who, on two occasions, had undertaken to perform much, and miserably failed. His judgment, then, was decidedly condemnatory.

In France, M. DEMOURS held similar language in 1768, enforcing it by the details of a case in which the opaque cornea had been subjected to innumerable scarifications, which resulted in leaving the opacity worse than it had been before.

In 1779, Professor GOUAN, of Montpellier, read to the Royal Society of that city a case in which the result was the very reverse of the preceding. In 1777, a child aged seven was brought to him, which had lost its right eye when three months old, and when eighteen months, and laboring under small-pox, had been rendered quite blind by an opacity or cicatrice which covered the whole cornea of the left eye. For this the more common remedies—stimulants, irritants, &c., had been long used in vain; and the professor then advised partial excision. For the performance of this operation he engaged the services of M. PELLIER, surgeon oculist to the king, who excised about two-thirds of the thickness of the diseased membrane. The child showed no indications of pain; cold dressings were applied, and after six days he could distinguish such objects as the fingers, keys, &c. Dr. GOUAN subsequently ordered the application of nut oil, under which the vision improved, and, after the lapse of two years, the cure was still considered perfect.

In 1789 M. PELLIER gives the result of his more extended experience during ten years in these words. "Though I have described this operation for the cure of albugo and nephelium, yet uniform success is not to be expected. Experience has taught me its insufficiency in some cases, and its success in others."

SCARPA was very decidedly opposed to the operation, introduced, he alleges, by the ignorant, and commended by the charlatan. WENZEL was equally severe, remarking that it was likely to produce staphyloma.

In spite, however, of these authorities, Baron LARREY thought that the operation was sometimes worth a trial. In opacities of the cornea, says LARREY, of a certain degree of thickness, the membrane may be thinned down by repeated strokes of a slender bistoury. He performed the operation upon a young lady at Toulon, and thereby removed an old opacity which covered the whole extent of the cornea, and completely interrupted the entrance of the rays of light. The transparency continued in the part from which the opacity was removed, and the patient ever afterwards saw very fairly.

M. MALGAIGNE performed this operation on a young girl, on the 20th of March, 1843, and two years afterwards, (5th May, 1845,) he exhibited the patient to the Royal Academy of Medicine, and read an account of the case.* This case presents some points which are so very remarkable, that we will give a brief outline of it The subject of it, a girl of 18 years of age, had been afflicted from infancy with violent inflammation of her eyes, followed by partial opacity of the cornea. At the age of 13 years, an opaque spot existed on the right cornea, which did not decrease during the following three years. To remove this M. MALGAIGNE made a circular incision, about six millimetres in diameter, and dissected the flap so as to remove more than half the thickness of the cornea. The patient left the hospital on the fiftieth day, with her cornea almost transparent and able to read with the eye operated on, small type. The previous degree of vision is not mentioned. At this period, a circular depression in the cornea, resulting from the loss of substance, was visible, which, however, did not disturb the sight. A circumstance worthy of notice, says M. M., is that, "during the operation, the point of the instrument having penetrated into the anterior chamber, and touched the iris, a small projection at the external circumference of the pupil, seemed to show that there was an adhesion between the iris and cornea."

Four months afterwards, in consequence of exposure, the opacity returned, and the patient lost all the benefits of the operation. Under the use of resolvent applications, the transparency of the cornea was restored, and on the 23d Oct., the patient was again discharged from the hospital. The *depression* and the protrusion of the iris continued to this period, and as seven months had elapsed since the operation, M. MALGAIGNE considered these conditions permanent. In January, 1845, the patient suffered from a severe attack of inflammation of the eye, but which did not impair the transparency of the cornea.

On the 5th May, 1845, when the patient was shown to the Academy, an examination of the eye operated on showed, M. M. remarks, some very curious phenomena. "First, the projection of the iris has completely disappeared, and *it must be admitted that from the effect of time and the motions of the iris, the adhesions of the cornea have been absorbed and destroyed.* Moreover, the depression in the cornea, excavated by the bistoury, and which persisted seven months after the operation, has at present *entirely disappeared.* The cornea of this, is as smooth as that of the other eye, except a small depressed cicatrix, which did not exist at the time of the operation, and which appears to me to be the consequence of an ulcer of the coat attendant on the last attack of ophthalmia."

Notwithstanding the very fortunate result in this case, we cannot recommend a recourse to this operation. It can, at all events, only be suited to a limited number of cases, those in which the opacity is very

* See Journal de Chirurgie, May, 1845.

superficial, and which may be more safely cured by other means; whilst the risk of a recurrence of the opacity, when the wound heals, or of the thinned cornea being expanded into a staphyloma, are valid objections to a resort to it. Moreover, the danger of penetrating the cornea in the dissection is a serious difficulty, and certainly, one not very unlikely to occur, since it happened to so skillful an operator as M. Malgaigne; and finally, were it to take place, so remarkable an event as the disappearance of the protrusion and absorption of the adhesion, cannot be expected to occur.]

When red vessels are seen proceeding to the opaque part, their division has been recommended. I have seen no advantage from this proceeding.

[Our own experience relative to this measure, corresponds with that of Mr. Lawrence.

Mr. S. M. Griffiths states that in Tehran, Persia, an operation is practised for the cure of opacity of the cornea, which is said to be frequently successful in improving the transparency of the cornea, if not always capable of restoring perfect vision. The object of this operation seems to be, to completely cut off the vascular communication, by excision of a circular portion of the conjunctiva at a small distance from the margin of the cornea, which is accomplished by fixing eight small hooks into the conjunctiva, about a line from the union of the cornea with the sclerotica, quite round the cornea; the operator then raises that part of the conjunctiva by pulling these hooks towards him, and with a pair of scissors he cuts off the portion thus raised, and completely insulates the conjunctiva covering the cornea, the consequence of which is the gradual absorption of the opacity of the part affected, and the cornea recovers its transparency. The after-treatment is very simple, consisting merely in the introduction of a small quantity of antimony between the lids; in fact the result of the operation is confidently expected to be successful without any other application.—*Transactions of the Med. and Phys. Soc. of Calcutta,* vol. viii., Pt. 1.]

Some forms of opacity may be remedied, others not. I shall mention first such cases as admit of recovery. A general dullness or haziness, and sometimes a thin nebula of the cornea occur in iritis, and other internal inflammations of the eye; the change appears diffused through the whole texture. Often a more or less thick film covers the cornea in the purulent ophthalmia of infants, the conjunctival layer being thickened and loosened by the inflammation; the cornea assumes a pale grayish color; and this appearance frequently extends over the whole surface. Sometimes it is a white opacity, so dense as completely to hide the iris and pupil. A general nebulous or more opaque state of the cornea is produced in *corneitis*. There is also nebulous opacity, often accompanied with some redness, in strumous ophthalmia. These several cases present examples of impaired transparency, which admit of complete relief; and in all of them, although the opacity should be considerable, it may be removed by the treatment just pointed out. Indeed, it is sufficient to arrest the inflammation which has caused the opaque change, and the latter will disappear of itself. In the first, and the last two instances, there is general disturbance of the corneal circulation, and interstitial deposition; in the second, the mucous layer alone is the seat of change. The dotted opacity caused by inflammation of the membrane of the aqueous humor also disappears, when the inflammation has been arrested. (See Chap. XV., Section 2.)

Another and a denser kind of opacity arises from inflammation of a more serious character. The change affects the surface and the corneal laminæ

more or less deeply: it is interstitial deposition under considerable inflammation of the corneal texture. It may exist in various degrees, from the slight cloudy appearance of a nebula, properly so called, to the most dense form of leucoma; in the first we find that the change of structure is confined to the external lamellæ of the cornea, whilst in the more dense forms the whole thickness of the part has been altered in structure. The corneal substance is condensed and hardened, so that, when the part is squeezed between the finger and thumb, the laminæ no longer move on each other, as in the normal state. These white and dense opacities may be occasioned by escharotics, such as lime, applied to the surface of the cornea, by acute inflammation of the corneal substance, or by the effusion of matter, when suppuration has taken place. In the latter case, the opacity has at first a yellowish, and subsequently a light brownish tint. These are cases which admit of partial relief, but not of complete cure. The extent of the mischief is lessened by the gradual removal of the thinner halo, which surrounds the spot of acute inflammation.

The third description, which does not admit of cure, is the firm white shining cicatrix of wounds or ulcers. When an ulcer has extended into the corneal laminæ, the cicatrix is a permanent white mark; but if it should be superficial merely, like an excoriation, it may leave no trace. A cicatrix is distinguished by its sharply defined margin, and shining appearance: the edge of an opacity produced by an interstitial deposit is gradually shaded off. In the dense opacity of the entire texture called leucoma, the organization is so much changed, that we can do no good by any treatment as respects the state of the cornea. It will depend upon the situation of the leucoma whether the case may be relieved by the operation for artificial pupil or by the use of belladonna.

[When the leucoma occupies only the centre of the cornea, merely covering the pupil in the ordinary state of contraction of the iris, as in fig. 51, very useful vision may be gained by dilating the pupil, see fig. 52, by the habitual use of the extract of belladonna.]

Fig. 51.

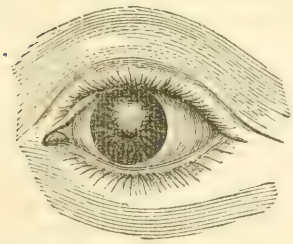

Fig. 52.

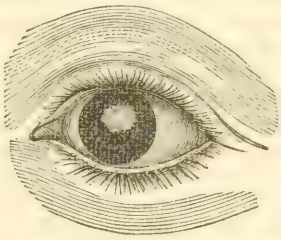

Mr. Middlemore's opinion respecting the advantage derivable from surgical treatment in leucoma is more favorable than that which I have expressed. "In many cases where dense opacity and leucoma of the cornea have been under treatment for many months, I have effected very great benefit by applying the strong nitrate of silver ointment every day, or every other day: indeed, without the slightest exaggeration, I may state that in those cases in which the application of this ointment can be borne, I have effected as much benefit by a single application of it, as the use of the common stimulating drops has produced in several weeks." Mr. M. combines with this application the administration of mercury so as to maintain

slight ptyalism, occasional leeching, counter-irritation behind the ears or at the back of the neck, or by means of an issue in the temple.*

Another mode in which the transparency of the cornea may be impaired, is by the effusion of blood between its layers, which may take place, according to Mr. MIDDLEMORE, from local injury, or during the progress of acute corneitis. In the former case it is fluid at first; in the latter it is deposited in the solid state. If neglected, the fibrinous substance may become organized, and no longer within the action of remedies. The same treatment is required as for inflammation and opacity of the cornea under other circumstances.†

Congenital opacity of the cornea.—Mr. WARE observes, that children are sometimes born with eyes remarkably large and prominent, and with an opaque state of the cornea. This happened in three children of the same family. The opacity in these cases gradually diminished after birth, without any applications: in two of them, it was quite removed in less than a year; while in the third, the alteration was not complete until the end of the second year. Mr. WARE found the cornea very prominent in these children, who were all short-sighted, though they had recovered distinct vision. In another new-born infant both corneæ were large, prominent, and completely opaque. At the end of nearly three years, the left cornea was sufficiently clear to allow the perception of all large objects; the opacity of the right cornea being also diminished round its outer edge, though the greatest part of the pupil was still obscured. In a fifth case, both corneæ, at the time of birth, were large, prominent, and completely opaque, the child in other respects being healthy. At the end of a year, the cornea of one eye is not only perfectly transparent for a considerable space round its circumference, but the pupil can be seen through the diminished opacity which remains in its centre; and though the cornea of the other eye has improved less, its transparency has increased, particularly towards the circumference.‡

I have seen two or three similar cases, in which the corneal opacity has diminished after birth; but the progress has been very slow, and I have not known the ultimate event.

[Dr. P. W. MACLAGAN relates (*London and Edinburgh Monthly Journal Med. Sci.*, July 1845) a very interesting case of congenital opacity of the cornea. Fourteen hours after birth the eyes presented the following appearance:

"On neither was there the slightest trace of vascularity or purulent discharge; the left cornea was completely opaque; the right was in the same condition, on its inferior two-thirds, but the upper third was clear, the opacity terminating by a tolerably defined edge. At first, I thought that I could perceive this edge to change its position, as the child's head was inclined to one side or the other, which led me to suppose the opacity resided in the aqueous humor; but this I found to be a mistake. Never having seen such a case, and not being able to hear of one, I was led to form an unfavorable prognosis; but in this I was agreeably disappointed; for in a few weeks the edge of the opacity on the right cornea began to thin off, to become less defined, and at length to recede, so that a part of the pupil could be seen on looking straight at the eye, whilst at first it could only be observed by looking from above. It was long before any change could be perceived on the left eye; but about the beginning of January, *i. e.*, three months after birth, it too began to improve—the

* Vol. i. p. 452, 453.

† Ibid., p. 465, 466. This occurrence is represented in AMMON's Klinische Darstellungen, pt. i. tab. 3, fig. 5.

‡ Tracts on the Eye; London, 1818; p. 285–8.

opacity at the upper part of the cornea becoming more diluted-looking, and by degrees disappearing. At this time it was curious to observe the infant instinctively depressing the eyeball, when any bright object was held before it, so as to permit its image to fall through the upper portions of the cornea.

When I was removed from that post, a few days ago, the improvement was gradually progressing. There is now only a small portion of the right cornea opaque, and the upper half of the left is tolerably clear."]

SECTION V.—STAPHYLOMA.

The cornea is subject to changes in figure as well as to the alterations of texture, which impair or destroy its transparency. The term *staphyloma* denotes an increase of size, with change of figure in the membrane, (fig. 53,) these alterations being accompanied almost invariably by more or less opacity; it is derived from the Greek word σταφυλη, which signifies a grape. The name was originally applied to that projection of the cornea in which its texture, having been weakened by alteration of structure consequent on the inflammatory process, yields to the pressure of the fluids contained in the posterior chamber, and is elevated into a rounded prominence on the front of the eye, the iris being adherent to its internal surface, and stretched out so as to afford it a thin general lining. The term has since been applied more extensively, having been given to other tumors of the front of the eye, and even to expansion of the coats in other directions. However, when the term staphyloma is used alone, it is understood to denote the affection of the cornea now under consideration.

Fig. 53.

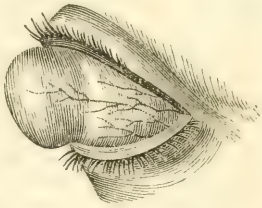

In order that staphyloma should be produced, there must have been inflammation of the cornea, rendering its texture more or less generally opaque; that inflammation must have extended to the iris, and caused it to adhere to the cornea; and the cornea must have been weakened by sloughing or ulceration, so that it yields to the distension from within, and forms, with the adherent iris, the staphylomatous tumor.

The external surface of the staphylomatous swelling is formed of the extended and thinned cornea, of the aqueous membrane, or of a tissue like that of cicatrix covering the iris where it has been denuded by sloughing of the cornea. This external covering may be so thin at some parts, as to allow the color of the iris to appear through, giving the tumor a dark bluish aspect in such situations.

The expanded cornea is sometimes thicker, generally thinner than the membrane in its normal state. The aqueous membrane and the adventitious pellicle are as thin as writing paper, the iris being closely adherent in such situations.

The cornea is lined internally by the iris, which is thinned, expanded, and adherent. It is sometimes found to have given way partially to the distension, so that openings are seen in it.

The interior of the swelling is filled with aqueous humor: it flows out, if a puncture be made, and the part collapses. The crystaline lens is sometimes contained in the staphylomatous enlargement.

The morbid distention, which in the great majority of cases is confined

to the cornea, sometimes embraces also the anterior portion of the sclerotica, the enlargement of the eyeball being then much more considerable.

Fig. 54.

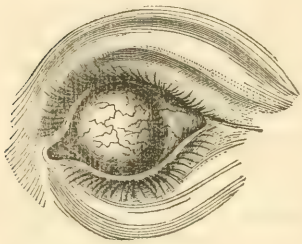

Fig. 55.

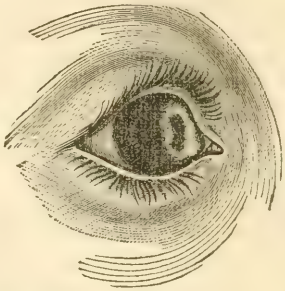

The figure of the swelling is generally tolerably regular; sometimes otherwise. Staphyloma corneæ may be either *total* (fig. 54), or *partial*, (fig. 55;) that is, including the whole, or confined to a part only of the cornea. The enlargement is generally rounded, either hemispherical, or more nearly globular; sometimes it is conical, the circumference of the cornea having yielded less than the middle: hence the distinctions of *staphyloma hemisphericum*, *globosum*, *conicum*. The term *staphyloma racemosum* is employed when the tumor is subdivided into smaller portions by more or less deep fissures, so as to admit of its being compared to a bunch of black currants or small grapes.* See p. 282.

The foregoing account represents the generally received opinion respecting the mode in which staphyloma corneæ is produced; and my own experience corresponds with this opinion. Its correctness has been questioned by Mr. Wharton Jones, whose views are clearly detailed in the following quotation. "When destruction of the cornea has taken place to a certain extent by ulceration or suppuration, the iris protrudes, 'and forms a projection at one part of the cornea, generally the lower or lateral.' This projection is at first merely a bag of the iris distended by the aqueous humor; but by and by its exposed surface becomes covered by an opaque firm tissue, of the nature of the tissue of cicatrices; and this tissue is incorporated at the base of the tumor with the sound cornea. The projection, the mode of origin (of which) I have just described, is a *partial staphyloma;* it is not a distention of the cornea itself, but a protruded portion of the iris covered by a new tissue, intended to supply the loss of substance which the cornea has sustained. The mode of origin of a *total staphyloma* is essentially the same, but differs only in degree. The whole or greater part of the cornea being destroyed, as occurs in gonorrhœal, purulent, and very often in variolous ophthalmia, as also that of new-born infants, the whole iris falls forward, the pupil becomes closed, and the aqueous humor being thus allowed to accumulate in the posterior chamber, the iris is kept distended in the form of a tumor on the front of the eye. Its surface gradually gets covered with an opaque cicatrice-like tissue, or pseudo cornea, which assumes a greater or less degree of thickness, and a total staphyloma is the result. Sometimes the central part only of the cornea is destroyed, a ring of the

* In the first part of his Klinische Darstellungen, tab. 5, 6, and 7, Ammon has devoted numerous figures to the subject of staphyloma corneæ, exhibiting the varieties of configuration, as well as the changes in the cornea and iris, and the state of the organ generally.

circumference still remaining; the staphylomatous projection has then the form of a small globe stuck on the front of a larger."*

Mr. Jones finds it difficult to understand how the iris can become adherent to the cornea; yet partial synechia anterior occurs not unfrequently, without wound or penetrating ulcer, as an effect of acute corneitis, and in conjunction with leucoma. He enumerates various cases of disease, wounds, and operations, involving the cornea, in which no adhesion of the iris takes place. We cannot hence infer that the iris will not become adherent to the cornea, in the widely different morbid conditions of the organ, which lead to the development of staphyloma. Mr. Jones has forgotten to explain how, when the whole cornea has been destroyed, the aqueous humor can be accumulated in the posterior chamber, so as to distend the iris into a staphylomatous tumor.

I think it probable that the explanation offered by Mr. Jones is correct, as regards partial staphyloma; though it may be doubted whether the iris protrudes nakedly, as he represents, or whether the bulging portion is covered by the membrane of the aqueous humor. In the latter case, the adhesion of the iris to the membrane, which constitutes with him so great a difficulty, must still occur; and the covering of the staphyloma would be the aqueous membrane in an altered state, and not the supposed new tissue.

Respecting total staphyloma, I think the old notion the correct one. If it be otherwise, and if Mr. Jones be right, we want proofs; his mere assertion is not sufficient.

What I have observed, after entire destruction of the cornea, is, that the bulging iris has gradually receded, and become covered by an opaque pellicle; the front of the eye being thus permanently flattened. It is, however, not improbable that the iris, instead of shrinking, may sometimes be pushed out by the secretion of aqueous humor in the posterior chamber and form staphyloma. This view of the subject, adopted as I think too exclusively by Mr. Jones, had been already clearly set forth in explanation of certain cases by the late Mr. Ware, who says, "I have sometimes seen the whole cornea sloughed off during an acute purulent ophthalmia, and a white opaque substance gradually effused from the ulcerated surface, sufficient to form a complete cover to the iris; after which this opaque body has gradually projected in a conical shape, until at length it has become so prominent as to hinder the eyelids from closing over it." Mr. Ware adds, "I have at other times seen the projecting cornea partly opaque, and partly transparent; the pupil being distinctly visible through the transparent part." (Op. cit., p. 271.)

It has always appeared to me that the aqueous membrane, and more or less of the cornea, have remained where staphyloma has occurred. In the numerous instances in which I have operated for staphyloma, the excised portion has seemed to me to be obviously cornea, often of its natural thickness, and exhibiting partially the smooth internal surface natural to that membrane. The external covering of the staphyloma, and the expanded iris, are perfectly distinct, and often but slightly adherent: we do not see the close adhesion, and the blending of substances which are observed in cicatrices of other parts.

When the staphyloma is once established, the enlargement of the corneal region gradually increases, especially if the eye still suffers from remains of the previous inflammation, or from any of the various external or internal causes of irritation. As the tumor becomes more prominent, its surface,

* Some Observations on the Pathology of Staphyloma, in the London Medical Gazette, vol. xxi., p. 849.

which is often irregular, presses unusually against the eyelids, which again press upon and mechanically irritate the staphyloma. The latter may become so large as to protrude between the lids, when their margins and the cilia rub against the base of the swelling. Thus in addition to the great and conspicuous deformity of an enlarged, misshapen, opaque eye, the patient experiences attacks of inflammation, which exert a sympathetic influence over the other eye, rendering it irritable and painful, so that the patient cannot use it freely in reading, writing, or other occupations requiring active exertion of the organ.

Under increasing distention of the cornea, it becomes thinned at some point, and occasionally gives way, allowing the aqueous humor to escape with temporary diminution of the eye. Frequently the swelling remains stationary after a certain time, occasioning no inconvenience except the deformity.

Causes.—The changes in the cornea just described are the immediate cause of staphylomatous enlargement. These changes occur most frequently in purulent ophthalmia, whether of the infant or adult, in gonorrhœal and variolous ophthalmia. It may have its origin in strumous inflammation, and perhaps in common external ophthalmia.

Fig. 56.



Treatment.—We may prevent the development or increase of the affection, by removing inflammation, and by guarding the eye against all sources of irritation. Occasional evacuation of the aqueous humor by puncture of the cornea might aid the beneficial operation of these measures. After bringing the eye into a quiet state by such means, solution of the nitrate of silver or oxymuriate of mercury might be applied to the morbid enlargement.

The treatment of staphyloma, when fully developed, is either palliative or radical. The former consists in removing inflammation, or in diminishing the volume of the swelling, by puncturing the cornea, which may be done with a cataract knife or needle. Sometimes by repeated puncturing, the palliative remedy has been converted into a radical cure, the globe shrinking, and becoming quiet: however, it will be necessary, if the patient be subject to relapses of inflammation, more especially if these should affect the other eye, to resort to the radical treatment.

This consists in cutting away the staphylomatous protuberance with a cataract knife. [Fig. 56.] The lids being held asunder by an assistant so as to expose the globe, the operator transfixes the staphyloma with a hook, and removes it at one cut by carrying the knife through its base, from above downwards, a little in front of the sclerotica. Or the knife may be passed through the middle of the basis, then carried upwards, and afterwards turned to divide the lower part. After dividing the upper portion with the knife, in the way described, it may be found more convenient to cut through the lower part with scissors. The effect of this operation is, that the globe shrinks, the coats collapse, and form a small tubercle in the orbit, and the lids fall in. It has been advised to pass a curved needle and thread through the tumor, for the purpose of holding it more securely, but the tenaculum or hook is quite sufficient. In separating and fixing the lids, pressure on the globe should be avoided: if all the vitreous humor be squeezed out, the tubercle formed by the tunics after their collapse, may be too

small to admit of the adaptation of an artificial eye. The front of the globe in its shrunk state, is generally divided into four portions by superficial sulci, corresponding to the insertions of the four recti muscles. When the first puncture is made into the tumor, the contained fluid escapes, and that fluid is aqueous humor.

Generally speaking no serious consequences follow this operation, but severe inflammation sometimes results, as I have seen in two or three instances. This happened in a medical student, in whom staphyloma had occurred from gonorrhœal ophthalmia. He found that he could not pursue his studies in consequence of the irritability of the staphylomatous eye and its influence on the sound one, and he requested that the projection, which was by no means considerable, might be removed. Although he was a person of great firmness, he complained of severe pain on making the division of the parts, and soon after the operation was finished, very acute suffering came on; the conjunctiva covering the sclerotica, and that of the eyelids, became the seat of active inflammation, not distinguishable from the original gonorrhœal ophthalmia. Violent chemosis and purulent discharge came on, with acute pain in the eye and head. He was bled copiously, and other measures of depletion were put in force, although his diet had been low some time before the operation. These means did not diminish the pain, and it was necessary to give opium largely; however, the inflammation subsided, and the case recovered. I have seen one or two other instances of severe inflammation after the operation, but in general little pain or inconvenience is experienced. Scarpa speaks also of inflammation happening after the removal of the tumor, and he advises the method of Celsus. The directions of the latter are much like those of many modern practitioners: he advised the removal of the tumor by *deligation* or *excision.* In the former a needle should be carried through the base of the tumor, armed with a double ligature, the ends of which should be tied above and below, so as to embrace the enlarged and protuberant cornea. In the latter case, he says, we should cut away "*magnitudo lenticulæ*," a portion of the size of a lentil seed, and not the whole unnatural prominence. Scarpa recommends that only a small portion of the cornea should be taken away; but I see no good reason for deviating from the ordinary operation of removing the tumor at its base, inasmuch as severe inflammation is an unusual result of the operation, and referable to something in the state of the individual, and not to the kind of operation.

["It occasionally happens," Mr. Mackenzie states, "especially in cases of staphyloma attended with varicosity of the internal vessels of the eye, that either immediately, or some hours after the operation, hemorrhagy takes place, both from the eye and into its cavity. A bloody, dark-colored mass, of pretty considerable consistence, protrudes to such an extent from the wound, that it is impossible to keep the eyelids shut. The eyeball is painfully distended, while the conjunctiva and lids become greatly ecchymosed. The hemorrhagy into the eye gives rise in some cases to agonizing pain, and may even bring on convulsions. Under such circumstances, we ought to cut away with the scissors the protruding substance, which perhaps is in some cases the hyaloid membrane injected with blood, but in other cases is nothing more than a clot of blood, hanging from the front of the eye. After this is done, the bleeding ceases, and the pain abates. Left to itself, the protrusion dies away in the course of a few days. The eye is apt in either case to shrink below the usual size of a staphylomatous eye after operation.

"It occasionally happens that the opening into the eye, formed by the removal of the staphylomatous cornea and iris, is long of closing, no

pseudo-cornea being present when we open the lids on the eighth or tenth day, and even for weeks, the clear humors lying uncovered behind the gap in the front of the eye. At length, however, the aperture contracts and cicatrizes. Fungous granulations sometimes sprout from the aperture, requiring the use of lunar caustic. If the eye is not kept shut after the operation, the lens may come forward and protrude through the wound. When this is the case, the lens should be removed, and the eye kept closed till the cicatrice is formed."]

When the globe has shrunk in the socket, we can adapt an *artificial eye* to the prominence which remains, and in this way completely remove the deformity. An artificial eye may be obtained to match exactly the color of the sound one. The resemblance to the natural appearance is so perfect, that casual observers do not notice the defect. The artificial eye, which is made of enamel, is a concave kind of shell, perfectly smooth on both surfaces. It is introduced by first pushing the upper edge under the upper lid; then by depressing the lower lid, the lower edge of the eye slips into its place. The introduction of this foreign body does not in general produce any irritation of the mucous membrane. Patients can take it out and put it in at pleasure; and they generally remove the eye at night, which is done easily by depressing the lower lid, and raising the lower edge of the eye with a bodkin, or with the end of the nail. When taken out it should be wiped clean. The artificial eye moves in harmony with the natural one, especially from side to side; the motions upwards and downwards are not so well performed. The muscles of the globe are uninjured in these cases, and remain attached to the collapsed tunics; when the eye has shrunk they continue to act in concert with those of the sound organ, moving the remaining tubercle, and the artificial eye which is supported on it.

In total staphyloma sight is lost, for the cornea is more or less opaque, and the axis of the eye greatly lengthened. If partial staphyloma does not involve the pupil, or if it should engage only a small portion of the aperture, a considerable degree of vision, or even perfect sight, may remain. If it embrace the entire pupil, or be accompanied with general opacity, it destroys sight altogether. Evacuation of the aqueous humor by puncture of the cornea, and the external application of a solution of nitrate of silver, may be employed as means of prevention or cure. With the former, I have succeeded completely in removing the swelling, and restoring the natural outline of the cornea, the affected portion of which has presented a thin semi-opaque texture, with dark appearance from the adhesion of the iris. If this partial projection of the cornea should be the source of irritation from friction of the lids, or if it should affect the opposite eye sympathetically, it must be dealt with as if the staphyloma were total. I have never found it necessary to resort to excision. Some cases of partial staphyloma admit of relief from the operation for artificial pupil.

Staphyloma pellucidum.—The case is thus called when the cornea is increased in size, without diminution of its transparency or any other apparent alteration. The source of mischief here is probably not in the cornea, but in some cause affecting the anterior chamber generally. The subject is further considered in the next chapter.

CONICAL CORNEA.

Synonymes:—*Sugar-loaf cornea; staphyloma conicum; staphyloma pellucidum conicum; staphyloma corneæ totale pellucidum conicum; pro-*

*lapsus corneæ ceratoconus; hyperceratosis,** from υπερ *super*, and κερατοω *in cornu muto;* the term is equivalent to *hypertrophy of the cornea.*—The cornea is also subject to a change of figure, in which its regular convexity is lost, and it is elevated into a conical protuberance without previous or concomitant inflammation, pain, or suffering, without opacity or indeed any visible change in its own texture, or in any other parts of the eye. It becomes conical, and that is all we can observe in the case, [fig. 57.] The elevation is sometimes pointed or conical, sometimes obtuse or shaped like a sugar-loaf. Its situation is usually central; but it may be situated a little below the middle line. This state of the membrane has been called *staphyloma pellucidum conicum*, though it is a totally different condition from that of staphyloma properly so called; we generally call it simply conical cornea. This change of figure begins insensibly, proceeds very slowly, and will require several years to reach its full development. When we see a patient laboring under this affection, we are at first struck with a peculiar brilliance or dazzling look of the eye, the light being reflected in an unusual manner from the altered portion of the cornea. When we survey the eye laterally, we see that the cornea does not present its natural convexity; that it is elevated into an obtuse cone, and that it looks as if a piece of crystal were placed in front of the eye. The cornea remains perfectly transparent, and there is no apparent deviation from its natural structure; the iris and the pupil are natural; the external surface of the eye is perfectly so; in short, there is no other visible alteration but this change of figure in the cornea.

Fig. 57.

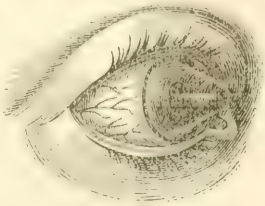

In the early period of the complaint, it is difficult to ascertain its existence; after a certain time we notice it from the before-mentioned dazzling reflection of light. The change in the shape of the cornea interrupts the transmission of light; the focus is altered and the patient is rendered myopic, or nearsighted; he brings objects very close to the eye. The near-sightedness becomes more and more considerable as the disease advances, so that at last the patient can only read at about the distance of an inch, and he holds what he has to read towards the side of the eye, not in front of it, the circumference of the cornea being the part least altered.

When the complaint has gone to the length of elevating the cornea into a decided conical protuberance, which generally occupies some years, it will remain stationary. The friction against the lids sometimes renders the apex of the cone opaque.

This change may go on in one eye without the other being affected, and so little inconvenience does it occasion at the commencement, or even after it has made some progress, that the patient only discovers its existence by shutting the sound one, or by some accidental occurrence.

Professor Jaeger, of Erlangen, examined after death an eye, in which this disease had existed. When the cornea was taken between the finger and thumb, a depression towards the middle was plainly perceptible surrounded by a thick margin. On cutting it through, the middle third was found three times thinner than usual, and not thicker than writing paper.

* The inaugural dissertation of G. E. Wimer, de Hyperceratosi, Leipzig, with a lithographic plate, contains a full historical statement of what is known on the subject, and references to all the recorded cases.

The exterior two-thirds were thickened, the increase being in the middle laminæ. The thicker was continued gradually into the thinner portion, which was about the size of a moderately dilated pupil.*

Mr. MIDDLEMORE had also the opportunity of examining the eye in a person who had been affected with conical cornea in an extreme degree. Its laminæ were less movable on each other; its circumference was of the natural thickness, but the apex was much thinner than usual, and opaque on its exterior only.†

It may be doubted whether the thinning and distention of the cornea at its centre are owing to direct pressure from increased secretion of aqueous fluid. Such a cause might be expected to act on the cornea generally, and to be attended with evidences of increased vascular activity, such as pain, redness, and changes in the state and position of the iris.

It occurs in young and healthy subjects, in whom there is no constitutional cause to which the local change can be referred, generally coming on about or soon after the period of puberty. I have seen it in healthy country girls; and it is more frequent in women than in men. We must suppose it to be a rare affection, as it is not mentioned in the work of BEER; Professor HIMLY, of Goettingen, had never seen a case of it. I have seen several instances, so that it would not appear, comparatively speaking, to be of unfrequent occurrence in this country.

If we do not know the cause of the affection, we cannot be prepared to propose any rational treatment. I cannot say that I have seen any plan productive of benefit. Repeated evacuation of the aqueous humor and astringent washes have been employed without advantage. It is doubtful whether the latter are even capable of checking the progress of the complaint in the early stage.

During the progress of the complaint, the use of concave glasses will assist sight; and if pain should attend the affection, we must have recourse to such local measures as the state of the organ may seem to point out. The eye should be used sparingly, and blood may be taken locally, if circumstances seem to require it. A young woman from the country, who labored under this affection, had some symptoms of congestion in the head, which were relieved by cupping, and the sight was assisted by using concave glasses.

An old clergyman, who was the subject of this affection for nearly thirty years, was enabled to continue his duty in the pulpit with tolerable accuracy to the time of his death, which happened when he was about seventy. The apex of the cone had become opaque in his case; the opacity was diminished by the solution of nitrate of silver; and he employed belladonna to enlarge the pupil.

It was proposed by Sir WILLIAM ADAMS to perform the operation for cataract by solution as a remedy for this affection. The refractive power of the eye is increased by the unnatural convexity of the cornea; and his object was, by getting rid of the lens, to counterbalance that increased refraction. I should not think of proposing any such operation, unless the affection had gone so far as to make the eye useless; and I should then expect no good from it. The proceeding has not been employed with advantage in any instance.‡

* AMMON's Zeitschrift, vol. i. p. 548. † Treatise, vol. i. p. 532, note.

‡ A good colored figure of the complaint is given by DEMOURS, pl. 57, fig. 1, who states that he and his father had often seen it, and that the latter had noticed it as long ago as 1747. Traité des Maladies des Yeux, tom. i. p. 316. Dr. LYALL detailed the particulars of four cases, and gave to the affection the name of *staphyloma pellucidum conicum*, in an Essay which he contributed to the Edin. Med. and Surg. Journal, vol.

Mr. TYRRELL* says that he has relieved several cases to a considerable extent by altering the position of the pupil, and removing it from behind the conical centre towards the margin of the cornea, where the membrane is little changed. He punctures the cornea with a broad needle, close to the sclerotica, at the lower and outer part, and then introduces a small blunt hook to catch the pupillary margin of the iris, which he carefully draws out of the aperture far enough to bring the pupil from the centre to the lower and outer part of the cornea. The iris remains embraced by the wound; the portion dragged out by the hook may be cut off with a fine pair of scissors.

[Dr. JAMES H. PICKFORD, in an elaborate paper read before the association of King and Queen's College of Physicians, Dublin, and published in the *Dublin Journal of Med. Sci.* for Jan. 1844, offers some new views respecting the nature of this malady, and relates a few cases successfully treated by him.

Dr. P. believes conical cornea to depend upon some disturbance in the functions of the great sympathetic spinal nerves, and par vagum, producing, through the medium of the lenticular ganglion and fifth pair of nerves, faulty action of the nutrient capillaries and absorbent vessels of the cornea itself; and that emetics and purgatives, by the powerful influence they induce upon the gastric, associate, and consensual nerves, restore the healthy functions of the weakened nutrient and absorbent vessels, the result of which is a slow but progressive retraction of the diseased corneal growth, and a consequent restoration of vision.

The combination which Dr. P. prefers is the following:—℞. Zinci sulph. ℈j; magnesiæ sulph. ℥ss: primo mane quotidie sumend. In one case this emetico-purgative plan was continued for upwards of twelve months, when the patient was cured. The disease, however, returned in about eighteen months, but was cured a second time by the same means. Dr. P. also relates a case of a similar kind in which one grain of tartarized antimony with half an ounce of epsom salts, was given every morning for a considerable period with almost equal success.]

CHAPTER XV.

DISEASES OF THE AQUEOUS MEMBRANE AND CHAMBERS.

SECTION I.—INTERNAL INFLAMMATIONS OF THE EYE; ARTIFICIAL DILATATION OF THE PUPIL.

THE internal inflammations constitute a subject of the greatest importance. With less external appearance of disease, with fewer visible marks of inflammation, with less to excite the attention of the patient or the alarm of

vii. p. 6. He afterwards made it the subject of his inaugural dissertation, printed at Petersburg in 1816. The affection was also noticed by LEVEILLE, in a note to his translation of SCARPA's work on Diseases of the Eye, tom. ii. p. 179, It was particularly described under the name of *conical formed cornea* by Mr. WARDROP, in his Essays on the Morbid Anatomy of the Eye, 1808, vol. i. ch. xiii. He has also given a figure of it in the ninth plate of his work.

These, with some other notices on the subject, are collected by HIMLY in his Bibliothek für Ophthalmologie, vol. i.

* Vol. i. p. 277.

friends, than in the external affections already described, there is much greater danger to vision. Slight alterations in the pupil, in the transparent media behind it, or in the retina, are sufficient to impair or destroy sight. These often take place without external redness, without any changes visible to superficial observation. The commencement and progress of chronic and internal inflammation are frequently most insidious; the existence of the affection, when confined to one eye, not being discovered till the change of structure is irreparable, and then only observed accidentally. This part of the subject has been much neglected by English writers, until within a recent period. It has been more accurately and successfully investigated by the Germans than by any others: they deserve the merit of having first observed, described and discriminated the principal forms of internal ophthalmic disease.

Inflammation may be confined to one of the internal structures, or these may be involved altogether. The close connection between the different internal parts, and their common vascular supply, is sufficient to account for the circumstance of inflammation spreading from one to another, and indeed make it difficult to understand how it is so often limited to one part. If inflammation commences in the iris, it easily extends to the ciliary body, choroid coat, vitreous humor, and retina; on the other hand, it will spread forward to the anterior part of the eye: so that a case of iritis often involves, in its progress, the greater part or the whole of the internal tunics, and the external parts also. Inflammation beginning in the retina spreads in like manner to the vitreous tunic, choroid, iris, &c.

The phenomena of inflammation have been most accurately noticed as they present themselves in the iris, because it is immediately open to external observation; hence its history, progress and treatment are best understood. We are not so fully acquainted with the appearances of inflammation in the retina, choroid coat, and vitreous humor; we cannot give so clear and satisfactory an account of choroiditis and retinitis, as these affections have been termed, as we can of iritis. We labor under peculiar disadvantages in the pathology of these parts; their internal position secludes them from observation during life, so that we do not see the actual changes which constitute the inflammatory state; and we have no opportunity of investigating these changes after death, because the affections do not destroy life. There are hardly any recorded dissections of such cases in the active state of inflammation. The few examinations hitherto made have been in instances of long standing blindness; hence they have only shown the ultimate effects, without elucidating the origin, progress or primary state of the affections.

Artificial dilatation of the pupil.—This state of the pupil is one of the most important points in the internal ophthalmiæ; to preserve its circular figure, its natural dimensions, and permeability to light, is our principal object in most instances. Here we derive essential assistance from that anomalous and hitherto unexplained power, which certain narcotic vegetables possess, of acting upon the iris so as to dilate the pupil.* Before I

* The influence of belladonna on the pupil had been observed long ago, and is incidentally mentioned, as if it were well known in a case of amaurosis, related in ARNEMAN'S *Magazin*, vol. i. REIMARUS, who saw a striking instance of it, proposes to employ the application as a means of facilitating extraction of the cataract. See BALDINGER, *Sylloge*, as quoted in the next note. But the attention of the profession was first expressly directed to the subject by Professor HIMLY, in some remarks on "*Paralysis of the Iris by the local application of Hyoscyamus, and the use of this remedy in the treatment of some diseases of the eye*," published in his "Ophthalmologische Beobachtungen," Bremen, 1801. These were translated into French, and published at Altona in 1801, under the following title: "*De le Paralysie de l'Iris par une application locale de la Jusquiame, et de son utilité dans la traitement de plusieurs maladies des yeux.*"

describe the internal inflammations, I shall speak of the effect which these substances produce on the eye.

The power in question resides in the atropa belladonna,* (deadly nightshade,) the hyoscyamus niger,† (henbane,) the lauro cerasus,‡ (cherry laurel,) and the datura stramonium, (thorn apple.) It is found in the recently expressed juice of these vegetables, in an inspissated decoction of them, in the extract, or in the active narcotic principles, lately discovered by German chemists, and named by them hyoscyamine and atropia.§ There are vegetables, somewhat analogous in their properties to these, which might, therefore, be expected to possess similar power; but they do not. This has been ascertained of the conium maculatum, aconitum napellus, and opium; also of the digitalis purpurea, arnica, rhus radicans, and saffron.‖

The usual mode of proceeding is either to rub the moistened extract on the brow, or to drop a solution of it in distilled water into the eye: the last is the most efficacious. A scruple of the extract of belladonna, or of the extract of hyoscyamus, should be rubbed down with an ounce of distilled water; the fluid should be filtered through linen, and two or three drops of it should be introduced between the lids. When the extract is employed, it should be brought to the consistence of honey by mixture with distilled water, and then copiously smeared on the upper lid, eyebrow, and neighboring part of the forehead; after remaining for an hour, it may be washed off.

In the observations just quoted from the *Edinburgh Journal*, Dr. Reisinger expresses his opinion that a solution of the hyoscamine, or the atropia, would be preferable to the other modes in which these narcotics have been

Ehlers, who translated the observations of Himly, communicated their purport to Dubois, who used hyoscyamus to dilate the pupil in cataract operations in the following year at the Hôpital de Perfectionnement.

Himly has the merit of first seeing and clearly explaining the practical utility of this artificial dilatation in various states of the eye. It is so important in internal inflammations, by preventing contraction of the pupil; in the distinction of cataract from other affections; in discriminating the several species of cataract; in facilitating some of our operations, and as a palliative remedy in contractions and displacements of the pupil, and in many cases of glaucoma and cataract, that its introduction into practice by Professor Himly may be deemed an important epoch in ophthalmic surgery.

Mr. Wishart has given a good account of the circumstances connected with this subject, historical as well as practical, in the ninth volume of the Edinburgh Medical and Surgical Journal, in a short paper, entitled "*Case of congenital cataract, with some observations on the means of artificially dilating the pupil in the operations of extracting and depressing the cataract.*"

* This effect of belladonna, which was known to our countryman, Ray, was observed in a young man, who had some of the fresh juice accidentally applied to the eyes. The pupils remained dilated for three weeks. See Baldinger, Sylloge Opusculorum, vol. ii., 1777.

† The fact was first noticed by Professer Himly, in 1799, in a case where the eyes had been bathed with a solution of hyoscyamus: see his Ophthalmologische Beobachtungen, quoted in the last note but one.

‡ Conradi saw full dilatation of the pupil produced by the external application of cherry laurel water, as a remedy for opacity of the cornea. Auswahl aus dem Tagebuche eines pratiscken Arztes, Chemnitz, 1794, p. 23.

§ On the effects of Hyoscyamine and Atropia, by Dr. F. Reisinger. Extracted from the Medicinisch-Chirurgische Zeitung, February, 1826. Edinburgh Medical and Surgical Journal, vol. xxiv., p. 287.

‖ See Barratta, Observazioni pratiche sulle principali Malattie degli Occhi, vol. i., cap. 4, and Benedict Handbuch der praktischen Augen-heilkunde, vol. i., p. 7—9. The latter author says that the lactuca virosa and pulsatilla nigricans produce slight dilatation.

used for dilating the pupil. His opinions and experience will be learned from the following passage:—

"In the first part of the Bavarian Annals for Surgery, Ophthalmic Medicine and Midwifery, I endeavored to draw the attention of German physicians to the narcotic principles of belladonna and hyoscyamus, discovered by BRANDES and RUNGE, and expressed my conviction of the great utility to be derived from these substances, in several diseases of the eye, and preparatory to different operations, on account of their being stronger and more certain in their action than the extracts generally made from these plants. My expectations appear now to be realized; for having found leisure to put them to the test of experiment, I have obtained the following results:—

"Hyoscyamine, prepared from the henbane seed, I found to be an extremely powerful substance for the dilatation of the pupil. A small drop of a solution of hyoscyamine (gr. i to ℈ss of water) was introduced into the eyes of dogs and cats; the eye was scarcely at all irritated in any case, and the pupil was so considerably widened, that, an hour after the application of the solution, only a small ring of the iris could be seen beyond the edge of the cornea; and after three hours, the pupil appeared as large as the cornea itself, without the power of vision being diminished, or any other bad symptoms being induced, even when the solution was introduced into both eyes. After three days the dilatation of the pupil first began to diminish; and it was not before the sixth day that the iris recovered its natural state. A drop of a solution of extract of hyoscyamus, containing five grains of the extract to half a scruple of water, produced in the same eyes a considerable irritation for the space of from five to eight minutes, which was shown by the secretion of tears, shutting of the eyelids, rubbing of the eyebrows with the feet, &c.; and a much less complete dilatation of the pupil, which in dogs disappeared after six or eight, and in cats after twenty-four hours. As soon as we learnt by these experiments, which we frequently repeated, that the hyoscyamine did not in its action injure either the conjunctiva, or any of the deeper-seated organs, as for instance the retina, I proceeded to apply it on the human eye, and found that a drop of a solution of one grain of hyoscyamine, in a drachm of distilled water, applied to the eye of a cataract patient, seventy-one years old, produced such a dilatation of the pupil, that only a small ring of the iris was apparent. The pupil continued dilated seven days, during which time the old woman could see moderately well, and no irritation whatever was produced in any part of the eye. At another time, a drop of a solution of five grains of extract of hyoscyamus in half a scruple of water, applied to the same eye, produced a considerable burning, and only a moderate dilatation of the pupil after twelve hours. From other experiments with the hyoscyamine, we obtained nearly the same results. The hyoscyamine which was obtained from the stalk and leaves of the plant irritated the eye much more, and was less efficacious, than that obtained from the root."

When the organ is inflamed and painful, so that it will not bear any direct application to its surface, the moistened extract of belladonna should be used; under other circumstances, dropping the solution into the eye is preferable, as being more powerful. If we wish to produce the greatest influence in the quickest manner, we may employ both methods at the same time.

The same substance will enlarge the pupil, when applied externally in

the neighborhood of the eye, as to an ulcer of the face,* or tongue,† or when taken into the stomach. In the case of a boy who had swallowed a teaspoonful of the moistened extract of belladonna, supposing it to be an electuary, and in whom a most alarming effect on the nervous system was produced, both pupils were dilated to the utmost, and continued so for two or three weeks.

The immediate effect of these narcotics is enlargement of the pupil, or, in other words, contraction of the iris, which at the same time loses its power of motion, so that the pupil remains dilated even in the strongest light: hence HIMLY has called it paralysis of the iris. The influence is generally produced in half an hour, or from that to an hour after the application to the eye, and the dilatation lasts for several hours or even some days. It is not uniform in all individuals, being greater in proportion to the healthy state of the eye, and sometimes so considerable as to reduce the iris to a narrow scarcely perceptible ring. Under such circumstances, vision becomes imperfect, sometimes to an alarming degree. This kind of amaurosis, which is analogous in its cause to the momentary dazzling and confusion of sight experienced in passing from a dark place into a strong light, goes off as the action of the iris returns, producing no permanent injury; as soon as the iris recovers its power of motion, vision is as perfect as before. I believe that the notion of the belladonna being injurious to vision‡ is unfounded. The Germans, however, acting on this notion, use hyoscyamus, which has a more feeble and temporary influence. In this country, the belladonna is used almost exclusively, as the more powerful agent; the suspicions of its injurious influence may have arisen from its greater efficacy in dilating the pupil. I have known some instances in which it has been employed daily for many years: it has merely dilated the pupil, without injuring sight, or doing harm in any way. We learn, too, from such cases, the important fact, that its influence on the iris is not diminished in the slightest degree by use. In two patients, of whom one had used it four or five and the other fourteen or fifteen years, it dilated the pupil just as well at the end as at the beginning of those periods.

Patients have occasionally complained of pain or undefined uneasiness as following each employment of the belladonna; but it has sometimes appeared to me doubtful whether such sensations were caused by the application.

SECTION II.—INFLAMMATION OF THE AQUEOUS MEMBRANE.

Synonymes: *Inflammation of the capsule of the aqueous humor:* WARDROP. *Inflammation of the aqueous chamber; aquo-capsulitis;* MACKENZIE. *Kerato-iritis;* ROSAS.—This disease, which forms a connecting link between the external and internal ophthalmiæ, has been called *inflammation of the anterior chamber*, because the visible changes are nearly confined to that part. We cannot doubt, however, that the inflammation occupies the posterior as well as the anterior chamber. It is frequently accompanied by *hypopyon*, that is, by the formation of matter which collects at the bottom of the anterior chamber.

* RAY mentions in his Historia Plantarum (L. 13, c. xxiii.) that in a woman who applied the leaves of belladonna to a cancerous ulcer below the eye, the pupil became dilated after each application.

† LANGENBECK, Neue Chir. Bibliothek, vol. ii., p. 389.

‡ BENEDICT, De Morbis Oculi Inflammatoriis, p. 116; see also his Handbuch, &c., vol. i., p. 7—9.

External inflammation, involving the cornea, may extend to the anterior chamber, and thus the iris may become adherent to the cornea; again, inflammation commencing in the iris may spread over the cavity which contains it, and in this case hypopyon is sometimes produced.

The disease, however, which I am about to describe, is a primary affection of the cavity containing the aqueous humor, not extending to the more internal tunics, and affecting the exterior of the globe only secondarily. I used to see it frequently in children from two to eight years of age, at the London Ophthalmic Infirmary; it is less common in older subjects, and Mr. Mackenzie probably alludes to this circumstance, when he calls it a "rare ophthalmia." (Op. cit., p. 472.) Between the membrane of the aqueous humor and the serous membranes there is analogy of structure and disease. Both are equally prone to adhesive inflammation, that is, to the effusion, under various appearances, of the matters called albumen or coagulating lymph, and to their subsequent transformation into preternatural adhesions, or adventitious membranes; and such effusion, when it is interstitial, may cause opacity in both instances.

Symptoms.—The cornea loses its transparency, exhibiting at first general dullness, then nebulous opacity more or less considerable; often there is an ulcer on its surface. The anterior chamber looks cloudy; but it is difficult to decide whether this appearance is owing to the state of the cornea or to a change in the aqueous humor. There is some, but not considerable external redness: it is chiefly in the form of a pink zone round the cornea. The color of the iris is altered; it loses its brilliancy and fibrous character, and becomes dark and dull. The whole surface, or at least the inner circle, assumes a reddish-brown tinge, and the pupillary margin becomes thickened. This reddish color of the iris is more remarkable in blue or gray eyes. The pupil is rather contracted. An effusion of yellow matter takes place into the anterior chamber. There is a sense of tightness and fullness in the organ, and the patient complains of pain and aching in the eye and forehead; but this affection often happens in subjects who are too young to express their feelings. Lachrymation and increased sensibility to light exist in greater or less degree. There is a white tongue, with some feverishness; these and the pain are confined to the commencement of the affection; so that, when the symptoms above described are fully developed, the patient is free from uneasiness, and opens the eye to the light without any appearance of intolerance. The progress is not very rapid; and it goes on for several days without the child suffering much.

Mr. Wardrop, who calls the disease inflammation of the membrane of the aqueous humor, represents that the opacity is seated on the internal surface of the cornea, and that it consists chiefly of small roundish specks, which give the part a mottled appearance. I do not know whether this affection, as I have described it in children, ought to be considered as included in his account of the subject, which seems to have been drawn from the adult, and to include many of the cases usually called iritis. In the latter, I have recognized the accuracy of Mr. Wardrop's description, but I have not seen this particular modification of opacity in the child, in whom the cornea seems to suffer generally. It is enough to know practically that the opacity, whatever may be its seat, will disappear, when proper means have been adopted to remove the inflammation.

Another question has arisen respecting the effusion into the anterior chamber, whether it is rightly named pus. Mr. Wardrop calls it albumen, considering it to be the same as that poured out on the iris, which causes adhesions. In the cases I have described, the pupil does not become adherent.

Treatment.—The affection is easily controlled: it yields readily to simple measures. We begin with leeches and aperients, and then proceed to the mild administration of mercury. A grain, or half a grain of calomel, or two grains of hydrarg. c. creta, combined with one or two grains of James's powder, should be given twice, or, if necessary, three or four times in the twenty-four hours. Counter-irritation is seldom necessary. Under this plan, which may be continued for a few days, the inflammation is soon removed, and the matter speedily disappears. Local means are of little service; occasional fomentation with the poppy, decoction or warm water, will suffice.

If this disease should occur in children of scrofulous constitution, the symptoms will be somewhat modified. The pain and intolerance of light will be more marked. It would be right to administer mercury more cautiously, and to combine it with tonics, such as the sulphate of quinine; or it may be omitted altogether, although its efficacy in checking effusion, and thus preventing change of structure, makes it a desirable remedy in such cases. The occasions are rare in which it is not admissible in small doses, and in conjunction with such other means as the state of the patient may require.

The characters of the affection are more distinctly marked, when it occurs in the adult. They are: 1st. Increased external redness in the form of a pink zone round the cornea. A narrow white line intervenes between the zone and the cornea, and red vessels do not extend into the latter. 2dly. Hazy or nebulous state of the cornea, more or less dense, with completely opaque, circumscribed, grayish, or yellowish-white specks or dots, not exceeding the size of a pin's head, in greater or smaller number. The haziness or nebula, with the opaque spots, is seated in the aqueous membrane, the latter being albuminous effusions on its surface, similar to what occur in other serous membranes when inflamed. In other respects the cornea is unaltered; the corneal surface has its natural polish and moisture, and the laminæ retain their transparence. The latter point is clearly ascertained by careful inspection, and especially by looking at the eye obliquely, when the situation of the opaque change on the aqueous surface of the membrane will be readily recognized. Similar albuminous depositions may be sometimes discovered on the surface of the iris. These circumstances are most distinctly seen in the early period, and when the affection is confined to the aqueous membrane. As the disease advances, the opacity becomes more considerable, and the cornea suffers more generally. 3dly. A turbid state of the aqueous humor, with or without shreds of lymph, has been generally enumerated among the symptoms. I do not doubt that the secretion is altered, but I have not been able to convince myself of the fact by direct inspection; the difficulty arises from the cloudy state of the cornea. 4thly. Dullness and change of color in the iris, especially in its inner circle, which has a general dull brownish-red tint, although the exterior circle may have its normal blue or gray color. Slightly contracted, misshapen, and motionless pupil, of which the edge may be thickened, and partially adherent, with albuminous effusion into the opening. Sometimes the iris and pupil are little altered; or their state may be concealed by the condition of the cornea. 5thly. Imperfection of vision, from dimness to loss of all useful sight. 6thly. Pain of the brow, with sense of fullness and tension. The latter feeling must be referred to increased secretion of the aqueous fluid, which distends the anterior chamber, and is said even to increase the prominence of the cornea. Increased sensibility to light, with lachrymation. 7thly. Puriform or more consistent effusion into the anterior chamber, under the form of hypopyon, is seen occasionally, but less fre-

quently than in younger subjects, and with more acute inflammatory symptoms. It is said that blood is occasionally effused into the anterior chamber, and even converted into hypopyon.* The appearance of pus is sometimes preceded by partial reddish discoloration of the cornea, by increased opacity at some point, or by changes considered to denote ulceration of the cornea on its aqueous surface.†

Constitutional disturbance of febrile character in some degree, or disorder of the digestive organs, may accompany the development of the affection; or it may be unattended with marked general indisposition. The character and progress of the disease may be acute or chronic. In the former case, with more redness, in which the conjunctiva participates, there will be considerable pain, intolerance, and lachrymation, and vision is soon seriously impaired. In the latter, which is more frequent, the local symptoms are mild, the pain and intolerance slight, or absent, while the disorder lasts for a long time, or relapses after apparent improvement.

Diagnosis.—The position and dotted or mottled character of the opacity, with the natural state of the corneal substance and surface, distinguish this inflammation from corneitis, where the opaque change is more uniform, where it occupies the whole thickness of the membrane, making the surface irregular, and giving it a sanded appearance. In the latter the vascular zone comes to the very edge of the cornea, and red vessels enter the membrane; not so in the former. The pains, intolerance of light, and lachrymation, are greater in corneitis. The cornea is clear, and the anterior chamber in a natural state in most cases of iritis, where the most striking phenomena are found in the iris itself, and the vascular zone round the cornea.

Under proper treatment the affection is easily arrested, especially in its early stage; the transparency of the cornea is restored, the iris and pupil regain their normal state, and vision becomes perfect. Corneal opacity in various degrees, adhesions of the pupil, closure or obstruction of the opening by adventitious membrane, and injury or loss of sight, are the probable consequences of neglect or injudicious treatment.

The general plan of treatment includes antiphlogistic means, more or less active, according to the character of the attack and the state of constitution, the use of mercury to arrest the effusion of lymph and cause absorption of that already deposited; counter-irritation by blister or tartar-emetic ointment, and fomentation. The vinum opii may be of use in the chronic stage.

In the following case, the affection, which had been of long duration, with loss of all useful vision, was soon arrested, with complete recovery of sight.

Case.—On the 30th of May, 1826, I saw a young woman of twenty, who looked perfectly well, and stated that she was so. She had sometimes suffered from pains in the limbs, which had never been sufficiently severe to confine her. About a year before she had experienced severe pain in the head. Her left eye began to be affected the preceding Christmas: it was painful and occasionally blood-shot, but not very red. Sight was dim: it had been impaired for the preceding two months. I found general haziness of the cornea, with several small roundish opaque dots, particularly towards the centre; these were obviously on the internal surface of the cornea. The opacity was sufficient to obscure the view of the iris, and especially of the pupil, which appeared contracted and adherent; but I could not determine the latter point. There was slight redness of the sclerotica

* Beobachtungen und Bemerkungen über die inflammatio tunicæ humoris aquei von Dr. Wedemeyer; Langenbeck's neue Bibliothek, vol. iv., st. 1.

† Mr. Tyrrell's Practical Work, vol. i., p. 318.

round the margin of the cornea, and some pain on the same side of the head. There was no useful vision; and the patient was quite unable to read. I could discover no cause for the disease. (Twelve ounces of blood from the nape by cupping; a dose of calomel and jalap; pil. hydr. g. v every night; to abstain from fermented liquors.) *3d June.* Improved: (to take the pill night and morning.) *3d July.* The treatment has been continued to the present time with great improvement. The pain and redness are gone; the general haziness of the cornea has disappeared, and the dots are lessened. The iris and pupil are now clearly seen; the former is altered in color, being lighter than that of the sound eye. The pupil is contracted, and rendered irregular by small white adhesions, but otherwise clear. She can read a small print with ease.

In a case seen by Mr. MACKENZIE (op. cit., p. 471), the spots appeared and disappeared at different points of the cornea, even in the space of a few hours.

I saw a lady of full habit, between fifty and sixty, in whom there was general haziness of the cornea with dotted opacity all over. Sight was lost. The inflammatory stage had completely subsided. She had recently employed stimuli, which had made her worse.

[The best marked case we have seen of inflammation of the membrane of the aqueous humor, was the following:

Eliza Williams, a colored woman, aged twenty, applied at the Pennsylvania Eye Infirmary, April 6th, 1826. Her sight had been growing dim for several days, and she suffered slight pain in her eye. On the most minute examination, no change from a healthy state could be perceived, except perhaps an extremely faint dullness, situated at the posterior part of the cornea, the cornea itself being evidently unaffected. After some days a small spot became evident, and was shortly followed by two others, differing both in situation and appearance from the opacities produced from inflammation of the cornea. They were deep-seated, and evidently produced by effusion of lymph on the inner surface of the cornea, giving it the appearance of being mottled with white. The margins of these spots were well defined, and the lamina of lymph so thin as not to produce perfect opacity. These spots remained permanent.]

The aqueous membrane may be the seat of inflammation, not presenting the appearances just described, causing increased secretion of aqueous humour, distension of the cornea, and enlargement of the anterior chamber. There is a red zone round the cornea, probably dullness of the latter, obvious increase of the anterior chamber, sense of distension, with pain of the eye and head. The complaint goes on for a long time, and perhaps ultimately causes diminution or loss of sight. If the affection is obstinate, and the patient's sufferings considerable, it may be advisable, in addition to antiphlogistic and mercurial treatment with counter-irritation, to evacuate the aqueous humor by puncture of the cornea.

A gentleman was under my care with inflammation of the eye, accompanied with enlargement of the anterior chamber. He was about twenty-five, of good constitution, and in good health, except as far as regards the eye. The latter, of which he states the vision to have been always imperfect, became inflamed while he was on duty, as a naval officer in the Mediterranean. The disorder continued with more or less violence between one and two years, and obliged him to return to England. At first view the globe seemed enlarged, but I could discover no increase of size, except in the anterior chamber, which contained about three times the usual quantity of aqueous humor. There was external redness of the eye, chiefly in the sclerotica, round the margin of the cornea; the latter being a little nebulous

at its circumference. The iris and pupil were nearly natural in appearance, size, and movement. The lens was opaque. Increased redness, with pain of the eye and head, came on occasionally; but in general there was no uneasiness. The active congestion was removed by cupping, low diet, and aperients. I then evacuated the aqueous humor, and repeated the process four or five times. The eye became quite quiet; but the patient left London, and I did not hear how the case terminated.

SECTION III.—HYPOPYON, (*Eiter-auge* of the Germans.)

The term hypopyon or hypopyum (from υπο, under, and πυον, pus), designates the presence in the anterior chamber of a yellow matter usually called pus, which it closely resembles in color and general appearance, as well as in its inflammatory origin. I have mentioned this as an occasional effect of the disease last described, in which the inflamed membrane of the aqueous humor pours out the matter. More frequently it proceeds from the bursting of a corneal abscess, when it is seen in conjunction with more or less opacity of the cornea and acute inflammation of the external tunics. Abscess of the iris, breaking into the anterior chamber, may produce hypopyon, which may also occur in iritis not proceeding to suppuration, in inflammation of the internal tunics, and in general inflammation of the globe; the circumstance common to the latter three affections, and leading to the occurrence of hypopyon, being inflammation of the membrane lining the chambers of the aqueous humor. When matter is effused behind the iris, as well as in front, the case is called *empyesis oculi*, which is equivalent to suppuration of the eye. Hypopyon, then, is not to be regarded as a peculiar disease of the eye; like the formation of matter in other parts, it is the occasional result of various inflammatory affections.*

The matter of hypopyon, being heavier than the aqueous humor, sinks to the bottom of the anterior chamber, forming a collection, of which the superior surface is a horizontal level line, while the inferior boundary, being formed by the margin of the cornea, is crescent shaped. Sometimes the upper line is not level; the matter is in lumps, and appears heaped up. This is particularly the case in abscess of the cornea, where we see occasionally a stratum of thick matter continued from the aperture to the collection below. In some instances the puriform fluid changes its level, when the head is moved to one side; but in general it is too thick and viscid. Sometimes, when the inflammation is violent, and the matter in heaps, an admixture of blood in small quantity is seen.

It is hardly necessary to observe, that the inflammations, in which matter

* The division of hypopyon into the *true* and the *spurious* may be discarded, as not resting on any satisfactory grounds Beer gives the epithet *true* to that which is produced by acute inflammation of the eye, accompanied with fever; while he says that the *false* is an effusion of puriform fluid not produced by true inflammation.—*Bibliotheca Ophthalmica*, vol. i., p. 53. Richter enumerates five kinds of true hypopyon; four of them are various suppurations of the cornea, the fifth and principal is formation of matter in the chambers from acute inflammation.—*Anfangsgründe*, vol. iii. § 79—87. He then specifies three kinds of spurious hypopyon; 1st, effusion of matter into the anterior chamber without inflammation; 2dly, from metastasis, as in suppressed clap; 3dly, from abscess of the cornea bursting internally; § 90—91. Benedict calls true hypopyon an effusion from the inflamed iris, without abscess or ulcer; false, the consequence of abscess in the iris. *Handbuch*, vol. i. p. 390. True hypopyon, according to Juengken, is inflammatory abscess of the globe; false, is a collection, in the chambers, of matter from an ulcer or wound of the cornea, or an abscess of the iris.—*Lehre*, p. 404—6.

is effused into the anterior chamber, must be treated on the same principles as other ophthalmiæ; that we must depend principally on antiphlogistic treatment and the use of mercury for preventing the occurrence, or arresting the progress of hypopyon. The only question that remains is, whether the presence of matter behind the cornea requires any particular course of proceeding; whether we ought to follow the practice that has been usually recommended, of puncturing the cornea to evacuate the matter, on the supposition of its presence being injurious to the parts with which it is in contact.

The practice of a late eminent oculist was very singular. He treated hypopyon with powdered sugar blown into the eye, with vinum opii, leeches, blisters and washes. If the quantity of matter be large, or if it should increase instead of diminishing, it will be necessary, he says, "without delay, to make an incision through the inferior part of the cornea, in order to discharge it. This incision will be best performed in the manner used for dividing the cornea, in the operation of extracting the cataract." He adds, that the opening in the cornea may close and the matter collect again; the best mode of preventing which is to take care that the first incision shall be sufficiently large; but if it should happen, the cornea must be again opened, and so on *toties quoties*. The perusal of this extraordinary advice prepares us, in some measure, for what follows. Delay in performing the operation above recommended, "may issue in the total destruction of the cornea, and of consequence, the irrecoverable loss of sight." "In this last and worst stage of the complaint, should it unfortunately have arisen to this height, nothing remains but to open a way for the discharge of the morbid matter, together with the vitiated humors, either by making a large aperture sideways through all the tunics of the eye, or, if the diseased state of the cornea make it necessary, by removing the whole of its anterior portion."*

Richter† recommends the evacuation of the matter by incision of the cornea, as the best mode of treating hypopyon. He says that "as the matter is tough and thick, the incision must not be small. It must be exactly like that for the extraction of the cataract; but it need not be quite so large. It is enough to divide the cornea in one-third of its circumference."‡

Langenbeck§ and Benedict‖ follow the same practice.

In his early writings, Beer¶ recommended letting out the matter: he appeals to his great experience, and will hardly condescend to notice objections. "Any one," says he, "who has successfully and completely cured by incision so many cases as I have, will not think it worth while to hear or read, and much less to refute such objections." Subsequent observation induced him to change his opinion completely, and to reprobate the incision in equally strong terms. "When matter shows itself in the anterior chamber, the surgeon must on no account think of opening the cornea; for the eye would certainly be much injured." I am sorry to say that the treatment he recommends is quite as objectionable as the discarded operation: it consists of dry warmth to the part, laudanum dropped between the lids, and blisters, combined with calamus aromaticus, naphtha, opium, and in urgent cases bark!**

Scarpa†† judiciously advises active antiphlogistic treatment, observing that the matter will be absorbed after the inflammation has been removed;

* Remarks on the Ophthalmy, &c., 5th ed., p. 74—76, and Cases 5 and 6.
† Anfangsgründe, vol. iii., § 92.
‡ Ibid., § 99.
§ Neue Bibliothek, vol. i., p. 182.
‖ Handbuch der Augenheilkünde, vol. i., pp. 359 and 393.
¶ Bibliotheca Ophthalmica, t. i., pp. 41 and 98.
** Lehre, vol. i., p. 430.
†† Treatise, p. 267 and following.

and he rejects the operation because it aggravates the inflammation, and gives rise to greater evils than the hypopyon itself.

WALTHER rightly observes that the operation for hypopyon should not be thought of until the secretion of matter in the corneal abscess has ceased, or the inflammation of the chambers is at an end.* If he had proceeded to say that it is then unnecessary, he would have spoken more consistently with his own principles; for he shows how actively absorption goes on in the anterior chamber. He chooses for the operation the very period when, in consequence of inflammation having ceased, nothing is wanting to complete the cure but a little time for absorption, and when the effused matter, according to his own description of its viscid, dirty-yellow, half-dried and lumpy state,† could not be extracted without difficulty.

I lay it down as an invariable rule not to puncture the cornea in hypopyon. Inflammation must be arrested by suitable means, and the effusion will be rapidly absorbed. If the matter increases, depend on it that the inflammation continues. Can an incision of the cornea be considered a good remedy for inflammation? It is much more calculated to increase than diminish the local disturbance; and as a means merely of getting rid of the matter, it is unnecessary, because the absorbents are very competent to that duty. I never saw an instance of hypopyon in children, where the puncture of the cornea was necessary, or even justifiable. These cases invariably do well under the treatment I have described. I have seen the anterior chamber punctured for hypopyon in the adult, but never with any beneficial result that might not have been obtained without it. These reasons are sufficient against the practice. There is still another, namely, that the matter is so thick, it will not in general come out. I suppose that the believers in its noxious properties would endeavor to squeeze or scrape it out.‡ The only exception I make to the general rule of not puncturing the cornea is in the case of general suppuration of the globe; but here the eye is lost, and our object is merely to relieve the patient by giving exit to the matter.

SECTION IV.—EVACUATION OF THE AQUEOUS HUMOR.

In connection with this question of opening the cornea to let out the matter of hypopyon, I shall mention the subject of puncturing it to discharge the aqueous humor, as a remedy in some inflammations, and in certain states of the cornea. We are indebted to Mr. WARDROP for this ingenious proposal, which was suggested to his active mind by a singular phenomenon in the dead eye, which I have mentioned in describing the anatomy of the organ, viz., the milkiness of the cornea, produced by squeezing the globe, and the return of its transparency when the pressure is removed.§ It immediately occurred to him, that vascular distension of the internal tunics during life, might cause a similar general cloudiness of the cornea, and that this could be removed by that diminution of the contents, which

* Merkwürdige Heilung, &c., pp. 18 and 66—69. † Ibid.

‡ "When an opening is made in the cornea to let out the matter of hypopyon, we become sensible of its tough viscid nature; for a part only escapes at the moment, while the more consistent portion is discharged gradually, sometimes not without the assistance of art."—BENEDICT, lib. cit., p. 393.

§ Observations on the Effects of evacuating the Aqueous Humor in Inflammation of the Eyes; and on the changes produced in the transparency of the cornea, from the increase or diminution of the contents of the eyeball.—*Edin. Med. and Surg. Journal*, vol. iii., p. 56.

escape of the aqueous humor would produce. In trying it with this view, he found it a source of so much relief to the patient that he was led to employ it extensively in various cases, where there is tension of the globe; and he has found results so advantageous as to induce him to continue the frequent use of the plan, although it does not appear clearly that it has ever had any marked effect in remedying opacity. Relief of pain, removal of the sense of tightness, diminution in the size of the blood-vessels, and improved vision are the effects of the operation, when it acts beneficially.

It may be performed either with a narrow cataract knife or a broad needle: the instrument should be introduced near the margin of the cornea, with its flat surface parallel to the plane of the iris, and carried on till the point enters the anterior chamber, when it may be turned on its axis, particularly if it be a needle, to facilitate the escape of the fluid. It should be immediately withdrawn, as soon as that is accomplished, care being taken to remove it before the iris can fall against it. The knife is the best instrument for this purpose, as it makes a larger aperture, the sides of which will separate so as to allow a repetition of the discharge, if the chamber should become again distended. The chief difficulty of the operation arises from the painful state of the inflamed organ, which is aggravated by the pressure necessary for keeping the lids open to expose the ball. The upper lid should be fixed by the fingers of an assistant, or by Pellier's speculum. The operator presses down the under eyelid, with the fore and middle fingers of one hand, and applies their points over the tarsus, so that they touch the eyeball, and can make such pressure as may be necessary to steady it: or, the patient being placed on a low seat, the surgeon may stand behind him, fixing the upper eyelid and globe with the fingers of one hand, while he makes the puncture with the other.

Mr. Wardrop recommends the operation in gonorrhœal and purulent ophthalmia, whether of the newly-born infant or adult, in cases where the membrane secreting the aqueous humor is inflamed, in inflammation of the external proper tunics, in staphyloma, and in prolapsus iridis, in inflammation consequent on injuries, in some kinds of opacity, in some cases of ulcer, and in all instances of hypopyon. In the latter, he says that it is sometimes necessary to make an incision nearly equal to that for the extraction of the lens. I must observe, that he does not recommend it, in any instance, as the sole or principal, but only as an auxiliary measure of treatment; and that he by no means proposes it, in the severe forms of inflammation in which he has used it, with the view of superseding the antiphlogistic measures, which are obviously required in such cases.

The paper of Mr. Wardrop in the fourth volume of the *Medico-Chirurgical Transactions*,* like everything he writes, is interesting and instructive; it contains a valuable series of cases. I must, at the same time, candidly state, that my opinion of the operation is by no means so favorable as his. I have tried it in some instances, but with so little benefit, that I have not been induced to persist in the practice; and I have been the less inclined to do so in severe inflammations of the organ, because the ordinary antiphlogistic treatment enables us to control them. I think so highly of Mr. Wardrop's knowledge and judgment, and rely so implicitly on all that he relates, that I doubt my own conclusions when I find them at variance with his experience. Let me observe, however, that although the puncture, regarded as an operation, may be spoken of lightly, it is not so trivial as to

* On the Effects of evacuating the Aqueous Humor in Inflammation of the Eyes, and in some Diseases of the Cornea, p. 142.

induce us to perform it, unless with decided expectation of benefit. It is often difficult to fix the eye for any operation, and the pain and irritability of severe inflammation do not make this easier; the swelling of the eyelids in some instances offers a serious obstacle. Cases have occurred where the instrument has been carried as far as the pupil, in which the lens and iris have been pushed forcibly against it, and cataract has been produced; an event which, indeed, is chargeable to unskillfulness, but its possibility must be taken into account in estimating an operation proposed for so great a number of affections: (see page 153, note.) The puncture has not been injurious in any case where I have practised it.

Mr. MACGREGOR* performed the operation twenty-three times in purulent ophthalmia with results so favorable as to induce him to recommend it strongly. He says, "it is to be regretted that this operation is not more frequently performed; for I am convinced that many persons have lost their sight from rupture of the cornea taking place in front of the pupil, which a timely and judicious performance of this operation might have prevented."

MUELLER† speaks favorably of the puncture, which he had performed eighteen times in cases of purulent ophthalmia. LANGENBECK‡ thinks well of the proceeding on the faith of three or four cases in which he had recourse to it.

BENEDICT regards it as the principal measure in the treatment of iritis,§ considering it applicable only where inflammation has affected both chambers. He employs it in every period of acute and subacute iritis, with or without hypopyon, when bleeding and other means have failed to relieve. It must be repeated as often as inflammation and pain return; three, four, or more times.‖

ROSAS¶ has found it injurious in acute iritis.

I believe that it is but little practised at the present moment, either in this country or in Germany.

SECTION V.—EFFUSION OF BLOOD AND OTHER MATTERS INTO THE ANTERIOR CHAMBER.

Effusion of blood into the chambers of the eye has been technically denominated *hæmophthalmus*. I have already mentioned this as an effect of injury in Chapter III. pages 174, 179 and 187. Blood is also occasionally effused, in conjunction with matter in hypopyon, and in iritis. I have seen it poured out into the anterior chamber alone, as an effect of inflammation.

This effusion is sometimes vicarious of menstruation. "I have seen," says P. F. VON WALTHER,** "a considerable quantity of blood effused into the anterior chamber, so as to form a true *hæmophthalmus*, in many cases of acute ophthalmitis. This happened particularly in one instance, where the affection occurred regularly at the monthly period, and supplied the place of the suspended menstruation."

The following case is in some respects analogous:—

"Louisa Martin, aged forty-five, ceased to menstruate during three months without inconvenience. She had suffered some injury of the eyes in early life from small-pox, and had always had weak sight. To these

* Transactions of a Society, &c., vol. iii., p. 59, 60.
† Erfahrungssätze, p. 147.
‡ Neue Chir. Bibl., p. 177.
§ Handbuch, vol. i., p. 409, 410.
‖ Ibid., p. 408.
¶ Ibid., vol. ii., p. 446.
** Abhandlungen, p. 395.

symptoms had lately been added some appearance of incipient cataract, and within the last twenty days she had been affected with an acute and permanent pain on the right side of the head, with throbbing. Besides this, however, there was no change in the habitual state of her eyes till the night of the 28–9th of August, when she experienced a sharp pricking in the right eye, giving the sensation of a foreign body, which she endeavored to get rid of by rubbing the part. In the morning she found that the sight of that eye was lost. She applied fomentations of rose water, and afterwards cold spirits and water, without avail. On the sixth of September she was admitted at La Charité. The ball of the eye was slightly tumefied; the vessels of the conjunctiva injected; the cornea of the affected side more prominent than the other, and perceptibly softer (?); behind it was seen an effusion of blood, occupying the lower part of the anterior chamber, changing its place with the movements of the head, and rising to a level with the edge of the pupil. The headache and pricking continued but slightly. The pulse was natural, but there were nightsweats.

"As this patient exhibited at the same time signs of gastric disturbance, an emetic was ordered on the 7th, which was the only treatment adopted till the 10th, when an astringent wash was prescribed; but, as yet, the blood effused has not been reabsorbed."*

The vicarious nature of the sanguineous effusion into the anterior chamber was unequivocal in an interesting case recorded by Mr. Tyrrell in his practical work, vol. ii., p. 40.

A girl of delicate constitution, between fourteen and fifteen years old, had suffered for a long time from internal inflammation of the eyes, which had rendered the irides dull and discolored, the pupils adherent, and vision very imperfect. Considerable improvement had been accomplished by a long course of treatment; but active mischief again occurred. There was great internal redness, with pain and tension, and almost total loss of sight. The anterior chamber of one eye was filled with dark blood. Under antiphlogistic treatment these symptoms disappeared in three or four days. They returned twice at monthly intervals. Means were now successfully adopted for inducing menstruation which had not occurred previously; and there was no subsequent effusion into the anterior chamber.

[An analogous case is recorded in the *Bulletin Général de Thérapeutique*, April 30, 1835. The subject of it was a woman 40 years of age, admitted into l'Hôpital la Charité, with her left eye filled with blood, the cornea convex, and the sclerotica distended, which occasioned violent shooting pains in the organ and corresponding side of the head. There was no photophobia, but all objects viewed with the left eye appeared red. This condition had existed nine days. No cause could be discovered for this lesion except a suppression of the menses.

By bleeding, leeches to the vulva, and resolvent cataplasms to the eye, the absorption of the blood was effected in two months, and the form of the eye and the faculty of sight were restored.]

In some rare instances blood has been poured out in this situation without previous injury or inflammation, or any recognizable morbid state of the organ. A remarkable example is related by Professor Walther. In a healthy young peasant, who saw well with both eyes, blood came into the anterior chamber, as he was working at harvest, much heated and in a bending position. Subsequently the effusion would occur in consequence of any considerable exertion, or indulgence in drinking, especially when

* London Medical Gazette, vol. v., p. 123. From the French periodical called La Lancette.

the head was held down. WALTHER saw the blood appear, first in small quantity, then gradually increase till it reached the level of the pupil. It would disappear completely in eight or ten minutes. When the effusion was considerable, it was attended with pain and tension of the globe. The blood appeared to come from the posterior chamber.*

In an analogous example related at length by Mr. JOHN BELL,† the effusion occurred in the first instance, in a gentleman of twenty, in consequence of violent exertion in running; and had recurred repeatedly. More pain was experienced than in the former case, and the absorption of the blood was not accomplished until after many days. Vision at last began to suffer, and it seemed probable that sight might be lost.

AMMON relates an instance of spontaneous sanguineous effusion in the anterior chamber of a diseased eye. (*Zeitschrift*, vol. i., p. 103.)

[Spontaneous effusion of blood into the anterior chamber of the eye, may be the result, it is observed by Dr. LOCKART ROBERTSON, (*Northern Journal of Medicine*, Aug. 1845,) of any over-exertion either of the body (*Bell's Surgery*, vol. iii., p. 350), or of the eye, (*Mackenzie, Practical Treatise, &c.*, 3d edit., p. 597,) or it may occur in weak subjects during the progress of scrofulous ophthalmia. (*Zeitschrift für die Ophthal. Erster Heft*, art. viii. *Démours, Traité, &c.*, tom. ii., p. 249.) Again, these spontaneous extravasations may be vicarious with the menstrual discharge, (*Walther, Merkwürdige Heilung eines Eiterauges. Zwieter Auflage*, s. 395. *Landshut*, 1819,) recurring at monthly intervals, and disappearing on the establishment of the catamenia, (*Tyrrell, Practical Work, &c.*, vol. ii., p. 40,) or they may occur in consequence of the cessation of this function. (*La Lancette*, copied in *Med. Gazette*, Oct., 1829.) A hemorrhagic diathesis may cause a similar result. (*Dublin Journal*, vol. xi., p. 395.)

"In such cases there is generally, after any excitement, bodily or mental, a return of the effusion. (*Bell, loc. cit., &c. &c.*) WALTHER, (*op. cit.*, p. 61,) in connection with this subject, relates a curious case, in which the patient could, at will, cause the effusion to occur, which, although occupying half of the anterior chamber, was each time re-absorbed in the wonderfully short period of from eight to ten minutes."

In spontaneous effusion of blood into the eye, the extravasation almost always occurs in the anterior chamber. Two cases are recorded, however, in which it took place into the vitreous humour. Dr. J. ARGYLL ROBERTSON states, (*Northern Journal of Medicine*, Dec., 1844, p. 68,) that he is attending a lady, 26 years of age, with effusion of blood into the hyaloid membrane, apparently caused by a sudden fright. Instantaneous blindness of the affected eye followed. The effusion is gradually being absorbed, and large objects can now be distinguished. The following well-marked case of effusion of blood into the chamber of the vitreous humor, occurring without direct injury, and probably dependent on a diseased state of the vessels of the part, is reported by Dr. C. LOCKART ROBERTSON in the same journal, (Aug., 1845.) The appearances presented in the eye in this case so exactly resembled those of medullary carcinoma, that the true nature of the disease could only be determined by the history of the case.

"Miss ———, ætat. 29, suffered when fifteen years of age from red spots appearing before the right eye, which in about a week yielded to the use of laxatives. When twenty years of age, she remarked that the

* Merkwürdige Heilung eines Eiterauges, p. 61.

† Principles of Surgery, 4to., vol. iii. p. 270.

left eye retained the image presented to it for some seconds after the object had been removed, and vision gradually became more and more impaired in that eye, till August, 1839, at which time she could not distinguish light from darkness. Under the use of leeches and blisters, and of mercury, given so as to affect the system, the sight in December began to improve.

"In June, 1840, she had an attack of blindness in both eyes, accompanied by severe pain in the eyes and forehead, which yielded to leeches, blisters, and mercurials.

"In January, 1842, she had another attack in both eyes, of a slighter character. In December of the same year, the disease suddenly recurred in both eyes, and again yielded to the use of leeches and mercurials. While still under treatment, she had in January, 1843, a sixth attack in both eyes. The same remedies were continued. Subsequently electro-magnetism was tried, with temporary improvement of vision.

"In August, 1843, the disease suddenly recurred, for the seventh time, in the right eye, (owing, it was supposed, to a sudden fright,) and again yielded to leeches and mercury.

"Sight continued improving until May, 1845, when she had another slight attack in the same eye. Under the employment of leeches and mercury, vision is being again restored.

"The right eye, after each attack, presented the following characters:—

"The conjunctiva and sclerotic were healthy, the pupil dilated but perfectly regular, the color and texture of the iris natural. On a minute examination of the posterior chamber,* it was observed that an effusion of blood had taken place into the vitreous humor at the nasal side, and about half-way between the iris and optic nerve. The red color gradually disappeared, leaving a mass of a brownish-yellow color, and of semi-metallic lustre. Under the action of mercurials, the bulk of this deposit was lessened and vision improved. At present it is about the size of a hazelnut.

"No effusion can be traced in the left eye.

"The pale colored mass in the right eye presented appearances nearly resembling those observed in the *first stage* of medullary carcinoma, from which it was distinguished,—

"*Firstly.* By the red color presented by the tumor, after each effusion, which, contrasted with the unvarying dark amber or greenish hue (*Wardrop on Fungus Hæmatodes*, pp. 10 and 41), of the incipient medullary carcinoma; while the single red vessels, (*Dr. Robertson, Northern Journal*, vol. ii., p. 66,) which, in the latter, may be traced over the tumor, were not present.

"*Secondly.* The pupil, instead of being, as it is in medullary carcinoma, irregular, and having the transverse diameter the larger, was equally and regularly dilated; while the color and texture of the iris remained unaltered, instead of being reduced in thickness, (*Dr. Robertson, loc. cit.*,) or presenting the injected, (*Wardrop, op. cit.*, p. 47,) or reddish-yellow hue, (*Dr. Robertson, loc. cit.*,) which it does in incipient medullary carcinoma.

"*Thirdly.* The tumor decreased in size, and sight was gradually restored under the employment of mercurials; while in the malignant affec-

* By the application of belladonna, and by allowing the focus of a double convex lens to fall on the eye, we are enabled more readily to appreciate any alteration in its deeper seated textures.

tion, the size of the tumor never decreases, and vision becomes more and more impaired, in spite of all remedial means.

"Similar appearances requiring most minute attention in the diagnosis, are likewise presented after deep-seated inflammation of the globe, terminating in the deposition of a clot of lymph, (*Lawrence, Practical Treatise, &c.*, 2d edit., p. 697,) or proceeding to the effusion of pus into the cells of the hyaloid membrane, (*Mackenzie, op. cit.*, p. 607.)

"Our *prognosis* in *spontaneous* effusion of blood, be it into the anterior chamber or into that of the vitreous humor, must be very doubtful, the primary cause, in most cases, being a diseased state of the vessels, which are liable again to give way on the application of any exciting cause.

"In spontaneous effusion of blood into the vitreous humor, we have further to fear that this constantly recurring extravasation, and the presence of the organized lymph resulting, may, by compression of the retina, cause at last permanent insensibility to the stimulus of light.

"The *treatment* most to be relied on, on the occurrence of any such sanguineous effusion, is general or local depletion, according to the circumstances of the case, accompanied by cold applications and quiet both of mind and body; while, farther to promote absorption of the effused mass, mercurials must be employed so as to affect the system.

"The recurrence of the extravasation must be guarded against by attention to the general health, due regulation of diet, moderate and regular exercise, avoiding all stooping or over-exertion, more particularly of the eye, keeping the feet warm and the head cool, and sleeping with the head more than usually raised."]

The appearance of pus in the anterior chamber, under various circumstances, has been already described under the name of *hypopyon*.

The effusion of lymph in the chambers of the *aqueous humor*, which occurs in inflammation of the iris, see Chapter XVI. § 1, has been technically called Hypolympha.

It has been supposed that milk, or a fluid nearly resembling it, is poured out sometimes into the chambers of the eye, and the name of *hypogala* has been given to the case. I do not consider that the fact is as yet established by sufficient evidence. Rosas, however, admits it, and says that it occurs under the following circumstances, viz., in suckling women, when the secretion of the breasts is suddenly interrupted or suppressed; or in other individuals, of either sex and every age, who take milk diet, and are exposed to disturbance of the cutaneous functions. Handbuch, vol. ii. p. 671.

Beer says, that he has seen spherules of quicksilver in the anterior chamber three times in venereal patients. *Repertorium*, vol. ii. p. 97.

SECTION VI.—ENLARGEMENT OF THE CAVITY CONTAINING THE AQUEOUS HUMOR; DROPSY OF THE ANTERIOR CHAMBER.

I have seen the chambers unusually large, with the cornea transparent or slightly nebulous, as a congenital malformation, in children otherwise healthy. The subjects of this defect have either seen very imperfectly, or been blind. Juengken says that he knows a Swedish family, in which seven brothers are affected with congenital dropsy of the anterior chamber, while the parents and two sisters have no defect in their eyes. *Lehre von den Augenkrankheiten*, p. 541.

I was consulted by a patient in whom the anterior chamber was enlarged, so as to contain about three times the natural quantity of clear aqueous

fluid, the cornea being perfectly transparent, and the pupil filled with an opaque adventitious membrane, as the consequence of acute internal inflammation, which had destroyed sight. The eye had been in the same state for some years.

Long-continued strumous inflammation of the cornea is attended with increased secretion of the aqueous humor and enlargement of the anterior chamber; the latter change being produced partly by greater prominence of the cornea, partly by the iris yielding to the pressure of the accumulating fluid. When the inflammation is at an end, the eye presents a natural appearance in all other respects, but the dropsy of the anterior chamber remains. Near-sightedness is produced, but vision is otherwise perfect. In a case of this kind there may be nebulous opacity of the cornea, with more or less imperfection of sight. I have seen this state of the eye remaining long after the cessation of strumous inflammation: I am unable to state whether it is ever removed, in the course of years, so as to restore the natural proportions of the anterior chamber.

Staphyloma may be considered as dropsy of the posterior chamber; for the tumor formed by the expanded cornea and iris is filled with aqueous humor. (See Chapter XIV. § 5.) We may probably regard in the same light the bulging of the iris, accompanied with absorption of the sclerotica round the cornea, occasionally consequent on severe and long-continued strumous iritis.

When the disease which has produced increased secretion of aqueous humor is at an end, and the enlargement of the cavity containing it is not considerable, we can do no good by surgical interference. Should inflammation still exist, with painful distension of the globe, should the enlargement be troublesome by its magnitude, or should it be attended with occasional attacks of inflammation exerting an injurious sympathetic influence on the sound eye, palliative relief may be afforded by puncture of the cornea; under circumstances of greater inconvenience and urgency, a larger opening may be made in the part, with the view of accomplishing more effectual and permanent diminution.

Mr. Middlemore has seen instances in which the cornea, retaining its perfect transparency, has assumed the globular form, with imperfection of vision. (Vol. i. p. 439, note.) He mentions also two examples in which undue development of the cornea existed. In a young man, the cornea, although perfectly transparent, had increased to three times its natural size, the iris and anterior chamber being enlarged in the same proportion, while the other parts of the eye were of normal magnitude. The same change was beginning in the opposite eye. The other example occurred in an infant after small-pox. The diameter of the cornea of one eye was twice as great as that of the other. Vol. i. p. 546.

CHAPTER XVI.

DISEASES OF THE IRIS.

INFLAMMATION OF THE IRIS; IRITIS.

Inflammation of the iris was, I believe, first described by John Adam Schmidt, professor at the Josephine Academy in Vienna, who designated

it by the term *Iritis*. His Essay,* published in 1801, contains an excellent description, which has not yet been surpassed, of inflammation of the iris, and its various results. To some of these, he acknowledges that his attention had been directed by his teacher and friend, Professor BARTH,† who founded the school of Ophthalmic Surgery at Vienna, and raised it to a high degree of excellence. When the clear account of the phenomena, progress and consequences of iritis, contained in the work of SCHMIDT, is contrasted with the entire ignorance which then prevailed, in this and other countries, on the same subject, we shall become sensible how far the Germans have preceded all other nations in cultivating the ophthalmic department of medicine. It appears incidentally that SCHMIDT was acquainted with the syphilitic and other forms of iritis, although he has spoken of the affection generally, and more especially for the purpose of illustrating some of the consequences which occasionally follow operations for cataract. Inflammation of the iris is not mentioned in the third volume of RICHTER'S *Elements of Surgery*, which was published in 1795, and treats of diseases of the eye; it is not alluded to in the first edition of BEER'S work‡ on diseases of the Eye, which appeared in 1792. In his second and enlarged edition,§ which is quite a different book from the first, BEER has treated the subject at considerable length; and the Germans in general have been well acquainted with iritis and its varieties since the appearance of SCHMIDT'S Essay already quoted, and through the practical lessons afforded in the admirable ophthalmic school of Vienna.

SECTION I.—GENERAL ACCOUNT OF IRITIS AND ITS TREATMENT.

General character of iritis.—The chambers of the aqueous humor, having a smooth membranous lining, which exhales and absorbs a watery fluid, present a striking analogy to the serous cavities. A similar correspondence is observed in their diseases; inflammation being generally attended in the former, as it is in the serous membranes, by the effusion either of albuminous fluid or of coagulating lymph. The peculiar structure and the situation of the affected part will, perhaps, account satisfactorily for our not being able to recognize in iritis the combination of circumstances, which is usually considered to constitute the state of inflammation; viz., swelling, redness, heat, and pain. The inflammatory process, however, is unequivocally characterized by its effects; that is, by altered secretion,—by effusion on the surface or into the texture of the organ; and by impaired function.

The effused matter, which is found under various circumstances and appearances, is called indiscriminately by the not very precise term of *coagulable lymph*. Besides changing the color and general appearance of the iris, it thickens and consolidates this delicate texture, thus impairing and destroying its motions, rendering it at first sluggish and afterwards motionless; it causes adhesion of the iris, particularly at its pupillary margin, to

* Uber Nachstaar, und Iritis nach Staar-operationen, 4to. A good analysis of this Essay may be seen in the first volume of the Quarterly Journal of Foreign Medicine and Surgery; the intelligent writer gives a general account of the views entertained by the German practitioners on the subject of iritis.

† Page 62 of the last work quoted, note.

‡ Lehre der Augenkrankheiten, Vienna, 2 vols. 8vo. 1792. The observations on venereal inflammations of the eye in this work are quite unworthy of the celebrity which BEER afterwards acquired in this department of surgery; they are either vague and unsatisfactory, or erroneous. See vol. i. sect. 425—437.

§ The two volumes of the second edition were published separately, in 1813 and 1817.

the surrounding parts; it alters the form and size of the pupil, contracting or entirely obstructing that aperture, with more or less injury, or complete loss of sight. Thus iritis belongs to the class of adhesive inflammations. The increased action in the vessels of the part, by which the changes just enumerated are produced, is attended by an enlargement of the vascular trunks and ramifications on the sclerotic coat, and, consequently, by preternatural redness of the eye, to which are usually added increased sensibility to light, and lachrymal discharge.

Change of color in the iris.—The change of color which the organ undergoes, is one of the most striking characters of iritis. A light-colored iris assumes, under inflammation, a yellowish or greenish tint; occasionally, it is distinctly yellow; and, if the eye be blue, a bright green is sometimes seen. Generally, however, the tint, whether yellow or green, is of a dull and muddy cast, and darker than in the sound state. In case of the iris being naturally dark-colored, it is less altered under inflammation, presenting merely a reddish tinge. Together with these changes of color, there is a complete loss of its natural brilliancy; it becomes dull and dark, and the beautiful fibrous arrangement, which characterizes it in the healthy state, is either confused or entirely lost. These changes, which are rendered particularly obvious by the contrast between the inflamed and the sound eye, commence in the pupillary margin. In an early period, the very edge of the pupil alone may be affected; the internal circle then becomes altered in color, and thickened; and afterwards, the change spreads gradually to the external or ciliary edge of the iris. This alteration of color is produced by effusion into the texture of the organ: and the particular tint is such as would arise from blending with the natural color of the iris that of the lymph, which is yellowish or brownish.

Effusion of lymph;—its various appearances.—The deposition of lymph in iritis shows itself under various forms: 1st. Its effusion into the texture of the iris causes the changes of color just described, 2dly. It may be deposited in a thin layer, covering a larger or smaller surface. In this way, the edge of the pupil first, and subsequently the lesser circle of the iris, assume a reddish-brown or rusty color in the beginning of the affection. The discolored part has a rough villous appearance, when closely inspected; and we shall generally find, on careful examination, more particularly on looking at the part sideways, that slight elevation and irregularity of surface are produced by this new deposit. Sometimes the stratum of lymph has a light yellowish-brown or ochry tint, and a loose villous texture, rising into obviously prominent masses. The rusty color is the most common, and is observed particularly in blue irides; the other is seen in the gray, or the mixture of gray and orange. This kind of deposit is generally confined to the inner circle of the iris; but the outer circle is usually, at the same time, more or less discolored and dull. 3dly. The lymph may be effused in distinct masses, that is in small drops or tubercles of a yellow, yellowish, or reddish-brown color; sometimes they have a red tint, which may be light or deeper, bright or more dull. They vary in size from that of a pin's head to a split-pea. Often there is only one, there may be two, or more. They may be deposited on the edge of the pupil, or in any part of the anterior surface of the iris. When the inflammation is very active, and has been neglected or improperly treated, the lymph is sometimes secreted so abundantly, as nearly to fill the anterior chamber; in which case it has a light dirty yellowish tint, and often a looseness of texture, with semi-transparency. 4thly. As the iris swells or is pushed forwards in the anterior chamber, its surface being sometimes partially concealed by a thin cloud, while the cornea is losing its transparency, suppuration may take place, and a true

abscess of the iris may be produced. At one or more points a small bright yellow, whitish or reddish-yellow prominence slowly arises from the surface of the iris; assuming a regularly rounded surface. It breaks and pours out matter, which sinks to the bottom of the anterior chamber, and forms hypopyon. Little shreds of the yellow cyst, after hanging from the iris for several days, at last disappear.* 5thly. Effusion may take place into the anterior chamber under the form of hypopyon. 6thly. Under violent inflammatory action, blood itself is sometimes effused; it may be seen alone, or mixed, in a coagulated state, with the tubercular masses of lymph, or with the yellow abscesses. I have seen such effusion of blood where the inflammation has not been of the most violent kind. 7thly. Lymph may be poured out from the margin of the pupil or the uvea, so as to agglutinate them partially or generally to the capsule of the crystaline. A mass of lymph sometimes fills the pupil. More commonly, a thin grayish web or film stretches across the opening, which loses its clear black color, and has a cloudy appearance. Lymph may be effused in considerable quantity into the posterior chamber, and make its way through the pupil into the anterior chamber; it may cause a bulging of the sclerotica, or penetrate that membrane, and form a tumor under the conjunctiva.† I have lately seen an instance of the last description, in a tailor, who had eruptions and inflammation of the eye after a chancre. These symptoms got better, but the eye relapsed in consequence of the patient resuming his occupation prematurely. I found the iris nearly in contact with the cornea; some red vessels were visible in it. The lower and inner half of the anterior chamber was filled with semi-opaque light yellowish lymph; and a small portion of coagulated blood was seen near the ciliary edge of the iris. Lymph of similar appearance was partially visible behind the pupil, towards the nasal side. On the same side of the globe, the conjunctiva was raised into a tumor about the size of a pea; and from the appearance of its contents, through the membrane, there could be no doubt that they consisted of lymph. Such was the state of the eye at the end of about three months. When I saw the patient again, after an interval of five or six weeks, the globe had begun to shrink: the conjunctiva oculi was intensely red, the cornea opaque, with a reddish tinge, so that lymph in the anterior chamber could be discerned through it with difficulty, and the protrusion of the conjunctiva continued of the same size, the brownish-yellow lymph that it contained being more distinctly visible.

The external swelling in these cases has sometimes a yellowish appearance on its most prominent part, from which, in conjunction with the intense redness and violent pain of the eye, it has been supposed that suppuration of the globe had occurred; and the part has been punctured, under that notion. I once did this in the case of a lady, whose eye was destroyed by syphilitic inflammation: neither matter nor lymph escaped from the opening.‡ A case, in which a similar attempt was made with the like result, is related in the posthumous work of Mr. Saunders,§ and illustrated by a colored figure of the organ. It may, I believe, be asserted, that suppura-

* The abscess of the iris is well represented by Beer in Lehre, tab. 2, fig. 1; tab. 1, fig. 6; tab. 2, fig. 4—5; and tab. 3, fig. 1, are excellent views of iritis in other forms Other representations of iritis will be found in Mr. Wardrop's Essay, pl. 8, and in Mr. Tyrrell's work, pl. 3.

† Cases illustrating these occurrences are detailed in my Treatise on the Venereal Diseases of the Eye, pp. 216 and 223.

‡ The particulars are detailed by Dr. Farre in a letter to Mr. Travers:—See Cooper and Travers' Surgical Essays, pt. 1. p. 93—96.

§ Treatise on some Practical Points, &c., 2d ed. pl. 1, fig. 3; and p. 213.

tion never takes place in syphilitic iritis: that the inflammation, however violent, is always of the adhesive kind; and that the changes, to which it leads, are produced by the effusion of lymph. Nor, indeed, have I seen general suppuration of the globe as an effect of iritis in any form.

The effusion into the texture of the iris, which causes a general change in its appearance, and the reddish-brown discoloration of the inner circle, with thickening of the pupillary margin, are generally the first alterations observed in this inflammation; they may take place separately, but are usually conjoined. In a case, which was of rather a chronic type, the greater circle of the iris retained nearly its natural color, while the lesser was reddish-brown or rusty-colored. In another, the whole iris, which was naturally blue, had become dark, dull, and muddy, while the pupillary margin and inner circle were of a rusty brown. As the inflammation proceeds, the tubercular masses appear; thus in one case the whole iris was dull and discolored, the inner circle being of a rusty brown, and a large mass of reddish lymph was deposited on it; in another, the irides were so discolored, dark, and muddy, that their natural appearance could not be estimated; the inner circle rusty brown; the edge of the pupil thick and villous; while about one-third of each was covered by a prominent mass of bright reddish-brown lymph. In the most violent degree, large effusion takes place into the anterior, or posterior chamber, and the pupil.

The progress of the affection was clearly marked in an instance, where proper treatment was neglected; we seldom see it so distinctly, as the complaint is usually arrested by the means we adopt. In this patient, the iris, at the end of nine days, and on the 16th August, had completely lost its blue color, and had a dull, muddy appearance, without any trace of the natural fibrous structure: the inner circle was reddish brown, while, in the outer, this tint was mixed with a dull yellowish color. On the 20th, a mass of light-coloured lymph was effused, and the general discoloration was more striking. Another effusion took place on the 27th. The two portions were united on the 30th, and increased to one light brownish-yellow deposition, covering the lower half of the iris. On the 21st Sept. the inflammation, which had been removed, recurred, and lymph was again effused, increasing in quantity to the 25th. In the following March, nearly the whole anterior chamber was filled with lymph.

Since the several modifications of effusion depend on the degree of inflammation, and not on any difference in the nature of the process, we see them combined together in greater or smaller number according to the stage which the affection has reached, and the effect of the measures which have been adopted. Occasionally, however, we may observe that the inflammation, although violent and of long standing, is characterized by general discoloration, alone, or with the addition of a thin stratum of lymph on the inner circle of the iris; while, in some instances, the tubercular deposition of lymph takes place with hardly any other observable change in the iris.*

When the complaint has been treated properly at an early period, it is soon brought to a conclusion, and several of the effects above described are not produced. We have the opportunity of observing these phenomena where the disease has been neglected and left to its own course; where it has been injudiciously treated, or aggravated by intemperance and other irregularities. Thus we often meet with instructive pathological studies in those who present themselves for relief at charitable institutions. The disorganizing effects of the disease, when thus left to itself or mismanaged,

* The cases illustrating the various points in this and the preceding paragraph, will be found in my Treatise last quoted.

present a striking contrast with the favorable progress and recovery of cases properly treated, enabling us to estimate the effect and appreciate the importance of such treatment.

In carrying on the processes and changes just described, the circulation of the iris is excited, and we cannot doubt that its vessels are enlarged. They may be occasionally seen, especially with the aid of magnifying powers, filled with red blood.

Motions of the iris, and state of the pupil.—The motions of the iris must be seriously impaired by the changes just described, more particularly by the interstitial effusion of lymph. It moves sluggishly at the commencement of the inflammation; and when effusion has taken place, its movements are entirely suspended, the preternatural connections by adhesion concurring with the change of structure in producing this effect. The pupil, consequently, cannot exhibit the ordinary variations in size; it is contracted, and it becomes smaller and smaller in the progress of the affection. At the same time the effusions of lymph and the adhesions change the figure of the opening, rendering it angular, and often extremely irregular. Together with other changes, the pupil sometimes undergoes an apparent alteration in situation, its edge being fixed at one or more points, and free elsewhere. The margin of the aperture is thickened, and has a villous or spongy appearance in the beginning of the disease, presenting a strong contrast to the thin, sharp, and well-defined edge which naturally belongs to it. The effusion of lymph into the aperture, which has been already noticed, destroys its clear black color, and gives it a dull, cloudy appearance.

Increased redness of the eye.—There is more or less external redness of the eye, in the form of a red band round the cornea, deeper-colored and abruptly terminated in front, gradually shaded off behind; the circumference of the globe being comparatively clear. In the commencement of the affection, the anterior part of the sclerotica exhibits a pale pink redness, and the vascular trunks, which lie on this membrane, are seen, of a deeper pink tint, under the conjunctiva, which is then unaltered. The pink tint of the inflamed sclerotica and of the trunks lying on it, which is observed in all inflammations of the membrane, is probably owing to their being covered by, and consequently seen through, the conjunctiva. These vessels advance in nearly straight lines from the circumference of the globe, ramifying towards the front, and are lost in the pink zone. The redness of the sclerotica, and the distension of its trunks, increase as the affection proceeds. The vessels of the conjunctiva soon become partially enlarged towards the anterior part of the eye; they are distinguished, by their scarlet color, from those lying on the sclerotica; they subdivide minutely, and their fine ramifications, which are crowded together, combine with the pink redness of the sclerotica to form the vascular zone round the cornea. The minute vessels terminate abruptly in front, probably passing under the edge of the cornea to the iris; generally the zone does not come to the very edge of the cornea; a narrow white line intervenes. This may extend round the whole circumference of the cornea, or be confined to the inner and outer sides; it is always broader and more conspicuous in the latter situations. This phenomenon is explained by the mode in which the sclerotica overlaps the cornea. The congestion in the former membrane, and in the vessels lying on it, reaches, in these cases, only as far as the situation where the iris is attached on the inside; the thin portion of the sclerotic, which passes externally beyond this situation, remains free; sometimes, however, it participates in the excitement, and then the white line is not seen.

The limits of the zone are clearly marked in front, while it is gradually shaded off behind. It differs in breadth in different instances. It is of a vivid red in acute iritis, when fully developed, the circumference of the globe being paler as the conjunctival vessels are less distended. When, however, the inflammation exists in its most violent degree, all the external vessels of the globe participate in the excitement, giving to its whole visible surface a uniform fiery redness. The red zone lasts as long as the inflammation of the iris continues, and disappears when that is removed; its origin, progress, degree, and termination, manifestly depending on the iritic affection.

The whole iris is usually the seat of inflammation, but not necessarily so; one point only may be inflamed, and then the redness of the sclerotica is confined to the part opposite to the inflamed portion of the iris; again, when the iris is inflamed generally, it sometimes happens that the excitement is more violent in one part, and the external redness will be greater opposite to that part.

State of the cornea and aqueous humor.—The phenomena of the disease show that an intimate vascular connection exists between the sclerotica, the cornea, and the iris, although the arrangement and the communications of their vessels in the healthy state of the organ, are not yet clearly explained. Hence it happens that active inflammation in either of the latter parts causes vascular distension and redness of the sclerotic, while inflammation originating in that membrane may extend to them; the latter event, however, is less frequent and regular than the former. When the sclerotica is inflamed, as it is in an acute attack of iritis, change may be anticipated in the state of the cornea. General haziness occurs at first; this is aggravated, as the case proceeds, and nebulous opacity comes on when the inflammation is violent and long continued. This change affects the cornea generally, in most cases; there may be more considerable partial opacity with the general haziness or nebula. Sometimes, but rarely, there is ulceration of the cornea. These corneal affections add to the imperfection of sight caused by the changes in the pupil. Under the existence of inflammation in the surfaces, which secrete the aqueous humour, we might expect that this fluid would be altered in its properties, and become turbid. We have, however, no clear evidence on this point. In considerable and active inflammation of the iris, with the cornea remaining clear, we can see no change in the aqueous fluid: when the cornea becomes hazy or opaque, we can hardly expect to discern it.

Intolerance of light and pain.—There is generally some, and often considerable intolerance in the beginning, and in the early progress of the affection; together with increased lachrymation, the tears flowing freely on exposure of the eye to light. These symptoms are probably owing to the participation of the sclerotica in the affection; and they continue, although the quantity of light admitted into the eye is constantly diminishing, in consequence of the changes produced in the pupil and the cornea. This was exemplified in a case which I have related in my Treatise on the *Ven. Dis. of the Eye*, p. 259, where the distress was experienced on approaching the light, although it was doubtful whether the patient could distinguish light from darkness, except from this circumstance.

There is generally more or less pain from the commencement, the degree varying according to the acuteness of the attack. It may be considerable, with burning sensation and tension; deep-seated in the globe and orbit, extending to the head, and so severe as to prevent rest entirely. Thus, in one case, there was no rest for three or four days in consequence of unremitting and most severe pain in the organ, and over the brow, and intense

general headache. On the other hand, it may be slight, even when considerable effusion of lymph and loss of sight have occurred. Thus, in another instance, the iris of the left eye was in contact with the cornea, the sclerotica was bulged by effusion of lymph behind the iris, and sight was destroyed; these changes, however, had been produced by inflammation of chronic character, and accompanied with so little pain as not to interrupt rest. In two cases the local appearances were those of the most acute inflammation; in one of them there were large effusions of lymph in both eyes, with the highest degree of vascular turgescence: yet these patients did not complain, and even when questioned, said that they had no pain. In another patient, although a mass of lymph was effused on the iris of the right eye, the patient not only had experienced no pain in the organ, but was not even aware that any disease existed in it. (Op. cit., p. 270.) Patients often complain of great pain in the temple, brow, or cheek, as if it were seated in the bone. In some cases the pain is most severe at night.

Dimness of sight occurs in the commencement of iritis. The changes in the pupil and cornea render vision more and more imperfect, so that the patient ultimately cannot see the largest print, discern objects, or even distinguish light and darkness.

General symptoms.—There is great variety in the degree of constitutional disturbance. In its most acute form, iritis is attended with severe febrile symptoms; with headache, restlessness, and want of sleep; with full and strong pulse; white tongue, thirst, loss of appetite, and costiveness. Often, however, even in cases that would be termed acute, such symptoms exist only in a slight degree, or are entirely wanting.

Progress and extension of the inflammation.—During the occurrence of the changes just described, which might be divided into two stages, that of *congestion* and that of *effusion*, the iris swells, or appears to swell; that is, it approaches towards the cornea, becoming convex in front, diminishing the anterior chamber, and sometimes having its surface puckered and irregular. Is this an actual swelling of the iris, real thickening of the part from interstitial deposition? or mere protrusion by the swelling of parts behind, by the effusion of lymph, or by aqueous secretion? Dissection has not yet elucidated these questions; for opportunities do not occur of ascertaining the state of the iris in the active period of inflammation, by examination after death. In dissecting eyes, which have suffered from iritis, long after the inflammation has ceased, we see sometimes considerable adventitious formations behind the iris, showing that there must have been, originally, large effusion of lymph into the posterior chamber. Does this protrusion of the iris ever occur, except in conjunction with adhesion of the entire pupillary margin, and consequent intercepted communication between the two chambers? I rather think not; but cannot speak positively.

If the progress of the affection be not checked, it does not remain limited to its original seat in the iris. At first it appears on the very border of the pupil; then shows itself on the inner circle; and subsequently extends to the outer circle, presenting the combination of symptoms already described. Supposing it to go on without interruption, it passes from the ciliary circumference of the iris to the corpus ciliare, the choroid coat and retina, with increase of pain and fever, and ultimately with irrecoverable loss of vision, from change of structure in the retina. At the same time the mischief is propagated forwards; the cornea becomes more opaque, the conjunctiva more inflamed, and great external redness is added to all the other symptoms, so that the case which was at first simple iritis, becomes ultimately ophthalmitis, or inflammation involving the external and internal tunics generally. The question naturally occurs, whether the inflammation,

when thus propagated to the posterior tunics, presents in them the same characters as in its original seat; that is, whether it is attended by effusion of lymph? I have never had an opportunity of dissecting an eye in this state of disease, nor are any such dissections recorded. The escape of lymph through the sclerotica, which has been already mentioned, and the bulging of the globe at some distance behind the cornea, in cases where it is disorganized by this inflammation, which certainly is not owing to suppuration, would lead us to suppose that the question ought to be answered in the affirmative. Sometimes the internal tunics suffer generally from the beginning; and vision is impaired, although the pupil may remain clear. The term iritis, implying that disease is confined to one texture, is not properly applied to such cases.

Effects of iritis—gradual recovery.—The effusion into the texture, or on the surface of the iris, like the interstitial deposition which produces swelling of other inflamed parts, is removed by absorption when the inflammation is at an end. Under favorable circumstances, that is, when the inflammation is recent, and proper treatment has been adopted, the iris may be completely restored, recovering its natural color, brilliancy, and power of motion. This restoration may take place equally whether the organ should have been simply discolored, whether suppuration should have commenced in the form of yellow abscess, or effusion of lymph should have taken place, either in a thin stratum or in tubercular masses.

Change of texture and color in the iris.—Where the inflammation has been more violent, and of longer duration, we shall find that it has produced serious changes of structure, which come under our observation when the active excitement has subsided. The eye may be flattened anteriorly, if the iris should have become adherent on both surfaces: but these are not ordinary consequences of iritis. I have seen dropsical enlargement of the anterior chamber (*hydrophthalmus anterior*) with closed pupil, and staphyloma scleroticæ, as results of the disease.

When the disorder has been of acute character, affecting the entire iris, and particularly after repeated attacks, serious disorganization is the consequence. The color and texture are so much altered, that the normal appearance of the iris is lost. The pupillary margin is adherent to the capsule of the lens; the iris no longer forms a level partition between the two chambers, but is elevated into a convex protuberance, which is puckered in various places. It has commonly a dull leaden color, with dark spots in various number, and an intermixture of white, apparently tough fibres. Usually this kind of change is general; it may be partial. It has not yet been ascertained whether the iris be thickened in these cases, or pushed forwards by a secretion behind.* Sometimes the iris ultimately becomes thinner and lighter colored than in the normal state. The cornea may be clear, or more or less opaque. Vision is irrecoverably lost; for, whenever the inflammation is sufficiently violent to produce such changes, it will be found to have extended to the retina, and to have rendered it insensible.

In other cases the effects are less considerable; but the continuance for some weeks of slighter inflammation will produce permanent change in the

* Dr. Klemmer, of Dresden, represents this state of the membrane as thickening and consolidation from interstitial effusion of lymph occurring in parenchymatous iritis. He has not ascertained this by direct examination in the human subject, but has found the iris thus thickened in the eye of an ox. To this mere thickening from inflammatory effusion, he has given the name of iridoncosis, as if it were a distinct disease; and has described it in that point of view with tedious minuteness. Die Iridoncosis, ein wenig bekannter Ausgang der Iritis parenchymatosa; in Ammon's Zeitschrift, vol. v., p. 203; with five figures.

texture of the iris, causing alteration of its color, which may be lighter or darker than the healthy tint, diminution of its lustre, and confusion of its fibrous structure, so that it presents a striking contrast to the sound iris. Sometimes it is marked with small dark specks; sometimes it has, almost throughout, a dull leaden hue. These organic changes concur with the adhesions of the pupil in lessening or destroying the motions of the part. In the iris, when thus seriously disorganized, vessels carrying red blood are occasionally visible to the naked eye, in greater or smaller number.

In a case of acute syphilitic iritis, with a large effusion of lymph, the part of the iris which had been covered by the lymph was left, after its removal, of a dark black color. It was a little elevated above the level of the iris, and of triangular figure, with the basis at the pupil, and the apex at the edge of the cornea. Vision was perfectly restored in this case.

Adhesions of the pupil.—The lymph effused in iritis, like that poured out on the surface of an inflamed serous membrane, soon becomes organized, producing adventitious structures of a permanent character. Thus, when the inner circle of the inflamed iris has regained its natural appearance by the progress of absorption, the edge of the pupil is found preternaturally fixed to the crystaline capsule. The whole pupillary margin may be thus fixed. A tubercle of lymph effused on its edge will leave an adhesion including one-half, one-third, or one-fourth of the circle. The pupil may be closely attached at one or more points, the rest being free. More commonly the connection is effected by slender threads, one, two, or more, long enough to allow some motion; there may be many of these fringing the whole opening. Such adhesions are dark colored; that is, they are of the same color as the edge of the pupil or the uvea, partaking, like other adventitious formations, of the nature of the surface which produces them.

Under suitable treatment, in an early stage, adhesions of the pupil are sometimes detached, leaving behind, at least, in some instances, black marks on the capsule, which I believe are permanent. These marks escape notice in consequence of the blackness of the pupil; they are, however, sometimes detected on close examination with a strong light on the eye. I have seen a complete circular series of such marks, which I discovered while accidentally examining the eye with the sun shining upon it. The patient had labored under iritis; and the pupil, which had been fixed to the capsule in its whole circumference, was completely liberated by the means employed.

Adhesions of the pupil are sometimes whitish or grayish, not being colored by the pigment. The difference probably arises from the lymph being effused from the anterior surface, or iris properly so called, in the one case, from the pupillary margin or uvea in the other.

The changes now described must necessarily affect the figure and motions of the pupil. It is generally contracted; and it may exhibit every variety of form, being in different cases oval, angular, shaped like an hour-glass, stellated, or otherwise irregular. Mere alterations of figure are not injurious to vision; which is just as good with the most irregularly shaped pupil as with a circular one; and we often see perfect vision with great and permanent contraction of this aperture. It must be understood, of course, that the retina is uninjured, and that the pupil, however irregular or small, is clear. By the adhesions now described, the motions of the iris are impaired or entirely lost.

Adventitious membrane in the pupil.—If the lymph thrown out into the pupil, and lying on the crystaline capsule, be not soon absorbed, it becomes organized, and forms an opaque adventitious membrane adherent to the capsule and to the pupil, and corresponding in size to the dimen-

sions of the pupil at the time of effusion, (fig. 58.) The opacity of this new production is greatest in the centre, and gradually shaded off towards the circumference. In the contracted state of the pupil, it fills the old aperture; but when the edge of the iris is withdrawn, it is surrounded, partially or entirely, by a clear black margin, and the iris is found to be attached to it by one or more adhesions, which may be either close, or in the form of short black or whitish threads. These adhesions sometimes divide the clear portion of the pupil into small roundish or irregular apertures. In such cases, the pupil does not change under variations in the quality of light; it is usually necessary to apply belladonna in order to expose the clear part of the opening, and the adhesions which connect its margin to the adventitious membrane. If the effusion should have occupied the pupil and margin of the iris only partially, the adventitious membrane will be found towards one side, not in the centre, the edge of the pupil being fixed to it, and thus drawn out of its regular line, while the rest of the opening is natural. This state, which has been called imperfect closure of the pupil (*atresia iridis imperfecta*), is attended with greater or less injury of sight. Although the patient may have no useful vision when the aperture is contracted, he may be able even to read if a little enlargement can be procured by the influence of belladonna.

Fig. 58.

Closure of the pupil, (*synizesis*, a Greek word, συνιζησις, collapse, sinking in; *atresia iridis*, *i. e.*, imperforate state of the iris.)—When large effusion has taken place into the posterior chamber, it is organized into a dense opaque substance, to which the entire circumference of the pupil is closely fixed, the opening itself being greatly contracted, or actually shut, and sometimes removed more or less from the centre of the iris. By this complete closure of the pupil (*atresia iridis perfecta*), the communication between the two chambers is destroyed, and the passage of light into the eye almost entirely intercepted, with corresponding loss of sight. By means of the adventitious membrane thus produced, the uvea may be rendered generally adherent to the crystaline capsule; and there may be a free anterior chamber: or the iris may have been previously pushed forwards and in contact with the cornea, so as to lessen or destroy the anterior chamber.*

Atrophy of the globe, and fluidity of the vitreous humor.—When large effusion had occurred in both chambers, and when lymph has been deposited behind the iris in such quantity as to cause bulging of the sclerotica, or to escape through that membrane and raise the conjunctiva into a swelling, it will be completely removed by absorption, when the inflammation has ceased. But the internal parts of the globe are so altered in structure, that it becomes flaccid, and reduced in size (*atrophia bulbi*). This change sometimes occurs after complete closure of the pupil. A fluid state of the vitreous humor (*synchisis*) and consequent softness of the globe, may take

* Von Ammon has taken great pains to delineate the phenomena and effects of iritis. Twenty-three figures are devoted to this subject in his Klinische Darstellungen, pt. i. tab. 14, and others in tab. 15. His Commentatio de Iritide, 4to. 1838, has two plates on this subject, with eighteen figures, representing the appearances on an enlarged scale.

place after acute syphilitic iritis of long standing, without shrinking in size or atrophy.

Impaired vision.—When the inflammation has extended to the posterior tunics, although it should have been arrested by proper treatment, it often leaves behind imperfection of sight in various degrees; and this may take place in cases of chronic, as well as of acute character. In an instance, where the inflammation was treated rather actively, and lasted a month, several thread-like adhesions of the pupil were produced, and the opening was contracted, but quite clear. The patient could read in a good light, but found a mistiness and dimness before the eye. Both eyes were affected in another patient, the inflammation being of a decidedly chronic character in the right, with very slight redness, and no heat or pain. At the end of ten weeks the pupil, which was clear, was fringed by short dark adhesions, and the patient could only make out large print with difficulty. His sight was afterwards improved, but he could not read a small print by candle-light. In two instances, adventitious membranes were formed in the pupils, leaving, however, in the dilated state, sufficient marginal openings of clear black color for the purposes of vision: one of these patients could distinguish the letters of middle-sized print; but vision was much more imperfect in the other.

After the apparent cure of the disorder, the eye sometimes remains preternaturally sensible to external influences. It will become red, and water, with some pain, on exposure to cold and damp, or after exertion. This is more particularly observed when the inflammation has been considerable, and has lasted long, in consequence of neglect or injudicious treatment; and thus the patient may experience repeated and troublesome relapses of the affection.

Causes.—The causes of iritis are the same as those of other ophthalmic inflammations. In the first place, direct injuries, such as wounds and various surgical operations, particularly those of cataract and artificial pupil. Secondly, over exertion, as in the long employment of the organ on minute or bright objects: in this way it may occur in those whose occupations are attended with continued exertion of the sight. We cannot point out how it happens that the same kind of injurious influence should, in one instance, produce iritis, in another affection of the retina. We observe, however, that iritis is easily excited in unhealthy states of the constitution, such as the gouty and rheumatic, and that produced by syphilis. Observation discloses the fact, that in these cases there is a strong disposition to disease in certain textures; but no satisfactory reason can be assigned for the iris being included among these, unless the observations on gonorrhœal and rheumatic ophthalmia should be considered as elucidating the subject. See pages 295, 296 and 330.

I have heard it asserted that iritis never occurs with obvious effusion of lymph, except under the unsound states of constitution already specified. In corroboration of this remark, I may observe that iritis is rare in young subjects, in whom these states of constitution do not exist; it is comparatively uncommon before puberty. The iris may become affected by extension of inflammation from the external tunics under neglect or improper treatment; but I am speaking of primary iritis, that is, of inflammation commencing in that part, which is a rare affection in young persons. I have seen some instances of the disease, accompanied with tubercular effusions of lymph in children; but the patients have exhibited obvious marks of unhealthy constitution; and a few examples have come under my notice of iritis in infants not apparently unhealthy, where closure of the pupil has taken place from effusion of lymph.

The same external circumstances, such as cold, wet, particular states of atmosphere, which are capable of exciting gout and rheumatism in other forms, may bring on iritis in the predisposed; but it often appears in such subjects without any obvious local agency.

In the same way, syphilitic iritis generally appears to us as the simple offspring of the morbid poison. The only reason we can assign for its occurrence, is the previous existence of primary syphilis, or, to use the ordinary language, the contamination of the body by the venereal poison. When we come to understand the nature and operation of that change, to which syphilitic affections of the throat, skin, bones, and other parts owe their origin, we shall probably be able to explain the occurrence of syphilitic iritis. It may occasionally happen, as some have represented, that cold, wet, and other external influences will immediately excite the complaint in those who are already disposed to it by having previously contracted syphilis; but it appears, in most cases, without any assignable external cause.

According to Beer, syphilitic inflammation of the eye may arise in two ways. External influences, even though slight in degree, and such as would probably be uninjurious to a person in good health, will, he says, excite inflammation of the eye in a syphilitic person. This may at first be a rheumatic or a traumatic inflammation, and may be transformed in two or three days into syphilitic iritis; or, particularly if the constitution be thoroughly affected with lues, syphilitic iritis appears at once under its proper character. This last he calls *primary* or *genuine*, the former *secondary* syphilitic iritis.* I have not seen this metamorphosis of disease; nor do I believe that there is any ground for the distinction.

Whether iritis is caused by the use of mercury.—An opinion has partially prevailed that the use of mercury is capable of producing iritis; if so, it is both bane and antidote; for we know that it will cure the disease. Some have considered that syphilitic iritis, as well as other secondary symptoms, either are rendered more frequent and severe by the employment of this remedy, or owe their very existence to it; while others have spoken of iritis generally as being caused by it. I have seen no instance of iritis, of whatever kind, in which there has appeared to me any reason for ascribing the occurrence of the complaint to this cause. In nine of the cases related in my *Treatise on Venereal Diseases of the Eye*, p. 165, iritis came on where no mercury had been taken previously to its appearance; and in some of them the complaint was severe and produced consequences injurious to vision; in nine others, mercury had been administered only in small quantity, and the mouth had not been made sore; and there is not one in the whole list in which the remedy had either been employed for a long time, or affected the system severely. Iritis occurred in some of the cases which had been treated by Mr. Rose and Dr. John Thomson without mercury.† Dr. Ekstrom, of Stockholm, informed me that he had seen many similar instances in the patients of an institution where the use of mercury in syphilis had been entirely abandoned for a long time. Iritis took place in a woman, who had contracted syphilis from suckling a diseased infant, and had taken no mercury.‡

* Lehre, vol. i. § 547, 548.

† Medico-Chirurgical Transactions, vol. viii. p. 361; and Cases 17–19. Edin. Med. and Surg. Journal, vol. xiv. p. 91.

‡ Medico-Chirurgical Review, August, 1829.—The patient had suckled the child of another woman, who was known to have had the venereal disease. The child, about six weeks after birth, had ulcers of the mouth and blotches on the trunk, and when in this condition was applied to the patient's breast. Soon afterwards, a sore formed near the nipple, with a smooth and slightly excavated surface, thin discharge, indurated

Prognosis.—This is favorable when the affection is recent, and confined to its original seat in the iris. Continuance of the inflammation is attended with increasing contraction of the pupil, with augmented effusion of lymph, and with its organization into those adhesions and adventitious opaque substances, which, together with the contraction of the pupil, so frequently injure or destroy sight. In the progress of the affection, further injurious consequences arise: the inflammation extends to the posterior part of the globe, including the retina, with the greatest danger to vision; also to the cornea, which may become more or less opaque.

We need not entertain apprehension for the result, if the changes, however considerable, are confined to the iris. The inflammation may be arrested; and then extensive alterations of color, large effusions of lymph, and great contraction of the pupil, will be removed. The mere quantity of effusion is of little moment.

Before pronouncing the prognosis, we should closely examine the organ in order to decide the question whether the posterior tunics are involved. The state of vision alone will not determine the point: the changes in the cornea and pupil may impair sight considerably, so that the patient may be unable to distinguish objects, and may be reduced to the mere power of discriminating light and darkness, in cases where the function of the organ is ultimately restored. Indeed, a considerably impaired state of vision is sometimes found where the cornea is clear, and the pupil not visibly obstructed, and yet the sense is recovered; so that even affection of the retina is not necessarily a ground of unfavorable prognosis. The case is hopeless when we find a change of color in the whole iris, with considerable contraction of the pupil and an opaque substance in it, with intense external redness, great and deep-seated pain, and complete extinction of sight. I have not seen vision recovered when large effusion has taken place behind the iris, more particularly if it should have caused bulging of the sclerotica, or have made its way through that membrane. Great contraction and general adhesion of the pupil, a protruded and puckered state of the iris, are very unfavorable circumstances. Considerable imperfection of sight may be removed if the inflammation be recent, but not if it be of long standing. Cases differ so much in the degree of disturbance, and the rate of progress, that we can hardly speak of definite periods. We confidently expect to arrest the inflammation and remove its effects when iritis has lasted a fortnight or three weeks; and we often succeed in cases of a middle kind as to severity, at the end of a month. In a case where the inflammation had existed six weeks, and the patient could not make out large print without much difficulty, complete and permanent recovery was effected. In another, where inflammation of active character had gone on for six weeks, the recovery of sight was nearly perfect. Much improvement of sight was accomplished in a third, although the affection had lasted nearly ten weeks. We must take a combined view of the activity and duration of the inflammation before we decide on the probable termination. The power of treatment is great: much good is often done in unpromising cases: we must therefore take care not to form hastily an unfavorable opinion, and thus neglect means by which sight might be improved.

Treatment.—The three principal objects which we have in view, namely, to arrest the inflammation of the organ; to prevent the further effusion of lymph, and promote the absorption of that which has been already

basis, and great pain: a gland in the axilla swelled to the size of a chestnut. In seven weeks, no mercury having been used, either internally or locally, iritis of the left eye came on. It yielded speedily, as did the primary symptoms, to calomel and opium, under which the mouth became sore.

poured out; and to prevent the contraction of the pupil, may be accomplished by antiphlogistic measures, by the administration of mercury, and by the use of belladonna.

Antiphlogistic means, particularly loss of blood.—It can hardly be necessary to enforce at length the propriety of resorting immediately to active treatment when violent inflammation attacks the delicately organized internal parts of the eye. Whenever, therefore, the inflammation is acute, with great vascular congestion, severe pain, and constitutional disturbance; when we have reason to fear that inflammation may extend from the iris to the posterior tunics, and more particularly if we should suppose that such extension has already occurred, we must immediately adopt active antiphlogistic treatment in all its parts; that is, we must bleed generally and locally, repeating the evacuation until the inflammation is subdued, clear the alimentary canal by an active purge, following it by saline aperients and the tartrate of antimony, put the patient on low diet, guard the eye from all injurious external influences, and keep the body at rest as well as the affected organ. When the disorder is less violent, the local abstraction of blood by cupping or leeches will supersede the use of the lancet. The latter, however, may be advantageously employed in many instances, which, from the duration of the complaint and the local symptoms, would not be considered as of the most acute kind. General depletion may be had recourse to with propriety whenever there is feverishness, particularly if the pulse be full and strong. I must observe, however, that the absence of such symptoms does not contra-indicate venesection. If the local complaint be serious, and threaten mischief to the organ, the treatment may properly begin with loss of blood from the arm, unless there should be objections in the particular circumstances of the case: in the progress of the affection we should not hesitate to repeat the depletion whenever the state of the part, or of the system, or both, call for it.

Mercury.—The measures now described lessen the violence of the inflammation, remove or greatly diminish the agonizing pain in the part and in the head, moderate the accompanying general excitement, and thus give great relief to the patient. But they fail, at least, in many instances, to accomplish the second object. We frequently see, after large and repeated bleeding, that the action of the capillary vessels, the essential agents of the mischief, continues: the effusion of lymph goes on, and leads to the alterations of structure which have been already described. Some further power is necessary to put a stop to this disorganizing and destructive process, and that power is afforded by mercury, not however when employed as a purge merely, nor in those small doses, given at considerable intervals, which have been called alterative, but in such a way as to produce quickly a decided effect upon the system. The mercurial action, when thus effectively and speedily produced, cuts short the inflammation, and puts a stop to the effusion of lymph, when that which is already effused will be absorbed; thus, it not only prevents further changes, but remedies those already produced. The redness of the eye diminishes, and sudden relief is experienced by the patient; the lymph, in whatever form it may have been effused, begins to lessen, and is soon removed; the distinct masses are absorbed; the adventitious layer is removed from the pupil; the color of the iris is restored last. The red zone round the cornea begins to look pale, and soon disappears. Small doses of mercury are quite inadequate to the production of these changes, and I do not know how it has happened that such doses have been called alterative, for they certainly will produce no alteration in a decided inflammatory attack of this kind; while, on the contrary, if any such effect is to be caused by mercury, it must be employed freely. After

the loss of blood, either from the arm, or locally by cupping and leeches, and after clearing out the bowels by purgative medicines, the use of mercury may be commenced; and the best way of employing it is in the combination of calomel with opium, two, three, or four grains of the former with one-fourth, one-third, or half a grain of the latter, every eight, six, or in urgent cases, every four hours. In this plan of proceeding, the influence of the remedy on the system will soon be perceived. Under particular circumstances, blue pill, the hydrargyrum c. creta, or mercurial frictions, may be employed instead of calomel.

[When it is desirable, as is often the case, to continue the use of antiphlogistic measures at the same time that we are endeavoring to establish the mercurial action, we have given with much utility, calomel combined with nitrate of potassa and tartar emetic. The usual proportions are the following. ℞. Calomel, gr. viij—x; potass. nitrat. ʒj; antim. tart. gr. j. ♏. Div. in chart. No. viij. One to be given every four hours.]

Two important questions present themselves respecting the mode of conducting this part of the treatment; first, to what extent mercury should be used; and secondly, how long it should be continued. The more powerful its action on the system, the more effectually does it control the disease, putting a stop to the excitement of the capillary circulation, diminishing the size of the distended vessels, preventing the further effusion of lymph, and its organization into those new structures, which are so injurious to sight. Sometimes these ends are not accomplished by a slight action on the mouth, when a more powerful influence will quickly do the business. Full salivation, quickly produced, cuts short recent disease, as if by a charm. The remedy may then be suspended, and its effects allowed to subside slowly, which will take two or three weeks: it will not be necessary to give any more mercury. Although the disease yields more quickly and effectually to a powerful mercurial action, it will be sufficient, in general, to make the remedy sensible in the mouth. In cases of longer standing its influence is not so quickly effectual. We must persevere until the lymph is absorbed, until the natural color of the iris returns, the red zone round the cornea is gone, and vision is restored. This will require four, six, or eight weeks in some instances. A longer time is usually necessary in relapses and second attacks, than on the first occurrence of the complaint. I attended a gentleman for an attack of syphilitic iritis, in which the disease was of a chronic character; it yielded slowly, and was well in six weeks. It recurred in consequence of premature exposure to cold, and the patient was obliged to keep the house for twelve weeks in a state of salivation, recovering perfect vision, which has continued unimpaired from that time, now many years ago.

The question will naturally occur, why this affection should require a different treatment from other inflammations? whether iritis may not be cured by simple antiphlogistic means? and whether the employment of mercury be absolutely necessary? To the latter, there can be no hesitation in giving a negative reply. Iritis may go through its course and come to an end without any treatment: but, when thus left to itself, it often produces effects more or less seriously injurious to vision, such as contraction and adhesions of the pupil, obstruction of the opening by adventitious membrane, and large effusion behind the iris, with total loss of sight.

Again, the affection may be controlled and brought to a conclusion by the common antiphlogistic means.*

* "In seven cases of eruption, attended with iritis, which have occurred to my observation, the disease has been cured without the use of mercury."—Dr. Thomson in the *Edin. Med. and Surg. Journal*, vol. xiv. p. 91.

Case.—A patient, thirty-two years of age, was admitted into St. Bartholomew's Hospital, under my care, on the 1st of October, 1829, with superficial sores round the orifice of the prepuce, and superficial ulceration of the velum palati and tonsils. He was ordered to take a blue pill night and morning, and the compound decoction of sarsaparilla; and to apply the black wash. On the 7th, his mouth not having been affected by the mercury, the right iris became inflamed; the attack was not severe, nor attended with much pain. Sixteen ounces of blood were taken from the temple by cupping, and active aperients were administered. On the 9th, there was a tubercle of yellowish-brown lymph on the iris, with dimness of sight. The cupping was repeated to the same quantity. On the 14th, twelve leeches were applied to the temple; and he left the hospital on the 19th, perfectly well; the eye had recovered completely.

In another case, where both eyes were inflamed, active antiphlogistic treatment was employed, and the patient became very pale and feeble from the loss of blood. The right eye recovered, but the inflammation continued in the left, with increased pain and lachrymation, and progressive diminution of vision, until mercury was exhibited and carried to the extent of ptyalism.

In general, however, simple antiphlogistic treatment is not so effectual, as it was in the foregoing case, in arresting the effusion of lymph. Hence, when we trust to such means only, although the inflammation may not be violent, the pupil will contract, and lymph will be thrown out: the disease may be checked and subside, leaving the organ apparently recovered, but the adhesions and adventitious membranes resulting from the organization of the newly-deposited substance will permanently injure vision. Many years ago I treated a case of iritis in St. Bartholomew's Hospital without mercury: the inflammation was reduced by cupping, bleeding, and other corresponding measures, but a partial opacity of the crystaline capsule in the centre of the pupil, with imperfection of sight, remained.

During the time that I was surgeon to the London Ophthalmic Infirmary, I frequently saw patients who had been treated by common means, and in whom general disorganization of the iris, contracted, closed, or partially adherent pupil, obstruction of that aperture by adventitious organizations, and loss or serious injury of sight, had resulted from inflammations that might have been checked by mercury, without leaving any permanent ill consequence. I may observe that iritis, of whatever kind, is an affection easily managed; that it rarely fails to yield to proper treatment even when the case has been originally neglected; and that the serious effects just detailed are chargeable to injudicious management only. A strong contrast to such cases is afforded by those, in which mercury is properly administered; the cure in the latter being rapid and complete, and the occurrence of ptyalism being in general attended with the most decided improvement in all the symptoms. In this latter respect the action of mercury exerts a much more marked influence over the complaint than the loss of blood. In numerous instances, which have come under my observation, the continued progress of the inflammation until the system was brought under the influence of mercury, the immediate cessation of pain and the corresponding diminution of all the other symptoms, as soon as the mercurial influence was established, have afforded the most unequivocal proof of the great power which the remedy possesses over the complaint.

In comparing the progress, effects, and treatment of iritis with those of other inflammations, our attention is chiefly directed to the effusion which takes place from the inflamed texture, to its influence on the pupil, and to the paramount importance of stopping that effusion, and producing the ab-

sorption of the newly deposited substance. A very small quantity of lymph thrown out in the pupil, and then organized, may impair or destroy sight. A similar occurrence in any other part would be of no consequence. Effusions take place into the serous cavities, leading to the formation of adventitious membranes, or unnatural adhesions, without any subsequent injurious influence on the functions of the parts. Interstitial deposition occurs in other organs with similar results.

The good effects of the mercurial treatment appear most obvious when it has been resorted to after the failure of other measures. I have seen it rapidly effectual in many cases after active antiphlogistic means had been employed without success. I was consulted in the year 1822, by a gentleman laboring under iritis, who had undergone considerable depletion during three weeks. He had been bled twice, freely leeched and purged, and kept on low diet, the use of mercury having been carefully avoided, under the notion that his constitution, which was supposed to be scrofulous, would not bear it. He had become very pallid and feeble, without experiencing any amendment of the local complaint. The sight, on the contrary, had grown more and more dim. There was a red zone round the cornea, which was hazy; the iris was discolored and dull; the pupil adhered above and below, so as to have the shape of an hour-glass placed horizontally, and vision was so dim that no print could be distinguished. Under the use of the hydrarg. c. creta and belladonna, with a more generous diet and wine, the disease was speedily stopped; the adhesions gave way, so that the natural figure of the pupil was restored, with perfect vision.

Two opposite opinions are entertained respecting the comparative efficacy and advantages of the simple antiphlogistic, and the mercurial treatment of iritis. Some, placing unlimited confidence in the powers of mercury, assert "that the mercurial action *alone*, when properly kept up, is sufficient to subdue the ophthalmia iridis in its most acute stage;"* while others, dreading the injurious effects of the remedy on the constitution, discard it entirely in these cases, believing that other antiphlogistic means are capable of accomplishing all that is required. I cannot adopt either of these views. Although mercury alone, or, at least, in conjunction with purgatives and restricted diet, will often cure iritis, I have seen many instances in which the sufferings of the patient have been protracted, and the organ has experienced serious injury from the continued progress of the inflammation, when the use of mercury has not been preceded or accompanied by the loss of blood. A striking example of this kind is related in my *Treatise on the Venereal Diseases of the Eye*, p. 208, which contains many other cases of acute iritis greatly relieved in their most urgent symptoms by active depletion. The danger of trusting to the antiphlogistic treatment alone has been already sufficiently explained. The practical conclusion, therefore, at which I have arrived after ample experience of the complaint, under every variety of treatment, is, that iritis generally, and the syphilitic form of the complaint particularly, will be most advantageously treated by the successive or combined employment of antiphlogistic means and mercury: that this plan will give the quickest relief, will most effectually arrest the inflammation, restoring the iris to its healthy structure and functions, and will afford the best security against the return of the disease.

Although there are few, if any instances, in which medical treatment acts more beneficially or certainly than when mercury is employed for iritis,

* Dr. Farre, in his Prefatory Observations to the posthumous work of Mr. Saunders; 2d edition, p. 38.

the remedy must not be employed indiscriminately. In determining on its use, and selecting the form and dose, we must be guided by various considerations of individual peculiarity, diversity of constitution, state of general health and constitutional power. Sometimes it disorders the stomach and bowels, disturbs the circulation, causes want of rest and loss of appetite, and must therefore be discontinued. Under such circumstances the local complaint is not benefited; perhaps it will rather be aggravated. Effects of this kind are likely to be produced in those of weak constitution, especially the strumous. Where health is already impaired, or where general weakness has been brought on by previous disease and treatment, the free use of mercury will often disagree, and our expectations of benefit to the local complaint are not realized. In some of the cases now alluded to, the use of the remedy must be abandoned; in others it may be employed cautiously and in small doses, the strength being at the same time supported by good diet, tonic and strengthening medicines, and the general influences favorable to health.

Small doses of mercury have sometimes been of service when the use of the remedy in larger quantities has failed. Between one and two years ago I attended a lady with internal inflammation of the left eye, manifested chiefly by changes in the iris and impaired vision, to which was added slight increased vascularity of the external tunics. She employed calomel and opium freely so as to make the mouth very sore, and kept up the effect for some weeks. The complaint yielded at first; it then became stationary, and afterwards got worse. Ultimately vision was extinct, and the cornea became generally nebulous. In a few months after this unfortunate event, disease of similar character showed itself in the right eye with impaired vision. Remembering how she had suffered from mercury on the former occasion, she said she had determined not to use that remedy again. I was not surprised at her determination, but at the same time strongly recommended her to employ it in small doses, and to go on with it for a considerable time, taking her usual diet and exercise. She took one grain of the hydrarg. c. creta twice a day, and sometimes only once, for five months, with the effect of producing and keeping up slight swelling and redness of the gums. The disease was arrested, sight perfectly restored, the health, strength and appearance decidedly improved.

The hydrarg. c. creta is the mildest and most eligible form of the remedy, where we fear that mercury may disagree. Its efficacy as a mercurial is often underrated. When administered in the dose of two or three grains three times a day, it often makes the mouth sore: and I lately saw a powerful effect produced, in a robust person, by twenty grains given in the dose of two grains and a half three times a day. Swelling of the tongue, gums, lips, cheeks and jaws came on with profuse ptyalism. These symptoms continued with little abatement for about three weeks, and the effect had not completely gone off at the end of six weeks.

The strumous constitution is a reason, not for objecting altogether to the use of mercury, but for employing it cautiously, and in conjunction with auxiliary measures of a strengthening kind.

In some cases, where mercury has disagreed, or where, after a fair trial, the affection of the eye has either not improved or got worse, I have lately employed, with excellent effect, the iodide of potassium, giving three or four grains in two or three ounces of the compound decoction of sarsaparilla, three times a day. The beneficial operation of the change seems analogous to what we observe from the same succession of remedies in certain cases of venereal disease.

Mercury is used with the greatest effect in the active period of the inflam-

mation, and in the acute form of the complaint. It is desirable to determine the time, after which it can no longer be administered with benefit; but this is a difficult point. The question of practical importance is, whether there is any advantage in using it after the active period is passed? In many such cases I have employed it with great benefit to vision: I speak of instances in which pain, redness, and every indication of vascular excitement had disappeared, where the iris had regained its natural character, and the apparently permanent effects of inflammation had been produced, such as organized adhesions, and considerable imperfection of sight. In many instances, where several weeks had elapsed from the supposed recovery of the organ, and where mercury had been used almost without expectation of advantage, it has nevertheless been of service, and has essentially improved vision. In such cases, therefore, it is best to make trial of this powerful remedy. As the circumstances are not urgent, the mercurial influence may be slowly produced; but it will be necessary to keep up the effect for some weeks.

The local employment of mercury has been recommended in addition to its internal use. A weak solution of the oxymuriate has been used as a lotion; and the red precipitate ointment, also in a mild form, has been introduced between the lids. Such local stimuli are obviously inadmissible in the active stage of the inflammation; and I believe that they are of no use as mercurials, at any period. One mode of using the remedy locally is often of much service. When patients complain of severe pain over the orbit at night, the mercurial ointment, combined with opium, may be rubbed on the neighboring integuments of the forehead and temple, with great alleviation of suffering. Eight or ten grains of the ointment, with two grains of finely powdered opium, should be well rubbed in before the time at which the nocturnal pain is expected to recur. A larger proportion of both ingredients is sometimes used.* By this mode of proceeding, for which we are indebted to the Germans, the attack of pain will generally be prevented. The benefit, however, is confined to the relief of this particular symptom: mercurial frictions on the brow do not arrest the inflammation as the internal use of the remedy does.

Belladonna.—The artificial dilatation of the pupil must be combined with the use of mercury in order to prevent that contraction to which there is so strong a tendency in iritis. Belladonna and the other narcotics do not exert their power when the iris is actively inflamed, and the disease not yet checked. The application, however, although it may fail to produce the desired effect, does no harm, especially if it be confined to the surrounding skin, and not actually dropped into the eye: perhaps it may even be advantageous by preventing further contraction.

The use of belladonna is of great importance, not only in preventing further diminution of the pupil, but because the contraction of the iris, under its powerful influence, is capable, where adhesions have already taken place, if the effusion be recent, of elongating them, and sometimes of separating them entirely, so as completely to liberate the pupillary margin. But the belladonna cannot do this alone; two conditions are necessary to the accomplishment of the object; the case must be recent, and with the employment of the belladonna we must produce as quickly as possible a full mercurial effect on the system. Under these circumstances, I have seen the whole edge of the pupil detached from the capsule of the lens, to which it had become adherent; and, in proof that adhesions had previously

* Juengken mentions 20 to 30 gr. of the ointment, with 10 to 15 gr. of opium for each friction.—*Handbuch*, p. 272.

existed, the capsule has exhibited a circular arrangement of black spots, marking their number and situation. These marks, of which the dark color, like that of the adhesions, is derived from the pigment of the uvea, are permanent, so far as my observation goes.

Adhesions of the pupil prevent its dilatation more or less completely, according to their number and nature. A general and close attachment precludes all change in the dimensions of the aperture, but partial adhesions only affect that part of the iris in which they are situated, so that when the edge of the iris is fixed only at certain points, the pupil may be dilated in the intervals, and then has a more or less irregular shape. A close adhesion prevents all contraction in the corresponding part of the iris; but when the preternatural connection is formed by slender threads, the iris may still move in a limited degree. Belladonna and the other narcotics are capable of dilating the pupil in many instances, where the iris is no longer affected by variations in the quantity of light. But the permanent condensation of this delicate texture by the effusion of lymph under violent inflammation, when allowed to proceed uncontrolled, renders it altogether incapable of motion; consequently, in such cases, the narcotics have no effect on the pupil.

Operation of mercury.—We know so little of the mode in which medicines produce their effects generally, that it need not surprise us if we should be unable to explain satisfactorily the beneficial operation of mercury in the treatment of iritis. Its influence is not confined to the syphilitic form of the disease, but extends equally to the idiopathic. Although the general opinion is well founded that the full effect of the remedy is less advantageous in the iritis of rheumatic and gouty persons, I have often found it necessary to use it freely in such cases, more particularly those of the rheumatic kind, and have so employed it with decided benefit, while its more moderate employment in alterative doses is generally resorted to with advantage in all arthritic cases.

The subject receives no elucidation from what we know of the effect of mercury in syphilis. Indeed the latter is quite as obscure as its influence in iritis. After it has been used for three centuries with a confidence in its specific powers almost complete and general, we now find its efficacy doubted by many, while others ascribe several of the symptoms called syphilitic to the noxious influence of the remedy. Putting these doubts, however, out of the question, and supposing the ancient faith and doctrines to remain unshaken, what information do we gain when we are told that mercury cures syphilis by its specific power; or that mercury causes an action or a disturbance in the constitution which destroys the action of the morbific poison?

The case of iritis is particularly favorable for studying the influence of mercury, because the transparency of the cornea enables us to see what is going on in the diseased structure. We can observe the alterations caused by disease, and the changes effected by our treatment. In this way we discover that mercury, when employed in the manner already described, puts a stop to that increased action of the capillary vessels, on which the effusion of lymph depends. A circumstance so striking could not fail to attract notice as soon as the diseases of the eye were closely observed; thus we find Beer strongly recommending the employment of mercury in internal inflammations of the eye expressly on this ground. "I know," says he, "no remedy so capable of preventing hypopyum and opacity of the parts essential to vision, in genuine acute ophthalmia, as mercury."* Again, in the second volume of the same work, he observes, "that no remedy is so

* Bibliotheca Ophthalmica; Vienna, 1799, t. i. p. 55.

efficacious as mercury in the most acute inflammation, and in preventing suppuration and the exudation of lymph, proper evacuations of blood being premised. I promote its excellent effects in obstinate cases by mercurial friction on the superciliary region; and since employing their method, I meet, even in the acutest cases, with no suppuration, nor with cataract from lymphatic exudation."*

The late Mr. SAUNDERS employed mercury in syphilitic iritis only as an anti-venereal remedy. In his Essay "*on Inflammation of the Iris, and the influence of Belladonna to prevent the consequent Obliteration of the Pupil,*" he says, "But this state of the iris (inflammation, with effusion of lymph) sometimes arises from syphilis. Then the general plan of treatment here proposed (the antiphlogistic) must be changed for the specific remedy, and mercury must be vigorously exhibited if it be proposed to obviate the effect of inflammation, which is the same whether the inflammation be general or specific."† His friend and colleague, Dr. FARRE, was led, from observing the influence of the remedy in syphilitic iritis, to employ it in other forms of the disease; and his observation of its great power in arresting inflammations of this texture, led him to ascribe to it a general property of controlling increased action of the capillary vessels. In the observations prefixed to the second edition of Mr. SAUNDERS' posthumous work, he says, "The certainty with which the mercurial action arrested the deposition of coagulable lymph in syphilitic inflammation of the iris, led the editor to give this remedy a fair trial in simple inflammation of the iris, in which the disorganizing process by the adhesive inflammation is precisely the same, however it may differ from the former in its exciting cause. The result of the trial has perfectly satisfied him that the mercurial action *alone*, when properly kept up, is sufficient to subdue the ophthalmia iridis in its most acute stage. Although the full action of mercury is often efficient in arresting that disorganization of the various parts of the body which results from the gradual deposition of coagulable lymph within their interstitial textures; yet the free abstraction of blood is still essential to prevent its bolder and more immediately destructive effusions in phlegmonous inflammation. It is, however, too low an estimate of the operation of mercury to consider it only as a specific against syphilis, or as an evacuant and promoter of certain secretions and excretions,—it powerfully alters the action of inflamed arteries, more especially in respect to the effusion of coagulable lymph, which it, in various degrees, controls, or even altogether suspends."‡

Masses of lymph quickly disappear from the surface of the iris, and the interstitial deposition into its texture is speedily removed under the mercurial action. Hence mercury has been supposed to possess the power of causing absorption. I rather think that it has no such direct operation, and that the removal of these depositions takes place in consequence of the inflammation, to which they owe their origin, being arrested. Thus the effused lymph was immediately absorbed, as soon as the inflammation had been stopped, in the case related at page 399, although the mercurial treatment was not adopted. I never saw it disappear more quickly under any circumstances. In the same way tumefaction from interstitial effusion, whether in the cellular membrane, or in any organ, is soon dispersed, when the increased action which produced it is subdued, although no mercury may have been employed. Again, fragments of cataract, effused blood, and pus are rapidly removed from the anterior chamber without any use of mercury.§

* Lib. cit. t. ii. p. 85. † A Treatise on some Practical Points, &c., 2d ed., p. 66.

‡ See the work last quoted; Preface, pp. 38 and 39.

§ For further observations on the use of mercury in other affections, see my Treatise before quoted, pp. 198—203.

Local applications.—The use of belladonna, and frictions of mercurial ointment with opium on the forehead, which have been already mentioned, hardly come under the denomination of local applications, in the ordinary acceptation of means applied to the eye itself. From these we cannot expect much benefit in a serious affection of parts comparatively internal. Warm fluids, such as the poppy fomentation, or tepid water, to which a little tinctura opii, or extract of belladonna might be added, will be found most agreeable to the patient, who may, however, use cold applications, if he should find them more comfortable.

The use of blisters is not advisable in the active period of the inflammation. They add to the excitement, instead of lessening it, particularly when applied near to the inflamed organ. They are seldom necessary in the treatment of iritis; but they may be employed occasionally, when the violence of the inflammation has been lessened, if the disease should be stationary, and the eye should continue irritable.

Use of vinum opii and blisters in the chronic stage.—After the symptoms of active inflammation have been removed, and sight has been restored, the eye sometimes continues preternaturally red and irritable; it will not bear exertion, or exposure to strong light, and attempts to use it bring on pain. The vinum opii may be employed with advantage in such cases; blistering is also serviceable. The latter remedy may be resorted to when pain continues after the diminution or removal of the other symptoms.

Precaution against relapse.—Relapse of disease is a frequent occurrence in iritis. The eye, although apparently recovered, will not bear exertion, exposure, or the excitement incidental to irregularities in diet. The use of mercury, too, leaves the constitution unusually susceptible of external influences. The injurious effects of premature return to ordinary occupations and habits is often seen in hospital patients, who get tired of restraint and leave such institutions as soon as they feel themselves relieved. Hence it is necessary to pursue steadily a proper course of medical treatment and general care, until the organ has completely regained its normal condition.

Oil of Turpentine.—Mr. Hugh Carmichael, of Dublin, has lately recommended the oil of turpentine in iritis generally, and more particularly in the syphilitic form of the affection.* He appears to place the greatest confidence in the efficacy of mercury, speaking of "its almost unerring powers over the inflammation of the iris," p. 25, and admitting "that in the treatment of disease generally, an instance wherein a remedy is more successfully employed cannot perhaps be adduced, p. 26:" but he recommends the turpentine in instances where mercury is inadmissible, in consequence of its occasional injurious influence, or of the debility produced by protracted disease. The following extract will show the mode in which the treatment was conducted.

"I use the turpentine in this complaint in drachm doses, given three times a day. Its disagreeable flavor and nauseating effects I have found best obviated by almond emulsion. This circumstance it is very necessary to attend to, the medicine being so unpleasant, that if its taste be not in some way disguised, it is difficult to depend on patients taking it with the necessary regularity. In the formation of the emulsion, if double the quantity of confection directed in the London Pharmacopœia be employed, that is, two ounces to the half pint of water, it answers the above objects much better; the residuum may be removed by straining.

* Observations on the Efficacy of Turpentine in the Venereal and other deep-seated Inflammations of the Eye, with some Remarks on the Influence of that Medicine on the System, accompanied by Cases; 8vo., Dublin, 1829.

"With an emulsion so made, the following is the formula I now generally adopt:—℞. Olei terebinth. rectificat. ℥i; vitellum unius ovi. Tere simul et adde gradatim, emulsiones amygdalarum ℥iv; syrupi corticis aurantii ℥ii; spiritus lavandulæ compositi ʒiv; olei cinnamomi guttas tres vel quatuor. Miscè, sumat cochlearia larga duo ter de die.

"In a few cases it has been necessary to increase the quantity of turpentine to an ounce and a half, or two ounces, in the above mixture, the other ingredients being proportionally diminished, so that a drachm and a half or two drachms of it may be taken each time; but in general, when administered to the extent directed in this formula, it has very seldom indeed failed, though extensively tried, and in very urgent cases: the instances of its failure shall be presently noticed.

"The strangury, so frequently induced by the internal use of turpentine, is obviated by the usual means—flax-seed tea and camphor julep: when very urgent, the medicine may be suspended for a time. The tendency to acidity in the stomach, which it sometimes causes, is relieved by the addition of carbonate of soda to the mixture; ten or fifteen grains to the eight ounces will be sufficient; some patients have said, the taste was further disguised by this addition.

"When the local inflammation is high, and acute pain is present in the eye and side of the head, the abstraction of blood from the temple by cupping, or from the more immediate seat of the disease by leeching, may be resorted to: the same practice is adopted where mercury is used. Nevertheless I have frequently, when these symptoms were very urgent, relied solely on the turpentine mixture, and with the most decided and expeditious relief; indeed, in some instances, where the pain and hemicranium existed as acutely as they are, perhaps, at any time to be met with, patients have declared they were considerably relieved after they had taken it once or twice, and that its subsequent exacerbations were lessened in a very remarkable degree. It is in the former cases I have generally found it necessary to follow up the bleeding by increasing the quantity of the turpentine.

"It is highly necessary to observe, that the condition of the bowels will require attention: the beneficial effects of the medicine appear to be in certain cases suspended when constipation is present, and are called forth, as it were, when this is removed." p. 9—11.

The cases related by Mr. Carmichael exhibit the powers of the remedy in a favorable light. In several well marked instances of syphilitic iritis, the pain, redness, and other symptoms were quickly removed, effused lymph was soon absorbed, and vision restored under its influence. In other instances it was less successful.

As the result of some trials of the remedy by Mr. Guthrie, it is reported, that "in some cases it has succeeded admirably; in others it has been of little service; and in some unequal to the cure of the complaint." London Medical Gazette, vol. iv. p. 509.

I have had no experience of this remedy in iritis.

[Our experience with this article is sufficiently ample to satisfy us that the turpentine is a valuable remedy in certain cases of iritis; not as a substitute for calomel in all cases, but rather in those where there are objections to the use of the latter.]

SECTION II.—ACUTE AND CHRONIC IRITIS.

The disease, which I have now described generally, is not a uniform affection, always pursuing a certain course, and marked by the same symptoms; we recognize distinct forms of the complaint, with important differences in the phenomena and treatment.

Acute and chronic iritis.—Cases differ much in the severity of the symptoms, in the rapidity of progress, and in the entire duration. Serious mischief may occur in a few days; or weeks may elapse without permanent change of structure or injury of sight. Hence the distinction of *acute* and *chronic iritis;* or the threefold division adopted by some writers, of *acute*, *subacute*, and *chronic*. There are indeed numerous gradations; but in this, as in other cases, it is sufficient to mark the difference of character generally: we cannot attempt to give a name to each degree.

The acute form of the disease (*iritis acuta*) is seen in robust persons of full habit, where a powerful cause has acted on the organ; more especially if the case has been neglected at the commencement, or the cause has continued to act. Here we shall find bright external redness, great distension of vessels, rapid and general change of color in the iris, contraction of the pupil, effusion into its aperture, dullness of the cornea, loss of sight, agonizing pain of the eye, severe headache, considerable fever, with want of sleep and restlessness. In a few days vision is irreparably destroyed. In one case, at the end of four or five days, the natural color of the iris was completely lost, the pupil filled with lymph, and vision reduced to the mere power of distinguishing light from darkness. In another patient, within a few days, the iris had become so dark and discolored, that its natural color could not have been determined; a mass of reddish-brown lymph was deposited on it; the pupil was irregular, contracted, and motionless; and it was doubtful whether the patient could distinguish light and darkness. The blood drawn from the arm in both these cases had a firm buffy coat.

As examples of slower progress (*iritis subacuta*) I may mention a case in which vision was not seriously impaired at the end of six weeks, although the iris was discolored, and two masses of lymph were effused; a second, where there was discoloration, but the patient could still make out print after six weeks; and a third, in which the disease had lasted nine weeks, yet tolerable vision was recovered. Another patient had iritis of the left eye in rather acute form. I observed in the right eye a stratum of light yellowish lymph of loose texture, covering one half of the inner circle of the iris; there was no redness, no pain, nor diminution of sight, and the patient was not conscious that his eye was affected.

The disease sometimes arises so slowly, proceeding to effusion of lymph and its organization into adhesions, to diminution or even loss of sight, that no visible vascular distension occurs, no alteration is observed in the eye, no pain is felt, and the patient even discovers the existence of the disease accidentally (*iritis chronica* or *lenta*).

Case.—A lady of twenty-five, tall, with light hair and irides, who had been in the habit of spending much time in needle-work, had experienced for some months before she consulted me, dimness of sight in the right eye, which had come on gradually, without pain or redness, except that the eye had been a little bloodshot for a day or two in the very beginning, after which the appearance went off. For the previous six weeks she had been judiciously treated by a physician: venesection, leeches to the temple, aperients, and mercury, carried to the length of salivation, had been employed.

There were three adhesions of the right pupil, scarcely discernible in its natural state, but rendered obvious by the use of belladonna: all useful vision was lost in this eye. Two adhesions existed in the left eye, and vision was dim. No pain or redness had ever been noticed in this eye. The irides, pupils, and all visible parts of both eyes were perfectly natural in all other respects.

Case.—A young lady of delicate frame and constitution, of great information and accomplishments, who habitually devoted a large portion of her time to music, reading, drawing, and fine needle-work, found, on looking at a picture with the left eye shut, that she had lost the sight of the right. She had experienced no uneasiness in it; there had been no redness, nor any other change to attract the notice of her friends. A gentleman, since dead, who had great reputation in this department of practice, was consulted. He said that the eye had probably been originally defective; and in answer to an inquiry on that subject, he observed that there was no necessity for restriction in the use of the other eye. As this opinion, which accorded with the inclination of the patient, was acted upon, the left eye soon became diseased, and the case was placed under my care. I found inflammation of the left iris, with adhesion of the pupil, slight external redness and some pain. In the right eye, the iris was slightly altered in appearance, and the pupil fringed with slender dark adhesions; the aperture itself was clear, but vision was extinct. A mild antiphlogistic treatment, followed by the use of mercury, restored the sight of the left eye: it was necessary to continue the mercurial course for some weeks, although the patient's friends had in the first instance entertained great apprehensions of the remedy, on account of her delicate constitution and supposed consumptive tendency. A relapse took place at the end of a year, when the employment of mercury was again successful, but not till after it had been used for many weeks. In a third relapse, the patient again used mercury, not so much from the recommendation of her medical advisers as from her own conviction that it was the only means of restoring her sight. She employed it by friction, and persevered for five months before vision was restored. These unusually long and repeated mercurial courses produce none of the anticipated injurious effects on health. Disease returned again, and at last destroyed all useful vision. It is now more than twenty years since I first attended this patient; and she is better in constitutional strength than she was at that time.

Extension of inflammation to the posterior tunics is most to be feared in acute iritis, but, that the chronic form of the disease is not exempt from this danger, is rendered evident by the two foregoing histories.

SECTION III.—SYPHILITIC IRITIS.

Iritis is called *idiopathic*, when it occurs from mechanical injury, or other immediate influence on the part, in persons of healthy constitution. The yellow abscesses already described, and the hypopyon resulting from their bursting, are said to belong more particularly to the acute idiopathic disease. The *sympathetic* forms of the affection are those which it assumes in unhealthy states of constitution.

I consider the *syphilitic* to be the most frequent description of iritis: it is indeed very common, and as unequivocal a consequence of syphilitic infection as any other symptom of the disease, although Mr. Hunter* and

* Treatise on the Venereal Disease, p. 324.

Mr. PEARSON* were not only unacquainted with it, but have expressly denied the existence of any affection of the eye as dependent on the venereal poison. It is a secondary symptom, taking place in the constitutional stage of the disorder.

Although sometimes occurring alone, it is more commonly accompanied by other secondary symptoms, such as eruptions, ulceration of the throat and mouth, pains of the limbs, and swellings of the periosteum. It is seen in conjunction with papular, scaly, tubercular, and pustular eruptions. As it belongs to the earlier class of secondary syphilitic affections, it sometimes shows itself, like the other symptoms of that class, before the primary disorder is cured.†

It is rarely seen as a symptom of syphilis in infants: numerous children laboring under this disease have come under my observation, but iritis has occurred in two instances only. In one of them, there were excoriations and ulcerations round the anus. The iris had lost its brilliancy, and become dark-colored; the pupil was slightly contracted, and there was some redness of the sclerotica. On the other case I was consulted by letter from the country. The father had had primary venereal sores before marriage. In a few weeks after birth, the child had an eruption all over the body, wasted, and seemed on the point of dying. It got well under the use of mercury in very small quantities. In a few weeks more, severe inflammation of the eyes came on: mercury was employed in the same manner; the inflammation was arrested, but the child remained blind. I saw it some weeks after. Both pupils were fixed, and moderately contracted. An opaque body, which was not a cataract, was seen behind one; the other was clear. Both eyes were blind.

I have seen one instance in which syphilitic iritis, or rather syphilitic inflammation of the internal tunics, occurred as a secondary symptom, in conjunction with scaly eruption, after the infection of a chap on the hand by the contact of discharge from a sore in delivery.

Syphilitic iritis may be either acute or chronic. It is frequently, but not invariably accompanied with effusions of lymph in masses or tubercles of a reddish or yellowish-brown color. (See fig. 59.)

Fig. 59.

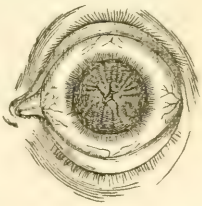

BEER seems to regard these depositions of lymph as analogous to the condylomatous excrescences which appear on the organs of generation and the neighboring parts in some venereal cases. I do not see the analogy. "When effective and appropriate treatment is not adopted at this critical period of the disease, other much more important phenomena present themselves, if it be a case of pure genuine syphilitic iritis. On the pupillary, or on the ciliary margin of the iris, or on both, there are formed reddish-brown, knotty elevations, which become larger and larger, and appear on close examination with a glass, very similar in structure to those condylomata, which are called cristæ galli."‡

It has been represented by BEER and others, that the pupil seems drawn upwards and inwards, or towards the root of the nose; it is displaced in this direction sometimes, but not constantly. Its form and situation depend on the effusions of lymph.

* Letter to Mr. BRIGGS in his translation of SCARPA's Treatise, p. 164—166, note.

† The cases related in my Treatise on Venereal Diseases of the Eye, illustrate the various points referred to in this paragraph.

‡ Lehre, vol. i. p. 558. The appearances are well represented in tab. 2, fig. 4.

The pain is chiefly nocturnal: the patient may have hardly any uneasiness during the day, even although the attack be acute, and the external redness considerable; but, as evening comes on, or soon after bed-time, the pain, which is usually seated in the brow, begins, and arrives at such a pitch as to prevent rest, going off again completely towards morning. Where pain exists constantly, there is a marked exacerbation at night.

I have not seen the appearances described by Beer in the following sentence: "Lardaceous (speckige) ulcers frequently appear at the same time both on the cornea and on the white of the eye; while gummata, or true tophi, which quickly pass into the state of ulceration, form on the edge of the orbit, particularly in the neighborhood of the frontal sinus and at the root of the nose." Lehre, vol. i. § 580.

Diagnosis.—The tubercular depositions of lymph, the reddish brown discoloration of the iris on its inner circle, the nocturnal exacerbations of pain, which is felt either in a much slighter degree or not at all during the day, the angular disfiguration of the pupil, and its occasional displacement towards the root of the nose, together with the previous occurrence of syphilis, and, in most instances, the concomitant existence of other syphilitic symptoms, clearly designate this kind of iritis and distinguish it from other forms of the affection. The local symptoms alone are not sufficient, in all cases, to establish the distinction; for we sometimes see merely a general discoloration of the part, such as might occur in idiopathic or arthritic iritis. In one patient the complaint exhibited all the characters of the latter affection, including the white ring between the red zone and the margin of the cornea; and the state of the iris was similar in another. Under such doubtful appearances, the age of the patient, with the previous and concomitant circumstances, will not fail to elucidate the nature of the affection. In idiopathic iritis there is no distinct deposition, or it occurs as a yellow abscess, with the addition of hypopyon if the abscess breaks. Such yellow abscesses are seldom seen in syphilitic iritis. Lymph is effused from the margin of the pupil in the arthritic species, but not deposited in a distinct form, and the adhesions are generally white. Both in the idiopathic and arthritic iritis the pupil generally retains its circular figure and central position in the iris.

Although the effusion of reddish, brownish, or brownish-yellow lymph on the iris, in the adult, clearly shows the case to be venereal, I have seen analogous appearances in several instances, both of young children and infants, in whom no suspicion of syphilis could be entertained.

The treatment falls under the general rules already laid down.

SECTION IV.—ARTHRITIC IRITIS.

Inflammation of the iris is a common affection in the rheumatic and the gouty. The circumstances characterizing it are, in addition to some local peculiarities, the temperament of the individual, and the previous occurrence, or present existence, of rheumatism or gout.

In describing gonorrhœal inflammation of the external proper tunics of the eye, and rheumatic ophthalmia, I have mentioned that the inflammation occasionally extends to the iris. Rheumatic iritis thus produced is not a serious affection.

The following is an example of simple rheumatic iritis.

Case.—A man, forty-one years of age, who has been subject to occasional pains of the limbs from exposure to cold in his occupation, that of a waterman and fireman, but otherwise healthy, became my patient on the 14th of July, 1831, for an inflammation of the right eye, which had existed three

days. The symptoms were external redness, chiefly in the sclerotica, and in the form of a zone round the cornea; dullness of the iris; pupil rather contracted and irregular; dimness of vision; intolerance of light, and pain shooting across the head. Cupping, leeching, blister, Plummer's pill and colchicum were tried in succession without much benefit. On the 3d of August the sulphate of quinine was given, two grains three times a day, and the emetic tartar ointment was rubbed on the back of the neck. The symptoms rapidly subsided, and he was discharged on the 7th. No effect of the complaint remained except a slender adhesion or two of the pupil. He was readmitted on the 15th with a similar attack in the left eye. The quinine and the tartar emetic ointment were now immediately resorted to, but without advantage. The vinum colchici was then administered in the dose of half a drachm every six hours with some advantage. Cupping, leeching, and blister were employed. He then took a drachm of the vinum colchici every six hours, under which the symptoms quickly yielded, and he was quite well on the 7th of September.

In persons of gouty habit inflammation often attacks the iris, and is usually of an acute character. Uneasy sensations are experienced in the neighborhood of the eye; pains occur about the forehead, brow, and orbit, extending to the side of the head. Redness of the sclerotica comes on with pain of the eye, intolerance of light and lachrymation. It has been observed by the Germans, that in consequence of the repeated motions of the lids, which become red and a little swelled, a small quantity of white froth or foam collects on their edges, particularly towards the angles. With increase of the local symptoms, the iris is now obviously involved; it becomes dull and discolored, the pupil is contracted, but preserves its central situation, and it is fixed at one or more points to the capsulæ. The complaint is attended with headache and feverish disturbance of the system.

The red zone round the cornea does not advance to the very edge of the latter; but a narrow white ring is left between them. This white border is often partial, being observed more especially towards the angles of the eye. It has been remarked by the Germans, that the color of the zone in arthritic iritis is more dull than in the other forms of the affection, that it is sometimes even livid, and that the vessels occasionally exhibit a kind of varicous enlargement. After a violent attack of this kind, with great diminution of sight, the symptoms subside, the eye recovers, and vision is completely restored, the iris being connected to the capsule by adhesions of white color. The inflammation returns again and again, and we are surprised to see the eyes recovering so completely as they do after these repeated attacks. A gentleman whom I saw laboring under severe arthritic iritis, told me that his eye had been inflamed fourteen times, yet vision was unimpaired, though there were in each eye adhesions connecting nearly the whole pupillary border to the capsule. In each attack fresh effusion takes place; the pupil is more and more contracted, and at last filled entirely with an opaque adventitious membrane. Even now, although sight is destroyed, the texture of the iris is in many cases but little altered. Sometimes one violent attack closes the pupil, or greatly contracts and fills it with a densely opaque plug. Sometimes gouty inflammation, when severe and long continued, causes complete disorganization with puckering and tubercular projection of the iris and extinction of sight.

When this violent local inflammation occurs, as it frequently does, in persons of plethoric habit and robust constitution, abstraction of blood by venesection and cupping, and other suitable antiphlogistic measures are urgently necessary. In older persons, whose powers are reduced by frequent gouty attacks, if there is active local mischief, with heat of head, white tongue

and thirst, and full pulse, the indication for depletion is still obvious. The antiarthritic remedies, as they are called, which are either stimulant or narcotic, can only add to the mischief. This remark, however, does not apply to colchicum, which may be employed alone, or in combination with purgatives.

[We have used with great advantage in this form of iritis, colchicum combined with purgatives, in the form of Scudamore's draught, and with the addition of the oil of turpentine. Our formula is the following:—℞. Magnes. sulph. ʒiv—ʒvjs; magnes. carb. ʒij; vin. rad. colchici ʒj—ʒij; ol. terebinth ʒj—ʒij; syrup cort. aurant. (or some other agreeable syrup) ℥j; aq. carbonat. ℥vij. Dose, one to two ounces, two, three, or four times a day.]

I believe that arthritic iritis neither requires nor admits that free use of mercury, which is so advantageous in other forms of the complaint. I have seen cases in which mercury, carried to salivation, has been injurious rather than beneficial. Calomel is useful as a purgative, particularly in combination with antimony; and, after the bowels have been evacuated, mercury may be given in the alterative form, such as Plummer's pill once or twice a day, with mild aperients. Sometimes we are obliged to use the remedy more freely, and we do it with advantage.

Absence from all stimuli in diet, and attention to the state of the bowels, are points of obvious necessity. Counter-irritation by blister, or preferably by the tartar emetic ointment, may be employed with advantage after depletion. Tepid fomentations are the best local means. The Germans recommended dry warmth, and opiate frictions to the forehead, using for the latter purpose opium moistened with saliva or mucilage.

Since repeated attacks of arthritic iritis must either seriously injure or destroy sight, it is of importance to adopt preventive measures; to enforce such regulations of diet and mode of living as will remove that plethoric state of the system which exposes it to the attacks of gout.

I subjoin two cases to illustrate the nature of the affection.

Case.—In the summer of 1829 I saw a gentleman, forty years of age, of sanguine temperament and stout frame. He led a dissipated life at Oxford, where he drank port wine very freely. At the age of twenty-two he had a severe attack of gout, that is, painful affection of the feet, knees, and other parts, which lasted several months. This induced him to leave off port; but, having an excellent appetite, he has been accustomed to eat largely, and to drink beer and other liquors. Since his arthritic affection he has had ten attacks of inflammation in the right eye, and the left suffered on two occasions. At one time he had no inflammation of the eyes for three years; and in that time he had swelling, with some pain of the right hand. With this exception, he has not suffered in the joints or limbs since his first illness. The iris of the right eye is of a dull leaden color, irregularly tuberculated on its surface, and in contact with the cornea, except at its central portion, where the pupillary margin, being adherent to the capsule, seems depressed. The globe is hard to the feel, and vision is extinct. About one-half of the circumference of the left pupil is connected to the capsule, by white adhesion. Vision is perfect. From this gentleman's description, the various attacks of the eye seem to have been highly inflammatory. For some time after the last inflammation of the right eye he felt a flow of blood to the head, and uneasiness of the eye after every meal.

Case.—A gentleman, fifty-two years of age, of spare habit, has nearly lost the sight of both eyes by arthritic iritis. He has been subject to rheumatism all his life. His father was gouty, had chalk stones, and died of

gout in the stomach. A brother lost his sight from repeated attacks of iritis; and a sister is rheumatic. The eyes of this gentleman have been inflamed about a dozen times, each return having been preceded and accompanied by rheumatic ailments. He had repeated inflammation of both eyes, from September, 1827, to September, 1828, with rheumatism all over the body. The iris of the left eye is bulged, tuberculated, and thoroughly discolored; the vessels are varicose, and sight is destroyed. In the right the iris is convex, and nearly in contact with the cornea, the pupil is fixed by a white adhesion, and enough sight remains to enable him to find his way about. This gentleman had an attack in the right eye recently; the local and general symptoms were inflammatory; three cuppings on the temple, to eighteen, sixteen, and fourteen ounces were necessary.

Scrofulous iritis.—The inflammation which begins externally, under the usual character of strumous ophthalmia, or corneitis, sometimes extends to the iris, and even to the more deeply-seated parts of the globe. It is preceded and accompanied by such change in the state of the cornea, as prevents us from observing what is going on in the anterior chamber, so that we sometimes do not know that iritis has existed, until we see its effects on the subsidence of the inflammation. I believe that scrofulous iritis will seldom be seen as a primary and separate affection. The presence of this complication, should its existence be recognized, does not require any departure from the principles of treatment applicable to strumous ophthalmia generally.

I have to observe, in conclusion, that the several kinds of iritis are not different diseases, but modifications of one and the same affection. Although the form of the malady is more or less different in the various species of iritis, the nature and effects of the disturbance are nearly the same, and there is no difference in the principles of treatment. In distinguishing to which division a particular case ought to be referred, we are often guided by the history and concomitant circumstances rather than by the local appearances, and thus the difference turns out at last to be in the exciting cause, and not in the nature of the malady. The differences of form are, however, often striking enough; and the example of the skin would be sufficient to teach us that inflammation may present itself under very various aspects in the same texture.

The distinctions I have pointed out will be found, I think, sufficient for all practical purposes. They have, however, been carried further, without, as far as I can understand, any useful result in pathology or treatment.*

[Mr. J. P. France, in a paper published in *Guy's Hospital Reports*, (Oct., 1844,) presents some views relative to the pathology of iritis which are of sufficient interest to deserve a notice here.

The main object of Mr. France's paper is to show that arthritic and syphilitic iritis should be considered as distinct forms of disease, and to point out the peculiar habitudes of each. Simple iritis, Mr. F. conceives to be very rare as a primary affection, independently of wound, injury, or disturbance.

* The *Commentatio de Iritide* of Professor Von Ammon is an elaborate description of iritis in its various forms. He first describes traumatic iritis. Subsequently he distinguishes iritis generally into three modifications; 1st, *serosa anterior* or *superficialis;* 2dly, *parenchymatosa;* and 3dly, *serosa posterior* or *uveitis.* Under the first head he speaks of *scrofulous, rheumatic,* and *cachectic* subdivisions. The simple forms of parenchymatous iritis are the *syphilitic* and *arthritic;* but he mentions, as complicated cases, *iritis syphilitico-mercurialis, syphilitico-arthritica, syphilitico-scorbutica, scrofuloso-syphilitica, psorica,* and *plicosa.*

The early and middle periods of manhood are the ages most liable to syphilitic iritis, whilst arthritic iritis is most frequently met with in elderly people. In both, the feeble and cachectic are those who chiefly suffer, at least among the applicants in hospital practice.

"In well-marked cases of syphilitic iritis," Mr. France states, "the first morbid changes in the membrane itself are commonly observed at or close to the margin of the pupil, where the iris is found not only to have its mobility impaired and its brilliancy tarnished, but the sharpness of that margin lost; and as the disease advances, the natural color of the iris, at one or more inflamed points, which appear thickened, is seen to give place to the development of a dusky reddish-brown hue (frequently described by the terms foxy or cinnamon-color), which has been correctly deemed an almost absolute gnomon of syphilis.* This color, as the disease progresses and the tumefaction becomes greater, is usually rendered still more striking; but it sometimes is obscured, to a certain extent, by fibrine effused into the cavity of the anterior chamber, which presents the ordinary light-yellow color of similar effusions elsewhere, or, in very acute cases, may be discolored by admixture of red particles of blood, and remotely simulate the reddish swelling of the iris just spoken of. So great participation of the aqueous membrane is, however, far from common in syphilitic iritis, in which, generally, exudation takes place from the free surface of that membrane only in sufficient quantity to attach parts of the edge of the pupil to the capsule of the lens, and perhaps cover, more or less, its contracted aperture. Very often, indeed, attachment of the edge of the pupil to the anterior capsule, at the situation of the most inflamed portions of the iris, is the only evidence of any morbid effusion whatever upon the free surface of the membrane of the aqueous humor; and the changes just described in the aspect of the iris itself are most frequently left open to view."

There is another appearance which is far from constant, but whenever it is detected, Mr. France thinks the syphilitic origin of the disease may be confidently asserted; this is "the occurrence of very minute dark-brown specks in the lower segment of the substance of the cornea: they appear circular in form, with well-defined margins, and their production seems independent of any general haziness or inflammation of the corneal structure; these characters mark them as quite distinct from those mottlings described by Mr. Wardrop as a consequence of aquo-capsulitis."

The ordinary aspect of the iris under arthritic inflammation is, according to Mr. France, as follows:—

"Here, dullness of the anterior chamber is much more extensive and considerable; and if the disease be not quickly checked, the entire circle of pupillary margin is soon fixed by lymph, to the capsule of the lens; and even the whole area of the pupil may be thickly overspread with this effusion, which presents very generally a white or yellowish-white color. The surface of the iris too will be found not *partially* discolored in rusty-looking spots, but uniform in its alteration to a greenish or yellowish hue; a circumstance of considerable import, as contrasting with syphilitic discoloration: and lastly, whatever tumefaction of the iris there may be, and it is usually very slight, will be observed to partake of the same character, not being confined to a spot here and there, but general.

* "It is a curious fact, that a similar tinge of reddish-brown (copper color) characterizes syphilitic cutaneous eruptions. More truth is conveyed than was ever intended in the remark—

Heu! Quam difficile est crimen non prodere vultu!"

The fact is, that in the immense majority of cases of arthritic iritis, the lining of the anterior chamber and serous covering of the iris are, in common with the sclerotic, the principal seat of the disease; and it is remarkable how closely herein it tallies with the recognized disposition of rheumatic inflammation in other regions to affect free membranous surfaces (as those of the synovial cavities and pericardium), and then give rise to abundant effusion, which is unknown as an accompaniment of rheumatism of fibrous and muscular tissue. Thus the large participation of the aqueous membrane in the inflammation called arthritic iritis, is manifested by copious effusion into its cavity, generally fibrinous, but sometimes serous; while the affection of the muscular structure is inferred only from its proximity, the contracted pupil, aching pain, and especially the exacerbation of that pain occasionally produced by the application of belladonna. Now, it is to the circumstance that syphilitic iritis, on the contrary, is, for the most part, essentially an inflammation of the parenchymatous structure, that the disease owes its peculiar character of producing tumefaction or thickening; and, in proportion as it departs from this type are the chief marks deemed diagnostic either ill-developed or absent. The tuberculation of the membrane, and its cinnamon discoloration, (which are merely the ordinary 'notæ inflammationis tumor et rubor' of Celsus, modified by texture and specific action,) are owing to this, and yet are commonly accounted for in just the opposite way; for the tubercles are generally regarded as attachments of lymph to the free surface of the iris, and their color is ascribed to admixture of some extravasated red particles, or (as by Mr. Lawrence, who yet seems, with Beer, to recognize distinctly the interstitial origin of the tubercles) to the combination of the color of lymph with that natural to the iris. Of these two suppositions, the former is certainly the more tenable; for a combination of the faint straw-color of lymph with gray, blue hazel, or brown, can never yield a tinge of red—one of the three primitive colors.

"When, however, a normal case of syphilitic iritis is examined closely in the earliest stage, it is clear to demonstration that the irregularities of the surface of the iris are due to its proper substance being, at certain parts, swollen and infiltrated, because the surface, though irregular in level, is continuous, and the confines of the swellings are lost insensibly in the surrounding comparatively healthy part: and if the case be attentively watched as the disease advances, it may, for a considerable time, remain equally evident that any morbid deposit there may be interstitial. The tumefaction at one or more of these points, however, sometimes greatly increases, generally less in superficial area than in elevation; and though at first it barely rises above the surrounding level, it may eventually proceed to such extent, owing to the loose and distensible texture of the iris, as to constitute a tubercle, projecting high above the general plane, and sometimes even overlapping its own base. In the latter event, as also when a film of fibrine is effused over the surface of the tubercle, from sympathetic inflammation of the aqueous membrane (an occasional but not common circumstance), the real origin of the tubercle may be for a time obscured; yet, as it subsides at length, and the free lymph is absorbed, the natural reticular appearance of the anterior surface of the iris again comes into view, and the roots of the tubercle (so to speak) are seen to lie beneath that surface."

Eighteen cases are related in illustration of the various points which the author desires to establish.

With regard to the treatment Mr. France observes: "A more or less

antiphlogistic course is naturally suggested as the cure for so decidedly an inflammatory disease as syphilitic iritis; experience, however, proves that the more powerful antiphlogistic means—venesection—is but very sparingly demanded; so seldom, indeed, that I do not remember an instance of its being resorted to at Guy's for this complaint. Perhaps in country districts this mode of depletion may be found necessary in full plethoric habits. The same mould of constitutional frame may demand it in metropolitan practice; but I much question whether, at the present time, our rural and civic laboring population really requires that difference in the rigor of remedial measures which was formerly inculcated. I have, at least, no hesitation in deprecating that free resort to venesection, 'whenever there is feverishness,' (whether the pulse be full and strong or no,) which has been recommended in this disease;—first, as needless for its cure; but, above all, as tending to produce or aggravate that irritable cachectic state, to which the syphilitic subject is especially prone.

"Local depletion by cupping is, however, a remedy of the greatest service; it gives often immediate relief to the patient, at once mitigates his pain, and dissipates, in some degree, his obscurity of vision. Coupled with a brisk purgative, to clear the intestinal canal, it forms a nearly constant preliminary to the commencement of a mercurial course sufficiently decided to affect the mouth, or make the disease recede; and the practitioner may, of course, be well content if this latter should be even the only evidence of mercurial action upon the system. For mercury must not be administered in a set dose: it should in many cases be introduced into the system in the mildest form; while, on the other hand, in a more favorable constitution it may be exhibited with comparative freedom.

"The cases are numerous, in which the patient may be advantageously supported under, and shielded, as it were, in a measure, from the injurious effects of the use of mercury, by the simultaneous employment of sarsaparilla, with or without the iodide of potassium—a combination no less valuable in this form of syphilitic disease, than in others where an irritable and vitiated constitution forbids the enforcement of so energetic a system of treatment as the local disease appears to demand. It is, in short, of infinite use when this malady arises in a cachectic individual; and it enables us then, if necessary, to diminish our dose of mercurial, and yet, retain good hope of effectually reducing the disease, and discharging the patient with improved health and preserved sight. The mercurial may be advantageously given in form of pill with the extract of hyoscyamus, which possesses this claim of preference to opium—that, in place of favoring a disposition to contracted pupil, which is one of the ordinary concomitants of the disease, it aids the belladonna externally applied in counteracting that morbid tendency. Chalk may, at the same time, be administered, to prevent any purging effect of mercury, which hyoscyamus is not equally calculated with opium to restrain.

"Conium, it is asserted, does not possess the power of causing dilatation of pupil in common with belladonna, hyoscyamus, stramonium, &c.; yet, in one case of syphilitic iritis, in which the nurse had, by mistake, omitted the application of belladonna, I observed extreme dilatation follow its use in full doses combined with mercury; and I could not satisfactorily account for this phenomenon, except by ascribing it to the action of the hemlock.

"When the acuteness of the inflammation has been subdued, and the disease is quickly yielding, the dose of mercury at first requisite should be diminished. Small doses are, however, often needful for a long time after the disappearance of every external mark of inflammation, in order

to remedy some slight visual defect—as a musca—which may continue to give annoyance to the patient. Its exhibition in this mild form is perfectly compatible with the administration of tonics and permission of a moderate diet, when deemed desirable.

"Blisters become available as soon as ever further local depletion by cupping is judged unnecessary; and inunction of blue and opium ointment to the temple and forehead, when pain about those regions is severe, very often produces the greatest relief.

"The oil of turpentine is certainly capable of exercising a controlling power over syphilitic iritis, more especially, according to Mr. Carmichael, who first recommended it, when the aqueous membrane is chiefly, or, at least, largely involved;—a set of cases, however, it must be recollected, which, in that very particular, depart from the normal type of the syphilitic disease." Mr. F. relates a case which "at once exhibits the beneficial action of the medicine upon the local malady, and the difficulty of preventing its unpleasant, and, if continued, injurious effects upon the kidney, which would probably entail more serious mischief upon the constitution, especially if previously unhealthy, than the administration of mercury in full doses for three or four days, and its repetition, in alterative doses, combined with tonics subsequently. In one other case, where turpentine was employed under my observation for this disease, it was likewise necessary to discontinue it, in consequence of the disturbance it excited in the system; Mr. Carmichael, however, succeeded in warding off these morbid effects, and deriving the expected advantages from it.

"Differing in habit and character as syphilitic iritis does from arthritic, it is not surprising that they stand apart also as respects treatment. Less vigorous measures altogether are called for in the latter disease. Cupping is, indeed, generally necessary, but only to small extent. Mercury need not be given to affect the system; but as an alterative, or accompanied with saline purgatives and colchicum, to cause free action upon the bowels, it is, in the active stage, and to persons of moderate power, advantageous; while an early resort should be had to tonics with alkalies, the alterative dose of mercury being continued. Arthritic iritis is remarkable in its sensibility to the actions of belladonna and conium,—a peculiarity, I believe, first observed by Mr. Morgan. The application of the first is occasionally followed by so much suffering in the globe of the eye, mitigated on omitting, and renewed on reverting to the application, as to necessitate its discontinuance;—a circumstance before alluded to, and apparently depending upon the tension produced in the muscular fibres of the iris, which, in all probability, partake in some measure of the general rheumatic affection; for such effect of the use of belladonna appears to be confined to arthritic cases. Arthritic inflammation of the conjunctiva and cornea, as well as of the sclerotic aqueous membrane and iris, is sometimes remarkably under the influence of the extract of conium, given in doses of five or ten grains thrice daily, so that very serious inflammation of this kind will sometimes subside rapidly under its use; and it has, therefore, obtained with us a place among the remedies recognized as most eligible in this disease."]

CHAPTER XVII.

MALFORMATIONS, AND VARIOUS AFFECTIONS OF THE IRIS.

Congenital deficiency of the iris (*Irideremia*).—Sometimes the iris is entirely deficient, vision being at the same time imperfect, frequently so much so, as hardly to answer any useful purpose. I have lately seen two infants a few months old, in whom this congenital peculiarity existed. They were supposed to be blind, and brought to me on that account. I could observe no other defect except the absence of iris. They did not bear exposure to light well. In one I thought that I could observe a reflection of light at one part, as if there had been a narrow rudiment of iris. The parents of these infants had no defect in the eyes.

In Ammon's *Zeitschrift*, vol. i. No. 4, mention is made of three sisters born without iris. The father has only a rudiment of iris at the lower margin of the cornea. The full light of day is offensive to him, and his sight has become impaired lately, so that he makes out even large letters with difficulty. The eldest daughter, now twenty-eight, was born without irides, always experienced intolerance of light, and saw imperfectly. She has lost one eye by inflammation, which was followed by total staphyloma. The second daughter, aged twenty-one, with complete deficiency of the iris, cannot bear the light, and is troubled by repeated ophthalmiæ, with increasing imperfection of sight. The youngest daughter, thirteen years old, has clear black pupils; but, like her sisters, has not been able to read and write.

Another instance, in which the hereditary transmission of the congenital defect is seen still more remarkably, will be found in the same periodical. Christian Kehl, born of healthy parents, was the first of the family, and the only one of eight brothers, in whom this defect existed. He was annoyed by light, and pursued his occupations in the dark. He had eight children, of whom three boys inherited this defective formation. The eldest of these has four sons now living; the iris was absent in all excepting the second, in whom a segment of the membrane exists. The second son had a son, whose eyes, as well as those of his children, are normally constructed. The third son died a few months after his birth. The eldest of the four children of Christian Kehl's eldest son had a son whose eyes were well formed. The second who had the segment of iris, had, 1st, a well-formed boy; 2dly, a girl with deficiency of the iris, who sees clearly in twilight. The third had two children; a daughter with deficiency of the iris and constant motion of the eyeballs, and a malformed child. The fourth had a well-formed child. The several individuals above mentioned as affected with this malformation, see near objects clearly, but distant ones very indistinctly, excepting one, who has good distant sight. The eyelids are habitually half closed, so that light enters the eyes by a narrow slit. The vessels of the ciliary body and choroid coat are not seen. No particular movement of the eyes is observed. The interior of the globe is black-brown or black-blue, and shining. No reflection of light is observed from the interior. Strong light is painful, and makes them hold the eyes down.*

Barattat saw complete congenital deficiency of the iris in both eyes of

* Gutbier, Diss. inaug. de Irideremia, seu defectu Iridis Congenito, 1834. In Von Ammon's Zeitschrift, vol. v. p. 78.

† Osservazioni pratiche, vol. ii. p. 349.

a youth aged twenty-two. There had been great weakness of sight from birth. He distinguished distant objects very imperfectly; near vision was rather better. When this person was seen again at the end of a year, he had cataracts. In one eye the lens was of natural size and steady in its position, with a black circle round it of a line in breadth, through which the patient had good sight. The other cataract moved backwards and forwards, reclining backwards when the head was erect, and coming against the cornea when he stooped.*

[Mr. FRANCE† has published a case of absence of the iris in both eyes, in the person of a young woman, an out-patient at the eye infirmary at Guy's. She is unable to bear exposure to a strong light; sunshine in particular is disagreeable to her, and causes profuse lachrymation. Objects are only distinctly seen when within the distance of a foot or two. The eyelids are habitually more than half closed; the globe of each eye affected with an almost incessant oscillatory motion in a horizontal direction, and the power of directing the eye towards an object, particularly upwards or downwards, is much impaired. The corneæ are partially clouded. "The sclerotic coats are moderately healthy—perhaps rather more bluish than natural; their degree of tension is that of health. On inspecting the right eye very carefully, and looking above or beside the corneal nebula, there is observed a central opacity of the anterior capsule of the crystaline, about the size of a large pin's head; and a similar spot is also to be seen on the posterior capsule, the lens remaining perfectly transparent. Thus a very satisfactory illustration is afforded of the size of the walls of the cavity within which the lens is contained. In the left eye, the centre of the anterior capsule, or more superficial parts of the lens, is opaque; while the posterior, appearing as if corrugated, is opaque also in the centre, to about one-third of its extent, and shoots forwards, as it were, flakes of opacity into the lens on the nasal side.

"With these exceptions, the entire space viewed through either cornea is of uniform brownish-black hue. The closest examination does not disclose any vestige of iris."

Two cases of complete absence of the iris are recorded by Dr. F. PRAEL. (See *Amer. Jour. Med. Sci.*, Aug. 1840, p. 476.)

The editor has seen one case of the same kind. The subject of it was an infant a few months old; it was accompanied with partial opacity of the lens in one eye and complete opacity of that part in the other.]

Fig. 60.

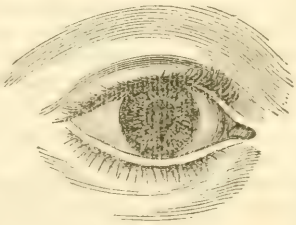

Coloboma‡ *iridis.*—Another original peculiarity in the iris consists in a fissure of its lower portion, and a consequent prolongation of the pupil to the margin of the cornea. [Fig. 60.] This natural defect, which is not very uncommon, was first expressly noticed by Professor WALTHER,§ although it had been previously

* VON AMMON has represented an eye, in which the iris was entirely deficient, and a capsulo-lenticular cataract had formed. Klinische Darstellungen, pt. I, tab. 10, fig. 7.

† Guy's Hospital Reports, April, 1842.

‡ The Greek word, κολόβωμα, meaning defect or mutilation, was applied to fissure of the eyelid.

§ Ueber einen bisher nicht beschriebenen, angebornen Bildungsfehler der Regenbogenhaut, in GRAEFE u. WALTHER's Journal, vol. ii. p. 601. The various recorded cases are referred to by SCHON in his Pathologische Anatomie des menschlichen Auges, p. 70.

observed; he gave it the name of *coloboma iridis.* The sides of the fissure are sometimes perpendicular, sometimes a little inclined towards each other below, so as to make the lower portion of the pupil triangular. I am acquainted with a youth in whom this natural defect exists, his eyes being well formed in all other respects, and vision being perfect. No deviation from the normal structure exists in the eyes of his parents, brothers, or sisters. Von Ammon* examined after death the eyes of an individual in whom this peculiarity existed. There was a rising of the sclerotica along the middle line on the under surface, and towards the back part of the globe. Corresponding to this external rising, there was a fissure of the choroid and retina, from which a rising fold was continued in front along the corpus ciliare, where it took the place of ciliary processes. An impression in the lower part of the vitreous humor corresponded to this fold. The lens had not quite its regular figure below. This defect is said to have occurred on the upper, inner, and outer, as well as at the lower part of the iris. I have seen it in the latter situation only.

Change of color in the iris.—Sometimes the iris undergoes change of color without any other indications of disease. A lady, thirty-five years of age, of dark complexion, black hair, and dark irides, had passed eleven years in hot climates. When I saw her, the right iris had been slowly changing in color for two years, and had acquired a dull gray tint. There had been no inflammation, pain, nor other assignable cause. The iris moved properly, the pupil was natural, and she could read the smallest print, but complained of dimness. Another lady, of fifty-eight, has a bright dark brown iris in the right eye, while the left is light gray and rather dull. There is also a firm lenticular cataract in the latter eye. Both eyes were originally very dark. The color of the left iris changed twenty years ago without inflammation, pain, or diminution of sight. The cataract has existed eight years.

I have several times seen change of color in the iris in conjunction with capsulo-lenticular cataract. In a person of twenty-five, who has opacity of the capsule, with incipient opacity of the lens, the sound eye is orange, inclining to yellow, while the other is a dull bluish gray. In another, the right iris is very dark; the left, with capsulo-lenticular cataract, is light gray. There has been no inflammation.

Spotted iris.—Dark brown spots of roundish figure and various number, seldom exceeding the size of a pin's head, are frequently seen on the iris. They are often met with in eyes that are not quite sound; but they occur also where there has been no disease, nor any diminution of vision. They do not belong to the original structure of the iris, for we do not see them in young subjects; and in most individuals they do not occur at all. They are met with about or after the middle period of life.

Prolapsus or *procidentia iridis.*—The iris floats loosely in the aqueous humor. When an opening is made in the cornea by wound, sloughing, or ulceration, that fluid escapes, and the iris passes out at the aperture, forming a kind of hernia, more especially if pressure be made on the globe by its muscles, or if the parts in front are pushed forwards by inflammatory congestion in the posterior tunics. The tumor formed by the protrusion is called sometimes *staphyloma iridis.* If the cornea be completely penetrated, as in wounds and some ulcers, the protruded iris is naked, and forms a dirty looking brownish or grayish irregular and ragged prominence. If the membrane of the aqueous humor remains entire, it gives a smooth covering to the prolapsed iris. The protrusion of the whole iris, after general

* Zeitschrift, vol. i. No. 5, with figures. In the work and plate of Von Ammon just quoted, there are three figures of eyes affected with coloboma iridis and cataract. Figs. 5, 6 and 13.

slough of the cornea is called *staphyloma racemosum;* a small prolapsus, forming a brownish tumor, as large as a fly's head, is called *myocephalon*, and those of larger size have received the names of *clavus*, or *helos*, and *melon*. The progress and result of the protrusion are described in CHAPTER IX. on *gonorrhœal ophthalmia.*

The *treatment* consists in removing the inflammation; no specific measures are required for the prolapsus. We cannot remedy that, whether it has occurred in the case of wound or ulcer. It would not come out unless there were pressure from behind; we cannot restore it in opposition to this force, and the attempt would only aggravate the mischief. The employment of belladonna, at an early period, might be of use in some cases.

If the tumor should not subside, when the inflammation has been removed, if its friction against the lids should cause renewed irritation, it has been recommended to touch it with lunar caustic scraped to a point for the purpose, both of reducing the tumor, and of furthering the adhesion of the protruded part to the corneal aperture. This application must be used cautiously, since it may not only fail to do good, but be absolutely injurious. I do not use the caustic, having found that the prolapsus recedes when inflammation has been quieted.* If the protrusion were large, it might be expedient to puncture the part, so as to let out the aqueous humor, and thus lessen the tension of the globe. A small quantity of a strong solution of nitrate of silver might then be carefully applied with a camel-hair brush.

[The pressure of the aqueous humor tends to protrude more and more of the iris, until sufficiently firm adhesion is established between this tissue and the edges of the opening in the cornea, to counteract that force. The stretching of the iris—its strangulation in the opening of the cornea—and the friction of the lids against the prolapsed portion, are so many sources of irritation which it is very desirable to remove. By snipping off the part of the iris which protrudes, the aqueous humor escapes and relief is afforded; but this is only temporary, for the iris soon unites, the aqueous humor is regenerated and the evil is renewed. We have been accustomed, therefore, in these cases, to apply a point of nitrate of silver to the protruded portion of the iris, by which it is made to shrink, adhesion between it and the edges of the wound in the cornea promoted; and we are persuaded that by this course the sufferings of the patient and the period of cure are abridged, and that less distortion of the pupil occurs than when antiphlogistics alone are trusted to.

The following case illustrates this practice:

Rosannah M'Nally, ætat. 8, was admitted into Wills' Hospital November 8th, 1838, with prolapsus iridis of the right eye. About two weeks previously, whilst attempting to untie a knot in her shoe-string by the aid of a fork, the instrument slipped, and a prong penetrated the cornea of

* My opinion and experience on this subject coincide with those of DEMOURS, who observes, that "la petite portion de l'iris, pincée entre les lèvres de l'ouverture de la cornée, s'atrophie et se perd peu-à-peu." Respecting treatment, he says, "après de nombreux essais, je me suis aperçu que tout ce qui provoquait l'augmentation de la phlegmasie était nuisible, que l'on devait, sans s'arreter à cet épiphénomène, s'attacher à combattre les causes qui lui ont donné naissance, en un mot, qu'il ne fallait rien faire à la hernie de l'iris, quelle que soit la cause qui lui ait donné lieu, et que les efforts seuls de la nature, lorsqu'ils n'étaint point contrariés suffisaient pour la faire disparaître en quelques semaines ou en quelques mois, selon sa situation, son volume, et la gravité des causes qui lui ont donné naissance."

"Pour moi, une guérison obtenue par le nitrate d'argent fondu, est une guérison obtenue malgré l'emploi de ce caustique. La nature est si habile! Elle resiste avec tant d'énergie à l'action des mauvais moyens."—*Traité des Maladies des Yeux*, tom. i., p. 302—304.

her right eye, towards the lower and outer portion, at about a line and a half, or two lines from its junction with the sclerotica. Some inflammation followed, which resisted the homely applications made and continued when admitted in the hospital. The iris at this time protruded, forming a small dark tumor, and the iris was drawn towards the wound, rendering the pupil oval.

The inflammation was first subdued by venesection, saline purgatives and the usual antiphlogistic treatment; and the prolapsed iris was then touched with nit. argent. Under this treatment, the prolapsed portion of the iris shrunk, and eventually the wound healed, and the patient was discharged cured, on the 19th of December. There remained, however, permanent adhesion of the iris to the cornea, at the seat of the wound, and the pupil was irregular, (see fig. 61.) Her sight was, however, excellent, and the motions of the iris, though limited, were not entirely destroyed.]

Fig. 61.

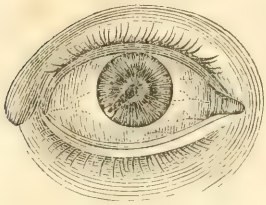

Prolapsus iridis may cause unfavorable changes in the pupil, so as either to impair or destroy vision. The figure of the opening may be rendered oval or elongated; the pupillary margin may be drawn out of place so as to contract or close the opening. If, in addition to such displacement and contraction, there should be opacity of the neighboring portion of the cornea, vision will be rendered very imperfect, or entirely destroyed. Sight may not be injured by a small protrusion near the margin of the cornea, above or on either side of the pupil; while if it take place towards the centre, it may involve the entire pupil, and thus cause blindness. The pupil may be closed in consequence of a prolapsus at the edge of the cornea. There may be two or more protrusions, not only lessening the size of the pupil, but drawing it into the form of a narrow slit.

The changes in the figure of the pupil, and in the state of its margin, and the adhesions, which the iris contracts to the neighboring parts, are considered in Chapter XVII. on *Iritis*. The adhesion of the uvea to the crystaline capsule (*synechia posterior*) caused by iritis, and that of the iris to the cornea, which is at the same time generally opaque, in common and purulent ophthalmia, or after prolapsus, (*synechia anterior*,) cannot be remedied by operation. In these cases, however, especially if complicated with contraction of the pupil and the formation of adventitious membrane in its aperture, we are often able to render essential service by the use of belladonna. A small dilatation will sometimes extend the edge of the pupil beyond the corneal opacity. Even in cases where there is an adventitious membrane in the pupil, and its margin appears at first sight adherent throughout, it has been often found, on applying the belladonna, that a small portion of the opening has remained free, and capable of dilatation, with great improvement of sight. We ought not, therefore, to consider these cases irremediable; and I have often been surprised to find how well patients could see through a minute pupillary aperture. I have seen patients enjoying tolerable vision, when the opening in the iris has not been larger than a small pin's head. In these cases, if we find that the use of belladonna will give the patient vision, or improve it, we must employ it once in twenty-four hours, to keep up its effects permanently. This is the only remedy in some instances; others may be relieved by making an artificial pupil.

[*Staphyloma iridis*,—*Iridauxesis*,—*Iridoncosis*.—Under these titles,

there is described a peculiar morbid alteration of structure of the iris, the result of chronic or neglected inflammation of the parenchyma of the iris. Elevated spots of greater or less size, with dark sharply defined margins, are visible on the surface of this part. These spots are at first whitish or whitish-yellow, but in general they afterwards become dark, or even black, and increase in elevation. The proper substance of the iris which remains evident, is changed in color, and presents a remarkably fibrous appearance. See fig. 62.

Fig. 62.

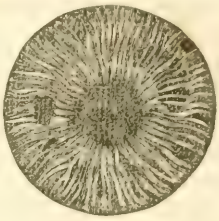

By JAEGER who first called attention to this change in the iris, it was supposed to consist in an attenuation of the substance of the iris, at the dark spots, with protrusion there of the uvea forwards. But the observations of KLEMMER and others seem to show that it consists in a thickening of the iris from exudation of lymph into its substance. In this lymph new vessels are developed, and deposition of pigment subsequently takes place, producing the dark spots. The pupillary margin of the iris is generally retracted, and adherent to the capsule of the lens, and there is lymph in the pupil. Vision is greatly impaired or wholly extinguished, even although the pupil be not much obstructed.*]

FUNGOUS EXCRESCENCES FROM THE IRIS AND CILIARY BODY.

The following two cases occurred in the practice of Mr. SAUNDERS.

CASE I.—*Fungous excrescence from the iris and corpus ciliare, ulcerating and discharging: spontaneous cure, and atrophy of the globe.*—In a girl ten years old, who was brought to the London Ophthalmic Infirmary, "the sclerotica was unusually vascular, but not inflamed. The vessels were large and serpentine. The iris, retired from its situation, seemed to be twice as far from the cornea as is natural. The pupil was dilated, and the iris contained many distinct red vessels. The cornea, the aqueous, crystaline and vitreous humors were at this time transparent. In the course of a few weeks the crystaline became opaque; the iris, covered with lymph, and as red as if injected, advanced towards and touched the cornea; shortly, a blue excrescence was thrown out at the superior part of the eye, at that part of the sclerotica which unites with the ciliary ligament. It increased rapidly, and became as large as the anterior portion of the globe. This tumor ulcerated; for a long time a thin watery fluid was discharged, then pus, and lymph, which trailed out through the aperture. After some months this aperture closed, the eyeball, much reduced in bulk, became tranquil, and even retained some vestiges of the cornea, the blue excrescence being totally extinct. During the process there was nothing like acute inflammation, and the pain was very trivial.†"

CASE II.—*Fungous growth proceeding from the iris: spontaneous cure.*—"In 1809, a boy about three years old was brought to the infirmary. On the inferior part of the iris a small patch of lymph was deposited, the pupil was not influenced by it, but varied as usual. There was no ophthalmia, nor any irritability from exposure of the organ to light. In a fort-

* Wharton Jones, Manual of the Diseases of the Eye, p. 200.

† A Treatise on some practical points relating to Diseases of the Eye, &c., 2d edition, p. 143, 144.

night the mass of lymph was so much increased, that it occupied the inferior half of the anterior chamber. Now a process of organization commenced in the lymph, and an action analogous to inflammation was set up in the cornea; it became turbid and vascular, the iris and cornea wasted, a blue mass arose in the situation of the ciliary ligament, which, together with the whole of the cornea, ulcerated or suppurated, and an ill-conditioned and very luxuriant fungus shot forth. By degrees this fungus diminished, and finally the eyeball healed."*

Mr. Mackenzie† has quoted from a German work‡ a case of fungous excrescence from the iris, in a weakly child, affected at the same time with caries of the foot. A white elevation began at the pupillary, and extended gradually to the ciliary edge of the iris, approaching at the same time to the cornea. After a considerable time the tumor was so much increased that it seemed likely to implicate the whole organ, and removal of the front of the eyeball was proposed. The patient was not seen again for a year, when the globe had become atrophic, and the cornea constituted a white cicatrix.

From this and the two preceding cases we may derive a salutary caution against proceeding hastily to operation in such affections. It may be confidently expected that the active disorder exemplified in the first two instances will come to a natural conclusion under mild antiphlogistic treatment, aided perhaps by the moderate use of mercury. In the more chronic disease, a similar natural termination may be looked for, under the strengthening and restorative plan of diet and medicine, which is calculated to raise and uphold constitutional power.

Mr. Middlemore mentions fungoid growths arising from prolapsed portions of iris, and curable by nitrate of silver.§

He saw two small fungoid productions arising from the iris, which was in other respects quite healthy. They were removed by mercury administered internally, so as to produce its specific action.‖

Mr. Wardrop met with an example of bleeding excrescence from the iris. It was small, though of long standing, and extremely vascular; for it often bled profusely, without any external cause, and would quickly fill the anterior chamber with blood.¶ Mr. Middlemore heard of a similar case, in which the swelling went away under the use of mercury.**

Tumors growing from the iris.—Some years ago, in a boy about eight or nine years of age, I saw an apparently simple vascular growth of a light brown color, equal in size to a large pea, proceeding from the iris, without much redness or pain, and without opacity of the pupil. It had caused ulceration in the cornea, and thus appeared externally. As the young patient was removed to his residence in the country, I did not witness the progress or termination of the case, but I was informed that the tumor subsided after a time, and that the eye shrunk into its socket. Mr. Mackenzie mentions the formation on the iris of tubercles, which he regards as scrofulous. The eye generally becomes atrophic in such cases.††

A boy had the cornea injured by a particle of hot iron, which lodged in the iris, causing severe inflammation, which was removed with difficulty; he recovered good vision. Some months afterward a cyst was formed on the injured part of the iris, without pain, and acquired the size of a pea.

* Ibid., p. 144, 145.
† Practical Treatise, ed. 3, p. 602.
‡ Jahrliche Beyträge zur Vervollkommnung der Augenheilkunst, vol. i. p. 37.
§ Treatise, vol. i. p. 721.
‖ Treatise, vol. i. p. 722.
¶ Essays, vol. ii. p. 49.
** Treatise, vol. i. p. 722.
†† Practical Treatise, p. 602.

It had a rounded figure, and shining white surface. It was removed in the London Ophthalmic Infirmary.*

A similar cyst formed on the front of the iris, in a girl, some months after the eye had been injured by a beard of corn. As it increased, inflammation of the eye was excited, and thus excision became necessary, which was performed by Mr. TYRRELL.†

Mr. MACKENZIE‡ saw a semi-transparent cyst formed on the iris in consequence of a wound. It did not increase, and gave no pain; it was therefore left alone.

Mr. M. saw another case, in which a cyst, apparently originating in the posterior chamber, came gradually through the iris, increasing in size, and being painful. It was punctured through the cornea, when a little fluid escaped, and the cyst collapsed. The puncture was twice repeated, and the cyst did not fill again. Vision was not injured.§

[Mr. DALRYMPLE has recorded a case in which there was a cyst attached to the anterior surface of the iris. It was roundish, cystiform in appearance, semi-transparent or gelatinous-looking, and adherent to the ciliary border of the iris at the inner side. It was punctured with a broad needle, and a semi-opaline fluid, of a saponaceous feel, evacuated. The cyst then sensibly shrunk. The puncture was subsequently repeated, the cyst entirely evacuated, and it did not subsequently fill.‖]

Myosis is a name given to unnatural contraction of the pupil. This is a frequent consequence of iritis, being usually accompanied with adhesions, and irregularity in the figure of the opening, and occasionally with adventitious membrane obstructing it more or less completely. In some instances the imperfection of vision, caused by this state of the pupil, may be remedied or alleviated by the use of belladonna.

Individuals who employ their eyes habitually on minute objects, often have small pupils, yet see perfectly well; and this state of the pupil sometimes exists where we see no cause for it. Under such circumstances, the motions of the iris are limited. Contracted pupil is sometimes seen in conjunction with impaired vision. The use of belladonna has but little effect on the opening, and does not improve vision. The prospect is unfavorable in such cases.

Mydriasis denotes the opposite or preternaturally dilated condition of the pupil. Most frequently this is a symptom of amaurosis, and consequent on disease of the retina. It has sometimes followed injury of the head, being then probably caused by affection of some part within the cranium. As a temporary state, it is produced by the external application or internal use of certain narcotics. (See Chapter XV., § 1.) It occurs, with other symptoms, as an effect of disease affecting the nerve of the third pair. Such cases are alluded to at p. 81. It is sometimes, but rarely, seen without any other evidence of disease in the organ.

Mydriasis, when it exists alone, or in conjunction with paralysis of the muscles supplied by the motory nerve, implies the existence of disease in the ciliary system of nerves. It is usually connected with disorder of the digestive organs.

As the dilatation of the pupil is permanent, strong lights have a dazzling effect on the eye. Distant objects are seen better than those which are near; but vision altogether is indistinct. Sight is improved, so that patients can even read, by looking through a small hole in a card; and this circum-

* Mr. TYRRELL's Work; vol. i. p. 368, pl. 3, fig. 6.
† Ibid., p. 369.
‡ Practical Treatise, ed. 3d, p. 602.
§ Ibid., p. 604.
‖ American Journal Med. Sci., Jan. 1845, p. 227.

stance distinguishes simple mydriasis from the dilated pupil of amaurosis. Convex glasses will improve the sight of near objects. Irritating applications to the surface of the eye are said to cause contraction of the pupil with improvement of sight.

Curative proceedings must depend on what we can discover respecting the nature and cause of the affection. These points are obscure where mydriasis is the sole symptom. In such a case we shall often find the source of mischief in the digestive organs. The employment of electricity has been suggested. A portion of blackened card, with a small central opening, corresponding to the natural size of the pupil might be fixed into a frame, and worn as a spectacle. The prognosis is favorable in these cases.*

[We have seen some cases in which the application to the eye of a few drops of a collyrium of acetate of strychnia, instantly contracted the pupil, so that the patients, who previously could not distinguish letters an inch long, were able to read promptly from a book printed in type of the size of the body of this work.

M. Serres, of Uzès, employs a fine point of nitrate of silver, which he applies for a second to the cornea near its junction with the sclerotica, and he reports some cases cured by this method.†

Dr. Kochanowski, of Warsaw, relates a case cured by ergot, given in the dose of three grains three times a day, gradually increased to twenty grains. At the end of a few days the pupil had recovered its normal dimensions and the iris its natural contractility.‡]

Tremulous iris.—The iris sometimes loses its natural tension, becomes flaccid, and oscillates backwards and forwards, when the globe is moved, like a rag in a bottle of water. This movement is sometimes considerable and obvious; in other instances slighter, so that close observation is necessary to detect it. There is no apparent change of structure. The pupil does not contract and dilate, or only slightly, and in sympathy with that of the other eye. It is often combined with cataract, which may exhibit a similar oscillation or vibration. Vision is generally lost or very imperfect. In a few instances I have seen the iris tremulous, and that to a great degree, after the operation for cataract, with good vision.

The more frequent cause of the tremulous motion is a fluid state of the vitreous humor, under which the natural support of the iris by the parts behind is lost, so that it waves backwards and forwards when the globe is moved, in obedience to the impulse of the contained fluid. As this condition of the humor indicates disease of the internal parts including the retina, the tremulous state of the iris is regarded as a most unfavorable symptom. When it occurs after cataract operations, it probably depends on increase of the aqueous humor.

It may be seen after serious injuries, and in other cases where we do not ascertain that the vitreous humor is in a fluid state. The cause is obscure under such circumstances. The affection itself is in all cases irremediable.

* Such a case is related in the London Medical Gazette; vol. xxii., p. 68.

[† Archives Générales, June, 1828, p. 307.]

[‡ Ibid., Nov. 1838, p. 351.]

CHAPTER XVIII.

FORMATION OF AN ARTIFICIAL PUPIL.

SECTION I.—GENERAL AND PRELIMINARY CONSIDERATIONS.

When vision has been destroyed or impaired by contraction, closure, or displacement of the pupil, or by such changes combined with obstruction of the opening by an adventitious membrane, or an opaque capsule, or with synechia anterior, or with opacity of the cornea, relief may be given by enlarging the natural pupil, by making a new aperture for the passage of light through the iris, or by a combination of both these proceedings. The various methods employed for these purposes are called THE OPERATIONS FOR ARTIFICIAL PUPIL, (*conformatio pupillæ artificialis; coremorphosis*, from κορη pupil, and μορφωσις, formation.)

Although the first attempts of this kind were made in the earlier part of the last century, the operation was not much practised till towards its very close; since which period so much attention has been paid to it, so many persons have investigated and attempted to improve it, that the methods of proceeding, and the instrumental apparatus, are perhaps more diversified than in any other surgical operation. The latter circumstances are partly accounted for by the differences in the states of the eye requiring operative assistance, partly by that desire of producing something new, which often leads us to neglect what is simple and sufficient, for more complicated, but less advantageous proceedings.

The changes in the state of the eye, requiring the formation of an artificial aperture, through which light may gain admission into the interior of the organ, are numerous and various, and cannot all be comprehended under the common expression, *closure of the pupil;* although such closure or rather obstruction of the aperture, direct or indirect, must exist whenever the operation is required. Some of these changes are seated in the cornea, others in the cornea and iris; several in the iris alone; some in the capsule and lens as well as in the iris; while others involve at one and the same time, the cornea, iris, capsule, and lens.

Although we speak of the operation for artificial pupil in the singular number, a mere glance at the subject will suffice to show that no one operation can be suited to the various morbid conditions of these several organs, which interfere, more or less seriously, with the passage of light into the posterior part of the globe. It is not our object to compare the various proceedings with the view of finding which is generally preferable; the attempt at devising any one method that would be applicable in all cases, would be manifestly absurd. We must carefully examine the several states of the organ, in order to determine which mode of proceeding may be preferable in each instance.

STATES OF THE EYE REQUIRING THE OPERATION.

The following are the conditions of the organ to which the operation for artificial pupil is applicable:

1. Simple closure of the pupil, consequent on acute iritis, without opacity

of the lens or capsule. This is a rare occurrence; and it must be difficult to ascertain that the lens and capsule have undergone no change.

2. Closure of the pupil by an adventitious membrane, (*occlusio pupillæ lymphatica.*) Such a state may be the result of the different operations for cataract; that is, of extraction, depression, reclination, or the operation by absorption; or it may remain after iritis, when it occurs from internal causes, as in the idiopathic, arthritic, or syphilitic kinds.

3. Closure of the pupil, with adhesion of its margin to an opaque capsule, the lens being at the same time generally, if not always, opaque, (*occlusio pupillæ cum synechia posteriori*). This is a consequence of iritis.

In the cases now enumerated, the cornea and anterior chamber are usually natural, and the fibres of the iris are more or less on the stretch.

4. Contraction or closure of the pupil, with synechia anterior, from prolapsus iridis, either through wound or ulcer of the cornea. A prolapsus near the centre of the cornea may include the whole pupil, and thus completely destroy sight. In such a case the cornea is leucomatous in its centre, transparent in the circumference; the fibres of the iris are stretched from the ciliary margin to the edge of the leucoma, and either in contact with the transparent portion of the cornea or separated from it by the smallest interval. The entire pupil may be involved in a prolapsus more or less near to the circumference of the cornea, or at its very edge; the fibres of the iris are tightly stretched between the opacity and the most distant part of the corneal margin, and a larger anterior chamber is left in the same situation. If the prolapsus should have included a part only of the pupillary margin, or a portion of the iris near the pupil, the aperture may be merely displaced, or contracted and altered in figure, yet the passage of light through it may be more or less effectually impeded by the opaque cicatrix, which remains after the wound or ulcer has healed. If a large portion should have been protruded, the fibres of the iris must be tightly stretched from the ciliary margin to the situation of their adhesion to the cornea; they are more or less tense in all cases of contracted or closed pupil from prolapsus iridis.

5. Contraction or closure of the pupil from partial staphyloma.

6. Obstruction of the pupil by central leucoma, the iris and other parts being natural. The effect on vision of central corneal opacity will vary according to its extent. If it is small, for instance not exceeding one-third of the diameter of the cornea, the patient may enjoy good vision when the pupil is dilated either in a moderate light, or by the use of belladonna; and an operation would not then be advisable. If the leucoma should extend to two-thirds of the diameter, there will be no useful vision, and an operation will be required.

7. Obstruction of the pupil by synechia anterior and partial leucoma. The anterior adhesion may embrace the whole pupillary margin, with complete obstruction by the accompanying leucoma, and blindness. The adhesion may be partial, and the obstruction of the contracted and misshapen pupil may be partial also. The effect on vision will depend materially on the situation of the adhesion, and of the leucoma; if they are above the natural situation of the pupil, or on either side of it, they may not interfere much with vision; if below, the effect will be more injurious. In partial synechia anterior, the pupil may sometimes be so much enlarged by the use of belladonna, as to give good sight.

8. Central leucoma, with closed pupil, or synechia posterior, and opaque capsule.

9. Partial opacity of the cornea, with synechia anterior and cataract.

I have never seen the congenital closure of the pupil from continuance of the membrana pupillaris, (*imperforatio pupillæ*,*) which is mentioned by some writers.

Diagnosis.—Before we undertake to form an artificial pupil, we must satisfy ourselves that the morbid state of the organ cannot be remedied by any other means. Opacities of the cornea may often be diminished by external applications. The adventitious membrane closing the pupil may be lessened by absorption in recent cases. The use of belladonna may improve sight, or even render it perfect in partial synechia, anterior or posterior.

The operation merely provides for the admission of light into the eye: it will not restore sight unless the organ be in other respects healthy. A careful inquiry is therefore necessary to ascertain that no other change has taken place in the eye capable of frustrating the success of the operation. The various conditions of the organ, enumerated above as requiring the formation of an artificial pupil, are mostly the consequences of severe inflammation, either external or internal. This inflammation may not have been confined to the cornea, iris, and capsule of the crystaline; it will be found, in many instances, to have extended to the nervous structure of the eye, or to other parts of the organ. We must ascertain whether the loss of vision is produced by the changes in the pupil only, before we think of forming a new opening for the passage of light.

Our first step then must be a careful examination of the organ, in which attention must be directed to the condition of its various component parts. The color and texture of the iris must be observed; these are changed by inflammation, and the alteration may be detected by comparing the affected with the sound eye. A blue or gray iris may exhibit a greenish or yellowish discoloration; a brown one may become of a dull bluish or leaden color; the unnatural tint may be general, or in variously sized and shaped spots or patches. The fibrous texture may have disappeared, and whitish threads may be seen in various parts of the iris, with the spotted discoloration just mentioned. The natural brilliancy of the organ is gone. Under such changes the texture of the iris loses its natural softness and contractility; it becomes tough, thick, and incapable of motion. In other instances it is unnaturally thin and semi-transparent. If the inner circle only

* "I believe," says Beer, "that I have hitherto seen only once a truly congenital closure of the pupil, that is, an iris remaining completely imperforate after birth. In the sixth week the pupil had become open without any interference of art. I have, however, seen in newly-born infants, when a few days old, closed pupil; but careful inquiry has shown, in all such instances, that it was the consequence of iritis, produced in a few hours after birth, by exposure to strong lights, and neglected."—*Lehre.* vol. ii. p. 190, note.

Juengken enumerates it among the conditions of the eye requiring operation, adding that it is of very rare occurrence.—*Die Lehre von den Augenoperationen*, p. 628.

So far as my researches have gone, there is no evidence of the membrana pupillaris having ever been found perfect even a few days after birth; and I believe that no record exists of any case in which an operation has been performed on it. Dr. Jacob gives the following account of its disappearance:—"The period now approaches when it is to disappear; this occurrence takes place, according to my observations, a short time previous, or subsequent to birth. In every instance where I have made the examination, I have found the membrana pupillaris existing in a greater or less degree of perfection in the new-born infant; frequently perfect without the smallest breach, sometimes presenting ragged apertures in several places; and, in other instances, nothing existing but a remnant hanging across the pupil like a cobweb. I have even succeeded in injecting a single vessel in the membrana pupillaris of the ninth month. Where I have examined it in subjects who have lived for a week or fortnight after birth, as proved by the umbilicus being healed, I have uniformly found a few shreds still remaining."—*Medico-Chirurgical Transactions*, vol. xii. p. 515, 516.

be changed in color, it is not of much consequence; but if the alteration extend through the whole iris, it is unfavorable. If change of texture should be equally extensive, and occupy the whole of the greater or ciliary circle, it is probable that the inflammation extended beyond the iris, and that the ciliary body and other posterior parts of the globe have suffered. We must observe whether the iris preserves its natural position and uniform surface, or whether it bulges forwards, and is elevated into tubercular projections, separated by intervening constrictions. If it form a convexity in the anterior chamber, pushing against the cornea at its outer circle, and drawn in at the pupil, which adheres in its whole margin; and if its surface be puckered and irregular, it will have been so changed in texture, as to render the operation impracticable; while the retina will have undergone such alteration as to make the opening, even if one could be formed, totally useless. Simple bulging of the iris, without change of color or texture, does not absolutely contra-indicate the operation; though, as it implies a diseased state of parts behind, it is an unfavorable circumstance. The pupil is closed when the iris is thus pushed forwards, and the bulging may depend on accumulation of aqueous fluid behind. The effect of opening the pupil with the needle, and thus re-establishing the communication between the two chambers may be tried in such a case, if the state of the retina should hold out any encouragement to an operation.

The globe should have its natural size and consistence, being neither enlarged by dropsy, nor shrunk and flaccid from atrophy. No benefit can be expected from the operation if there should be either hydrophthalmia, or a soft and diminished globe.

Softness of the eyeball, without diminution of bulk, especially if accompanied by a tremulous state of the iris, denotes synchysis, or disorganized vitreous humor, with which insensibility of the retina is usually, but not necessarily, connected. If the state of vision should be favorable, the operation may be undertaken in such a case, although the flaccidity of the organ may occasion additional difficulty in the execution, and the chance of benefit is small.*

Absorption of the sclerotica in the neighborhood of the corpus ciliare,

* Sir William Adams speaks more favorably of these cases. "When the vitreous humor is transparent, its partial or total disorganization does not appear materially to affect vision. For after the cataract has been removed, or the artificial pupil formed, vision appears to be equally good as if no such morbid change had taken place."—*Treatise, on Artificial Pupil*, &c., p. 117.

"In several cases, where from the fluidity of the vitreous humor, it has escaped so abundantly during the operation, through the puncture made by the needle, as to occasion almost an entire collapse of the coats of the eye; yet, after its regeneration, the patient's vision has been restored as perfectly as is usual after the operation for cataract."—Ibid., p. 117, 118.

"Even when so much of the vitreous humor is absorbed, as to occasion a flaccid and diminished condition of the eye, I have in several instances operated with perfect success, both in the removal of cataract, and in the formation of an artificial pupil. Indeed, the success which has attended the operations for artificial pupil in these morbid states of the eye has frequently excited my surprise. For in several cases which have scarcely offered a sufficiently favorable prospect to justify the performance of an operation, but which, at the urgent importunity of the patient, I have executed, almost contrary to my judgment, the happiest results have nevertheless been obtained. In the case of a young lady who had been for many years a patient of the late Mr. Ware, I actually refused, from the soft state of her eye, to operate upon it. But encouraged by my success upon cases of a similar kind, I again sent for her to town to undergo the operation for artificial pupil, which in one eye terminated in the most favorable manner, the patient being enabled to see the minutest objects. An artificial pupil was formed with equal success in the other eye, but the retina had lost its sensibility."—Ibid., p. 119, 120.

giving the globe a bluish or leaden color at that part, staphylomatous protrusions of the sclerotica, and a varicose state of the external vessels, indicate serious disorganization of the internal parts of the globe, with insensibility of the retina.

We must examine further whether the retina possesses a clearly marked sensibility to light; for without that no benefit can be expected from the operation. It might be supposed that closure of the pupil, with opacity of the capsule, would prevent the passage of light to the retina, and thus deprive us of direct evidence respecting its sensibility. However, light is transmitted in sufficient quantity for this purpose. If the pupil be closed, and the lens and capsule opaque, the patient can still distinguish light from darkness, if the retina is unaffected. If the patient, therefore, cannot make that distinction, we may conclude that the eye is amaurotic, and the operation consequently hopeless. In many of the conditions requiring the operation for artificial pupil, a much greater degree of vision exists.

These various points must be inquired into, that we may inform the patient whether an operation is likely to be successful or otherwise. It is our duty to represent to him accurately the state of the case. We can recommend the operation only where we think that it will be of advantage. Some states of the eye, however, are unfavorable without being hopeless. Under such circumstances, the patient may be inclined to try the experiment of a doubtful operation, rather than submit without an effort to permanent blindness.

The presence of external or internal inflammation, in any degree, absolutely contra-indicates the operation, so long as it continues. When the organ is thus excited, the additional irritation of mechanical violence would aggravate the inflammatory disorder, and thus probably increase the evils which the operation was designed to remedy.

A good state of health is necessary to the success of the operation, which must not be thought of so long as any constitutional disease, such as gout or rheumatism, is in activity.

"The formation of an artificial pupil," says Beer, "without reference to the particular mode of proceeding, is indicated in those cases only in which the blindness is caused merely by the closure or the obstruction of the normal pupil; when the sensibility to light is unequivocal; when no other deviations exist from the natural form and structure of the globe, which might render the operation extremely difficult or impracticable; when the previous inflammation has been long and completely terminated; when the patient is, in other respects healthy, and does not show even any marks of previous scrofulous, syphilitic, or arthritic disease; and when, moreover, he is completely blind in both eyes." (*Lehre*, vol. ii. p. 196.) From the previous statement respecting sensibility to light, it is obvious that the last observation is not to be taken strictly, but that it must be understood as importing the absence of useful vision.

Prognosis.—A serious wound is inflicted in this operation on the most sensible texture of the eye: considerable inflammatory reaction may be expected, and the results cannot be estimated with much certainty beforehand. Generally speaking, the necessity for the operation arises out of disorders originally inflammatory; and the eyes, on which it is performed, having suffered much from wounds or violent inflammations, are rendered more susceptible of injury, and more likely to suffer from future attacks. Hence it is difficult to determine the probable consequences of an operation. "We cannot," says Juengken, "satisfy ourselves respecting the state of the posterior structures, particularly in the cases in which the natural pupil is completely closed. Instances occur in which we conclude with great

probability that the vitreous humor and retina are healthy: yet it turns out afterwards that they are not so. I have observed cases of the kind, in which, although there was a distinct perception of light, the posterior parts of the globe were altered in texture as the result of the operation proved.*

The operation is often performed on eyes, in which the lens has been already lost; while we are frequently obliged to make the new pupil in a situation disadvantageous for vision. These are two sources of imperfection in the subsequent state of the sense.

The new opening is not susceptible of those changes in its dimensions which occur in the normal pupil. On this point, Mr. Gibson says, "I have paid considerable attention to the state of the artificial pupil, after the eye has quite recovered, in order to ascertain whether the fibres of the iris possess any power of motion, so as to alter the size of the new opening; but have never been able to detect anything similar to the contraction and dilatation of the natural pupil."†

Again, there are often niceties and difficulties in the execution of the operation, which are increased by the involuntary motions and unsteadiness of the patient. Hence we must be very guarded in our promises as to the result of the proceeding. In some rare instances, in which the eye has not suffered much, in which the lens and capsule are entire, and not injured by the operation, perfect sight may be restored. But, generally speaking, the result of this proceeding is much less favorable than that of cataract operations. In many instances, the patient must be contented if he should be able to see large objects, and to find his way alone.

Mr. Gibson observes, that "the degree of vision restored by an operation of this kind, is not quite so perfect as that which succeeds the removal of a cataract. In most cases, however, when the cornea has been perfectly transparent to the full extent of one-third of its diameter, the patient has been able to read tolerably small print. In looking at anything, the direction of the eye and position of the head are somewhat altered, and the object viewed is not held directly before the eye. Thus the artificial pupil, when formed towards the external angle of the eye, is turned by the motion of that organ more towards the internal angle, so as to bring that side of the eye somewhat forwards, and to produce a squint. And when an object, as a watch, is taken into the hand to be viewed, it is not held, as in the natural state of the eye, directly before the observer, but a little to one side. This alteration in the direction of the eye, and in the situation of the object viewed, is evidently the result of experience; for a person having an artificial pupil situated towards the external angle of the eye, can discern an object placed directly before him; but he sees it indistinctly, as another person, whose eyes are perfect, discerns objects inaccurately which are placed aside whilst the eye is directed to objects before him. The reason of this appears to be, that the rays of light passing from oblique objects, or entering the eye with great obliquity, do not reach the retina in sufficient quantity to render vision distinct. This indistinctness the patient attempts to remove, by placing the object in different situations, and by varying, at the same time, the position of the eye and head, until he at length discovers the exact position of the eye and object most conducive to distinct vision. (Lib. cit., p. 47—49.)

The prognosis is more favorable in proportion as the imperfection or loss of vision is simply dependent on obstruction of the pupil, and as the

* Lehre, von don Augenoperationen. p. 361.

† Practical Observations on the Formation of an Artificial Pupil, p. 49, 50.

‡ Treatise, &c., p. 312, 383.

iris itself, the cornea, and other parts of the organ are sound. The best cases, therefore, are those of central leucoma with healthy iris and unadherent pupil, of partial synechia anterior, and of pupils contracted or closed from prolapsus of the iris through the wound or ulcer of the cornea. In those which are usually the results of common inflammation affecting the external tunics, if we except the changes requiring the operation, the globe is perfectly healthy. Closure of the pupil after operations for cataract is also a favorable case, especially after extraction: in the serious internal inflammation, which sometimes follows depression and reclination, the posterior tunics generally are often involved. Iritis and other internal inflammations do not come on in healthy constitutions. Hence, when the pupil has been closed under such circumstances, the operation itself may cause a return of the original disease with renewed effusion of lymph. The prognosis is bad when the iris is changed in color and texture throughout, and still worse if it is also convex on its anterior surface, tuberculated and puckered.

The prospect of benefit from the operation is influenced by the extent of the organic changes in the cornea and iris, which render it necessary. It is better in proportion as more of the cornea remains transparent, and more of the iris and pupil unadherent. If the clear portion of the former, and the free part of the iris, are less than one-third of the whole, the result will be doubtful.

Position of the artificial pupil.—The situation and size of the new opening must be taken into consideration. The nearer it is to the centre of the iris, the better will the patient see: the more it approaches to the circumference, the more imperfect will vision be, both because the rays of light fall on a part of the retina naturally less sensible, and because the patient must learn to squint more or less, in order to bring the eye into the best direction for vision.

A further reason against making an artificial pupil at the greater circumference of the iris, is derived from the position of the ciliary processes, the anterior extremities of which are placed behind this part of the iris, and would therefore partially obstruct the new opening. This point has been particularly insisted upon by Scarpa. "Another rule," says he, "no less important to be followed in these cases, is, that the *lateral* pupil, although necessarily instituted in the semi-diameter of the iris, be always at a sufficient distance from the corpus ciliare, that this part may not render the operation useless by intercepting the passage of light through the new pupil. All, who are acquainted with the structure of the eye, know that the corpus ciliare, with its processes, is prolonged from the ciliary ligament to the circumference of the capsule of the crystaline lens behind the great margin of the iris, extending to about a fourth of the length of the semi-diameter of the membrane, from this ciliary ligament towards the centre of the iris. Every artificial pupil, therefore, which is not made at such a distance from the great margin of the iris, and consequently from the corpus ciliare, that the apex at least of the triangular aperture may correspond directly to the circumference, which would have been occupied by the capsule of the crystaline, must be useless.*

In general, sight will be better, the larger we can make the new pupil. The artificial opening has in most cases a disposition to contract or close: it is formed in a part where there is no natural aperture, and as attempts are generally made to repair the consequences of injury, we may expect that the new opening in the iris will become smaller after the operation.

* Treatise, &c., p. 312, 383.

The iritis consequent on the injury increases the contraction, which sometimes proceeds to entire closure. "The permanency of the artificial pupil," says Mr. GIBSON, "appears to me to depend principally upon the size of the opening, and healthy state of the iris and contiguous parts of the eye, at the time of the operation. When the artificial pupil has been made almost as large as the medium size of the natural one, and especially when the part of the iris removed has included its border, I have never seen any disposition in the opening to close. When, however, a mere narrow slip has been removed; when the iris from previous inflammation, has become more vascular than natural, or when it is complicated with adhesions to the capsule of the crystaline lens, in such cases its closure has occasionally taken place.*

The prognosis is most favorable when the purposes of the operation are accomplished by a simple clean cut of the iris; forcible detachment of it from the ciliary body, with laceration, protrusion, and strangulation of the part, is a more serious kind of injury, from which inflammation is more likely to result.

Previous considerations.—When one eye is sound, it is not advisable to operate on the other. Vision, with an artificial pupil, is imperfect, compared to natural sight; hence the patient continues to use his sound eye, so that he is no better off after the operation than he was before, even if it should succeed. The apprehension has been expressed, that the imperfect sight on the operated side might confuse that of the good eye.†

When the sight of one eye has been irrecoverably lost, our decision respecting the propriety of performing the operation for artificial pupil on the other, must be regulated by the degree of its vision. If the patient can see large objects, and find his way without a guide, it would be hazardous to operate, because blindness sometimes results from the operation, particularly where the eye has already been seriously and repeatedly diseased. If there is no useful sight, the experiment may be tried, as the patient cannot be rendered worse.

"When both eyes," says Mr. GIBSON, "have happened to be similarly affected with opacity of the cornea, I have found it of little use to the patient to form an artificial pupil in each. For when the vision of one eye, after the operation, is more perfect than that of the other, the patient (as in many cases of defective vision) acquires the habit of using the more perfect eye, and entirely neglects the other. When, therefore, I meet with defect in both eyes from opacity, I select the more perfect for the subject of an operation."‡

The situation of the new pupil is often determined by the nature of the case; as the artificial opening must be made opposite to such part of the cornea as retains its transparency. Certain positions, however, being more advantageous than others, are to be preferred, when we have a choice. The middle of the iris is the best place, as the axis of the new opening then corresponds to that of the natural pupil. When a lateral opening is to be made, in consequence of the circumference of the cornea only remaining transparent, the nasal side of the iris should be chosen on the level of the natural pupil; then comes the temporal side. The normal place of

* Practical Observations on the Formation of an Artificial Pupil, p. 47.

† "To form an artificial pupil in one eye, when the other is perfect, is quite superfluous, by no means advantageous to the patient, and therefore a thankless undertaking. After such an operation, the patient would be obliged to keep the eye closed, in order to see well, because its axis does not correspond to that of the other."—BEER. Lehre, vol. ii. p. 196, note. I doubt the correctness of the latter statement.

‡ Lib. cit., p. 51.

the opening is nearer to the nasal than to the temporal edge of the cornea; the axis of vision, therefore, with a pupil in the former situation, coincides more nearly with that of the perfect eye, than when it occupies the latter place. The next best situation is the lower and outer part of the iris, after which comes the lower; but the optic axis then deviates widely from its natural direction. The least favorable position is above; for a pupil is not of much use here, as the upper eyelid interferes with it, so that the eye must be turned downwards, and even then sight is imperfect.

When circumstances permit, Mr. Gibson prefers the external angle of the eye for the new pupil, alleging "that instruments can be used in this part with more facility than in any other part of the cornea; and every advantage is at the same time derived from the operation. When this part of the eye has been found opaque, I have formed the pupil, in several cases both at the inferior part of the cornea, and towards the internal angle of the eye. I did not, however, observe, that my patients saw at all more distinctly; on the contrary, when the artificial pupil was formed towards the internal angle of the eye, the sight in my opinion was less extensive; the nose appearing in some measure to curtail the field of vision. I prefer, therefore, the operation at the external angle in all convenient cases; and if the patients are enabled to read with more certainty by this mode than any other, they can have little reason to be dissatisfied with the slight squint of which it may be productive."*

The reasons for making the artificial opening large have been already mentioned. In the majority of cases we should make it as large as we can: in some few instances we must be on our guard not to make it too ample. Juengken† says, that it will never be too large if it extends to one-third of the diameter of the iris. Rosas‡ observes, that in order to secure a permanent opening of sufficient magnitude, the new pupil ought to be made rather larger than the middle size of the normal one; that it would be improper to make it much larger, and to extend it beyond one-third of the iris, since the impulse of light would be too powerful, and would destroy the sensibility of the retina.

Since the changes of structure requiring the operation for artificial pupil are generally caused by severe or repeated inflammations, which leave the organ more susceptible of future attacks; and since the violence inflicted on the iris in the operation is a serious exciting cause of inflammatory disorder, we should omit no precaution calculated to prevent its occurrence. We must carefully prepare the patient before, and watch the case closely, after the operation. The observations on these points, in reference to the operation for cataract, are equally applicable to that of artificial pupil: the only difference is, that the greater probability of inflammation requires greater care in the latter instance.

Various operations.—The differences in the states of the eye, which render the formation of an artificial pupil necessary, require corresponding diversities in the mode of accomplishing the purpose. The combinations of the various derangements already specified are so numerous, that almost every case presents something peculiar and individual. Hence the methods, which have either been practised, or devised and described, are very numerous. Mr. Guthrie mentions nearly fifty in his work§ on this subject;

* Lib. cit., p. 50, 51. † Lehre von den Augenoperationen, p. 635.

‡ Handbuch, vol. iii. p. 333.

§ A Treatise on the Operations for the Formation of an Artificial Pupil; London, 1819. Also, Lectures on the Operative Surgery of the Eye, 1827.

The following works may be consulted:—Gibson, Practical Observations on the Formation of an Artificial Pupil, &c., London, 1811. Sir William Adams, Practical

and the list might now be augmented. I do not deem it necessary or advantageous to enter into all these details, and shall therefore confine myself to the general plans of proceeding without considering all the modifications which may be required in particular cases.

OPERATIONS.

There are three principal methods, viz., *incision*, *excision*, and *separation*, to one or the other of which, or to a combination of them, all the proceedings hitherto proposed, however apparently various, may be referred.

SECTION II.—OPERATION BY INCISION; KORETOMIA, (from κορη, pupil, and τομη, section;) IRIDOTOMIA.

Synonymes: *Corotomia, coretotomia.*

Method of Cheselden.—CHESELDEN has shortly mentioned, in the *Philosophical Transactions*, a proceeding which he adopted in two instances of closed pupil following the operation of depression. He introduced a narrow knife, or, as he calls it, "a sort of needle, with an edge on one side," through the sclerotica, as in the ordinary operation of couching, and then brought it forwards, through the iris into the anterior chamber. "This

Observations on Ectropium, on the modes of forming an Artificial Pupil, &c., 1814. SIR WILLIAM ADAMS, Treatise on Artificial Pupil, in which is described a series of improved operations for its formation, &c., 1819. Observations on the operation for Artificial Pupil, illustrated by cases and engravings; by E. RYAN, M. D., in the second volume of the Dublin Hospital Reports and communications in Medicine and Surgery. J. A. SCHMIDT, Ueber Pupillenbildung mittelst Einschneidung der Iris (coretotomia) mittelst Ausschneidung der Iris (coretonectomia) und mittelst Ablösung der Iris (coretodialysis) nebst einem Zusätze von K. HIMLY; in HIMLY und SCHMIDT's Ophthalmologische Bibliothek, vol. ii. p. 1. BEER, Ansicht der staphylomatosen Metamorphose des Auges, und der künstlichen Pupillenbildung, Wien, 1805. Nachtrag, 1806. BEER, Lehre der Augenkrankheiten, vol. ii., section iii., chap. ix. LANGENBECK, Ueber Pupillenbildung, in Neue Chir. Bibl., vol. i., 197. Nachtrag zur künstlichen Pupillenbildung, ibid., p. 676. SCHLAGINTWEIT, Ueber den gegenwärtigen Zustand der künstlichen Pupillenbildung in Deutschland; Münich, 1818. WAGNER, de coremorphosi sistens brevem methodorum ad Pupillæ artificialis conformationem hucusque adhibitorum, adumbrationem, &c., Brunswick, 1818. KROHN, de Iridodialysis operatione, instrumentisque in ea adhibendis; Berlin, 1826, 4to. ASSALINI, Ricerche sulle Pupille artificiali con cinque tavole incise in rame e colorite; Milan, 1811, 4to, 2d edition, 1818. DONEGANA, Della Pupilla artificiale ragionamento corredato di osservazioni, e rami; Milan, 1809, 8vo. QUADRI, Annotazioni pratiche sulle Malattie degli Occhi; Naples, 1819, 4to. WAGNER, Kritische Revision der neueren Verhandlungen über die künstlichen Pupillenbildung in GRAEFE und WALTHER's Journal, vol. iii., 1822. JUENGKEN, Lehre von den Augenoperationen, Berlin, 1829; Kap. 22. ROSAS, Handbuch, vol. iii., § 390—442.

In his Chirurgische Kupfertafeln, Dr. L. F. VON FRORIEP has delineated all the various instruments hitherto devised for the operation of artificial pupil, and has given other figures relating to the same subject. Several instruments used in incision and excision of the iris are represented in Plate 193, Part 39. The numerous figures of Plate 199, Part 40, relate to the operations by excision and separation. Plates 228 and 229, in Part 45, are devoted to the same subject. Plate 270, in Part 53, exhibits the instruments employed by LUSARDI, and described in his Mémoire sur la Cataracte congéniale, &c., Paris, 1827. The Plates above mentioned contain also numerous figures representing the appearances of the pupil before and after operations in several cases. The methods of operating are mentioned at more or less length in the description of the figures.

done," says he, "I turn the edge of the needle, and cut through the iris as I draw it out."*

Fig. 63.

[Fig. 63 represents the artificial pupil, in CHESELDEN's first operation. It is copied from the figure given in the *Philos. Trans.*, (fig. 67.) The artificial pupil, as will be perceived, is formed above the centre of the iris, and this was done to avoid the lens, as CHESELDEN did not know how low he might have depressed it in the operation of couching, which had led to the closure of the natural pupil. In his second case, for reasons which he does not mention, he formed the artificial pupil below the centre of the iris.]

WENZEL's *Operation.*—Baron WENZEL, having employed the method of CHESELDEN without success, adopted a different proceeding, in which incision of the iris was performed through the cornea, and was combined with excision. He made an opening of the cornea with the cataract knife, as in extraction; but after puncturing this part, he carried the point of the knife through the iris, then brought it out again into the anterior chamber at a short distance from the point of entrance, and subsequently completed the corneal section, as in extraction, thus at the same time dividing the iris, so as to make a small flap, [fig. 64,] which is then cut off by a small scissors introduced under the cornea. (*Treatise on the Cataract*, translated by Mr. WARE, sect. 27.)

Fig. 64.

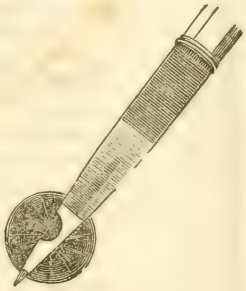

JANIN's *Operation.*—JANIN tried the operation of CHESELDEN unsuccessfully. The fibres of the iris did not retract, so that the incision which he had made appeared as a simple line; he says that the wounds cicatrized completely. Having accidentally wounded the iris with the scissors in operations of extraction, he found that the openings thus made did not close, and that they did not subsequently interfere with vision. Hence he was induced to adopt a new method of forming artificial pupils. He opened the lower half of the cornea, as in extraction. Then, elevating the flap of that membrane, he introduced under it a curved scissors, one end of which was pointed. He penetrated the iris with this pointed end, about one line from its greater circumference, then carried the instrument directly upwards and half a line from the original pupil towards the external angle, and divided the iris by closing the blades of the scissors, so as to form an opening about two lines and a half in extent. He adopted this proceeding

* Philos. Trans., No. 402, p. 451. Philos. Trans., abridged, vol. vii., p. 493. The two pupils, which are elliptical and transverse, are represented in figs. 67 and 68. Fig. 69 represents the eye with the instrument carried through the sclerotica. The latter figure is repeated in the Anatomy of the Human Body, tab. 36, fig. 1, p. 317. In the explanation, Mr. CHESELDEN says, "This operation I have performed several times with good success; indeed, it cannot fail when the operation is well done, and the eye no otherwise diseased, which is more than can be said for couching a cataract."

successfully in many instances, which he has detailed.* In some of them cataract existed, which he extracted through the new pupil.

Fig. 65.

Operation of Sir W. Adams.—The formation of an artificial pupil by incision through the sclerotica, which had fallen completely into disuse, was revived and improved by Sir W. Adams, who devised for the purpose a very small knife, which he calls an iris scalpel, [fig. 65, *c*.] It is less than a line in width, with a straight back and sharp point. The edge is convex towards the point, like that of a scalpel, and cuts back towards the handle for about three lines.† The iris scalpel may be made still narrower than is mentioned above, [fig. 65, *d*.] In his last work on artificial pupil, Sir William thus describes his mode of employing the instrument. The patient is seated, the upper lid raised by an assistant, while the lower is depressed, and the globe fixed by the operator. The iris scalpel already described, with its edge turned backwards, must be introduced through the coats of the eye at their external part, about a line behind the iris, and in the transverse diameter of the latter membrane, [see fig. 66.] The point of the instrument should then be made to penetrate through the iris, into the anterior chamber, in a line with its central diameter, and somewhat less than one-third of the width of that membrane, from its ciliary margin. The iris scalpel is then to be carried cautiously through the anterior chamber, towards the inner canthus, keeping its edge in contact with the iris, (in order to prevent the point from piercing the internal part of the cornea,) until it has traversed more than two-thirds of the width of the iris, when it should, with great care, be drawn backwards, almost out of the eye, making the most delicate pressure with the edge of the instrument against the iris, lest it should be detached from the ciliary ligament. If the division of the iris is not effected to a sufficient extent, during the first effort, the iris scalpel should be again carried forward, and withdrawn in a similar manner. This is to be repeated as often as may be necessary to effect a division of the iris, to the extent of a third part of its diameter. In my work, published in 1812, I directed that two-thirds at least of the extent of the transverse diameter of the iris should be divided, in order to guard against the supposed disposition of that membrane to re-unite; but abundant experience of the favorable results of this operation, which have since occurred in my practice, has convinced me that no such apprehension need be entertained, and that a division of one-third the extent of the diameter of the iris, is sufficient. Indeed, so far

Fig. 66.

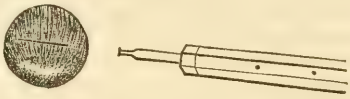

* Mémoire sur l'Imperforation de l'Iris, dans lequel on indique le moyen qu'on doit employer pour faire une ouverture à cette tunique, lorsque la pupille est détruite; in Mémoires et Observations anatomiques, physiologiques et physiques sur l'œil. 1772, p. 177—205.

† Sir W. Adams has given two views of this instrument in his Practical Observations on Ectropium, &c., plate 3, fig. 1 and 2. [Fig. 65, *c*, is copied from the original figure above referred to. This instrument is too large; *d* represents the blade of a similar knife of a better size.]

is there from being a disposition in the newly-formed pupil to close again after it has once been established, that the very reverse is the case; for the radiated fibres sometimes contract in a greater degree from delay; whereby the artificial pupil is proportionably enlarged. In the species of case now under consideration, an almost immediate contraction of the radiated fibres of the iris usually takes place after that membrane has been divided, which produces a new pupil of a sufficient size for all the purposes of vision." (See fig. 67.) *A Treatise on Artificial Pupil*, &c., 1819: p. 34—36.

Fig. 67.

In order to avoid the long ciliary artery, the sclerotica should be pierced a little above or below the middle transverse line of the eye.

Incision of the iris, according to this description, seems a simple affair; it is not, however, always easily accomplished. When the lens has been previously lost, as in closed pupil consequent on cataract operations, or if the vitreous humor should not possess its usual consistence, the iris, being unsupported, is not divided, but yields to the pressure of the knife, and is carried back into the vitreous humor: if the pressure be increased, it easily separates from the ciliary ligament. Hence it is necessary to draw the edge of the knife along the surface of the iris with as little pressure as possible, and to repeat this movement, until the purpose is accomplished. In so doing, care must be taken not to enlarge the opening in the sclerotica, as the vitreous humor might escape through it. When the texture of the iris is healthy, and more particularly if its fibres are on the stretch, it is easily divided; the edges of the incision retract immediately, and leave an oval opening of good size. If the iris be thickened and hardened by previous disease; and if it should be still further strengthened by adhesion to a thick and tough capsule, its division by means of the iris scalpel, may be impracticable. When, however, the iris is thus changed in structure, it will usually be found that the retina has been involved in the mischief, and consequently that an operation is not advisable.

If there should be an opaque capsule adherent to the iris, one and the same incision will divide both. If the new pupil should be more or less obstructed by the capsule, it may perhaps admit of division or detachment by the iris scalpel.

When the closed pupil is complicated with cataract, Sir W. Adams recommends that the capsule and lens should be freely divided with the iris scalpel. "The larger portion of the fragments should then be brought into the anterior chamber, and the remainder left between the edges of the divided iris, so as to prevent their reuniting by the first intention." (Lib. cit., p. 38.) In this complicated proceeding, considerable violence is offered to the organ, and the iris is also subjected to pressure, a description of injury which generally causes inflammation of the membrane. I consider it preferable to leave the cataract in its place for absorption, and if necessary, to depress or break it up further in another operation, after the lapse of some time.

Maunoir's *mode of incision.*—The method of performing incision of the iris, by means of scissors, which was practised by Janin, was adopted and improved by J. P. Maunoir,* of Geneva, who has described it in two

* Mémoires sur l'Organization de l'Iris et l'Operation de la Pupille artificielle, Paris, 1812. Mémoires sur les Amputations, l'Hydrocèle du Cou, et l'Organization de l'Iris; Genève, 1825. Observations and cases relating to the Operation for Artificial Pupil; in a Letter from M. Maunoir of Geneva, in the Medico-Chirurgical Transactions, vol. vii. p. 301. Further Account of the Result of an Operation for forming an Artificial Pupil; Medico-Chir. Trans., vol. ix. p. 382.

memoirs. It was approved and strongly recommended by SCARPA* in the last edition of his work on diseases of the eye, from which I have drawn the following description of it, as being more clear and connected than that given by its author. "In order to attain the object proposed, this learned and expert oculist has had scissors [fig. 68] made of a delicacy and fineness hitherto unequaled in the construction of surgical instruments.† The blades

Fig. 68.

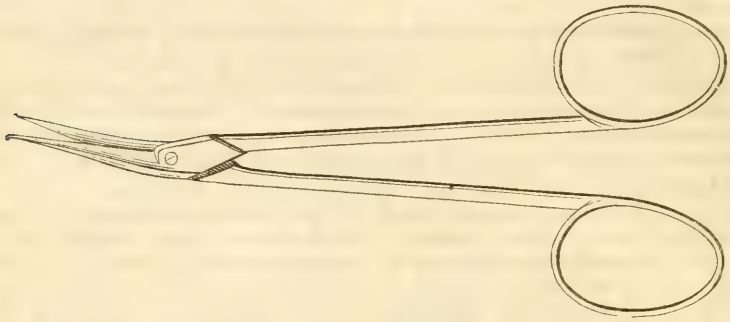

of the scissors are slightly inclined to the handle, (at an angle of 140°.) The upper blade, or that which is designed to pass through the anterior chamber of the aqueous humor between the concavity of the cornea and the iris, terminates in a small button. The lower blade for perforating the iris and advancing along the posterior surface of this membrane, has a very sharp point similar to that of a lancet. The thickness of the two blades united does not exceed that of an ordinary fine probe. The mode of operating with it, as is practised by Professor MAUNOIR with great success, and which has been advantageously repeated in this hospital, is as follows:

"The patient being placed horizontally with his head a little raised, a position no less commodious in the operation for the extraction of the cataract than the formation of the pupil, and supposing the cornea to be perfectly transparent, and the capsule and lens in the case of cataract to have been completely removed from the axis of vision, an incision is made in the cornea at its lower or lateral segment, as may be most convenient, of half the extent of that which is usually made for the extraction of the crystaline lens. Through this small opening in the cornea, the scissors are to be introduced closed, with the flat part in a line parallel to the transverse diameter of the iris; and as soon as the point of the instrument has advanced near to the great margin of the iris, that is to say, nearly opposite the small incision made in the cornea, it is gently opened, and inclined in such a manner that the inferior pointed blade may perforate the iris, and run along the posterior surface of that membrane, until the small button of the upper blade has reached the part where the cornea and sclerotica unite. The iris is then to be divided in its transverse diameter by a single stroke passing as nearly as possible through its centre. This incision being

* Treatise on the Principal Diseases of the Eyes; chap. xvi., on the Artificial Pupil.

† Mém. sur l'Organization de l'Iris, &c., fig. 11; SCARPA's Treatise, plate 3, fig. 8 and 9. [Represented in fig. 68.]

executed, another is to be expeditiously made, so far diverging from the first that the two incisions may form in the centre of the iris a triangular flap of the figure of the letter V, the apex being precisely in the centre of the iris and the base near its greater margin." [Fig. 69.]—"On opening the eye operated on five or six days after, the apex of the triangular space is found to have retracted towards its base, leaving in the middle of the iris an artificial pupil of the figure of a parallelogram, [fig. 70,] or of a crescent, with the cornua directed to the great margin of the iris, when the apex of the divided portion has not completely shrunk towards its base."*

Fig. 69.

Fig. 70.

According to M. Maunoir, the triangular portion of the iris, included between the two incisions, sometimes retracts immediately and suddenly. In the first case on which he operated, he says, "A very interesting circumstance occurred immediately after the second incision; the flap or portion comprised between the two incisions rolled itself up, or appeared to do so, like the spring blind of a window-carriage, leaving at the moment a free opening for the passage of light."†

When partial opacity of the cornea exists with synechia anterior, the mode of proceeding is a little altered. "To remedy this morbid state, it is necessary to have the scissors of Maunoir made with the points of both blades terminating in a button. A small incision being made in the cornea at the most commodious part, according to the rules before laid down, and the scissors introduced closed, an attempt is to be made to free the adhesion, which the iris has contracted to the cornea by them; which, if it is effected, the natural pupil in general recovers its former situation and size; but, if the adhesion of the iris to the cornea is very firm, the operation is to be completed in the following manner. One of the blades, by means of the small button, is introduced within the contracted natural pupil, and conducted behind the posterior surface of the iris, until the other blade, defended in the same manner, has reached the confines of the cornea with the sclerotica. The iris is then to be divided in the form of the letter V, without at all injuring either the capsule or lens, both of which have preserved their transparency. It is asserted by some able operators, and men of careful observation, that in this case a simple incision alone is requisite, in order that the pupil may recover its proper size, and maintain it, provided, however, that such incision strictly include the orbicular muscle of the natural pupil." (Lib. cit., p. 384, 385.)

If the closed pupil should be complicated with cataract, it is recommended that the opaque lens and capsule should be cut through by the scissors, together with the iris; and that the fragments of the lens should then be extracted. The practicability of dividing the lens in this manner may be doubted; but, if the cornea and anterior chamber be nearly in their normal state, the incision of the former might be made large enough to allow of the lens being removed through the artificial pupil. This object was successfully accomplished in two of the cases related by M. Maunoir in the *Medico-Chirurgical Transactions*, vol. vii.; also in another instance detailed in vol. ix.

* Treatise, &c., p. 378—380. Figures of pupils formed in this way are given in the two French publications of M. Maunoir already quoted. [Figs. 69 and 70 are copies of them.]

† Mém. sur l'Organization de l'Iris, p. 38.

When the fibres of the iris are tense, as in closed pupil after cataract operations, or from large prolapsus, and the texture of the membrane is at the same time healthy, the double incision will not be necessary. A single vertical or horizontal incision will suffice; the edges of the cut will retract so as to leave a pupil of sufficient size.

The method by incision is best adapted to the cases in which the anterior chamber and cornea are in the normal state, and the lens has been removed; that is, to closed pupil after cataract operations; also to contraction or closure of the aperture from prolapsus near the circumference of the cornea. M. Maunoir employed this proceeding in cases of leucoma with synechia anterior; it is practicable, if a considerable portion of the cornea be still transparent, not otherwise.

[M. Maunoir's method of operating for artificial pupil is based upon his views of the structure of the iris; and it is impossible fully to understand the former, without a knowledge of the latter, which we will therefore briefly explain.

M. Maunoir conceives that he has discovered in the iris two orders of muscular fibres; one radiating, occupying the larger circumference of the iris, and the contractions of which enlarge the pupil; the other arranged circularly, forming the margin of the pupil, and the contractions of which diminish this opening. This discovery of the direction of the muscular fibres of the iris, M. M. maintains furnishes us the most important indication for the incision of the iris, which is always to be made perpendicular to the fibres, for it is by this mode alone, he says, that we can hope to make a wound in the iris which will not unite, and by which a simple incision will change into a more or less elliptical opening. (*Mém. sur l'Organization de l'Iris*, p. 68, 31.)

According to his views if the radiating fibres be divided transversely through their middle, the equal contraction of their two ends will widen the incision so as to make an elliptical opening. If these fibres be divided transversely near their ends either at their ciliary or pupillary border, the longer portion of them being capable of greatest contraction, the opening will be more or less semi-elliptical. If the circular fibres be divided transversely, and at the same time a fasciculus of the radiating fibres be separated by two incisions, forming a triangular flap, the apex of which is formed by the incision at the margin of the pupil, (see fig. 69), the contraction of the circular fibres will widen the opening at the apex of the triangle, and the contractions of the radiating fibres at the same time will draw the point of the flap towards the ciliary margin, and thus we shall have an opening of the figure of a parallelogram. (See fig. 70). The great aim then of M. Maunoir is to divide the fibres of the iris in such a way that their contractions will have most effect in enlarging the opening.

Fig. 71.

In his first case, a man named Cemoreau, M. Maunoir, after opening the cornea, as described (p. 440) introduced his scissors and made an incision in the upper portion of the iris, dividing transversely the radiating fibres near their junction with the circular. The former contracting, left a semi-elliptical opening. (See fig. 71).

In a woman named Yétre, M. Maunoir divided the circular fibres transversely, separating a cone of the radiating fibres by two incisions at the same time, as just described, (see fig. 69.) and a pupil was formed which is represented in fig. 70.

Mr. MACKENZIE, in his admirable Treatise, gives a different mode of making the flap; but it must be evident from what we have said, that incisions made in the direction represented by him, (see fig. 72,) would not be in accordance with the views of M. MAUNOIR, nor would there result from such incisions, according to those doctrines, a pupil of the form which he delineates. (See fig. 73.)

Fig. 72.

Fig. 73.

Nevertheless we have little doubt that in some cases the operation described by Mr. MACKENZIE might succeed, and it would be available where M. MAUNOIR's would not.]

SECTION III.—OPERATION BY EXCISION; CORECTOMIA (from κορη, pupil, and εκτομη, excision); IRIDECTOMIA.

Synonyme: *Coretonectomia.*

The object of this proceeding is to form an opening for the passage of light by cutting out a portion of the iris. What is thus removed may include a part of the natural pupil, or not. The excised portion may be taken from the centre, or towards the circumference of the iris; in other terms, the excision may be *central* or *lateral.* The operation of WENZEL, already described, (see p. 437,) is a modification of central excision. ARNEMAN* proposed to cut out a circular portion with the concave scissors; and complicated instruments, in which scissors and hooks have been combined, have been devised, I do not know whether they have been used, by others.†

BEER‡ made a small incision in the cornea, introduced a fine hook or a toothed forceps into the anterior chamber, seized the iris, drew it out, and then cut off the portion thus displaced with scissors.

GIBSON'S *operation.*—Mr. GIBSON'S proceeding was nearly the same as that of BEER: it was modified according to the different states of the eye requiring the operation. He used, besides a cataract knife for opening the cornea, a small hook, [fig. 75,] a pair of small forceps, [fig. 74,] and iris scissors with one or both ends blunt, [fig. 76.] The most favorable case is central leucoma of the cornea, with the pupil unadherent, and the lens and capsule transparent. "The first step of the operation is to secure the eyelids, as in the operation for extracting a cataract. A puncture is then to be made in the cornea with a broad cornea-knife, within a line of the sclerotica, to the

* System der Chirurgie, vol. ii., p. 199.

† KUNSTMANN in GRAEFE und WALTHER's Journal, vol. i., p. 519. REISINGER, Meine Hakenscheere zur Bildung künstliche Pupillen, und ihr Schicksal; in the Baiersche Annalen, B. I. St. i. p. 121, tab. 3, fig. 1—7.

‡ Ansicht der staphylomatösen Metamorphose des Auges, &c., p. 114.

extent of about three lines. All pressure is now to be removed from the eyeball, and the cornea-knife gently withdrawn. The consequence of this is, that a portion of the aqueous humor escapes, and the iris falls into contact with the opening in the cornea, and closes it like a valve. A slight pressure must now be made upon the superior and nasal part of the eyeball, with the fore and middle fingers of the left hand, till at length, by an occasional and gentle increase of the pressure, or by varying its direction, the iris gradually protrudes, so as to present a bag of the size of a large pin's head. This protruded portion must be cut off with a pair of fine curved scissors, and all pressure at the same time removed; the iris will then recede within the eye, and the portion which has been removed will leave an artificial pupil more or less circular.

Fig. 74. Fig. 75. Fig. 76.

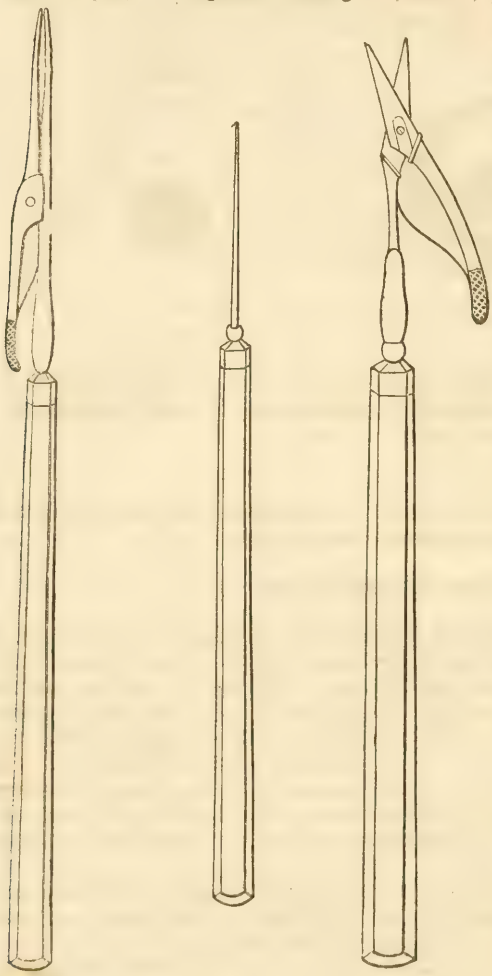

"It sometimes happens, that the whole breadth of the iris to the border of the natural pupil is protruded and removed this way. This I consider is rather an advantage, because it ensures a large pupil, though generally one which is oblong in its shape. I have found, however, the mere circumstance of shape to be of little consequence in this operation, and always to be sacrificed to the object of size. It may also be remarked, that the opening has no disposition to close, when, in forming the artificial pupil, the border of the natural pupil is divided. It occasionally happens, also, that as soon as the knife is removed, the muscles of the eyeball act with violence, and project a small staphyloma or bag of the iris through the incision. If this bag be not large enough to form the new pupil, the iris must be further protruded by gentle pressure."*

The incision in these cases should be made close to the edge of the sclerotica, more especially when the transparent border of the cornea is narrow, that the opacity sometimes following the wound may not encroach

* Practical Observations on the Formation of an Artificial Pupil, &c., pp. 39—41.

on that part of the membrane through which the light will pass into the new pupil. The corneal opening should not exceed the size mentioned above. The protruding portion of the iris should be seized with a small forceps, [fig. 74,] and snipped off as quickly as possible: it may be previously drawn out further, if the prolapsus should not be sufficient. If the opening, as first made, should not be large enough, the iris may be again drawn out by means of the small hook, [fig. 75,] and another portion removed.

Adhesion of the iris to the opaque cornea requires some modifications in the mode of operating. If one half of the pupil should adhere, the portion next to the transparent part of the cornea generally remains free. One or two points of adhesion may be separated by the knife employed to open the cornea, or by the iris scissors, [fig. 76,] so as to disengage the pupil partially or entirely. Considerable adhesion will prevent a protrusion of the iris sufficient for our purpose. In that case, we must introduce the small hook, [fig. 75,] seize the unadherent border of the pupil, draw it out through the puncture of the cornea, and cut off a sufficient portion with the curved scissors, (op. cit., p. 56, 57.) When the pupil is generally adherent, "the point of the cornea knife is to be passed through the cornea in the usual way, and is to be directed to those adhesions, the division of which will most effectually tend to render the iris free, for the subsequent part of the operation. Care must at the same time be taken to avoid undue pressure on the eyeball, that the aqueous humor may not escape before that object is accomplished; for otherwise, the cornea and the adhering iris will become flaccid, and the adhesions will be much more difficult to separate."

Having separated some part of the iris from its connection with the cornea, and consequently made an aperture in it, the next step will be to remove a portion of it in a convenient situation. If the iris appear sufficiently loose, the hook [fig. 75] may be first introduced through the puncture in the cornea, and a gentle attempt may be made to draw out a sufficient portion from the eye, to be cut off with the curved scissors, [fig. 77, and which are to be held as represented in the figure.] If this be found impracticable, the iris must be removed within the eye with the iris scissors. [Fig. 76.]

Fig. 77.

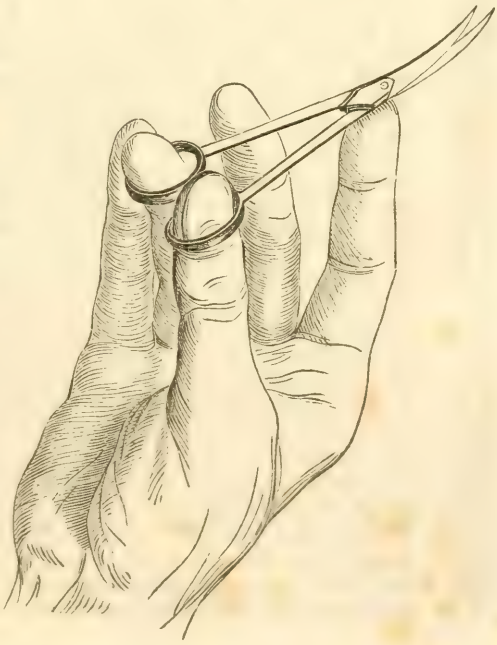

In using these small scissors [fig. 76], they are to be introduced shut and flat, through the aperture in the cornea; and at the place where the artificial pupil is to commence, a small opening is to be made with them in the iris.

Through this opening, the blade of the scissors, which is attached to the long handle and has a blunt point, is to be conducted between the iris and crystaline lens by opening the scissors a little. The other blade is to be passed between the inner surface of the cornea and the iris, until their points reach a little beyond the border of the iris, where it has been separated from its adhesions. This portion of the iris is then to be divided, and the flap thus formed may generally be easily removed by another snip or two with the scissors. By this means an artificial pupil of a triangular or oblong shape will be made, which may easily be enlarged by the use of the scissors, if it should appear too small." (Ibid., p. 66—68.)

The iris scissors may be employed in the way just described, in those cases of partial pupillary adhesion, where we cannot draw out the iris with the hook. The operation by detachment and strangulation is, however, more suitable to the two last mentioned cases; and the use of scissors within the eye in the way just described can hardly be regarded as a practical proceeding.

Fig. 78.

Mr. Tyrrell employs a more simple and easy method of changing the position of the pupil, when its margin is unadherent, or of making a new opening when the normal pupil is closed by adhesion to the cornea. He employs a broad needle and a fine blunt hook, with a long bend [fig. 78]. The preferable situation for the new pupil is downwards and outwards. The needle pierces the cornea close to its margin, and makes an opening just sufficient to allow the introduction of the hook. It should be carried fairly into the anterior chamber and then withdrawn so as to prevent free escape of the aqueous humor. "The hook should be passed with the bent limb towards the cornea, or forward; and then it should be carried as far as the aperture of the pupil; and, the extremity of the instrument being introduced through the pupillary space, the bent part of the hook should be directed backward, by half rotating the handle of the instrument between the finger and thumb. The pupillary margin of the iris should next be caught by the hook, by pressing the point gently towards the surface of the lens, at the same time that the instrument is carefully withdrawn. When, however, the bent part of the instrument is withdrawn as far as the opening in the cornea, its passage will generally be impeded while the point is directed backwards, as when catching the margin of the iris; it is then again necessary to half rotate the handle, so as to direct the bent limb forwards; but, in doing this, the instrument must not be allowed to recede from the opening in the cornea, or the iris may slip from the hook. The hook being directed forwards, and still retaining hold of the pupillary margin of the iris, should then be withdrawn through the corneal puncture, bringing with it part of the iris; and sufficient of the membrane should be brought through the opening in the cornea, to effect the desired change in the pupillary aperture of the iris." The piece of the iris drawn out may be cut off with a fine pair of scissors. [Fig. 77.] (Op. cit., vol. ii., p. 500—502.)

If the pupil should be partially adherent to the cornea, and consequently diminished, the hook may produce a fissure instead of drawing the iris out. It may then be necessary to perform a second operation, in which the hook is passed into the fissure, and draws out one or the other edge, according to circumstances, so as to enlarge the new opening sufficiently. (Ibid., p. 504.)

If the adhesion to the cornea should have completely closed the natural pupil, Mr. TYRRELL carries the broad needle, after perforating the cornea through the iris close to the place of its adhesion, taking care that the point of the instrument shall not be directed backwards. He introduces the blunt hook into the opening thus made, seizes and withdraws the iris, as in the former case. (Ibid., p. 510.)

The use of the blunt hook is particularly important in order to avoid wounding the capsule or the lens, when they are perfect. When the operation is successfully accomplished, the patient regains perfect vision, sometimes, however, requiring the aid of convex glasses.

SECTION IV.—OPERATION BY SEPARATION.

COREDIALYSIS (from κορη, pupil, and διαλυσις, loosening or separation), IRIDODIALYSIS.

Synonymes: *Corodialysis; Coretodialysis.*

The object of this operation is to form an artifical pupil by separating the iris, at some part of its greater margin, from the ciliary ligament. The method at first proposed, consisted of simple separation: subsequently, it was found necessary to strangulate the iris, when separated, in an aperture of the cornea, or to cut away a portion of it.

The operation of SCARPA *and* SCHMIDT.—The idea of this operation occurred at about one and the same time to two celebrated men, SCARPA,* of Pavia, and J. A. SCHMIDT,† of Vienna, who tried it in several cases, and published the results of their experience without any knowledge of each other's proceedings. They had observed how easily the iris separates from the ciliary body, so that when it is seized with a pair of forceps in the dead subject, even near the pupil, it gives way at the ciliary margin. They had seen it separated in the same way in the living eye from violence, as in smart blows with a whip, or other similar accidents; from injury in extraction or depression, and even from the dragging of the iris in cases of large prolapsus.

SCARPA used his slender curved cataract needle, and introduced it at the external angle of the eye, two lines behind the margin of the cornea. He carried it behind the iris until its point had reached the upper and internal part of the ciliary margin, which he then perforated so that the point of the instrument should be just visible in the anterior chamber: if it were

* Saggio di osservazioni ed experienze sulle principali Malattie degli Occhi; small folio, Pavia, 1801, cap. xvi. The last case detailed in this chapter was communicated by Signor F. BUZZI, of Milan, and gives the history of a closed pupil consequent on extraction, in which he formed an artificial pupil by separation, in the year 1788. He used the common spear-shaped cataract needle, which he introduced through the sclerotica, as in depression. He perforated the iris from behind in its upper part, about a line above the closed pupil, carried the instrument parallel to the anterior surface of the iris, and then directing its point downwards and backwards, detached the iris for at least one-third of its circumference, on which the anterior chamber became filled with blood. There remained an oblong artificial pupil, and the patient was able to read and write with cataract glasses. Osservazione 62, p. 212, 213.

† Ueber Pupillenbildung, &c., in HIMLY und SCHMIDT's Bibliothek, vol. ii. stück 1, p. 1: Jena, 1803. This essay, in which six cases of the operation are detailed, was read at the Josephine Academy in Vienna, on the 21st of September, 1802.

further advanced, it would become engaged in the substance of the cornea. The needle was now carried downwards and outwards, moving in a line parallel to the anterior surface of the iris, so as to detach a portion of its margin from the ciliary ligament. When this detachment had been partially effected, he lowered the point of the needle to the inferior angle of the artificial opening, and extended the separation to the requisite length by dragging the iris towards the temple and backwards. If any opaque substance should be seen in the new opening, he advises that it should be detached with the needle, and carried into the anterior chamber. (Lib. cit., p. 208, 209.)

Schmidt says, that for ten years he had formed artificial pupils in several instances annually, by the method both of Janin and Wenzel; but that even where he had reason to expect favorable results, he had been disappointed in seven or eight out of every ten cases. The cause of failure was generally the effusion of lymph, and the consequent formation of an adventitious opaque substance in the new openings. (Lib. cit., p. 23 and 24.) The following facts awakened his attention to the possibility of forming artificial pupils in another way. In 1792 he saw a coachman, whose left eye had been struck with a whip six months before. The iris was separated from the ciliary ligament to a considerable extent on the nasal side. The natural pupil was collapsed, (*considentia, synizesis pupillæ,*) with a cataract behind it. The new opening, which was of a clear black, contracted and dilated according to the degree of light, so that the patient enjoyed clear and distinct vision. In 1795, a similar instance occurred in a youth of sixteen, who had been struck on the eye by a hard ball. A considerable detachment of the iris on the temporal side had ensued, with collapse of the pupil and cataract. Through the artificial opening, which was clear, and contracted, and dilated like a natural pupil, the smallest objects could be seen distinctly. In 1797, an officer received a severe injury of the eye from a shot. The iris was separated at its lower part and torn through so that the laceration and the normal pupil formed one large opening, occupied by an opaque lens, below which the posterior chamber was clear. This patient took up a book, closed the sound eye, and read small print.*

In his first attempt, which was in 1802, Schmidt made an opening in the cornea, seized the iris with forceps, and thus separated it from the ciliary ligament, (lib. cit., p. 30, 31.) He afterwards adopted a proceeding almost exactly similar to that of Scarpa. (Ibid., p. 41.)

The separation of the iris from the ciliary body has sometimes been effected by means of a curved needle, or a hook, introduced through the cornea.†

* Lib. cit., p. 27—29. Several other cases of unnatural pupil consequent on accidents, in which the iris had been detached from the ciliary body, are quoted by Himly, ibid., p. 50—52. Janin has four instances of similar separation in his Observations et Dissertations sur le Décollement de l'Iris considérée comme contigue, et non continue à la Choroide. He observes that Hoin of Dijon had found by repeated trials in human eyes and those of animals, that the iris, when held with forceps and gently drawn, separates easily from the choroid without injury to either part. Memoire, &c., sur l'œil, p. 415.

† Bonzel in Hufeland und Harles, Journal der practischen Heilkunde, January, 1815. Wagner, de Coremorphosi, p. 36, 1818. Langenbeck, Neue Chir. Bibl., vol. i., p. 221. Beer performed iridodialysis from the front; but he pierced the sclerotica, and carried the needle into the anterior chamber on the temporal side of the eye. Nachtrag zu seiner Ansicht der staphylomatosen Metamorphose, &c. This proceeding has not been repeated by other operators; nor can it be considered worthy of imitation. Himly had also separated the iris from the front, having carried his needle

Subsequent experience induced SCARPA to think less favorably of the operation by separation, which he seems from the following passage in the last edition of his work, to have abandoned altogether. "Experience, to which all theory is subordinate, has since convinced me that, independently of the mode of operating which I proposed, being inapplicable, of which I was aware, to the greater number of cases of complicated closure of the pupil, I was also mistaken with regard to the most material point in the operation, that is, the permanency of its success; as I have since found that the marginal pupil or opening, which is formed by the detachment of the greater circumference of the iris from the ciliary ligament, from being oval, becomes, in process of time, *filiform*, and consequently useless." (*Treatise*, &c., translated by Mr. BRIGGS. Second edition, p. 368.)

This closure of the unnatural opening caused by detachment of the iris is exemplified in the case of JOHN O'BRIAN, related at p. 177 of the present work.

Professor ROSAS justly observes, that "the objections to the detachment of the iris through the sclerotica are so obvious, that they were soon observed and appreciated by the proposers of the method. The very extensive injury inflicted on an organ already weakened in most cases by serious previous disease, the unavoidable destruction of the lens, the great difficulty of bringing the needle into the anterior chamber exactly at the ciliary margin of the iris, the almost inevitable passage of the needle into the cornea, the difficulty of effecting an adequate detachment of the iris from the painful nature of the process, and the consequent unsteadiness of the patient, and the subsequent closure of the newly-formed pupil in spite of all precautions, are disadvantages belonging to the operation of SCHMIDT and SCARPA, which seriously diminished its value in the estimation of well-informed and unprejudiced surgeons."

THE OPERATION BY DETACHMENT AND STRANGULATION.

As the simple separation of the iris from the ciliary ligament cannot be depended on for the formation of a permanent opening, except perhaps in the case of its being effected in the upper part, because experience teaches us that the detached iris generally resumes its former position, either soon after the separation, or at a rather later period, particularly during the inflammation, it is necessary to adopt some further means for maintaining the artificial aperture. LANGENBECK proposed for this purpose the strangulation of the detached iris in the wound of the cornea; while ASSALINI cut off the prolapsed portion, after dragging it through the cornea.

LANGENBECK'S *operation.**—This plan of detaching the iris (*iridodialysis*) by means of instruments introduced through a wound of the cornea, and then strangulating the detached portion in the aperture had been called *iridencleisis*, from ιρις, and εγκλειω, to lock in, or confine. It consists in making an opening in the cornea; in detaching the iris by means of a hook, or some other instrument introduced into the anterior chamber through that wound; in drawing the detached portion through the corneal wound, and leaving it there as a prolapsus, so that it may become permanently fixed to the cornea, and thus prevent the subsequent closure of the new pupil.

through the adventitious membrane by which the pupil was closed. Ophthalmologische Bibliothek, vol. iii., st. 2, p. 160.

* Neue Chir. Bibl., vol. i. p. 224—240.

Fig. 79.

The first step in the operation, that of making a small opening in the cornea, may be conveniently accomplished by means of BEER's cataract knife [or JÆGER's keratome, fig. 79]. This wound must be large enough to allow the passage of the hook; but it should not extend beyond that size; otherwise we shall not succeed in strangulating the iris. It may be one and a half or two lines.

The incision should be distant from the point at which the separation of the iris is to be effected, by one half the diameter of the cornea at least; some advise that the distance should be three-fifths of the diameter. If the wound of the cornea should be nearer to the new pupil, its cicatrix may interfere with the transmission of light through the aperture; if it be further, too large a detachment of the iris will be necessary, and the extent of injury to the organ will be thus increased without any object.

The situation at which the detachment of the iris is to be effected, will determine the place and direction of the small opening of the cornea. If the new pupil is to be made on the nasal or temporal side of the eye [fig. 80], the cornea must be opened in its middle by a vertical incision; if at the upper [fig. 81], or lower part, [fig. 82,] the incision must be horizontal, and a little above or

Fig. 80.

Fig. 81.

Fig. 82.

below the middle. If the circumstances should require it, the incision may be made in a leucomatous portion of the cornea.

[If any circumstance, as adhesion of the iris to the cornea at its centre, will not allow of the cornea being opened in the middle, the opening may be made either above, fig. 83, or below, fig. 84.]

Fig. 83.

Fig. 84.

The point of the knife directed at a right angle to the surface of the cornea must be carried through it into the anterior chamber: the handle must then be depressed, so as to bring the blade into a direction nearly parallel to the surface of the iris, in which it is to be pushed on until an opening is formed of the size already mentioned. The point of the knife should then be moved a little towards each angle of the wound, so as to make the division of the internal laminæ equal in extent to that of the external. The instrument should then be withdrawn quickly, so as to prevent the escape of the aqueous humor.

A great variety of contrivances have been employed for the purpose of seizing and detaching the iris. On this subject, JUENGKEN has sensibly observed, "that amidst the multitude of instruments invented, modified, and changed, often very ingeniously, for the purpose of iridodialysis, the most

important point has been overlooked, namely, that for holding the iris securely; the kind of instrument is of less consequence than the place at which the part is seized. I confess that, until instructed by repeated experience, I had not sufficiently appreciated this circumstance. The texture of the iris is very different at its pupillary and ciliary margins. In the former it is fine, delicate, and so soft that instruments easily tear out without separating the iris from the ciliary ligament. In the latter it is of firmer texture, so that the finest instruments will hold when fixed in it; and the nearer we come to the margin, the more easy is the detachment.

When the lens and its capsule are in the normal state, we run the less risk of injuring them the nearer we fix the instrument to the ciliary ligament, because the vitreous humor is behind the latter part, and not the crystaline capsule. Hence, for performing iridodialysis that instrument is best suited with which we can come nearest to the circumference of the iris, so as to seize it close to the ciliary ligament; and no one can deny that a simple fine hook [fig. 85] is the best for this purpose. If, however, the iris should have become changed in texture, and soft throughout, no kind of hook will answer the purpose, whether single, double or covered; our resource, then, is to seize the iris with forceps, and thus effect the detachment. It has been objected to the simple hook, that its point may pass between the corneal laminæ and become entangled. This may equally happen with any other instrument, if attention is not paid to the direction in which it is carried through the wound of the cornea. It is a great mistake to suppose that the performance of iridodialysis is more difficult with the simple hook than with other instruments: on the contrary it is more easy, when the mode of employing it is well understood." (*Die Lehre von den Augenoperationen*, p. 656, 657.)

Fig. 85.

The hook must be carried through the wound of the cornea at

Fig. 86.

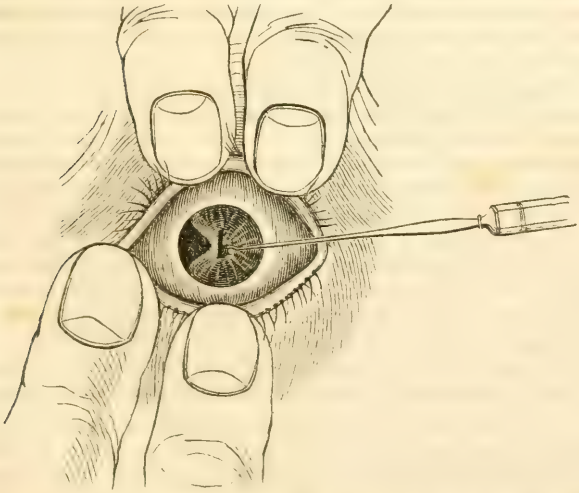

right angles, like the knife, the convexity of the curve going first, and the point following. when it has entered the anterior chamber, the handle

should be depressed, so that the hook may lie flat between the cornea and iris, with its point downwards, and in this direction it must be carried on to the very margin of the iris, when it will be nearly concealed by the edge of the sclerotica. It must now be turned, so that the point may be directed against the iris: it may then be fixed by gentle pressure, and afterwards drawn a little back, so that the hooked portion of the iris may be safely placed in the concavity of the instrument. When we find that the iris is securely seized, the hook must be turned flat again; but with its point directed upwards, that the iris may not slip off. The point should indeed be directed a little towards the cornea, to avoid the lens, if it be present. We now detach the iris by drawing the hook backwards through the wound of the cornea very slowly and carefully, [fig. 86.] In carrying it out of the eye we must give the instrument the same direction as that in which it entered. The convexity of the hook must be drawn out through the inferior angle of the wound, and the point will then pass without any risk of catching in the wound. Having conveyed the hook with the iris safely through the wound, we continue to draw it gently in the same direction, until we have got an artificial pupil of sufficient size. We now cease to draw the iris, and observe whether it remains fixed in the wound of the cornea. If it does so, we detach the hook and the operation is finished.

Fig. 87.

The new pupil becomes filled with blood, which begins to flow when the detachment of the iris commences, and soon occupies the whole anterior chamber. The cases are rare in which the effusion is inconsiderable, and still more uncommon where it does not occur at all. This hemorrhage, which proceeds from the external arterial circle of the iris formed by the primary branches of the long ciliary arteries, has no unfavorable influence on the result of the operation. The blood, as in other effusions into the anterior chamber from accidental violence,* is removed by absorption in a few days.

Reisinger's *double hook, or hooked forceps, for detachment of the iris.*—The iris is sometimes torn by the hook, instead of being detached. To avoid this inconvenience, Dr. Reisinger,† of Landshut, devised an instrument formed of two branches united like those of forceps, [fig. 87, *a.*] Each of these terminates in a small hook, [as seen in the side view of one of the branches, fig. 87, *b.*] When the branches are pressed together, the two hooks, having the same size and direction, lie close together, so as to form a single hook: when the pressure is discontinued, they separate again. This instrument, with its branches approximated, so as to form a single hook, is carried through the wound of the cornea, into the anterior chamber, and pushed

* See p. 149, 150. In a case where the iris had been thickened by inflammation, Dr. Ryan made an artificial pupil by incision, according to the method of Sir W. Adams. The anterior chamber became obscured by an effusion of blood, which was completely absorbed on the third day.—*Dublin Hospital Reports*, vol. ii. p. 364. The anterior chamber became filled with blood in another instance, after the operation of incision. The effused blood was completely absorbed in twenty hours. *Ibid.*, p. 368.

† Darstellung eines neuen Verfahrens, die Mastdarmfistel zu unterbinden, und einer leichten und sichern Methode künstliche Pupillen zu bilden. Augsburg, 1816.

on like the simple hook to the ciliary ligament. It is now partially turned, so as to direct its point against the iris, when the discontinuance of the pressure on the branches allows the two hooks to separate: they are then fixed in the iris in the same way as when the simple hook is employed. The branches, being again pressed together, hold the portion of iris included between the two hooks in the manner of forceps, while the hooks fixed in its substance render the hold still more secure. The instrument is now to be turned so as to lie flat against the cornea, with the convexity downwards and the points upwards; it is then to be carried back through the wound steadily and gently, so as to effect a sufficient detachment of the iris.

On this double hook, or hooked forceps of Reisinger, Professor Rosas* makes the following remarks:—"Nobody, who has tried this plan, can have failed to observe, that the use of the double hook is attended with greater difficulties, and yet presents fewer advantages, than the simple hook of Langenbeck. That the iris may be securely seized and detached, the points of the instrument must be turned directly backwards, so that the iris cannot be hooked near enough to its circumference, and the lens is generally seized at the same time. These inconveniences are avoided with the single hook, which can be entered obliquely into the ciliary margin of the iris. The instrument, strictly speaking, does not act as a double but only as a single hook, for when its branches are opened, they will be found to have separated the fibres of the iris, so that there is a mere empty space between them. In unsteady patients there will be a greater danger of the instrument becoming entangled, or the iris escaping, than with the simple instrument. We cannot rely on its action as forceps in giving a firmer hold of the iris."

Unless the opening in the cornea be carefully made, and similar attention be paid to the other steps of the operation, the fine hook employed for seizing and detaching the iris may become entangled in the sides of the wound, or within the anterior chamber. To obviate this risk, various complicated instruments† have been devised with contrivances for covering the point of the hook, or at least placing it in such a situation as to prevent it from catching in the parts along which it passes. I agree with Juengken‡ and Rosas,§ in preferring the simple hook to any of these complicated instruments.

Operation by separation and excision.—When the iris cannot be strangulated in the wound of the cornea, either in consequence of the opening being too large, or of the iris having been rendered incapable of extension by disease, the portion which has been drawn out of the anterior chamber may be cut off with scissors. This operation, in which excision is united with separation, has been called *Iridectomedialysis*. Assalini,‖ who first

* Handbuch der theoretischen und praktischen Augenheilkunde, vol. iii. § 429.

† These instruments have been designated by the names *coreoncion*, or *coroncion*, (from κορη, pupil, and ογκος, hook,) also *iridoncion*. Langenbeck first employed one of the kind; see his Beschreibung eines von mir erfundenen Instrumentes, die Coretodialysis zu verrichten, in the Neue Chir. Bibl., vol. i. p. 454 and 676. The instrument employed by Graefe is described by Juengken, in Das Coreoncion, ein Beitrag zur künstlichen Pupillenbildung; Berlin, 1807. See also Schlagintweit, Ueber den gegenwärtigen Zustand der künstlichen Pupillenbildung in Deutschland; Munich, 1818; in which he describes, under the name of Iridankistron, an instrument very similar to the coreoncion of Graefe. Wagner, de Coremorphosi. Dzondi, Geschichte des klinischen Instituts zu Halle, 1818, and Beschreibung eines neuen Instrumentes, &c.; Halle, 1819. The instrument proposed by Embden, in his Diss. de Raphiankistro, &c., Göttingen, 1819, is a combination of a hook with a lancet-shaped needle. The former, which lies close on the latter, can be protruded and withdrawn again.

‡ Lehre von den Augenoperationen, p. 656.

§ Lib. cit., p. 365, note.

‖ Ricerche sulle Pupille artificiali. Milan, 1811.

employed it, used a small forceps of peculiar construction for seizing and detaching the iris, introducing the instrument into the anterior chamber through an opening previously made in the cornea. The simple hook, which can be employed with a smaller division of the latter part, is preferable.

"Although," says Professor Rosas, "I do not approve Assalini's method of operating, I think that iridectomedialysis, when performed in a proper way, possesses advantages both over simple detachment, (*iridodialysis*,) and over detachment with strangulation (*iridencleisis*). The operation is performed more quickly, not requiring, as the latter operation does, a small and oblique wound of the cornea, nor being attended with falling back and repeated dragging out of the iris. Closure of the newly-formed pupil is less likely. Inflammation and suppuration, or effusion of lymph, occur more rarely than in the other modes of iridodialysis. The wound heals more quickly, and the corneal cicatrix is less extensive and conspicuous than in iridencleisis. These advantages have led me to employ the operation for many years, in the manner recommended by Langenbeck, for cases in which the detached portion of iris cannot be strangulated in the cornea. Still I am of opinion, that its advantages are not equal to those of Maunoir's plan of incision, or excision, as practised by Wenzel and Beer; and, therefore, that its employment must be restricted to cases in which these methods are not applicable. Such are obstructions of the pupil by central leucoma of the cornea, by accumulation of lymph in and about the aperture, and by a universally adherent cataract. The following are the considerations which make me think the operations last mentioned more advantageous than the iridectomedialysis.

1. The lacerated wound inflicted in this operation, as in all kinds of iridodialysis, is a much more serious injury than the simple cut of incision or excision. 2. The lens is more endangered than in iridectome, so that often we have to treat subsequently a cataract caused by the operation. 3. Inflammation, suppuration, and effusion of lymph are much more frequent after this operation. 4. The cure is more tedious; since the separation is generally followed by copious effusion of blood into the anterior chamber, the removal of which by absorption occupies some time, during which it impedes vision. 5. The marginal pupil, formed by iridodialysis, is much less useful than one produced by incision or excision in the centre of the iris, or near it; since the rays of light falling on the margin of the cornea are much less serviceable for vision than those which go through its middle. Moreover, the ciliary processes projecting into the posterior chamber, occupy a part of the opening, so that, although the patient is obliged to squint, vision is still very feeble. 6. Iridodialysis can never be performed with advantage where the patient still sees with one eye. 7. For the reasons already given, vision is less lasting than after the other methods. (*Handbuch*, vol. iii. § 431—433.)

The operation by separation may be performed in all the cases requiring the formation of an artificial pupil, to which neither incision nor excision is applicable; and in those, where another operation having been previously performed, the opening has since closed; in central leucoma covering more than half the diameter of the cornea with general synechia anterior; in opacities with partial adhesion, where the transparent portion of cornea is so situated as not to allow of excision.

The combination of excision with detachment is often preferable to the operation of iridencleisis. The former must be adopted where strangulation cannot be effected; also in large synechia anterior, or partial staphyloma, where only a third or fourth part of the iris remains free. It is a preferable

method where we expect the operation to be followed by considerable inflammation, as we avoid the irritation which might be expected from pressure on the prolapsed iris. When we intend originally to perform iridectomedialysis, the opening in the cornea should be rather larger than the operation of iridencleisis. This opening is made in the opaque part, when the case is synechia anterior, occupying half or two-thirds of the cornea. We may be able to direct the knife in such a way as to detach partially the adherent iris, and thus make way for the passage of the hook into the anterior chamber: otherwise, on opening the leucomatous cornea in the adhesion, we penetrate the posterior chamber; the hook must then be introduced behind the iris, and carried through the membrane from behind forwards, for the purpose of detaching it. Great caution will then be necessary to prevent the point of the hook from becoming entangled in the cornea. When the detachment has been effected, the iris should not be dragged through the wound until the operator has the scissors ready close to the eye for cutting it off immediately. In this and many other cases, where the surgeon must employ both his hands in the manœuvres of the operation, the care of the eyelids must be confided to an assistant.

The operation for artificial pupil is simplified when the lens has been previously removed from the eye. In the majority of instances, however, it is still present, either transparent or opaque. It is important, in the former case, to adopt a mode of proceeding, in which no injury shall be offered to the lens or its capsule. This object is secured in the operation of excision according to the method of Gibson, and in the use of Mr. Tyrrell's blunt hook. Incision of the iris, with the scissors of Maunoir, blunt at both ends, is not quite so safe: and detachment through the cornea (coredialysis) is still more dangerous. If there be cataract, it will be advantageous to adopt a mode of operating, when circumstances will admit, by which the lens may be removed from the axis of vision at the same time that the new pupil is formed. This may be accomplished by the operation of Wenzel, and by Maunoir's method of incision. The lens might be depressed, or broken up and left for absorption, in Sir Wm. Adams' mode of incision. It is, however, dangerous to add this violence to the injury which the organ necessarily sustains in the formation of an artificial pupil. In such cases, therefore, as well as in others where cataract is present, it will perhaps be safest to leave the opaque lens in its situation, from which it may be removed afterwards by depression or absorption.

[THE OPERATION BY DISTORTION OF THE NATURAL PUPIL.

It has been observed, (p. 436,) that there are three principal methods of operating for artificial pupil, viz., by *incision*, *excision*, and *separation*. In one case we have operated by a proceeding which cannot be strictly referred to either of these, and by which the natural pupil is drawn aside or distorted, without any incision, excision, or separation of the iris.

The subject of the case was a young man named John Kane, who had both eyes injured whilst engaged in blasting rocks, in March, 1840. In August of that year, he was admitted into Wills' Hospital with central opacity of both corneæ, adhesion of the upper edge of the iris to the cornea of the right eye; and the pupil of the left eye closed by a mass of lymph. He was submitted to the usual treatment for the removal of the opacity of the cornea, and of the lymph from pupil, and the former was so much lessened by the following spring that it was believed useful vision might be obtained with the left eye, if the opaque matters which

closed the pupil were removed. Extract of belladonna around the eye, and mercury given to salivation having failed to accomplish this, Dr. Fox with a needle inserted in the sclerotica broke up the lymph and lens, and after twice repeating the same operation, the pupil was cleared and the patient discharged with his sight much improved. In the fall of 1841, he applied to be again admitted into the hospital, stating that though his sight was much improved, it was not good enough to enable him to work at his ordinary labor, and begged that something further might be done. I did not feel justified in attempting any operation upon the left eye, as it would involve a risk of destroying what had been gained, which the chance for further improvement did not justify.

Fig. 88.

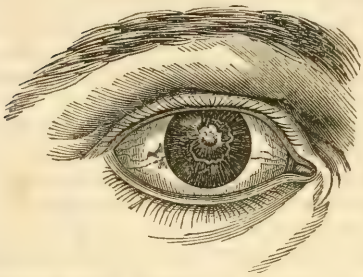

The right eye was, however, in a different condition. The lens was transparent and the pupil clear; and whilst there was dense opacity of the centre of the cornea, the lower portion was perfectly clear, excepting a few very minute points where it had been burned by grains of gunpowder. The upper edge of the pupil adhered, as already stated, to the cornea. (See fig. 88.)

The pupil could be slightly dilated with belladonna so as somewhat to improve the sight, but not sufficiently to enable the patient to see even as well with it as he could with the other eye. In consultation with my colleagues, I therefore determined to attempt an operation for his relief.

The one which first suggested itself, as best suited to this case, was that of Gibson; but the risk of wounding the anterior capsule of the lens with the hook, and also the danger of effusion of lymph from the margin of the incision of the iris, rendering the capsule opaque, and closing perhaps the new pupil, presented objections to it. Reflecting on the general occurrence of prolapse of the iris in wounds of the cornea with consequent synechia anterior and drawing aside the pupil, (see fig. 61,) and that if the pupil were thus drawn towards the lower margin of the cornea by a simple wound of this coat, everything that could be desired would be attained, and at little risk; I decided to operate in conformity with these views.

This I accordingly did on the 28th October, 1841, in the presence of my colleagues, Drs. Littell, Fox and Parrish, the house surgeon Dr. S. L. Hollingsworth, and Drs. Pepper, Neill, &c. The patient being laid on his back on a table, the lower lid of his right eye was depressed by Dr. Fox, whilst I raised the upper lid with the two fore fingers of my left hand, steadying the ball with the third finger. I then with a properly constructed cataract knife incised the cornea near its junction with the sclerotica, commencing a little below the middle and extending so as to divide nearly one-fourth of the circumference of the cornea. The knife was carried steadily and rather quickly forward, to prevent the escape of aqueous humor before the completion of the incision, as its sudden discharge would favor the prolapse of the iris. The moment the incision was completed the knife was withdrawn; at the same instant the aqueous humor was evacuated at a gush; and the lids were allowed to close. The gush was even greater than I had hoped for, so much so, that at first

I supposed some pressure must have been made on the eye, which was not, however, the case. After the lapse of a minute or two, the lids were separated and the iris found prolapsed so as to draw the lower edge of the pupil quite to the incision. I felt satisfied that the iris would adhere to the cornea at the wound forming at this point, synechia anterior, and determined, contrary to the opinion of all present, to trust to this taking place. The patient was placed in a dark room, and put upon a restricted diet. The result justified my confidence; adhesion formed, no inflammation occurred, the patient was soon able to bear the light; his vision improved, and Kane now enjoys excellent vision, sufficiently so to make a livelihood. The accompanying figure (fig. 89) represents the form of the artificial pupil.

Fig. 89.

I had intended, should the iris not have been prolapsed spontaneously, to draw it out with a small blunt hook which I had prepared by bending a small Anel's probe, (see fig. 90;) and such an instrument will be occasionally required.* But I believe that in the large majority of cases, if the knife used be a good one, and the incision properly made, that the iris will either be forced out by the gush of aqueous humor, or prolapse soon afterwards from the pressure of the humors.

Fig. 90.

This operation is suitable to a number of cases, and in such it possesses advantages over those usually resorted to.

Since this operation was first described by me (*American Journal of the Medical Sciences*, Oct. 1842), I have found that it had previously been done by others, though by a somewhat different method. Sir William Adams performed it in 1811, (*Practical Observations on Ectropium*, London, 1814, p. 96.) He operated by opening the cornea with his closed pupil knife, and effected the protrusion of the iris by pressing on the ball with the speculum. Himly has also performed it by opening the cornea, and dragging out the iris with a small hook. (*Bibliothek fur Ophthalmologie*, 1 B. 1 st., s. 175. Hanover, 1816, as quoted in Weller's "*Die Krankheiten des Menschlichen Auges*," translated into French by Riester, Paris, 1832. Vol. i. p. 386.)

Still more recently, it has been performed by M. Guepin, a distinguished surgeon of Nantz, and by a still different method. After opening the cornea with a narrow-bladed knife, he cuts a piece out of the flap of the cornea, either a triangular portion with a scissors, or, what he prefers, a circular piece with a small punch. (*Dict. de Méd.*, tom. xxvi. p. 388, Paris, 1842.)

We must confess that we prefer our method, and therefore advise its adoption in suitable cases.]

Formation of an artificial pupil in the sclerotica.—When the entire cornea has been rendered irremediably opaque by leucoma, Autenrieth proposed to attempt the formation of an artificial pupil in the sclerotica: that

[* I have since employed it in several operations for artificial pupil, in which the iris had lost its natural extensibility from deposit of lymph in its texture, and found it exceedingly useful.]

is, to remove a portion of the sclerotic and choroid coats, near the edge of the cornea, and thus expose the vitreous humor, in the hope that the wound might be covered by a transparent pellicle, through which light enough might pass into the eye for imperfect vision. After experiments on animals, AUTENRIETH tried it on the human subject.* The operation (which has been called *scleroticectome*) has been performed without an useful result by BEER† and Mr. GUTHRIE.‡ Professor AMMON§ has given a history of all that has been done and written on the subject, and has detailed three cases in which he tried the proceeding. The operation has also been performed by Dr. ULLMANN,‖ of Marburg. No advantage seems to have been gained in any of these operations.

CHAPTER XIX.

AFFECTIONS OF THE CHOROID COAT, RETINA, VITREOUS HUMOR, LENS, AND CAPSULE.

SECTION I.—AFFECTIONS OF THE CHOROID COAT.

WE have seen, in a previous chapter, that inflammation commencing in the iris will extend, sooner or later, to the other internal structures, and that it may ultimately affect the whole organ. The posterior tunics, particularly the choroid and retina, may be primarily inflamed: the disease may be confined, for a longer or a shorter period, to its original seat; or it may spread to the contiguous and connected structures, and to the iris.

As the choroid and retina are out of sight, and their diseases do not terminate fatally, we have not the same direct and clear evidence respecting the seat and nature of the malady in choroiditis and retinitis as in iritis. This deficiency is more sensibly felt in the case of the choroid than of the retina. From its high vascular organization, we should confidently expect that it would be frequently the seat of congestion or inflammation; and it probably may be so. But direct proof is wanting. The opaque sclerotica completely conceals it; and its disorders are not manifested by peculiar functional symptoms, as in the case of the retina. The latter membrane indeed, from its close vicinity, must suffer when the circulation of the choroid is deranged; impaired vision will be one of the most important evidences of such disturbance; and hence it may often be difficult to distinguish between the diseases of the two tunics.

Mr. MACKENZIE published some remarks on inflammation of the choroid in the twelfth volume of the *London Medical Gazette*, p. 18; and he has considered the subject at greater length in the last edition of his

* L. SCHMIDT, Diss. de Pupilla artificiali in sclerotica aperienda; Tubingen, 1814.

† J. S. WEBER, Diss. inaug. sistens observationes quasdam in Coretodialysin et Pupillam in sclerotica aperiendam; Tubingen, 1817. ROSAS, Handbuch, vol. iii. p. 380. He mentions that the operation had been unsuccessfully performed by RIECKE, and quotes the authority of ROSNER, Diss. de Pupilla artificiali; Tubingen, 1823, p. 46—47.

‡ A Treatise on the operations for the Formation of an Artificial Pupil, p. 205.

§ Die Sclerectomie oder die künstliche Pupillenbildung in der Sclerotica nach eigenen Erfahrungen und Operations versuchen dargestellt. Zeitschrift, vol. i. p. 183.

‖ AMMON's Zeitschrift, vol. ii. p. 123.

Practical Treatise, Chapter XII. § 24, under the denomination of *sclerotico-choroiditis.*

He says that it is rare in children; that the subjects of it are usually adults, and more frequently females than males. There is no general external redness; but one or more of the arteries derived from the muscular branches are enlarged, and end in a broad lash of small vessels near the edge of the cornea. Under these vessels the sclerotica is thickened and altered in color. There is displacement of the pupil, the iris being drawn towards the affected portion of the choroid. The iris may be involved in the disease, or remain sound. Partial opacity of the cornea towards its edge is an occasional symptom. There is intolerance of light, lachrymation, impaired vision, with pain, sometimes slight, sometimes extremely severe.

Serious changes in the state of the eye may be produced by choroiditis; viz., staphyloma scleroticæ, effusion of fluid between the sclerotica and choroid, or between the latter and the retina, and general dropsical enlargement of the globe.

Mr. Mackenzie advises active antiphlogistic treatment in the beginning of the complaint, including profuse and repeated blood-letting, followed by free leeching. On mercury he places little reliance; but he strongly recommends the arseniate of potass, in small doses, beginning with the thirty-second part of a grain, in the form of pill, thrice daily. Under this remedy, he says, "I have had the satisfaction, in a number of instances, to observe the varicose vessels to shrink, the blueness to become whiter, the tumor of the sclerotica and choroid to fall, and the patient's health and vision to improve." He considers that the favorable effect on choroiditis of a remedy known to exert considerable influence on some obstinate cutaneous diseases, corroborates the analogy, in certain points of structure, between the choroid and the rete mucosum.

Mr. M. also advises puncture of the sclerotica and choroid, to evacuate fluid effused internally, in the chronic stage of the complaint.

Observation and reflection have induced Mr. Tyrrell to believe that disorders of the choroid coat are of frequent occurrence, and to assign to them an important place in the pathology of the eye. He gives the following enumeration of the affections, to which he considers that the tunic is liable. 1st. Partial distension of its vessels, disturbing the retina by pressure. 2d. Permanent partial preternatural dilatation or varicosity of its vessels, affecting the retina. 3d. Temporary congestion, affecting the vascular structure, generally or partially, and disturbing or destroying the power of the retina. 4th. Acute or chronic inflammation, extending to the iris and sclerotic by vascular connection, or affecting the deeper tunics and humors of the globe by morbid deposit. The latter is considered to be most frequently fibrine, more rarely serum. (Vol. ii. p. 13.)

To the three states first mentioned, Mr. T. refers the various forms of muscæ, whether temporary or permanent, with the partial imperfections of sight coming under the head of impaired vision. There is no direct evidence of morbid change in the circulation of the choroid; the symptoms are subjective, not objective.

Choroiditis is most frequently chronic, and preceded by muscæ or impaired vision, on which more serious imperfection of sight supervenes, generally as a mist, cloud, or network, gradually increasing, and terminating ultimately, but in general slowly, in blindness. The whole course of the affection is usually of very chronic character. In its progress, the iris becomes dull, and sluggish: the pupil is at first contracted, and then rather dilated. More considerable changes occur subsequently; alteration of color, thickening, and adhesion of the pupillary margin, with loss of trans-

parency in the crystaline capsule. Occasionally the iris is little altered. The only other external appearance is slight redness round the margin of the cornea. Staphyloma scleroticæ and effusion within the globe, are effects of the disorder.

Acute choroiditis, which generally supervenes on the chronic form of the affection, is characterized by dull throbbing pain, with sense of tension and tenderness of the globe; rapidly advancing imperfection of sight in the shape of dark gauze or mist, with gray or dark spots; dull redness of the eye from congestion in the vessels of the sclerotica, and changes in the iris and pupil. The affection extends to the retina and vitreous humor with irremediable blindness. Staphyloma scleroticæ may result, or the opposite condition of softness and flaccidity of the globe.

In a patient who had experienced repeated attacks of the disease, and had suffered for a long time, Mr. Tyrrell found after death the choroid coat of a fawn color, softened, and covered internally by a thin layer of fibrine; albuminous fluid effused between the choroid and retina; the latter membrane covered irregularly by a deposit of fibrine, thickened, opaque, thrown into folds, and preternaturally firm; the iris thickened, softened, and adherent; the vitreous humor of serous consistence.*

Mr. T. represents that choroiditis occurs usually in persons under the middle period of life, and that it is not uncommon in the infant. It is most frequent in those of scrofulous constitution; and more so in females than in males. He adds, that is is not common as a primary disease, either in the acute or chronic form.

From the intimate vascular connection between the iris and choroid, inflammation soon extends from the one to the other. Hence choroiditis may be easily confounded with iritis. In the former, disturbance of vision precedes the changes in the iris and sclerotic, and amaurosis is often nearly complete before increased action is apparent in the latter tunics. The changes in the iris are not in proportion to the loss of power in the retina. In iritis, extensive changes may occur in the iris, with increased redness of the sclerotica, and even of the conjunctiva, with but little imperfection of vision.

Mr. Tyrrell has found choroiditis to be connected with general debility in nineteen cases out of twenty. Hence he advises nutritious diet and tonic medicines, such as bark, the mineral acids, sarsaparilla, steel, in conjunction with small doses of mercury, using the latter more freely when the state of the iris and of vision indicates considerable and advancing disorganization. In the small number of instances, where increased fullness of the vascular system is present, loss of blood may be cautiously employed as a preliminary measure.

Mr. Tyrrell recommends that in the cases which he regards as examples of choroiditis, the use of mercury should be tried, even where complete amaurosis has existed for some time, provided the globe be in other respects healthy, the pupil generally or partially clear, and the age and power of the patient favorable. He adopted this course in a strong man, thirty-eight years of age, who had been amaurotic for seven years, and had lost the perception of light. The pupils were clear, but adherent at many points, the irides discolored and dull, and the patient had the vacant stare of a blind person. He was put under mercurial treatment with a nutritious diet: the free action of the remedy was maintained for sixteen weeks, with the daily discharge of a pint and a half of saliva. Belladonna was applied night and morning. The adhesions of the pupils gave way, and the openings regained their

* Ibid., p. 74. Various morbid conditions of the choroid are delineated by Von Ammon in his Klinische Darstellungen, pt. i. tab. 15, fig. 20—24; and tab. 16, fig. 8, 9, 10, 15, 16, 17; also in several figures of tab. 19.

natural figure; the natural color and brilliancy of the irides was restored; vision improved gradually, and became at last quite perfect.*

Von Ammon† has described inflammation of the orbiculus ciliaris, which, according to his description, closely resembles inflammation of the anterior chamber. Whether or no inflammation in any case commences in this part, is a question of observation and experience. We cannot doubt that disorder, if it should thus originate, would spread quickly, forwards and backwards, to the continuous membranes, so that the affection would become more general. I have seen partial elevation of the sclerotica, round the margin of the cornea, in conjunction with other symptoms of internal inflammation. This symptom has yielded, with others, to the usual treatment of such inflammations.

Deficiency of pigment.—As age advances, the quantity of pigment in the choroid is diminished, and the membrane at last becomes pale. Hence the pupil presents a gray appearance, so nearly resembling that of cataract, that on the first view we may mistake it for that disease. By looking at the pupil laterally we immediately discover that the lens is not opaque; and the unimpaired state of vision will prevent us from confounding the case with cataract. A greenish, or yellowish-green discoloration of the pupil is sometimes seen in elderly persons without imperfection of sight. The cause not yet ascertained, may be some change in the choroid, or in the transparent media.

SECTION II.—INFLAMMATION OF THE RETINA: RETINITIS.

This affection is not of uncommon occurrence, though the membrane is so completely concealed from our view, that we cannot speak of retinitis with the same confidence that we do of iritis. We often meet with cases, in which there can be no doubt that inflammation of the retina is the cause of the symptoms. Dimness of sight and pain in various degrees are the early symptoms: the pupil is at first contracted, and afterwards enlarged.

Rosas‡ rightly observes that the affection does not usually extend over the whole retina; he says that it is found, on examination after death, to be confined to the neighborhood of the yellow spot. He adds, that under favorable circumstances it often leaves behind a temporary or permanent weakness of sight, while in worse cases it leads to amaurotic blindness, from effusion of lymph, varicose change of structure, or even ossification of the retina, and adhesions of it to the neighboring parts. I have often seen it entirely removed by active treatment in the early stage, without any permanent injury to vision. The nature and treatment will be best illustrated by a few cases.

Case.—*Retinitis from exposure to heat and light.*—A young woman, of florid complexion and full habit, came to the London Ophthalmic Infirmary, complaining that she had lost the sight of one eye. She was cook in a family, and occupied for several hours daily before large fires, supporting her strength by free living. The pupil was slightly dilated, the iris motionless; a faint and scarcely perceptible pink tint was observed in the sclerotica near the cornea. Vision was dim and had been so for three days. There

* Ibid., p. 79.

† Rust's Magazine, vol. xxx. p. 240. Von Ammon has represented the external appearance of the eye in this inflammation, and the changes produced by the disease in the orbiculus ciliaris, in the Klinische Darstellungen, pt. i. tab. 8, fig. 4, 5, and 12.

‡ Handbuch, vol. ii. § 780.

were headache, flushed countenance, heat of skin, whitish tongue, and thirst. I considered the case to be pure retinitis, and to afford a favorable opportunity for showing whether the affection could be arrested by antiphlogistic treatment. At that time (now many years ago), I did not possess the knowledge of the powers of mercury in inflammation of the retina, which subsequent experience has given me. I directed a full bleeding from the arm, free purging, low diet, repose of the organ, and general rest. At the end of two days the sight was worse; cupping and blister were now ordered, but there was no improvement at the end of two days more. I now determined on trying mercury, and ordered two grains of calomel every four hours. Before the remedy had affected the system, vision was quite lost, or at least reduced to the mere power of distinguishing light from darkness. Full salivation, which took place in about a week from the first application of this patient at the Infirmary, suspended all the symptoms; sight immediately improved, and was soon completely restored.

Case.—*Retinitis from the same causes.*—A young woman, twenty-four years of age, came under my care in the spring of 1831. She was a cook, and employed much before fires; she ate meat twice a day, took two pints of ale daily, and sometimes gin and water. She had lately experienced headache, and now complained of dimness of sight, for which she had been bled and purged. The iris was slightly and partially discolored, and its pupillary margin adhered at two points to the capsule. The pupil was clear, sight was dim, so that she could not read. There was pain over the brow, and no external redness. I ordered abstraction of blood from the temple by cupping; two grains of calomel, with one-third of a grain of opium every eight hours. The mouth soon became sore, and vision improved. Plummer's pill, night and morning, was now substituted for the calomel and opium, so as to keep up a certain influence on the system. In three weeks the patient was able to return to her situation with perfect vision.

Case.—*Retinitis from a stroke of lightning.*—A young man of irritable habit, standing at a door under a lamp-iron, during a thunder-storm, on the 2d of August, 1832, was struck by lightning, fell backwards, and was convulsed for some minutes. He said that the lightning appeared to enter his eye with a scorching sensation. Mr. Wheble, of Waltham Abbey, who saw him, and had charge of the case, bled him from the arm with great relief. Another flash of lightning produced a slighter attack; but the sight returned. During the night vision was completely lost. On Friday morning there was no redness, nor any unusual appearance of the eye; the iris was motionless, and the patient could not even see the sun. He could, however, open the lids, and move the eye. A blister was applied to the back of the neck, and three grains of calomel, with some Dover's powder, were given night and morning; in two days, the calomel was given every four hours. The lids became spasmodically closed, and the patient could neither open them nor move the eye. On Thursday, the 9th of August, he suddenly jumped up from a sofa on which he had been sleeping, with a most violent pain, similar to that of the first attack. This lasted about five minutes. Similar paroxysms occurred every five or ten minutes for two hours, when he suddenly opened the eye, and saw light. Most intense pain, similar to that experienced at the time of the accident, now came on, and he writhed in agony. Light was intolerable, even though the eyes were carefully covered. The pain went off in the night, and sight returned. It has gradually improved, but is still (August 28) very weak, so that he cannot use the eyes at all, without the protection of blue glasses.

Case.—*Retinitis caused by lightning.*—An interesting case of retinitis,

with temporary loss of sight, caused by lightning, is recorded in the second volume of the *London Medical Gazette*, p. 58, 59. JANE HUMPHREYS, eleven years old, was standing, on the 6th of May, 1828, in a school-room, with her left side toward the window, when a storm came on, and the room was strongly lighted up by a flash of lightning, which produced instantaneous loss of sight in the left eye, with tingling pain in the globe. As the pain increased during the following days, Mr. MAYO was sent for. Repeated leechings on the temples, blisters behind the ear and on the back of the neck, and mercury, so as to affect the mouth, were employed by his directions: under this treatment there was visible daily progress towards recovery.

The symptoms on the 11th of May were sense of heat in the eyeball, and tenderness on pressure; inability to raise the upper lid; extreme sensibility to light, when the eyelids were held open; vision almost extinct. There was no increased redness, nor any change in the transparent media. Pain and tightness across the forehead; throbbing in the head; white tongue; frequent pulse.

May 20th. Objects could be distinguished; total want of power to raise the upper lid; she could bear the light when the lids were opened.

24th. The power of the levator palpebræ superioris was restored.

27th. Although the left eye appeared sound, and was used habitually with the other, it was weaker than before, and somewhat painful when exercised. She could read ordinary print with it when held near to the eye, or distinguish a pin and pick it up from the ground; but the faculty of distinguishing colors was lost. In a yellow silk handkerchief, spotted with scarlet, she could point out the spots; but they appeared to her black, and the ground less black. She described white paper as a shade of black, and the leaves and petals of a rose as a deeper shade.

CASE.—ELIZA RADLEY, sixteen years of age, with light hair and eyes, was admitted into St. Bartholomew's under my care, on the 1st of August, 1826. The left eye is kept half closed, but she can raise the upper lid. When brought to the window for examination of the complaint, she closes both eyes, apparently experiencing a painful impression from the light. The retina of the left eye is totally insensible, so that she could not distinguish the situation of the window when brought near it. There is slight redness of the sclerotica. The pupil, like that of the other eye, is rather contracted, but the irides move naturally. There is considerable pain in the head, and a dull expression of countenance. Opening medicine has been taken, and the tongue is clean. She first noticed the defect of sight four days ago, when it was attended with headache: both symptoms have increased to the present time. The sight was previously good. (Sixteen ounces of blood by cupping from the back of the neck.) 2d. Opening medicine; afterwards two grs. of calomel, with one-third of a grain of opium every six hours. 4th. Sight was improved yesterday, and is now restored; (continue the medicine.) 8th. The calomel and opium were left off yesterday; the mouth had not been affected. She is discharged quite well, the left eye opening freely, and the countenance much improved.

CASE.—GEORGE WINSTON, aged twenty-seven, a carman, and accustomed to drink freely, went to bed well on the 29th of July, 1826. Towards three in the morning he felt great pain in the right eye, and he found himself blind with that eye when he got up on the 30th. When he came to St. Bartholomew's Hospital on the 1st of August, there was slight redness of the sclerotica; the size and motions of the pupil were nearly as in the other eye. The access of light was painful, and he could not read large print. There was headache; pulse 84 and soft; bowels confined. (Venesection

and opening medicine immediately; then calomel and opium every six hours.) 2d. Thirty ounces of blood were taken, when fainting ensued. Sight much improved; pulse more full and strong; (cupping to 16 oz.) Aug. 4. Mouth sore, and sight perfectly recovered. In three or four days more he left the hospital.

The following case, which was completely relieved by antiphlogistic treatment, is interesting, because the appearances of constitutional debility, combined with the failure of power in the retina, might have been regarded as indicating the propriety of tonics and stimulants.

Case.—*Retinitis from over-exertion of the eye.*—M. Gibbs, twenty-three years of age, tall, with pallid countenance, and the appearance of general feebleness, found the sight of the left eye become dim, after complete confinement within doors, and close attention to needle-work. The occurrence was preceded by dizziness, and attended by headache and severe pain in and around the orbit. Leeches were applied a few times, to the amount of eighteen, and a blister behind the ear; she was also put under a gentle mercurial course till her mouth became rather sore. She continued to use the eye, which grew worse, and the vision of the right began also to suffer. She therefore came under my care at St. Bartholomew's on the 26th of August, 1830. At this time there were a few red vessels in the sclerotica of the left eye, giving it a pink hue. The pupil was of the same size as in the other eye, and the iris acted feebly. She could barely distinguish light from darkness. There was frequent headache, with deep-seated pain in the orbit, especially at night. The right eye was dim, so that she could not read small print. She has not menstruated for the last two months, and has been quite irregular since the eye was first affected, now four months. (Cupping behind the ears to 12 oz. Pil. hydrarg. gr. v manè et vesperè quotidie.) 31st. Less headache and pain; vision not improved. (Pil. ferri c. myrrha gr. x omni nocte.) September 1. Cupping on the temples to 12 oz. 5th. Vision of the right eye nearly perfect, that of the left improved; the redness of the sclerotica has disappeared. (A blister between the shoulders, to be dressed with savine cerate.) On the 11th, she was attacked with partial inflammation of the left pleura, which required leeching, cupping, and antimonial medicines. 20th. The pleuritic attack has subsided, and the pain of the side has disappeared; she is considerably reduced by the treatment. The headache and orbital pain are gone, and the vision of the left eye is perfect, so that she reads the smallest print with facility.

[*Acute retinitis caused by the use of the microscope.*—A very interesting example of this was communicated to the Royal Medico-Chirurgical Society, (June 18, 1844,) by Mr. W. W. Cooper. The patient was engaged in dissecting the nerves of the human tongue under a powerful microscope; the nerves, having been cleanly dissected, were of a dazzling white, and whilst he was intently regarding them through the microscope, the sun, which had previously been obscured, suddenly shone forth with all its brilliancy upon them. Acute pain was instantly felt in the eye, pervading the whole globe. In about twenty minutes the pain subsided, though all uneasiness did not cease until evening.

The following day, the eye not being painful, the patient incautiously used it to complete his dissection, when the same occurrence took place as on the preceding day. This was followed by great and deep-seated pain, pervading the whole globe, with much intolerance of light, &c. Under the use of leeches to the eye, followed by frictions with mercurial ointment and opium, mercury and cicuta and other appropriate remedies, entire recovery took place.—*London Med. Gaz.*, July, 1844.]

A considerable portion of the cases included under the head of *amaurosis*

are affections of the retina; states of congestion, chronic inflammation, or functional disorder. This subject will be considered separately. Medullary or fungoid disease of the retina will be spoken of under "Malignant Diseases of the Eye."

SECTION III.—INFLAMMATION OF THE INTERNAL TUNICS GENERALLY.

Internal ophthalmia. Ophthalmitis interna idiopathica, BEER. *Ophthalmitis posterior totalis*, ROSAS.—Pain in the organ and impaired vision are the principal characteristics; there is but little external redness in the early stage, and often there is not much throughout the affection. The pain is deep-seated, of a dull aching kind, with a sense of pressure and tension, and often with a feeling of heat; it increases in intensity, and is aggravated by exposure to light, by using the eye, or by circumstances that excite the circulation, or produce determination towards the head. It extends from the globe to the orbit, and soon spreads to the brow, the occiput, the side of the head, or the head generally. Dimness of sight comes on with the pain, and in severe cases sight is sometimes speedily extinguished. At this period the external appearances of disease are not considerable; there is a little redness of the sclerotica round the cornea. The pupil may be either contracted, the iris moving quickly, or the latter may be sluggish, and the former rather dilated. The first is the earlier stage, denoting excitement of the retina, while the latter circumstances indicate more advanced affection, with impaired sensibility of the nervous structure.

The patient is feverish; there are heat of skin, thirst, white tongue, disturbed circulation, and restlessness.

With the continuance of the complaint, the inflammatory symptoms are more developed and obvious. The sclerotic redness increases, and forms a bright red zone round the cornea. The iris changes color and expands, the pupil contracting towards the centre, losing its clear blackness, and becoming filled with a web of lymph, effused from the thickened margin. The sight becomes more and more imperfect, and is soon lost. This happens from the inflammatory excitement and consequent change in the retina; it takes place before the entrance of light is mechanically impeded by the changes in the pupil. After vision is entirely lost, sparks, flashes, and various luminous appearances may still be perceived, and even be troublesome to the patient.

In the second stage, with increased external redness, pain, headache, and fever, the pupil closes, sight having been previously lost. The iris becomes convex, being pushed forwards towards the cornea, so as to diminish or destroy the anterior chamber. Suppuration occurs, matter is effused in front of the iris, constituting hypopyon; blood is sometimes mixed with it. Now the internal and external tunics are fully involved, and the appearances are those of general ophthalmitis.

The results of such an affection are, closed pupil with the formation of an adventitious membrane, insensibility of the retina from change of structure consequent on violent inflammation, contraction and partial obstruction of the pupil, the function of the retina being impaired, the capsule and lens opaque. Resolution may occur, with vision more or less impaired, or with complete recovery of sight.

The complaint is seen both in the acute and chronic form. The latter is the most frequent, and a long time often elapses between the early symptoms of muscæ with slight dimness, and the occurrence of blindness.

Prognosis.—When disease attacks the nervous structure, in which vision

immediately resides, and the pupillary aperture through which light enters the organ, the case cannot be otherwise than serious, requiring that the history and causes of the complaint, the state of the organ, and the condition of the constitution, should be investigated with great care.

The prospect is favorable in the beginning, and is less and less so, in proportion as time elapses. The state of the retina, as indicated by the degree of vision, and the condition of the iris and pupil, are the most important criteria. Greatly impaired vision, produced quickly, with pupil still clear, and not much contracted, may be restored. If sight should have been totally lost, before the pupil has closed; or if that opening be much contracted, and vision gone, there is no hope. The loss of vision is not altogether discouraging in itself, but it is a bad sign when connected with considerable change in the iris and pupil, and great external redness.

The prospect is more favorable when the complaint owes its origin to obvious external agencies, such as excessive and imprudent exertion of the organ, than when it is referable to constitutional causes; also, in persons of good constitution and health, than in those naturally delicate, or whose health is already impaired.

The *treatment* is the same as in iritis; it must be antiphlogistic in the first instance, unless reduced constitutional power should forbid direct depletion; and this must be followed up by the use of mercury, combined with the local employment of belladonna.

It might be expected that antiphlogistic measures alone would answer the purpose; but this is not the case; they check the disease, they diminish the external redness, the pain and headache, and relieve the patient altogether, but they do not improve the sight much; they do not control that excited state of the capillary circulation which threatens such dangerous results to vision. Mercury is equally powerful in checking this, when it occurs in the retina, as in the iris, and the object cannot be accomplished without this remedy, nor, in many cases, without its decided action on the system. The beneficial results from the combined action of the antiphlogistic and mercurial plans are often truly surprising. It has so often happened to me to see depletion, even when carried to the largest extent, fail, and vision immediately benefited, and soon restored by the employment of mercury, that on this point I speak with the greatest confidence.

INTERNAL INFLAMMATION OF THE EYE CONSEQUENT ON FEVER.

In the fourteenth volume of the *Medico-Chirurgical Transactions*, p. 286, there is "*An essay on a peculiar inflammatory disease of the eye, and on its mode of treatment*," by Mr. Wallace, of Dublin, in which he describes what he calls a most obstinate and dangerous form of inflammation of the eye, frequently observed among those who had labored under fever. He observes that "the complaint in question strongly resembles venereal iritis, not only in the appearance of the diseased organ, but also in the character of the patient's countenance. The eyelids are half closed, reddish, and swoln; the vascularity of the sclerotica and conjunctiva being greatly increased, with a peculiar dark brick red color. The iris is altered in color, generally greenish, and incapable of motion; the pupil contracted, with its edge thickened and irregular. The cornea is dim, with an appearance like that of glass which has been breathed upon. There is often a turbidness of the aqueous humor: and a pearly appearance of the parts behind the iris may be observed by looking through the pupil. There is great intolerance of light, and a copious, hot, lachrymal discharge. The vision will be found

for the most part, so extremely imperfect, that the patient can merely distinguish light from darkness, and he is often tormented by flashes of light which shoot across his eye, and these occur more particularly in dark places; or he is troubled by brilliant spectra, or by the constant presence of muscæ volitantes. There is very considerable pain, which returns in paroxysms, and these are almost always more severe at night. The pain is sometimes referred to the ball of the eye, sometimes to one of the lids, sometimes to the temple, or the circumference of the orbit. It is, one while, compared to the action of a saw on the bones, and on other occasions, to the darting of a sword through the eyeball. This disease occurs as frequently in the male as in the female. The youngest patient, of whose case I have a note, was ten years of age, and the oldest thirty-six years. It seldom attacks both eyes, and the right eye suffers more frequently than the left. Of forty cases which I have noted, there were only four who had the disease in the left eye, and only two who had it in both. The general health seldom appears to be much deranged. The tongue is for the most part slightly white. There is often considerable thirst, and the pulse is somewhat accelerated. The bowels are frequently confined, and there is occasionally a disposition to nausea. The disease has occurred more generally in those who have been the subjects of relapse, but the period at which it takes place after the first attack of fever is extremely uncertain. In some it has appeared immediately, in others not for months. Sometimes a state of apparently full health has intervened between the attack of fever and the commencement of the inflammatory disease of the eye; on other occasions, the general health has seemed imperfect from the time of the fever, until the occurrence of the ophthalmic affection."

Mr. Wallace proceeds to observe that the disease presents two distinct stages, in the first of which there are amaurotic symptoms alone, to which, in the second, those of inflammation are superadded. The period at which the former commence after fever, and the length of time that they exist before external redness comes on, are very uncertain. Sometimes dimness of vision and muscæ volitantes have been experienced at or before the time of convalescence from fever; yet the inflammatory state has not supervened for weeks or months; while on other occasions, the dimness has not commenced for weeks or months after the febrile attack, and has then been immediately followed by the symptoms of inflammation. The inflammatory also precede the amaurotic symptoms in the time of disappearance.

Mr. Wallace had found the treatment by depletion and mercury insufficient, and even injurious, when he accidentally witnessed the rapid recovery of a case, in which the patient took bark on account of an intermittent under which he labored at the same time. This led him to employ the same remedy in other cases, which he did with striking, and apparently constant success. At first he did not venture to employ it when the inflammatory symptoms were severe, without previous bleeding and purging. "But latterly," he adds, "whenever a case has presented itself, I have prescribed the bark alone, or simply with such medicines as were suited to the regulation of the bowels, and with the most decidedly good effects. Indeed, I have thought that the abstraction of blood has, on some occasions, considerably retarded the cure; yet cases may occur in which bleeding and purging may be necessary." Mr. Wallace gave the bark in powder, half a drachm or a drachm three or four times in the twenty-four hours; or the sulphate of quinine in two grain doses. He relates several instances in which this treatment had been employed, both where mercury had been used in vain, and where it had not been resorted to. He employed it equally during the amaurotic stage, and after the inflammatory symptoms had commenced.

At page 201, I have quoted from Professor WALTHER a case of ophthalmia occurring after fever; apparently similar to the affection described by Mr. WALLACE: it was successfully treated by loss of blood.

Mr. HEWSON* has related five "*cases of ophthalmia succeeding to typhus fever*," in which the symptoms were exactly the same as those described by Mr. WALLACE. They all yielded readily to mercurial treatment.

The observations of Mr. WALLACE, respecting the efficacy of bark in this affection, are confirmed by the testimony of Dr. REID in the following passage. "On my first noticing this affection of the eye, as a sequela of fever, I was informed by Mr. WALLACE of this city, that in some cases of a similar nature, which came under his treatment, he had found small doses of Peruvian bark the most efficacious remedy. I therefore immediately adopted his suggestions, and with ultimate success, in all the cases which came under my care. There were two patients with this form of disease, to whom I gave preparations of bark: after a few days the ophthalmia certainly disappeared, but they had a relapse of fever in an aggravated form."†

This species of internal ophthalmia has been described by Dr. JACOB, of Dublin, in the work last quoted.‡ This gentleman and Mr. WALLACE agree very nearly in what they say respecting the history and symptoms of the disease; but on the subject of treatment, particularly in reference to the powers of bark and mercury, their evidence is completely contradictory.

Dr. JACOB had met with seventy or eighty cases of the disease within the year. He had not seen it at a later age than forty-five; and of thirty cases in which the ages were noted, three only were above twenty-five. It is more frequent among the poor than the rich, and among females than males. Children are not exempt; cases have been seen at three, five, and seven years of age. It came on generally within six weeks or two months after recovery from fever; sometimes earlier, sometimes at the end of four, five, or even eight months. It affects only one eye. Dr. J. does not remember seeing any case in which both suffered. Symptoms of retinal affection occur first, and the inflammation supervenes in six, eight, or ten days: the interval is sometimes longer, even to two months. "In this inflammation the transparent parts are rendered more or less clouded or opaque; the cornea especially has its margin or circumference almost always of a whitish or gray appearance, presenting an opaque circle resembling the arcus senilis. The anterior chamber of the eye appears clouded, independent of the opacity of the cornea, arising probably from thickening of the membrane of the aqueous humor; this cloudiness is sometimes general, sometimes it presents a muddy patch behind the cornea as in syphilitic iritis. In the worst form of the disease the lens itself becomes partially opaque, reflecting light falling obliquely upon it, and presenting an opaline amber color; indeed it is in this way I have observed vision to be destroyed when the disease has been fatal to the organ." The iris is always altered in color, and loses its brilliancy; but Dr. JACOB has not seen it assume the decided yellowish-green, observed in some other inflammations; nor has he observed the formation of abscesses or tubercles of lymph. Hypopyon sometimes occurs, but not as a consequence of more intense inflammation; on the contrary, it is seen in very

* Observations on the history and treatment of the Ophthalmia accompanying the secondary forms of the Lues Venerea, p. 109—114.

† Clinical Observations made during the Epidemic Fever of 1826; in the Transactions of the Association of Fellows and Licentiates of the King and Queen's College of Physicians, vol. v. p. 294.

‡ On Internal Inflammation of the Eye following Typhus Fever, p. 468—478. This paper, read in January, 1828, was published in the same year. Mr. WALLACE's essay was read in December, 1827, and published in 1828.

mild cases, even when the pupil contracts on exposure to light. The pupil is slightly irregular, but does not contract adhesions, or become closed: often the iris moves actively. A stinging or aching pain darting to the temple or nose is generally present; often there is little or no suffering. There is intolerance of light, with lachrymation and severe pain on exposure to strong light. "Vision is in all cases much impaired; some cannot read print of moderate size, others cannot distinguish large capital letters, others are unable to see a key, or other large object, held at a short distance from the eye, while others can only distinguish light from darkness. I have not observed that the degree of injury to vision was proportioned to the extent of the inflammation; the cases of mildest appearance being sometimes attended by the most defective sight. The patient can seldom distinguish all the prismatic colors, deep blue and green generally appearing black."

"The treatment of this inflammation of the eye is not attended with much difficulty. Bleeding, locally, or generally, in proportion to the urgency of the symptoms; blistering, where there is much pain or intolerance of light; purgatives, antimonial medicines, and opiate stupes, are obvious means of relief." Dr. Jacob strongly advises the use of belladonna, and adds, "I do not, however, by any means recommend that the surgeon should depend on these remedies alone; on the contrary, I believe that they will prove ineffectual in the majority of cases, and therefore we must have recourse to mercury, which has been found so valuable a resource in other cases. In my own practice I have found the relief from the use of mercury so certain and decisive, that I have trusted to it almost exclusively, with the assistance of the belladonna. I have generally found that two grains of calomel with a quarter of a grain of opium, three times a day, answered every purpose; and in the majority of cases I produced the necessary mercurial action, as marked by tenderness of the gums, in eight or ten days, by the use of three, four, or five grains of the blue pill alone, three times a day; and if the pain should be severe, combining hyoscyamus or belladonna with the dose taken at bed-time. I have heard that the sulphate of quina has been administered with advantage in these cases; but as my experience of its efficacy is not considerable, I cannot speak of it with any certainty. In two cases which I saw after the inflammation had subsided, and in which vision was as much impaired as if no remedies had been adopted, bark in powder had been administered for ten days. I gave trial to the sulphate of quinine myself in four well marked cases for eight days, but finding no relief, had recourse to mercury, which effected a cure in the usual time."

[During the year 1842, an epidemic fever of a peculiar character prevailed in some parts of Scotland, and which was followed in a great many cases by severe inflammation of the eyes, similar to that which occurred after the Dublin epidemic of 1815 and 1826, described by Mr. Hewson,* Dr. Reid,† Dr. Jacob,‡ and Mr. Wallace.§ Dr. Mackenzie has given a very interesting account of this affection as it was observed by him in Glasgow. (*London Med. Gaz.*, Nov., 1843.)

Out of 36 cases treated by Dr. Mackenzie in August, September, and October, 27 occurred in females, and only 9 in males.

The ages of the 36 patients were as follows:—Below ten, 2; from

* Observations on the History and Treatment of the Ophthalmia accompanying the Secondary Forms of Lues Venerea, pp. 34, 109. London, 1824.

† Transactions of the Association, &c., vol. v. p. 294. ‡ Ibid., p. 468.

§ Medico-Chirurgical Transactions, vol. xiv., p. 286. London, 1828.

ten to twenty, 17; from twenty to thirty, 9; from thirty to forty, 2; from forty to fifty, 3; from fifty to sixty, 3.

In eighteen of the cases, the right eye only was affected; in ten, the left only; and in eight, both eyes, either together or consecutively.

The attack of ophthalmitis occurred at various periods from three to sixteen weeks from the commencement of the fever. In several cases it came on about two weeks after convalescence from the relapse, but generally somewhat later.

The attack, Dr. M. says, is generally traced to draughts of cold air during the night; it is probably the eye which is exposed which becomes affected, while that belonging to the side on which the patient rests escapes.

Symptoms.—The character of the disease appears to be, Dr. M. says, "in the first instance, that of congestion, followed by inflammation of the internal parts of the eye, and especially of the retina, producing great imperfection of sight. This is succeeded by evident inflammation of the iris and sclerotica; the disease extends to the capsule of the lens, and sometimes to the lining membrane of the cornea; there can be little doubt but that the choroid is also inflamed; while the conjunctiva remains in general but slightly affected.

"The part which the sclerotica takes in the disease is plain enough, from the intense injection of the blood-vessels which lie on its surface, and which, derived from the muscular and anterior ciliary arteries, are seen running in radii towards the cornea. The change of color in the iris, the contracted state of the pupil, and the tags of adhesion between the edge of the pupil and the capsule of the lens, show the part which the iris takes in the disease. The internal membrane of the cornea, and the anterior crystaline capsule, especially the latter, are extremely muddy, showing their participation in the inflammation. The whole walls of the aqueous cell seem in some cases as if coated with a thin layer of lymph, of a yellowish-green color. The great deficiency of sight is not explicable from the mere muddiness of these parts, and is, besides, often the earliest symptom of the disease, showing an affection of the retina. At an early period, the pupil is sometimes dilated, and does not become contracted till the inflammation embraces the iris. If not promptly combated by the appropriate remedies, the cornea and sclerotica become preternaturally flexible under the pressure of the finger, showing that the disease has extended to the vitreous body. In one case I found the cornea very flexible in the amaurotic stage, before there was any appearance of inflammation.

"At the commencement, it is possible that only the central artery of the retina, and the vasa longa of the hyaloid, may be affected. The irritation and injection speedily spread, in all likelihood, to the short, as well as to the long ciliaries; to the vessels of the ciliary processes, and of the zonula Zinnii; to the vassa brevia of the hyaloid, the vessels of the anterior crystaline capsule, and those of the lining membrane of the cornea; and to the sclerotic network.

"The lachrymation is very considerable, and seems to be connected, not so much with the state of the conjunctiva, as with the pain in the interior of the eyeball. The severe pain in and around the eye, aggravated during the night, is exactly similar to what attends rheumatic and syphilitic ophthalmia, and may partly be ascribed to the pressure exercised upon the ciliary nerves within the eye, by the inflamed parts, partly regarded as a direct neuralgic affection, such as we often meet with in the six branches of the fifth nerve which emerge from the orbit, when

there is no evident inflammation present. It is, in general, only after the iris and sclerotica have taken part in the disease, that the patient complains of the occular and circumorbital pain. So long as the disease is confined to the retina there is little or no pain. Hence the patient is less alarmed than he should be, by the mere dimness of sight, which, indeed, from only one eye being generally affected, may scarcely attract his attention. Even photopsia, in the early stage, is not much complained of; in the last stage, muscæ volitantes form a constant symptom.

"Although, in by far the greater number of cases, all the textures of the eye suffer in this disease, on which account it may be designated as an *ophthalmitis*, it sometimes happens that the inflammation is confined to one or two textures only. Thus in case 6 the anterior crystaline capsule and the lining membrane of the cornea only were visibly affected with inflammation.

"The pulse varies from 84 to 120. Frequently rigors occur. The tongue is generally clean and moist. The pain entirely prevents sleep.

"*Diagnosis.*—The present disease is much more extensive, in respect to the number of textures affected, and much more intensive, in so far as the morbid action which is at work is concerned, than rheumatic ophthalmia, or rheumatic iritis; to which, however, in many particulars it bears a resemblance. Yet, along with postfebrile ophthalmitis, we have neither the bounding pulse, the hot skin, nor the white and loaded tongue, which attends inflammation of the sclerotica and iris from mere exposure to cold. Neither is the blood drawn from a vein so buffy. The pain is not less distressing. Vision is much sooner, and much more seriously involved.

"Mr. Wallace considers this affection of the eye as bearing so very striking a resemblance to syphilitic ophthalmia, that the one cannot be distinguished from the other without particular attention to the history of the case. The absence of the tawny-reddish border which surrounds the pupillary margin of the iris, and there being tubercles on the iris in postfebrile ophthalmitis, will serve to distinguish the two diseases.

"The acuteness of the present disease will discriminate it from scrofulous iritis, to which, particularly in the appearance of the lens, it bears considerable resemblance, as well as in the degree in which the retina is affected.

"In some instances, postfebrile ophthalmitis bears a considerable resemblance to catarrho-rheumatic ophthalmia. Onyx, so frequent in the latter disease, I have not witnessed in the former. In one case I observed a considerable portion of the conjunctiva cornea ulcerated, but never the ulcer which affects the proper substance of the cornea, and which is so characteristic of the catarrho-rheumatic disease.

"The disease to which postfebrile ophthalmitis bears the nearest resemblance is sympathetic ophthalmitis; which results so frequently from incised and lacerated wounds of the edge of the cornea and sclerotica, and consequently of the annulus albidus of the opposite eye. The cause of the great similarity is, that in both cases the inflammation commences in the retina, advances to the iris, embraces all the internal textures of the eyeball, and ends, if neglected, in closure of the pupil, opacity of the crystaline, softening of the globe, and insensibility to light. The slightest inquiry into the history of the case will in either instance elucidate the origin of the affection."

Stages.—Mr. Wallace has described this disease as presenting two stages; the first amaurotic, and the second inflammatory. Dr. Mackenzie's observations illustrate the accuracy of Mr. Wallace's description. "During the first stage," says he, "there exist amaurotic symp-

toms alone; and in the second stage, to the amaurotic symptoms are superadded the symptoms of inflammation. The length of time that the amaurotic symptoms exist before the occurrence of external redness, or of the visible symptoms of inflammation, is extremely uncertain, as also the period after fever at which the amaurotic symptoms commence. On many occasions the amaurotic symptoms, particularly a slight dimness of vision, with muscæ volitantes, have commenced at or even before the time of convalescence from fever, and yet the inflammatory stage has not supervened for weeks or even months; while on other occasions the dimness of vision has not commenced for several days, weeks, or even months, after the febrile attack, and has then been immediately followed by the symptoms of inflammation. It is to be particularly observed that I have never seen a case in which, upon strict inquiry, amaurotic symptoms, more or less strongly marked, have not preceded the inflammatory symptoms. This is, in fact, one of the most remarkable characters of the disease. It is also to be noticed that a similar distinction of symptoms is observable during amendment, for it uniformly happens that the inflammatory symptoms subside a longer or shorter time before the amaurotic symptoms disappear, and often before they are diminished in severity.'

Two of the cases related by Dr. Mackenzie, bear not merely at the commencement, but all along, much more the aspect of amaurosis than of ophthalmitis. In one case which he saw, the patient was suddenly struck blind of the affected eye. In another case, along with amaurotic symptoms, the cornea had become flexible, and no longer apprehensive of inflammation supervening, he had commenced the use of quina and blisters, when suddenly pain and redness set in. He met with several cases in which, for days, the principal symptoms were pain in and around the eye, and dimness of sight. In other cases, there was redness of the eye from the very commencement.

Predisposing and exciting causes.—That an opportunity is left for the disease of the eye by the fever is, says Dr. M., plain; there may even be grounds for suspecting that the fever may have left the circulating fluids in an altered state, favorable for the production of the local complaint. However this may be, the affection of the eye is generally traceable to some exciting cause, and especially to cold. Sleeping in an apartment with broken windows, working in a cold damp shop, and washing the head with cold water, are mentioned in the cases as exciting causes. Using the eyes too early in sewing is another.

Prognosis.—The recovery is tedious. In the majority of cases, says Dr. M., two months of uninterrupted and careful treatment have been necessary to effect a cure. That the disease, without any treatment, will wear itself out, is true; but the eyes will be left useless, from the contracted and adherent state of the pupil, and the amaurotic condition of the retina. If trifled with, the cure will be imperfect; synechia posterior, muscæ volitantes, and other irremediable sequelæ, remaining. If taken early, and treated vigorously, a complete cure may be prognosticated. Recovery is much more speedy and complete in young subjects; in adults it is more tedious.

Treatment.—1. *Depletion.* The wan appearance of many of the patients, the smallness of their pulse, and the state of general debility in which they are, might tend to deter from a use of the lancet. Dr. M. is satisfied, however, that we can rarely, with safety, dispense with this remedy. The blood, drawn from a vein, is only in a few cases buffy. Often it is difficult, from syncope coming on, to obtain more than a few

ounces from the arm. When this is the case, leeches to the temples and round the eyes must be had recourse to.

"If depletion is neglected, the recovery is very slow and uncertain; adhesions form, and cannot be got rid of, and vision continues imperfect. We must not be regulated by the pain alone in taking away blood. Nothing relieves the pain so strikingly and effectually as venesection; but the state of the eye, independently of the pain, demands the taking away of blood. We should not even wait for the inflammatory stage of the disease, but relieve the congestion, on which the amaurotic symptoms depend, by the employment of depletion.

"Some cases, especially in children, I have trusted to leeching; but in adults venesection is almost always necessary. I have not used arteriotomy, nor cupping, but have no doubt of their efficacy."

2. *Purgatives.*—"The tongue being generally clean, and the bowels regular, there seems to be little demand for purgatives. At the same time, I have found them of considerable use in the course of the treatment. Sulphate of magnesia, castor-oil, and compound powder of jalap, are those I have most employed."

3. *Mercury.*—Dr. M. is "decidedly of opinion that the safest and the most effectual plan of cure embraces the use of calomel with opium, exactly as in the treatment of rheumatic or syphilitic iritis. This view of the matter is confirmed by the testimony of Mr. Hewson, who seems to have trusted to opening the temporal artery, and giving a dose of three grains of calomel with half a grain of opium each night. Dr. Jacob also found the use of mercury so certain and decisive in this affection of the eye, that he trusted to it almost exclusively. He gave two grains of calomel and a quarter of a grain of opium thrice a day. The mouth should be made sore, but not too suddenly, lest we be obliged to omit the medicine prematurely.

"4. *Belladonna.*—The dilatation of the pupil is an essential part of the treatment. This is to be effected by liberally smearing the eyelids and eyebrow with the moistened extract of belladonna, morning and evening; directing the patient to renew its activity from time to time, by re-moistening it with his finger dipped in water."

5. *Counter-irritation.*—Considerable benefit, Dr. M. states, is derived from blisters to the temples and behind the ears, after due employment of depletion. They aid in removing the pain, lessening the inflammation, and recalling the power of vision.

"6. *Cinchona.*—Mr. Wallace has keenly advocated the supremacy of cinchona as a cure for this affection of the eye. He thinks it has a specific influence over the disease; recommends it both when the patient is weak and seems to demand tonics, and when he is in full health; maintains the incurability of the disease by mercury; and is decidedly of opinion that there must exist some source of error in Mr. Hewson's account of the cases cured by this medicine. 'When I commenced the use of bark in this disease,' says Mr. Wallace, 'I did not venture to employ it when the inflammatory symptoms were very severe, without preceding its administration by bleeding and purging. But latterly, whenever a case has presented itself, I have prescribed the bark alone, or simply with such medicines as were suited to the regulation of the bowels; and with the most decidedly good effects. Indeed, I have thought that the abstraction of blood has, on some occasions, considerably retarded the cure; yet cases may occur in which bleeding and purging will be necessary.'"

Dr. Mackenzie has not employed cinchona bark in powder, but the

trials he has made of sulphate of quina have not led him to adopt any very high opinion of its efficacy in this disease. Some of the milder cases have yielded, in a great measure, to the combination of calomel and quina. On the whole, he feels indisposed to trust to this remedy; and on this point his views correspond to the experience of Dr. JACOB. See p. 469.

Advantages are to be derived from regulating the diet of the patient in this disease, and protecting him from cold; and warm fomentations and anodyne frictions will be found highly useful. Such internal remedies as tartar emetic, colchicum, or turpentine, Dr. MACKENZIE has not tried, and he considers their effects problematical.]

ARTHRITIC INFLAMMATION OF THE INTERNAL TUNICS.

In arthritic iritis, which has been already described, the disorder begins in, and is chiefly confined to, the iris. But in the gouty, or in persons whose constitution and general health are impaired in a similar manner, a more extensive inflammation is frequently developed, affecting the internal parts of the globe generally, that is, the choroid, iris, retina, vitreous humor, lens and its capsule, and involving the sclerotica and cornea secondarily. It ends in loss of sight, with a dilated pupil, and opaque lens. Sometimes the latter change does not occur, but there is deep-seated green discoloration of the pupil, that is, the appearance called glaucoma: the disease might then be named *acute glaucoma*, in contradistinction to the slowly occurring change of similar character, which will be afterwards described. BEER* has given an account of this affection under the name of *arthritic iritis*, thus leading to the erroneous notion of its being confined to the iris, although his own description of its progress and destructive influence on vision, as well as of the changes of structure produced in various parts of the globe, shows it to be much more extensive. This disease almost invariably destroys sight: while the eye will recover completely from repeated attacks of arthritic iritis. BENEDICT† and ROSAS‡ have given it the appropriate name of *ophthalmitis arthritica*, because it attacks gouty persons, and involves the whole globe.

A severe burning or tearing pain is felt deep in the globe, with a sensation as if the eye were too large for the orbit. At the same time, a dull and rather livid redness is developed in the sclerotica, increasing in intensity to the edge of the cornea, from which, however, it is separated by the narrow white ring mentioned in the description of arthritic iritis. Soon the vessels of the conjunctiva become distended, and the cornea loses its brightness. In the beginning there is increased sensibility to light and lachrymation. The pain of the eye becomes severe and almost intolerable, and extends to the orbit, face, and side of the head; it entirely prevents rest, and sometimes is hardly lessened by the most active treatment. The iris is rendered darker and dull, the pupillary margin being turned backwards, and the opening itself dilated and fixed, sometimes having an oblong figure in the transverse direction. A dull green discoloration is observed deep in the eye, and considered to indicate loss of transparency in the vitreous humor, or organic change in the retina. The posterior parts of the globe swell, and push forwards the lens into the dilated pupil, wedging it into the aperture, and squeezing it against the cornea. Under such circumstances, or without

* Lehre, vol. i. § 567—572.
† Handbuch, vol. ii. p. 263.
‡ Ibid., vol. ii. § 814—828.

being thus displaced, the lens loses its transparency, turns of a dull green, yellowish-green, or dull white, forming a *green* or *glaucomatous cataract*. This vascular congestion, and the consequent swelling of the internal parts, distend the sclerotica, and give to the globe a stony hardness. The disturbance in the vessels of the sclerotica extends to the cornea, often causing considerable haziness; this change, and those in the iris and pupil, destroy all the brilliancy and expression of the organ, making it look almost like a dead eye. Sight is greatly impaired, often entirely lost, from the very beginning: this loss of sight may be sudden, taking place in the course of a night. Yet the patient often perceives flashes and various luminous appearances, although unable to distinguish light from darkness; and from time to time a glare of light is seen, which leads to the fallacious hope that sight may be recovered.

The pain and redness lessen, and the affection subsides, leaving an iris of dull leaden hue, a fixed and dilated pupil, either of a dull green color, or occupied by a glaucomatous cataract, with total and irreparable loss of vision. The external trunks lying on the sclerotica are enlarged, knotted, and varicose, (*varicositas oculi*,* *cirsophthalmia*, *varicose ophthalmia*.) Sometimes there is a distension with partial absorption of the sclerotica, giving it a dull leaden or bluish appearance, especially in the situation of the ciliary body, causing small projections, supposed to arise from various enlargements of the choroid veins, or the larger bulgings which constitute staphyloma scleroticæ, and alter the form of the globe. These appearances in the sclerotica must be ascribed to a morbid condition of the choroid and other internal parts. Mr. Mackenzie says, that in a preparation belonging to Beer he saw varices of an inflamed choroid as large as small peas. (*Practical Treatise*, p. 460.) It has been found in some cases that effusion of fluid has occurred between the choroid and retina.

The disorder generally affects the two eyes in succession; but both may be attacked at once. The course of the affection varies in rapidity and severity of symptoms. Sometimes sight is more slowly extinguished, pain is less, and even inconsiderable, the change in the iris is not so remarkable; the varicose enlargement of the external vessels is not seen.

The pathology is imperfect from the want of dissections. We do not know where the disease begins; what structure is its primary and essential seat. The early diminution or entire loss of sight shows us that the retina is disordered in the very outset, and that it undergoes serious disorganization; if, therefore, the complaint were to be named from the structure, in which it first breaks out, we should call it retinitis. Mr. Wardrop informs me that in two cases of acute glaucoma, where blindness occurred in the very beginning of the attack, he found after death opacity and thickening of the retina, in a space about equal to the nail of the little finger. The changes in the pupil indicate alteration in the transparent media; while the tension of the globe and the bulgings of the sclerotica imply congestion and swelling of the choroid.

The chief cause of the affection is an unhealthy state of constitution; it takes place in gouty subjects, and in such as have had other forms of gout. We see it in elderly persons, always after the middle period of life; in those of full habit, of corpulent make, with the bloated, red, purple, and veined faces, that denote habits of indulgence.

It is important to distinguish this affection from cataract; from amaurosis, properly so called; and from common internal ophthalmia.

The prognosis is entirely unfavorable. Where vision is lost in such a case, it is never restored; nay, if the characteristic symptoms are present,

* Beer, Lehre, vol. ii. p. 247.

we may be tolerably certain that the disease will go on to the extinction of sight; and we cannot prevent it. The disorder indeed is so unmanageable, that treatment has very little effect upon it; the pain in the eye and head continues in spite of our treatment, and vision is neither restored nor improved. In the beginning we resort to depletion, perhaps to loss of blood, according to the degree of local and general disturbance; subsequently a mild mercurial course, with aperients, regulated diet, and blistering may be necessary.

This disease is sometimes seen in the chronic form, the symptoms and progress being essentially the same as in the acute affection, but much milder and slower. Vision is impaired in the beginning, with scintillations or other luminous appearances, and perhaps pain in the eye or brow. There is dull or livid redness of the sclerotica, with enlargement of its vessels; the iris undergoes change of color, and loses its mobility; a dull or brighter greenish appearance is seen deep in the pupil, no longer observable when we look at the eye sideways, and varying its apparent position according to the direction in which light falls on the organ. The pupil is often dilated transversely, so as to assume an oblong form. Ultimately, glaucomatous cataract occurs, perhaps with staphylomatous bulging of the sclerotica, varicose enlargement of the subconjunctival vessels, and complete extinction of sight.

As weeks or months may elapse without the complaint making much progress, an opportunity is afforded for trying the effects of treatment, which hardly occurs in the acute disease. We may remove the affection in an early stage, and arrest its progress at a more advanced period.

The subjects of the complaint are generally individuals, at or beyond the middle period of life, of unsound constitution or impaired health. Depletion, or any treatment calculated to lessen constitutional power must therefore be resorted to cautiously. Local abstraction of blood may be required, and the mild employment of mercury, if the system will bear its influence, is of great service.

The protection of the organ from excitement, or other injurious influence, the removal of all causes, whether bodily or mental, capable of lowering the energy of the nervous system, residence in pure air, and tonic or restorative medicine under particular circumstances, are important, or rather essential auxiliaries.

GLAUCOMA.

The name of *glaucoma*, which was formerly given to cataract, is now used to denote an affection of the eye attended with alteration in the color of the pupil. It is an important disease, because the discoloration of the pupil may be confounded with cataract, and because it is either originally attended with impaired vision, or leads in its progress to diminution or loss of sight.

Symptoms.—The first symptom is pain in the head, usually situated over the brow, and frequently the patient describes it as extending quite across the forehead. This pain in many cases is severe, but in others not so strongly marked, or even absent. At the same time, the patient begins to complain of dimness or weakness of sight; and, if we examine the eye, we find that instead of exhibiting its natural black color, the pupil is sea-green, clear green, muddy green, or yellowish-green. There is a discoloration, which, if we look at it in a strong light, appears like a yellowish metallic reflection, and sometimes concave: it looks almost as if there was a portion of metal at the bottom of the eye. The pupil at the same time is rather

dilated, and the iris sluggish. The state of vision is different in different instances; in some, the alteration of the pupil is distinctly produced, and yet vision remains tolerably perfect. In other cases vision is entirely lost, though the change of color in the pupil is inconsiderable. Sometimes vision is impaired in one eye and not in the other, though the pupil may be equally discolored in both.

In the progress of the disease, vision gradually grows worse: the discoloration of the pupil, or rather of the fundus of the globe behind the pupil, is more considerable; the iris is more sluggish, until it becomes at last motionless, and vision is entirely lost. The affection does not always stop at this point, but sometimes attacks the lens, and renders it opaque, so that it is no uncommon thing for cataract to occur subsequently in an eye which was originally attacked by glaucoma. The cataract thus produced is greenish, yellowish or dirty white, (*cataracta viridis* or *glaucomatosa.**)

Sometimes the lens and iris are pushed forwards, so that the latter is convex; it may even be in contact with the cornea. The external vessels of the globe are sometimes enlarged and varicose; but all the characteristic appearances of glaucoma may occur with loss of sight, without any change in the state of these blood-vessels.

Causes.—We can point out nothing peculiar as contributing to its occurrence. It takes place at or after the middle period of life, in those whose constitutions have been impaired by free living, especially by drinking. It appears to me to be the most chronic form of the same affection which I have described, as arthritic inflammation affecting the internal tunics; the changes which occur in the retina, vitreous humor, and lens, as the consequences of that inflammation, are rapid and sudden, whilst in the present case the disease has a slower progress. It certainly occurs more frequently in such persons as are liable to gout than in others. "Glaucoma and green cataract," says Beer,† "considered as consequences of inflammation, belong to arthritic inflammation of the globe; and the same forms of disease, when occurring without inflammation, are only seen in the gouty."

Seat of disease.—The situation of the discoloration has naturally led to the supposition that it arose from change of structure in the vitreous humor, and it has accordingly been assumed, without direct evidence, that inflammation of this structure produces the phenomena of glaucoma. From the immediate contiguity and close connection of the retina we might expect that it would often suffer in conjunction with the vitreous humor originally; or that inflammatory affection commencing in the latter, would soon extend to the former. Thus we might explain how sight is seriously impaired, from the beginning, in some cases: while in others, amaurosis appears secondarily, and proceeds slowly. Mr. Mackenzie has recently shown, by pathological examinations, that the commonly received notions on this subject are incorrect. He found the following changes to have occurred in eyes which had been affected by glaucoma:—"1. The choroid coat, and especially the portion of it in contact with the retina, of a light brown color,

* Weller has delineated, in several figures, the appearance of the eye in the various stages and forms of glaucoma. See his Icones ophthalmologicæ, fascic. i. plate 1, 2.

Von Ammon has given numerous representations of eyes affected with glaucoma, illustrating the changes caused by the disease in the iris and pupil, in the crystaline, the sclerotica, and the external vessels of the globe. Klinische Darstellungen, pt. i. tab. 10, fig. 14—24; tab. 15, fig. 1.

Two excellent representations of the disease will be found in Beer's Lehre; vol. i. tab. 2, fig. 6; and vol. ii. tab. 3, fig. 5.

A figure of glaucoma is also given by Mr. Tyrrell, vol. ii. pl. 5, fig. 1; and by Mr. Morgan, tab. 11, fig. 3.

† Lehre, vol. ii. p. 255.

without any appearance of pigmentum nigrum. 2. The vitreous humor in a fluid state; perfectly pellucid; colorless, or slightly yellow. No trace of hyaloid membrane. 3. The lens of a yellow or amber color, especially towards its centre; its consistence firm; and its transparency perfect, or nearly so. 4. In the retina, no trace of limbus luteus or foramen centrale." (*Glasgow Medical Journal*, vol. iii. p. 259.) Mr. MACKENZIE considers that the glaucomatous discoloration of the pupil is owing to the change in the lens.

Professor WALTHER (*Abhandlungen*, p. 40—42), examined the eyes of a man, who had lost his sight a year before death, with violent pain of the head. Besides the discoloration of the pupil, which was not considerable in proportion to the loss of sight, the aperture was rather dilated, the iris convex anteriorly, the sclerotica bluish over the corpus ciliare, and vision completely extinct, although light was offensive. Several varicose vessels were observed in the conjunctiva and sclerotica. The lens and vitreous humor were in the normal state, and perfectly transparent: no change in the choroid. In the retina of both eyes were numerous black, and partly reddish spots, roundish, and of various size; they were more numerous towards the dentated margin, and not disturbed in their situation by gentle pressure.

Two glaucomatous eyes were dissected by EBLE. (AMMON's *Zeitschrift*, vol. i. p. 310, 311.) One was from a woman of sixty, who had suffered much from gout, and had had glaucoma completely developed in one eye for a year before death. The covering of the uvea was reddish-brown, instead of the usual dark pigment. The vessels of the choroid were varicose in several places, particularly in the ciliary processes; the pigment was much lighter than natural, and had disappeared in many parts. The retina was of extraordinary softness; it was almost fluid. The capsule was partially opaque; the lens small, firm, and of amber color. The whole vitreous humor had a yellowish tint; and there were scattered through it twenty or thirty points of a gray, brownish-green, or sea-green color.

The other patient was seventy years old, had frequently experienced arthritic inflammation of the eyes, and had become glaucomatous shortly before death. The vitreous humor was partially thickened, and firmer to the touch. The retina was more seriously affected than in the former instance, the vessels exhibiting some varicose enlargements, and the color being dark gray.

"The pathological changes," says Professor ROSAS, "exhibited by glaucomatous eyes are various. The vitreous tunic is commonly thickened, covered with lymph, ossified; the vitreous humor degenerated; the retina thickened, and marked with red spots; the choroid varicose. In a case, which I examined, the vitreous humor contained a reddish-gray fluid, with brownish particles intermixed; the retina was thickened, the choroid varicose, and the lens converted into a yellowish, red, cheesy mass. In another instance the vitreous humor formed a true fungous growth, (*schwammgewächs*,) from which, when cut into, blood flowed; the retina was leathery and white, the choroid thin and atrophic, and the lens converted into a purulent fluid. In a fourth case I found the vitreous humor, together with the lens which had become confounded with it, ossified, the retina cartilaginous, and the choroid atrophic. All these preparations are preserved in the pathological collection of the ophthalmic department in the University of Vienna." (*Handbuch*, vol. ii. § 1203.)

From the preceding pathological facts, we may conclude that the vitreous humor is not originally and essentially the seat of glaucoma: we may perhaps draw the further inference, that affections in some respect different are included under that term. When we consider the numerous gradations

between the acute internal arthritic ophthalmia, which destroys sight at once; and the imperfection of vision, which comes on so slowly in glaucoma, properly so called; also that difference of morbid changes may be expected according to the stage of the complaint, we shall not be surprised at finding that the results of examination are not always alike.

The cases examined by Professor Rosas must have been arthritic inflammation of the internal tunics, and chiefly in their chronic stage; some of the disorganizations which he met with, are such as occur only after long continuance of disease.

The phenomena of glaucoma, according to these dissections, must be referred to disease of the choroid and retina; and the reflection of light from the surfaces thus morbidly altered, especially if the lens should have begun to exhibit that change to amber color which takes place in advancing age, will sufficiently explain the change of color behind the pupil.

Diagnosis.—The discoloration of the pupil arising from glaucoma, and that from cataract, may be distinguished by the tint of color. In glaucoma it is green or yellowish-green, and if we look at the eye laterally, we see no discoloration, whilst in cataract the pupil is gray, or grayish-white, and it has the same appearance in whatever direction it is viewed. The loss of vision in glaucoma is not in direct proportion to the change of color in the pupil; with an inconsiderable change, vision may be entirely destroyed or seriously impaired; but in cataract there is a direct proportion between the degree of opacity and the injury to sight. In cataract, vision is best in a moderate or weak light; but in glaucoma it is most perfect in a strong light, because in glaucoma, as the retina is less sensible, more light is required to make an impression on it.

Prognosis.—The prognosis in glaucoma is unfavorable; we have no means of changing that condition of the internal parts, on which the loss of transparency depends; we cannot bring back again the natural appearance of the pupil; we cannot restore the vision which has been lost; and all we can expect to do, is to preserve the little sight which remains.

Treatment.—Beer says (*Lehre*, vol. ii. p. 254—256), that no treatment will be of any effect in preventing complete amaurosis. As he speaks of glaucoma with green cataract, his observations probably refer rather to the state in which the eye is found after acute arthritic inflammation of the internal tunics, than to the disease which I have been describing, in which sight is effected in conjunction with a peculiar discoloration behind the pupil, the lens retaining its transparency, and without previous apparent inflammation. I have found by repeated experience that many of these cases admit of considerable relief; but I quite agree with him in regarding the combination of glaucoma with green cataract as incurable.

There is sometimes congestion in the head, the removal of which is attended with considerable benefit. The treatment must in such cases be antiphlogistic; we must take blood by cupping; give active purgatives, and administer mercury; the patient must be put upon a regulated plan of diet, and avoid all strain or fatigue of the eye. If this treatment be followed up, we shall at least prevent the disease from advancing.

In the first place when there is active congestion with pain, the patient is relieved from uneasy sensations. The continued prosecution of the plan will not only prevent the progress of disease, but even improve sight when it is begun at an early period of the affection. After taking blood by cupping, which may be repeated according to circumstances, it may be necessary to persevere for weeks or months in the mild use of mercury, not carrying it to the extent of salivation, carefully regulating the diet, and attending in other respects to the health, and the state of constitutional power. In this

way I have seen the swoln and pimpled countenance of a drinker surprisingly altered for the better, with corresponding improvement in the complaint; and in some instances, where glaucomatous discoloration of the pupil has been attended with slow inflammation of the iris, evidenced by adhesion of its margin, and with protrusion of it against the cornea, the disease has been kept in check, and good vision has been preserved for years.

[Glaucoma cannot, strictly speaking, be considered as a disease; the term being applied to a group of symptoms which result from several and very distinct pathological conditions. The existing imperfect state of our knowledge, however, relative to these conditions, and our inability to distinguish them in many cases during life, are perhaps valid reasons for treating of them under one head.

The appearances presented by glaucoma are usually considered as resulting from some change in the vitreous humor or hyaloid membrane, the retina or choroid. Dr. Mackenzie's investigations led him to believe that these appearances much more frequently result from a change in the crystaline lens. He is inclined to think that there is never any very distinct glaucomatous appearance, (that is to say, cloudiness of a greenish hue,) except what is caused by the amber or reddish-brown color of the central and posterior laminæ of the lens. "In lenticular glaucoma, the lens," he says, "has become, in a certain sense, dichromatic, being of a deep amber when allowed to transmit the light, but appearing green by reflected light; the green hue being probably the result of the absorption of the extreme prismatic rays of the light entering the eye, while the middle prismatic rays are but little affected.

"The reddish-brown color," he adds, "upon which lenticular glaucoma depends, affects only the internal and posterior laminæ, and fades away into an amber hue towards the surfaces, and especially the anterior surface and circumference of the lens. These, so long as the disease is one of simple lenticular glaucoma, have lost comparatively little of their natural transparency, but the reddish-brown part often presents, on making a section of the extracted lens, a peculiar dryness of substance, as well as a considerable degree of opacity.

"After lenticular glaucoma has existed for a time, the surfaces of the lens may become coagulated and opaque, so as to constitute a complication of glaucoma with cataract. This sometimes occurs very suddenly."

The catoptrical signs of the three stages of lenticular glaucoma are the following:—

1st. In the first degree or incipient stage, both the deep erect image, and the inverted one, are distinct, (Mackenzie.) While the outline of the deep erect image remains pretty sharp, its size is rather larger and brighter than in the healthy eye; it is also somewhat of a yellowish hue; and with the increase of glaucoma the inverted image becomes larger, and more of a yellowish color; its outline becomes sooner diffused than that of the deep red image. (Staberoh.)

2d. In the second degree of glaucoma, the inverted image is pretty distinct when formed near the circumferential part of the crystaline: but as the candle is moved across the eye, the inverted image becomes less and less distinct, and in some cases is altogether extinguished; but when the candle passes to the opposite side, the image reappears. (Mackenzie.) Both images of the candle are represented by yellowish spots, or blazes, of a pretty bright appearance, following the motions of the candle in their respective directions. (Staberoh.)

3d. In complete lenticular glaucoma the inverted image is no longer visible even at the edge of the lens.

4th. The deep erect image, according to Dr. MACKENZIE, "is better seen in the second and third degrees of glaucoma than in the healthy eye. It is large and evident, but its outline is not sharp, so that it appears like a diffused blaze. It is best seen when the eye is looked at downwards and from one side. The fact of its being more distinct than in the healthy eye is to be attributed to the reddish-brown part of the lens serving as a foil to the image." (*London Med. Gaz.*, April, 1838, and *Amer. Journ. Med. Sci.*, May, 1839.)

We shall relate in the chapter on cataract a case which presented the glaucomatous discoloration of the pupil, in which we had an opportunity of making a post-mortem examination; and notice more fully the diagnosis of these two conditions.

Since the publication of the first American edition of this treatise, Dr. MACKENZIE has published in the *London Medical Gazette*, Oct., 1843, a very interesting paper on this imperfectly understood disease. Dr. M. is one of the most learned and judicious ophthalmic surgeons of Europe, and his views are entitled to the most respectful consideration. We accordingly subjoin them, though we must confess that we cannot but entertain the persuasion, that Dr. M. has grouped together under the term glaucoma, several affections not necessarily connected, and which it would be better to consider separately.

"Glaucoma is so called," Dr. M. remarks, "from the greenish appearance which it presents behind the pupil. It is a reflection of the light which has entered the eye, by the central and posterior laminæ of the crystaline lens, arising from these laminæ having lost their natural color and consistence, and acquired an amber or reddish-brown hue, with an abnormal degree of hardness and dryness.

"The history of pathology sufficiently shows that dissection is the only way of discovering the nature of such diseases as cataract or glaucoma. If a cataractous lens is extracted from the eye of a person of 50 or 60 years of age, its superficial laminæ are found to be of an opaque whitish appearance, like half boiled white of egg, while the rest of the lens is of an amber color, and rather less opaque than the surface. If a glaucomatous lens is extracted, its superficial laminæ are found to be comparatively transparent, and the departure from the normal state to affect chiefly its central portion. Viewed entire, by transmitted light, it appears more or less amber-colored throughout. Divided by a section perpendicular to its surfaces, the kernel, and laminæ immediately behind the kernel, are found to be of a reddish-brown color, in a considerable degree opaque, hard, and drier than the superficial laminæ. The lens, so changed, appeared while in the eye, and viewed therefore by reflected light, to be of a muddy green color, but this was in a great measure an optical deception; for, taken out of the eye, all greenness is gone, both within the eye deprived of its crystaline, and in the lens under examination. The lens, then, in glaucoma, is in a certain sense dichromatic, like a bit of gold-leaf; only that the latter viewed by reflected light is yellow, and green when viewed by transmitted light, whereas the glaucomatous crystaline is the reverse—green when seen within the eye by reflected light, and amber-colored when seen by transmitted light out of the eye.

"In its advanced stages, the disease styled glaucoma involves many other textures of the eye besides the lens, so much so, that Dr. HAYS, the American editor of Mr. Lawrence's Treatise on the Eye, remarks, that 'glaucoma cannot, strictly speaking, be considered as a disease; the term being applied to a group of symptoms which result from several and very distinct pathological conditions.' I cannot see, however, that glau-

coma is more objectionable in this respect than hundreds of other nosological terms. In an early stage, glaucoma is often limited to the lens, as it was in Shaw's left eye; or to the retina and lens, as it was in his right eye. It is sometimes the case, as in this individual, that the disease may continue for a number of years, without absolutely destroying vision, or becoming altogether irremediable.

"The case of Shaw confirms two statements which I made respecting glaucoma in 1830; the one, that if the lens is removed by operation, the green appearance behind the pupil is lost; and the other, that the removal of a glaucomatous lens improves the vision of the patient, unless, indeed, he be amaurotic.*

"The term *glaucoma* comprehends a series of morbid changes, which in general develops itself slowly, in the course of years, and involves at last all the structures of the eye. I say 'in general,' for there is an *acute glaucoma*, in which many of the symptoms of the chronic variety are manifested often in a single night's time. The earliest and least important appearance of *chronic glaucoma* is merely a greenish hue, reflected from behind the pupil in the eyes of old people, but which is not necessarlily connected with any material deterioration of vision, as is shown by the liveliness of the iris and the sensibility of the retina. A muddy green color of the crystaline marks the *second* stage, as in Shaw; and along with this there is sluggishness of the pupil, and more or less obscurity of vision. The consistence of the eyeball is natural. This stage may last for five or six years, or more, vision declining by insensible degrees all the time. An unnatural hardness of the eye, with dilatation of the pupil, a varicose state of the external blood-vessels, and a still more marked loss of sight, are the signs of the *third* stage. In the *fourth*, the crystaline becomes cataractous as well as glaucomatous, opaque, that is to say, on its surface, as well as in its nucleus; it is also augmented in thickness, and pressed through the pupil, till at length it touches the cornea; the sclerotica is thinned, so as to allow the choroid to shine through it, and vision is totally extinguished. In the *fifth* stage, the cornea, pressed upon by the hypertrophied lens, inflames and gives way by ulceration, the lens escapes, and the internal vessels of the eye burst, and bleed through the ruptured cornea. A *sixth* stage presents the eye shrunk and atrophic.

"These different stages of glaucoma run insensibly into each other. Although the disease is scarcely at any period of its course under the control of medical treatment, it is frequently arrested spontaneously in one or other of these stages, and makes no further progress. In Shaw, it stopped, as it often does, in the second stage; the amber-colored degeneration proceeding gradually towards the surface of the lens, but the other textures of the eye not becoming involved.

"In the first and second stages, glaucoma is generally a disease of the crystaline alone. I say 'generally,' for sometimes amaurosis accompanies glaucoma from the very commencement. In its advanced stages, it presents symptoms depending on certain morbid conditions of almost all the textures of the eye. The elements, in which glaucoma consists, when far advanced, reside in the lens, the vitreous humor, the retina, the choroid, the iris, the sclerotica, the blood-vessels of the eye, and even in the cornea. The order in which these different parts become affected is not invariably the same, nor the proportions in which they take part in this complex disease.

* Glasgow Medical Journal, vol. iii. p. 266. Glasgow, 1830.

"It is only in the early stages of glaucoma that the catoptrical examination of the eye is of importance. In the first stage, both the deep erect image formed by the anterior capsule of the lens, and the inverted image formed by the posterior capsule, are distinct. Both the images are rather larger than in the healthy eye, and both of them are of a yellowish hue. In the second and third stages the erect image is still larger than it was in its first stage, but its outline is indistinct, so that it appears as a diffused blaze. In the second and third stages, the inverted image is seen for a time, if, by moving the candle to one or other side, it is formed near the edge of the lens, but it appears less and less distinct as it is made to approach the centre of the pupil. At last, as the disease advances, it disappears entirely.

"The second stage of glaucoma is the only one in which the removal of the lens is a practice which can be defended. The pale muddy green opacity behind the pupil, more deeply seated than the opacity in ordinary cataract; so that, owing to the transparency of the superficial laminæ of the lens, the iris throws a broader shadow on the opacity than when the surface of the lens is affected; the consistence of the eyeball natural; the iris healthy in texture; the pupil not dilated; no inverted image, while the deep erect image forms a large yellow blaze; vision such as accompanies lenticular cataract; the progress of the disease much slower than that of lenticular cataract, occupying perhaps five or six years, whereas the formation of common cataract is generally effected within as many months: these are circumstances which enable us to pronounce the disease to be lenticular glaucoma in the second stage, and vision likely to be restored by the removal of the lens. This is an important fact, because practitioners are apt to conclude, when they see a green opacity behind the pupil, that the case is one of amaurosis, as well as of change in the refracting media of the eye. Hence patients are left as incurable, to whom the removal of the glaucomatous lens might restore vision. In the cases in question, a careful examination shows that vision is not extinguished, but that the eye retains nearly the same degree of sight as does a cataractous eye; the eyeball is not hard and stony to the feeling, as it is in the third stage, when, to a glaucomatous state of the lens, there are added a dissolution and an accumulation of vitreous humor; the sclerotica is not thinned, so as to allow the choroid to shine through; nor are the external vessels of the eye enlarged and varicose, as in the advanced and hopeless stages of the disease.

"It sometimes happens, however, that incomplete amaurosis attends the second stage of glaucoma, as in Shaw's right eye, and then the operation proves fruitless.

"In the third stage of glaucoma, the hope of doing any good by an operation is gone; and from the dissolved state of the vitreous humor and varicose condition of the vessels, there is much risk in attempting such a thing.

"I have already hinted that the different elements of glaucoma do not present themselves in the same invariable order. The retinal, or amaurotic element, for example, is often the first to attract notice. WELLER thinks that it is always the first in the series of morbid changes, for he says 'Primum hujus morbi symptoma visus defectio est, pupillæ color subviridis multo serius demum animadvertitur.'* But I believe it were more conformable to the fact to say, that in such instances as WELLER has taken for the ground of this remark, an amaurotic eye has become glaucomatous,

* Icones Ophthalmologicæ, p. 22. Lipsiæ, 1824.

than that the group of symptoms which constitute glaucoma has originated in the retina.

"Amaurosis so generally attends the advanced stages of glaucoma, that it has been presumed always, and in all stages, to do so. Mr. WARDROP even goes the length of calling glaucoma a species of amaurosis. 'In some cases,' says he, 'the vitreous humor acquires a dull greenish color, accompanied with insensibility of the retina, a species of amaurosis which has generally been called glaucoma.'* Shaw's case shows the erroneousness of this view; his left eye was affected with distinct glaucoma, advanced into the second stage, yet the retina proved perfectly sensible.

"It is scarcely necessary to remark, that the notion of glaucoma being an opacity of the vitreous humor is incorrect.

"In its advanced stages, glaucoma is attended by dissolution of the hyaloid membrane. An inordinate quantity of vitreous fluid renders the eye preternaturally hard to the touch, and by pressure causes pain, photopsia, and destruction of vision. If the pressure is taken off, by puncturing the vitreous humor through the sclerotica, or even by evacuating the aqueous humor through a small opening in the cornea, a transient amelioration of vision, as well as relief from the pain, is sometimes the result. But the aqueous humor, or the fluid which fills the place of the vitreous humor, being speedily regenerated, the pressure returns with its former effects.

"The primary cause of glaucoma, from whence the whole series of symptoms springs, is unknown. BEER supposed it to be arthritic inflammation: TAYLOR, a preternatural viscidity of the blood, and a cessation of the circulation through the vessels of the crystaline.

"TAYLOR's notions regarding the seat and nature of glaucoma were much more correct than those of BRISSEAU, which so long prevailed. He understood it to be a diseased alteration of the crystaline, implicating its color, transparency and consistence, and ultimately combining with dilated pupil and amaurosis. He erred in supposing the capsule to be affected. His practice was to depress the lens and capsule, under the circumstances which I have enumerated as characterizing the second stage, or, to use his own words, 'where the iris, and immediate organ of sight, maintain their healthful state.'

"Operating, then, for the cure of glaucoma is not a new practice. Of late it has been revived in France by Dr. SICHEL, who styles the second stage of glaucoma, as above described, *cataracte lenticulaire verte opérable.*

"It is necessary to be aware, that a glaucomatous eye is always very susceptible of suffering inflammation and disorganization, even from the slightest operation which may be practised upon it. Arthritic inflammation, with severe and long-continued pain, closure of the pupil, and total insensibility of the retina, is exceedingly apt to be the result of the displacement of a glaucomatous lens; while the operation of extraction exposes the eye almost as much to the danger of complete suppuration. Hence the propriety of having recourse rather to the operation of comminuting the centre of the anterior capsule by means of a fine curved needle passed through the sclerotica, and afterwards repeating a cautious division of the lens every six weeks till it is entirely absorbed. A cataractous eye is generally perfectly healthy, except that the lens, and especially its surface, has become opaque, but in every texture of a glaucomatous eye there is a lurking tendency to disease, against which we cannot be too much on our guard."]

* Morbid Anatomy of the Human Eye, vol. ii. p. 127. London, 1818.

SECTION IV.—AFFECTIONS OF THE VITREOUS HUMOR.

Hypertrophy or *vitreous dropsy.*—I have seen hypertrophy of this structure, that is, enlargement of the globe apparently dropsical, where the contents were transparent, but too thick to escape through a small puncture of the coats at the middle of the globe.

Ecchymosis.—Mr. TRAVERS mentions effusion of blood into the vitreous cells, as occurring after the operation of extraction, or from external violence. (*Synopsis*, p. 200.)

The vitreous humor has been found after death reddened throughout, and permeated by numerous red vessels in the purulent ophthalmia of infants, and in other ophthalmia; yellow, with numerous red vessels in an icteric patient; green, and of increased consistence in an amaurotic eye; in cases of old disease affecting the internal parts, sometimes shrunk and atrophic, sometimes of firm consistence and opaque.*

Synchesis oculi.—A change occurs in the vitreous humor, the nature and causes of which are obscure; it is the conversion of it into a fluid state, and is called *synchesis*, a Greek work, which means melting. It may be the result of chronic internal ophthalmia, or a gradual change in the consistence of the vitreous humor, unconnected with inflammation. The fluid is sometimes of brownish color. The iris is little affected in its appearance or figure; but instead of the natural changes of the pupil, or rather instead of the gradual contraction and relaxation of the iris, there is a peculiar *tremulous* or *oscillatory motion* of the *part.* (See the remarks on *tremulous iris*, in Chapter XVII.)

The globe loses its tension and feels flaccid. The lens often loses its transparency in these cases, and cataract is added to the other affection; the capsule of the lens has been found converted into a cretaceous substance, which could be distinguished by its peculiar yellowish-white color.

BEER† says that, as the result of inflammation he has seen synchesis only after venereal ophthalmia, and that a careful consideration of such cases had led him to the conclusion, that it was owing to the abuse of mercurial medicines, particularly calomel. I have met with no facts capable of supporting such an opinion, which seems to rest merely on the antiquated notions which ascribe to mercury a resolvent power. Having used this remedy freely, both in syphilitic iritis and other forms of ophthalmic disease, I should have had ample opportunities of observing the fact, if BEER's supposition had been correct: such a result has never come under my observation.

I have seen synchesis produced by internal inflammation consequent on penetrating wounds of the globe. I have also seen it with flaccidity of the globe and impaired vision in a boy of eighteen, in whom there was no apparent cause for it. Discoloration of the iris with tremulous motion, cretaceous cataract, and adherent pupil, are sometimes met with, though the globe may not be flaccid: it is doubtful, in these cases, whether the vitreous humor is fluid or not. I have, however, seen it flow out of the eye, as a brownish watery liquid, when extraction of the cataract has been performed in such a case.

Sir W. ADAMS says on this subject, "In three cases which I have seen, it was in one of a pea-green color; in another of a yellowish hue resem-

* The several changes mentioned in the text are exhibited by VON AMMON, lib. cit. tab. 16

† Lehre, vol. ii. § 216.

bling amber; and, in the third, of a dark brown color like porter. In all, the vitreous humor was as fluid as water."*

Usually, this state of the vitreous humor indicates a diseased condition of the internal parts of the eye; and we find accordingly that the retina has lost its sensibility. Such a state of the humor cannot be remedied; and if a cataract should be present, its removal will not improve vision.

Change of structure and consistence.—Mr. TRAVERS has seen the vitreous humor converted into an opaque substance resembling curd; in one case it was like boiled rice. The appearances in the early state are like those of incipient medullary disease. The lens subsequently becomes opaque, and is pushed forwards with the iris against the cornea, giving to the globe a conoidal figure. Mr. T. found this disease of the humor in the eye of a fine infant, eight months old, which he extirpated under the belief that it was a case of malignant fungus. The child grew to be a healthy boy, without any reappearance of disease.†

SECTION V.—AFFECTIONS OF THE LENS AND CAPSULE.

An opaque change in the capsule, incidental to advancing years, and analogous to the arcus senilis of the cornea, has been alluded to in the account of the latter. See Chapter XIV. § 4. Injuries of these structures have been described in Chapter III. § 1.

The subject of cataract generally will be considered in Chapter XXI.

Inflammation of the capsule, either in its anterior or posterior portion, has been described. It has been represented that the vessels are enlarged, so as to contain red blood, and to be visible with a magnifying power; and the appearances under such examination have been delineated.‡ The opacities, the thickening and induration of the capsule, so frequently met with, as well as the irregularities of surface caused by the deposition and organization of fibrine, are closely analogous to the changes produced by inflammation in other membranous structures.§ But the previous inflammatory disturbance leading to these effects escapes our observation; at least, I have not recognized it as a distinct affection.

If the lens is susceptible of inflammation commencing in and confined to itself, the symptoms, excepting the opaque change in the part, are hardly distinguishable. I have not seen them, although cases of cataract occur occasionally, in which the development of the disease is attended with muscæ, luminous appearances, and other evidences of congestion in the internal tunics. This point is adverted to in the chapter on cataract.

If the presence of capsulitis or lenitis were recognized, the treatment directed for internal ophthalmia would be proper.

Inflammation commencing in the iris, or other internal structures, is readily propagated to the crystaline body; hence capsular or capsulo-lenticular cata-

* Treatise on Artificial Pupil, &c., p. 116, note.

† Synopsis, p. 202, pl. 3, fig. 7.

‡ Capsulitis, Lentitis, also Hyalitis, are described by Mr. MACKENZIE, JUENGKEN and ROSAS.

Inflammation of the lens and capsule is dwelt on at considerable length by WALTHER, in an Essay on "The Diseases of the Crystaline Lens, and the formation of Cataract" in his Abhandlungen aus dem Gebiete der praktischen Medicin; Landshut, 1810, with figures.

See also MACKENZIE's Treatise, 3d ed. chap. xii. § 27.

§ VON AMMON has delineated an eye, in which the anterior portion of the capsule is thickened and opaque from interstitial deposition. Enlarged vessels carrying red blood are seen ramifying upon it. Klinische Darstellungen, pt. i. tab. 11, fig. 9.

ract is among the effects of internal ophthalmia. Even purulent ophthalmia sometimes leaves behind, particularly in the infant, a small, circumscribed, central, dense opacity.

The cataracts caused by internal inflammation are complicated with effusion of fibrine, with adhesions and irregularity of the pupil, or its closure by adventitious membrane; with various changes in the state of the iris, and sometimes with deposits of pigment on the surface of the capsule.*

Where inflammation has been so serious as to have produced these effects, it will be found to have extended to the retina, disorganizing it, and thus causing amaurosis. Such results of inflammatory disease are irremediable. Lymph may be removed from the pupil and from the affected tunics of the eye, while the effusion is recent, but not when it has become organized. Hence the condition of the lens and capsule cannot be altered by internal treatment; and the state of the retina in most instances precludes all expectation of benefit from an operation.

Glaucomatous cataract is a result of inflammatory disturbance, more or less active, in the internal structures of the eye; the peculiar appearance of the opacity being referable to the peculiarity of the preceding inflammation.†

Calcareous and bony change of the capsule and lens.—The capsule may be converted into a thin brittle shell of earthy or bony composition‡ (*cataracta gypsea*). Its dead white or yellowish color, and solid aspect, denote clearly the nature of the alteration. When thus changed it may separate from its surrounding connections, so as to constitute a floating cataract. Mr. Gibson found partial ossification of the capsule in a case, on which he was operating; "it felt gritty to the couching-needle, and produced a noise, as if the instrument passed over a piece of dry parchment." (*Practical Observations*, p. 121.) Mr. Wardrop has seen several examples of complete ossification of the capsule, which has sometimes retained its natural form, and contained an opaque lens, while in other cases it has been shriveled, and the lens partially or completely absorbed. The ossified capsule has sometimes been thin and brittle; in other instances thicker and firmer. He has "met with it in eyes where there was ossification of the choroid coat; in eyes where the hyaloid membrane was converted into bone; in some cases of fungus hematodes and in staphyloma."§

The lens has been found ossified more rarely. Mr. Wardrop met with an instance in an eye so shrunk and disorganized that little of the natural structure remained. (*Essays*, vol. ii., pl. 14.) In another instance, of an eye long preserved in spirits, the central portion of the lens was found converted into hard bone, the external laminæ being soft. (Ibid., p. 96, pl. 11, fig. 5.) Mr. Tyrrell found an ossified lens in a lad of fifteen who had received a blow on the eye some years previously; deep-seated inflammation, amaurosis, and cataract had been the result. Subsequently the cataract had passed partly through the pupil into the anterior chamber, keeping up by its pressure inflammation of the iris with much suffering. Mr. T. extracted the offending body, which consisted of an opaque thick capsule, containing a mass about equal to one-third of the original lens, hard and brittle, so that it broke on attempting to separate it from the capsule. (*Practical Work*, vol. ii., p. 343.)

Mr. Alexander showed me an ossified lens. It was of the natural size,

* Such changes are delineated by Von Ammon, tab. 10, fig. 1—4.

† The various appearances of such cataracts are represented by Von Ammon in the last eight figures of tab. 10.

‡ Mr. Wardrop's Essays, vol. ii., pl. 11, fig. 6. Von Ammon's Klinische Darstellungen, pt. i., tab. 9, fig. 22.

§ Lib. cit., p. 114—117, pl. 11, fig. 6, pl. 14, fig. 1 and 2.

hard as bone, perfectly opaque, and scabrous on the surface. In an eye rendered amaurotic by disease of old date, this lens had passed into the anterior chamber, where it excited so much irritation, that its removal was necessary.

Mr. Middlemore says that he has removed the ossified lens and capsule, by a surgical operation, on ten occasions. (*Treatise*, vol. ii., p. 52.)

The changes now described are met with in eyes which have been affected with severe and long-continued internal inflammation, either from injury, or, more frequently, from internal causes, and which have thus become completely amaurotic. If this kind of cataract, having become loose and displaced, should be a source of irritation, it must be removed through an opening of the cornea. In two instances Mr. Tyrrell depressed cataracts of this kind, at the request of the patients, to get rid of the deformity caused by the presence of the opaque body in the pupil. (Lib. cit., p. 344.)

Spontaneous passage of the crystaline into the anterior chamber.—A few instances are recorded, in which the lens, either in an opaque, or in its naturally transparent state, has come through the pupil into the anterior chamber without any apparent cause. In one instance, observed by Professor Himly,* the vitreous humor was in a fluid state; in the others, the eye was more or less diseased. The previous changes in the organ, and the mode in which the displacement occurs, are not however as yet clearly understood. The presence of the lens in the anterior chamber, as in the instances in which it becomes thus displaced from external injury, sometimes causes so much inflammation and pain as to render its removal by incision of the cornea expedient.

From the two following cases, related by Professor Chelius,† of Heidelberg, it would seem that this spontaneous prolapsus may occur in eyes previously healthy. "A robust man, about thirty years of age, felt suddenly a violent pain in the left eye; at his admission, a few days afterwards, great intolerance of light and lachrymation were present; the conjunctiva and sclerotica were injected. The iris was not changed in color, but its upper margin was pushed forwards. Part of the lens protruded into the anterior chamber, transparent, though of a grayish-yellow hue. Under suitable treatment, the inflammatory symptoms subsided: the lens remained in its position, and after a few weeks gradually became opaque, so that sight was completely lost. The patient would not consent to the performance of extraction. A middle-aged woman, who had formerly been subject to rheumatism, was affected with rheumatic ophthalmia and spontaneous prolapsus of the lens, accompanied by the same symptoms as in the preceding case. The inflammation having been subdued, extraction was performed, with partial recovery of sight.

In a case related by Professor Ammon,‡ a serious injury of the eye, had occurred in early life, followed by "a prolapsus of the choroid coat, which drew the pupil outwards, and increased to such size by accumulation of fluid within, that its removal became necessary, and was successfully performed by Dr. Schmaltz, of Pirna. The patient could use her eye after the operation, although she felt weakness in it, which did not trouble her much." Many years after, (April, 1830,) having had occasion to exert herself considerably, she felt pain in the eye: the sight became very dim, and her husband saw what he thought a bladder in the anterior chamber. Various means were used without relieving her pain, which was considerable, and

* Loder's Journal, vol. i., p. 127.
† Heidelberger Klinische Annalen, B. iv. st. iv. p. 521.
‡ Zeitschrift fur die Ophthalmologie, Band i., p. 260.

she consulted Professor Ammon in August. The eye was now inflamed, painful, and watering, the anterior chamber being completely filled by an opaque lens. The pains were relieved, but returned with great violence, and several remissions and exacerbations occurred till the month of October, from which, until the time of writing the history, in December, the patient had been easy. On each alleviation of the inflammation and pain, the lens underwent visible diminution, and it was thus reduced to one-third of its natural size, lying obliquely in the anterior chamber, and leaving the pupil free. Vision was lost.*

Mr. Middlemore† saw a patient in whom the lens, retaining its transparency, had passed spontaneously into the anterior chamber. He had previously lost the sight of the right eye: some years after confusion of vision came on in the left, without any assignable cause. The lens, preserving its figure, size, and transparency, was found in the anterior or posterior chamber, according to the position of the head. There was no useful sight. As the eye thus appeared amaurotic, and was free from irritation, it was not thought proper to extract the lens.

The opaque lens may become detached from its surrounding connections, and pass into the anterior chamber. A lady had cataract, which had formed with pains in the head, redness and uneasiness in the organ. She experienced a violent attack of headache, with pain in the eye so severe that she felt as if the organ had been traversed by some foreign body. An opaque lens was found in the anterior chamber, but still partly engaged in the pupil. It was extracted with favorable results.‡

Another patient, thirty-one years of age, had cataract since the age of six. The opaque body sunk behind the iris at the time of puberty. At nineteen, in consequence of exertion in military duty, the opaque lens came into the anterior chamber, and caused so much pain that he left the service. Demours dropped a solution of belladonna into the eye, and directed the patient to lie on his back for twenty-four hours. The lens went back behind the pupil, and continued there for eight years and a-half, when it again passed forwards. By varying the position of the head, he could place the cataract either in the anterior or posterior chamber.§ Another instance is mentioned by Demours of a patient who had lost the sight of one eye from cataract for fourteen years. He experienced a violent disturbance with convulsive movements and fever during the night, and found in the morning that he had regained his sight. The cataract had sunk behind the iris, leaving the pupil quite clear. There was slight tremulous motion of the iris.‖

Dr. Ullmann,¶ of Marburg, extracted the lens from the anterior chamber of a patient, thirty-seven years old, in whom cataract had taken place before the age of twenty. This female, in whom menstruation had begun late, and been very irregular, and who had suffered much from catarrhal and rheumatic affections, pains in the head, erysipelas of the face, and disordered digestive organs, represented that the lens had been in the anterior chamber nine months, having previously passed occasionally through the pupil, and returned on lying down. Since the lens had been permanently in its unnatural situation, there had been great pain in the eye and head, with frequent inflammation of the former, and muscæ volitantes on the opposite

* In Ammon's Klinische Darstellungen, pt. i., tab. 9, fig. 11, an eye is represented with the transparent lens lying in the anterior chamber. A similar view is given in Langenbeck's Neue Bibl., vol. iv., tab. 1, fig. 3. He merely says that it was the case of a young man, and that he removed the lens through an incision of the cornea.

† Treatise, vol. ii. p. 49.

‡ Demours, Traité des Maladies des Yeux, tom. iii. obs. 449. § Ibid., Obs. 450.

‖ Ibid., p. 395. ¶ Zeitschrift fur die Ophthalmologie, vol. ii. p. 129.

side. The anterior chamber was filled with a brownish-gray cataract, squeezed against the cornea, which Dr. U. found it necessary to remove. It was a capsulo-lenticular cataract; the capsule formed a thick cretaceous shell, in the cavity of which there was a small nucleus of the lens. The pains ceased after the operation, and the health was much improved. At the end of some months the pupil was clear, and there was considerable vision.

CHAPTER XX.

AMAUROSIS, AND OTHER DEFECTS OF SIGHT.

SECTION I.—GENERAL OBSERVATIONS ON AMAUROSIS.

The imperfection or loss of sight, which results from affection of the nervous apparatus belonging to the eye, whether that affection be seated in the retina, the optic nerve, or the sensorium; whether it be idiopathic or primary, sympathetic or secondary; whether it consist in vascular congestion, inflammation, or organic change, or simply in functional disturbance, is called Amaurosis. This word which is Greek, (αμαυρωσις from αμαυροω, *obscuro*, to darken,) considered etymologically means dim or darkened sight; it is a general term, embracing affections of the nervous visual apparatus in all their forms and degrees. Amblyopia, (αμβλυωπια, *hebetudo visus*, from αυβλυς, *hebes*, obtuse, dull, and οψις, sight,) to which the epithet *amaurotica* is sometimes attached, denotes the less considerable degree of the disease, in which objects, even of the smaller size, can be recognized, but are seen imperfectly. The expression, Gutta Serena, employed by the writers of the middle ages, is often used as synonymous with Amaurosis: it is more properly applied to that full development of the nervous affection, in which complete blindness has been produced; the patient can no longer discern objects however large; he can perhaps distinguish light from darkness, or he may be unable to make that distinction. This term seems to have been derived from the pathological notions formerly prevalent respecting the cause of blindness. It was supposed to result from the effusion of a humor or fluid at or behind the pupil; as the latter opening retained its natural blackness in amaurosis, the effused drop was said to be clear. In the following passage of his address to light, Milton translates literally this technical expression of *Gutta Serena*—

> . . . . . "But thou
> Revisit'st not these eyes, that roll in vain
> To feel thy piercing ray, and find no dawn;
> So thick a *drop serene* hath quenched their orbs,
> Or dim *suffusion* veiled."

*Suffusion** is also a technical term, employed by Celsus and other medical writers of antiquity, to denote generally imperfection or loss of sight, whether arising from cataract or from affection of the nervous struc-

* In Greek, υποχυμα or υποχυσις, which as employed by the earlier Greek writers, include amaurosis and cataract; for the cases were not then distinguished. Subsequently, the latter was called γλαυκωμα.

ture. The latter has sometimes been called *suffusio nigra*, or *cataracta nigra*,* because the pupil generally retains its natural blackness.

Since amaurosis may arise from affections of the sensorium, of the optic nerve, or of the retina, we can understand how it happens that it sometimes appears in both eyes at once; that it may be confined to one eye, or that, having taken place in one, it may attack the other also after a longer or shorter interval.

Amaurosis may be induced by causes acting immediately on the nervous apparatus of the eye, such as excessive exertion of the organ, or a stroke of lightning; it may arise, secondarily, from sympathy between the nervous structure of the eye, and some other previously affected organ, as from irritation of the stomach, or of the nerve of the fifth pair, or it may be a symptom of affection of the sensorium more or less general. Hence the distinction of the complaint into *idiopathic*, *sympathetic*, and *symptomatic*. According to differences in degree and duration, it is called *incipient* or *recent*, *inveterate* or *confirmed*, *partial* or *imperfect* (*amblyopia*), and *complete* (*amaurosis* strictly so called, or *gutta serena*).

It has been divided into *organic*, and *functional* or *dynamic;* the latter being supposed, at least, in many cases to be sympathetic. The distinction would be important, if it could be clearly established during the patient's life: unfortunately, we cannot accomplish this. The retina is withdrawn, by its situation, from direct observation and investigation; its diseases produce no visible changes in the exterior of the globe, from which we can determine the exact nature of the affection; and, as they do not terminate fatally, we are deprived of the light which pathological inquiries after death might throw on the subject. Hence it is a mere matter of conjecture, in many instances, whether the nervous structure of the eye is affected organically or only functionally. Indeed, if we could see the parts, it might not be so easy, as the familiar employment of these terms implies, to establish the distinction in question; for medical inquiries have not yet determined the exact limits of the changes which they call organic. We apply the epithet functional to those diseases which produce no changes in a part recognizable after death. But we cannot infer in these cases that no alteration has existed during life. The state of an organ necessary to the correct execution of its function is a living not a dead condition; it requires, not merely a certain organization, as we find it after death, but a supply of healthy blood in a certain quantity, a natural state of nervous influence and sympathy, and perhaps other circumstances not clearly understood. If all these conditions are combined, can we consider it possible that the function should be disordered or interrupted? If one or more should be altered or wanting, can the disease be properly regarded as simply functional? Vascular congestion is an obvious deviation from the normal state of a part. If the retina, or any other organ, be said to be functionally disordered, when its vessels appear twice as numerous and large as in the normal condition, the expression must be employed too loosely to convey any clear information. Some restrict the term organic to alterations in the essential structure of an organ, thus excluding changes in the state of circulation, even although they should be visible after death. Since, then, the epithets organic and functional are indefinite, being employed in different senses by different persons; since they do not denote generally, well ascertained and clearly

* The Germans apply the same substantive *staar*, to cataract and amaurosis, distinguishing them by the epithets *gray* and *black*. Thus cataract is *graue staar*, and amaurosis, *schwarze staar*. The German *staar* is the name of the starling. The Greek καταρακτης, from which *cataract* is derived, is not only applied to a waterfall, but also to a bird of the cormorant kind, perhaps the pelecanus bassanus.

understood conditions of parts; and since the situation of the nervous apparatus of sight renders it impossible for us to know its exact state in most instances, I consider this distinction of amaurosis to be of little practical utility, but, from its vagueness, rather calculated to mislead. We may, however, employ the terms conveniently to denote the general character of disease, remembering that they are not used strictly, and that, from the completely concealed position of the retina, the propriety of their application is often doubtful.

Amaurosis has been divided into the *continued* and the *intermittent*,* the latter being either *periodical* or *irregular*. It has been further distinguished into the purely *local* or *nervous*, and the *complicated*. In the former the affection is confined to the nervous structure; while, in the latter, there is at the same time disease of other textures in the eye, or of other organs. Cataract and strabismus are complications of amaurosis situated in the visual apparatus; the combinations with diseases of other parts, or with morbid constitutional dispositions may be very various.

Choroiditis, inflammation of the internal tunics, glaucoma, dropsy and atrophy of the globe, and some other affections, are occasionally described as amaurosis complicated with other disorders. I think it better to confine the name of amaurosis to the instances in which the disease has commenced in, and been originally confined to, the nervous structure. In course of time, other changes, such as cataract, may be superadded to the nervous affection.

The diseases of the nervous apparatus are less understood than those which affect other parts of the eye. They do not come under our immediate observation during the active state of disorder; and we very seldom have the opportunity of exploring, after death, the pathological condition of the affected parts, especially in the instances of most frequent occurrence, where the disease is seated in the retina. Hence the attention of medical observers has been directed to the impaired vision, the various modifications of defective sight, the pain in the eye or head, rather than to those changes in the nervous structure, constituting the real disease, of which these circumstances are merely symptoms. Amaurosis and amblyopia, then, like dyspnœa, indigestion, and jaundice, are merely names of symptoms, with which we are obliged to be contented, in our ignorance of the morbid conditions producing them. Our notions of the nature and treatment of these nervous affections must remain imperfect, until they can be founded on a more correct pathological knowledge of the diesased parts. How should we be able to treat diseases of the lungs or stomach, if we knew nothing more of the matter than the simple fact, that respiration and digestion were disordered and imperfect? Could we expect any beneficial result, if we should follow in these cases the same course which has been often pursued, and is still recommended in treating weakened sight, that is, to administer a variety of stimulating and tonic remedies in order to remove the imaginary

* [A very remarkable case of intermittent amaurosis was related to the Reading Pathological Society by Mr. Bradshaw. The subject of it was a French lady, aged 37, who was seized with fits of complete blindness. They came on suddenly without probable cause, night and day, irregularly, without periodicity, and each fit lasted about three hours. During the attack the pupils were widely dilated, there were complete blindness and perfect immobility of the eyes and their appendages. After the attack they resumed their wonted activity, and were apparently in a perfectly healthy condition. In other respects the lady was in the best possible health. This affection had continued for some years, and the fits recurred with about the same frequency, viz., three in a fortnight. She had submitted to a variety of treatment without benefit. Her sister was affected in a similar manner.—*Prov. Med. & Surg. Journ.*, 24 July, 1844]

debility or torpor, on which the impaired function has been supposed to depend?

As the true nature of amaurotic affections is not yet understood, we cannot be surprised at finding that the divisions of the subject, even in modern works, are objectionable. It has been divided into organic and functional, although we are without data sufficient to mark the distinction. Of the latter, the following subdivisions have been adopted: viz., increased sensibility, diminished sensibility, and paralyzed condition of the structure. As these are merely degrees of impaired function, and may all exist successively in one and the same case, they can afford no proper grounds for nosological distinction. Again, species have been established on very questionable, if not obviously erroneous grounds. Thus, in the epileptic, convulsive, and paralytic amauroses of BEER and others, the impaired vision and the concomitant symptoms, from which the specific names are derived, instead of standing to each other in the relation of cause and effect, are merely joint results of common causes. Although BEER has a chapter devoted to the amaurosis caused by certain vegetable bitters, and narcotics, and by lead, it is at least very doubtful whether either of these can produce the affection in any degree. We can admit that the nervous structure of the eye may be diseased in the rheumatic and gouty, as well as in other persons; but it will require clearer evidence than we possess at present, to show that there are distinct gouty and rheumatic amauroses.

To avoid all ground of dispute, we may consider the subject under three divisions, according as the disease proceeds from affection of the sensorium, or of the optic nerve, or of the retina. I must, however, observe beforehand, that we cannot always make the distinction quite satisfactorily. The evidence during life leaves us sometimes in doubt whether the case ought to be referred to one or another of these heads.

Perhaps there might be reason for establishing a fourth division of amaurosis arising from affection of the ciliary nerves. These, and the retina, although not actually connected in the eye, are so intimately united in function, that they exert a powerful mutual influence. The pathology of this subject, on which I have made a few remarks in the subsequent division of this chapter on *symptomatic and sympathetic amaurosis*, requires further elucidation.

SECTION II.—AMAUROSIS FROM AFFECTIONS OF THE BRAIN.

Temporary or permanent blindness may result from compression or severe concussion of the brain.

I have related two cases at pages 117 and 118, in one of which complete blindness, and in the other, imperfect vision in one eye, followed concussion, and were the only permanent consequences of the injuries.

In another instance of concussion the left eye remained totally blind. The injury was not particularly severe, nor attended with danger; and the sensorial functions were not impaired in any other respect. The eye and the surrounding region suffered no direct injury: and the occurrence of blindness was not noticed till the patient began to recover from the accident. The insensibility to light was complete; the pupil was partially dilated; the independent motion of the iris was lost, but it moved in harmony with that of the other eye. There was no other visible change in the organ. The patient remained under observation and treatment for some weeks; but no improvement of vision was effected.

While these sheets are passing through the press, I have seen a patient

who was stunned by falling down a flight of steps in the night. There was no external wound; but the right temple had come to the ground. He found himself blind with the right eye, but had no other symptom of injury of the head. When I saw him, on the fourth day after the accident, no active measures had been adopted. Both pupils were about the middle size; the iris moved very slightly in each eye, perhaps less in the right than in the left. He could not see the persons who stood round him in the room; but, in looking straight forwards, he faintly discerned an individual placed on his right side.

In the third volume of the *Glasgow Medical Journal*, at p. 201, Dr. Auchincloss has reported a case of injury to the head accompanied with complete amaurosis, in which the iris retained its mobility.

"James Armour, aged twenty-seven, a quarrier, admitted 8th of May. The accident had happened a week previously, and was occasioned by a quantity of earth falling upon him. He remained insensible for two hours, during which, considerable hemorrhage is said to have taken place from the right ear. On recovering, he felt acute pain on the right side of the head for which he was twice bled with marked relief. On admission, he had little or no uneasiness, and complained chiefly of giddiness when he attempted to raise his head from the pillow. He was perfectly blind of the left eye, the pupil of which, however, contracted freely on exposure to light. The sense of hearing in the right ear was much impaired. His mouth was slightly drawn to the left side, which deformity increased greatly when he spoke." The other symptoms were nearly removed in the course of a month, but the sight was not recovered.

Amaurosis occurs as a symptom of cerebral disease, either when the latter is general, and therefore includes with the rest that portion of the sensorium with which the optic nerves are connected, or when it is partial, and so situated as to affect that part. That the amaurosis owed its origin to sensorial affection, was proved by dissection in the last of the four following cases: the point is not so clear in the first, though the circumstances lead obviously to that conclusion.

Case I.—*Imperfect amaurosis remaining after violent disorder of the head.*—In August, 1826, I saw a lady, forty-two years of age, who was still menstruating. Twelve or fourteen months previously she had been reduced to so dangerous a state by violent disorder of the head, that her medical attendant had discontinued his visits, stating that further efforts were useless, and death inevitable. The gentleman who came with her to my house, and who had been called in on this occasion, found the patient comatose, and discharging her urine and feces unconsciously. By leeches to the head and other antiphlogistic treatment, her state was improved, and she ultimately recovered, but with loss of sight in both eyes. I found the pupils of middle size, with scarcely any sensible change on variations in the quantity of light. The right was a little altered in figure, and slightly dull in color. She could make out, one after the other, capital letters of the second size in the title-page of an octavo book. Her health was excellent. Before the illness, she had suffered much for years from headache; since her recovery she had been thrown from a gig, and freely bled and evacuated. This depletion had completely removed the pain in the head.

Case II.—*Complete amaurosis, with perfect motion of the irides occurring with violent pains of the head.*—A girl of eighteen was brought to me by her mother totally blind. The sight had been gradually lost, with violent pains in the head, three years previously, when she had not begun to menstruate. She had been treated at the time by cupping and other corresponding measures. The pupils were rather dilated, but the appearance of

the eyes was in other respects perfectly healthy; and the irides acted well. She menstruated regularly, but had still pains in the head. The latter were removed by a course of the hydrargyrus cum creta with aperients; but vision was not improved.

Case III.—*Complete amaurosis produced suddenly by sensorial congestion.*—A patient in St. Bartholomew's Hospital, about thirty years of age, with enlargement of the testicle, had been directed to rub a little mercurial liniment on the part daily, and had done this four or five times, when salivation occurred. He felt indisposed in the evening of Saturday, but went to bed without making any complaint. He awoke in the middle of the night with great pain in the head, and feeling very ill. He got up, and thought that the candle, usually kept burning during the night, had gone out, for he could not see it; in fact, his sight which had been perfect when he went to bed, was lost. The house surgeon found him with a full, strong, and frequent pulse, and bled him. He afterwards administered an emetic, which was acting when I saw him at twelve o'clock, Sunday. The pulse was still full and strong, and there was great pain in the head. The pupils were about the middle state, the irides nearly but not quite motionless, and vision so completely extinct, that when a lighted candle was held near the eyes, the patient was not sensible of its presence. I ordered repetition of bleeding, and the application of a large blister at the nape. These means were again repeated. In a week vision was restored, and in a fortnight the patient left the hospital quite well.

Case IV.—*Sudden complete amaurosis from violent inflammatory attack of the brain and membranes.*—A patient, thirty-seven years of age, came under my care at St. Bartholomew's Hospital on the 2d of March, 1832, on account of inflammation of the basilic vein, consequent on venesection: the affection had begun on the 29th of February. The symptoms, which were serious and alarming, subsided under active treatment; the phlebitis had completely disappeared by the 16th of March, when the circulation was tranquil, the rest sound, the tongue clean, and the appetite good. A mutton chop was ordered daily, at the urgent request of the patient, who felt very hungry, and a draught of infusion of cascarilla, with infusion of rhubarb, three times a day. He took the chop, and three draughts on the 17th, slept well, and had the bowels open on the 18th, when he arose and dressed himself, and was found by the dresser sitting by the fire. He said he felt so well, that he could not remain in bed; he complained of being very hungry, and requested that he might have wine or beer at dinner: this was immediately refused. In the course of the morning his friends came to see him, and it was strongly suspected that they had brought him wine or spirits. He could not eat the chop at dinner; but he made no complaint at that time. At six P. M. he was suddenly seized with faintness, loss of sight, and slight pain in the head. He went to bed immediately, and had some calomel and James' powder, followed by an ounce of castor oil in four hours. 19th. Restless and delirious during the whole night; the retinæ are totally insensible, so that he cannot distinguish light from darkness. The pupils are slightly dilated, but contract when a candle is held before the eyes, although he is not aware of its presence. The head is hot and painful. He is sensible, and answers questions rationally. The pulse small and quick, tongue white and rather dry; there is great thirst. (The head to be shaved and covered with cold lotion; cupping on the nape to 14 oz., a blister between the shoulders; a saline draught with antimonial wine every four hours.) 20th. Vision the same. (Twenty-four leeches to the temples: a dose of castor oil; two grains of calomel, with two of antimonial powder every four hours.) 21st. A little sleep towards the morning;

vision improved, so that he can see fingers held before him, and tell the number. In the middle of the day the former symptoms returned in an aggravated degree; delirium came on with continual muttering, and the stools are passed unconsciously. (Blisters to the calves.) Death took place on the 23d. Sero-purulent effusion was found in the pericardium, and purulent infiltration to a considerable extent had taken place in the muscular substance of the heart. Unequivocal evidences of vascular excitement were found throughout the encephalon; the medullary substance was partially softened in several situations. The arachnoid membrane was thickened at the basis of the brain, and yellow, apparently from purulent infiltration. These changes were particularly conspicuous about the infundibulum, and the union of the optic nerves.

Impaired vision, in a greater or less degree, is a symptom occurring generally, if not invariably, in hydrocephalus both acute and chronic. The state of the retina in the former varies according to the stage of the affection. During the period of excitement, there is increased sensibility to light; strong lights are avoided, the eyes being opened only in the dusk; if the lids are separated the cornea turns up behind the upper. When effusion occurs, dullness succeeds to the increased sensibility; the natural direction and harmony of the optic axes are lost; the patients squint and look downwards; the pupils are dilated, or exhibit oscillatory movements, without being sensible to light. In the last or paralytic stage, when convulsions come on, succeeded by palsy, the sight is lost, the pupil highly dilated, sometimes contracted but motionless. There is generally squinting, with fixed direction of the hoop downwards. Sometimes loss of sight is an early symptom of hydrocephalus.

Amaurosis may exist in the chronic form of hydrocephalus, as a permanent consequence of the distension of the ventricles. Mr. Langstaff's museum contains some interesting pathological specimens, illustrating the mode in which the blindness is produced in these cases. The third ventricle is enlarged by the accumulated fluid, and its parietes bulge in front, so as to press on the united portion of the optic nerves.

I examined the head of a female, who died at the age of eighteen, after suffering from hydrocephalus internus for eight or nine years. The symptoms came on and increased very gradually. They first consisted of change in manners and character, inability to learn, or to attend to any subject. There were occasional attacks of pain requiring depletion. The intellectual faculties then gradually declined. She was confined to the house for the last three or four years, and to bed for about two years totally blind. Severe paroxysms of active affection took place occasionally. The pia mater was loaded with serous fluid to an extraordinary degree, forming a loose spongy mass, under which the cerebral convolutions could not be discerned. There were about eight or nine ounces of fluid in the ventricles. The anterior part of the third ventricle was greatly enlarged, so as to cause pressure on the union of the optic nerves.

The eyes exhibit no other change than a motionless state of the iris, with dilated pupil of its natural clear black. In a boy, six or eight years old, in whom the head far exceeded its natural dimensions, and in whom all uneasiness and every symptom of active disorder had been removed, and an excellent state of health produced, by long perseverance in occasional mild antiphlogistic measures, with the use of mercury, total insensibility to light remained, with partially dilated pupils; but the irides acted naturally on exposure to light.

Partial amaurosis, with strabismus and double vision, occasionally precedes an apoplectic attack. It is frequently attended with vertigo and head-

ache, as well as with derangement of other parts. In a gentleman of full habit and short neck, who had many years previously experienced a severe apoplectic seizure, the return of vascular excitement in the head, which had been vaguely indicated for some time by headache, sense of heaviness, lassitude, and various uneasy feelings, was at last accompanied with so much confusion of vision and giddiness, that he could not keep his eyes open.

There can be little doubt that the amaurosis, in the following case, arose from cerebral hemorrhage:

A coal-weigher, fifty-five years of age, lost the use of his right eye suddenly: "Whilst attending to his business, he was suddenly seized with giddiness and slight pain in the head, with the feeling of a snap, as if something had given way. From the immediate effects of this he recovered in a few minutes, but found that he was unable to elevate the upper eyelid; and that when he had done so with his fingers, he saw only the half of objects, and that very indistinctly. He was assisted home, where he remained quiet for two days. On looking at him, the first thing that attracted my attention, was the upper eyelid hanging down over the eyeball so as completely to conceal it. He had no power whatever over it. On examining the eyeball it appeared perfectly sound. The pupil was very much contracted and immovable, being as small as a pin's head; did not dilate with belladonna. Stated that three years previously he had a slight paralytic shock, of which he recovered: and that he had been subject to hemorrhoids, and strongly suspects this attack to have been brought on by their getting better. Bowels were also confined."*

Amaurosis is one of the symptoms attendant on various organic diseases of the head; such as induration, softening, suppuration, tubercles, hydatids, fungus hematodes of the brain, enlargement of the pituitary gland, aneurism of the internal carotid artery, tumors in the membranes of the brain, exostosis, caries or various sarcomatous growths of the bones, especially when these diseases are so situated as to interfere with the optic nerves behind their junction, or with that part of the sensorium with which they are immediately in relation. These affections are accompanied with other important symptoms, which show that the malady is not confined to the nervous apparatus of vision. Among these may be enumerated vertigo, pain in the head, often of the most racking kind, either preceding or accompanying the affection, or coming on at a later period; an impaired state of other senses, or of the intellectual faculties; delirium, or sleepiness, and coma; convulsions, impaired speech, hemiplegia, or other paralytic affections. One eye only or both may be affected, according to the situation of the internal disease. Dark appearances are seen (*scotomata*), and objects appear confused or distorted (*metamorphopsia*). There is often increased sensibility to light, with luminous sparks or flashes before the eye. According to the period and character of the complaint, the pupil may be either contracted or dilated. Squinting occurs occasionally, sometimes with convulsive movements of the globe or eyelids.

[A very interesting case of amaurosis, resulting from a fungoid tumor at the base of the cerebellum, is recorded by Mr. H. Taylor, in the *Lancet* for August 23d, 1845.

The subject of it was a married man of good conformation, nervous temperament, and fair complexion, having large prominent eyes, with blue irides. He appears to have been subject to severe headaches from an early age, but otherwise enjoyed good health, until eight or nine years ago,

* Mr. Knox, *in Glasgow Medical Journal*, vol. iii. p. 348, 349.

when he became affected with dyspepsia, which was attributable to a habit of eating his meals hurriedly, and without any regard to wholesome diet, at the same time he was sedulously engaged in business. He was then troubled with flatulence, noises in the head, and total deafness in the left ear.

In the beginning of 1840, being then forty years of age, he found his eyesight fail, with frequent lachrymation and muscæ volitantes. There was then no obvious change in the pupil, and the conjunctiva was merely in a relaxed state. As the gastric disturbance was also much increased, the failure of sight was referred to this, and by the prescription of Mr. Ware he was bled, took Plummer's pill, and used astringent collyria, with but little benefit. In July of the same year he had an attack of articular rheumatism, and from this time became subject to increased action of the heart.

In January, 1841, he consulted Mr. Tyrrell, who pronounced him to be amaurotic, and considering the case, from the first, as of cerebral origin, but not despairing of a recovery, he put him upon a strict regimen, and prescribed an alterative course of mercurials and sarza, with occasional purgatives. Contra-irritation was kept up by blisters on the forehead and behind the ears. Ointments of iodine and of veratria were successively tried: our patient was also cupped occasionally over the occiput and nape of the neck, and a seton was kept introduced in the latter situation for many months.

This plan of treatment was rigorously pursued for two years without any good result. His sight had now become so bad, that he could not walk out unassisted. The pupils were much dilated, though still obedient to a strong light, and the globes appeared more prominent and firmer than natural. His headache recurred with greater severity, chiefly affecting the left side of the occiput.

In January, 1842, he was attacked with neuralgic pains, commencing in the left sciatic notch, and extending, in the course of the sciatic nerve, to the outer side of the knee, and down the leg as far as the ankle. The pain, which was agonizing, occurred in paroxysms, and seemed to increase by exercise of the limb, and to subside altogether at night, or on his assuming the recumbent posture.

No very marked relief was obtained from blistering in the course of the nerve, nor from the endermic use of morphia and opiate frictions; neither was the internal exhibition of narcotics any more successful, and the pains only wore off as his increasing debility obliged him to keep his bed. Mr. Tyrrell saw him occasionally at this period, and gave as his opinion that the neuralgia, as well as the amaurosis, was dependent on a tumor at the base of the cranium; and with this impression of the case, all acute treatment was relinquished, and only such medicines were given as the state of the digestive organs might require. There was now very great impairment of muscular power generally, but no paralysis nor loss of common sensibility. The left leg wasted visibly, at the same time that he was becoming generally emaciated. His appetite, however, continued good, and latterly it was found difficult to satisfy his wants; the bowels were so torpid as to require the almost daily administration of purgatives.

In November, 1842, he had several attacks of delirium, with excitement, like that of drunkenness, which were followed by stupor; these afterwards assumed much of the character of epilepsy, there being clonic convulsions, usually in the night, and occurring at intervals of a month.

From this time he remained in bed from sheer exhaustion, and sank into a state of apathy, with apparent moroseness of temper; he expressed

himself well in conversation, but with much slowness, as if a great effort were necessary to collect his ideas; and when roused he seemed to have the full use of his mental faculties. The senses of taste and smell were not at all impaired; his hearing on the right side was very good, but vision was now completely extinguished, so that there was no perception of light left. There does not seem to have been any excitement of the sexual appetite, and all that could be elicited from the nurse on this point was, that he had lost all sense of decency. He lingered on in this state during sixteen months more: at the conclusion his urine and feces were passed unconsciously; and during the oppressive weather of August, 1844, his appetite failing him, in a few days he expired.

An examination of the body was made sixteen hours after death. The bones of the skull were thin, and the diploe scarcely visible. The dura mater was healthy, and not unusually adherent. The vessels of the pia mater were much congested, and serum was effused extensively into the cellular tissue between the convolutions. The brain was extremely firm, and on dissection presented a great number of large bloody points. The lateral ventricles were distended with clear serum, of which four or five ounces were collected. The septum lucidum was broken down; the choroid plexuses were shrunk and pale, and had several small serous cysts formed on them. On removing the brain, the optic nerves were observed to be very small, and of firm consistence; on cutting away the attachments of the tentorium, a bulging of it was seen on the left side, and when this was punctured, about half an ounce of gelatinous fluid, of a greenish color, escaped. The cerebellum was now raised up, and under its left hemisphere a tumor was discovered, lying on the petrous portion of the temporal bone, and firmly attached to the auditory foramen. There were also extensive connections between it and the cerebellum, which was hollowed out to receive it. In attempting to dissect it out, so as to preserve its relations to the cerebellum, the morbid growth was found to have extended some way into the auditory canal, which was widened considerably, and the surrounding bone appeared to be eroded. The tumor, when removed, was an oval mass, compressed from above downwards, and having the following measurements:—Length, two inches, greatest width, one inch and a third, and vertically, one inch. Its surface was lobulated, and studded with small serous cysts, the color of a darker tint than the brain, owing to the greater vascularity of its coverings; these consisted of the arachnoid membrane and a thin cellular layer, which were continuous with the investments of the cerebellum, forming the only bond of union between them. Situated in the angle between the lateral mass of the cerebellum and its large peduncle, it pressed also on the pons varolii. The seventh nerve, and the divisions of the eighth, passed under it to their respective foramina, without being at all flattened or displaced.

A section of the tumor showed a dense structure of glandular firmness, made up of whitish arborescent fibres, leaving numerous interstices, which contained some gelatinous serum. The striæ of white tissue were speckled here and there with black points, which proved to be coagulated blood, and sections of minute vessels. One half was shown to Dr. Walshe, who considered it to be a variety of encephaloid cancer, and rare, as occurring in the membranes, and not in the substance of the cerebellum.

In the thorax, the heart was found much enlarged, from dilated hypertrophy of the left ventricle. There were several patches of cartilaginous deposit at the bases of the mitral valves, and the aorta was somewhat dilated at its commencement, but healthy in its valves and lining membrane.

Old adhesions existed between the ribs and middle and lower lobes of the left lung; the latter organ was much congested, and the bronchiæ filled with frothy mucus.

In the abdomen, there was nothing worthy of notice besides the kidneys, which were in an advanced stage of granular degeneration.

Another very interesting case of amaurosis, produced by a fungoid tumor of the cerebellum, was communicated to the Birmingham Pathological Society by Mr. Simons, and is recorded in the *Provincial Medical and Surgical Journal*, for April 30th, 1845.

A porter, aged twenty-five, of rather full habit of body, about two years back, was taken with pain and giddiness; this was repeated two or three times, for which he was bled, purged, &c.; his eyesight now began to fail him, and pain in the head continued. Occasionally, upon going home at night, he could not see his way for some time. He then applied to the Eye Infirmary, where he underwent a course of treatment, but gradually got worse, and became completely amaurotic. At this time he was admitted into the General Hospital, and continued there without any improvement for about six weeks. "He now came under my care, when he principally complained of pain in the back of his head; the eyes were bright, quite insensible to light; he was very morose and dull in disposition, but was easily excited, and became very passionate; had no inclination whatever to occupy himself in the manner that persons in his unfortunate situation do, but preferred sitting in the corner from day to day. There was slight imperfection in walking.

"He went on in this way without any material alteration until about four months before his death; when one morning I called, and observed the right eye very much inflamed, and the cornea ulcerated; there was no discharge; no sensibility to light; and so little pain, that neither he nor his friends were aware of it. By treatment the eye quite recovered its wonted clearness. His bowels now began to be very costive, and he had great difficulty in keeping them open; he also had great difficulty in voiding his urine.

"His health now began to give way; his appetite failed him, and he complained of most violent pain in the occiput; always obliged to sit in the stooping position, or resting his forehead on the table. For about two months before his death, even this position was not sufficient to give him ease, but the lower he could bend his head the easier he felt, so that for two months preceding his death he used to sit on a chair by the table, with his head bent below the level of the table, and in this position take his meals, which he would reach off the table with his hand, and convey to his mouth in this crouching position. He died on the morning of the 21st of January, without any aggravation of his symptoms."

Sectio cadaveris, forty hours after death.—"The membranes of the brain healthy, the substance quite firm; the left ventricle contained fully half a pint of clear colorless fluid, the right about four ounces; the substance of the brain was so firm that the finger was moved about in the ventricles freely, without injuring the septum lucidum; corpora striata and optic thalami, healthy; most of the base presented a degree of softening, the more decided by comparison with the consistency of the remainder of the brain; this condition affected more particularly the surface of the crura. The pons and medulla oblongata had quite lost their consistency.

"The cerebellum was very large. It contained a fungus as large as an orange, which occupied the left and a part of the right lobe. It grew from the back part of the organ, where it was attached by an extensive base,

and projected into a cavity within the cerebellum, occupying the place of the natural nervous tissue. The remaining substance of the organ, which enclosed this cavity in front and on the left side, was about half an inch thick, and quite healthy. The inner surface of the cavity, and the surface of the fungus, were thickly coated with a matter, which had much the appearance of inspissated mucus, though rather less tenacious. The texture of the fungus was somewhat softer than the natural condition of brain; it seemed to be composed of altered cerebral substance."]

SECTION III.—AMAUROSIS FROM DISEASE OF THE OPTIC NERVE.

Fractures of the skull at the anterior part of its basis may cause pressure in one or both optic nerves, or on their union, or may otherwise injure them. They may be variously affected by diseases of the bone, or of its membranous coverings in the same situation, or in the orbit. Such disease may have a venereal origin, which may be indicated by the simultaneous existence of other symptoms referable to the same cause.

A remarkable example of the latter kind is related by Mr. Wilson, in the third volume of the *Transactions of a society for the improvement of medical and chirurgical knowledge*. (Art. xii. p. 115.)

In the spring of 1803, the patient had been attacked with very severe deep-seated pain in the orbit of the left eye, for which antiphlogistic means, nervous medicines, change of air, and various other remedies were tried without any advantage. The complaint, on the contrary, became worse; "the sense of hearing in the left ear was now totally lost. The levator palpebræ muscle of the left side became paralyzed, and a great degree of strabismus was produced by the rectus externus having also lost its power. The pupil of the left eye became much and constantly dilated, and the sight of that eye was lost. The right angle of his mouth was permanently drawn to the right side. An extreme hoarseness took place, and his articulation became so indistinct, that he could not be understood even by his friends. He lost the power of swallowing solids, and swallowed fluids with great difficulty, as the attempt brought on a distressing sense of suffocation."

When Mr. Wilson saw the patient in 1806, there was hemiplegia of the right side. Violent pain continued in the left orbit: there were severe pains in the cervical vertebræ, and at the top of the shoulder. He could not raise his head from the pillow; he could scarcely sleep at all, and had no respite from excruciating pain; in short, dissolution was hourly expected. Mr. Wilson also learned that he had had chancres and buboes two or three times before his present illness commenced, and had used mercury until they had disappeared. He further discovered enlargement of the tibia and of the cervical vertebræ, swelling of the acromion and spine of the scapula, of the os brachii near the insertion of the deltoid, and of the clavicle, which was three times its usual thickness. Deeming the disease to be venereal, Mr. Wilson immediately began the use of mercury by frictions, and placed a seton in the back of the neck. The mouth became affected in four days, and the influence was continued for eleven weeks, with rapid disappearance of the symptoms, and proportional recovery of strength and health. The enlargements of the bones were reduced, and the pains removed; the muscles of deglutition and those of the paralyzed limbs recovered their power. The pupil of the left eye remained somewhat dilated, and the upper eyelid could not be completely elevated. Objects and colors could be distinguished with the left eye, and even small objects when green spectacles were used, and the

left eye only was open. When both eyes were used, double vision with some confusion was produced.

Amaurosis may be caused by injury of the optic nerve in penetrating wounds of the orbit, or in fractures with displacement of the orbital parietes; by pressure from orbital tumors, from exostosis, or other diseases of the socket; or by stretching of the nerve in consequence of protrusion of the globe (*exophthalmia*) from accident or disease. If the protrusion is recent, the amaurosis incomplete, and the replacement of the eye can be satisfactorily effected, vision may be completely restored. (See the case related in Chapter XXIV. § 1.)

Atrophy of the nerve, either in the orbit, or throughout its course, has often been found after death in cases of complete and incurable amaurosis. It is also found in other instances, where the eyes have been seriously disorganized for a long time before death;* hence, when it occurs in conjunction with amaurosis, it may probably be the effect, and not the cause of that disease.

Among the invaluable pathological treasures of Mr. Langstaff's museum, there is a specimen in spirit, consisting of the eyes, optic nerves, and part of the basis of the brain of a man who had been amaurotic for twenty-eight years before his death. The sclerotica and cornea, iris and pupil, choroid and retina are perfectly healthy, so far as an opinion can be formed of the state of such parts after long immersion in alcohol. The optic nerves, in their whole extent, from the globes backwards, are shrunk into white cords, not larger than a small crow-quill. At the point of union they merely lie together without being joined, and each proceeds to its own side of the brain. Where they sweep round the crura cerebri they are gradually confused and lost. Mr. Langstaff has favored me with the following history of the case.

Thomas Maddey died in June, 1821, at the age of sixty-four, in Cripplegate work-house, of which he had been an inmate from December, 1806. He had been subject for many years to severe attacks of gout in the feet, knees, hands, and wrists, by which he at last had become completely crippled. All the fingers and toes were deformed by depositions of what are called chalk stones; and both knees were greatly enlarged by effusion into the joints, the swellings being firm and elastic. He had been blind twenty years when Mr. Langstaff first saw him. Previous to losing his sight, and almost ever since, he had suffered violent pain in the front of the head. He had been under the care of an oculist, who had bled him copiously, and produced salivation. The irides were dark, and completely insensible to light; the pupils greatly dilated. In other respects the organs were healthy. He continued subject in the workhouse to severe inflammatory attacks, having the character of acute rheumatism rather than of gout, particularly in the knees, and he sunk under one of these, which was attended with high fever and delirium. The examination of the head presented obvious marks of recent and considerable inflammatory disturbance in the brain and its membranes, and, besides, thickening of the dura mater, with partial cartilaginous induration and ossification of the membrane, which adhered to the skull with unusual firmness, and cartilaginous and osseous thickening of the arteries at the basis of the brain. The eyes presented a perfectly normal structure. The aorta was converted into a cartilaginous and bony tube. The liver was small, indurated, and granulated. The

* Three examples are figured by Von Ammon in his Klinische Darstellungen, pt. i. tab. 6, fig. 1, tab. 7, fig. 8, and tab. 18, fig. 1. They were cases of staphyloma scleroticæ and atrophy of the globe.

synovial membranes, articular cartilages, and ligaments of the affected joints, were extensively disorganized; but the bones were healthy.

Professor Rostan has detailed the fatal illness and examination after death of a woman seventy-five years old, admitted on account of blindness, into the Salpêtrière, where she had lived several years. The state of her eyes is not described. She died from softening of the brain. "The optic nerves were flattened, diminished in calibre, in a state of atrophy, of reddish appearance like a small arterial tube, and without any resemblance to the whitish cord which they ordinarily represent."*

Dr. Monteath, of Glasgow, who translated Weller's *Manual of the Diseases of the Human Eye*, has mentioned in a note a somewhat similar case.

"Mrs. ——, aged eighty-three, had been completely blind from amaurosis for thirty years before her decease in 1817. She had also been subject to irregular gout, which assumed a variety of forms, and seven months before her death she was attacked with palsy of one side. On opening the head, aqueous effusion was found below the tunica arachnoidea, and in both ventricles. One part of the cerebrum was observed to be of a pulpy texture; but these appearances were most probably connected with the recent paralytic attack, and not at all with the amaurotic. All the nerves, with the exception of the optic, had the usual appearance. On examining the membranous sheaths of these nerves, it was ascertained that their medullary matter had been completely removed, and this change had taken place even nearer to the brain than where the nerves cross each other." (Vol. ii. p. 79, 80, note.)

Demours mentions two cases of amaurosis caused by disease of the optic nerve, in both of which the iris retained its power of motion. The first was a man forty years old, who had lost the sight of his left eye six months before death. The affection, which had come on slowly, had been attended with severe pains in the head, ascribed to his occupation, that of a porter. The eye appeared healthy, and the iris retained its complete mobility. He died of fever in the Hôtel Dieu. The eye was sound, the optic nerve partially softened. The state of the latter is thus described:—"On slitting the sheath of the nerve, I found it, in nearly half its extent, as it were in a state of suppuration, and reduced into a liquid of dirty white color."

The other patient, thirty-six years old, had lost his sight gradually, without pain, for two months before death, which took place from chronic peripneumony. The eyeball was perfectly sound. In the middle of the optic nerve was found a small hard tubercle, of grayish color, about the size of a hempseed. (*Traité des Maladies des Yeux*, tom. i. p. 74—76.)

Von Ammon has delineated the following morbid changes in the optic nerve: thickening of the neurilemma, effusion of fibrine between it and the substance of the nerve, ecchymosis in the situation of the arteria centralis, induration of the medullary texture. (*Klinische Darstellungen*, pt. i. tab. 20, fig. 12—17.)

In speaking of amaurosis which arises from disease of the optic nerve, Beer says that "it is developed slowly, commonly in one eye only, seldom in both. A black cloud appears before the eye, and becomes gradually thicker, while the patient experiences an annoying distortion of objects, without the smallest uneasy sensation in the eye or head; he only feels a slight sensation of pressure in the back of the orbit, as if the globe were pushed out of the socket, of which, however, there is no appearance. In the very beginning of the affection, the pupil is considerably dilated, and the pupillary margin of the perfectly motionless iris is angular at various points,

* Recherches sur le Ramollissement du Cerveau. Seconde edition, obs. ii. p. 28—31.

so that the pupil often presents an irregular pentagon or hexagon. Gradually, but very slowly, a glaucomatous degeneration of the vitreous humor, and even of the lens occurs, forming the only kind of glaucoma that I have hitherto seen without any varicose affection of the blood-vessels of the globe. At last the eye is visibly lessened, but complete atrophy does not take place." He proceeds to observe, that the affection is caused by morbid change of the nervous structure, that he cannot explain its origin, and therefore merely details what he has met with on dissection. "The diseased alterations which I have hitherto met with, have consisted of true induration of the optic nerve, and adhesion of it to the sheath. Within the cranium, the gray and completely shrunk optic nerves, as far as to their connection with the brain, have been without a trace of medullary matter; the thalami nervorum opticorum have had their natural appearance; the neurilemma has been destitute of medulla, tough, not easily torn, and has consisted of a simple vascular membrane. On one occasion, though both eyes were perfectly blind, and had been so for the same length of time, the nerve of the left eye only and its neurilemma were in this state of atrophy as far as the sella Turcica, while that of the right eye was indurated and closely adherent to its sheath, without being in the least shrunk. Between the union of the two nerves and the brain, they were in a perfectly normal state. The left corpus striatum was so hard, that it required a strong and sharp scalpel to divide it, but its color and form were natural. The plexus choroideus was wanting on this side. In three amaurotic persons of this kind, I found hydatids in the sheath of the optic nerve, the medullary substance being apparently pushed aside; and on the most careful examination, I could not discover the lenticular (?) ganglion, (Augennervenknoten.") (*Lehre*, vol. ii. pp. 578, 580, and 581.)

SECTION IV.—AMAUROSIS FROM AFFECTION OF THE RETINA.*

The retina may be affected originally and exclusively, or secondarily, and in conjunction with other parts of the globe. Under the name amaurosis cases of the first description are generally understood; and in order to prevent confusion, it would be well to confine the term to them. In the affections, which either originally or subsequently involve the nervous together with other structures, such as general inflammation of the globe (*ophthalmitis*), inflammation of the internal tunics (*ophthalmitis interna*), whether idiopathic, syphilitic, or arthritic; in glaucoma, in atrophy, and dropsy of the eye, in fungus hematodes, cancer and melanosis, blindness is ultimately produced; and, inasmuch as the retina is disorganized, the eye may be said at last to be *amaurotic*, though the diseases are properly named from other more prominent characters.

The effect of laceration and concussion of the retina, in producing blindness or injury to vision, has been already considered in speaking of wounds

* In compliance with general usage, I apply to the affections considered in the present division, the name amaurosis, without any epithet to denote the particular seat of the affection. This name should be confined to the cases in which either the optic nerve or the retina is the seat of disease. In the other instances, the disease is in the brain, or in its immediate neighborhood, and impaired sight is only one out of many symptoms.

As the characteristic symptoms are not sufficiently known for us to establish clearly and satisfactorily, in every instance, the diagnosis between that amaurosis which has its source in the retina, and other forms of the affection, the following observations are principally, but not exclusively, applicable to the former.

of the globe. (See page 176, and pages 185 to 187.) The cases there detailed show that amaurosis, more or less complete, which sometimes admits of cure, sometimes not, may result from such accidents. Mr. Knox mentions the following instances of partial injury to vision from external violence. "A central, black cloud appeared in the eye from a blow with a chip of stone, beyond which vision was perfectly distinct. There was no other apparent cause for the affection. Mydriasis, in another case, was produced from a blow on the eye with a snow-ball; blood was also mixed with the humors. In a third instance, diplopia and confusion of vision, particularly when looking at distant objects, were occasioned by a fall, which at the time caused insensibility. Strabismus and visus dimidiatus, in a fourth case, were produced by a blow with a stone on the lower eyelid; and in a fifth case, the pupil became perpendicularly oval and dilated, and vision very much impaired, in consequence of a blow on the eyeball with a blunt arrow."*

Mr. Knox observes further, that "a considerable period sometimes elapses between the receipt of the injury and the occurrence of the amaurotic symptoms. In many cases those symptoms do not evince themselves until weeks or months after the receipt of the blow." In some cases, the sound eye becomes affected, sooner or later after the accident, with amaurosis, which may be called secondary or sympathetic. An example is mentioned at pp. 186–7. Mr. Knox mentions the case of a girl, who received a blow from a potatoe on the outer canthus. Vision, though injured, was not destroyed till four weeks after the accident, when complete amaurosis occurred, and the globe afterwards became soft. About five months afterwards, the sight of the other eye failed, and was ultimately completely lost.†

Amaurosis has been sometimes ascribed to the direct pressure of a hard lens on the retina, when the operation of depression has been unskillfully executed. Beer mentions a remarkable illustration of this point. "A patient had become perfectly amaurotic immediately after the depression of a hard cataract in each eye, probably from the lens having been incautiously carried down too far, and thus having pressed on the retina. The cataracts rose again into their places, in consequence of the patient, when in a state of intoxication, having fallen on the head from a high bed. I extracted them, and thus restored sight, after eight years of blindness."‡

That small simple punctures of the retina, and slight transient pressure from the displaced lens, lead to no consequences injurious to vision, is proved by the experiments of Magendie, mentioned at p. 95. In the operation of depression the retina is punctured without any bad effect.

The amaurosis having its origin in the eye itself, which is the most frequent and important form of the disease, arises, in many cases, from inflammation of the nervous structure, and the usual result of such disturbance, namely, organic change, which, if not removed at an early period, becomes so established as to render the part permanently incapable of executing its function. Under the term inflammation may be included all degrees of increased vascular activity, whether designated as fullness or turgescence of vessels, determination of blood, congestion, or as inflammation in its more limited sense. From the structure of the retina, we might expect that it would be liable to such affections. The minute ramifications of the arteria and vena centralis retinæ are connected together so as to form a membrane of extreme thinness, but appearing, after successful injection, to consist almost entirely of vessels: in this vascular network the nervous

* Glasgow Medical Journal, vol. iii. p. 344. † Ibid., vol. iii. p. 345.
‡ Lehre, vol. ii. p. 448, 459.

pulp is expanded, like a thin layer of soft jelly. This delicate organization not only participates in those causes of vascular disturbance which affect the head generally, but is exposed by the nature of its office to numerous, powerful, repeated, and long-continued impressions. Thus it may be compared to the brain, in its structure, and in the morbid influences which it experiences. When the disturbance of its capillary circulation has reached a certain height, interstitial deposition and change of structure may be expected. Von Ammon has found effusion of fibrine on the retina, with adhesion between it and the choroid.* He has also given representations of the membrane under various morbid changes, such as increased vascularity, ecchymosis, thickening and induration, and the formation in its texture of numerous minute black spots.† The retina of an amaurotic eye, dissected by Langenbeck,‡ exhibited increased firmness of texture, with numerous blood-vessels and yellow spots. It has been found, in other cases, thickened,§ opaque, spotted, buff-colored, tough, and sometimes even ossified.‖ It may be probable, as Langenbeck¶ suggests, that the change of color occasionally seen in the pupils of amaurotic eyes, arises from alteration in the condition of the retina consequent on inflammation; but this point is not as yet proved by dissection.

In representing that increased activity of circulation is the most frequent cause of amaurosis, I do not mean to assert that every alteration in the function of the membrane, displayed in amaurotic affections is attended with visible changes of structure: there may be a temporary impression, leaving

* Klinische Darstellungen, pt. i. tab. 20, fig. 1—4.

† Ibid., tab. 19, fig. 4, 5, 7—11. In tab. 20, fig. 7, and 8, it is seen separated from the choroid, and thrown into folds.

‡ Neue Bibliothek, vol. i. p. 56.

§ In an eye, dissected by Magendie, the retina was converted into a white fibrous membrane, very firm, and like an aponeurosis. On its outside, and adhering closely to it, was an osseous stratum, varying in thickness from one-fourth to three-fourths of a line. The choroid adhered to the external surface of this bony layer.—Demours, Traité des Mal. des Yeux, tom. i. p. 73, 74.

‖ In an account of the Ophthalmic School of Vienna, by Dr. Juengken of Berlin, he mentions that it contains a collection of anatomical and pathological preparations of the eye, unique in its kind, as he supposes. Among them is a series of amaurotic and atrophic eyes, in which the retina and ciliary body are ossified. The change begins in the retina from the foramen centrale; a bony ring is formed round it at first, in the middle of which the foramen remains open, and larger than in the natural state. In some eyes nothing is seen but this ring; while in others, the ossification of the retina, which is collapsed and in folds, extends towards the circumference, and there gradually ends. In the most diseased eyes, ossification is seen in the ciliary body as well as in the retina, the change being most considerable in the middle of each organ, and less strongly marked where they approach each other. Graefe und Walther's Journal, vol. i. p. 514.

¶ "What," says he, "can afford a stronger argument that the retina undergoes a material change, than the pale dull color of the fundus oculi so often observed in the amaurotic? If the substance of the retina becomes changed by an inflammatory process, the fine pulpy texture must be lost, it must become incapable of receiving luminous impressions, and sink to the level of organs destined to fulfil less important offices. If we look back to causes, we find in many cases that amaurosis obviously proceeds from various morbid states of constitution (*dyscrasien*), of which the first effect is inflammation. During the prevalence of the humoral pathology, several cases of amaurosis were supposed to result from the deposition of morbific matter. Why do not we proceed in investigating the causes of amaurosis as we do in arranging inflammations of the eye? As there are ophthalmia from dyscrasia, or metastasis, so there may be inflammations of the retina of like nature. In very vascular organs inflammations are always more acute than in less vascular and more nervous structures: hence inflammation of the retina has a chronic rather than acute course."—Reflexionem uber die Natur, Ursachen und Heilung des schwarzen Staares; in the Neue Chir. Bibliothek, vol. i. p. 56, 57.

no traces after death. On the whole, however, impaired vision bears the same relation to the retina and optic nerve, as other symptoms do to the various organs from whose disorders and diseases they proceed.

The prevailing notions respecting amaurosis have been not only different, but almost opposite. It has been supposed to arise generally from debility. Patients commonly speak of their sight being weak, and fancy that it requires to be strengthened. The vague opinions thus expressed seem to be the only foundation for the views which long prevailed respecting the pathology and treatment of amaurosis. Believing that the complaint arose from atony or debility of the optic nerve, medical men have endeavored to combat this state by strengthening treatment, by tonics and stimulants of all kinds, both local and general. As this view of the disease is totally erroneous, the treatment founded on it must be not only improper, but injurious. Let us apply, for a moment, the same notions and treatment to other cases. What would be the result, if we should view diseases of the brain, lungs, or stomach, in the same light; if we should see nothing but the impaired function, and proceed immediately, without considering the state of the organs, to adopt a course of direct stimulation, in order to remove the weakness of the mind, of breathing, or digestion? The pathology of amaurosis must be founded on the same principles as that of the affections just alluded to; and the only successful treatment will consist, with the exceptions to be noticed hereafter, in the variously modified antiphlogistic measures deduced from those principles.

It must be understood at the same time, that amaurosis often occurs in conjunction with depressed constitutional power: and that, in certain cases, it is the direct offspring of debility, arising from a weakened state of circulation, and consequent deficient supply of blood to the nervous structure. Hence the important division of *sthenic* and *asthenic* amaurosis. Again, the affection of the retina is, in many cases, purely functional, and excited sympathetically by disorder in other quarters.

Inflammation of the retina, or at least active disturbance of its capillary circulation, sometimes comes on suddenly, and proceeds rapidly to loss of vision. Although the affected texture is out of sight, the symptoms demonstrate clearly the seat and nature of the disease, and we do not hesitate in calling it *retinitis:* it might be termed *acute amaurosis*. (See Chapter XIX. § 2. It is equally obvious that inflammation of the retina exists in the disease described in the third section of the same chapter.) In the great majority of instances, the disease arises gradually, and proceeds slowly, observing altogether a chronic type. The following account is a description of this affection, which might be named, in order to distinguish it from the other,—*chronic retinitis* or *chronic amaurosis*. There is no boundary between the two forms of disease, which pass gradually into each other. A similar insensible transition connects simple retinitis, whether acute or chronic, with inflammation of the internal tunics, either idiopathic or arthritic. Indeed the latter cases differ from the former only in the extent of disease.

SYMPTOMS OF AMAUROSIS.

Impaired and altered sight.—The leading symptoms of amaurosis consist in the variously altered state of the function. We find sight impaired in all possible ways. The most various imaginary objects and colors appear before the eyes. In different instances there are all kinds and degrees of defective perception in respect to the form, color, and proportions of objects,

and their relations to each other; augmented and diminished sensibility to light; impediments to vision most diversified in degree and kind.

In the beginning of the affection patients complain of the sight being weak or dim; the imaginary objects called muscæ are seen; objects are perceived but imperfectly; they appear more or less obscured by cloud or haziness; the letters of a book run into each other and become confused; the eye is soon tired, and waters or becomes bloodshot if exertion is continued. Sometimes near objects are not clearly recognized, when those more distant are seen perfectly. This incipient stage, in which vision is partially impaired, is *amblyopia*, or weakness of sight: it is sometimes seen as a permanent condition.

They who divide amaurosis into two kinds, that with increased, and that with diminished sensibility of the retina, enumerate, as symptoms of the former, various kinds of impaired vision, some of which rather denote the period of excitement in disease of the retina, than the more advanced stage, ordinarily designated as amaurosis. Some of the symptoms now alluded to are merely the offspring of sympathetic disturbance caused by primary disorder in other quarters.

Beer observes that in some rare cases of incomplete amaurosis, the sensibility of the retina to light is so much increased, that the patient avoids all places where there is strong light, particularly where strong reflected light falls on the eye, and seeks comparative darkness; protecting the eyes, when he goes abroad, with a green shade or with green spectacles. This state passes under the name of intolerance of light, or *photophobia*. Under such circumstances, the patient sometimes discerns for a short time, that is, for a few moments, or more rarely for a longer period, even the smallest objects in an extremely weak light, as clearly as the best eye can see them in the light of day; while, at other times, he cannot distinguish even larger things in the same light. This state which is called *oxyopia*, that is, *acuteness of sight*, (from οξυς, sharp, and οψις, vision,) deserves the particular attention of the practical surgeon." (*Lehre*, vol. ii. p. 426.)

This increased sensibility of the retina may become so considerable, that the presence of light cannot be borne; at least it causes severe pain in the eye and brow, with discharge of tears and confusion of all objects. The patient, therefore, remains in a darkened chamber, and may be said to suffer under a kind of day blindness, or *nyctalopia*. I saw a patient, in whom, although amaurosis had existed for some time, and advanced considerably, the smallest light could not be borne; and he remained constantly in a room with the very crevices of the shutters carefully stopped up. More commonly the retina is in an opposite state. Its increasing insensibility, and the consequent necessity of a powerful impression to produce any effect, lead the patient to get as much light as he can. He seeks clear and bright lights; and in attempting to read, places his back towards the window, that the light may fall on the book.

When the amblyopia, with increased sensibility, proceeds a little further, a shining glare appears before the eye, sometimes with rainbow colors, sometimes tremulous, surrounding and confusing objects. A light cloud may pass before the eye; or luminous and fiery points, flashes, or streaks, may appear. Blue or yellow flashes, or globes of fire, are seen in the dark, or when the lids are closed. This glare of light, and these various luminous appearances, often continue when the sensibility of the retina has been completely extinguished, and lead the patient to indulge in hopes that his vision may be restored (*vicus lucidus; photopsia*, from φως, light, and οψις, sight; *Marmaryge* of Hippocrates, that is, μαρμαρυγη, flashing or dazzling light.)

Objects are sometimes perceived with prismatic colors, halos or rays

round them; sometimes they appear completely altered in color, for example, as if seen through a yellow glass (*visus coloratus; chrupsia*).*

The preceding, and various other defects of sight (*vitia visus*), which have sometimes been enumerated, as if they were peculiar affections, or even distinct diseases, are merely forms of the impaired function, symptoms of amaurosis, that is, of disease seated in the nervous structure of the eye. One of the most frequent of these symptomatic phenomena is broken or interrupted vision (*visus interruptus*). The eye misses parts of objects; letters or words are lost in reading, and the patient moves the whole head to search them out. Sometimes the upper or lower half, sometimes the right or left half, is not seen (*visus dimidiatus; hemiopsia*): sometimes a small part only of the retina retains its sensibility, and such things only are seen as are placed in a particular direction with respect to the eye. Slight movements of the head or eye put the latter out of its proper position for vision, and it is not easily brought back again to the right place. Things sometimes appear deformed or distorted (*visus defiguratus; metamorphosia*); sometimes as if enveloped in a mist or cloud, which may be light, dark, or changeable, or apparently composed of minute objects coalescing (*visus nebulosus*). This cloud becomes thicker and more extensive, until the perception of objects is destroyed.

A common symptom of incipient amaurosis is the appearance of floating or moving bodies before the eye, (*visus muscarum; myodesopsia.*) Dark, gray, or semi-transparent threads, spots, streaks, insects, rings, chains, globules, indeed minute substances of every description, seem to float before the eye, moving rapidly upwards and then falling, more conspicuous and more troublesome in impeding vision in a clear light, or in looking at a white or light object. A single black speck is called *scotoma;* the more numerous moving bodies are called *muscæ volitantes.* It is not uncommon for the patient to see before the eye a black disk, which increases in size as the affection proceeds, becoming larger and larger until at last it covers the field of vision. As the moving bodies increase in number, they become more completely opaque, and unite so as to form a net or thick veil, more or less completely enveloping whatever the patient looks at, (*visus reticulatus.*) This net appears dark in a clear place, or against a white ground; while in the dark it is shining, and whitish or yellowish.

Double vision (*diplopia, visus duplicatus*) is a common circumstance in incipient amaurosis. The affected eye deviates from its proper direction, or squints, so that the optic axes do not correspond. Hence objects are seen double; the two images sometimes being equally clear, though the second is generally fainter. The two may be close together, or at some distance; and the second may be above, below, or at one side of the first. When either eye is closed, vision with the other is single. The movements of the two eyes coincide in certain directions, so that the double sight is only partial.

Squinting and double vision may be caused by sensorial affections, without amaurosis. The symptom in this form sometimes precedes apoplexy.

The very rare occurrence of double vision with one eye must be referred to affection of the retina. Beer calls it *dyplopia nervosa.*

In some instances the commencement of amaurosis is attended with near-sightedness (*myopia*), or far-sightedness (*presbyopia*). The latter is the most common.

In some instances vision is enjoyed during a part only of the twenty-

* This word, employed by Beer, (Lehre, vol. ii. p. 428.) seems to be compounded of χρως, or χροα, color, and ωψις, sight.

four hours, and the patient is blind during the other part. He may see well in the day, and be blind at night, (*cœcitas nocturna* or *hemeralopia;*) or vision may be imperfect in the day, and better at night (*cœcitas diurna* or *nyctalopia*).

Although the various kinds of imperfect vision, now enumerated and described, are designated by appropriate names, they are not distinct diseases, but mere variations in the state of the function originating in a common cause, namely, disease, or disorder of the retina. The pathological conditions of this texture, especially in the early and active periods of disease, are almost entirely unknown to us ; and we are therefore unable to point out the particular circumstances in the affection which give rise to each of these modifications.

The central portion of the expansion, which is the usual seat of impression, loses its sensibility first ; the circumference, which does not undergo the same degree of habitual exertion, retains its powers longer. Hence patients can frequently see objects placed laterally, particularly on the temporal side, after the power of distinguishing them in the direct line of vision is totally lost.

Progress of the disease.—The origin and progress of amaurosis are very various. It may be produced suddenly, and reach its full development in a few hours. This is exemplified in the cases related at page 495, as well as in that of the patient struck with lightning, at page 462. I have seen a few instances, in which persons having gone to bed with perfect sight have been totally blind the next morning Sometimes blindness is produced in a few days, weeks or months, while in other instances years elapse before vision is altogether lost. In some cases the imperfection of vision reaches a certain point, and the disease is then stationary.

I was consulted by a gentleman, twenty-six years of age, who, three years previously, had gone out shooting at night, the ground being covered with snow. The next day his sight was dull : within a few days it had become very imperfect, and had continued in the same state to the time of my seeing him, in spite of various treatment. In the large print of a title-page, he could just slowly make out the letters one by one. The pupils were about the middle size, and the irides possessed but little power of motion.

More commonly, and especially under neglect, with continued exposure to the causes which have induced the affection, or injudicious treatment, it ultimately ends in total blindness. In this stage there is a peculiar vacant stare, very characteristic of the affection. On entering a room, instead of looking at persons or surrounding objects, the eyes are directed forwards with the lids wide open, and are fixed in a kind of gaze on vacancy. There is a want of movement in the eyeballs and the head, and a quiescence of all the external parts whose motions ordinarily harmonize with those of the direct visual apparatus, which immediately betray the state of the case even to an inexperienced observer. This vacant stare at nothing does not occur in cataract. Although the patient may be unable to discern objects, he looks about, as if conscious that vision still exists. In short, the state of the eyes, eyelids, and surrounding parts, with the mode of carrying and moving the head, are expressive of blindness in the one case, of sight in the other.

The surface of the organ, in some rare instances, is more or less bloodshot in amaurosis ; though, in the great majority of cases, the only visible changes are those in the size and form of the pupil, and the motions of the iris, with the fixed state and peculiar expression of the eye.

State of the pupil and iris.—The pupil and the iris of amaurotic patients exhibit various changes, some of which are so conspicuous as to attract the

notice even of careless observers. The former is dilated, often considerably, even in the strongest light: sometimes it is equally contracted, and that permanently. The opening often deviates from its normal form, being oval, oblong, or angular at different points of its circumference. It may deviate from its central situation in the iris, being most frequently displaced upwards and inwards: in such cases the margin generally presents angular irregularities.

In many cases, the clear blackness which characterizes the normal state of the opening is lost, and the pupil has, instead, a dull, smoky, or cloudy discoloration of greenish, grayish, or leaden cast; sometimes it is of a yellowish green, much like that of glaucoma. The healthy retina is transparent, and the dark choroid seen through it gives the pupil its black color. If the texture of this nervous expansion be changed by disease, corresponding alteration in the appearance of the pupil may be expected. It is difficult to account for the symptom in question, except on this supposition. Beer says that "the blackness of the pupil in amaurotic patients is seldom so clear as in the healthy eye of a young person. Sometimes the opening is slightly smoky, or cloudy, and we cannot always distinguish at what distance from the uvea this inconsiderable discoloration is situated, or determine whether it proceeds from change in the transparent media, in the retina, or choroid. When the pupil is dark gray, or rather greenish gray, we can discover by looking at the eye sideways, that the change must be either in the vitreous humor or behind it." (Lehre, vol. ii. p. 436, 437.) If this symptom be caused by alteration in the state of the retina, the latter is not irremediable; and consequently, the former is not of itself a sufficient ground for unfavorable prognosis.

Beer proceeds to state, that the pupil may be reddish, or really red, or yellowish white, in amaurosis; and that, in all such cases, the discoloration is obviously in the fundus of the eye and concave. I think that such appearances would denote organic disease of the eyeball, rather than amaurosis, in the strict sense of the word. I once, however, observed a red appearance in the pupil of an amaurotic eye.

Case.—A student at one of the universities, of sanguine complexion, light hair, and full habit, about twenty years of age, who had been reading, but not very hard, was not aware of any other cause for the complaint on which he consulted me, namely, loss of sight in the right eye. Dimness had come on two months previously, and had increased gradually, so that he could merely discern large objects with the right eye, and he saw them best when they were placed quite to the right of the eye. The iris acted equally on both sides. I thought that I caught a glimpse of something red behind the iris, in some movements of the eye, and therefore, dilated the pupil by means of the extractum belladonnæ. A portion of blood was then distinctly seen behind the lower part of the iris. It was of arterial color, and moved a little up and down, when the globe was moved. The dilatation of the pupil produced no alteration in the state of vision. I did not see this gentleman again.

In the following passage Richter states his experience respecting the change of color in the pupil of amaurotic patients. "Colorem pupillæ oculi gutta serena affecti nigrum, sanum, omnisque vitii expertem esse, plerique uno ore affirmant. Hoc autem assertum magis adhuc quam prius erroneum esse, iterum iterumque expertus sum. Plerumque sane splendido illo puroque nigrore orba est pupilla oculi, qui amaurosi laborat; languorem in illo hebetudinemque, loco nitoris illius, quo gaudet sanus integerque oculus, quilibet in illo animadvertet. Aliquoties tam insignem pallorem pone pupillam percepi, ut, quod ingenue fateor, dubius aliquando hæserim,

cataractane incipiente an amaurosi æger laboret. Facilis sane in hoc casu error est, imprimis si perfecta nondum est amaurosis, motuque adhuc pupilla, luminisque quodam sensu retina gaudet. Plures sane, quod affirmare possum, ad me pervenerunt ægri, et medicorum suasu, qui cataracta illos laborare credebant, operationem petierunt." (*Obs. Chirurg.* fascic. ii., p. 65, 66.)

A motionless state of the iris, together with dilated pupil, has usually been enumerated among the symptoms of amaurosis, as if it were a constant attendant on the complaint. There are, however, many exceptions in respect to both circumstances. The various impressions on the retina by light in its several gradations are the cause of the motions exhibited by the iris in the natural state of the eye. Hence we should expect what we usually see, namely, that the iris moves imperfectly in proportion as the sensibility of the retina is impaired, being at first sluggish, and then ceasing to move when blindness is complete. In the early stage of the affection, the iris and pupil will not deviate much from their normal condition, the fixed and dilated state of the latter not occurring till the amaurosis is complete. In some individuals, whose sight is perfect, the iris possesses but little mobility; and, occasionally, it is even motionless with unimpaired vision; on the other hand, the full power of motion sometimes exists in complete amaurosis. Janin* has mentioned two instances in which he noticed this circumstance. One was a boy, nine years old, who had been blind six months; the other, a female of thirty-two, who had lost her sight three years before. Both were totally blind, although the eyes were to all appearance perfectly healthy, and the irides had the full natural degree of motion. The same combination came twice under the observation of Schmucker,† and had been seen still more frequently by Richter: "Vidi enim non raro," says the latter, "perfectissima amaurosi occæcatos, quorum pupilla mobilis erat, et ad minimum lucis attactum valde vivideque se constringebat."‡

I have mentioned, at page 496, the case of a boy totally blind from hydrocephalus, in whom the motions of the iris were unimpaired.

Case.—*Amaurosis of one eye with perfect motion of the iris.*—A lady of fifty-six, of spare habit, healthy appearance, temperate, and always enjoying good health, had lost the sight of the right eye fifteen months before I saw her, without pain, headache, or any obvious cause. She had never used her eyes imprudently in reading, needlework, or any injurious occupation. The two eyes were so completely alike, that I could not discern which was amaurotic. With the right she could merely distinguish light from darkness. The independent as well as the associated action of the iris was perfect, and both pupils were of the same size under similar circumstances of light.

When the affection is confined to one eye, the other remaining sound, we shall not, in many cases, observe the slightest defect in the amaurotic eye, so long as both are open. But as soon as the sound eye is closed, the pupil of the other is dilated and fixed, and its margin perhaps becomes angular. In other words, the iris of the amaurotic eye moves in harmony with the other after its independent action is destroyed. In complete amaurosis of old date, accompanied with change of color in the iris, I have sometimes seen the associated action perfect, when the strongest light directed on the affected eye with the other closed, has caused no sensation nor change in the state of the pupil.

* Dissertation sur la Mobilité de l'Iris dans des Yeux affectés de la plus grande cécité; in Mémoires et Observations Anatomiques, etc., sur l'Œil, p. 425.

† Vermischte chir. Schriften, p. 13.

‡ Obs. chir. fascic. ii. p. 63.

Other symptoms.—Cases of amaurosis differ considerably in the accompanying pain, whether of the eye or head. Sometimes the disease arises insensibly, and is developed very slowly, without any pain. Sometimes there is an uneasy feeling in the eye and neighboring parts without pain; a sensation of fulness and an unusual weight in the globe. Sometimes the patient feels as if dust or sand were under the lids. Frequently, the impaired vision is preceded or accompanied by headache, giddiness, dizziness. Sometimes there are pains in the forehead, over the eyebrow, and in one side of the head: these are occasionally severe. There may be heaviness about the eye, aggravated by motion or employment of the organ. The pain may begin with the amaurotic affection, or precede it by some considerable time. If it comes on after vision has been lost in one eye, or in both, we may conclude that the pain and the amaurosis are both caused by some other disease. This observation holds good of many cases of painful amaurosis; the pain not being caused by the latter affection. Racking pain in the brow, temple, or head, not relieved by treatment, or, if alleviated, quickly returning, and accompanied by similar pain in the eye, either constant or brought on by slight exertion, indicates the existence of disease in the orbit, skull or brain.

The state of the circulation, and of the digestive organs, is very various in amaurosis: the former may be excited, with fullness and strength of pulse; it may be natural; or the pulse may be small and feeble; that is, the retinal affection may be sthenic or asthenic. Sometimes the latter are in an unhealthy state, and the disturbance of this important system is a leading feature in the affection, contributing, with other circumstances, to its origin and continuance; on other occasions there is no marked derangement of their functions.

Causes of amaurosis. Age; the disease sometimes congenital.—The disease may occur at all ages, and is sometimes even congenital. A fine and healthy infant, which I saw at the age of six months, was quite blind. The eyes, on cursory inspection, would have been pronounced free from defect. They were blue, like those of the mother and father. The pupil, which was of middle size and clear, was not observed to vary in its dimensions. The iris was in contact with the cornea. The mother had brought forth seven children, three of whom had been born blind in this way. I have seen other instances of congenital amaurosis, where the eyes appeared perfect. In a family of children belonging to a healthy father and mother, one of whom had blue, the other dark eyes, some were light and the others dark-eyed. The latter had all of them become successively amaurotic in their early years, without apparent cause.

"Five or six years ago," says Mr. Gibson, "I recollect to have seen five or six children, the families of two sisters, who were all totally blind, and in an idiotic state, with cataracts accompanied by amaurosis." (*Edinburgh Med. and Surg. Journal*, vol. vii., p. 398.)

Dr. Monteath saw a family at Paisley, the three eldest of whom were born amaurotic. He gives the following account of one, who at the time of his examination was an interesting girl of eighteen. "Her eyes and their appendages are well shaped; the iris is of a blue color; the pupils are of natural size, form, and color. The size, however, does not perceptibly vary from the action of different degrees of light, at least I could not discover any motion of the iris. Her eyes have not the inanimate appearance so characteristic of amaurosis, and they have less of the irregular involuntary motions usually observed in blind people." The father and mother, and their relations, have good eyes. (*Manual of the Diseases of the Human Eye*, vol. ii., p. 82, note.)

Although the disease spares no age, it is most frequent at, or after, the middle period of life, especially about the cessation of menstruation in females, and the corresponding age in the male.

Hereditary disposition.—The influence of peculiar hereditary formation in predisposing to amaurosis is unequivocal. I had under my care, at the London Ophthalmic Infirmary, twin sisters, whose habit of body, features, complexion, and state of health, were exactly alike, as well as the color of the hair and eyes. They were both amaurotic at the same time, and with exactly the same symptoms.

"Amaurosis," says BEER, "is much oftener hereditary than cataract; thus we see many members of a family for more than one generation, becoming blind from this cause at a certain period of life. I know more than one family, in which this is the case; and the circumstances in one instance are curious. The females, even in the third generation, become completely and incurably amaurotic, as soon as menstruation ceases; but they who have borne children escape. The males of this unfortunate family, who as well as the females have very dark brown eyes, show a disposition to amaurotic amblyopia, though none have become actually blind." (*Lehre*, vol. ii., p. 442.)

I have quoted, at page 503, from Dr. MONTEATH, the case of an amaurotic old lady, in whom the optic nerves were found atrophic. Dr. M. adds, that "the twin sister of this lady died in the eighty-first year of her age, and for eight or ten years before her death she also had been completely amaurotic. Though her general health was more entire than is usual at such an advanced age, she had lost completely not only her sight, but also her senses of taste, of smell, and of hearing. She could not distinguish animal from vegetable food, or one sort of fluid from another. No opportunity was obtained of inspecting the head. The only daughter of Mrs. ——— (the lady mentioned at p. 503), is at present alive, and has been totally blind from amaurosis for several years; she is at present in her fifty-sixth year. I have been consulted by the son and grandson of Mrs. ———, who have both weak eyes. The grandson, in particular, has a very distressing degree of congenital amblyopia. Any exertion of his eyes induces temporary blindness, and though he can sometimes see a minute object, at others he will walk directly against a chair or table." (Lib. cit., p. 81, 82.)

General causes; plethora.—The causes, which contribute more directly to the occurrence of amaurosis, are analogous in their nature and operation to those which produce disease in other textures of the eye and in other parts of the body. Excitement of the circulation by errors in diet, particularly by intemperance in drinking, and the determination of blood to the head more immediately produced by such indulgences, are circumstances of frequent and powerful operation in causing disorder and disease of the retina, as well as of other parts of the eye, and of the brain. A sedentary mode of life, and residence in bad air, seriously aggravate the injurious effects of these disturbances. The continuance of such habits through a course of years impairs the functions of the assimilative organs and nervous system, and thus induces an unhealthy state of constitution, in which amaurosis occurs more frequently than in the direct plethora caused by excess in an individual whose general powers are unbroken.

Excessive exertion of the organ.—In a great number of instances the immediate or exciting cause is excessive exertion of the organ, particularly its employment on minute or shining objects. In many cases the affection can be clearly traced to inordinate use of the eye, which brings on the disease without any observable influence from the remote or predisposing circumstances just alluded to. Hence it is frequent in those who follow the various

occupations requiring close attention and constant exertion of the organ, as in tailors, shoemakers, mantua-makers, milliners, sempstresses, law-writers, compositors, engravers, painters, especially in miniature, jewelers, watch-makers, and the various workers in metal. When we consider, that in these, and many other similar cases, the eye is incessantly exerted for several hours daily, and reflect on the delicate texture of the retina, we shall only be surprised that it should retain its powers so long unimpaired.

Limited or temporary exposure to strong light may produce amaurosis suddenly, as in a stroke of lightning, *coup de soleil*, or microscopic observations. But it is more frequently seen as the consequence of habitual exposure to less powerful lights, as in cooks, workers in metal, and in glass-houses, in soldiers or sailors when living in tropical countries, in those who pursue their employments under strong gas-light.

Indirect causes of general plethora, or of determination to the head.—All circumstances favoring the production of general plethora, or determination to the head, render the occurrence of amaurosis more probable; such are the sudden suppression of accustomed discharges, the cessation of menstruation at its usual period, its interruption at an earlier age, and its non-occurrence at the time when it ought to commence. In enumerating the causes of the complaint, many writers lay great stress on the suppression of bleeding from the hemorrhoidal vessels, on that of epistaxis, perspiration, or the secretion of milk, on the rapid healing of itch, or other cutaneous eruptions, or of large ulcers of the lower extremities. Without denying the agency of these causes, which in some instances is unquestionable, I consider that it has been greatly exaggerated, both in frequency and degree. I have never seen any disease, internal or external, caused by the cure of itch, although I often see the complaint in its worst form, and see it rapidly disappear under proper treatment. I never traced an amaurotic affection to the repulsion or cure of a cutaneous disease. Some of the causes above mentioned, by producing unnatural fullness and excitement of the circulation, may render the occurence of amaurosis more probable in those predisposed to the disease. Thus amaurosis is one out of many effects that may proceed from such causes, the influence of which is not exerted directly on the retina, but is of a more general kind. The retinal affection, therefore, is not specific, but similar in its nature to that proceeding from other causes, and requiring analogous treatment. Proceeding on these views, I cannot but think that to establish, as Beer* has done, specific distinctions of amaurosis founded on the supposed cause, is erroneous in principle, and calculated to produce confusion and indecision in practice.

Sympathetic influences.—Disordered states of the abdominal viscera often have a share in producing amaurosis. Sudden or violent irritation, as by acrid ingesta, or by worms, may cause temporary blindness. Here the retinal affection is sympathetic. More frequently, disorder of the stomach and alimentary canal is one circumstance, and an important one, in the chain of events leading to that unhealthy state of constitution, in which amaurosis most frequently occurs. If the hypochondriac or gastric disorder should be strongly marked, the retinal affection will probably be ascribed to it,

* He has devoted separate chapters to the following forms of the complaint: namely, that from irregularity or suppression of the acute exanthemata, as scarlatina, measles, and small-pox.—Lehre, vol. ii. p. 522; from the suppression of coryza without apparent collection of mucus in their frontal sinuses.—Ibid., p. 530; from the disappearance of impetiginous eruptions, and the healing of old ulcers.—Ibid., p. 556; from the suppression of coryza with accumulation of mucus and pus in the frontal sinuses.—Ibid., p. 566; from the suppression of milk in suckling women.—Ibid., p. 572.

though I believe that there are few cases, if any, in which amaurosis can be traced to the direct and simple action of such a cause.

Syphilis.—Syphilis has sometimes been enumerated among the causes of amaurosis; according to my experience, without sufficient reason. There is no syphilitic inflammation of the retina, like that of the iris. In the latter disorder, the inflammation which begins in the iris, often spreads to the internal tunics generally, and the eye is sooner or later amaurotic. Thus, in describing syphilitic amblyopia and amaurosis, JUENGKEN* enumerates the symptoms of syphilitic iritis, or, more properly speaking, of syphilitic inflammation of the internal tunics, including change of color in the iris, effusion of lymph, adhesions and disfiguration of the pupil, and vascular zone round the cornea. But that chronic affection beginning in, and confined to, the nervous tunic of the eye, which we generally understand by the term amaurosis, has never been produced by syphilis, in the way that iritis is, within my observation. The optic nerve may suffer by contiguity in consequence of syphilitic disease in the bones of the head. Something of this kind seems to have occurred in the case quoted at p. 501.

Gout and rheumatism.—Amaurosis may occur in the gouty and rheumatic; but the local affection receives no peculiar character from the constitutional disposition, nor does it require peculiar treatment.

BEER† and JUENGKEN‡ have given the name of arthritic amaurosis to an internal inflammation of the globe occurring in gouty persons, generally very slow in its progress and development, accompanied by change of color in the iris and pupil, enlargement of the sclerotic vessels and dullness of the cornea, and ending in glaucomatous cataract, varicosity of the external vessels, and staphylomatous bulgings of the sclerotica. In these cases the retina undoubtedly suffers in common with other parts, and thus impaired sight is one of the first symptoms, while blindness often occurs at an early period of the affection. This disease may appear either in an acute or a chonic form; the first is described in Chapter XVIII. § 3, under the name of *arthritic inflammation of the internal tunics;* the second in Chapter XXII. under that of *glaucoma.*

At page 502 I have related the history of an amaurotic affection in a gouty individual. The narrative is the more interesting as it contains a description of the changes in the affected organ and in other parts discovered on examination after death.

I subjoin the following case to show that when amaurosis, in the more strict and proper sense, occurs in an arthritic subject, the appearances in the organ present no characteristic peculiarity.

CASE.—*Amaurosis in an arthritic subject; trial of mercury without benefit.*—In the year 1828, I saw a gentleman, about thirty, affected with nearly complete amaurosis of the right eye. He had been laid up with a severe attack of rheumatic gout in the right instep, in the spring of 1820, when at college, after three months of the closest application to study previous to an examination for his degree. This was preceded by a copious running, which he supposed to be gonorrhœa, though it did not yield to cubebs, which quickly stopped true gonorrhœa with him. The eyes were not affected. In the autumn of next year, being then at Venice, he had what seemed gonorrhœa, though he could not account for it. The discharge stopped by the use of cubebs, and the eyes became affected, so that he could not bear the light; he was laid up for ten days. There was no affection of the joints. He says, "I set this down at the time for gonorrhœa and nothing else, and it

* Die Lehre von den Augenkrankheiten, p. 803. † Lehre, vol. ii. p. 544—555.
‡ Die Lehre von den Augenkrankheiten, p. 801—803.

seemed to yield the cubebs, which I took in quantities on the road from Venice to Rome. I think now, however, that the remedy only changed the seat of the disorder from the urethra to the eyes. This was a short attack, but the only one in which the eyes were affected. In the following four years, I had three or four attacks, all preceded by running, similar to that of gonorrhœa, though in some instances I stoutly maintained that there was no gonorrhœa in the case, but in vain. Every one of these attacks was in the joints, generally in the feet or in the knees, sometimes for a time flying about the chest. From 1825 to 1828 I was entirely free, though I once or twice had gonorrhœa, which always stopped in a short time by rest, low diet, and the use of cubebs. In 1828 I was seized with rheumatic gout in the left foot, which came on in one night, so that having gone to bed well, I rose quite lame. For about three weeks previously the bowels had been disordered, and flying pains had been felt in the joints. Both feet suffered, but the left principally; the knees were also affected. This attack lasted one month, at the end of which I discontinued medicine, and went into the country, still weak in the limbs." Colchicum was freely given, with magnesia, and afterwards sulphate of quinine. Soon after this, the right eye began to be affected. The attack in the limbs commenced on the 9th of August: the patient left Dublin on the 6th of September, still continuing the sulphate of quinine, under which the pains of the limbs had ceased. The eye began to be affected on the 11th of September. There was slight inflammation of the lid, and for two or three days slight pain in the eyeball on turning the head. He began to perceive that sight was impaired about the 14th. He could distinguish objects only in the lower portion of the field of vision, and this portion gradually lessened, so that by the 28th nothing could be seen. He returned to Dublin on the 4th of October, when his sight was gone. Eight ounces of blood were taken from the temple by cupping; a blue pill was given every night. Afterwards, electricity and sulphate of quinine were employed. When I saw this gentleman on the 24th of October, 1828, there was no useful vision with the right eye, although he could distinguish light from darkness. He saw nothing straightforwards; but he could sometimes distinguish an object, such as the hand, when held towards his right side. The associated action of the iris was perfect; but when the left eye was closed, the right pupil dilated, and continued in that state. There was no pain; and the left eye was unaffected. A mild mercurial course was recommended in consultation on this case. Five grains of the blue pill were taken twice, thrice, and sometimes four times daily, until the mouth was slightly affected. Calomel with opium was then administered, so as to increase the mercurial influence; the bowels became disturbed, and the patient thought the eye worse. On the 24th of December the sight remained as at first; the health was improved. He was ordered to leave off the blue pill gradually.

Narcotic poisons and various other substances.—The German writers, particularly Beer and Benedict, consider that amaurosis may be caused by various articles of food, and by many of the substances employed in medicine. They enumerate the vegetables, which have the property of dilating the pupil; viz., belladonna, hyoscyamus, stramonium, and cherry laurel; also opium, succory-coffee, bitter beers; bitter almonds; gentian, quassia, simaruba, centaureum, cynoglossum; ammoniacum, and galbanum; and the various preparations of lead.*

* Beer, Lehre, vol. ii. p. 445. He has also an express chapter "On the Amaurosis produced by the abuse of bitter substances, and such as contain carbon, in food and medicine, and by the narcotic metal, lead." Ibid., p. 499—505. Benedict, Handbuch, vol. v. p. 95—100.

In describing the influence which the four vegetables first named exert over the iris and pupil, at page 369 I have mentioned the confusion or interruption of sight which occurs when the dilatation of the pupil is carried to its full extent. This temporary diminution of sight which seems to depend, not on any immediate influence exerted by the vegetables in question over the retina, but on the previous dilatation of the pupil, goes off in proportion as that opening recovers its natural size; and no permanent injury to sight has been produced within my experience.

In two soldiers, who had eaten the young shoots of the hyoscyamus niger dressed with olive oil, giddiness and stupidity came on, with loss of speech and sensibility, difficult breathing, small and intermittent pulse. The pupils were excessively dilated, and the eyes so insensible that the eyelids did not wink when the cornea was touched. Vomiting was soon excited in one, when he recovered in a short time. Both were fit for duty in two days.* The loss of sight after poisoning by belladonna, which is sometimes so complete that the brightest light cannot be perceived, together with extreme dilatation of the pupils, may last for two or three days; and these symptoms, in a less degree may continue for two or three weeks; they disappear spontaneously, but slowly.

According to Dr. Christison, opium, when taken in large quantities for the purpose of self-destruction, generally causes contraction of the pupil, which is sometimes excessive.† The facts observed and collected by this judicious and indefatigable inquirer, show clearly that no injury to vision is produced by this powerful drug, either in small or large doses, or when habitually taken in large quantity by opium eaters.

The roots of the wild succory (*cichorium intybus*), roasted, have been long employed as a substitute for coffee; and when the latter was rendered extremely scarce and dear by the prohibitory regulations of Napoleon, the practice became general, particularly in Germany. Beer‡ says that he was more than once consulted on account of weakness of sight depending entirely on the free use of this substance, and that the complaint disappeared simply by avoiding the exciting cause.

Benedict§ states that this practice had afforded no clearly marked instance of the affection. The wild succory has been so extensively used in diet and medicine, that if it possessed the noxious properties ascribed to it by Beer, the fact must have been long ago well known. The continued employment of the plant sufficiently proves the negative. The same observation is applicable to beer, bitter almonds, and the vegetable bitters and gums above enumerated.

According to Beer, amaurosis may be brought on by the continued and incautious handling of colors and other preparations containing lead; by the application to the face and breast of coloring matters prepared from lead; and by any preparation of lead swallowed in large quantity. He says, that he had often seen amaurosis from this cause, and treated it successfully.‖ The information on the effects of lead, collected by Dr. Christison,¶ affords no confirmation of this opinion.

Beer considers that a diminution of the dark pigment covering the choroid

* Dr. Christison, Treatise on Poisons, 2d ed., p. 648.

† Ibid., p. 620, 621. "The pupils are always at least sluggish in their contractions, often quite insensible; sometimes they are dilated, but much more commonly contracted occasionally to an extreme degree." In the case last noticed they were no bigger than a pin's head. The insensibility of the iris may probably be explained by the state of the sensorium.

‡ Lehre, vol. ii. p. 445.

§ Handbuch, vol. v. p. 97.

‖ Handbuch, vol. v. p. 501.

¶ Lib. cit., p. 489—494.

and uvea may explain the imperfection of sight incidental to elderly persons (*amblyopia senilis.*) It would be difficult to verify this opinion. The pupil often becomes gray or green as persons advance in years, and there can be no doubt that this change arises from diminution in the quantity of the pigment. Yet sight is perfect in such cases.

I shall speak subsequently of debility as a cause of amaurosis, and particularly of the impaired vision induced by protracted suckling; also of the disease as caused by affection of the nerve of the fifth pair.

Diagnosis.—The distinction between amaurosis and cataract will be considered in the chapter on the latter disease.

[The most certain means of distinguishing amaurosis from cataract is afforded by a catoptric examination. In perfectly uncomplicated amaurosis, the three images of a candle can always be seen; whilst in cataract the second upright, and the inverted images are one or both absent, or changed in size, brilliancy or distinctness, as will be pointed out in the chapter on this disease.]

The retina is affected in glaucoma, as well as in amaurosis; but in the former other textures are also involved, and the presence of symptoms arising from this source, in addition to impaired vision, will afford the distinguishing marks of glaucoma. These symptoms are the deeply seated green discoloration of the pupil, and the altered color of the iris. If, as it sometimes happens, the pupil should be also dilated and fixed in the commencement of the affection, the distinction will be still more easy. The color of the iris is not always changed in glaucoma; green discoloration of the pupil is sometimes seen in amaurosis, while a sluggish or motionless state of the iris and dilated pupil are common to both. Hence the distinction is difficult in some cases. It is more important in reference to prognosis than in treatment; for the same means are applicable to both affections, though the chance of benefit is much less in glaucoma than in amaurosis.

The distinction between internal ophthalmia and amaurosis does not involve the nature of the disease, but its precise seat and extent. By the former we designate inflammation affecting the internal tunics generally, and therefore including the retina; when the latter alone is affected, the disease is called amaurosis. The presence or absence of the alterations caused by inflammation, whether acute or chronic, in the iris or pupil, will form a sufficient ground of distinction. When the source of disease is in the retina, the affection, in the greater number of instances, is inflammation of that structure, more or less violent. When the affection is active, its pathology is clear, and we name the disease retinitis. This active inflammation may extend to the internal tunics generally, and thus produce ophthalmitis interna. Under other circumstances, the nature of the affection is not so obvious, and instead of calling the disease chronic retinitis, after the organ affected, as we probably should do if its pathology were well understood, we name it from a symptom; and we must continue to employ the term, although it conveys no information of the seat or nature of the disease, until the morbid changes, of which the retina is susceptible, shall have been more accurately investigated.

Since the principles of treatment are the same in both instances, it is of no importance practically to draw an accurate line of distinction between the cases, in which inflammation, whether acute or chronic, is confined to the nervous structure, and those in which the internal tunics generally are involved in the inflammatory affection.

Prognosis.—This turns principally on two points; viz., the degree in which vision is impaired, and the length of time the disease has existed.

It is more favorable in proportion as the injury to vision is less, and the attack more recent. If the affection be partial, and the case seen early, a complete cure may be expected. We think favorably of the event when amaurosis is evidently caused by active congestion in the head; for that cause can be removed by suitable treatment. We take a similar view of the subject when the disease approaches more or less nearly to chronic internal inflammation. Our prognosis is doubtful in the earliest cases if the insensibility of the nervous structure be complete; it is equally so in imperfect amaurosis of long standing. Violent vascular disturbance may at once produce so serious a change in the retina as to render it incapable of vision, and a less degree of congestion will have the same effect, if it be long continued. The prognosis is bad when the complaint has been preceded and accompanied by severe pains in the brow, temple, and head; by pains either not relieved by treatment, or, if relieved, quickly returning; also when attended with similar pain of the eye, whether constant or brought on by slight exertion of the organ. The same observation applies to the cases attended with epileptic symptoms, paralytic affections, or great change in the pupil. Under such circumstances we may reasonably suspect the existence of organic changes in the retina, optic nerve, orbit, skull, or brain.

We cannot trace an accurate line of demarkation between what is called internal ophthalmia and amaurosis; in the former the inflammation is more active and affects more parts; in the latter it is a slower affection, and confined to the retina. The bolder and more strongly marked inflammation is more easily arrested than the more chronic form. The prognosis is doubtful, and rather unfavorable than otherwise, as to the complete recovery of vision, if the affection, even in its most recent state, should have produced complete insensibility of the retina. We should speak doubtfully of the result in the case of complete insensibility to strong light, even if it had only lasted twenty-four hours. I have, however, already detailed cases in which vision was completely restored after such insensibility of several days duration, (see pages 461, 462 and 463,) and I shall subsequently bring forward other analogous instances. It is difficult to say in what number of days or weeks we should give up all hope of recovery. In the supposed case of total insensibility, or even of a near approximation to it, there would be more ground for apprehension than hope at the end of a week, though sight is sometimes restored under these circumstances; but the lapse of a few weeks without improvement, makes the case hopeless. In a case of amaurosis related at p. 462, sight was completely restored, although the complaint had lasted several weeks, and had nearly attained the degree of complete insensibility to light. When we succeed in the earlier cases of these serious affections, the restoration of sight is often only partial, the patient remaining in a state of amblyopia or weakness of sight.

The amaurosis attendant on confirmed hydrocephalus is hopeless; congenital cases are completely so. The subject of amaurosis consequent on direct mechanical injuries, has been already considered. See p. 185—189.

It is important to know what is likely to happen in the opposite eye, when amaurosis has occurred in one only. The causes of this affection are not merely local, or confined within the affected organ; they will generally, if unchecked, bring on disease in both eyes. The close sympathy between the two organs must also be considered; they both suffer in most cases, even in forms of disease that cannot be traced to causes of general influence. Interesting evidence on this point is afforded by those cases of wounds, in which the sight of one eye is lost: in many such instances internal inflammation, change of structure, and blindness occur subsequently in the other

eye. See p. 185—189. Hence our prognosis must be directed to the sound as well as to the diseased eye; hence, also, without expecting to benefit the diseased organ, we institute active treatment, and follow it up steadily in many cases, for the purpose of preventing the occurrence of disease in the sound eye.

Treatment.—Antiphlogistic measures.—The object is to put a stop to vascular excitement, to prevent the permanent injury of altered structure and impaired function in a part, the peculiar delicacy of which particularly exposes it to such danger. We must, therefore, employ antiphlogistic treatment, following it up with a decision and steadiness commensurate with the importance of the affected organ. Under this head must be included general and local blood-letting, more particularly the latter, as by cupping from the back of the neck or the temples, or by the application of leeches, the evacuation of the bowels by purgatives, and a restricted diet. Repose of the organ should be observed, more or less complete, according to the nature of the case.

[The following case shows the efficacy of these measures in simple congestive amaurosis.

Margaret McQuid, ætat. 19, a robust Irish girl, a servant in a family in West Philadelphia, applied to me February 18th, 1839. She stated that she had lost the sight of her left eye suddenly, two days previously whilst washing clothes; she had at that time intense headache, which still continues. Her bowels are open; menstruates regularly; eyes natural in appearance—three images of a flame visible in the pupil. Irides light blue, moderately active; pupil mean size. Vision with right eye perfect, with left she cannot distinguish any object, not even a lighted candle, though she has a faint perception of the light from it. She is of full habit; pulse active. I ordered her to be bled to the extent of sixteen or eighteen ounces and to take the following pills. ℞.—Calomel pp. gr. viij; pulv. rhei gr. x; g. aloes gr. ij. M. Ft. pilul. No. iv. Strict antiphlogistic diet.

20th. The patient had neglected to attend to these prescriptions until last evening. The headache had been promptly relieved by the bleeding. Pills have not operated; there is a slight improvement in vision. Ordered magnes. sulph. ℥j.

22d. Medicine has operated freely. Can see now pretty well the smallest objects, though they all appear as through a thin mist. Ordered a blister behind right ear, and senna and manna tea.

27th. Vision quite restored. Intends returning to her place.

I met this patient in the street ten or twelve days subsequently, and learned from her that her sight was as perfect as ever.]

Use of mercury.—This remedy is as beneficial in many cases of amaurosis, as in iritis, or general internal inflammation. The remark which I made respecting its employment in those affections, applies also to the present case, namely, that its good effect mainly depends upon the promptitude with which it is administered. The alterative form is insufficient; we give it with the view of arresting inflammation in the structure, which is the very seat of vision; that structure is easily changed by the inflammatory process; our only chance of success is to push the mercury in a decided manner, and if we do so, we shall put a stop to the affection. In the more acute cases, the remedy must be employed freely: it must sometimes be carried to the extent of producing ptyalism; and its use must be continued for several weeks, in order to ensure all the benefit that it is capable of conferring. I have treated numerous instances of amaurosis on this plan with the most

favorable results; with such benefit as I have not seen produced under any other mode of proceeding.

This mode of treating certain cases of amaurosis, that is, those in which the disease consists of active vascular disturbance in the retina, whether simply congestive or inflammatory, which is now generally adopted, and supposed to be of recent origin, is found to be the revival of an old practice. That it was thoroughly understood and clearly described by MEAD, has been shown by Mr. MIDDLEMORE, (*Treatise*, vol. ii. p. 276,) who adduces the following quotations from the *medical works* (*London*, 1762, p. 536), of our celebrated countryman, thus adding to modern practice the weight of comparatively ancient authority. "First of all blood is to be drawn both from the arm and the jugular, and to be repeated according to the degree of the disease. Then it will be necessary to give cathartics, especially such as purge gross humors; it will then be very proper to join calomel to other cathartics; or rather to take it by itself, and a few hours afterwards some gentle purgative. And this method often succeeds when the disease is beginning or recent; but if it be of some standing, it requires a more powerful treatment, that is, a plentiful salivation, raised by mercurials taken inwardly in small quantities, and at short intervals." "I made the first trial of this course on poor patients in the hospital, when I was a young practitioner, and afterwards on others, who thereby recovered their sight, for which I was complimented by the physicians, who till then had looked on the disease as incurable."

Some readers may be surprised at seeing this remedy mentioned again; at finding a plan of treatment proposed for amaurosis so nearly similar to what has been advised in other widely different affections. The free use of mercury has been already recommended in iritis and other internal inflammations, and in inflammation of the cornea, when proceeding to change of structure. Is it then a panacea? How does it happen that the same remedy should have the power of counteracting disease in textures so different from each other? This intended objection seems to me to constitute the strongest ground for confidence in the remedy. Although inflammatory diseases differ in their phenomena, symptoms, and results, and although these differences are often very striking in different textures, the essential nature of the diseased process is everywhere the same: it is unnatural exertion of the capillary vessels; and if we should have a remedy capable of checking that excitement in one part, there is every reason to suppose that it would be equally effectual in other instances. Thus we resort to abstraction of blood in the affections of organs most different from each other in structure. In the same way, if we are correct in ascribing to mercury the power of controlling certain forms and effects of inflammation, its use will be co-extensive with those forms and effects; consequently, each new example of its efficacy, instead of being inconsistent with our former evidence of its powers, affords fresh confirmation of its general influence.

Counter-irritation is a valuable auxiliary in the treatment of amaurosis; and blistering is generally the most convenient mode of carrying it into effect. The nape, behind the ear, the temporal and frontal regions are the most eligible situations, and may be blistered successively; a fresh application being made every five, six, or seven days. The blister should be of moderate size, particularly when applied on the temple or forehead.

When the means now recommended have failed, we shall not effect much by other measures. We must enjoin the mode of living most conducive to general health, and take the chance of such local amendment, as the affected organ may slowly experience under gradual general improvement. Residence in pure air, frequent exercise in the open air, a plain and mild but

nutritious diet, the regular use of mild aperients, and repose of the affected organ, form a combination of measures best calculated to invigorate the system generally, and thus to arrest local disease. It would be quite consistent with this plan to try the effect of mercury in minute doses continued for a long time. Counter-irritation may be employed at the same time. Blisters may be applied behind the ears, and at the side or back of the neck, and a discharge may be kept up by the savine cerate. But I prefer a succession of blisters, applying a new one to a fresh surface every five, six, or seven days. Some persons make blistering a principal part of the treatment, using thirty, forty, or more blisters in a single case. A seton in the back of the neck is another mode of accomplishing the same object.

Dr. Prichard has strongly recommended an incision through the scalp in the whole length of the sagittal suture, and converting it into an issue by filling it with peas.

The treatment I have described must be graduated, according to the violence of the attack, the constitution, age, and strength of the individual, and numerous other circumstances. No one mode of treatment is proper in all cases. It must not be supposed that all amaurotic patients require bleeding and salivation. When we meet with the affection in the form of active inflammation of the retina, more especially in a young and vigorous individual of full habit, where there are obvious marks of local vascular congestion and constitutional excitement, we must adopt active treatment, and follow it up steadily. A similar course of proceeding is necessary in the slower inflammation that is confined to the retina, when it occurs in robust and plethoric individuals, though it should not be attended with constitutional excitement; indeed, the indication for loss of blood, whether general or local, is not to be drawn entirely from the state of the circulation, but partly from that of the organ. The condition of the retina, as indicated by the degree of vision and other local circumstances, is the principal guide. General fullness of the vascular system, or determination to the head without general plethora, constitute additional reasons for abstracting blood, and for taking it freely from the system. If the affection be chronic, and unattended either with general plethora or congestion in the head, mercury may be administered in a milder way; and it may be necessary to pursue the treatment longer.

Amaurosis often comes on slowly and insidiously in persons of enfeebled constitution. The organ suffers from habitual excessive exertion, at the same time that the general powers are depressed by residence in confined dwellings, and bad air, by sedentary occupations, unwholesome diet, costiveness, and the other injurious influences of such causes. In the pallid and feeble woman, who had destroyed her health by close confinement to needlework, and whose eyes were beginning to fail, the same active measures would by no means be admissible as in the former case. To think of bleeding and salivating such a patient would be perfect madness; we should, in such a case, obviate costiveness, take a little blood locally, if at all, by cupping, or by leeches behind the ears, and then use mercury in the alterative manner, together with mild aperients. A few grains of Plummer's pill, or of the hydrarg. c. creta, might be given every night, or every second night, and the bowels might be kept open by electuary, castor oil, rhubarb and magnesia in some warm vehicle, or the compound decoction of aloes with tincture of rhubarb or senna taken occasionally. The blue pill may be taken in combination with aloes, or the compound extract of colocynth. If the retinal affection is serious, it might be necessary to persevere with mercury, slowly increasing the dose until a slight influence is visible in the mouth. A nutritious diet, with or without stimuli, good air and exercise, and repose,

or sparing and regulated exercise of the affected organ, are important auxiliaries; a succession of moderate-sized blisters might be advantageously combined with these means. Thus while the same principles regulate our treatment, it is modified in degree according to the violence of the symptoms and the patient's strength. In the latter description of cases, after mild antiphlogistic means and clearing the alimentary canal, it may be expedient to administer tonic and strengthening medicines, such as sarsaparilla, quinine, cusparia, calumba, cascarilla; and to allow a nutritious diet with porter or wine.

I subjoin a few cases, in order to illustrate practically the principles of treatment just explained.

Case I.—*Complete amaurosis, with congestion in the head, in a plethoric subject; perfect recovery.*—A young woman, twenty years of age, came to the London Ophthalmic Infirmary, then in Charter-house Square, laboring under active congestion in the head; her countenance was peculiarly florid; all the veins were obviously turgid, and she had considerable pain. Before I saw her, she had experienced severe external inflammation of one eye, which had produced a large leucomatous opacity of the cornea; the latter was in the state of incipient staphyloma. These serious changes, and the consequent loss of an eye in a young female of considerable beauty, were the obvious results of inactive treatment. She still suffered occasional relapses of inflammation in the eye; and at these times she experienced so much sympathetic affection of the opposite eye, that she could not use it without pain. Hence she readily submitted to the removal of the staphylomatous projection, which quickly and effectually relieved the sound eye. Within a month she came again, saying that she had lost the sight of the other eye. On examining it, I found that she had an attack of almost complete amaurosis; although it had existed only two or three days, she could hardly distinguish the situation of the window. She had a dilated pupil, and the iris was nearly motionless; there was no external redness, but she had, in addition to her usual florid color, a flushed countenance, considerable pain in the head, and some febrile disturbance of the system. Knowing from experience how prone she was to inflammatory attacks in the eye, I had her bled largely, and cupped on the back of the neck, placed her upon low diet and gave purgative medicines; but although this plan of treatment was followed up vigorously, no improvement of vision ensued; the retina indeed became quite insensible. Mercury was now used actively; as soon as it caused salivation, the affection began to give way, and she recovered her sight perfectly. She was still liable to returns of congestion about the head, and repeatedly lost blood by venesection and cupping; she continued to employ mercury and aperients, and ultimately had a seton in the back of the neck. In spite of such means, continued and repeated for more than a year, during which time she was often bled and cupped, and took an immense quantity of mercury and purgatives, she still retained her beautiful color and the florid red of a person from the country. She attended the infirmary nearly a year and a half, undergoing the treatment above described, more or less actively, during the whole time. I saw her two years afterwards, the eye remaining perfectly well; but, although she had still much color, the characters of youth and beauty were in a great measure lost.

Case II.—*Imperfect amaurosis with plethora, before menstruation had begun.*—Another young woman came to the Infirmary with impaired vision; her countenance was red and flushed, and she complained of considerable pain in the head; there was evident congestion in this part. She was about fifteen years of age; menstruation had not commenced, and the consequence was a plethoric condition of the system. She was bled two

or three times, purged actively, and continued this plan of treatment for two or three weeks before the retina was relieved, when the menses appeared and she completely recovered.

Case III.—*Imperfect amaurosis with congestion in the head; antiphlogistic and mercurial treatment; recovery.*—I was consulted in January, 1829, by Mr. M., a linen and woolen draper, of florid complexion, with much color in the face. He was rather lusty, but stated that he had been originally spare. He was accustomed to much exercise in the open air, and said that he did not live freely. On more minute inquiry, I found that he ate heartily of animal food, drank daily a quart of table ale, and a glass or two of spirit and water. Two years previously he had experienced a severe attack in the head, attended with slight paralytic symptoms. He was then twice bled, and cupped: he underwent other treatment, and was laid up for five months; but the sight was not then affected. On the 25th of December, 1828, he felt heaviness and dullness in the head, and was altogether unwell; but he took no medicine, and followed his usual occupations. On the 1st of January, 1829, the sight became dim, and the eyes would not bear employment. When he came to me on the 2d, the appearance of the organs was natural; the iris acted on both sides, not very briskly, but as well as in many persons with healthy eyes. There was no pain in the eyes, nor in the head. With the left eye he could not see even large print; with the right he could distinguish small print; but if he used them for a minute or two, as in reading, writing, or examining patterns, the sight became confused, and he could not go on; words and lines ran together, the stripes of a pattern became broken and mixed. The appetite was good, the tongue clean, the bowels regular, the pulse of moderate strength and not accelerated. (To lose twenty ounces of blood by venesection; a dose of calomel and jalap immediately, and a purgative draught the next morning; to discontinue fermented liquors and solid animal food.) 3d. Cupping in the nape to twenty ounces; afterwards, two grains of calomel and one-fourth of a grain of opium every six hours. 5th. Not worse, nor sensibly better. 7th. The head had been very uncomfortable yesterday, when the purgative draught was repeated with complete relief. To-day, the mouth is considerably affected, and the sight much improved; he can read ordinary print with the left eye, and he can employ the eyes without experiencing confusion of vision. 9th. Mouth very sore; breath fetid. Sight perfect. The irides act naturally, and he sees equally well with both eyes. (To continue the mercury.) 13. He has taken two pills daily, for the last three days, and is freely salivated. He went on a little longer with one pill daily; and in about three weeks the mercurial effect had gone off.

Case IV.—*Amaurosis nearly complete; antiphlogistic and mercurial treatment; recovery.*—Sarah Raymond, seven years old, with florid color and blue eyes, was brought to the London Ophthalmic Infirmary, in December, 1825. On first view she appeared healthy; but, after closer inspection, she might have been considered rather too fleshy; the color of the countenance was beyond that of health. She had become blind of the right eye, without any marked pain or complaint, and without obvious cause of any kind. The right eye was almost completely amaurotic; the left unaffected. 1st Dec. Four leeches to each temple; a dose of calomel and jalap every second day. 8th. Five grains of hydrarg. c. creta night and morning; a dose of rhubarb occasionally. 15th. Vision completely restored; medicines continued. 22d. The powder to be taken every night, and the aperient every second day. As she continued perfectly well, on her next at-

tendance, after a few days she was discharged, with instructions to her friends respecting the mode of living.

Case V.—*Amaurosis of both eyes, complete in one, imperfect in the other; antiphlogistic and mercurial treatment; recovery.*—About the same time another instance of amaurosis occurred at the infirmary, in a girl about fourteen. Sight had been lost in the right eye, and it was beginning to fail in the left. The duration of the affection on the right side was not known; the blindness had not been noticed until the sight became impaired in the left eye. There had been no pain of the eyes or head; and I could ascertain no other circumstance calculated to throw light on the origin and nature of the affection, than that the appetite had been good, and animal food had been taken freely. There was an appearance of fullness, with some flushing of the face, and a dull, heavy look. The parent, who accompanied this girl, applied on account of the left eye, considering the condition of the right hopeless. The treatment consisted in the abstraction of blood by cupping and leeches, aperients, the administration of mercury, (*hydrargyrus cum creta,*) and abstinence from animal food and fermented liquors. In about a month vision was completely restored in both eyes.

Case VI.—*Amaurosis, with visus dimidiatus in the first instance; use of mercury to ptyalism; complete recovery.*—A gentleman, thirty-eight years of age, of middle stature, moderate in his way of living, and constantly enjoying good health, came to me on the 14th of August, 1826, on account of impaired vision in the left eye. He had usually been employed from nine to twelve hours daily in his profession, that of an engraver; and he had been working very hard for several weeks on an important plate. He said that he chiefly used his right eye. The vision of the left had been imperfect for a few days. He could see the upper part of an object perfectly, with sharp outlines, as usual, but the lower part was confused. In looking at the title-page of a book, or a word in capital letters, the lower half of the leaf or of the word was not seen with clearness. He could not read an ordinary print with the left eye, and could only make out small capitals, one by one, and with difficulty. He had experienced some uneasiness; a kind of throbbing over the brow, and a weight of the upper lid, as if he could not elevate it so easily as the lower. There had been no general headache. There was no perceptible difference between the two eyes, nor any change in the pupil, the iris, or its motions. By the advice of his usual medical attendant, he had been cupped and taken aperient medicine the day before. (To lose sixteen ounces of blood by cupping on the nape; aperient pills daily; to abstain from fermented liquors, and take animal food sparingly, and not to employ the eye.) This patient did not visit me again till the 21st, when the pain was removed but the sight had become worse. He now saw the entire object imperfectly, and could not distinguish the capital letters in a title-page. (Ten ounces of blood from the left temple by cupping; two grains of calomel, with one-third of a grain of opium, every six hours,) 31st. Mouth not affected, sight rather worse. (To rub in ung. hydr. fort. ʒj. every night, and to continue the calomel and opium.) 24th Sept. The mouth has been sore for three weeks, and is now severely affected, with great irritation of the bowels and constitutional disturbance. Vision is greatly improved. (To keep up the mercurial influence by means of blue pill.) 10th Oct. The mercurial effect has been maintained in a slighter, but still decided degree. Health is recovered. Vision is perfect, but exercise of the eye brings on uneasiness. 24th. He can read the smallest print, but the eyes do not yet bear exercise. (To leave off mercury; to go to the country, for change of air; and to return slowly to the use of the eye.) In a few weeks this gentleman had completely recovered.

In 1829, I learned from his brother that there had been no relapse: that vision continued perfect, and that the patient followed his occupation of engraving regularly as he had done before. In the present year (1840) I have heard that no return of disease has been experienced in this case.

In the preceding case, the patient saw only the upper half of objects with the affected eye. In another instance, which came under my observation in the autumn of 1830, where there was incipient amaurosis of one eye, the patient saw only the left half of objects; thus in the word CLINIQUE he saw only the first three letters.

CASE VII.—*Imperfect amaurosis of four weeks' duration: treatment by depletion and mercury; recovery.*—In the summer of 1830, I saw the captain of a merchant vessel, between fifty and sixty years of age, who had lived freely. He had enjoyed but little sight with the right eye since he had the small-pox; but the cornea, iris, and pupil were natural. In coming home from the Mediterranean, the sight of the left eye failed. When I saw him, four weeks after the attack, he could not distinguish even capital letters. The pupil was in the middle state; the iris acted equally well in both eyes. He had been bled and purged. I ordered mercury. The mouth became sore, but was not considerably affected; it remained so for five weeks, when I saw him again. He could now read ordinary print. I recommended that the mercurial influence should be carried further, and kept up for some weeks.

CASE VIII.—*Imperfect amaurosis; with partial double vision: antiphlogistic and mercurial treatment; recovery.*—James Bailey, fifty-five years of age, a tall muscular man, with light complexion and eyes, applied at the London Ophthalmic Infirmary in 1826, with imperfect amaurosis of both eyes: he saw double in some directions. He could make out capital letters a third of an inch in height; but he could not read even a large ordinary print. Severe headache had preceded and accompanied the failure of vision. The motion of the irides was hardly impaired. The pulse natural. Jan. 5th. (Venesection to twenty ounces: a dose of calomel and jalap immediately, and afterwards five grains of blue bill three times a-day. To abstain from animal food and fermented liquors.) 7th. Vision improved. (Cupping on the nape to sixteen ounces; the pills continued.) 10th. The mouth is sore; the double vision and headache are gone; he can read middle-sized print. (The pills continued.) 17th. Sight quite recovered. (Five grains of blue pill every night, and an occasional aperient.) 28th. Quite well; recommended to continue the remedies for a fortnight.

CASE IX.—*Amaurosis nearly complete; mercurial treatment; recovery.*—Mrs. G., forty-four years of age, of fair complexion and blue eyes, who had ceased to menstruate two years, consulted me for an affection of the eyes, on the 27th of July, 1831. Her eyes had been bad eight years before, while she was suckling. The disease begun a month after delivery: there was some external redness, and the sight was so bad, that she could not see to read or work for some months. This gradually went off, and sight was completely restored. She had been confined to the house for three weeks before I saw her with an attack of influenza, in which the bronchial membrane had been principally affected. The illness had not been considerable. Leeches had been once applied to the chest; she had felt weak, and the tongue had been foul. She had felt some imperfection of sight, but had been able to read. On the 24th vision had become rapidly worse. Six leeches had been applied to the temple, on the 26th, without any benefit. When I saw Mrs. G. on the morning of the 27th, the appearance of the eyes was nearly natural; the irides were rather sluggish, and the pupils slightly dilated. With the right eye she could distinguish nothing; with the left she could

difficultly discern a large object, such as a person, but without being able to determine what it was. There was no pain in the eyes, and she said that she felt none in the head; but it appeared, on close examination, that there was some unusual sensation about the right temple. She felt weak; the pulse was a little accelerated, but not full nor strong. The tongue is foul. (Cupping on the nape to fourteen ounces; an aperient draught; then two grains of calomel with one-third of a grain of opium every six hours.) 11th August. The calomel and opium have been continued to this time, without affecting the mouth further than to produce an unpleasant taste in the morning. The bowels have not been disturbed; indeed they have required the occasional use of aperients. The tongue has become cleaner; the health and spirits are improved. There has been a regularly progressive amendment of vision; and Mrs. G. was this day able to read the print of an ordinary octavo. The eyes, however, are fatigued even by a short trial, and light is rather offensive. 16th. The bowels had been irregular and rather confined, and an attack of purging, with considerable pain, took place on the 14th. Chalk mixture with tinct. opii was ordered by Mrs. G.'s usual medical attendant. She felt very ill, and the sight was much worse on the 15th, the nervous structure of the eye probably partaking of the depression under which the system generally was laboring. Last night she slept well, and she is much better to-day; the sight not only having recovered, but improved. She can now read a small print. (To omit the pills for twenty-four hours; then to take five grains of hydrarg. c. creta three times a day.) 20th. A return of pain in the lower part of the abdomen took place, with purging: there was a sensation as if the bowels were imperfectly relieved, and there was still something to come away. Purgatives were ineffectual. On examining the rectum, it was found blocked up with hardened feces, which it was necessary to remove with the finger and instruments. Very copious evacuations then ensued, with complete relief of the intestinal symptoms. Mrs. G. continued the hydrarg. c. creta for ten days or a fortnight, the power of vision having been previously completely restored. The eyes, however, remained unnaturally sensitive to light, so that the protection of a shade or colored glasses was necessary when she went out; and employment of them in reading, writing, or needlework, could not be borne for more than a few minutes without bringing on confusion of vision and pain. Mrs. G. now went into the country to recruit her health. The power of continued exertion has returned but slowly; and Mrs. G. cannot now (December, 1832) exert the eyes for more than two hours at a time. She can discern the minutest objects as well as ever. Subsequently the powers of the retina were completely restored; this lady's eyes became, and continue, (1840,) as strong and useful as ever.

Case X.—*Impaired vision with presbyopia; mild antiphlogistic and mercurial treatment; recovery.*—Late in the spring of 1827, a young lady had severe inflammation of the fauces, attended with loss of voice, for which she was confined to bed nearly a fortnight, and employed depletion to the extent of weakening her considerably. "During this illness," she says, "the light was very distressing to my eyes; but when a little recovered, they appeared quite uninjured, and I was able to read, &c., as usual; till one day, my strength being a little restored, I was induced to walk a few paces in the open air, but quickly returned into the house, being sensible of pain from the glare of sunshine, and also finding my eyes water from the influence, as I supposed, of a keen east wind. Whether the light or the wind had anything to do with the disorder that ensued, I do not pretend to determine, only stating the fact, that the suffusion of water in the eyes continued for two or three days, during which time I gradually experienced more and

more difficulty in reading, &c. For a time I could read a good print at the distance of eighteen or twenty inches; afterwards at the distance of a yard; whilst, on holding the book nearer, the letters were quite confused; but in a few days I lost even this power, and could no longer clearly discern small objects in any part of the room: a white thread would appear double, and one fly on the ceiling would seem to be two. The indistinctness of objects to my sight resembled that which we experience when looking through a lens at a wrong focus, with this difference, that whilst perpendicular and curved lines were indistinct, horizontal ones were distinguished as clearly as before. Though I had not then completed my twenty-third year, I had all the symptoms of that decay of sight which accompanies old age, and found the defect supplied by convex glasses; but as the use of these was followed by unpleasant sensations, and as I had occasionally some pain above the eyebrow, with a weakness which made it difficult to fix the eye steadily on any object, it was judged expedient that some remedies should be tried in preference to having recourse to the use of artificial aids to the sight. Bleeding with leeches under the eyes, and some other means, were tried ineffectually."

When I saw this lady on the 1st of June, I found that after the inflammation of the throat had been removed, she had begun to live more freely, in order to restore her strength; but yet had proceeded cautiously. Soon after, slight uneasiness was felt about the forehead, and some imperfection of sight was noticed. In consequence of the menstrual discharge having failed, steel was given, with some benefit, in respect to the intended object; but the sight became rather worse. At this time there was a little pain across the lower part of the forehead, only mentioned on close questioning; a little flushing of countenance. The left iris is rather sluggish. A luminous circle appears before this eye, on using it. There is general debility. It appeared to me that the impaired vision depended, in this case, on an affection of the retina of inflammatory character, caused in a debilitated individual by slight stimuli, which would not have affected one of ordinary health and strength. The treatment recommended was, leeches to the temples, mild aperients, five grains of the hydrarg. c. creta twice or thrice daily, simple and unirritating, but not low diet, gentle exercise, and taking the air in an open carriage. 19th. The mercury soon produced gentle salivation, and has agreed well: the symptoms are decidedly improved. 26th. The gums continue sore; objects can now be seen at various distances nearly as well as ever; but the eye is soon fatigued. In the following statement, dated January, 1828, the intelligent patient describes the progress of her recovery.

"Some improvement was observed as soon as the soreness of the gums came on; but it was not till the means had been persevered in for several days, that any further benefit was perceptible. The power of distinguishing objects at various distances returned by degrees, together with the increase of distinctness in their outline. I was greatly surprised one day, on taking up a book, to find, that, instead of the perpendicular lines being doubled, as I had before uniformly observed to be the case, it was the horizontal which then exhibited this curious variation; but very soon after this, the power of distinct vision was restored, and I once more beheld every object, whether near or distant, clearly. It was thought best to continue the use of the mercury for some time longer; and even after discontinuing the medicine, I was advised to abstain for some months from every employment which required much exertion of sight; indeed the weakness of my eyes rendered this caution necessary, as well as that of avoiding the glare of sunshine and lamp-light, both of which gave me pain. Six months have now elapsed, and I am thankful to state, that I have been able to perceive a slow, but

steady increase of the power of sight, which has kept pace with the restoration of my general health and strength."

Although the preceding cases exhibit, in a striking point of view, the power of mercury in controlling that disturbance of the retinal circulation which causes amaurosis, it must not be inferred that all cases will yield to the remedy. The prognosis seems to me particularly unfavorable when the pupils are contracted, as will be apparant from the following instances.

Case.—*Amaurosis with contracted pupil; mercury employed without benefit.*—In the summer of 1826, I saw a patient who had lost the sight of his left eye in the East Indies two years before. No effectual treatment had been adopted. When he reached England, he consulted a surgeon, who made light of the complaint, and said that it would do well, and advised him to live as usual, and take four or six glasses of wine daily. When I saw this gentleman in May, the sight of the left eye was gone; the right was still perfect. Both pupils were rather contracted, and equally so, not quite circular, but of natural color. The irides moved but very slightly. He had not experienced much pain in the eyes or head. The countenance was rather flushed, the tongue foul, and the breath offensive. It appeared, on close examination, that although sight was still perfect with the right eye, the use of it brought on pain. I recommended cupping, mercurial alteratives and aperients, and regulated diet, which were adopted with some advantage. After a consultation held on the case with Dr. Farre, a mercurial course was tried without any benefit. Indeed, at the end of it, there was more pain in both eyes, especially after using the right; the sclerotic vessels were distended in both. When these symptoms had been removed by cupping and blistering, I recommended removal to a pure air, exercise in the open air, quiet and regular living, mild and simple diet, with regulation of the bowels.

Case.—*Amaurosis with contracted pupils; not benefitted by mercury.*—A gentleman about thirty, rather tall and thin, who had been occupied for many years in the counting house, and had lived freely, gradually lost, first one, and then the other eye. I saw him a few times at distant periods, but he did not follow any plan regularly. When he was nearly blind with the second eye, he thought more seriously of the matter, and consulted Dr. Farre with myself. Both eyes were amaurotic; the pupils contracted and motionless. Mercury was tried for twelve weeks without any benefit.

Local applications.—These have been frequently employed in amaurotic cases; but what good can we expect from such means in the affections of a part so deeply seated as the retina? They have generally been of a stimulating kind, and have been used on the erroneous notion of the affection depending on weakness, of its originating in a debilitated state of the optic nerve. Spirits of wine and ether have been applied round the orbit and on the forehead; and when there is congestion and increased heat, the evaporation may have produced some benefit. Luckily these applications cannot accomplish the purpose for which they have been generally recommended, that is, stimulating the optic nerve. It is necessary sometimes to employ local measures to satisfy patients, who often feel, or fancy that they feel, better after them. We may prescribe, as an embrocation for the forehead, rose water, with some rectified spirits or spirit of rosemary; Hungary water, or Eau de Cologne. Ammoniacal vapors have been applied to the eye itself; and the stimulus to the conjunctiva might possibly relieve the retina. It has been recommended to wash the head every morning with cold water; this is often attended with pleasurable feelings to the patient, and it is a practice which cannot do harm under proper discrimination.

In the foregoing remarks, I have represented that form of amaurosis,

which has its origin in the retina, as a symptom, in the majority of instances, of inflammatory affection, or, at least, of disturbed circulation in the nervous structure; and, consequently, requiring treatment analogous to that pursued in the management of other inflammations. Whether the correctness of the pathological view be admitted or not, the practical deduction will, I am sure, be justified by experience. The treatment now recommended is nearly opposite to what has been heretofore advised and relied on. I must therefore advert shortly to some of the ordinary modes of proceeding.

Emetics.—Schmucker,* Richter,† and Scarpa have placed great confidence in medicines of this class, followed by what they call resolvent remedies; using them, not merely where decided symptoms of disordered stomach might lead to the conclusion that the amaurotic affection was caused sympathetically by disturbance in the alimentary canal, but very generally in cases of imperfect amaurosis. Scarpa says that "by an attentive examination of the nature and causes of the *imperfect amaurosis* which admits of a cure, it is found, from the careful observations of Schmucker and Richter, that this disease is most frequently derived from a morbid excitement or irritation in the digestive organs, from sordes, or from worms, especially in children, either alone or accompanied with general nervous debility, in which the eyes participate sympathetically. Agreeably to these principles, in the greater number of cases of *recent imperfect amaurosis*, the principal indication of cure which the surgeon ought to fulfil in the treatment of this disease, is that of unloading the stomach and primæ viæ of the crudities, worms, or morbific stimuli; and afterwards, of strengthening the gastric system, facilitating the digestion, and at the same time exciting the whole nervous system, and particularly that of the eyes, which are affected and rendered torpid by a sympathetic connection." (*Treatise, &c.* p. 458.)

"With respect to the first part of the treatment of the *imperfect amaurosis*, the intention is perfectly answered by emetics and internal resolvents (*antiphlogistic purgatives*). In the class of emetics, experience has taught that the *antimonium tartarizatum* is preferable to every other, and that when given afterwards, in small and divided doses, it answers the purpose of a resolvent medicine, the action of which may be increased by conjoining it with gummy or saponaceous substances. In the treatment of the *imperfect amaurosis*, therefore, which is most frequently sympathetic, and depending on acrid matters in the primæ viæ, it will be proper at first, in the greater number of cases, to dissolve, for an adult, three grains of tartarized antimony in four ounces of water, of which two tablespoonfuls may

* In his Chirurgische Wahrnehmungen, first part, Schmucker states that he had often seen soldiers become suddenly blind on forced marches, particularly in hot weather, and when they had much to carry. A venesection immediately, and the day after three grains of the tartrite of antimony, generally restored the sight. If recovery did not take place, the jugular vein was opened, the antimony repeated on the following day, and a blister applied: these means were usually successful. The commencement of the second volume of his Vermischte Chirurgische Schriften is devoted to amaurosis, in certain cases of which he recommends the tartrite of antimony, given in such doses as to excite nausea, but not vomiting. He had often experienced the best effects from his pills, which are mentioned further on.

† In the fourth volume of the Commentarii Soc. Reg. Scient. Goetting. Richter says, that in a patient who had become blind after being in a violent passion, he restored sight by an emetic, administered on the following day. In his Anfangsgründe der Wundarzneykunst, he recommends emetics and purgatives, with other resolvent medicines, in the cases where there is reason to suspect the existence of acrimonious matters in the primæ viæ; vol. iii. § 448. He also advises this mode of proceeding on merely empirical grounds, when the cause of the affection is not discovered; and we are consequently unable to pursue a rational plan of treatment. Ibid., § 454.

be taken every half hour, until it produces nausea, and afterwards abundant vomiting. On the following day he should be ordered to take the resolvent powders, composed of one ounce of the crystals of tartar, and one grain of the tartarized antimony, divided into six equal parts, of which the patient should take one in the morning, another four hours afterwards, and the third in the evening, during eight or ten successive days. This medicine will produce a slight nausea, and some evacuations of the bowels more than usual, and perhaps, after some days, even vomiting. But if, during the use of this opening powder, the patient make ineffectual efforts to vomit, and complain of a bitter taste and want of appetite, without any amendment of the sight, the emetic should be repeated, and even a third and fourth time, if the presence of the morbific stimuli in the stomach, bitter taste, tension of the hypochondria, acrid eructations, and tendency to vomit, require it. For it not unfrequently happens, that the patient, on the first action of the remedy, throws up only water, with a little mucus; but, on repeating the emetic, after the nauseating powder has been used for some days, a considerable quantity of yellowish-green matter will be thrown up, which will greatly relieve the stomach, head, and eyes." (*Treatise, &c.*, p. 459, 460.) When the disease is caused in children by worms, Scarpa recommends the *coralline of Corsica*, (*mousse de Corse, fucus helminthocorton;*) or, when that cannot be procured, the semen santonici (quære, *artemisia santonicum?*—Ibid., p. 460, 461). When the stomach has been cleared, he advises the pills of Schmucker, or those of Richter, of which the following are the formulæ. For the former: ℞. Gum. sagapen. galbani, saponis veneti, aa ʒj; rhei. opt. ʒjss; antimon. tart. gr. xvj; succi liquirit. ʒj M. The mass should be divided into pills of one grain, and fifteen should be taken morning and evening for four or six weeks. For the latter: ℞. Gum. ammoniaci, asafœtidæ, saponis, veneti, radicis valerianæ, summitatum arnicæ, aa ʒij; antimon. tart. gr. xviij. Misce. To be divided into pills of two grains each: fifteen to be taken three times a day for some weeks. (Ibid., p. 461, 462.)

"The phenomena," says Scarpa, "which are usually observed to happen in consequence of this treatment, are the following:—The patient, after having vomited copiously, feels more easy and comfortable than before. Sometimes, on the same day on which he has taken the emetic, he begins to distinguish the surrounding objects; at other times this advantage is not obtained till the fifth, the seventh, or the tenth day; and in some cases not till some weeks after the administration of the emetic, and the uninterrupted use of the opening powders and pills. As soon as the patient begins to recover his sight, the pupil is found less dilated than before, and also contracts more when exposed to the vivid light of a candle; and in proportion as the power of vision augments this contraction and mobility of the pupil increase. Upon the whole, the cure is seldom completed in less than a month, during which time the use of local remedies calculated to excite the torpid action of the nerves of the eye should not be neglected." (*Treatise, &c.*, p. 462.) For the latter purpose, Scarpa recommends the vapor of the liquor ammoniæ. The eye may be exposed for half an hour at a time, three or four times in the day, to the penetrating vapor arising from this fluid in a small vessel, as near to the organ as can be borne conveniently.

When the stomach has been cleared, and the patient has in a great measure regained his sight, Scarpa endeavors to strengthen the stomach, and invigorate the nervous system. An ounce of powdered cinchona, and half an ounce of valerian root should be divided into six powders, of which one may be taken night and morning for at least five weeks. During this time, exercise in a good air, and tender juicy food, with a moderate quantity of wine, are recommended. (Ibid., p. 463.)

The respect justly due to the names of RICHTER and SCARPA would naturally lead us to try a mode of treatment which they have so strongly recommended. I have accordingly employed their plan in some instances which appeared favorable, but entirely without success. I have seen no case of amaurosis cured, or even relieved, by such measures. On the contrary, after the ineffectual trial of emetics and nauseants, I have removed the disease by the abstraction of blood and the other treatment already described. I have therefore entirely abandoned the use of emetics in amaurosis. I should not consider them safe if general plethora, determination to the head, or active disturbance of the retinal circulation were present. As the full trial of the plan would require several weeks, we must also consider the loss of time that it involves. If the disease does not yield to our treatment, it will advance; and, from being imperfect and curable, it may become, in a few weeks, complete and incapable of cure.

[Our own experience is in entire accordance with that of Mr. LAWRENCE respecting the value of emetics in the treatment of amaurosis.]

Electricity has been frequently employed in amaurosis, as well as in most other nervous affections. Mr. HEY,* of Leeds, published some cases of amaurosis which he considered to have been much benefited by electricity; and the late Mr. WARE† seems to have relied on it almost entirely. Indeed this influence, in all the varieties of its application, as well as various other stimulants, has been tried over and over again in this affection, with so little decided benefit, that its efficacy is altogether doubted by the profession. This doubtful remedy is objectionable in the early stage of the complaint, because it supersedes other means, of which the superior efficacy is well established. Nor can I deem it safe at that period, inasmuch as a powerful stimulus is not likely to tranquilize an over-excited organ. For this reason I should consider it dangerous whenever congestion exists in the head, or active disturbance in the eye. The indiscriminate use of electricity, therefore, for which the authority of Mr. HEY and Mr. WARE might be quoted, seems to me both ineligible and unsafe. If, however, the rational means, which a full consideration of the case points out, should have been judiciously tried without effect, the patient may take the chance of this empirical remedy.

[We have related at p. 120 some cases in which galvanism was used by us with advantage.]

Sternutatories.—Mr. WARE has strongly recommended the use of a snuff consisting of ten grains of turpeth mineral (not in the London Pharmacopœia; it is the *hydrargyri oxydum sulphuricum* of the Dublin) and one drachm of the *pulvis asari compositus* (Dublin Pharmacopœia: it was formerly called *pulvis sternutatorius*). "A small pinch of this snuff taken up the nose is found to stimulate it very considerably; sometimes exciting sneezing, but in general producing a large discharge of mucus." (Ibid., p. 405.) Mr. WARE afterwards says, that "in order to be more exact in the use of this remedy, I have lately accustomed myself to prescribe one grain of the turpeth mineral to be mixed with twenty grains of the powder of liquorice, of snuff, or of sugar; and one-fourth, or one-third of this powder to be snuffed up the nose two or three times in the course of the day. And in those cases, where the nose has been particularly dry, I have rendered the powder more effectual by directing the patient to inhale the steam of warm water through the nose previous to the use of the snuff." (Ibid., p. 417.)

* Medical Observations and Inquiries, vol. v.

† Memoirs of the Medical Society of London, vol. iii. Also, "A description of fifteen Cases of the Gutta Serena, with incidental Remarks," in Observations on the Cataract, Gutta Serena, &c. Third Edition, 1812.

Stimuli and tonics.—The generally prevalent notion, that amaurosis depends on nervous debility or atony, has led at all times to the free employment of various means supposed to possess the power of rousing the energy of the retina or of the nervous system generally. Such means, or at least some of them, have been called *antiamaurotic;* and they have not unfrequently been used empirically, one after the other, where the practitioner has not perceived any obvious indications of treatment. A glance over the list that follows will show how much physic must have been wasted in practice conducted on such principles. If I were to enumerate all the remedies of this description, which have been recommended and actually used, the catalogue would comprehend everything that comes under the head of tonic and stimulant, of nervous, antispasmodic, and antiparalytic. The greatest favorites, however, have been the various bitters and tonics, the arnica montana, pulsatilla, valerian, bark, black hellebore, calamus aromaticus, camphor, opium, hyoscyamus, musk, assafœtida, castoreum, phosphorus, ether, ammonia, flores zinci, steel, and naphtha; even millepedes have been strongly recommended. If the treatment already advised be capable of doing any good; if the pathological views on which that treatment is founded approach in any degree to correctness, all this farrago of nervous medicines and stimulating substances must not only be inefficacious, but absolutely injurious; and indeed, on referring to many of the articles in this list, we cannot suppose that they could be put into the stomach without disordering the health generally. If these substances are capable of doing any good in this affection, then the antiphlogistic and mercurial treatment must be completely wrong. I am, however, firmly convinced that the tonic and stimulating plan is entirely erroneous; that it is founded on mistaken notions, or rather on complete ignorance of the pathology of the affection. Unfortunately this error is not an indifferent one, for if we treat a case of amaurosis on wrong principles, we are not only losing time, which is of the greatest value, but contributing to the progress of the disease. I have seen too many cases where the disorder has been decidedly aggravated by the very means used for the purpose of removing it.

A striking example was afforded by the case of a boy at school, about fifteen years of age. He came home to dine with his family not having felt ill, nor made any complaint. In helping himself to wine, he poured it not into the glass, but by the side. It was found by examination, that the sight of one eye was very imperfect. A gentleman, who was consulted, directed a few leeches to the temple on account of slight pain in the head, and opening medicine; measures of proper kind, but not sufficiently active. At the end of two or three days, the symptoms not being removed, the parents were informed that the imperfection of sight arose from want of tone in the nerve, which must be remedied by generous diet and tonic medicine; the pilula ferri cum myrrha was prescribed. Under this plan, in ten days, the eye first affected had become totally amaurotic, and dimness of sight occurred in the other. I saw the patient at this period, and could only succeed in preserving imperfect vision in the eye last affected.

In the summer of 1831, I saw a lady, thirty years of age, with light hair and gray eyes, of spare habit, married, and menstruating regularly; but without children. She had been accustomed to read much, particularly at night. In the preceding winter she had experienced headache, to which she had not been previously subject, and she still suffered much from it. Five months before I saw her, the sight of the right eye had become dim, and the affection had gradually increased. Within a few days she had been alarmed by imperfection of vision in the left eye. She had been told, some time previously, that the affection of the eye was nervous, and that she ought to

take strengthening medicine and to live well. In pursuance of this advice, she drank porter, and brandy and water. I found her with a strong and full pulse, hot skin, headache, and foul tongue. With the right eye, of which the pupil was in or about the middle state and motionless, she could see nothing straightforwards: there was still a little sight of objects placed towards her right. The pupil of the left eye was rather smaller than that of the right, and sluggish. Light was very offensive, causing a dazzling, which prevented sight almost entirely. With this eye she could see the smallest print; but she could not read ten lines. Abstraction of blood from the temple, which was accomplished twice by cupping and once by leeches, discontinuance of the dietetic stimuli, and the administration of mercury for six or seven weeks, removed the general excitement and the headache, made the tongue clean, and improved the health considerably. The sight of the right eye, however, was not restored; nor were the inconveniences produced by strong light on the left entirely removed.

The belief that amaurosis depends on impaired energy of the nerve has been strengthened by the circumstance occasionally noticed, that patients feel and see better after the excitement of wine or of a full meal. The failing powers of the retina may experience a momentary increase by the temporary acceleration of the circulation consequent on the stimulus; as ideas are produced more rapidly, and thoughts and language become more powerful and brilliant, when the blood circulates more quickly in the brain, and as the enfeebled stomach of the drunkard is roused by a dram. What should we expect from a regular course of drams, or from permanent excitement of the brain?

Tonics and stimuli, medicinal and dietetic, occasionally find place in the treatment of amaurosis. The disease, in some cases, depends on weakness of the nerve, or is connected with general debility. In other instances the patient is reduced by our treatment, and perhaps by the distress of mind, often amounting to despondency, consequent on the dreadful calamity of blindness. Sometimes, when there is no longer any reasonable prospect of restoring sight, nothing is left for us but to enable the sufferer to bear up under his privation, by upholding the general powers, and restoring the tone of the nervous system. In these several cases there are sufficient reasons for employing medicines of the class now under consideration. My objection is to their indiscriminate use, to their being ranked as primary and principal means in all cases of amaurosis, merely because the nerve is said to be *weakened*, and to the blind empiricism which often administers them in succession, because they have been called *antiamaurotic*.

Use of strychnia.—As this remedy, both in its external and internal administration, has been found a powerful stimulant of the nervous system, in various cases of paralytic affections and impaired sensibility, its powers have been tried in amaurosis. It may be considered particularly applicable to the instances in which simple want of power, or atony of the nervous structure without vascular excitement, is the cause of the symptoms. Mr. Middlemore, who has tried the remedy in many cases, says, "If a person be suffering from loss or diminution of the power of vision from an atonic state of the retina, or other part of the nervous apparatus of the eye, or of the system generally, the local use of strychnia will be, in my opinion, the most likely means of removing the defect, more especially if it be of recent occurrence."

On another occasion, Mr. M. describes more particularly the cases in which benefit may be expected from strychnia. "If a patient has overworked the eye by long continued action, confined to the inspection of objects of the same color and description, an enfeebled condition of retina

(just as we produce an exhausted state of muscle by over exertion) will take place. If a man subject his eye to unnatural stimulus, by looking for many hours daily at bright substances of the same or nearly the same color, or to sudden transitions from an artificial glare to comparative darkness (as miners), or to a diminished stimulus, as by working in dark rooms, or places imperfectly supplied with light; or to any cause allowing the visual textures of the eye to remain, for a long period, in a state of inactivity, as takes place where large opacities of the cornea, and fully formed cataract exists, the power of the retina will be partially destroyed, its susceptibility to the stimulus of light diminished; but in none of these cases will there be found any structural change in the retina or the optic nerve, any congestion of vessels, or any discoverable alteration from a healthy and natural condition; nor will the system, in all probability, be found affected; no altered state of health, sufficient to account for the dimness of vision, will be found to exist." "Loss or diminution of the power of vision sometimes comes on from certain causes which diminish the vigor of the system generally, as, for instance, after profuse salivation, long continued suckling, menorrhagia, &c. In all these cases, I believe, the strychnia is calculated to produce great and permanent advantage, in combination, of course, with other remedies suited to the particular exigencies of the case; for example, if the retina be weakened in consequence of diminished vigor of the system, remedies adapted to strengthen the system, and a removal of the cause enfeebling it, might be joined to the local application of the remedy in question. But the power of the retina will not always return with the returning strength of the system; in such cases the strychnine is singularly valuable, producing with wonderful rapidity, the restoration of the organ of vision. Strychnine, given internally, does not produce the same beneficial effect upon the retina, as when applied externally."

The mode of employment is to place a blister over the eyebrow, to remove the cuticle, and then dust the remedy over the denuded surface, beginning with the sixth of a grain on each side, and gradually increasing the quantity until one grain is used on each side, or until the head becomes affected. Mr. M. considers that greater effect is produced when the substance is applied over the supraorbitary nerve. He gives the following general directions:—"Place a narrow blister over each eyebrow, which must not extend beyond a line drawn upwards from the external canthus; when it has arisen sufficiently, cut away the cuticle, and apply, for half an hour, a piece of linen to absorb the serum, which is apt to be discharged in large quantities for a short time after the removal of a blister; then dust the remedy chiefly in the situation of the supraorbitary nerve, but not so thickly as to prevent the absorption of the whole layer of the powder, at the time of the second dressing, which should be twenty-four hours afterwards; this is a proper interval between the dressings; cover the blistered surface with a piece of linen thinly spread with ung. cetacei." "Increase the dose of strychnia very gradually until the state of vision is improved, or symptoms indicative of the injurious agency of the remedy occur. If there be much local pain, excited by the application of the strychnia, dilute it with flour, or mix it with opium; and if that do not succeed, suspend its employment, until the stomach and bowels be improved, by a plan of treatment instituted expressly for their benefit, and then resume its use. If severe pain in the head, convulsive muscular twitchings, great general nervous excitement, or other symptoms, denoting the injurious agency of the strychnia upon the constitution, supervene, and the condition of vision be not improved, it must be discontinued altogether."*

* Report of the Birmingham Eye Infirmary, in the Midland Medical and Surgical

This remedy has been employed by Mr. LISTON,* in the Edinburgh Royal Infirmary. He applied the blisters on the temples, and began with a quarter of a grain of the strychnia on each side, gradually increasing the quantity to one grain and a half, which brought on headache, vertigo, debility, nausea, and muscular tremors. As other means were employed at the same time the evidence respecting the powers of strychnia is the less clear.

In his *Treatise on Diseases of the Eye*, (vol. ii., p. 290, 291,) published since the observations previously quoted, Mr. MIDDLEMORE states that his favorable opinion of strychnia has been strengthened by subsequent experience.

Mr. TYRRELL says that he has frequently tried the remedy in the cases which appeared to him most appropriate, but that he had not seen one single instance of benefit from its employment, although he had persevered until alarming muscular contractions were produced. He considers, further, that serious mischief has resulted from its indiscriminate use. (Vol. ii., p. 316.)

My own experience coincides with that of Mr. TYRRELL, in reference, not only to strychnia, but also to veratria, which he has found equally inefficacious.

The latter remedy is employed in the form of ointment, in which from ten to twenty grains of the veratria are incorporated in an ounce of lard or spermaceti cerate. The size of a large pea, or a horsebean is to be rubbed on the temples and forehead for a few minutes, once or twice in twenty-four hours. The application causes redness, heat, and tingling; sometimes with more considerable irritation; and the friction should be continued until these effects are produced In this mode of employment the veratria may be of some service as a mild counter-irritant. I have seen it used many times, but it has never produced essential and unequivocal benefit in a decided case of amaurosis within my observation. Sometimes, in females, it has irritated excessively, causing nervous symptoms, which have excited alarm; and patients have even stated that it has injured sight.

[The results of our experience with strychnine in amaurosis, are much more favorable to the value of this remedy, than those of Mr. LAWRENCE and Mr. TYRRELL. It has certainly proved inefficacious in not a few cases which seemed suitable for its employment, but in others it has been productive of the best effects. We have found it far more effectual, however, when applied to the eye, in the form of collyrium, or given internally, than when applied to a blistered surface; indeed, we do not remember a single cure effected by the latter method of using it. The cases in which it shows its best effects are those attended with dilatation of the pupil; for this article has almost as decided an effect in producing contraction, as belladonna has of causing dilatation of the pupil.

The following case is one of the most striking we have met with of the efficacy of the remedy. Harriet Taylor, aged twelve, was admitted into Wills Hospital, November 10th, 1838, with amaurosis of right eye:

Reporter, May, 1830, vol. ii., p. 158, 159; also, On the Utility of Strychnia in certain forms of Amaurosis, ibid., p. 481—485. The remarks are republished in the London Medical Gazette, vol. viii., p. 434—437.

In another short notice contained in the same periodical, Mr. MIDDLEMORE mentions, that in two or three instances it has produced so much headache and spasm, that its employment could not be continued; whilst two or three patients who were much benefited by it experienced so much local pain, that they would not persevere in the use of the remedy. In three cases where it was serviceable, its continued use was necessary to preserve vision, which was invariably lost when the strychnia was discontinued—Ibid., p. 240.

* London Medical Gazette, vol. v., pp. 541 and 575.

vision in left eye good. Her mother stated that she had first noticed her daughter's defect of sight about three years ago, since which period it had been growing gradually worse. For four months the right eye, to use the patient's own expression, had been "quite dark." She cannot distinguish a candle with it, though she has a faint perception of the light. The patient has light hair; complexion fair; irides gray, contracting on exposure to light; pupil of right eye rather more dilated than that of left; is sometimes troubled with headache. We could not learn anything from the history of the case, as given by her mother, calculated to throw any light on the cause of the loss of sight.

There was evidently no congestion of the cerebral organs, or inflammatory excitement in the system, and we therefore ordered a dose of sulphate of magnesia at bed-time, and the next morning a few drops of the following to be applied to her right eye. ℞. Strychnin. gr. ij; acid. acet. ʒj; aq. puræ ℥j. M.

November 11*th.* Noon. Medicine has purged her actively. The nurse had applied the solution to the eye early in the morning, and the patient finding her vision much improved, afterwards, in the absence of the nurse, had twice used it herself. Says she can now see pretty well with her right eye. Upon trial found she could read with that eye, the other being carefully closed with my fingers, a newspaper which happened to be at hand. Says there is some cloudiness of right eye. Continue collyrium.

12*th.* Sight improved. She read with either eye, almost equally well, the other being closed. Cloud before right eye diminished but not entirely gone. Continue collyrium.

13*th.* Cloudiness of right eye entirely gone; sees perfectly well with it; is not sensible of any difference in the power of vision of her two eyes. She was discharged November 17th, and went to her mother, who resides a few miles in the country.

The rapidity of the cure in this case led us at first to suspect deception; on inquiry we could not discover any ground for such suspicion. The friend who had recommended the patient to our care informed us that her mother was a respectable, industrious widow, who supported by her labor several children, of which the patient was the oldest; that the daughter was intelligent, active and obliging, and her aid was of so much importance to her mother, that he had interested himself to have her relieved from her infirmity, which much lessened her usefulness. As to the excellence of her sight, when she was discharged from the hospital, we verified this in a way that admitted of no deception.

In June, 1839, we had the gratification to learn from the friend who sent this patient to us, that the cure had been so far permanent. He informed us that he had seen Harriet frequently, and that a short time before he had inquired particularly of her respecting her sight, and was assured that it continued perfect.]

SECTION V.—PARTICULAR KINDS OF NERVOUS AFFECTION.

To the general principles of treatment, which I have now explained, together with the modifications required under certain circumstances, there are some exceptions, which will be noticed in the following remarks on particular kinds of nervous affection.

Affections of the retina from excessive employment; commonly called weakness of sight. The retina may lose the power of continued exertion from habitual or excessive use of the eyes, as in reading or writing, par-

ticularly by candle-light, in drawing or painting minute objects, in microscopic or telescopic observations, or in any other way in which they are closely and intently occupied. I have seen this affection principally, if not solely, in young persons, especially in university students, and in females who have been employed through several successive hours of the day, as well as by candle-light, in drawing, music, needle-work, reading and writing. The power of vision is not impaired; the minutest objects are seen clearly as in the natural state of the eye. But when it has been exerted for some time, the organ becomes tired; objects appear dull, confused, or distorted, and can no longer be recognized; a sense of weariness comes on in the part, occasionally with redness and lachrymal suffusion. The eyelid drops, and a painful pressure is felt in the brow. The uneasiness goes off by rest, the powers of the retina are restored, and the eye may be employed again; but, if exertion be imprudently pursued, the organ becomes sooner tired. The time in which this occurs varies in different instances, from an hour and a half, or two hours, to a few minutes. I have seen many instances in which the patient could not read more than five minutes at a time. No pain is experienced in passive vision, or in looking at distant objects out of doors; nor is even strong light offensive. The patient is often annoyed by the appearance before the eye, in various forms, of the imaginary object called *muscæ volitantes*.

Patients naturally enough call this state weakness of sight. We cannot propose any technical name, because the pathology of the affection is unknown; the mode in which the retina suffers has not yet been ascertained; nor do we know whether the primary seat of mischief is in the retina or the choroid. The term amblyopia, designating the early stage of amaurosis, in which, although smaller objects can be discerned, they are seen under some imperfection, is not applicable to this affection, in which the power of vision is unimpaired.

This disease is very obstinate and tedious, often lasting one, two, or more years, in spite of all our efforts, and appearing at last to cease spontaneously, rather than to yield to medical or surgical treatment. It is not benefited by strong measures, such as cupping, blistering, purging, &c. The state of the organ, or of the circulation in the head, may render moderate depletion by cupping or leeches advisable occasionally; and in the same way blistering may sometimes be required. A principal circumstance is moderate use of the weakened organ: the eyes must not be employed so as to bring on fatigue and pain. The diet and state of the bowels must be attended to; the patient should live regularly. He should reside in a pure air, and take exercise freely both on horseback and walking. Washing the head every morning with cold water: the cold and shower baths will often be advantageous. In short, the mode of living should be such as is most favorable to health and strength, most likely to brace the nervous system. Gentle stimuli to the surface of the eye and the lids have sometimes appeared to do good. The vapor of ammonia or ether, the vinum opii, and a stimulant liniment to the edges of the lids, may be employed for this purpose.

In a gentleman, about thirty, whom I saw with this affection, the eyes became tired and painful in about half an hour. There was some unusual vascularity, and he appeared rather of full habit. Scarification of the lids afforded temporary benefit. He regulated his diet, and attended carefully to the stomach and bowels. In four months he was less plethoric, and the eyes were quite natural: he could read for an hour, and sometimes from one to two hours. He washed the head with cold water, paid great attention to diet, and occupied himself considerably with traveling. The affec-

tion gradually declined, and might be said to be at an end in about a year and a half from its commencement.

In the following case there may, perhaps, have been a natural disposition to the complaint.

I saw, in 1827, a gentleman from Norway, thirty-one years of age, stout and healthy, with fair complexion and blue eyes. His left eye, which had always been imperfect, appeared healthy: the pupil was of middle size, and the iris moved as usual. He could see the first and second sizes of print in the title-page of an octavo. Five years before, the right eye began to be weak, and had continued in nearly the same state. He could see the minutest objects perfectly, and could read the smallest print, but employment either in reading or writing soon fatigued the eye. A brown smoke or mist, and sometimes a bright glare came before it, and in an hour, or an hour and a half, he was obliged to desist. Heat, strong light, and the reflection from snow in sunshine were painful: colored glasses gave relief. The less he used the eye, the better he felt it. Leeches on the temple, with alterative and aperient medicines, were of some service. He had been under my care in London two years before, and had derived benefit from similar measures. Since that time he married, having previously led a chaste life, and he thought himself better for the change. No unusual appearance could be discerned in the right eye. The father and mother of this gentleman had always enjoyed excellent sight; also the grandfather and grandmother, of whom the former could read without spectacles at the age of eighty-seven. He had two brothers, one about twenty, who had labored for a year and a half under a similar affection of both eyes. The other, rather older, had experienced some degree of the same inconvenience. He had one sister, whose eyes were weak.

[The affection which has been ably, though briefly, sketched by Mr. Lawrence in the preceding paragraphs, is one not of infrequent occurrence, and it is so troublesome in its effects, and often proves so refractory to treatment, that some further remarks in illustration of its character and of the measures which are most successful for its relief, may be useful.

This disease has been briefly noticed by Beer,* Plenck,† Tyrrell,‡ Stevenson,§ Adams,‖ Bonnet,¶ Petrequin,** and others, but the fullest and best account that we have of it, is by Dr. Mackenzie.†† Various names have been given to it, but Kopiopia (from χόπος, *fatigue*, and ωκ, *the eye*,) the term devised for it by Dr. Petrequin, or Asthenopia (from α, *privitive*, σθένος, *strength*, and ωκ, the eye) that under which it is described by Dr. Mackenzie, are the most appropriate and convenient.

The ordinary symptoms of the complaint are clearly related by Mr. Lawrence, but there are some of less frequent occurrence which may be here pointed out. Thus in certain subjects, particular employments will induce asthenopia, while other exercises of sight, which might be supposed equally likely to occasion it, do not do so. Thus Dr. Mackenzie states that a young lady was brought to him by her governess, who stated that the disease showed itself only when her pupil tried to make

* Lehre von den Augenkrankheiten, vol. ii., p. 34. Wien, 1817.

† Doctrina de Morbis Oculorum, p. 188. Vienna, 1777.

‡ Practical Work on the Diseases of the Eye, vol. ii., p. 25. London, 1840.

§ Weakness of Sight, or Morbid Sensibility of the Eye, p. 16. London, 1830.

‖ New Operation for the Cure of Amaurosis, &c., p. 12. London, 1841.

¶ Annales d'Oculistique, tome vi., p. 72.

** Ibid., tome v., p. 250.

†† Edinburgh Medical and Surgical Journal, July, 1843.

out her music at the piano-forte. A girl also applied to him, who had been employed for some years in winding yarn in a warehouse, and had done this without difficulty, but who could not, from asthenopia, make a livelihood by sewing white seam.

The disease, generally, is not attended with any intolerance of light, but this complication we have repeatedly met with.

The most frequent subjects of this complaint are pallid, delicate persons, but it sometimes occurs in those who are robust and plethoric. It usually commences at an early age, and may continue through life. We were consulted three years since by a married lady, the mother of several children, who had suffered with it from infancy; she was unable to read or sew, except for a few minutes at a time.

The affections with which asthenopia are most likely to be confounded are presbyopia and photophobia. It may be distinguished from the former, which is a permanent affection, while asthenopia is temporary. Presbyopic persons can at no time see near objects distinctly without the aid of convex glasses, while the asthenopic see near objects distinctly for a certain time, after which they become obscure. Asthenopia, though sometimes complicated with photophobia, in most instances is not attended with any intolerance of light, and a little attention will therefore enable the surgeon to distinguish these two affections, when uncombined.

The remote causes of asthenopia, usually affording the most reliable therapeutic indications; these causes are of great importance, and should in each case be carefully traced out. Dr. Mackenzie, in his paper already referred to, has very fully indicated the remote causes of asthenopia, and we shall quote his remarks on the subject.

"1. In many instances," observes Dr. Mackenzie, "asthenopia appears to be an idiopathic disease, resulting entirely from over-exertion of the sight. On inquiring into the history of the case, we find, that previously to exercising the eyes upon minute objects, without proper intermissions, these organs were strong and healthy, having either never suffered from any of the ophthalmiæ, or if so, having perfectly recovered, and that, as the patient has labored under no chronic affection of the general health, there is no reason to regard the weakness of sight as a symptom of any other disorder of the nervous, or of the circulating system.

"Young lads engaged as clerks or book-keepers, or bound apprentices as tailors, watchmakers, pattern-drawers, compositors, or engravers, and young women, employed as dress-makers, or sempstresses, afford frequent examples of asthenopia from pure abuse of the eyes. Students, and those engaged in literary pursuits, who spend their days, and great part of their nights, in reading and writing, often reduce their sight to a state in which it is incapable of supporting the smallest application. Individuals whose circumstances relieve them of any necessity to overwork their eyes, who are sober and chaste in their mode of life, and scrupulous observers of the general rules of health, not unfrequently sacrifice their sight to their particular tastes in literature, or in the fine arts.

"Various incidental circumstances seem to aid the influence of overuse of the eyes in producing the impotency constituting the characteristic symptom of the disease; such as working by artificial light, want of the due quantity of sleep, and excessive occupation of the brain.

"For various reasons, it is always more injurious to the eyes to overwork them in the inspection of minute objects, by artificial than by day light. This is a topic which has been carefully handled by the late Dr.

James Hunter, of Edinburgh, whose work* may be consulted with advantage. He ascribes the injurious effects of artificial light chiefly to the four following causes, viz.: 1. The bad colour and defective chromatic constitution of the rays of artificial light; 2. Their greater heating power in proportion to their illuminating effect; 3. The formation and disengagement of carbonic acid gas during combustion; 4. The unsteadiness, and the generally disadvantageous position and direction of the light. Though Dr. Hunter dwells chiefly on the injury sustained by the surface of the eye, and by the retina, it cannot be a matter of doubt that the whole organ suffers from these causes.

"From the excess of red and yellow rays in artificial light, coloured objects seen by it appear very different from what they do in daylight, which contains a larger proportion of blue rays. Not merely does the retina become less sensible to those rays which are in excess in artificial light, but from its great inferiority of defining power, objects appear much less distinct in it than when viewed by daylight, and hence a greater straining of the eyes is necessary in order to discern them. Thus, in reading or writing by daylight, as Dr. Hunter observes, the black ink is strongly contrasted by the pure white paper; but by artificial light, as the paper then assumes an orange or yellow hue, the contrast is not so marked, and for distinct vision it becomes necessary to increase the quantity of light. In sewing blue fabrics by artificial light, the eyes must be very much exerted, because, in consequence of the fewness of blue rays, which are the only ones reflected from blue surfaces, the cloth appears almost black, except the light be very intense.

"The rays of artificial light are generally allowed to fall directly on the object looked at, from whence they are reflected to the eye, along with nearly all their accompanying heat. The heat acts injuriously on the surface of the eye; it irritates and indirectly weakens the whole optic apparatus.

"It is the absorption of carbonic acid gas by the lungs and skin, that causes the headache so generally and often so severely felt, after remaining for some time in crowded and brilliantly illuminated assemblies at night, as in churches, ball-rooms, and theatres. It does not act directly on the eye, but on the brain and nerves, the sensibility of which it weakens and ultimately would destroy.

"Sunlight is remarkable for the equability with which it flows, so that in looking closely at an object illuminated by it, not the slightest wavering or flickering is perceived. But all artificial light is more or less unsteady, from the impossibility of perfectly regulating the supply of air and of inflammable material. This unsteadiness is highly trying to the eyes, particularly if it takes place to such an extent as happens when a gas-pipe contains some drops of water. Even in more common cases, a much slighter degree of unsteadiness always proves hurtful, by rendering necessary the employment of a greater quantity of light than would be required if the flame were of uniform intensity.

"The generally improper position of the sources of artificial light, allowing a great quantity of extraneous light to pass into the eye, is productive of bad effects. When the eye is protected from the direct rays of artificial light, a small and near object can be seen with less light, and consequently with less excitement of the organ of vision. Yet how generally are artificial lights placed directly in front of the eyes of those engaged in fine work, and almost close to them!

* On the Influence of Artificial Light in causing Impaired Vision. Edinburgh, 1840.

"The last five paragraphs contain a summary of Dr. HUNTER's views regarding the disadvantages of artificial light. I have no doubt that these disadvantages operate powerfully in the production of asthenopia.

"Want of sleep is sometimes the chief agent in producing the disease, as in night-work of all kinds, and especially in night-study. When not the chief agent, it in no small degree aggravates the operation of other causes. Sleep, by suspending the sentient and muscular actions of the organ of vision, repairs its vigour. This repose being denied, it is inevitable that the powers of the eye must become debilitated. Even in the dark, want of sleep is detrimental to the sight; much more so, if, amid the glare of artificial light, the eyes are forced on to exertion, in spite of the natural feelings of fatigue.

"What may be called the hot-house education of modern times, is a fruitful source of asthenopia. Nothing is so hurtful to the sight as the combined straining of the eyes and mind, to which young people, and especially girls, are so often subjected about the period of puberty. A few days ago, a boy of twelve years of age, was sent to me by his parents, laboring under asthenopia. He told me he attended school from 9 A. M. till 4 P. M., with only half an hour's intermission. The whole of the evening he spent in perusing the volumes of Chambers' Edinburgh Journal,—a work printed in small type. The disease had increased rapidly during the three weeks preceding my seeing him. With girls, there is no end the live-long day to instruction of one kind or another,—reading, writing, the acquisition of different languages, arithmetic, drawing, needle-work, music, &c. Asthenopia appears frequently to arise from practising at the piano-forte, especially by artificial light. The notes are so small, and so like each other, that they cannot readily be distinguished, and are placed at a distance from the eyes, to which these organs with difficulty accommodate themselves. If the exhilarating recreation which the eyes, along with the rest of the body, and the mind, should enjoy in the open air, is denied, and a young person, at the very period when the process of growth is going on rapidly, is pent up within artificial bounds, and condemned to sedentary occupations, is it to be wondered at that asthenopia should ensue, with paleness, feebleness, and emaciation? The natural development of the body is checked, a congested state of the brain is produced, the martyred being is crippled in body and mind, and but too often falls into incurable disease."

The worsted work on cloth and canvas, recently a fashionable employment for young ladies, we have found to be a fruitful source of this complaint, and the cheap publications in vogue in this country, in which form most of the novels and light literature of the day are published, are equally so. The latter is often productive also of amblyopia and even confirmed amaurosis, of which we have seen some melancholy examples.

"2. We frequently trace asthenopia," says Dr. MACKENZIE, "to the influence of one or other of the ophthalmiæ, from which the patient had suffered at some previous period of life.

"A child is sent to school at the age of six or seven; but it is found that he cannot be taught to read, and he is beaten for a month or two, because, though he sees quite well out of doors, and quite well when he first takes up his book, he cannot continue to read for more than a few minutes. On being brought for medical advice, the symptoms are found to be evidently those of asthenopia. On inquiry, it is stated by the parents, that the child suffered, when a few days old, from purulent ophthalmia, which, being at first neglected, was perhaps not overcome for a couple of months; or, that when two or three years old, he lay for

weeks or months on his face, with sore eyes, unable to bear the least light. In either of these two cases, asthenopia is by no means an uncommon result, although it may not be discovered for several years after the existence of the ophthalmia.

"The ophthalmia first referred to, or *ophthalmia neonatorum*, often extends to the internal parts of the eye. It is extremely likely to do so if it is either neglected for a number of weeks, or from insufficient treatment is allowed to fall into a chronic state. In some subjects it leaves an affection of the lens and capsule, and in others one of the choroid and retina. These sequelæ are often detected, only when the child is sent to school. In the former case, the eyes are found to be myopic; in the latter presbyopic. In either case they are apt to be asthenopic; or they may suffer from asthenopia without any deterioration of their refracive powers. Even when the eyes recover from the inflammation without any opacity of the cornea, asthenopia is apt to be a sequela of *ophthalmia neonatorum*.

"A fruitful source of asthenopia is to be found in the scrofulous inflammations of the eyes, and especially in the *phlyctenular ophthalmia*. It is well known, that in this disease not only do serious changes take place in the textures of the eye, but that an obstinate reflex action of the *orbicularis palpebrarum* is excited by the incidence of the light upon the sentient nerves in an irritable state. The asthenopia which follows successive attacks of phlyctenular ophthalmia, may be ascribed partly to the changes produced by inflammation on the internal textures of the eye; partly, and perhaps chiefly, to the pressure on the eyes, produced by the patient, as he lies with his face upon his hands or upon the pillow, aided by the action of the eyelids, so long and violently closed by spasm. I have elsewhere mentioned* a case in which, on the photophobia of scrofulous ophthalmia subsiding, the child, who was the subject of the disease, was discovered to be amaurotic,—a result which I incline to ascribe to the pressure so long exercised on the eyes. To the same cause may in some measure be attributed the impeded growth of the eyes, which attends a long-continued attack, as well as such changes in texture as leave the patient in some instances amblyopic, and in others asthenopic. A girl was brought to me, with a small speck on each cornea, the results of scrofulous ophthalmia in infancy. She was now sixteen years of age, and affected with such a degree of asthenopia, that although she saw the smallest objects, she had never been able to learn to read. In cases of this sort, sometimes only one eye is affected with asthenopia; more frequently, both. The fear of so serious a consequence makes it important to cure phlyctenular ophthalmia as speedily and perfectly as possible.

"It is not the ophthalmia of childhood alone which gives rise to asthenopia. This result may follow any of the inflammations of the eye.

"If the patient relates that his weakness of sight was preceded by a frequent flashing of fire in his eyes, intolerance of light, and epiphora, with pain deep in the eyeballs, and extending from the eyes to the occiput, and that these symptoms were increased on stooping, or on straining in any way; or if his weakness of sight is still attended by these signs, along with *muscæ volitantes*, and contracted pupils, there is reason to suspect that retinitis has existed, or still continues to exist in a chronic state.

"If similar symptoms have been attended by a shifting of the pupil to

* Practical Treatise on the Diseases of the Eye, p. 453. London, 1835.

one side, along with manifest thickening, or consequent thinning, of the sclerotica, the asthenopia is a result of sclerotico-choroiditis.

"If the pupil be irregular, contracted, imperfectly movable, and fringed with red vessels, or with projecting particles of pigment, and the iris discolored, and bolstered forward towards the cornea, iritis has been the cause.

"If, on viewing the pupil through a lens of short focus, red vessels are descried, ramifying on the anterior crystalline capsule, the asthenopia has arisen from capsulitis.

"If the patient is myopic, the cornea hazy, and the eye hydrophthalmic, corneitis has been the cause.

"Such names as corneitis, iritis, &c., denote merely the chief seat or focus of certain ophthalmiæ, each of which affects more or less the whole textures of the eyeball, internal as well as external, and any one of which may lay the foundation of asthenopia. More frequently, no doubt, the ophthalmiæ are productive of amblyopia.

"3. Injuries of the branches of the fifth nerve around the orbit appear, in many instances, to give rise to asthenopia. A large proportion of the patients who have come under my care with this disease have presented cicatrices in the eyebrow or in the skin of the forehead, and many of them have been able to state, that till they had received the wound, leaving the scar, their sight had been strong. One lad, whom I saw on the 24th February, 1843, stated, that, in about a year after he had received a deep cut at the inner extremity of his left eyebrow, his sight began to fail, and had now continued weak for seven or eight years. In other instances, the weakness of sight has not supervened till several years after the injury. It is well known, that incomplete amaurosis may often be traced to injuries of the integuments round the orbit, but I conceive asthenopia to be a still more frequent result.

"The irritation or inflammation of the injured branch of the fifth nerve, in such cases, may be supposed to be propagated along the trunk of the nerve to the brain, and a reflex affection to be produced, implicating the third nerve, the optic nerve, or both.

"4. Asthenopia is often traceable to affections of the encephalon.

"The irritation of the brain in teething children, so frequently attended by convulsions, appears in many instances to be the cause of asthenopia.

"A boy, of thirteen years of age, was brought to me with asthenopia and presbyopia. When six years old he was very ill with measles, and lay insensible for some days. This was the origin of the affection of his eyes.

"Another patient dated his weakness of sight to inflammation of the brain, when he was nineteen years of age. Another traced it to nervousness, produced by a fright.

"A gentleman, of sixty years of age, came under my care with slight hemiplegia; and, as this subsided, he found himself asthenopic. He saw the figures in some small prints which hung in his room, and all other distant objects, quite distinctly. He could read a line or so with the aid of his convex glasses, but no more. The letters seemed to him as if they began to tremble, and get confused, so that he was obliged to desist.

"Many asthenopic patients have consulted me whose heads were hydrocephaliform, and some of these considerably above the average size.

"I have known typhus fever and malignant cholera, by implicating the brain, prove causes of asthenopia.

"5. If asthenopia is attended by a heavy, sunk appearance of the eyes; if they present a dark circle round them, and feel hot to the touch; if the patient has a melancholy expression, with an air of absence and timidity; if he answers questions with hesitation; if he complains of pain and feebleness in the back and limbs, and inability to undergo ordinary bodily fatigue; these are strong grounds to suspect the cause of all his symptoms to be some abuse or disorder of the generative system, such as excessive venery, masturbation, or spermatorrhœa. This suspicion will be strengthened, if we learn that, within a short time, a remarkable change for the worse has taken place in his frame of body and mind; that he has become pusillanimous, deficient in memory, slow of intellect, incapable of bending his mind to any serious subject, taciturn, discontented, hypochondriacal, fond of solitude, misanthropical, and liable to indulge in thoughts of self-destruction.

"If the patient be a male, we should inquire whether he is troubled with nocturnal pollutions. If these are frequent, there can be little doubt that the whole symptoms have originated in masturbation. The health may also suffer from diurnal spermatorrhœa, or the patient may be troubled both with nocturnal and diurnal emissions, and these may continue long after he has abandoned masturbation. The patient may have pollutions only when he goes to stool, a symptom generally attended by costiveness, and apt to affect those who sit too much, as tailors. Pollutions immediately after passing urine are also not uncommon; and in this case there is pain at the neck of the bladder, the calls to make water are frequent, and the urine is thick, depositing a sediment like gruel, and speedily affording an offensive smell.

"If the patient admits that he has been addicted to masturbation, it is proper to ascertain at what period of life he commenced it. Before puberty, although no semen is yet secreted, the nervous perturbation which is produced is exceedingly apt to affect the eyes with weakness, and often brings on epilepsy. At any period of life, besides the effects already enumerated, masturbation is often followed by loss of appetite, indigestion, headache, vertigo, *tinnitus aurium*, rigors, flushings, constant clamminess of the hands, want of sleep, signs of congestion or chronic inflammation of the brain, apoplectic symptoms, palpitation of the heart, and emaciation, leading to a suspicion of phthisis. Palsy and insanity are not unfrequent consequences of masturbation.

"I have often ascertained, that asthenopia, in young men, is a result of excessive venereal indulgence, but more frequently still, of masturbation, or of involuntary emissions. I have no doubt that masturbation is a frequent cause of the same complaint in females.*

"Dr. Pauli relates† the case of two sisters, the one 28 and the other 23 years old, both of whom, from masturbation, brought on asthenopia, along with great debility, and melancholy. Among other symptoms, he mentions a habit of constantly biting their nails, a trick to which masturbators are particularly attached, and a repugnance to marriage, which is also characteristic of the class. Females, affected with asthenopia, often labor under leucorrhœa, and this, as well as barrenness, is in many cases a consequence of abuse of the generative function.

* Les femmes sont également enclines à ces mauvaises habitudes. Berton, Traité pratique des Maladies des Enfants, p. 800. Paris, 1842.

Cette malheureuse passion améne exactement les mêmes resultats dans l'autre sexe à tous les ages. Lallemand, Des Pertes Seminales Involontaires, tome iii. p. 207. Paris, 1842.

† Ammon's Monatsschrift für Medicin, vol. i., p. 592. Leipzig, 1838.

"I shall not insist on the other causes to which asthenopia appears to owe its origin. I may merely mention the following as deserving attention;—congenital imperfection, a sedentary life, want of exercise, a bent position of the body during work, dyspepsia, constipation, and the use of alcohol, opium, and tobacco,—poisons which tend to blunt all our sensitive and motive powers."*

The pathology of asthenopia has not yet been satisfactorily determined. Mr. Tyrrell regards this affection as depending upon temporary congestion of the choroid, but the reasons he adduces for this opinion are altogether inconclusive, while the fact that the remedies which cure choroiditis have no effect in relieving asthenopia is adverse to such a doctrine.

Equally hypothetical is the notion of Adams, Bonnet, and Petrequin who attribute asthenopia to a morbid activity of the muscles of the eyeball. Mr. Adams, who terms it muscular amaurosis, believes that it "depends on the bending, or partial folding, and compression of the optic nerves, caused by the shortening and thickening of the recti muscles during a state of morbid contraction, which farther may be attributed to an affection of the third and sixth nerves, probably at or near to their origin." Dr. Petrequin imagines that in asthenopia the muscles of the eye are in a state of inordinate action or spasm. There is, however, present in asthenopia no symptom calculated to lead to the least suspicion of any such spasm or contraction of the muscles of the eyeballs, or compression of the optic nerve, supposed to exist by Dr. Petrequin and Mr. Adams.

Dr. Mackenzie considers asthenopia as in a great measure a disease of the apparatus by which the eye is adjusted to the vision of near objects, but that the retina also is implicated. That this disease is not wholly an affection of the adjusting apparatus of the eye, but that the retina is also implicated, is evident, he remarks, "from the fact, that when the eye is fatigued in asthenopia, the patient cannot see distinctly or with comfort through a small aperture, and that cases of this disease occur in combination either with myopia, or with presbyopia. Were asthenopia entirely a disease of the apparatus of accommodation, looking through a small aperture, by rendering the use of the accommodating power unnecessary for the time,† would make vision distinct. In myopia, the formation of the refractive parts of the eye renders it permanently fitted to see near objects, and yet those who are short-sighted are liable to asthenopia. Patients laboring under the combination of presbyopia and asthenopia, by the use of convex glasses, render the action of the adjusting organs unnecessary, yet are not exempt, while using their glasses, from the attack of weak-sightedness."

"The eye," he goes on to observe, "in its normal condition, possesses a power of adjustment, by which it is enabled to bring to focal points upon the retina, the diverging rays proceeding from near objects as well as the parallel rays proceeding from objects which are remote. Wherever the motion resides, by which the refraction performed by the eye is increased, so as to shorten its focal distance, and adapt it to the vision of near objects, it is plain, that the asthenopic eye is not entirely deprived of the power of performing that motion; for on first looking at near

* As far as my experience goes, the operation for squinting has little effect either in improving or impairing vision. Mr. James J. Adams relates (Medical Gazette, vol. xxxi., p. 398, London, 1842) a case, in which he thinks asthenopia arose from the operation, and in which it was cured by new divisions of the recti.

† Porterfield's Treatise on the Eye, vol i., p. 395. Edinburgh, 1759.

objects, the patient sees them perfectly, and continues to do so till the attack comes on. He then loses sight of near objects, and becomes presbyopic. His vision of distant objects continues distinct, but his eye refuses to sustain the effort, necessary for bringing the rays of light, arising from objects within a certain distance, to focal points on the retina. The organ or organs of adjustment, then, are affected in this disease; and are probably the chief seat of the complaint.

"A hypothesis which I have formed* on the subject of adjustment is, that the iris and the ciliary processes are antagonists; so that, when the pupil contracts, as it always does on our directing our attention to near objects, the ciliary circle expands; and when we look at distant objects the pupil expands, and the ciliary circle contracts around the lens. On the ciliary circle expanding, the crystalline will be allowed to advance towards the pupil, so as to assist in shortening the focal length of the eye; on its contracting, the crystalline will again retire towards the retina. This alternate motion of the crystalline probably does not exceed one-twentieth of an inch in extent. The expansion and contraction of the ciliary circle, coinciding with a contraction and expansion of the pupil, are facts which I have ascertained by observing the state of the parts in the dead body. These changes of the iris and ciliary processes, attended by a change of place of the crystalline, may be accompanied by a change of figure of the crystalline, its axis being elongated when it advances in the eye, and shortened as it retires. Nor is it at all improbable that the contraction of the straight and oblique muscles, while it tends both to elongate the axis of the eye, and shorten the radius of curvature of the cornea, aids the advance of the crystalline.

"Without entering on the question, whether the iris and ciliary processes are muscular, I may observe, that the motions of these parts are undoubtedly under the influence of the third nerve, or *motor oculi*, and if deprived, by any cause, of their usual nervous stimulus, their motions must be impeded, and the function of adjustment be imperfectly performed. This is the case in asthenopia. On exposing an asthenopic eye to various degrees of light, the motions of its pupil may be as vivid and extensive as those of a healthy eye. On first being turned towards a near object, the pupil may also be observed to contract, but if we watch the eye, applied seriously to the continued vision of a near object, as in reading, the pupil will be seen, in general, to assume a medium state of dilatation, and not to maintain its state of contraction, as would the pupil of a sound eye under the same circumstances. We cannot doubt that the ciliary circle assumes also a medium degree of expansion,—a state of parts sufficient of itself to produce almost the whole symptoms of the disease. The effort necessary for adjustment cannot be sustained, the focal length of the eye can no longer be shortened as it should be, the letters of the book necessarily fade from before the sight, and the feeling of fatigue creeps over the eye. It is probable that the cause of impotency resides, not in the ciliary circle nor in the ciliary nerves merely, but in the third nerve, and other muscular nerves of the eye, generally. The contraction of the recti and obliqui, then, so necessary for keeping the eye in a state of libration, for directing it along the lines of the printed page, for converging the two eyes to the same point, and perhaps for compressing the globe of the eye, so as to maintain an increased distance between the retina and the cornea, must, in this case, gradually give way

* London Medical Gazette, vol. xiii., p. 631. London, 1834. Physiology of Vision, p. 185. London, 1841.

under the effort demanded, so that these muscles fall into a state of minimum contraction. The consequence is, that at length the upper eyelid drops, and the patient is obliged to indulge in that cessation of visual exertion which experience has taught him will regenerate his exhausted powers of sight, and enable him by and by to resume his labor.

"That asthenopia, however, is not solely an affection of the adjusting organs is shown by the facts already mentioned; namely, that looking through a small aperture does not render vision distinct under the attack; that this disease is frequently accompanied by myopia, and that presbyopic persons occasionally suffer from it, even when using convex glasses."

This theory, if it does not explain all the phenomena of asthenopia, certainly offers a plausible interpretation of most of them, and is probably as near an approximation to the true pathology of the affection as can be offered in the existing state of our knowledge.

This disease, when once fully established, is often so intractable that its prophylaxis is of extreme importance. Dr. MACKENZIE's observations are so judicious that we may quote them.

"With regard," he says, "to the prevention of asthenopia, it may be remarked in general, that the remote causes are carefully to be avoided. Those who, hitherto with impunity, have been exposed to one or other of the remote causes, should be particularly guarded in tempting the injurious influence of the rest. Thus children who have suffered from scrofulous ophthalmia, if put to a trade requiring earnest application of the sight, are very liable to become asthenopic. The following hints respect the exercise of the organs of vision, and the management of artificial light.

"It is impossible to limit the time during which healthy eyes may be employed with safety upon minute objects, as there is a great variety in their power of bearing fatigue. The sight may be regarded as fatigued, whenever the person finds that he requires to bring the object nearer to his eyes than usual; whenever the object appears confused; whenever the eyeball or eyelids become red, or the eyes feel heavy, hot, or affected with a pricking sensation, or with a flow of tears. These symptoms occur more or less promptly in proportion to the strength of the organs of vision. The moment such symptoms are experienced, the person should rise from his work; relieve his eyes by turning them towards distant objects; bathe them with cold water, and, if circumstances permit, expose them to the external air.

"Giving the eyes even a few minutes' occasional rest is of great service in preventing them from becoming weak, especially when employed in such exhausting occupations as reading, writing, drawing, engraving, sewing, and the like. As important means of preserving the sight from weakness may be mentioned, changing the occupation from a fatiguing one to one requiring a less earnest use of the eyes; turning away from the light, if it is brilliant, or closing the eyes for a few minutes; changing the bent position of the body for the erect, and walking about for a little; avoiding everything tight about the body, as tight neckcloths, stays, and even shoes, so as to allow a free and equable circulation of the blood; regular exercise in the open air. The eyes should never be forced to continued exertion. The eyes of children especially should never be fatigued. They should never be allowed to read books printed in a very small type.

"As it is impossible by any arrangement, to render artificial light at all

equal to daylight, he who would avoid weak-sightedness, should get through as much of his labor as he can between sunrise and sunset, and leave as little as possible to be done by artificial light. Daylight is comparatively steady and clear, and its defining power vastly greater than that of artificial light. All objects, therefore, are seen more distinctly, and consequently with less fatigue to the eyes, by daylight, while, at the same time, the debilitating heat, and the inhalation of the carbonic acid gas produced by combustion, are avoided.

"In the work of Dr. Hunter, already referred to, are numerous hints respecting the management of artificial light. Of the most important of these, the following is an abstract.

"Of the various sorts of artificial light, that of gas made from parrot or cannel-coal, should be preferred, as the purest and most equable. Gas-light admits of being placed in any position, and it is easy to increase or diminish its intensity. The argand is the best form of burner.

"If the sight is much employed in fine work by gas-light, advantage should be taken during any temporary interruption, of the facility with which the intensity of the light may be instantly diminished, so as to afford rest to the eyes, and allow them to recover their tone. During the interval of repose, they may also, with advantage, be bathed with cold water, as a preventive of the bad effects of the heating power of artificial light.

"The bad color of artificial light should be corrected by the use of a conical opaque reflector, colored blue inside, and placed above and around the light. By this means, the blue rays that are deficient in artificial light are added, and light approaching more to the white color of daylight is obtained. Dr. Hunter recommends also to allow the light to pass through some transparent medium of a pale blue color, such as stained glass or a colored fluid, so as to absorb the red and yellow rays which are in excess. But as this cannot be effected without a considerable diminution in the intensity of the light, the former plan is preferable.

"To avoid the bad effects arising from the great heating power of artificial light, the ventilation of the apartment should be constantly attended to, and care should be taken to obtain the highest illuminating power with the lowest consumption of inflammable matter. If the room is warmed by hot air, or by a stove, a flat dish, containing water, should be set in some convenient situation, so that a proper degree of moisture in the air may be maintained by the evaporation of the water. If the light is nearly on a level with the eyes, and shaded by a metallic reflector, the outside of the reflector should be covered with some bad conductor of heat, such as wood or leather.

"If a number of individuals be congregated in a small apartment, where artificial light is much employed, as in the workshops of many classes of artisans, the carbonic acid gas and heated air, generated by respiration and combustion, should be carried off by ventilators in the roof, communicating directly with the open air, or leading into a chimney in which there is a constant draught. A metal tube, with a funnel-shaped extremity placed over the lights, and communicating with the open air, or with the chimney, is of great advantage, by removing the carbonic acid gas as soon as it is formed, and allowing the apartment to remain cool.

"In public places, and in the sitting rooms of private houses, artificial light should be diffused equally by ground glass-shades. In libraries, counting-rooms, and workshops, the light requires to be concentrated on the objects of inspection, by opaque, conical shades or reflectors, which

protect the eyes from the source of the light and from its extraneous rays, as well as, if painted blue internally, correct the bad chromatic composition of artificial light. Those who work much over strong fires will find it useful to wear a bonnet shade, made of pasteboard, blackened on the inside, and covered with tin-foil on the outside, so as to reflect the heat."

The pathological condition upon which asthenopia depends being as yet so little known, its treatment is of course uncertain and multifarious. It is of the first importance in the treatment of this disease to ascertain the remote cause of it and to relieve the patient from its operation.

Rest of the eyes is an essential means of cure; for though it may not be sufficient of itself, except in mild or recent cases, to remove the disease, still without it other measures would be fruitless. The patient should give his eyes frequent intervals of repose, and avoid as far as possible fixing them on very minute objects. "Supposing a patient could work for an hour," says Mr. Tyrrell, "but not longer, without producing disturbance of vision, he should then be directed to work only for half an hour at a time; and to allow intervals of rest, of a quarter of an hour each: he can thus work for two-thirds of his usual time, while his cure proceeds." "The period, allowed for employment, should be short of that in which application produces the disturbance of vision; and the time devoted for resting the eyes, should never be less than a quarter of an hour.

"Supposing that the impaired vision," continues the same author, "occur within half an hour, or less, after the eyes have been employed at work, it is best for the patient to refrain from work altogether, for a week or two, until the affection be mitigated."

Blood-letting, general or topical, is rarely indicated, and should be had recourse to only when manifest signs of local congestion are present, and in robust individuals.

Purgatives and laxatives, when constipation co-exists, as is often the case, will be found very useful, and in some instances mercury in alterative doses is required for the regulation of the digestive organs. We have used also as an alterative, the hydriodate of potassa with much benefit in some cases.

The subjects of asthenopia being often persons of feeble constitution and lymphatic habit, tonics have been much employed for its cure. Dr. Mackenzie regards quina and the different preparations of iron as the most effectual of this class of remedies. We have employed with much advantage iodide of iron in the form recommended at p. 306. In some cases, however, as remarked by Dr. Mackenzie, tonics do harm; "when spermatorrhœa is the cause," he says, "this symptom is sometimes increased by every sort of tonic or stimulant, but may be cured by remedies of an opposite kind, and especially by cauterization of the verumontanum."

Cold bathing, particularly sea bathing, the shower bath, sea air, and active exercise, are among the best tonics, and are among the most efficient remedies.

The diet should be nutritious, and of easy digestion.

Dr. Mackenzie speaks highly of the effects of belladonna, which he says he has frequently employed in the form of tincture, and that it lessens the disposition to fatigue of the eyes in a very remarkable degree. We have used it frequently in the form of extract, but are not prepared to report so favorably of it, though we have thought it productive of relief in some cases. We have also used the aconite, and with very similar results.

When the brain is implicated a seton in the neck, or repeated blisters behind the ears will be useful.

Bathing the eyes in cold water, or salt and water, affords relief in some cases, and in others fomentations with warm water, or infusions of chamomile, hops, poppies, &c., give temporary relief. "Exposing the eyes," Dr. MACKENZIE says, "to stimulating vapors, such as that of strong aqua ammoniæ, of sulphuric ether, or of a mixture of these, proves useful. The fluid selected may be poured into an egg-cup or eye-glass, previously warmed by being placed for a few minutes in boiling water, and the vessel held close under the eye, so that the vapor may rise into contact with the conjunctiva. This should be continued till the eye begins to water and becomes red, and repeated twice or thrice daily. WENZEL* objects to the use of ammonia, and the like, in this way, and recommends the eyes to be fumigated with the vapor arising from aromatic resins thrown upon a live coal." We have no experience with these applications.

Convex glasses sometimes afford relief, and when they are resorted to, glasses of the longest focus that will afford relief should always be selected.

The division of one or more muscles of the eyeball which has been employed for the cure of asthenopia, is founded on an erroneous view, we conceive, of the pathology of the disease, and the evidence of its good effects is so entirely unsatisfactory, that we have never resorted to this means, and will dismiss the subject by quoting the following excellent remarks of Dr. MACKENZIE.

"Mr. PHILLIPS appears to have been the first to propose the application of myotomy to the cure of myopia. He attributes this disease to an inordinate action of the obliqui, and recommends the superior oblique to be divided, which allows, he says, the cornea to become less convex, and thus cures the myopia. 'Le grand oblique étant coupé, la convexité de la cornée s'est affaissée, et la myopie a été guérie.'†

"M. GUERIN proposes to divide the internal and external rectus for the cure of myopia, and thus compares his own views with those of M. PHILLIPS. 'J'attribue la myopie à la rétraction des muscles droits; il la met sur le compte des muscles obliques; il la regarde comme le résultat d'une dépression latérale, c'est-à-dire d'un allongement du globe oculaire, et moi d'une dépression antéro-postérieure, c'est-à-dire d'un raccourcissement.'‡ It is scarcely necessary to remark, that M. GUERIN's view of the pathology of myopia, viz., that the disease is caused by an antero-posterior depression, or a shortening of the axis of the eyeball, is contrary to the principles of optics. Such a shortening would produce presbyopia, not myopia. His plan of operating may be correct, namely, that of dividing the recti, but his theory of the disease is inadmissible.

"The plan of dividing the rectus internus and externus in myopia is very favorably reported on by M. CUNIER.§ Dr. BONNET‖ prefers a section of the inferior oblique close to its origin.

"Now, granting, for the sake of argument, that a division of the muscles of the eyeball, recti, or obliqui, cures myopia, what probability is there that the same operation will cure asthenopia? In myopia, the eye is permanently accommodated to the view of near objects. We divide the external muscles of the eyeball, and the eye acquires the power of

* Op. cit., vol. i., p. 334.
† Annales d'Oculistique, tome v., p. 33. Bruxelles, 1841.
‡ Ibid., p. 35.
§ Ibid., p. 139.
‖ Ibid., tome vi., p. 73.

accommodating itself to the view of distant objects. What is the state of vision in asthenopia? The eye, in this disease, cannot sustain an accommodation to near objects beyond a certain length of time, but continues perfectly adapted to the vision of distant objects. Is it likely that the same operation will cure both myopia and asthenopia, two diseases, which are so far the opposite the one of the other, that in myopia there is a permanent adjustment of the eye to near objects, while in asthenopia the eye fails to sustain such an adjustment?

"Setting aside, however, all theoretical objections, we are bound to consider the results, which are said to have been obtained from the surgical treatment of asthenopia. Mr. ADAMS has published several remarkable cases cured by a division of the rectus internus and externus, and Dr. BONNET a number of others equally relieved by a section of the inferior oblique. The operation requires to be performed on both eyes. The practice I believe to be perfectly safe; but of its efficacy I can say nothing from my own experience. The narratives of Mr. ADAMS and Dr. BONNET bear every appearance of authenticity; yet it is difficult to refrain from characterizing them in the words of SCARPA, as "istorie di guarigioni sorprendenti, e poco dissimili dai prodigi." A remarkable circumstance is, that Dr. BONNET's section of the inferior oblique is not less efficacious than Mr. ADAMS' division of the two recti."

We cannot go as far as Dr. MACKENZIE in believing that this operation is perfectly safe, for it seems to us that it must expose the patient to the risk of the parallelism of his eyes being impaired.]

Symptomatic and sympathetic amaurosis.—When the function of the retina is disturbed, as it frequently is more or less seriously, not from primary disease of the nervous structure, but from affection of some other part, the state of the organ primarily diseased must be the object of treatment; and no good can be expected from measures calculated to act on the eye. Increased sensibility of the retina, and impaired vision in various degrees, sometimes with squinting and double sight, may be symptoms of disease existing in or affecting the sensorium or its membranes; the questions will be, whether we can ascertain the nature and seat of such disease, and whether we may be able to arrest and remove it.

The retina may be affected in consequence of inflammatory disease originating in and confined to other tunics of the eye, as the cornea, sclerotica, and even the conjunctiva. The cause and nature of the affection are here too obvious to be mistaken.

The retina often sympathizes with remote organs, especially with the uterus and the alimentary canal. To this head must be referred the intolerance of light (*photophobia*), whether of scrofulous children, or of hysteric females, muscæ volitantes, with or without dimness or heaviness of the eyes, various modifications of altered vision, in which objects are confused or distorted, seen irregularly or imperfectly, and impaired sight in various degrees, even to complete amaurosis, in children more especially, whose stomach and bowels are disordered, or in young women in whom menstruation either has not occurred, or is interrupted, irregular, deficient, or painful. A careful investigation of the mode in which the affection of vision has begun, and of all the attendant circumstances, with an inquiry into the past and present state of health, will not fail to point out the origin of the disease, and the quarter to which our treatment must be directed.

The effect on the eye of an irritating cause in the stomach is exemplified in a case related in the *Medical and Physical Journal*, for December, 1816.

A child seven years old was affected with severe and almost intolerable pain of the left eye, in occasional paroxysms of some minutes, recurring

at uncertain intervals, and extending to the eyelids. There was no visible change in the organ. The food was rejected unaltered. The affection had lasted three weeks. An emetic was given in the evening, and a purgative of calomel and jalap the next day. With the motions produced by the latter, a coral bead came away; the little patient immediately recovered.

In the following interesting case, recorded by Mr. Wishart, complete amaurosis of some months duration was caused by a loaded state of the bowels, and cured by clearing the alimentary canal.

A boy nine years of age was brought to Mr. W. with complete blindness of the left eye, which was insensible even to bright sunshine: the pupil was of natural size, and the iris moved readily. The right eye was unaffected. Pain was occasionally felt over the left eye. He was pale and languid; and the tongue was slightly loaded. He had been always subject to disorder of the stomach from any irregularity of diet, apparently from his nurse having been in the habit of giving him whisky to quiet him at night. The loss of sight, which had lasted about four months, was said to have occurred in consequence of his grandmother's death having been incautiously communicated to him. An emetic of ipecacuanha was first administered, and was followed by two pills, night and morning, consisting of the compound extract of colocynth, with one grain of calomel, and the same quantity of James' powder. The emetic and the pills operated freely; the latter were continued for twelve days. The vapor of the liquor ammonia was applied to the eye three or four times a day; and at the end of a week, a small blister was placed over the mastoid process, and subsequently dressed with savine ointment. Under a suspicion that he might have worms, a dose of oil of turpentine and castor oil was administered, but no worms came away. On the evening of the twelfth day, when the reading lamp was brought into the room, he said that he could see the light of it; but on trial he could not distinguish the finger, or any object held up before him. The next day a dose of senna tea was given instead of the pills; it operated three times, but less abundantly: he said that he could see his fingers. On the following morning, he awoke with a smart attack of fever; with quick pulse, dry hot skin, thirst and headache. A copious evacuation of the bowels soon took place in greater quantity than any preceding one, and very consistent, with numerous lumps of indurated fæces. About mid-day sight was perfectly restored; he saw every object even as minute as the seconds' hand of a watch. The recovery of vision was permanent, and the patient soon left Edinburgh quite well. (*Edinburgh Medical and Surgical Journal*, vol. xxiv. p. 64—66.)

Case.—*Amaurosis from worms.*—In the last winter (1839—40), I saw a boy, seven or eight years of age, whose sight had recently become so defective, that he could not distinguish even the capital letters of print. The irides were sluggish, and the pupils large, the eyes in all other respects being quite healthy. The general health was undisturbed. I ordered some alterative and aperient medicine, and two leeches behind the ears. After I had seen him three or four times, during which no change had occurred in the state of the complaint, it was mentioned that he had ascarides. The oil of turpentine was now thrice administered in the form of injection, and brought away a considerable number of worms, none of which were seen afterwards. Vision was now restored rapidly and completely.

In the case just related, the irides were nearly motionless, and the pupils dilated; while in Mr. Wishart's patient the iris moved freely, and the pupil was natural. Disorder of the alimentary canal may affect vision by acting on the retina, or through the medium of the ciliary system of nerves; the ophthalmic ganglion being the upper extremity of the ganglionic sys-

tem. These affections may be quite distinct, although generally, if the retina be seriously disordered, the ciliary system suffers, as we see from the condition of the iris and pupil. Disorder of the ciliary system, which is not an unfrequent effect of abdominal irritation, does not so commonly extend to the retina. The dilated state of the pupil, however, impairs vision so considerably, that the retina may be supposed to be diseased where the case is simply mydriasis, and where vision would be found to be perfect if the patient were to make the trial of looking through a small hole in a card. In a doubtful case the state of vision should be carefully examined, especially in young subjects, before we pronounce a decided opinion on the nature of the affection. If the retina retains its sensibility to light, the prognosis is more favorable than under the opposite state.

[A case of complete amaurosis in a child, which instantly ceased, on a worm being puked up, is recorded by Mr. Welsh, in the *Medical Communications of the Massachusetts Med. Soc.*, vol. i. p. 87.]

Amaurosis from debility.—Persons who are ignorant of physiology and pathology may naturally suppose that imperfection of sight depends on weakness of the optic nerve, and that the remedy must be found in means capable of strengthening the weakened structure. We should not have expected that they who understand the structure of the body, the nature and action of the causes which produce disease, and the influences which remove it, should borrow this opinion, and refer amaurotic affections to debility or atony of the nervous structure, or to weakness of the frame generally. The following statement by Beer will show how extensively the notion prevails, and how firmly it is believed.

"The cause of amaurosis very often consists in direct local or general weakness, which may be produced by moral influences capable of agitating the nerves generally, or by real physical commotion of the nerves of the head, more particularly of those belonging to the forehead and eyebrow, by concussion of the spinal cord, by a jump from a considerable height with the whole weight of the body coming on the heels, by concussion of the globe, even by violent and continued sneezing, and still more by contusions of the eye with blunt instruments. One of the causes to which the greatest influence must be ascribed in the production of amaurosis, is the serious direct weakness induced by loss of fluids, as in cholera, continued diarrhœa, in salivation, not forgetting the copious spitting of the tobacco smokers, who in modern times pursue their unmannerly practice in all places, in hemorrhages, in paracentesis abdominis when incautiously performed, in the loss of seminal fluid from excessive venery, nocturnal pollutions or onanism, and in the abuse of issues. General debility, capable of exercising a very prejudicial influence on the nervous structure of the eye, may be induced by other directly weakening causes; for instance, long and bitter affliction, continued vexation, incessant weeping, with constant anxiety about the means of subsistence, particularly if the diet be unwholesome, long fasting and watching, sudden and violent fright, inconsiderate washing and bathing the eyes in very cold water, particularly when they are already weak and irritable, long residence in dark dwellings, especially in the exercise of occupations which strain the eyes, a case very common in Vienna. The amaurosis occasionally seen at the end of typhus, without headache, or any signs of excitement in the eyes, and occurring, according to my experience, only after the pure and not the contagious nervous fever, must be regarded merely as a symptom of the general weakness: and this view is supported by the method of treatment, which consists simply in directing a suitable plan of diet." (*Lehre*, vol. ii. p. 449, 450.)

It is not necessary to comment on the heterogeneous nature of the in-

fluences, which are thus incongruously assembled under the common head of causes weakening the retina; to show that direct injury of that structure by laceration and concussion, as well as excessive exertion of the eye on minute objects, produces a kind of disorder which cannot be called nervous weakness without a total perversion of terms; to observe, that if amaurosis should follow general concussion of the body or typhus fever, the effect must probably be produced through the medium of the sensorium; or to express the doubts which will immediately occur to every intelligent reader, whether amaurosis has ever been produced by many of the causes here assigned, such as washing the eyes with cold water, the discharge of issues, and the spitting incidental to the modern accomplishment of tobacco smoking. The latter point may be recommended, for attentive consideration, to the amateurs of the pipe and the segar.

Dimness, confusion of sight, and blindness, previous to fainting, are well-known temporary effects referable to the suspension or diminution of the circulation in the retina and sensorium, when the heart's action is enfeebled or stopped by loss of blood or other causes. Two interesting illustrations of this subject occur in Dr. Gooch's Essay on *The symptoms in children erroneously attributed to congestion of the brain.* He mentions the case of a young and delicate child, who had been brought into a state of dangerous and ultimately fatal exhaustion, by the injudicious application of leeches. "The child," he says, "was deadly pale, it had scarcely any pulse, its skin was cold, the pupils were dilated and motionless when light was allowed to fall on them, and when a watch was held to its eyes, it seemed not to see; there was no squinting. Did this state of vision depend on the pressure of a fluid, effused into the brain since the bleeding and during this exhausted and feeble state of circulation, or did it depend on the circulation of the brain being too languid to support the sensibility of the retina? It is well known that large losses of blood enfeeble vision. I saw a striking instance of this in a lady who flooded to death. When I entered the chamber she had no pulse, and she was tossing about in that restless state, which is so fatal a sign in these terrific cases. She could still speak, asked whether I was come, (she knew I had been sent for,) and said, 'Am I in any danger?—How dark the room is!—I can't see.' The shutters were open, the blind up, and the light from the window facing the bed fell strong on her face. I had the curiosity to lift the lid, and observe the state of the eye; the pupil was completely dilated, and perfectly motionless, though the light fell strong upon it. Who can doubt that here the insensibility of the retina depended on the deficiency of its circulation?" Dr. Gooch adds, that the child died at the end of a week, extremely emaciated and exhausted; that she sometimes revived a little, so as to induce an expectation of recovery; and that she clearly regained her sight, for if a watch was held up to her, she would follow it with her eyes. (*An Account of some of the most important Diseases peculiar to Women*, pp. 359—361.)

This transitory effect of diminished circulation on the functions of the retina or sensorium must however be distinguished from permanent amaurotic affection, which has not occurred, under my observation, as an effect of the extreme debility consequent on want and starvation, on fevers, and severe bowel complaints, or of that connected with profuse suppurations and repeated hemorrhages, although I have seen some instances of slightly impaired vision referable to the latter cause, and easily remedied by strengthening measures. I have never witnessed an amaurosis under the influence of mercury, that could be ascribed to the quantity of fluid discharged from the mouth. In the case related at page 495, the sudden loss of sight was

obviously caused by the excitement consequent on the use of mercury, and not by the ptyalism, which had hardly become established.

It is well known that the energy of the nervous system may be seriously impaired by excessive venery and by onanism: it seems not improbable that the nervous structure of the eye might suffer in the same way by those enervating causes; but examples of this kind are not common. I am convinced that nocturnal seminal discharges, simply considered, do not injure sight.

I shall not, however, deny that the powers of the retina or optic nerve may be impaired by causes, of which the exact operation is not yet understood, and which may be denominated weakening, until we are able to appreciate more exactly their mode of action. And it is an unquestionable practical truth that strengthening treatment, including tonics and stimulants, is employed with advantage in many cases and states of amaurotic disease. One of the clearest cases of this kind is the amaurosis brought on by protracted suckling; the local affection being accompanied by unequivocal evidences of general debility caused by the unusual drain on the system. This occurs particularly among the poor, who keep their children a long time at the breast to prevent the recurrence of pregnancy, being obliged at the same time to work hard, and often with insufficient and unwholesome food. Such women become thin, pale, and weak; they are subject to palpitation, hurry of the circulation, and profuse perspirations. Without any apparent change in the organ, they complain of dimness, confusion of sight and giddiness, and see imaginary appearances before the eye. It is a matter of primary and urgent importance in these cases to wean the child, and to avoid all fatiguing exertion. A good diet with moderate use of fermented liquors, will be advantageous. The combination of tonic and nervous medicines, such as bark and valerian, or the sulphate of quinine, and mild aperients, if the bowels require them, for example, rhubarb and magnesia, or castor oil, constitute the essential features of treatment. If the affection should not give way to such measures, which it usually does, blistering may be resorted to, or a trial may be made of electricity.

Case.—*Complete amaurosis from debility caused by suckling.*—E. N., twenty-five years of age, of slender make, fair skin, and red hair, who had been married a year and a half, brought forth her first child four months before I saw her, which was in the middle of June, 1830. She suckled the child, which was strong and took the breast very frequently: her milk was abundant. Lately she had begun to feel very weak; she could not lift a weight, and she cried frequently without having any reason for uneasiness or complaint. Being totally blind, she was led to my house by a friend. She was pallid and had a small feeble pulse. The pupils were in the middle state, and the irides moved slightly. The retinæ were completely insensible; she could not discern the situation of the window, nor see a lighted candle held close to her. I directed her to wean the child, to drink porter, and take the sulphate of quinine. In a few days, as sight did not improve, I ordered a blister to the nape, and afterwards friction of the tartar emetic ointment in the same situation. When the latter began to produce its effect, the sight mended. On the 2d of July she could see nearly all objects, but was unable to read: the motions of the iris and the pupil were natural. (To leave off the quinine; four grains of Plummer's pill every night; a draught of infusion of rhubarb, with compound decoction of aloes daily.) 16th July.—The pills have been increased to two daily; the health and strength are good; the irides act well, and the pupils are natural. Sight is improved; she can see the large letters over doors, but is unable to distinguish even the capitals of print. As this patient found herself improving,

she did not return to me for some time, but continued her medicines. When I saw her in November, she had long left off all treatment, and had resumed her usual active occupations. Her health and strength were good; the sight was completely restored, and she read to me the smallest print with facility.

The following case of amaurotic affection from suckling is related by Mr. Ware.

A lady, thirty years of age, found her strength fail after suckling for six weeks, and she soon became incapable even of moving about the house without experiencing painful languor. About the same time her sight also was affected; first only in a small degree, but afterwards so considerably that the full glare of the mid-day sun appeared to her no stronger than the light of the moon. She began to feel a violent pain in the neck, running upwards to the side of the head; and four ounces of blood were taken from the part by cupping. After this, the sight was worse than before, and soon the use of both eyes was entirely lost. The pupils were much dilated, and remained so in the strongest light. The means directed for her were, to wean the child immediately, to apply the vapor of ether frequently to the eyes and forehead, a bark draught three times a day, and opening medicine on account of costiveness, which had existed since her delivery. On the fourth day, the strength and spirits were improved, and faint glimmerings of light could be perceived, though the pupils remained dilated and fixed as before. The former means were continued, and electricity was employed in addition. The first application of the latter was almost immediately followed by amendment, so that the patient, to whom all objects had before been confused, could now tell how many windows there were in the room, though she was unable to distinguish the frames. On the third day the menstrual discharge came on, and the treatment was left off until it had ceased. At the end of a week she could perceive large objects, and in a short time her sight was so much recovered, that she could read even the smallest print. Her strength did not return so quickly; but it was soon restored by change of air, and a mild nutritious diet. (*Observation on the Cataract, Gutta Serena, &c.*, 3d edition, p. 385—389.)

[Dr. Ashwell in an interesting paper, in *Guy's Hospital Reports*, April 1840, "on the morbid consequences of undue lactation" remarks, "a Functual Amaurosis, accompanied by congestion of the conjunctiva, is a frequent result of excessive lactation; and seldom fails, from its interference with the sight, at once to arouse the patient's fears lest vision should be entirely and permanently lost. These apprehensions may with truth be allayed; as doubtless, in the greater number of cases, prompt weaning will alone remove the affection; still, it may be necessary repeatedly to apply small blisters near the eye, and absolutely to forbid its employment. Improved diet, country and sea air, exercise out of doors, iron and quinine, are important remedial auxiliaries. Nor is it unimportant that quickly-recurring pregnancy should, if possible, be avoided. I have known several instances where, during a pregnancy immediately succeeding the exhaustion of over-nursing, the eye has been almost constantly in a state of "blood-shot" or congestion, and the sight excessively imperfect. Months, and even years, sometimes elapse, where able treatment has done its best before distinct and strong vision is re-acquired. Specks, and slight ulcerations of the cornea, are occasionally connected with the exhaustion and irritability of nursing. In all these cases, provided there be no serious organic change, the sufferer may be encouraged certainly to expect the restoration of this most invaluable faculty.]

If amaurosis should occur in an individual who has been weakened by any of the causes just alluded to, or by others of analogous operation, and if well marked symptoms of debility should be present, strengthening means, both dietetic and medical, must be resorted to, as in the following example.

Case.—*Imperfection of vision from debility consequent on miscarriage.*—I saw a female in 1826, nearly forty years of age, who had experienced a severe miscarriage six weeks previously. She was pallid and feeble; the palpebral conjunctiva was quite white; the motions of the iris and the pupil natural in both eyes. She experienced dizziness with dimness of sight, and saw black specks before the eyes. I desired her to drink porter, to take a dose of powdered bark three times a day, and ten grains of rhubarb occasionally. In three days she was nearly well.

The effect of suckling on the eyes is not always clearly explicable on the supposition of debility. Ordinary inflammatory affections of the organ are more severe and obstinate during this state, so that it may probably exert some general influence of which we do not understand the exact nature.

We must take care not to confound the complaint just described with other modifications of amaurosis, to which women are liable during pregnancy and suckling. In the general fulness, which exists during utero-gestation, and particularly in its latter period, when the pressure of the enlarged uterus impedes the evacuation of the bowels, determination of blood to the head with impaired vision may occur. Venesection, purging, and regulation of diet would be necessary in such a case. Amaurosis may occur during suckling from plethora induced by diet too abundant and stimulating, and particularly by that free use of porter and other strong liquors which are erroneously considered necessary to support the strength of females during this process. The local symptoms are here attended with a full pulse, heat of skin, flushed face, headache, and white tongue; an assemblage of circumstances very different from those which attend debility from protracted suckling, and requiring depletion with change of diet.

Beer states that amblyopia or amaurosis, accompanied with nausea or with vomiting which cannot be quieted, sometimes occurs early in pregnancy, and ceases after parturition. He saw a young Jewess, who, in her first three pregnancies, which followed in quick succession, began to grow blind in the early period, and became quite amaurotic in the third or fourth month. On the first two occasions she continued blind until after parturition; and sight never returned the third time. (*Lehre*, vol. ii. p. 444.)

He has also devoted a chapter to what he calls amaurosis from suppressed secretion of milk in suckling women. (*Ibid.* 572—575.) In this, which he describes as a very rare affection, he says that all the blood-vessels of the eye are turgid, the pupil slightly dilated, the iris changed in color, and swelled, and the transparent media turbid; that there is amaurotic blindness with intolerance of light and luminous appearances before the eye, and racking pain of the eyebrow and forehead. The complaint is obviously not amaurosis, strictly so called, but acute inflammation of the internal tunics. In the constitutional excitement attending so violent a local disorder, we may expect that the secretion of the mammary glands would be diminished or suspended. It would require very strong evidence to convince us that the latter circumstance and the amaurotic affection stand to each other in the relation of cause and effect. Beer says that the prognosis is most unfavorable; and I doubt not that this remark would be fully justified by the event, if the affection were treated in the manner he proposes. Instead of the active antiphlogistic measures so urgently required

in a disease of this violent and dangerous character invading the very seat of vision, he is contented with endeavoring to restore the mammary secretion, by poultices with chamomile flowers, hemlock, and other herbs, by aromatic herbs with camphor, by rubbing the breast with flannels strewed with frankincense and mastic: if these means do not succeed, arnica, calomel, and camphor are recommended, with issues.

In persons of bad constitution and impaired health who use their eyes excessively, or even in those otherwise healthy, who exert the organs imprudently, their strength being impaired by confinement and unwholesome diet, an affection of sight may supervene, characterized by muscæ volitantes, dimness, and want of power to sustain continued exertion. The symptoms may here be referred to atony of the nervous structure; at least they are kept up and aggravated by the depressed condition of constitutional power. The necessity of tonic and restorative measures in medicine, diet, and general management, with discontinuance of the exciting cause, is obvious under such circumstances. Subsequently, counter-irritation, the cautious use of mercury, or both may be required, if the imperfection of vision should continue and indicate disease of the retina.

[Taking a hint from certain quack vendors of spectacles, Dr. Cunier, of Brussels, has made trial of the effects of convex glasses, in what he terms *cases of simple anæsthesia of the retina*, and with a considerable share of success. The influence of the light, directed upon the retina by such glasses, appears beneficially to excite the sunken sensibility of the optic nerve.

A lady, whose case he relates, could not for eight years without difficulty distinguish with her left eye the large characters forming the title of a newspaper; could not tell the hour on the clock, unless her eye was within two inches of the hands, nor distinguish the feature nor the figure of a person at the distance of two feet. If the right eye was covered, the left pupil became dilated, and remained so.

Glasses, whether concave or convex, ought always to be distinguished by their focal lengths, and not by numbers. As Dr. Cunier employs the latter mode, we are at a loss to know the precise power of No. 3, with which the patient could read a large type with her left eye, but probably it was a convex lens of three inches focus. After exercising the eye with this lens for some minutes, vision became confused and the head painful, so that the patient was obliged to desist. Next day she could with No. 3½, and on the third day with No. 4. The duration of this kind of exercise was gradually lengthened, and glasses of longer and longer focus employed. By the tenth day, the patient read the hour on the clock at the distance of 22 inches, and recognized individuals at double that distance. By the seventeenth day of the treatment, No. 24 was employed, and the patient could read small type. After two months use of No. 24, the sight of the left eye was as good as that of the right.

Several other successful cases are related by Dr. Cunier.—*Annales d'Oculistique*, May, 1842.

Hysteric Amaurosis.—There is a form of amaurosis to which allusion may be made here; it is that which occurs in hysterical persons, and to which attention has been recently more particularly drawn by Mr. Hocken. It is well known that hysteria simulates a great many diseases, among which number is amaurosis, not only in its mildest grades and of brief continuance, but sometimes amounting to complete blindness and of protracted duration. The treatment must be first directed to the correction of the derangement of the particular function which has called the constitutional disorder into activity, usually some disturbance of the

digestive or uterine organs, and next to allay the irritability of the nervous system.]

Amaurosis from affection of the nervus trigeminus.—I have already quoted the papers in which Mr. MAGENDIE has shown that injury or disease of this nerve within the cranium will cause inflammation of the eye, with destructive ulceration of the cornea, and that ultimately, evacuation of the globe and collapse of the tunics ensue. (See p. 96.)

These changes are sometimes preceded and accompanied by insensibility of the parts supplied by the trigeminus, including the surface of the eye. The latter may become insensible without passing into the state of inflammation and ulceration.

A striking illustration of this subject is afforded by an interesting case recorded in the first volume (page 531) of the *London Medical Gazette*, by my colleague, Mr. STANLEY.

In a lady, forty years of age, inflammation of the brain came on immediately after her confinement; she subsequently suffered severe and almost constant pain in the head. She was confined again about three months before her death. When nearly recovered, she was attacked with pain in the head more acute than usual, and delirium, which subsided, and were followed by hemiplegia of the left side. During the last two months of her existence, sensation and motion were completely lost on the left side of the face, but the former remained in the arm and leg. Frequent attacks of erysipelas occurred on the left side of the face; from the interior of the left nostril, which was deep red, blood was frequently discharged. Hearing was lost on the left side, and sensation on the same side of the tongue; but motion remained in the latter. Great vascular distension took place in the left eye and was followed by opacity and ulceration of the cornea, and escape of the aqueous humor. The pons varolii was enlarged on its left side, so as to compress the trigeminal, auditory, and facial nerves of that side, against the basis of the skull. This enlargement arose from a tumor about the size of a walnut, formed in the pons, of which it occupied the whole left side, and extending into the left crus cerebelli. In the eye, which is preserved in the Museum of St. Bartholomew's Hospital, the central portion of the cornea is destroyed by ulceration. The edge of the pupil is everted, and the opening filled by a dark substance. The iris, ciliary ligament, and choroid appear natural. The state of the interior parts has not been ascertained.

Injury, or other irritation of the branches of the trigeminus, may bring on impaired vision or amauroris. This point has been already illustrated, in reference to wounds of the supraorbital nerve. (See pp. 116—122.) The sympathy between the trigeminus and the immediate nervous apparatus of vision affords the only explanation of some apparently obscure cases, in which amaurosis seems to have depended on a carious tooth, or on some other local affection seated in the head.

CASE.—*Amaurosis caused by a carious tooth.*—F. P., thirty years of age, possessing a good constitution, and enjoying good health, with the exception of pains in the head and limbs, which never lasted long, suddenly experienced, in the autumn of 1825, a violent pain shooting from the left temple to the eye and the side of the face: he ascribed it to cold. This pain lasted several days, then lessened, and re-appeared from time to time without being sufficiently severe to induce the patient to seek medical aid. In about two months it suddenly increased in intensity, occupying the eye, particularly, with a feeling as if it would pass out of the orbit. F. P. now discovered that he was blind with that eye, and applied to a neighboring physician, whose treatment, continued for two months, did no good. The

pain, however, was no longer continual: it assumed a somewhat periodical character, leaving the patient easy for some hours in the day. At the end of the following six months the pain increased, the cheek swelled, some spoonfuls of bloody matter were discharged by a spontaneous opening in the lower eyelid, after which the swelling subsided, and the pains nearly disappeared, although the blindness remained complete. The discharge was renewed from time to time, during the following six months, and there was no great suffering. But in the autumn and winter (1826) the pain, particularly in the eye, became so violent, that F. P. came to Wilna, in the beginning of 1827, determined to have the organ extirpated, if no other remedy could be found. Professor Galenzowsky found the left eye totally insensible to light, with the pupil dilated, and no other visible alteration. The pain, not then so severe, consisted in violent occasional pricking or darting sensations in the left temple, and parts round the eye. There was discharge from the lower eyelid. The first molar tooth of the left side was carious; it had not caused much uneasiness; and the toothache, when it existed, had not coincided with the pains in the temple and eye. The professor determined on removing this tooth, and having done so, was surprised to see a foreign body at the extremity of the fang. When drawn out, it proved to be a small splinter of wood, about three lines in length, which had traversed the centre of the tooth, and had probably been introduced in picking the teeth. A probe passed from the socket into the antrum, from which a few drops of thin purulent fluid escaped. The pain ceased almost entirely, and, on the same evening, the eye began to be sensible to light. Vision gradually improved, so that, on the ninth day, the patient could see as well with the left eye as with the right, after a blindness of thirteen months: on the eleventh day he left Wilna to return to his family. (*Archives Générales de Médecine*, t. xxiii., p. 261—264.)

I had the pleasure of becoming acquainted with Professor Galenzowsky, when he visited England subsequently to this occurrence. He showed me the tooth and splinter of wood. He pointed out two circumstances in the case as particularly worthy of notice:—1st, that the entrance of the foreign body into the tooth had not been noticed at the time; and 2dly, that a local irritation, hardly perceived in the seat of injury, should have affected the ramifications of the nervus trigeminus so violently as to produce amaurosis.

[A number of similar cases in which amaurosis resulted from irritation of the nervus trigeminus might be adduced from various writers. We extract the following from our MS. work on the diseases of the eye.

Mr. Travers has seen an incipient amaurosis distinctly arrested by the extraction of a diseased tooth, when the delay of a similar operation had occasioned gutta serena on the opposite side, two years before, (*Synopsis of the Diseases of the Eye*, p. 305, 3d ed.;) and Richter relates a case of a lady who had been blind for years, and who experienced a short recovery of her sight on having a tooth extracted. (*Anfangsgr.*) Mr. Caffe quotes the case of a person who had an upper molar tooth excavated by caries, and who, whenever a portion of food entered its cavity became immediately amaurotic in the eye of the corresponding side. The amaurosis ceased as soon as the cavity of the tooth was cleared. (*La Lancette Francaise*, 22 *Aug.*, 1839.) Dr. Watson states that the son of a physician of his acquaintance, in London, became blind in one eye on two or three occasions, without obvious cause, and with no visible change in the organ, and the blindness, on each occasion, went off, *apparently*, in consequence of the extraction of some teeth which had grown irregularly, (*Lectures in London Med. Gaz.*, Feb. 5,

1841;) and Dr. ASHBURNER says that such cases are common, (*Ibid.*, p. 712.)

Dr. JAMES HUNTER relates the following case of temporary amaurosis in one eye, following the extraction of a tooth.

In July, 1838, a lad, aged 17, applied at the Dispensary on account of a dimness of sight in the left eye, which had come on rather suddenly and under peculiar circumstances. He stated that the sight of both eyes had been very good till four days previously, when, suffering from toothache, he went in the evening to a druggist to have a carious tooth extracted from the left side of the upper jaw. The operation was easily and dextrously performed, and the pain was not particularly excruciating. At the moment the tooth was loosened from the socket, he perceived a brilliant flash of fire before the left eye, which was followed for some minutes by several fainter ones at short intervals. On going to bed an hour or two after, the flashes of fire reappeared, and continued for about an hour, when they gradually ceased. Next day he found the sight of the left eye very much impaired, and all objects seen with it appeared enveloped in a thick mist. He also observed a sort of luminous colored ring, whirling round, as it were, in the interior of the eye. This state of matters continued much the same for the next two days, and, on the fourth day he thought there was a decided improvement.

"On examining the left eye, its pupil appeared a *very* little more contracted than that of the right eye, but its shape was perfectly regular, and the motions of the iris unimpaired. In every other respect, too, the organ presented a perfectly natural appearance. The general health of the lad, who was of a somewhat sanguineo-nervous temperament, was good. He had no pain in the eye, or in the brow, and no symptoms of cerebral congestion, or of derangement of the digestive organs. When he closed the right eye, the sight of which was sufficiently acute, and looked with the left one at the page of a book, printed in a type which I have since ascertained can be easily read by a good eye at the distance of 48 inches, I found he could not make it out at a greater distance than about 15 inches, and even then with difficulty, and at any nearer distance, though the letters appeared larger, they still seemed to run into each other. When I tried him with type about one-half the size of the first, he was unable to read a single word of it at any distance." "Neither convex nor concave spectacles improved his sight. His perception of colors appeared somewhat impaired, but I had not the means at hand of examining carefully the condition of the eye in this respect. The tooth which had been extracted was the first great molar on the left side of the upper jaw. On making firm pressure with the points of my fingers in its socket, there was no unusual tenderness nor any shooting nervous pain produced, and I could not discover any remaining portion of the tooth, nor any splintering of the alveolar process."

Dr. HUNTER left the case to nature, and at the end of a fortnight he could distinguish all but very minute objects. He did not return afterwards, so that his recovery was probably complete.—(*American Journ. Med. Sci.*, Oct., 1841.)

A case of amaurosis following a lesion of the fifth pair of nerves, occurred also in the service of Mr. PASQUIER, at the Hotel des Invalids. The subject of it was a lieutenant, convalescent from lumbago, who had had the first large molar of the right side of the upper jaw extracted, in consequence of its being carious, and giving him much pain. In the operation the alveolus was broken and the gum torn, which caused inflammation and suppuration in the alveolus, and the discharge of some

small portions of necrosed bone. The day after the operation the patient suffered from pain, extending to the right temple, without swelling, redness, or heat; this pain was lancinating, exacerbating at frequent and irregular intervals, most frequent in the evening, and was increased by pressure. The pain extended in the direction of the temporal nerves of the seventh pair as far as the parotid plexus; and also towards the forehead in the direction of the superciliary branch of the ophthalmic division of the fifth pair. The pain afterwards concentrated in the last mentioned branch, the superciliary. At this time, five days after the operation, the right eye became almost perfectly amaurotic, the pupil was dilated, and the patient experienced a constant convulsive action of the eyeball, as if the eye was leaping from its socket. The eyelids of that eye were slightly tumefied, and almost constantly contracting. The secretion of tears rather diminished than increased. At this time there appeared an abundant thick puriform, greenish fœtid discharge from the right nostril.

A blister was applied to the temporal region, and the raw surface powdered morning and evening with half a grain of acetate of morphium. The pain was promptly abated by this treatment, and by the tenth day vision was restored. By the seventh day the discharge from the nostrils diminished and lost its fœtor, and on the 22d day the pain entirely ceased. Until this last date the local application was continued. (*La Lancette Francaise*, 22 August, 1839.)]

The eyebrows and eyelids are involved, often very seriously, in the neuralgic affections incidental to the external branches of the ophthalmic and superior maxillary divisions of the nervus trigeminus. The treatment of such cases, as well as that of similar pains in the eyeball, which sometimes occur, comes under the general therapeutic principles applicable to neuralgia.

Amaurotic cat's-eye.—This is the name given by Beer to an amaurotic affection, accompanied with a remarkable change of color in the pupil, which presents, apparently in the fundus of the eye, a lighter tint, yellowish or brownish yellow, instead of its natural clear black. He says that "a pale gray, or whitish-yellow opacity, sometimes with a reddish cast in certain lights, is developed in the bottom of the globe, far from the pupil. The sight is not merely weak, but in the strictest sense confused; for all objects, particularly those of smaller size, seem to run together when the patient attempts to survey anything attentively. As the disease proceeds, the bottom of the eye becomes clearer and more visible, and the color of the iris paler, the latter change being particularly obvious in dark eyes. When sight is completely extinguished, we may discern, on close inspection of the pupil, a fine vascular network over the opacity, being apparently the ordinary ramification of the arteria and vena centralis, rendered visible on the shining opal-like fundus of the globe. Such an eye, when seen in particular directions, has a yellowish or reddish luminous appearance in twilight, resembling, in some degree, that of the cat, whence I have derived the name." (*Lehre*, vol. ii., p. 495—498.)

The following cases of this affection, which is uncommon, came under my observation at St. Bartholomew's Hospital.

Case.—Robert Mason, twenty-three years of age, a spare youth, of delicate appearance, was admitted into St. Bartholomew's Hospital under my care in the summer of 1828, on account of impaired sight in both eyes. He said that he had enjoyed good health; that the sight of the left eye began to fail eight years ago, and is now very imperfect; that the right has become dim in the last nine months; and that the complaint has not been

attended with any pain. The anterior chamber was unusually small; the iris dark-brown, and sluggish; the pupil about the middle size, and of a dull gray, instead of the natural black color. When the pupils had been dilated by the belladonna, an apparently concave opacity, of a gray or dull yellow color, with small blood-vessels ramifying on it, was seen far behind the iris, in the very back of the left eye. A similar appearance was found in the right eye; but the opacity was less extensive, and no vessels were visible. With the left eye, the patient could merely distinguish light from darkness, while, with the right, he could read large print. He left the hospital at the end of a month, the means employed having been of no service.

Case.—Ann Milling, twenty-five years of age, of spare habit, dark complexion and hair, and brown irides, has usually enjoyed good health, living in service, and not using her eyes in any occupation likely to be injurious. Seventeen months ago she began to observe a mist or cloud floating before the left eye: in twelve months the sight was entirely gone. She has experienced no pain. The iris is darker than in the opposite eye: it moves in harmony with the other, but has lost its independent action, excepting a slight oscillatory movement. The pupil, which is of natural size, presents a deeply-seated brownish-yellow discoloration, which occupies uniformly the whole fundus of the globe, whether observed in the dilated or contracted state of the aperture. Vision is totally extinct. The general health is good.

At the London Ophthalmic Infirmary I saw two boys with this affection: one was fourteen, the other eight years old. In the latter both eyes were diseased; vision was entirely lost in one, with a pale and dull yellowish discoloration of the whole fundus of the globe. In the other eye the discoloration was partial; its boundary could be seen when the pupil was dilated, and imperfect vision still remained.

Mr. Tyrrell considers that this disease is more common than has been generally supposed; but that it escapes observation unless the organ be very carefully examined. Until within the last two or three years he had considered it to be extremely rare; but he had found latterly that the metallic appearance exists in some degree in many cases of amaurosis. It is most easily seen when a moderate light falls on the eye, and the observer is a few feet off. In a boy ten years of age brought to the London Ophthalmic Infirmary for loss of sight, no change could be detected in the pupil by close examination. The nature of the case was not detected until the patient had attended several times. At last, when he was standing a few feet off in a part of the room shaded from direct light, Mr. Tyrrell observed a brilliant metallic reflection from the eyes, which was no longer discerned when the eyes were exposed to a strong bright light.

The appearances in the pupil leave no doubt that blindness is caused in these cases by organic changes in the retina and choroid coat; but hitherto the nature of the alterations has not been elucidated by dissection.*

We know nothing about the causes of the disease, which has always proceeded, within my observation, to complete loss of sight. Beer, however, says that it seldom reaches this full development, but usually remains stationary after causing a more or less considerable degree of amblyopia. I suspect that the latter observation arises from his classing under this name cases which probably belong to other affections. He says, for example, that the affection called *amblyopia senilis* is probably of this nature; al-

* Von Ammon has attempted to delineate the appearances which characterize this affection in his *Klinische Darstellungen*, part i., tab. 15, figs. 10 and 11.

though with a pale gray discoloration of the pupil, there is often but little diminution of sight. He states that it is more common in the old than in the young, which does not correspond with my experience. And he also represents that it follows violent injuries of the globe. A bright yellow discoloration of the pupil, with inequality of surface, sometimes remains, in the latter cases, after violent internal inflammation, and the globe becomes atrophic. This effusion of lymph, consequent on high inflammation, is a case quite distinct from the disease just described.

The early stage of fungus hæmatodes may be confounded with the amaurotic cat's eye. The distinguishing circumstances may be collected from the description of the latter affection.

Muscæ volitantes.—The imaginary objects occasionally seen moving before the eyes, and called in common language *motes*, are technically termed *muscæ volitantes*, by which name their apparent motion is designated. I have already mentioned them as an early symptom of amaurosis, and consequently as precursors of impaired vision. (See page 509.) They frequently, however, occur from some affection of the eye, which produces no other unpleasant effect, and consequently they do not, then, forebode any injurious consequences to vision.

Their appearances are infinitely varied. Sometimes they are spots of various shape and size, black or lighter colored; sometimes dark, with a luminous edge. They may be streaks or lines, straight, waved, angular, twisted, or united in various ways. Sometimes they appear as transparent bladders, or luminous chains, which are generally undulating. They may have a metallic appearance, like globules of quicksilver; or may seem transparent, like water or glass. Often there is the likeness of an insect, as a spider, worm, or that of a spider's web, or portion of net. In figure, number, size, and color, they present endless varieties. Frequently there is a single dark spot, moving with the eye and presenting before any object that is looked at: there may be many such, described as resembling the blacks floating in the atmosphere of London. When they are numerous, they interfere with vision, and annoy the patient greatly. They move with the eye, and appear to descend when the eye is turned upwards, and *vice versa*. Often they are luminous and various colored, or like sparks. They are most distinctly seen in a strong light, as when the person is looking towards the sky. They present themselves particularly when the organ is exerted, becoming more inconvenient as the exercise of vision is continued, and compelling the patient to desist. Often one eye only is affected. Sometimes they are seen even when the lids are closed.

In some cases this complaint is obviously connected with increased determination of blood to the head. The first appearance of the muscæ is generally traced to circumstances directly affecting the eye, such as unusual and continued exertion of the organ. They will be more likely to occur when the stomach and bowels are disordered, and when the energy of the nervous system is impaired by pressure of business, by anxiety and distress, by severe and continued affliction, or overwhelming grief. Often the complaint seems simply referable to causes of the latter descriptions; and it aggravates the mental disturbance by creating apprehensions for loss of sight.

These imaginary objects, depending on occasional causes in many instances, have only a temporary existence. Sometimes persons are troubled with them for many years, the sight remaining perfect in all other respects; and it is difficult, or even impossible to remove them.

The important point is to distinguish whether these muscæ volitantes are a symptom of incipient amaurosis or cataract; or whether they arise from

some affection of the eye, which causes no other mischief. If they should be attended with a cloudiness of vision, objects being seen as if a mist or fog surrounded them, the case may be incipient cataract, and careful examination of the eye under artificial dilatation of the pupil may be advisable. If other symptoms indicating amaurotic affection should be present, such as a sluggish or motionless state of the iris, alteration of vision in any of the ways just described as indicating affection of the nervous structure, change in the color of the pupil, pain in the head and eye, we must regard the muscæ volitantes as a symptom of approaching amaurosis. In these respects the shining or fiery objects, such as luminous stars, sparks, and flashes, are the most unfavorable.

If the motions of the iris be perfect, if the pupil possess its natural color, and if the patient can distinguish minute objects as well as before, the muscæ volitantes need not excite alarm: vision is in no danger.

[We must add a few words as to the importance of a correct diagnosis, where muscæ volitantes present themselves; for we have met with instances in which from a mistake in this, patients have been unnecessarily thrown into the greatest alarm, and subjected to severe treatment.

Some years since, we were consulted with our friend, Dr. S. Jackson, by a young gentleman of the legal profession, from the south, affected with muscæ, which his medical adviser supposed to be premonitory of amaurosis. The patient had been greatly reduced by profuse depletion, low diet, blistering, &c., by which he had been rendered exceedingly nervous, and his affection aggravated. After a careful examination, we assured him that he need have no apprehension of loss of vision; that if he would dismiss his fears of this, and by improved diet, with country air, regain his strength, he would soon be accustomed to the appearance of his muscæ, and they would then scarcely be noticed by him. We advised him to visit Saratoga, and travel for a month or two, to re-establish his health.

On his return south he called on us, with his health much improved, and with better spirits: and he then informed us that the apprehension of becoming blind, of thus being a useless member of society—all his youthful ambitious aspirations blasted—had been too much for him, and that he had determined, if we had confirmed the prognosis of his physician at home, to put an end to his existence. On taking his leave, he expressed his hopes that the encouragement we had given him might be well founded, and remarked in a significant tone, "you shall hear of me one way or another." We have heard of him, and not as a wretched suicide, but as one of the most prominent and influential men in his State.]

The immediate cause of this symptom has not yet been satisfactorily explained. The notions of partial pressure on the nervous structure, by distention of vessels in the retina or in the choroid, or by inequality in the surface of the latter membrane, are plausible but merely conjectural. Luminous appearances and imaginary objects of various kinds with temporary dazzling are produced by holding down the head, in healthy persons. The vessels of the choroid and retina must be filled in such an attitude. The explanation, derived from minute particles supposed to be floating in the aqueous humor, seems to me to have no foundation; at least I have never seen them: and these muscæ, which are seen in eyes apparently perfect, do not occur when a fragment of lens or capsule is in the anterior chamber, or when opaque specks exist in the cornea.

[Mr. Clay Wallace conceives, with some plausibility, that the nervous appearances of muscæ may be accounted for, by the structure of

the retina, which, it should be remembered, is composed of four layers, a vascular, a fibrous, a globular, and a serous. "I have occasionally," he observes, "when entering an ordinary lighted room, after a full meal, and exposure to a bright light, witnessed glimmerings like a network, which, from its resemblance to the vascular coat, left no doubt in my mind, that the blood-vessels of the retina were visible: at other times, in the same circumstances, there was a twisted tube, or a chain of beads, as if there had been an error loci of one of the curved fibres of the retina; or there was a cloud of globules sometimes packed together, but more frequently separated, and floating in all directions. Each globule was visible for a considerable time, and reoccupied the same space. When clustered together, they had a great resemblance to the globules of the retina.

"From the similarity of the drawing of the floating network, in Case No. 1, to the vascular coat of the retina, I am persuaded that any person who has seen both, will have no hesitation in locating the disease; and if the network, curved filaments, and globules appear to others as they do to me, the various *muscæ* will be ascribed to affections of the structure which they resemble." * * * * * *

"If, when the eye is directed forward at a distance, we move a lighted candle up and down on one side of the line of vision, a representation of the vessels of the vascular membrane shortly appears, as if displayed upon a screen. The vessels are greatly magnified, on account of the portion of the retina which they occupy, compared with that of an ordinary image. We may hence infer, that a very minute congestion may cause a large musca.

"It is stated by Demours, that the diameter of muscæ appears to increase in proportion as we recede from the plain in which they are examined. Such a filament as appears one-sixth of a line in diameter, and one inch long, when seen on a leaf of very white paper, at the usual focal distance, appears two lines in diameter, and more than a foot long, when we examine it by looking at a white wall, at the distance of twenty or thirty feet; and in the only case in which he mentions the subject, Mr. Ware says, that the magnitude of the moats depended much on the distance at which they were observed, being larger when seen far off, and smaller when near the eyes. Can the diminution arise from the less degree of pressure as the lens approaches the cornea, when adjusted to near objects?

"As the papillæ of other nerves become erected when excited, it would seem that the fifth, which is a compound nerve, enables the expanded fibres of the optic nerve to be placed in a proper condition for conveying a distinct impression to the sensorium. Should there be any unusual turgescence of the vascular membrane, or any *error loci* of the globules, or of the sentient fibres, or diminished supply of motive power to the latter, or should there be effusion of lymph or varicosity of the choroid, the fibres will not be free to the action of light, but will convey false impressions, and there will be an appearance of motion when, during their erection or tension, the fibres come in contact with diseased vessels, filaments, or globules.

"It is difficult to keep the eye on one object for a long time, but when it is accomplished, the retina soon becomes fatigued, the fibres lose their tone or tension, and the object disappears. As soon as they have rested the object comes again into view, and there is an alternate disappearance and reappearance of the object as long as the experiment can be continued. If, when the light is very obscure, we look intently at a feebly

illuminated object, the fibres, in endeavoring to adapt themselves to the degree of light, soon become painfully affected, and the object is no longer visible." (*A Treatise on the Eye*, p. 80—85. New York, 1839.)

"Dr. James Stark, of Edinburgh, has investigated the causes and phenomena of muscæ volitantes, with considerable care, and he conceives that the observations he has made seem to prove that muscæ are nothing else than the globules of mucus which lubricate the external or mucous surface of the transparent cornea. "These globules are," he remarks, "only rendered visible when the retina, or expansion of the visual nerve, is in an irritable state; and that it is so in all those cases in which this phenomenon is observed, is well known to every medical practitioner. It is, besides, a matter of common observation that the eye laboring under this malady feels uneasy and heated, and is unusually dry. This state would, therefore, render the mucous secretion more viscous than usual, so that the globules of mucus, instead of floating freely over the eye, would be wiped by the eyelid, and motion of the eyeball on the lid, into irregular wavy or zigzag lines of reticulations, and give rise to that appearance so often described as a net-work or cob-web before the eyes, (*visus reticulatus.*) The irritability of the retina is known to be induced by a great many causes. Two opposite states of the circulation will increase its irritability, viz. that of congestion from an overflow of blood to the part, or semi-stagnation of the circulating fluid in its vessels from want of tonic power to propel it. This is the reason why *muscæ volitantes* are not only seen in almost all affections of the retina, as in incipient amaurosis, retinitis, &c., but are also of very common occurrence in all dyspeptic complaints, the low stages of fever, &c. It is the circumstance of this malady generally attending the first stage of amaurosis,—a disease commonly leading to the loss of sight, which has made their occurrence be so much dreaded by all. It is the circumstance of so many practitioners confounding these moving muscæ with the fixed specks which depend on organic changes in the eye, (whether these arise from partial opacities in the humors, or their enveloping membranes, or depend on certain spots of the retina having lost their sensibility,) which has so often led them astray as to the cause of their production, and induced them to regard their presence as an indication of the existence of some serious disease of the eye.

"By attending to the characters laid down above, no doubt can ever arise as to the true nature of the bodies which are met with in the eye, and disturb vision. Where *muscæ volitantes* are found uncomplicated with fixed specks, nebulæ, or indistinct troubled vision, we can always satisfy the patient as to the innocuousness of the malady under which he labors, and free his mind from any anxiety as to his losing his sight. The diagnosis of the malady, then, is of no mean importance in practice; for though the complaint is of itself simply annoying and unattended with danger to the sight, it is so often also an attendant on those affections which lead to the destruction of vision, that every means ought to be used to discover its true nature. If, with the moving harmless muscæ, threads, lines, reticulations, or showers of fire, there be fixed specks in the eye, deep-seated pain, clouded or mottled vision, and the other more ordinary symptoms of amaurosis or affection of the retina, it is high time that the most active remedies be employed, as the total loss of vision is threatened. But if these are wanting, and it be ascertained that the muscæ exist alone, general treatment is all that is usually required to restore the vision to its accustomed clearness. It is worthy of remark, however, that when once *muscæ volitantes* have appeared in the eye,

they are scarcely ever got entirely rid of. Whether this depends on the eye becoming morbidly sensible to the globules of mucus moving over its corneal surface, or to the person attending more to the presence of such bodies and looking for them, and that the system once thrown into the condition which favors the appearance of these muscæ, is easily affected in a similar manner, has not yet been accurately ascertained. Certain it is that, in the eyes of those once affected with muscæ, even a trifling cause will produce their reappearance. A fit of indigestion, derangement of the bowels, overstraining of the eyes, &c., will, again and again, cause the reappearance of these troublesome visitors, and from these causes they may be seen at intervals, during the whole course of a long life, without permanently injuring vision." (*Ed. Med. and Surg. Journ.*, Oct. 1843.)

Dr. Mackenzie, in an elaborate philosophical and very interesting paper in the *Edinburgh Med. and Surg. Journal*, for July, 1845, has analyzed at length the several opinions of writers on the nature and causes of muscæ volitantes, and then considers the different spectra of which the eye is susceptible, and which, when they become exaggerated, give rise to muscæ volitantes, in the following order.

1. The *muco-lachrymal spectrum*, which is generally invisible to the naked eye, but may be usually seen in the form of dark globules (capable of being removed, or having their position changed by nictitation), when looking through the microscope, or still more distinctly and certainly when viewing a candle, placed at some twenty feet distant, through a deep concave lens. This spectrum is the result of each globule of the muco-lachrymal secretion lying on the cornea, acting on the small pencil of divergent light thus allowed to fall upon it, which it converges sufficiently as (together with the refraction of the transparent media of the eye) to bring it to a focus on the retina, where are consequently produced as many multiplications of the image of the candle as there are globules.

2. *Spectra depending on corpuscles between the cornea and vitreous humor.* These also are ordinarily invisible to the naked eye; but their presence may be detected by the same method as was indicated for the muco-lachrymal spectrum, from which they may be distinguished by not suffering displacement or nictitation, by occupying a posterior plane in the field of view, and by the double images which these corpuscles form on exposing the eye to two divergent beams of light (as in Sir David Brewster's experiment with two candles), being less separated from one another than the double images of the muco-lachrymal spectrum. From corpuscles residing in the vitreous humor they will be distinguished by their occupying an anterior plane in the field of view, by their double images being more widely separated, and by the possibility of readily inverting their spectrum by simply carrying forward the convex lens (through which the candle is being viewed in the experiment) from the eye, so that the cornea is no longer within the focal distance of the lens. In this latter circumstance it would seem that if, by shifting the focus of the rays which impinge on the retina, we find that the corpuscles (the situation of which is the object of investigation) are at one time anterior and at another posterior to that focus, and their spectrum thereby inverted; this proves that they are situated in the anterior part of the eye; whereas if the spectrum cannot be thus inverted, the cause must reside in the vitreous humor.

3. *Spectra depending on corpuscles in or behind the vitreous humor.* These are of four different kinds, and may be seen by looking at the sky

through a pin-hole aperture in a card, or more distinctly by looking at the flame of a candle, two or three feet distant, through the eye-glass of a compound microscope. In this last experiment "four sets of spectra will be seen, independent of the muco-lachrymal spectrum. The most remarkable one appears nearest to the eye, and consists of twisted strings of minute pearly globules hung across the field of view; this I shall call the *pearly spectrum*. These strings are of various forms and lengths; they also vary in number, sometimes existing in such large quantity as to be troublesome in ordinary vision, giving rise to another form of muscæ volitantes, which appear usually as a thin cloud, somewhat like the wing of a fly, or as semi-opaque threads, like a spider's web, or of blackish soot-like particles, dancing before the eyes. Sometimes the threads terminate in a kind of bulb. The pearl-like globules, of which the threads are composed, vary in size, and seem joined together merely by apposition, without being contained in a tube.* The second in point of remarkableness, and the farthest from the eye, consist of watery-like threads, destitute of any globular appearance, and depending chiefly from the upper part of the field, easily seen at the lower part: this I call the *watery* spectrum, merely from its appearance, for I have ascertained neither its seat nor its nature. The depending threads of which this spectrum consist have a somewhat rounded appearance, differing in this respect from the pearly muscæ, the threads of which seem flat. Each of the watery threads is bounded by two dark lines, within which there is a broad space, which is clear and entirely destitute of anything like globules. These watery threads measure fully twice the diameter of the threads of the pearly spectrum. They are generally six or eight in number, not all situated in the same plane. Their general course is vertical, and generally flexuous: they often divide at their lower extremity, into two or more branches, which seem to melt away insensibly. They have so much the appearance, which streams of tears, flowing over the cornea, might be supposed to present, that they might be readily mistaken for them, but from their lying in a plane posterior to the muco-lachrymal spectrum. At first sight they seem to slide down slowly from the upper to the middle part of the field of view; but they possess neither the extent nor the quickness of motion of the pearly spectrum. Any bending or extending which they undergo in the movements of the eye is slight, and although seemingly displaced and broken into fragments by nictitation, they are not really so. This watery spectrum sometimes becomes much exaggerated, and then produces the sensation of muscæ volitantes in ordinary vision. It is frequently compared to the appearance of threads of spun glass, laid across each other, or to that of a fine lock of wool, and occasionally, by one or two forcible acts of nictitation, they may be dispersed. In two distinct planes between the *watery* and

* Dr. Mackenzie enters very minutely into the subject of the probable seat and cause of the pearly spectrum, and after analyzing at length the opinions of the various writers who have regarded the pearly corpuscles as situated on the surface of the cornea, within the aqueous humor, the imagined humor of Morgagni, the vitreous humor, the space between the hyaloid membrane and the retina, the retina and the choroid, he concludes that in all probability the vitreous humor is their seat, (which view is also entertained by Dr. Jago, and by others.) What the cause may be is still obscure; Dr. Mackenzie inclines to the notion that the contracted (or probably obliterated) capsular arteries which traverse the vitreous humor may contain arrested blood-globules, and so give rise to the appearance which the pearly spectrum presents; whilst Dr. Jago (London Med. Gaz., May 16, 1845) seems to regard them as caused by fringes or processes of the hyaloid membrane, or deposits within this membrane.

pearly spectrum are placed two sets of insulated globules, which I call the *insulo-globular* spectra. The globules composing the set farthest from the eye are hazy and ill-defined, and may be compared to small grains of sago; those nearest to the eye are clear in the centre, exterior to which they present a sharp black ring, and still more exteriorly, a lucid circumference. The above four sets of spectra never mingle with one another, so as to change the order in which they stand before the eye; but the pearly spectrum always appears the nearest; then the sharply defined insulo-globular; then the obscurely-defined globules; and, farthest away, the watery threads. That the corpuscles which produce these four sets of spectra are situated in or within the vitreous, and not, as DONNE (*Archives Gén. de Méd.*, t. xxii., p. 115) supposed, in the aqueous humor, is manifest from the fact that none of these spectra can be inverted by viewing them through a concave lens, or by first viewing them through a convex lens held close to the eye, and then carrying the lens forwards from the eye, so that the eye is beyond the focal distance of the lens, experiments which at once invert the muco-lachrymal spectrum, and would, it is presumed, do the same to any spectrum depending on the state of the aqueous humor of the crystalline.

4. The next variety of spectrum Dr. MACKENZIE describes is the *circulatory* one. It is frequently observed after sneezing, coughing, or any kind of straining, especially when performed with the eyes open, and appears in the form of numberless minute lucid points, darting about in all directions, an effect which Dr. MACKENZIE thinks may probably be due to the passage of blood-corpuscles through the vessels of the choroid.

5. His last variety is the *vascular* spectrum, a term applied to certain fixed muscæ, as those produced in PURKINJE's well-known experiment, in which the blood-vessels and central spot of the retina are brought into view, as also the numerous class of phenomena known by the names of *accidental colors* and *ocular spectra.* (*Kirke's Report in Ranking's Abstract*, vol. ii.)]

Treatment.—If muscæ volitantes be caused by vascular disturbance of the retina, it is not of a nature to require loss of blood. Without asserting that this cannot be necessary in any case, we may safely say, that in the majority of instances it is neither advisable nor admissible. Should the stomach and bowels be disordered, a dose of calomel and an aperient may be proper. We should then improve the general health by mild alteratives and aperients, attention to diet, and regular mode of living. If the nervous system is weakened, and if the patient is in bad health, and feeble, from confinement, sedentary occupation, unwholesome residence, and other debilitating influences, tonic and nervous medicines, such as bark, the vegetable bitters, valerian, ammonia, camphor, ether, with which conium or hyoscyamus may be combined; and moderate stimuli, whether medical or dietetic, with removal into pure air, will be of service. Where mental causes have been concerned in inducing the disease, change of occupation, as well as of air and scene, may be advantageous in combination with some of the former means.

Mr. WARE* has recommended local measures, such as fomentation of the eyes two or three times a day with warm water, or a warm infusion of chamomile flowers, or of the herb eyebright, and afterwards embrocation of the forehead, temples, and outside of the eyelids, with camphorated spirits, eau de Cologne, Hungary water, or some similar application.

* On the Muscæ Volitantes of Nervous Persons; in the Medico-chirurgical Transactions, vol. v., p. 273.

When the health is improved, the muscæ volitantes become fainter and less troublesome. They do not interfere with sight, and are only noticed under particular circumstances, or when attention is expressly directed to them. They do not usually disappear altogether. In three cases related by Mr. WARE, in the paper just quoted, the symptom of muscæ volitantes had existed to a troublesome extent, and had been relieved by suitable treatment. The patients were seen again at the end of ten, twelve, and twenty-five years, when the objects were still perceived, though only in strong light, or when the attention was directed to the subject. Vision had continued perfect.

HEMERALOPIA AND NYCTALOPIA.

The two states of vision, in one of which persons see imperfectly or are blind by night, and in the other, by day, might be properly denoted by the plain English words night-blindness and day-blindness, though they are more generally called by names derived from the Greek, viz., *hemeralopia* and *nyctalopia*. A great confusion has arisen in the application of these learned terms, each word being nearly as often used to express one affection as the other. HIPPOCRATES uses the term hemeralopia to denote night-blindness, and we may as well follow his example.

Night-blindness, or *hemeralopia*, (*caligo tenebrarum; dysopia tenebrarum.*)—Hemeralopia is that state of vision in which a patient sees well during the day, but imperfectly as twilight comes on; and, when the affection is fully formed, he loses his sight entirely at the approach of night, not being able to see a lighted candle brought close to the eye. In the commencement of the affection the person can see by moonlight, or when the room is lighted by a candle, but as it proceeds he can discern nothing after sunset: in the morning vision returns. There is no unnatural appearance in the eye: indeed, if a person can see perfectly during the day, the organ can have undergone no important change. There is a little increased irritability in the commencement, but as the affection proceeds, the pupil becomes rather dilated. It is said, that as the complaint goes on, the retina becomes at length completely insensible.

The duration of the disease varies from one night to six or twelve months, or even longer. More generally it lasts from two weeks to three or six months, when left to itself. Relapses are frequent, so long as persons remain exposed to the exciting cause.

The *cause* of this affection seems to be the exhaustion of the power of the retina by exposure to strong light during the day; hence night-blindness is only found in those places and climates where there is strong light, and is seldom seen except between the tropics. In these regions the full glare of a vertical sun in an unclouded sky, and the powerful reflection of the solar rays from the sea, or from a sandy soil, produce an excitement of the retina to which we are wholly unaccustomed in our latitudes, although in some parts of Europe analogous influences exist in a sufficient degree to cause the affection. After the retina has been so strongly excited in the day, the feeble light of night and twilight does not impress it sufficiently for perfect vision. Europeans often suffer from this cause in the West Indies, and more particularly those much exposed, as soldiers and sailors. The cases are especially numerous among the latter, and great numbers of a ship's crew often suffer.

[Hemeralopia is of rare occurrence in the United States, except in the extreme northern and southern portions; and according to Dr. Forry,

it "is nearly eleven times more prevalent in the latter than in the former. In Florida, however," he adds, "it may be regarded as endemic." (*Am. Journal Med. Sc.*, Ap. 1842, p. 318.)

This affection is more prevalent than is generally supposed, we have reason to believe, in very high latitudes where the sun during a portion of the year scarcely sets, and the light from this luminary is reflected from the snow and ice. Sailors who have been much exposed on watch, in these latitudes, are frequently affected. The peasants in the interior of Russia are also very subject to it; and this disease, Dr. MATHEW GUTHRIE states, is there called Kuritsha Slepota, or hen blindness. It most usually occurs during the harvest (in June and July,) at which period the sun dips but a very little below the horizon, and that for a short time. And he states that some hundreds of a Russian detachment, during the war in Finland, were affected with this disease. (*Medical Commentaries*, vol. xix., p. 284.)

Hemeralopia also sometimes occurs as a sympathetic affection, an interesting example of which is recorded by Dr. ALANCON, in the *Journ. des Connaiss. Med. Chirurg.* for Sept. 1835. The subject of it was a boy whose health in all respects appeared perfectly good, and no cause for the affection could be traced. During the day he saw as well as usual, but as evening set in his vision declined, and at night he became blind. Learning that he had been subject to worms, Dr. A. administered a large dose of oil, which brought away a number of these animals, after which his sight immediately improved, and in ten or twelve days was perfectly restored.]

The *prognosis* of the affection is quite favorable; it may exist for weeks or months, yet the organ will recover perfectly, even if left to itself. There is a good description of this night-blindness in the fifth volume of the *Medico-Chirurgical Transactions*, by Mr. BAMPFIELD,* who states that he observed about three hundred cases within a very short time, and in all of them the complaint ended without any permanent injury to vision.

In saying that hemeralopia is a complaint of hot climates, I did not mean to assert that it never occurs in other situations. Under some peculiar circumstances, it happens in countries situated beyond the tropics. There is an account in one of the periodical works, of its having prevailed extensively among some French troops stationed in Belleisle,† under a combination of local peculiarities, calculated to act powerfully on the retina, and at a season of the year favorable to their influence. A similar epidemic occurred among some Prussian soldiers stationed on the Rhine, in the summer of 1834.‡ In all the cases which I have seen, the affection has commenced in the East or West Indies, and been brought to England.

If the complaint will run its course, and come to an end without injuring the organ, it cannot be necessary to adopt any powerful treatment. Mr. BAMPFIELD had an opportunity of trying various proceedings, and he says, in his essay, that what he ultimately found the most advantageous, was, in addition to the use of aperient medicine, the application of blisters to the temples: they very much abridged the duration of the complaint. In the few instances which I have met with, I have adopted the same practice; with the addition, in one or two instances, of previously taking some blood

* *A Practical Essay on Hemeralopia or Night-blindness, commonly called Nyctalopia.*

† R. DE HAUTESIERK, *Recueil d'Obs. de Medecine des Hôpitaux Militaires*, tom. ii. and iii. He represents that the complaint is common in Belleisle, a dry and hot situation. Bleeding, vomiting, and purging, followed by blisters, constituted the most successful treatment.

‡ *Dublin Journal of Medical and Chemical Science*, vol. viii.

by cupping, from the temples or nape of the neck. With such treatment the complaint has readily given way.

[Dr. W. L. Wharton, of the U. S. Army, relates in the *American Journal of the Medical Sciences*, several cases which were cured simply by exclusion of light. One of these was of three months' duration. The cure was effected in from 24 to 60 hours.

Dr. Charles Kidd states, that he cured two cases which had proved refractory to various remedies, by turpentine, given in the following combination: R.—Ol. terebinth., ol. ricin., āā ℥j; mist. camph. ℥iv; liq. potassæ ʒj; tr. opii gtt x. Ft. Mist. A large tablespoonful every morning and night. (*Dublin Med. Press*, May 10, 1843.)

Mr. Roussilhe says that he has effected a speedy cure of this disease, in numerous instances, by cauterizations with nitrate of silver around the margin of the cornea. (*Journ. de Med. de Bordeaux*, Sept. 1845.)

Mr. W. B. Page has resorted to the use of mercury with advantage in this disease. He reports in the *Provincial Medical and Surgical Journal*, (April 8th, 1846,) two cases of hemeralopia occurring in boys, aged 14 and 15 years, piecers in a cotton factory. This occupation consisted in constantly watching an extended surface of white cotton threads passing before them, in order that they might join those which became broken in this part of the process of cotton spinning. They were both treated with blue pill, gr. v., night and morning, with carbonate of iron, ʒss, three times a day. Amendment commenced as soon as the system became under the influence of the mercury, and both were cured.]

Congenital and hereditary hemeralopia.—In some rare instances night-blindness has been seen as a congenital affection.

H. C. E. Richter has related three cases of congenital hemeralopia, which occurred in a family of nine, the other six children and the parents being free from all defect of sight. The circumstance was first observed when the children began to go alone; they moved about very well in the day, but were quite unable to find their way as twilight came on. When the account was drawn up, they had reached the age of from twenty to thirty without any alteration in the state of sight. The eyes presented their normal appearance; and there was nothing unusual in the movements of the iris or state of the pupils, except that the latter were rather dilated at night. These persons saw well in the daytime, but very imperfectly at night, though they were not absolutely blind. They saw in strong moonlight or candlelight, but not well. One of them had never seen any stars, another only seven; but the sight of the third was rather better.*

Dr. Cunier, of Ghent, has lately recorded a unique and very remarkable example, in which this disease, probably congenital in the first instance, has been transmitted by hereditary descent through six generations. At the hospital St. Eloy, Montpellier, Dr. Cunier saw a young conscript, who claimed exemption from military service on the ground that he could not see at night. It had been supposed that the complaint was feigned; but Dr. C. found on careful examination, that this was not the case. The iris was motionless, even in the strongest light; and the pupil, when examined with a magnifying power, was hexagonal. The pupil was smaller in the evening, and there was an appreciable motion of the iris when a light was brought into the room. This young man represented that he belonged to a family in which many individuals were hemeralopic; and Dr.

* *Diss. inaug. exhibens tres Hemeralopiæ s. Cæcitatis nocturnæ casus: Jenæ*, 1828; in Radius, *Script. Ophthalm. Minor.*, vol. iii.

Cunier repaired to the commune of Vendémian, near Montpellier, to inquire into the circumstances. According to received tradition, the affection began with a certain Nougaret, surnamed the Provençal, from whom it was propagated, by means of his descendants, not only in Vendémian, but in neighboring places where it had never been seen except in individuals of this race. Dr. Cunier was accompanied by a gentleman skilled in antiquarian researches, who drew up a genealogical table of Nougaret and his descendants.

From this table, which is nearly seven feet long, and appended to the pamphlet of Dr. Cunier, we learn the following particulars. In the first generation, consisting of three persons, a daughter and two sons of Nougaret, all were hemeralopic. The second generation included 16 individuals, of whom 10 were hemeralopic; in the third generation, there were 14 out of 81; in the fourth, 23 in 208; in the fifth, not yet completed, 24 in 218; in the sixth, including 103 persons, there are 11.

Among more than 600 individuals who have descended during the last two centuries from Jean Nougaret, of whom from $\frac{1}{7}$ to $\frac{1}{8}$ have been hemeralopic, there is not a single example of the affection in the children of parents who were themselves free from it.

The hemeralopia has been transmitted in this family more by the women than by the men. Of 41 descendants from Elizabeth Gineste, 24 were affected, though in the fourth, fifth, and sixth generations, to whom these belonged, the general proportion was not more than $\frac{1}{9}$.

Dr. Cunier observed nothing very remarkable in the eyes of those whom he examined. The pupil was regular, but very large, and did not contract even on exposure to the ardent mid-day sun of Languedoc. Those affected with it see at night by the help of lights, and sometimes under very brilliant moonlight. The light then produces a winking, the pupil contracts, and objects are gradually seen better. Sight, however, is still confused. If they go into a cellar by day they lose their sight. The pupil contracts a little at night, and a motion of the iris can then be seen on sudden exposure of the organ to strong light.*

Day-blindness; nyctalopia.—The opposite state to the former, or blindness during the day, is called *nyctalopia.* There are many states of the organ in which vision is imperfect, even to blindness, in the strong light of day, and much better sight is enjoyed in twilight and the dusk: but I have not seen this as an amaurotic affection, or a condition of sight opposite to the preceding, dependent on disease of the retina or optic nerve.

In central leucoma of the cornea, in central lenticular cataract, in incipient opacity of the lens, in central opacity of the capsule, in contractions of the pupil from prolapsus iridis or adhesion of the pupillary margin, connected with either of the former circumstances, the patient will see best in a weak light, and find vision very imperfect in a strong glare. The enlargement of the pupil in the former, and its contraction in the latter state, sufficiently account for this difference. On the same ground sight is much improved in some of these circumstances by the use of belladonna.

In strumous ophthalmia the intolerance of light often amounts to blindness during the day; while the symptoms remit in the evening, when the eyes are opened, and the patient sees well. Unnatural sensibility to light, and consequent photophobia is the form which sympathetic affection of the retina sometimes assumes. Persons thus affected may be able to see well in dull lights.

* *Histoire d'une Héméralopie héréditaire depuis deux siècles dans une famille de la commune de Vendémian, près Montpellier, par* F. Cunier, M. D., in the *Annales de la Société de Médecine de Gand,* 1840.

The Albinoes are nyctalopic; the absence of pigmentum nigrum renders them acutely and almost morbidly sensible to light; they are hardly able to open their eyes in a strong sunshine; they contract their brows, and keep the palpebræ almost closed during the day, and when twilight comes they are able to see distinctly.

Such are the only forms of nyctalopia which I have seen. I never saw a case in which it existed, as an amaurotic symptom, to the degree of vision being perfect in the night or even twilight, and lost during the day, as we see the converse in hemeralopia.

["Among the few original observations," Mr. MACKENZIE remarks, (*Practical Treatise*, pp. 821–2,) "tending to establish the fact of there being such a disease as a periodic amaurosis, which makes its attack through the day, and departs at night, may be quoted the following from RAMAZZINI.

"'I have repeatedly observed,' says he, 'among our country people, and especially in boys, a thing sufficiently strange. In March, about the equinox, boys about ten years of age were affected with a great degree of weakness of sight, so that through the whole day they saw little or nothing, and wandered about the fields like blind people; but when night came they saw again distinctly. This affection ceased without any remedy, and by the middle of April, the patients were completely restored to sight. I frequently observed the eyes of these boys, and found the pupils much enlarged.'" (*De Morbis Artificum*, cap. xxxviii.; *Opera*, p. 363; *Londini*, 1718.)

"A gentleman related to Dr. GUTHRIE that he had witnessed the following example of day-blindness. Whilst in garrison in Landau, in Alsace, in the summer of 1772, two hundred men of the regiment of Picardie were seized with a species of blindness during the meridian splendor of the sun, and could not see their way when it was not overcast, insomuch that when they had strolled out into the fields during a cloudy day, if the sun suddenly shone out, they were absolutely obliged to be led by their companions till a cloud once more obscured the solar light, and enabled them to pursue their course. (*Duncan's Medical Commentaries*, vol. xix., p. 290; Edinburgh, 1795.)

"These instances look like an endemic or epidemic day-blindness; but are evidently too vague to furnish grounds for any general conclusions.

"BARON LARREY has recorded a remarkable case of sporadic day-blindness, occurring in an old man, one of the galley-slaves at Brest, who had for thirty-three years been shut up in a subterraneous dungeon. His long residence in darkness had had such an effect on the organs of vision, that he could see only under the shade of night, and was completely blind during the day. (*Mémoires de Chirurgie Militaire*, tome i., p. 6; Paris, 1812.)

"Another case, connected with a venereal taint, and cured by mercurial frictions, is related by Mr. ISBELL." (*Edinburgh Medical and Surgical Journal*, vol. ix., p. 269. Edinburgh, 1813.)]

[*Hemiopia*, from ημισυς *half* and οψις *vision*, or that form of partial blindness, in which the patient is able to see only the half of objects, may affect one or both eyes. Sometimes it is the right, and at others the left half of objects which can only be seen; again it may happen, Dr. MACKENZIE observes, "that the upper or the lower half of the field of vision may appear dark, or that the patient, looking directly forwards, may see tolerably well within a certain angle, but nothing to either

side. These latter varieties of hemiopia are less common than that in which the right or the left half of each retina appears to be insensible to light, but are not less worthy of attention." (*Practical Treatise*, p. 822.)

Hemiopia is apt to be sudden in its attacks and to recur at considerable intervals of time.

Dr. Wollaston attracted considerable attention to this affection, by the publication of an account of two attacks of it which he himself experienced, and of some cases of it which he met with in others. (*On the semi-decussation of the optic nerves. Philos. Trans.* for 1824.)

"It is now more than twenty years," says he, "since I was first attacked with the peculiar state of vision to which I allude, in consequence of violent exercise I had taken for two or three hours before. I suddenly found that I could see but half the face of a man whom I met; and it was the same with respect to every object I looked at. In attempting to read the name Johnson, over a door, I saw only son; the commencement of the name being wholly obliterated to my view. In this instance the loss of sight was toward my left, and was the same whether I looked with the right eye or the left. This blindness was not so complete as to amount to absolute blackness, but was a shaded darkness without definite outline. The complaint was of short duration, and in about a quarter of an hour might be said to be wholly gone, having receded with a gradual motion from the centre of vision obliquely upwards towards the left.

"Since this defect arose from over-fatigue, a cause common to many other nervous affections, I saw no reasons to apprehend any return of it, and it passed away without any need of remedy, without any farther explanation, and without my drawing any useful inference from it.

"It is now about 15 months since a similar affection occurred again to myself, without my being able to assign any cause whatever, or to connect it with any previous or subsequent indisposition. The blindness was first observed, as before, in looking at the face of a person I met, whose *left* eye was to my sight obliterated. My blindness was in this instance the reverse of the former, being to *my right* (instead of the left) of the spot to which my eyes were directed; so that I have no reason to suppose it in any manner connected with the former affection.

"The new punctum cæcum was situated alike in both eyes, and at an angle of about three degrees from the centre; for when any object was viewed at the distance of about five yards, the point not seen was about ten inches distant from the point actually looked at.

"On this occasion the affection, after having lasted with little alteration for about 20 minutes, was removed suddenly and entirely by the excitement of agreeable news respecting the safe arrival of a friend from a very hazardous enterprise."

In consequence of reflecting on these attacks of hemiopia, Dr. Wollaston was led to adopt the following hypothesis regarding the arrangement of the optic nerve, the hypothesis, in fact, of Sir Isaac Newton.

"Since the corresponding points of the two eyes," says he, "sympathize in disease, their sympathy is evidently from structure, not from mere habit of feeling together, as might be inferred, if reference were had to the reception of ordinary impressions alone. Any two corresponding points must be supplied with a pair of filaments from the same nerve, and the seat of a disease in which similar parts of both eyes are affected, must be considered as situated at a distance from the eyes at

some place in the course of the nerves where these filaments are still united, and probably in one or the other thalamus nervorum opticorum.

"It is plain that the cord, which comes finally to either eye under the name of optic nerve, must be regarded as consisting of two portions, one half from the right thalamus, and the other from the left thalamus nervorum opticorum.

"According to this supposition, decussation will take place only between the adjacent halves of the two nerves. That portion of nerve which proceeds from the right thalamus to the right side of the right eye, passes to its destination without interference; and in a similar manner the left thalamus will supply the left side of the left eye with one part of its fibres while the remaining halves of both nerves in passing over to the eyes of the opposite sides must intersect each other, either with or without intermixture of their fibres.

"Now, if we consider rightly the facts discovered by comparative anatomy in fishes, we shall find that the crossing of the entire nerves in them to the opposite eyes, is in perfect conformity to this view of the arrangement of the human nerves. The relative position of the eyes to each other in the sturgeon, is so exactly back to back, on opposite sides of the head, that they can hardly see the same object, they can have no points which generally receive the same impressions, as in us; there are no corresponding points of vision requiring to be supplied with fibres from the same nerve. The eye which sees to the left has its retina solely upon its right side; and this is supplied with an optic nerve arising wholly from the right thalamus; while the left thalamus sends its fibres entirely to the left side of the right eye for the perception of objects situated on the right. In this animal an injury to the left thalamus might be expected to occasion entire blindness of the right eye alone, and want of perception of objects placed on that side. In ourselves, a similar injury to the left thalamus would occasion blindness (as before) to all objects situated to our right, owing to insensibility of the left half of the retina of both eyes."

Having thus explained his hypothesis, Dr. Wollaston goes on to relate the following additional instance of hemiopia.

"A disorder" says he, "that has occurred within my own knowledge in the case of a friend, seems fully to confirm this reasoning, as far as a single instance can be depended upon. After he had suffered severe pain in his head for some days, about the left temple, and toward the back of the left eye, his vision became considerably impaired, attended with other symptoms indicating a slight compression on the brain.

"It was not till after the lapse of three or four weeks that I saw him, and found that, in addition to other affections which need not here be enumerated, he labored under a defect of sight similar to those which had happened to myself, but more extensive, and it has unfortunately been far more permanent. In this case the blindness was at that time and still is entire, with reference to all objects situated to the right of his centre of view. Fortunately, the field of his vision is sufficient for writing perfectly. He sees what he writes, and the pen with which he writes, but not the hand which moves the pen. This affection is, as far as can be observed, the same in both eyes, and consists in an insensibility of the retina on the left side of each eye. It seems most probable that some effusion took place at the time of the original pain on that side of the head, and has left a permanent compression on the left thalamus. This partial blindness has now lasted so long without sensible amendment, as

to make it very doubtful when my friend may recover the complete perception of objects on that side of him."

Dr. Wollaston gives in the same paper the following account of another case of this disease.

"One of my friends," says he, "has been habitually subject to it for sixteen or seventeen years, whenever his stomach is in any considerable degree deranged. In him the blindness has been invariably to his right of the centre of vision, and from want of due consideration, had been considered as temporary insensibility of the right eye; but he is now satisfied that this is not really the case, but that both eyes have been similarly affected with half-blindness. This symptom of his indigestion usually lasts about a quarter of an hour or twenty minutes, and then subsides, without leaving any permanent imperfection of sight."

Dr. Wollaston died about four years after the publication of the paper from which these extracts are taken. In the account which has been published of the appearances observed on inspecting his body, it is stated, that the optic thalamus of the right side was of an unusually large size, and that on making a section of it, little or no vestige of its natural substance was perceptible, with the exception of a layer of medullary substance on its upper part. It had been converted into a tumor, as large as a middle-sized hen's egg, towards the circumference of a grayish color, and harder than the brain itself, somewhat of a caseous consistence, but in the centre of a brown color, soft, and in a half-dissolved state. This diseased structure was not confined to the thalamus, but extended to the neighboring portion of the corpus striatum. The right optic nerve, where it passes on the outside of the thalamus, was of a brown color, more expanded, and softer than natural. (*London Medical Gaz.*, vol. iii., p. 293.)

"The reader will readily perceive," Dr. Mackenzie observes, "that between this state of the brain and the previous symptoms of hemiopia, there may or may not have been a connection; for there were two distinct attacks of the disease, at the interval of twenty years, each attack subsiding entirely after fifteen or twenty minutes, in the first attack objects to the left appearing dark, and in the second, those to the right. We know that morbid alterations in the substance of the brain often produce periodic diseases, and that certain additional causes of excitement operating upon an unsound brain, one or the other of the functions of that organ are for a time impeded, till the new cause ceases to operate, when the individual immediately returns to his former state of apparent health. (*Practical Treatise*, p. 826–7.)

An interesting case of hemiopia, in a person affected with slight hemiplegia of the left side, is related by Dr. Crawford. The patient regained the use of her limbs, but from the time of her seizure till her death, about five years afterwards, when she looked at an object, she could see distinctly only the one half of it which was towards her right hand, the other being very obscure. This was equally the case, whether she looked with both eyes, or only with the right one, but when she looked with her left only, the obscurity was greater. When four fingers were held before her, she could see two of them distinctly, the third she could distinguish, but could not see plainly; and the fourth she could not see at all. When she looked at three fingers, she could see two of them pretty plainly—the first, however, plainer than the second, the third she could not distinguish at all. When she looked at two fingers, she could see only one distinctly.

After she had recovered so as to be able to get out of bed, it was dis-

covered that, although she could see only half of an object plainly, when held directly before her, yet if it was moved towards her right hand, and she continued to look straight forward, she could see the whole of it distinctly. On the contrary, if it was moved toward her left hand, keeping her eyes fixed as before, she could not perceive any part of the object.

It should be remarked, that it was the motion of the left side of the body that was impaired, yet it was the right half of each retina which was insensible. (*London Med. and Phys. Journal*, liii., 48.)

Another case of hemiopia is related by Mr. LAWRENCE. See p. 526 of this work.

In reflecting on Dr. WOLLASTON's paper, the following remarks, Dr. MACKENZIE states, have occurred to him.

1. "The notion of a semi-decussation of the optic nerves had not merely been entertained by several distinguished authors,* before Dr. WOLLASTON, but had in some measure been demonstrated by dissection.† Even the idea that the two portions, of which each optic nerve may be regarded as consisting, remain distinct, after they form the retina, appears to belong to Sir ISAAC NEWTON. It is supported, however, by Dr. WOLLASTON, by an argument which is new, and probably without foundation; namely, that any two corresponding points of the two retinæ must be supplied with filaments either from the right or from the left optic nerve, and that upon this depends their correspondence. Dr. WOLLASTON appears to have overlooked the fact, that as the optic nerves pass through the sclerotica and choroid considerably nearer the middle line of the body than the centre of the globe of each eye, the two optic axes, which if any points deserve to be considered as such, are surely corresponding points, will not be formed by filaments from the same nerve, but from opposite nerves. It has always occurred to me as more probable, that the two portions of which each optic nerve consists, mingle their fibres, and then expand into the retina, so that the membrane in each eye should be regarded as a plexus, every point of which contains fibres derived from each side of the brain.

2. "It is not, however, by mere reasoning upon a subject like this, that we can arrive at any sound conclusion. By far the greater part of the mass of facts, in pathological and in what may be called experimental anatomy touching this question, go to prove, that injuries and diseases affecting one side of the brain, instead of hemiopia in both eyes, produce amaurosis only in the opposite eye.‡ The fact, also, which has been already mentioned in the beginning of this section, that we meet with a horizontal as well as a perpendicular hemiopia, appears scarcely reconcilable to the hypothesis of Dr. WOLLASTON. Not so, however, that other variety of the disease, in which objects to each hand appear dark, and those only which are placed in front are seen distinctly; for were any tumor or excrescence to press on the anterior edge of the chiasma of the optic nerves, the effect would be, according to the hypothesis of semi-decussation, to paralyze the inner half only of each retina. I had under my care a patient with amaurosis of the inner half of each retina, attended with total loss of the sense of smell, and an imperfect sense of taste. He presented no other signs of cerebral disease, and I thought it probable that the imperfection in taste was owing to the loss of the power of smell,

* NEWTON, VATER, ACKERMANN, VICQ. D'AZYR, CALDANI, CUVIER, &c.

† JOSEPHUS et CAROLUS Wenzel de Penitiore Structura Cerebri, pp. 109, 333. Tab. vi., fig. 1. Tubingæ, 1812.

‡ SERRES, Anatomie Comparée du Cerveau, tom. i., p. 331. Paris, 1827.

and that this, along with the hemiopia, was owing to some pressure on the optic nerves, immediately anterior to their union, and on the olfactory nerves." (*Practical Treatise*, p. 826–7.)

The *treatment* of hemiopia must be conducted in reference to the cause by which it is produced. If resulting from cerebral congestion, general or local detraction of blood, with revulsives &c., may be demanded. A frequent cause is disorder of the digestive organs, and of course, remedies appropriate for the correction of the particular derangement must be employed.]

Want of power to distinguish colors.—Some individuals are naturally unable to distinguish colors, and to judge of their relations. In rare cases this defect embraces all colors, so that a colored drawing or painting seems all of one tint; the objects are clearly seen, the light and shadow are understood, but the differences of color are not perceived. Some persons can only distinguish certain colors, and refer the others to one or other of these. Thus a person could perceive only red, yellow, and purple in the rainbow. Some are unable to distinguish one or two colors; red and green, for example, are commonly confounded in these cases. The eye has its natural appearance, and vision is perfect in all other respects.

This incapacity of distinguishing colors, which is an original defect, frequently exists in several members of the same family.

In a person named Harris, the defect was first observed at four years of age; he could not distinguish the fruit from the leaves of a cherry-tree by their color; nor could he understand why a stocking was called red; though he saw objects as well and at as great a distance as others, when the distinction did not depend on color. The gentleman who gives an account of this individual in the *Philosophical Transactions*, vol. lxvii. art. 14, says, "I believe he could never do more than guess the name of any color; yet he could distinguish white from black, or black from any light or bright color. Dove or straw color he called white, and different colors he frequently called by the same name; yet he could discern a difference between them when placed together. In general, colors of an equal degree of brightness, however they might otherwise differ, he frequently confounded together. Yet a striped riband he could distinguish from a plain one, but he could not tell what the colors were with any tolerable exactness. Dark colors in general he often mistook for black, but never imagined white to be a dark color, nor a dark to be a white color." He had two brothers, whose perception of colors was imperfect like his own, and two other brothers and sisters, who, as well as their parents, were free from this defect; one of the first-mentioned brothers pronounced an orange riband to be the color of grass, green. When asked whether the various colors were mere differences of light and shade, various degrees between white and black, he replied no, but with some hesitation.

In an instance recorded in the subsequent volume of the *Transactions*, art. 27, the defect was not so general. The relater, describing his own infirmity, says, "I do not know any green in the world; a pink color and a pale blue are alike; I do not know one from the other. A full red and a full green the same; I have often thought them a good match; but yellows (light, dark, and middle), and all degrees of blue, except those very pale, commonly called sky, I know perfectly well, and can discern a deficiency in any of those colors, to a particular nicety. A full purple and a deep blue sometimes baffle me." He adds, "It is a family failing; my father has exactly the same impediment; my mother and one of my sisters were perfect in all colors; my other sister and myself alike imperfect; but she has a daughter who is very perfect. I have a son and daughter, who both

know all colors without exception; and so did their mother. My mother's own brother had the like impediment with me, though my mother, as mentioned above, knew all colors perfectly well."

In the seventh volume of the *Medico-Chirurgical Transactions*, Dr. NICHOLL has related the case of a boy, eleven years old, who has this defect. "He does not call any color green. Dark bottle green he calls brown. Light yellow he calls yellow; but darker yellows and light browns he confounds with red. Dark brown he confounds with black. Pale green he calls light red; common green he terms red. Light red and pink he calls light blue; red he calls by its proper name. On looking through a prism, he said he could discover no color but red, yellow, and purple. I showed him paper stained with red radish root; this he said was blue; I dipped this paper in diluted nitrous acid, which converted the pale red color into scarlet; he then called it red. I placed this scarlet color by the side of paper stained with litmus; he said that both colors were the same, but that the litmus paper was a lighter shade than the other. I then placed the scarlet paper on the grass, and afterwards on green baize: he said that the grass and the baize were the same color as the paper, but that they were a shade lighter. I made him put on a pair of green spectacles, which he called red glasses; he said that everybody and everything in the room had a reddish cast when seen through them." (*Page* 477, 478.) This boy has four sisters, who, with his mother and her sister, are free from the defect, which, however, exists in his maternal grandfather. The latter gentleman, being in the navy, purchased a blue coat and waistcoat with red breeches to match the blue. He, as well as his grandson, seems to have no perception of green. He had two brothers and three sisters; the defect existed in one brother, the other and the sisters being free from it. His brother has mistaken a cucumber for a lobster, and a green leaf for a stick of red sealing wax.

A gentleman, who has detailed the circumstances of his own case in the *Glasgow Medical Journal*, vol. ii. art. 2, seems to be most deficient in the distinction of reds and greens. He can distinguish dark green and dark purple; but pale green, pink, and pale blue, all appear to him the same color. He says, "I cannot perceive a bit of red sealing-wax, if thrown down upon the grass, nor a piece of scarlet cloth hung upon a hedge, till I am almost near enough the latter to touch it; although in one instance, which I particularly remember, this was so conspicuous to ten or twelve other persons as to be distinctly visible to them a mile off. I once gathered some lichen, as a great curiosity, from the roof of a fishing-house, situated on the estate of a friend. This lichen appearing to me of a bright scarlet, from the circumstance of its seeming to be of the same color as the roof of the house, which was composed of fancifully shaped tiles; in reality the lichen was of a bright green, and the tiles of an unusually brilliant red.

The communication to the Glasgow Journal, by Dr. COLQUHOUN, in which the preceding account is found, contains a minute history of another instance, in which the defect is particularly observed in regard to red and green, more especially the latter.

This peculiarity, which is an original defect, and not a pathological condition, depends, according to the opinion of Drs. GALL and SPURZHEIM, on the sensorium. They conceive that the function of the eye is limited to the receiving certain impressions, but that the judging of these impressions, the power of understanding the relations which colors bear to each other, is the function of the sensorium; and they assign this faculty to a particular part of the brain. It is certain that an eye may be excellent for the general purpose

of vision, and capable of distinguishing the minutest objects, and yet the individual may not be able to judge of colors. The latter power, with the accurate perception of the harmony of colors, and their various relations to each other, is a higher endowment; indeed, only a few persons possess it eminently. Some can draw correctly, can take a portrait very well, although, if they attempt to color, they fail entirely. We even find that among the great painters, only a few have attained the reputation of thoroughly understanding the subject of color, and have been able to reduce that knowledge to practice in their art.

In the case of an original defect, and one probably seated in the organization of the brain, we can afford no remedy: indeed the matter is only mentioned now, in order to show the difference between this natural peculiarity and pathological states of the eye.

[Inability to distingush colors, hitherto supposed to be always an original defect, we have observed to occur, also, as a pathological condition. A case of this kind was reported by us in the *American Journal of the Medical Sciences* for August, 1840. We shall here relate this case, with some inferences relative to the laws which govern this defect, to which we have been led by a comparison of the various cases of it which have been recorded.

Mary Bishop, 20 years of age, unmarried, a segar maker, was admitted into Wills Hospital Feb. 9th, 1839. She stated that she had suffered, previous to admission into hospital, two attacks of cerebral disease, one in the spring of 1837, the other in the winter of 1837–38. After recovery from the first attack, objects for a time appeared to her double. The second attack left her entirely blind, in which condition she continued for four months. After this her sight began to return, and at the period of her admission into the hospital she could read large print, as the heading of a newspaper. She was of a short, robust stature, full habit, very dark complexion, black hair and hazel irides, flushed face, color of her cheeks at times almost of a purplish hue; catamenia suppressed. When she first came under my notice, which was in May, 1839, she had been largely depleted and had taken remedies for the restoration of the menstrual discharge, under the direction of my friend and colleague Dr. Fox, under which treatment her sight had improved.

Whilst examining her at this time to ascertain the degree of vision she possessed, her reply to one of our questions led us to suspect that she was unable to distinguish colors. When asked whether she could see the figure in her dress, which was a calico one with red spots, she replied "Yes, I see the brown spots." Our attention thus directed to the subject, we soon ascertained that while she could distinguish forms, even of small size, with accuracy, her perception of colors was exceedingly imperfect. Repeated and careful investigations during this and on several subsequent occasions, satisfied us that the only colors which she knew with certainty were *yellow* and *blue*. Nearly all other colors she termed brown, or hesitated to name, designating, however, their shades or intensity of color accurately. Thus a deep red she called a dark brown, a bright green a light brown, and a very pale pink a very light shade of brown.

We exhibited to her, both by day and by candle-light, a number of colors, and have them now in our possession, with the names she bestowed on them. With the exception of yellow and blue all the other colors were named with much hesitation, and some only after our insisting on her doing so, and she then manifestly named them by guess. We abstain from giving the details because we are satisfied they lead to no

further useful results than to prove that she could not distinguish other colors than the two just mentioned. On one occasion our friend, Professor A. D. Bache, visited the patient with us, and with a view of comparing her defect of vision with that of Mr. Dalton of Manchester, exhibited to her a number of fabrics of various colors, which he had received from that distinguished chemist, with their names, as they appear to him, attached. Nothing new or worth recording was elicited by this experiment, unless the following circumstance, which for a moment greatly perplexed us, be considered as such; and it is so, perhaps, in one point of view, as showing how careful it is necessary to be in similar investigations to avoid being deceived. After manifesting her inability to distinguish correctly any except two colors, she surprised us by naming accurately the color of some red silk, and which she had previously misnamed. A bunch of red cotton, however, shown her immediately afterwards, she termed brown. On inquiring why she termed the first red, she said she had "discovered some days before that red produced sparkles before her eyes." Suspecting from this she had been somehow led to connect glossiness with red, I called her attention to some bright, glossy *green* silk, which she promptly called red. When these same articles where shown her in such a light that she could not perceive their gloss, she miscalled them as usual. How the patient came to connect glossiness with a color we could not discover, but as her defect was at this time known through the house it is probable that some one had shown her a glossy red and given her its name.

The patient was not at all sensible, when we commenced the investigation of her case, that she labored under any particular defect in distinguishing colors. She had noticed, she said, however, that grass and roses did not appear as they formerly did to her; the latter especially, did not seem of their natural color; but as her sight was imperfect she considered this as a natural consequence. She remembered, when questioned, that as her sight began to return, *the first color she perceived was yellow.* This fact is of much interest, and she stated it with a degree of confidence, and mentioned some particulars which lead us to believe it to have been the case. She asserted most positively also that she had formerly been as well able to distinguish colors as any other person.

With a view to a revulsive action on the brain, and also to re-establish the catamenial flow, the patient was ordered pills of blue mass, rhubarb and aloes, every alternate night, in a dose to purge actively; mustard pediluvia at bed-time, and a blister to the sacrum. Two days before her regular period I ordered, in addition, mustard cataplasms to be applied nightly to the inside of her thighs, and the same, diluted with an equal part of flour, to her mammæ.

On the 29th of May her catamenia appeared and flowed copiously, but continued only for a single day. It was followed, however, by very marked improvement in vision. She stated to me at my visit on the 31st of May, with much satisfaction, that the roses now appeared to her of their natural color, and that she could distinguish the difference between the color of the rose and of the leaves of the bush, which she had not previously been able to do. Roses of different colors being presented to her she named them all correctly; she could also distinguish quite small letters distinctly, but not more than three at one time—her field of vision seemed limited.

On the first of June Dr. Fox took charge of the hospital, and from this period until the commencement of my regular term of service in October following, I saw the patient only at considerable intervals. During this

time her sight improved and with it her ability to distinguish colors. By the middle of June she was able, she said, to see the eye of a needle and the end of a thread, but could not thread a needle from inability to see both at the same time. At this period Mr. Bache again visited Mary with me and exhibited to her the prismatic spectrum. She distinguished pretty accurately the yellow, blue, green and red. The orange she hesitated about, and the violet she could not name. The colors were shown her together and separately: under the two circumstances she said they appeared somewhat different. Her retina on this, as on former occasions, seemed soon to become weakened by use. She would gaze at a color for some time before naming it, and, when looking from one color to another, the impression of the first seemed to remain on the retina and for a time to confuse her perception of the second. To avoid fatiguing the eye by too much exercise and to insure the accuracy of our observations, it was necessary on all occasions to conduct the experiments slowly and at intervals, and with great care and caution.

On the first of October, when the patient again came under my care, her vision was in the state just described, but her catameniæ were still suppressed, and she was subject to occasional attacks of fullness of the head, during which her sight somewhat diminished. She also suffered during the early part of this month from attacks of dyspnœa, which came on every morning before dawn and continued for an hour or two.

October 18th. For the last three days she has suffered much from fullness of the head. Face flushed; pulse active. Ordered v. s. ℥xvj, and to be purged with senna and salts. These remedies entirely relieved her head, and on the 22d of October she was free from all uneasiness, and could distinguish the different colors in a dress readily, and also small letters. She was now ordered mustard cataplasms to inside of her thighs, to sacrum and mammæ, and mustard pediluvium at bed-time, with a view to a restoration of her catamenia.

25th. Fullness of head; has had a return of dyspnœa; costive; sight not so good. Ordered cups to sacrum; to be purged briskly; mustard pediluvia. These relieved the head, but the period passed off without any catamenial flow.

30th. Feels quite well. Sight good; can read readily the small print of a newspaper. Distinguishes all the primitive colors readily and names most of the secondary ones as correctly as could be expected from one of her moderate intelligence, with the exception of violet; this last she seems always at a loss to name.

She would now have been discharged but for her earnest request to be allowed to remain in the hospital one month more, that another effort might be made for the restoration of her catamenia. It would be uninteresting to detail the treatment to which she was subjected during this month and which failed in producing the desired effect.

November 30th. Discharged this day, with her vision restored, and in good health, the catamenia, however, still suppressed.

This is, we believe, the first example hitherto recorded of this inability having resulted from disease, or being coexistent with it.* As a natural

* A case related by Mr. Mayo, of retinitis caused by a stroke of lightning, is quoted at page 463, in which it is stated that the patient lost the power of distinguishing colors. But the details of the case in regard to this particular are so few and imperfect, that Mr. Lawrence has entirely overlooked the feature of it, as it was also by ourselves at the time we drew up the above account. Mr. Mayo does not seem to have inquired whether the defect was actually the consequence of the disease or had previously existed.

defect, the power of distinguishing forms being perfect, it is not rare. Several instances of this have come under our own observation, and not a few others have been mentioned by writers. Such of these last as have been recorded with sufficient details to furnish data for comparison, viewed in connection with the case we have recorded, lead to conclusions which it may not be uninteresting to notice.

1. As a natural defect, inability to distinguish colors may exist in different degrees.

2. In the worst degree, the individual is able merely to distinguish shades,—the perception of color is entirely absent. Examples of this are afforded in the two Harris's, who could distinguish a striped riband from a plain one, but could not perceive the difference between any one color and another, except as darker or lighter,* in Dr. ELLIOTTSON's second case,† and a man named Collardeare, the subject of a case quoted by ROSIER.‡

3. In the next degree the individual can distinguish only a single color, and that color is always yellow. Thus Dr. BUTTER states that Robert Tucker knew to a certainty *yellow* only;§ and it appears that the boy whose case is recorded by Dr. NICHOLL‖ was in the same condition.¶ Now it may be called to mind that Mary Bishop stated when her sight improved the first color she recognized was yellow.

It may be mentioned here as connected with this subject, that we noticed a similar phenomenon in the case of a lady whom we attended for amaurosis in the winter of 1837–8. This patient, who was quite blind, began to recover her sight, and among the early evidences of improvement she mentioned, was her ability to distinguish shades of color, as the stripes in a Venitian carpet; she could not perceive, however, a single color. When further improvement took place she stated that she could recognise the *yellow* color of a large looking-glass frame. A relapse then took place, from which she did not recover.

4. We may consider as the next degree of this defect where the individual can recognize two colors only; and these seem to be always *yellow* and *blue*. This is the most common grade of this defect. Examples of it are afforded in Scott,** Dalton and his brother,†† in the case recorded by Dr. NICHOLL in the *Med. Chirurg. Trans.*, ix. 359; in that of J. B. related in the *Transactions of the Philosophical Society* of Edinburgh, vol. x., p. 253; James Milne,‡‡ Mr. C.,§§ and Mr. Troughton,‖‖ Dr. EL-

* Huddard, in Philosophical Transactions for 1777, p. 260 and 263.

† Am. Journ., vol. xxiii., p. 446. The narrator states that this patient was deficient in discerning two primitive colors. It is manifest from the account, however, that this defect extended to all, and that the gentleman could merely distinguish shades. The rainbow, it is said, appeared to him "as a band of a lighter color than the other part of the sky, but a little darker at one side than the other, and gradually shaded off between the two sides."

‡ Obs. sur la Physique et l'Histoire Naturelle, tom. xiii., p. 87. Année 1779.

§ Transactions of the Phrenological Society, p. 209.

‖ Medico-Chirurgical Transactions, vol. vii., p. 472.

¶ It would seem, indeed, that it was only the lighter yellows that this boy recognized accurately; he confounded the darker with red. This last color he is said to name correctly, but the whole account proves that he could not distinguish this color. Thus he called green, red; light red and pink, blue; paper stained with red radish root he termed blue; green spectacles he called red glasses, &c.

** Philosophical Trans. for 1778, p. 612.

†† Memoirs of the Literary and Philosophical Society of Manchester, vol. v., p. 28.

‡‡ Transactions of the Phrenological Society, p. 222.

§§ Glasgow Medical Journal, vol. ii., p. 15.

‖‖ Brewster's Optics, Am. ed., p. 260.

LIOTSON's first case,* and Sir DAVID BREWSTER's case.† Mr. Scott, J. B.‡ and Mr. C. were imperfect in their recognition of blue; in the other cases the perception of yellow and blue seems to have been complete.

It is remarkable that, whilst all the individuals who belong to this class of cases are able to discern yellow and blue, they cannot distinguish these colors when presented in a state of mixture. Green they do not know—they seem blind to it. They cannot perceive any difference in color between a stick of red sealing-wax and a green table-cover; between the color of the scarlet fruit of the Siberian crab and the green of its leaves, &c. &c.

So it was also with Mary Bishop: whilst able to detect yellow and blue she could not see the difference in color between the red roses and their green leaves. It was not until her eyes had become sensible to red that she could distinguish green.

5. In the first edition of this work we mentioned it as probable that individuals who are able to recognize *accurately* the three primitive colors, can also distinguish the secondary ones, but that to future observations must be left the decision of this question.

Since its publication we have received a memoir by Dr. SZOKALSKI,§ where are noticed two cases in which the individuals could distinguish the three primitive colors, but were unable to discriminate between the secondary ones. The first case was observed by SZOKALSKI, and the subject of it always unhesitatingly recognized the three primitive colors, but could not distinguish the secondary ones. He saw in the rainbow only yellow, blue and red. The second case is recorded by SOMMER.‖ The subject of it is a Dr. G., who states that he thinks he can distinguish the three primitive colors, but his perception of red is evidently not perfect, and such seems to have been the case also, though to a less degree, in Dr. S.'s case. It seems probable, then, that persons may distinguish the three primitive colors, without having that faculty in regard to the secondary ones. But persons whose perception of red is imperfect, certainly do not accurately discriminate the secondary colors.

As the imperfection in vision we have been noticing is a very curious one, it may be allowable here to call attention to some further facts connected with it.

It must be remarked that whilst those who labor under this defect naturally are unable to distinguish certain colors, though of the most vivid kind, they can discriminate any marked difference in *shades* or degrees of color, and often can see minute objects with perfect distinctness. It occurs in persons whose point of vision is natural, as was the fact in most of the cases on record, and also in those who are far-sighted,

* Am. Journ. Med. Sci., vol. xxiii., p. 436. † Optics. Am. ed., p. 260.

‡ The editor of the American edition of Brewster's Optics, in a note, p. 323, says in relation to this case, "The Plymouth tailor whose case is described by Mr. Harvey, seems not to have been entirely blind to red light, and to have been in a measure blind to blue." He has been, we believe, misled in the former inference, by the account of Mr. Harvey, who was himself deceived by the individual naming scarlet correctly on one or more occasions, by *guess*. A careful examination of Mr. Harvey's statement will, we conceive, justify this belief. This disposition to *guess* the names of colors is generally manifested by persons who have the defect under consideration; and the errors to which this may lead, must be carefully guarded against.

§ Essay sur les Sensations des Couleurs, dans l'état physiologique et pathologique de l'œil, memoire présenté a l'Academie des Sciences de Paris. Par VICTOR SZOKALSKI, M. D. P., &c. Paris, 1841.

‖ Journal de Græfe et Walther, vol. v., p. 20.

as Mr. NICHOLL's fourth case and Mr. COLQHOUN's second case; and in those who are near-sighted, as in Mr. DALTON.

This defect appears often to be hereditary, or at least to prevail in certain families. Thus HARRIS had two brothers who were unable to distinguish colors, while two other brothers and sisters, as well as his parents, had not this defect.* SCOTT's father and one sister had the defect; his mother and another sister were free from it; but his mother's brother had it. The former sister had two sons, both laboring under the defect. SCOTT had two children who were able to distinguish colors.† In NICHOLL's first case the mother and father and his four sisters were free from this defect, but his mother's father had it. This last had two brothers and one sister: one brother had the defect, the others not.‡ In Dr. NICHOLL's second case several of the family were similarly affected.§ Mr. DALTON had a brother who labored under the defect,‖ and he mentions that he knows of a family of six sons and one daughter, in which four of the sons were unable to distinguish colors.¶ TUCKER's maternal grandfather had this defect; WARDROP states that several branches of a noble family in Great Britain have been remarkable for having it;** and we know of two families in this country similarly circumstanced.

An example of very extensive hereditary prevalence of this defect in a family, is reported by our friend Dr. PLINY EARLE, in the *American Journal of the Medical Sciences* for April, 1845. Dr. E.'s maternal grandfather and two of his brothers were characterized by it, and among the descendants of the first-mentioned, there are *seventeen* persons in whom it is found. Dr. E. has not been able to extend his inquiries among the collateral branches of the family, but he has heard among these of one individual, a female, in whom the defect exists.

For the purpose of illustrating the prevalence of this physiological peculiarity in the family, he gives the accompanying genealogical chart. (See next page, fig. 91.) "Males are represented by squares, and females by circles. For those who cannot distinguish colors the squares or circles are wholly black.

"The chart includes five generations. Nothing is known of the first generation, in regard to the power of perception in colors. In the second, of a family consisting of seven brothers and eight sisters, three of the brothers, one of whom, as before mentioned, was the grandfather of the writer, had the defect in question. In the third generation, consisting of the children of the grandfather aforesaid, of three brothers and four sisters, there was no one whose ability to distinguish colors was imperfect. In the fourth generation, the first family includes five brothers and four sisters, of whom two of the former have the defect; in the second family there was but one child, a daughter, whose vision was normal; in the third there were seven brothers, of whom four had the defect; in the fifth, seven sisters and three brothers, of all of whom the vision is perfect in regard to color; in the sixth, four brothers and five sisters, of whom two of each sex have the defect; in the seventh, two brothers and three sisters, both of the former having the defect; in the eighth there was no issue, and in the ninth there are two sisters, both of them capable of appreciating colors.

"Seventeen of the persons in the fourth generation are married, and the whole number of their children is fifty-two. Many of the latter are

* Philosophical Transactions, 1777. † Ibid., 1778.
‡ Med.-Chirurg. Trans., vol. ii., p. 472. § Ibid., vol. ix., p. 361.
‖ Mem. Lit. and Philos. Soc. Manchester, vol. v. ¶ Ibid.
** Essays on the Morbid Anatomy of the Human Eye, vol. ii., p. 199.

Fig. 91.



very young, some of them not living, and as the defective perception has hitherto been detected in but two of the families, those alone are placed in the chart as the fifth generation. In one of them, consisting of three brothers and three sisters, one of the brothers has the defect, and in the other, a male, an only child, is similarly affected.

"*b.* The overleaping of one generation by the hereditary peculiarity of vision, is satisfactorily shown by the chart; in which it appears, as has been mentioned, that there are no cases in the third generation. Furthermore, in the cases of the two males of the fifth generation, it will be perceived that neither parent nor grandparent had the defect; so that there was an interval of *two* generations between the manifestations of that defect.

"*c.* That males are more frequently deficient than females, in the power of distinguishing colors, is manifestly confirmed by the cases mentioned for the first time in this article. These cases are *thirty-one* in number, *twenty-seven* of them being of males and but *four* of females. Of the twenty persons represented in the foregoing chart as having the defect, *eighteen*, or nine-tenths of the whole are males.

"This disparity of numbers of those affected in the two sexes is no less strikingly exhibited by the ratio between the whole number of persons of either sex and the number of those who have the peculiarity. Thus, in the chart, there are eight special families in which the defect prevails, one in the second generation, five in the fourth, and two in the fifth. These families include *thirty-two* males, of whom *eighteen*, or nine-sixteenths of the whole, have the defect; and *twenty-nine* females, of whom *two* or about one-fifteenth of the whole, also have it."

Some very remarkable peculiarities not hitherto noticed have been observed by Dr. Earle in some of the individuals of the family who are the subjects of his paper. The first is, that the power of accurately distinguishing colors varies at different times in the same individual. "In the man represented as the youngest of the first family of the fourth generation in the chart," Dr. E. states, "it would appear that at times the function of the 'organ of color'—to presuppose the truth of an undemonstrated theory—were performed with nearly as great a degree of perfection as in persons who can make the most delicate chromatic distinctions, while, on other occasions, the defective action of that 'organ' involves the individual in the most absurd mistakes. In describing a domestic fowl, he spoke of it as 'the yellow hen with a blue tail,' and, some years afterwards, being rallied upon the subject of his singular ornithological discovery, he declared that 'if the tail was not *blue*, it was *pink*.'"

The second is, the co-existence in some cases of an inability of discriminating between musical notes, with want of ability to distinguish colors. "The whole family," Dr. E. observes, "of which the chart has been exhibited, is probably no less generally characterized by a defective musical ear than an imperfect appreciation of colors.

Several of the individuals comprised in it are utterly incapable of distinguishing one tune from another. In some of the branches, however, where there was a high degree of musical talent *in the family of the other parent*, several of the individuals inherit it, and, among them, two who cannot distinguish colors. They are remarkably quick in 'catching a tune.'"

It is a curious psychological phenomenon, that two of these who labor under the double defect are poets. One of them "is generally acknowledged as one of the first and greatest of American poets now living." Yet this last gentleman, who is unable to distinguish one tune from another, writes poetry which "is not deficient in the requisites of perfect cadence, harmony, and rhythm; and while he is unable to distinguish a single color, no evidence of this can be detected from his writings."

We have often noticed that persons affected with cataract, who were unable to discern the *form* of objects, in consequence of the irregular refraction of some of the rays of light and the interception of others, could distinguish generally, very accurately, *colors*. Connecting this fact with the inability to perceive colors while forms could be discerned, as observed in Mary Bishop and some other cases of amaurosis, it occurred to us that we might derive from this a means of diagnosis between the two diseases. Subsequent investigations have not confirmed this idea. The subject may, however, be worthy of a more extensive examination than we have bestowed on it.

Several *theories* have been proposed to explain this defect of vision. Mr. Dalton thinks it probable that the red light is in these cases absorbed by the vitreous humor, which he supposes may have a blue color; but this is a mere conjecture, which is not confirmed by the most minute examination of the eye, and does not even explain all the phenomena.

Dr. Young thinks it more simple to suppose absence or paralysis of those fibres of the retina which are calculated to perceive red; but there is no evidence of there existing in the retina fibres suited to the perception of the different colors, and this also does not embrace all the degrees of the defect.

Sir David Brewster, after analyzing certain cases, says, "In all the preceding cases there is one general fact, that red light and colors in which it forms an ingredient, are not distinguishable by those who possess the peculiarity in question." Hence he at one time concluded that the eye is in these cases, insensible to colors at the one end of the spectrum, just as the ear of certain persons has been proved by Dr. Wollaston, to be insensible to sounds at one extremity of the scale of musical notes, while it is perfectly sensible to all other sounds. More recently he has offered the following explanation of the phenomena. "The eyes of such persons," he remarks, "are blind to *red* light; and when we abstract all the red rays from the spectrum constituted as already described,* there will be left two colors, *blue* and *yellow*, the only colors which are recognized by those who have this defect of vision. To such eyes light is always seen in the red space; but this arises from the eye being sensible to the yellow and blue rays, which are mixed with the red light. Hence blue light will be seen in the place of the *violet*, and a greenish *yellow* will appear in the orange and red spaces, or which is the same thing, the spectrum will consist only of the *yellow* and *blue* spectra."

This theory embraces only one class of cases, and even in them it does not explain all the phenomena, as, for instance, how it is that those

* Optics, Am. ed., p. 69.

who can perceive yellow and blue cannot distinguish those colors in a state of mixture; for of green they seem to have no perception.

Dr. W. Nicholl has proposed a theory* which is, however, so opposed to all the facts that it is unnecessary to occupy time in detailing it.

Mr. Wardrop thinks "it is not improbable that this defect of vision arises from a greater sensibility of the retina to the impressions of the blue and yellow-making rays, than to those of any of the others." "This may depend," he observes, "upon the refractive powers of the humor, by which the rays of these two colors are more accurately united on the retina than rays of any other color, and, consequently, the images formed there of objects reflecting these colors are more distinct than those formed of objects reflecting the other colors. When the color of a body is compounded of several colors, the superior correctness of the image formed by the blue and yellow rays reflected from it, may cause the sensations which these colors excite to predominate over the sensations caused by the other colors, and thus may cause in the mind of the observer the perception of that compound color to be different from the perception of the same color to another person, whose eye forms images of external objects differently."†

It is almost unnecessary to say that this is pure hypothesis, and is even contradicted by some careful investigations presently to be noticed.

Sir John W. F. Herschell attributes this state of vision to a defect in the sensorium, by which it is rendered incapable of appreciating exactly those differences between rays on which their color depends. This profound philosopher observes, "We have examined with some attention a very eminent optician, whose eyes (or rather eye, having lost the sight of one by accident) have this peculiarity, and have satisfied ourselves, contrary to received opinions, that all the prismatic rays have the power of exciting and affecting them with the sensation of light, and producing distinct vision, so that the defect arises from no insensibility of the retina to rays of any particular refrangibility, nor to any coloring matter in the humors of the eye preventing certain rays from reaching the retina, (as has been ingeniously supposed,) but from a defect in the sensorium, by which it is rendered incapable of appreciating exactly those differences between rays on which their color depends."‡

This is essentially the phrenological doctrine. According to the phrenologists the eye only receives impressions, the power of judging of them resides in the sensorium; and the inability to distinguish colors does not result from any defect or imperfection of the eye, but upon that particular portion of the brain which they have named the "*organ of color*."§

We trust that the preceding remarks will induce others to investigate the curious defect in vision under consideration. Opportunities, for this, we believe, are of more frequent occurrence than is supposed, and if advantage be taken of them, and the observations be made accurately and with a proper method, a clue will no doubt be obtained to its explanation.

The prismatic spectrum, as it is always the same, and thus enables us to compare observations, should be made use of. The colors should be shown together and separately, and the individual's powers tested carefully. It is particularly desirable now to ascertain first what primitive colors the individual can distinguish, and which if any of the compound colors.]

* Annals of Philosophy, Feb. 1822, p. 128.

† Essays on the Morbid Anatomy of the Human Eye, vol. ii., p. 200.

‡ Encyclopedia Metropolitana, Art. Light, p. 434 and 507.

§ Mary Bishop's case would seem to favor this theory, her affection having been the sequel of an attack of cerebral disease.

SECTION VI.—NEAR-SIGHT, AND FAR-SIGHT.

These are two defects of vision not dependent upon the optic nerve, but upon the refractive powers of the eye. They are produced by certain configurations of the transparent media, and happen in conformity to the general laws of optics. The rays of light are either collected too soon, brought together before they reach the bottom of the eye, rendering the person *myopic*, or near-sighted; or they are not brought together in front of the retina, the focus in which they would meet being behind the situation of that membrane, so that the person is *presbyopic*, or far-sighted. These kinds of sight are consequent upon some conditions of the transparent media of the eye, which, in all other respects, is perfectly natural. The eye, being in a great part of its functions a mechanical instrument, must be subjected to mechanical laws; and we find, that a given configuration of the transparent media, a certain relation of them to each other, and their position at determinate distances from the retina, are necessary to the formation of a distinct picture upon that nervous expansion. There is a certain distance from the eye, which is called the point of distinct vision, at which we can see objects in all their details with perfect clearness. Every eye, considered as an optical instrument, has its point of distinct vision; the latter, therefore, varies in different persons, and is often different in the two eyes of the same individual. Objects are not so distinctly seen, when moved nearer to, or further from the eye than this point. In ordinary well-constructed eyes, the distance ranges from about fifteen to twenty inches. It must be observed, however, that they are peculiarly strong eyes which can see distinctly beyond these limits on either side. Persons who are obliged to hold objects much closer to the eye than the distance already mentioned, are called myopic, or near-sighted.

Near-sightedness; myopia.—An individual who is myopic, holds a book for reading, or anything that he may wish to examine minutely, much nearer to the eye than others; he cannot distinguish the countenances of performers on the stage, nor the details of pictures when placed some feet from him; he cannot read the inscriptions on doors and houses, nor recognize persons across the street; if he goes into a large room in which there are many persons, he cannot readily distinguish those he knows. The cause of this is in the transparent media of the eye. Probably there is an original difference in the configuration, or the density of these media, or in the condition of their surfaces. Sometimes the cornea is manifestly more convex, and the anterior chamber larger than in the normal state. I have seen those changes, with great near-sightedness, as results of obstinate strumous ophthalmia, or other long-continued inflammation affecting the anterior parts of the eye. The affection called conical cornea is attended with myopia, which becomes more and more considerable as the affection advances. (*See* p. 363.) But, in most cases, the state of the eye appears quite natural, and we cannot discover the circumstances on which the defect immediately depends.

It may be a question whether this state of the eye is brought on by the habits of the individual. I am inclined to think that the habitual mode of employing the organ has some influence. In persons of a literary and studious character, who use their eyes much in reading or writing, and in others who are constantly occupied on minute objects near the eye, we observe that the sight is frequently myopic. I remember once attending a book-sale, at which I was struck by the number of persons wearing spectacles; having counted them, I found there were twenty-three gentlemen in

the room, and that twelve of the number had spectacles on. Mr. WARE endeavored to ascertain the proportional numbers of the near-sighted in the different ranks of society. "I have inquired," says he, "for instance, of the surgeons of the three regiments of foot-guards, which consist of nearly ten thousand men; and the result has been, that near-sightedness among the privates is almost utterly unknown. Not half-a-dozen men have been discharged, nor half-a-dozen recruits rejected, on account of this imperfection, in the space of nearly twenty years; and yet many parts of a soldier's duty require him to have a tolerably correct view of distant objects." "I pursued my inquiries at the military school at Chelsea, where there are thirteen hundred children, and I found that the complaint of near-sightedness had never been made among them until I mentioned it; and there were then only three who experienced the least inconvenience from it. After this, I inquired at several of the colleges in Oxford and Cambridge; and though there is a great diversity in the number of students who make use of glasses in the various colleges, they are used by a considerable proportion of the whole number in both universities; and in one college in Oxford, I have a list of the names of not less than thirty-two out of one hundred and twenty-seven, who wore either a hand-glass or spectacles, between the years 1803 and 1807." (*Tracts on the Eye*, p. 201, 202.)

Mr. WARE mentions the case of a mathematical instrument maker, who had long used convex glasses for reading. After having been employed several hours together, for many successive days, in looking through a double microscope, he has been able, repeatedly, for a few weeks, to read without glasses; this improvement goes off in a few weeks, and he is then obliged to resume his former spectacles. (*Ibid.*, p. 228.)

From these facts, together with the well known far-sightedness of sailors and country people, we may infer, that the habitual mode of employing the eyes has decided influence in rendering them either myopic or presbyopic.

Hence it may be true, as Mr. WARE surmises, that the smaller proportion of the near-sighted in the lower classes arises from their not resorting to means for correcting so slight an imperfection, which may be consequently overcome by the increased exertions of the eye to distinguish distant objects. Hence, also, it is probable that the defect may be confirmed by the habitual use of concave glasses, and even increased if the near sighted person employs those which give him the clearest sight. These at first cause uneasiness, which goes off under their continued employment; and a deeper glass will be required, after some time, to produce the same effect.

Near-sightedness is not observed early in life;* persons do not resort to the use of glasses until towards the age of fourteen. The defect may exist previously without being noticed, as young persons do not attend minutely to the state of their sight, or compare accurately their own vision with that of others.

We sometimes see anomalous cases of near-sightedness dependent on some change in the state of the eye, which we are unable to explain. Mr. WARE (*Tracts on the Eye*, p. 206,) mentions the instance of a youth at school, in whom it came on suddenly after previous anomalous nervous symptoms. He was sent into the country for the recovery of his health, with the recommendation to postpone the use of concave glasses until he returned. In ten days he died suddenly. A gentleman, who had found it necessary to use convex glasses at the age of forty, began, when he was

* We have seen several exceptions to this.

fifty, to see distant objects indistinctly, and was obliged to employ a concave glass (number six) for distant sight, though he still used convex glasses of the first number for reading. (*Ibid.*, p. 225.) A woman of fifty, who had become presbyopic, was attacked with dimness of sight and slight inflammation of one eye, for which copious evacuations were necessary. On recovery, she found herself near-sighted, and required concave glasses of the fifth number for seeing distant objects. (*Ibid.*, p. 226.) In a lady, who had long been presbyopic, inflammation of the eyes occurred requiring leeches and other means. When she got well, she could read without her glasses; but the presbyopia returned in a few weeks. (*Ibid.*, p. 227.)

The only mode of remedying near-sightedness is the use of concave glasses; the imperfection of vision is caused by too great a refractive power in the eyes, and we must have recourse to artificial measures for lessening it. Our object is to enable the near-sighted to see distant things; indeed, they see near objects very well, and this circumstance has given rise to the notion that their eyes are strong. In order to select the proper glass, the person must try several, and choose that with which he can see a distant object most distinctly. If this is accomplished without any sense of painful exertion in the eye, the glass which will enable him to do so, is that which he should choose. He will probably find that with a glass rather more concave, for instance of the next number to that which he has chosen, he can see still more clearly, but that after looking through it for a short time the eye feels strained and fatigued; he should not allow this slight advantage in point of vision to induce him to expose the eye to an influence that will be injurious. From the use, under proper precautions, of such concave glasses as will rectify the error in the refractive power, the near-sighted person need not apprehend any injury to the eye; indeed, the easy exercise of vision with the requisite optical aid, seems to me less hurtful than the straining and efforts to do without it. As there is some reason for concluding that the optical powers of the eye accommodate themselves to the circumstances under which vision is habitually exercised, I recommend near-sighted persons not to wear spectacles constantly, but only to use them on occasions when they more particularly require such assistance. When they have been worn for a considerable time, the person does not at first see so well on leaving them off as he did before; but this is only temporary. If spectacles, chosen in the manner I have described, be worn only occasionally, there is no fear of the eye becoming more near-sighted, so as gradually to require deeper glasses.

The eye in the progress of age becomes presbyopic, and it might be supposed that this natural change in the organ would remedy the excess of refractive power in the near-sighted, and enable them to dispense with their concave glasses: this is not the case; the near-sighted continue so in old age. I have known several instances, in which myopic persons were still obliged to use their concave glasses, although greatly advanced in years.* To the same effect Mr. Ware observes, that "the instances are few, if any, in which, if the use of concave glasses has been adopted, increasing years have either removed or lessened this imperfection." (*Tracts on the Eye*, p. 230.) His observations, in another part of the same tract, show that the range of vision, which is comparatively confined in the near-sighted originally, becomes still more limited in advancing years. Neither is there any ground for the notion that near-sight is strong sight.

* [The late Col. Pickering, of Boston, who was extremely near-sighted during the greater part of his life, several years before his death, which was at an advanced age, laid aside his glasses, and was able to read and see perfectly well without them.]

[The following remarks by Dr. Mackenzie, on the treatment of myopia, are of sufficient interest to justify our introducing them here.

"It is but rarely the case that the medical practitioner has an opportunity of advising those in whom myopia is not yet confirmed, to that course of treatment which might remove the incipient symptoms of this very serious imperfection of sight. If it be correct, that this disease, in by far the greater number of instances, is induced by too much exercise of the eyes upon minute objects, as in reading, writing, sewing, miniature painting, engraving, and the like, the cure would probably be found in abstaining entirely for a time from such occupations, refraining also from the use of concave glasses, and employing the eyes chiefly upon large and distant objects. Haller recommends looking through a small aperture, as a remedy for myopia; but probably this, as well as gradually removing the book from the eye till it can read at the ordinary distance, reading through convex glasses, and other attempts of a similar sort, will prove of little use, in comparison with the good effects to be derived from frequent exercise out of doors, walking and riding into the country, and traveling through new and interesting scenes.

"If, instead of such a plan of treatment, recourse be had to the employment of concave glasses, and the frequent and long-continued observation of near objects be persisted in, the disease becomes not only confirmed, but sometimes greatly aggravated."

"'When I first learned to read, at the usual age of four or five years,' says Sir Charles Blagden, 'I could see most distinctly across a wide church, the contents of a table on which the Lord's Prayer, and the Belief, were painted in suitably large letters. In a few years, that is, about the ninth or tenth of my age, being much addicted to books, I could no longer read what was painted on this table; but the degree of near-sightedness was then so small, that I found a watch-glass, though as a meniscus* it made the rays diverge very little, sufficient to enable me to read the table as before. In a year or two more the watch-glass would no longer serve my purpose; but being dissuaded from the use of a common concave glass, as likely to injure my sight, I suffered the inconvenience of a small degree of myopy till I was more than thirty years of age. That inconvenience, however, gradually though slowly increasing all the time, at length became so grievous, that at two or three and thirty, I determined to try a concave glass; and then found, that the numbers two and three were to me in the relation so well described by Mr. Ware; that is, I could see distant objects tolerably well with the former number, but still more accurately with the latter. After contenting myself a little time with No. 2, I laid it wholly aside for No. 3; and, in the course of a few more years, came to No 5, at which point my eye has now been stationary between fifteen and twenty years. An earlier use of concave glasses would probably have made me more near-sighted, or would have brought on my present degree of myopy at an earlier period of life. If my friends had persuaded me to read and write with the book or paper always as far from my eyes as I could see; or if I had occasionally intermitted study, and taken to field sports, or any employment which would have obliged me to look much at distant objects, it is very probable that I might not have been near-sighted at all.'†

"*Concave glasses.*—When once a near-sighted person has experienced

* Sir C. Blagden here employs the word *meniscus* (from μην, *moon*), in a sense which, though perhaps vindicated by occasional practice, it were better to avoid. A watch-glass is merely a segment of a hollow sphere, the surfaces of which are concentric.

† Philosophical Transactions, vol. ciii. p. 110; London, 1811.

the pleasure of seeing remote objects with that distinctness and comparative brilliancy which the aid of concave glasses affords, it is not easy to persuade him to renounce their use. Their effect, as is now universally known, is merely to diverge the rays of light before they enter the eye, by this means counteracting the over-refractive power of that organ, and bringing the rays of light exactly into foci upon the retina. The assistance afforded by concave glasses to one set of defective eyes, and by convex to another, had been the subject of admiration and perplexity for several hundred years, till Kepler, in his *Ad Vitellionem Paralipomena*, published in 1604, cleared up the mystery, by explaining, for the first time, the true mechanism of the eye. It had been proposed as a question to Kepler, by his patron, Dietrickstein, in what manner spectacles assisted sight. The first answer he gave was, that convex glasses were of use, by making objects appear larger, but his patron observed, that if objects were by them rendered more distinct, because larger, no person would be benefited by concave glasses, since these diminished objects. The striking resemblance between experiments with the camera obscura and the manner in which vision is performed in the eye, had been pointed out by Baptista Porta, who compared the pupil to the hole in the window-shutter, but fell into the mistake of supposing that it was in the centre of the eyeball that vision was effected.* Kepler, in his work above referred to, showed that the office of receiving the images of external objects is performed by the retina, and gave the first clear explanation of the effects of lenses, whether within or without the eye, in making the rays of a pencil of light converge or diverge. He now explained, that convex glasses assist the sight of presbyopic persons, by so altering the directions of rays diverging from a near object, that they should afterwards fall upon the eye, as if they had proceeded from a more remote one, and that concave glasses benefit the myopic, by producing a contrary effect upon rays which diverge from a distant object—a theory to which no addition has been made by any succeeding author.

"The glasses commonly employed for the assistance of myopic eyes are double-concaves, of equal concavity on each side. Occasionally, however, the two sides are made of unequal depth. A plano-concave glass might answer; and in the use of concavo-convexes (the exterior surface of the glass, or that which is turned from the eye, being convex, and having a less degree of curvature than the interior, or that which is turned towards the eye, which is concave), there is supposed to be a considerable advantage, in so far as they allow the eyes a greater degree of latitude in vision, without fatigue, whence the name *periscopic* glasses, under which they were recommended by Dr. Wollaston.

"Myopic persons are extremely apt to adopt the use of a single eye-glass, against which we ought to put them on their guard. Spectacles are always preferable, because by keeping both eyes in action, not only is vision rendered brighter and easier, but the labor of each eye is considerably lessened. Dr. Wells has pointed out another reason why glasses should be employed rather in the form of spectacles, than singly, which, though it applies more strongly to the use of convex than of concave glasses, I shall here introduce in his own words.

"'In regard to such spectacles as I have tried upon myself, I have always found that, when I looked with them at objects, placed at moderate distances before me, my optic axis passed through the glasses, more inwardly than their centres. With respect, therefore, to spectacles for

* Magiæ Naturalissive de Miraculis Rerum Naturalium, libri iv., fol. 118. Antuerpiæ, 1560.

long-sighted people, as the inner halves of their glasses may be regarded as two prisms, whose refracting angles face each other, to have allowed both my eyes to receive through them pencils of rays from the same point of an object, the intervals of my pupils must have been less than was necessary for that purpose in naked vision. The consequence of which would be, an increase of the refractive power of my eyes. Again; as the like parts of glasses in spectacles for short-sighted persons, may be esteemed to be two prisms, the refracting angles of which are turned from each other, the interval of the pupils must have been increased, and the refracting power of my eyes by this means diminished, when I looked at an object through them, which was directly before me. And effects similar to what I have mentioned, must have followed my viewing objects placed obliquely, through glasses of both kinds. Here then is one advantage, which persons who see with both eyes, either do or may enjoy from spectacles, but which they cannot derive from using single glasses. For if they are presbytic, they can see an object by means of them with a higher refractive state of the eyes, than if the optic axes met there, as in naked vision; and if myopic, with a less. It is also worthy of remark, that this advantage does not ultimately tend to increase the evil, which first gives occasion for spectacles. On the contrary, if what every writer upon vision asserts be true, that we are apt to become short or long-sighted, according as we are much accustomed to view near or distant objects, it must serve to diminish that evil. In support of this opinion, I shall mention a fact, with which I have been made acquainted by Mr. George Adams, of this place, who is not only well skilled in the theory of vision, but, from his situation as an artist, has better opportunities than most persons, of learning such matters. The fact is this, that he does not know a short-sighted person, who has had occasion to increase the depth of his glasses, if he began to use them in the form of spectacles; whereas, he can recollect several instances, where those have been obliged to change their concave glasses repeatedly, for others of higher powers, who had been accustomed to apply them to one eye.'*

"Double-concave glasses are numbered 1, 2, 3, &c., beginning with the longest focus, or shallowest concavity.† We must recommend to

* Experiments and Observations on several Subjects in Optics, p. 99; London, 1818.

† Concave glasses ought to be distinguished by their focal lengths, and never by numbers, because the gradations of concavity are not always worked to a certain standard, so that what one optican calls No. 1, another rates as No. 2, and so on. I find No. 1 to be 48 inches focus in one shop, and 24 inches in another; No. 12, to be 10 inches focus in one, and 4½ in another. Mr. Ramsden made the first number of his concave glasses equivalent to a convex of 24 inches focus, *i. e.*, if a convex of that focal length were united to a concave No. 1, the combination would be equivalent to a plane, and objects would appear through the two glasses neither larger nor smaller than they really are. No. 2 he made to correspond to a 21 inch convex; No. 3 to an 18; and so on.

The following are the foci in inches of a set of concave glasses which I keep by me, with which to try myopic eyes.

No. 1 - - 48	No. 5 - - 14	No. 9 - - 5
2 - - 36	6 - - 12	10 - - 4
3 - - 24	7 - - 9	11 - - 3
4 - - 18	8 - - 7	12 - - 2½

In Germany, what is called No. 1, is commonly of the focal length of 2½ or 3 inches, and each following number has an inch, or a certain number of lines, of additional focal length.

The focus of a concave lens may be ascertained, by reflecting from its surface, upon an opaque body, the image of any very distant luminous object, such as the sun, observing when the image becomes smallest, and measuring the distance be-

the near-sighted person to be content with the shallowest glass or lowest number, which answers his purpose. If No. 1 enables him to discern distinctly the names on the corners of the streets, and gives a decided outline to objects whose distance does not exceed about 40 feet, he ought not to have recourse to No. 2. Objects should appear clear through the glass which is chosen; but if it makes them less than natural, or gives them a dazzling or glaring appearance, or if the eye feels strained or fatigued after looking through it for a short time, it is too deep, and a lower number should be selected.

"When a near-sighted person wishes to be fitted with concave glasses, the simplest and surest plan is to try a series of them, at an optician's shop. It may happen, however, that an individual in the country is desirous of writing to town for concave glasses, and wishes to mention the focus which will be likely to suit his eye. This may be ascertained by means of the optometer, as improved by Dr. Young; but as this instrument is not always at hand, the following rules may be adopted.

"1. If the near-sighted person is desirous of assistance in seeing remote objects, *i. e.*, beyond 200 or 300 yards, the focal distance of the glasses which he will require for that purpose, should be the distance at which a small object appears distinct to his naked eye. For example, if he reads this type at 12 inches distance, 12 inches will be the focus of the concave glasses which he will require for seeing distant objects distinctly.

2. "If the glasses wanted are intended for reading with, or seeing near objects, let the near-sighted person multiply the distance at which he is able to read with ease with the naked eye, say 4 inches, by the distance at which he wishes to read, say 12 inches; divide the product 48 by the difference between the two, which in this instance is 8; the quotient, 6, is the focal length in inches of the glass which is required.

"It is a very common error with those persons who begin to use concave glasses, to tire of those which they first employ, and have recourse to deeper ones. To these the eyes do not fail (at least for a time) to accommodate themselves; but, in the end, the patient, who thus proceeds from one degree of concavity to a greater, will find it difficult to obtain glasses sufficiently deep to afford him much assistance, or he may produce such weakness of the retina, or amblyopia, as shall render him unfit to engage in any ordinary pursuit. Near-sightedness generally continues, as has been already stated, in nearly the same degree during the greater part of life. Therefore, the same glass will continue for many years to afford precisely the same assistance, and ought not to be heedlessly changed for one of deeper concavity.

"Dr. Kitchener tells us, that he was about fifteen years old, when he first discovered that he could not discern distant objects so distinctly as people who have common eyes usually do. 'Seeing,' says he, 'that I could not see what persons with common eyes frequently pointed out to me as well deserving my attention, I paid a visit to an optician, and purchased a concave eye-glass No. 2. After using this some little time, I accidentally looked through a concave No. 3, and finding my sight much sharper with this than with No. 2, had my spectacles glassed with No. 3, which appeared to afford my eye as much assistance as it could re-

tween the centre of the reflecting surface and the body upon which the image is received. Double this distance is the focal length of the lens, and is equal to the radius of curvature of its surfaces, these being ground on the same tool. The two surfaces, however, are not always ground on a tool of the same radius, so that the one side is sometimes deeper than the other.

ceive. After using No. 3 for a few months, I chanced to look through No. 4, and again found the same increase of sharpness, &c., which I perceived before when I had been using No. 2 and first saw through No. 3, therefore concluded that I had not yet got glasses sufficiently concave, and accordingly procured No. 4; however, this soon became no more stimulus to the optic nerve than its predecessors Nos. 2 and 3 had been. I then began to think that the sight was subject to the same laws which govern the other parts of our system, *i. e.*, an increased stimulus by repetition soon loses its power to produce an increased effect. Therefore I refused my eye any farther assistance than it received from spectacles glassed with No. 2, which I have worn for upwards of thirty-one years, and it is very nearly, if not quite as sufficient help to me now, as it was when I first employed it.'*

"The same author recommends persons who are extremely short-sighted, in order to prevent their being obliged to stoop in writing, reading, music, and the like, to wear spectacles with very shallow concaves, just enough to enable them to see the objects required in such cases, at the same distance with other persons; but for distant objects, to use a small opera-glass, which, having an adjustable focus, if it magnifies only twice, will be infinitely better than any single concave, because it can be exactly adapted to the various distances.

"It is advisable that near-sighted persons should not wear spectacles constantly, but only on occasions when they more particularly require such assistance. When they have been worn for a considerable time, the person does not at first see so well on leaving them off as he did before; but this is only temporary." *Practical Treatise*, p. 784–8.]

Far-sightedness.—The opposite state of the eye is called *presbyopia*, or far-sightedness; the former word being derived from πρεσβυς, an old man, because this state of the eye is observed in advancing age, and is most strongly marked in old persons. The eyes undergo certain changes in age, which have the effect of diminishing their refractive power, so that the rays of light are not brought to a focus before they reach the bottom of the eye. The focus of such rays would be formed behind the retina. This is the opposite state to that which we have just been considering. Persons between forty and fifty, and sometimes before that age, generally find that they cannot distinguish near objects so well as they have been accustomed to do. They find it difficult to read small print, or writing, to cut a pen or pencil, or to do anything that requires a clear near sight. The rays of light are more divergent the nearer the object is to the eye; and the further it may be, the more do they approach to the parallel direction; consequently a greater refractive power is necessary in the former than in the latter case. Far-sighted persons can see distant inscriptions, or distinguish the hour by a distant church clock, when they cannot read a common print held in their own hands, or see the figures and hands of a watch. This state of the organ must be remedied by the use of a convex glass, which, bringing together the divergent rays proceeding from near objects, remedies the deficient refractive power of the eye. The glasses must be chosen under the same restrictions as I mentioned in the former case; they must enable the person to see without straining or fatiguing the organ, and should only be worn for reading, writing, or the examination of near objects. This being a defective state of vision depending upon age, gradually increases, and therefore requires a corresponding increase in the power of the glasses employed.

* Economy of the Eyes, Part I. p. 111; London, 1826.

[The following remarks by Dr. Mackenzie on the use of glasses are very judicious.

"The assistance," he observes, "which the presbyopic eye derives from a double convex glass, ought neither to be too soon had recourse to, nor too long delayed. Many injure the sight, by adopting the use of magnifiers suddenly, and before they have any need of them; while others, actuated perhaps by a desire of concealing their age, refrain from employing them long after the period when glasses would not merely have afforded valuable assistance, but have proved a means of saving their sight. The presbyopic eye, if refused assistance, is necessarily strained by every attempt to perceive near objects, and suffers more in a few months by forced exertion, than it would do in as many years, if assisted by such glasses as would render vision easy and agreeable.

"It would evidently be absurd to fix upon any period of life at which glasses should be first employed, or at which the presbyopic eye should be assisted by stronger magnifiers than those made choice of in the first instance; but it may be laid down as a general rule, that whenever a person of 45 years of age, or upwards, finds, that in order to see small objects distinctly, he is obliged to carry them far from his eye; that he moves, as it were instinctively, nearer to the light, when he wishes to read or work, or holds the book or other object close to the light, in order to see with facility; that very small objects, after he has looked at them earnestly for some time, appear confused; that his eyes, after slight exertion, become so much fatigued, that he is obliged to turn them to other objects, in order to give them some relaxation; and that the sight on awaking in the morning, is very weak, and does not recover its customary degree of force for some hours; then, he may, if he has not hitherto used convex glasses, begin to use them, or if he has already had recourse to those of a very long focus, he may change them for a pair of shorter focus, or, in other words, of greater refractive power.

"A double-convex glass improves the vision of a presbyopic eye, simply by lessening the divergence of the rays of light proceeding from near objects, and thus ensuring their being brought into foci upon the retina. To see distant objects with distinctness, glasses are in general not required by the presbyopic eye; on the contrary, parallel rays being sufficiently converged by the refractive media of the eye itself, to be brought to their respective foci on the retina, the convex glasses must be laid aside, when objects at a distance are to be examined.

"As a meniscus will produce the same effect as a double convex-glass, in enabling the presbyopic eye to perceive near objects with distinctness, while it will allow the eye greater latitude without fatigue, Dr. Wollaston has recommended the former as a *periscopic* glass for far-sighted persons.

"Similar directions must be followed in choosing convex glasses as in selecting concave ones; *viz.*, that the lowest power, or longest focus, which answers the purpose, is to be chosen; and that as the concave glasses made use of by the near-sighted should not make objects appear smaller, neither should the convex glasses employed by the far-sighted make them appear larger than natural.*

* Convex glasses are kept in the shops, of every focal length, from forty-eight inches to six. It is evident, that no certain estimate can be formed from a person's age, of the focal length of the glass which he will require; although perhaps the following may be received as a tolerable approximation to an average, upon this head.

"If on trying the eyes separately, the individual discovers that one of his eyes only has become presbyopic from age, while the other is near-sighted from an original difference in conformation, he will find a reading glass, of about three inches in diameter, and of 12 or 14 inches focus, to answer him much better than spectacles.

"Persons at a distance from an optician, may determine the focal length of the convex glasses, which they will require, by means of the following rules.

"1. If they have a distinct vision of objects *moderately remote*, let them multiply the distance at which they see minute objects most distinctly, say 20 inches, by the distance at which they wish to read by the aid of glasses, say 12 inches, and divide the product, 240, by the difference between the two, 8; the quotient, 30, will be the focal length of the glasses required.

"2. If the distance at which the person sees most distinctly be *very great*, then the focal length of the glasses required will be equal to the distance at which he wishes to see objects most distinctly.

"Convex glasses of about 36 inches' focus are often used by ignorant people, under the name of *preservers*, before their sight has attained that degree of presbyopia which renders the use of glasses necessary. They seem to think that *preservers* have some specific power of arresting the progress of that failure of the sight, which is the natural consequence of age.

"As it is chiefly by candle-light that the presbyopic patient complains of his deficient sight, even after he has supplied himself with proper glasses, it is advisable that he should refrain, as much as possible, from employing himself at night in occupations which require intense use of the organs of vision. The moment that the eyes begin to feel hot and fatigued, while the individual is occupied in reading, writing, or the like, especially by candle-light, he should take the hint, and allow them a period of repose." (*Practical Treatise*, p. 792–4.)

Presbyopia is not a defect of old age alone, it occurs also in young persons, and if we may judge from the number of examples which have come under our observation, much more frequently than is generally supposed. Within the last six months we have been consulted in two cases, one a lad of nine years of age, the second a girl of ten. The former was supposed to be threatened with amaurosis, and had been subjected to very severe treatment in consequence. With a glass of eleven inches focus he could read sufficiently well, but he required for perfect vision one of four and a half inches. The little girl was still more presbyopic, seeing best with glasses of three and a half inches focus. Both cases seemed to have been congenital, the latter certainly was so.

Presbyopia sometimes occurs suddenly.

A very interesting case of sudden and temporary presbyopia in a young boy, is related by Dr. James Hunter, in the *Edinburgh Med. and Surg. Journ.*, Jan. 1840. The subject of it was an intelligent boy, 9½ years of age, who had been three years at school, and was very fond of his books. His sight began to fail about three weeks before Dr. H. saw him, and

Years of age	40	45	50	55	58	60	65	70	75	80	85	90	100.
Focal lengths in inches	36	30	24	20	18	16	14	12	10	9	8	7	6.

The focus of a convex glass may be measured by holding it near the side of a room, facing a window, or opposite to the sun, and moving it slowly backwards and forwards, until the image of the window frame, or of the sun upon the wall, becomes smallest and most distinct. The distance between the glass and the wall at that moment is the focal length.

was so much impaired in the course of four days that he could no longer see to read ordinary type with the naked eye. He had never had inflammation or other diseases of the eyes, nor received any local injury that could have caused this affection. His general health had always been good, and he never felt better than at the time when his sight gave way. Dr. H., on the most minute examination, could detect no visible symptom of disease. There was no vascularity of the tunics; the size and shape of the pupils, the motions of the iris, eyeball and eyelids were perfectly normal, and he felt no pain or uneasiness. He could see distant objects as well as ever, but near ones appeared very indistinct. With the assistance of his father's spectacles, which were fitted with glasses of nine and a half inches focal distance, he could read the smallest print.

The patient was ordered an active dose of calomel and rhubarb, and afterwards an aperient of senna and salts twice a week, a spare diet, active out-door exercise—to be kept from school, and not to be allowed to use spectacles. Exactly three weeks afterwards his sight began to improve, and in the course of two days was quite restored. The medicine had purged freely—no worms were discharged. The boy was afterwards able to read as well as ever without glasses.

After discussing the several proximate causes of presbyopia, Dr. H. very correctly, we think, considers that, in the present case, it resulted from a derangement of the mechanism for adjustment.

"All things considered," he remarks, "I think the best explanation of this case is to suppose that there was some derangement of the mechanism by which the eyes are accommodated to the distinct vision of objects at different distances. When the eye is turned from a distant object to the contemplation of a near one, a short interval elapses before the latter is seen distinctly; this interval being occupied in the adjustment of the focus vision. During this process the only visible change is a slight contraction of the pupil; but all physiologists agree that some other change must take place. The lens must either become more convex, or move forwards, or the antero-posterior diameter of the eyeball be lengthened, or the cornea become more prominent, or perhaps there is a combination of all or of some of these modes of adjustment. As all the above actions imply a power of contraction and relaxation in certain internal structures of the eyeball, it is very probable that the movements of these parts should at times be subject to derangement from spasms or from over-relaxation, in the same way as other organs endowed with a contractile power; and therefore, I think it not unlikely that in the present case, the eyes had temporarily lost the power of changing from the state necessary to fit them for the distinct vision of distant objects to that state required for the distinct vision of near ones: but whether that change is to be regarded as a *contraction* of certain parts, such as the ciliary ligament, as some suppose, or the fibres of the lens, as believed by others; or in a *relaxation* of these or other parts, cannot be determined in the present imperfect state of our knowledge of the exact manner in which the eye is adjusted to distance. This view of the case is supported by the following circumstances:

"1. The affection and recovery of the two eyes were simultaneous and equal, as might be expected if the presbyopia depended on a spasmodic derangement of their adjusting apparatus, which, being destined to act simultaneously and equally in health, is likely to be similarly affected in disease.

"2. The vision of distant objects was perfect, and near objects were

seen quite distinctly with convex glasses; showing the sensibility and other functions of the retina to be unaltered, and that the cause of the disease was one that did not interfere with the functions of the eyes, excepting by depriving them of their power of adjustment to distance.

"3. Other cases of the sudden occurrence of presbyopia in young children have been traced to the existence of various disorders, such as intestinal worms, epilepsy, and diseases of the brain or spinal cord, all of which are known to be frequently accompanied by spasmodic affections of different organs.

"The treatment of the present case was very simple; but I would call particular attention to the necessity in all similar cases of strictly prohibiting the use of spectacles in the first instance, for they can always be resorted to at an after period should the affection prove a permanent one; and I have but little doubt that, if the wishes of my patient had been complied with, and he had been allowed to continue to use his father's spectacles, the presbyopia would have become a confirmed disease."

An account of a second case, precisely similar, was found among Dr. HUNTER's papers, and is published in the *Northern Journal of Medicine* (May 1845). We subjoin this case, as it is interesting from the exact degree of loss of sight and focal lengths of the glasses required to correct it being carefully given.

"On the 17th of last April, a person from the country brought his son to me that I might examine his eyes. He was a strong, well-conditioned looking boy, eleven years of age, of a nervo-bilious temperament, very active, and fond of out-door sports; but withal a good scholar, and fond of reading. Fifteen days before I saw him, he was at school, and in his usual health; but about seven o'clock at night, when he set to prepare his next day's tasks, he found he could not read common-sized book type, nor distinguish accurately any very small and near object. There was no pain, nor any apparent symptom of disease in either eye, both of which were equally affected. His general health was unimpaired, and he had not received any injury of the eyes, or of any other part. During the two following days the sight became rather worse; but from that time till I saw him it had been quite stationary. Excepting the administration of some laxatives, no treatment had been adopted. Previously to the invasion of this attack, his sight had been extremely good, and he had never before experienced any similar affection, or been subject to fits or other nervous diseases, although his father described him as of a very excitable disposition, nor had he been troubled with intestinal worms, at least since infancy.

"The eyes appeared perfectly healthy in every respect; in particular, the prominence of the cornea, the shape, size, and motions of the pupil and iris, the size and configuration of the images of a lighted taper reflected by the cornea, and the surfaces of the lens, were perfectly normal, as far as could be judged by a careful examination. The only complaint was the inability to read common-sized print, or to see minute and near objects; for distant ones he thought were as distinct as ever, but I afterwards ascertained that his distant vision was very slightly affected. To ascertain the state of his sight, I gave him a printer's specimen-sheet, containing a series of paragraphs in all the various sizes of book type, from "English" to "Nonpareil" and the smallest, "Diamond." He could read the "English" type, though not very fluently, and saw it best at eleven inches from his eye. Of the paragraph printed in "Pica No. 1," he could make out a word here and there. The paragraph "Pica No. 2" was almost quite illegible, and the smaller sizes of type could not be

read at all. Directing his attention to a dark green stable door in my back garden, he could distinguish the key-hole, which was two inches long by five-eighths of an inch wide, the distance being seventy-one feet; but he could not see some black iron spikes about seven inches long and probably one-sixth to one-fifth of an inch in thickness, in a dovecot at a distance of nearly seventy-eight feet; but which even to a good eye were not very perceptible, from their being in contrast with a slated roof. The power of the two eyes seemed to be perfectly equal. In order to know the effect of different kinds of glasses, I first gave him *concave* spectacles of different foci, but they rendered his sight much less distinct. I then tried him with *convex* ones, beginning with a pair of twelve inches focus. These improved his sight very much, so that he could read any size of type, from the largest to "Brevier No. 1" inclusive. With a pair of ten inches focus he could read "Minion No. 1." With a pair of nine inches he could read "Nonpareil No. 2," and even a few words of a still smaller type, "Diamond," though with difficulty. With glasses of eight inches focus he saw better; but with those of seven inches focus he saw better still, and could distinguish the smallest type I could procure. Still he could not count a series of black spots, 0·007 of an inch in diameter, placed on a white ground, without using a glass of six inches focus, and with this again he could not see ordinary sized type so distinctly as with glasses of nine inches focus.

"When he looked at a distant object through any of the above mentioned glasses, it appeared less distinct. With convex spectacles of fourteen inches focus, objects at nineteen feet were seen very distinctly, but at a greater distance, as from eighty to one-hundred and fifty feet, he saw best with glasses of from sixteen to twenty inches focus. When his eyes were fitted with convex spectacles of a focus best suited to the size of any one near object, the point of most distinct vision was at the distance of twelve inches; but six inches nearer, or ten inches farther off than this, vision became very indistinct. With the naked eye he could not see to read "English" at less than five and a-quarter inches, or beyond nineteen inches, and then only imperfectly, the range of distinct vision being from eight to seventeen inches; whereas an eye whose power of accommodation is unimpaired can read the same type, though with difficulty, at any distance from three and a-half to eighty-five inches, and quite easily from five to forty-three inches; thus proving that the eye of a healthy person in the prime of life has a mean power of accommodation to distances from five to six times greater than was possessed by the patient.

"From the favorable term of my former similar case, I resolved to adopt an expectant treatment, after first of all administering some anthelmintic remedy, with the view of ascertaining if the patient was infested with intestinal worms. I therefore recommended that the boy should get two doses of a mixture of ol. terebinth. and castor oil, and his evacuations should be carefully examined; and that if no worms were found, he should be kept from school, made to take active out-door exercise, with a rather spare diet. I strictly prohibited the use of spectacles on any account, as being very likely to confirm the disease, whilst, if it should become a permanent affection, they could always be resorted to. Along with this regimen I prescribed a weak solution of sulphate of quinine with compound tincture of valerian to be taken twice a-day, more as a *placebo* than with the hope of any specific benefit from its action; and at the same time I gave a favorable prognosis, and warned his friends that the cure might probably be tedious.

"I heard nothing more of this case from the 17th April to the 26th

June, when I had a letter from his father, informing me that the castor oil and turpentine were administered twice according to my directions, and had acted powerfully as a purgative, but that there was no appearance of worms in the evacuations; after that, he had rigidly pursued the regimen and taken the medicine I had prescribed, without any apparent benefit, till about the last week of May, when the sight began to improve.

"This improvement increased daily, and in about ten days after the eyes were as well as ever, and the boy had returned to school, where he had been for three weeks without any recurrence of the disease."

Mr. Ware also mentions the case of a boy eight years of age, who suddenly became presbyopic, and was repeatedly punished at school on account of his incorrect and defaced writing, the real cause being unknown to his master. After the presbyopia had continued a fortnight, and different local applications had been used without producing any sensibly good effects, a cure was accomplished by the application of leeches to the temples, and the use of purgative medicines. Two sisters of this patient were similarly affected. The elder, twenty years of age, had never been able to do fine work, and for three years had been greatly assisted by convex spectacles. The younger, a girl of fifteen, had been presbyopic for about a year, being obliged to use glasses whenever she read, or worked with her needle. This patient in the course of six weeks, during which she totally abstained from the use of glasses, was completely relieved from the necessity of using them, by the application of two leeches to each temple twice a-week. The elder sister, in the same space of time, experienced much relief from similar treatment, but was still unable to do fine work without glasses, partly in consequence of the long continuance of the infirmity, and partly on account of her not having abstained from the use of her spectacles with equal steadiness. (*Philos. Trans.*, 1813.)

Irregular Refraction.—Besides the two defects of vision dependent upon the refractive powers of the eye, described by Mr. Lawrence, there are some others resulting from the same cause which it may be interesting briefly to notice.

For the due performance of its function as an optical instrument, it is necessary that certain parts of the eye should be transparent, that the surfaces of the cornea and crystalline lens should present certain regular and definite curvatures, and that the crystalline lens should be accurately adjusted, both as regards its own axis, and its relative distance from the cornea and retina.

So many conditions being requisite for perfect vision, it is less surprising that defects should be met with, than that they should ever be absent. Indeed, there is no structure more wonderful than the eye, or one which displays nicer or more extraordinary adaptation of means to the end, or which furnishes stronger evidences of wisdom, power, goodness and design of an intelligent Creator.

Various deviations from their regular curvature occur, both in the cornea and crystalline lens. These, if considerable, may be detected by a catoptric examination of the eye, when some change will be observed in the form of one or of all the three images of a lighted candle. They may also be detected by the patient, if he will close one eye, and direct the other to some distant, well-defined, luminous object, not too bright, —the horns of the new moon, for example,—and turn his head in various directions. The cornua will then appear doubled, trebled, multiplied, or variously distorted; and careful observation of its appearance, under different circumstances, may lead to a knowledge of the peculiar con-

formation of the refractory surfaces of the eye; and may suggest the proper remedy.

Dr. Young states (*Philos. Trans.* for 1801), that his "eye in a state of relaxation, collects to a focus on the retina, those rays which diverge vertically from an object at the distance of ten inches from the cornea, and the rays which diverge horizontally from an object at seven inches distance.

"Mr. Airy, of Cambridge, discovered, a few years ago, that he did not usually make use of his left eye in reading, and that it was entirely useless on looking at any near object. This he at first attributed merely to habit, and thinking that it might be corrected by calling the left eye into use, he endeavored to read with the right eye shaded, but found that he could not distinguish a single letter, at least of small print, at whatever distance he placed the book. Some time after, Mr. Airy perceived that the image made in the left eye by a bright point, as a star, or distant lamp, was not circular, but elliptical, the major axis making an angle of about 35°, with the vertical and the upper extremity being inclined to the right. With concave spectacles (through which distant objects were distinct to the right eye) Mr. Airy found that, to the left eye, a bright object as those above mentioned, had the appearance of a well-defined line, corresponding to the major axis of the ellipse seen by the same eye unassisted. He also found that if he drew two lines crossing each other at right angles, and placed the paper in a certain position, and at a proper distance, one line appeared perfectly distinct, while the other was scarcely to be seen. On bringing the paper nearer to the eye, the fact with regard to the lines was reversed, the distinct becoming indistinct, and vice versa. 'All these circumstances indicated that the refraction of the eye was greater in its plane nearly vertical, than in that at right angles to it, and that, consequently, it would not be possible to see distinctly by the assistance of lenses with spherical surfaces.' Mr. Airy's object then was to construct a lens capable of refracting the rays in a certain point more powerfully than those in the plane at right angles to it; and after various ineffectual attempts, his purpose was effected by a person named Fuller, at Ipswich. One surface of the glass is cylindrical, the other spherical: both are concave. Vision is most perfect when the cylindrical surface is turned from the eye; and Mr. Airy can thus read the smallest print with the left eye as well as with the right, and may thus be said to have recovered the use of an organ, which, but for his own ingenuity, would have been permanently lost." (*London Med. Gaz.*, vol. i., p. 134.)

A similar defect has been observed by a clergyman in this country, to exist in both his eyes. For the following account of this case, by the gentleman himself, we are indebted to our skilful opticians, the Messrs. McAllisters, No. 48 Chestnut street, Philadelphia.

"From my earliest years I have been sensible of a deficiency in sight, which I was induced to call near-sightedness, because I was obliged to approach nearer to objects to see them than most persons, which is still the case. This deficiency, until I was about sixteen years of age, was accompanied with weakness of sight, but my eyes are now strong. I commenced my studies regularly at the age of nineteen, and am now twenty-four. Close study has had no other effect on my sight than to strengthen its endurance, but not its precision, or length. My right eye is, and always has been, much better than my left, but the defect in both is precisely of the same nature. At the age of sixteen I procured a pair of plain green glasses, which were some little assistance in moderating

the intensity of the light. I tried to get concave glasses, but could find none that were of any essential assistance. I afterwards used a small convex lens, of about ten inches focal distance as a microscope, to assist me in reading, which was some assistance, but during the five years of studying, I have used no glasses whatever. In November last [1825] I procured a pair of concave glasses in New York, about 5 or 6, which will accompany this letter. Until then, I had never discovered that a change of position had any influence on my sight; but in looking through these glasses, I found that any object, whose length is in a horizontal direction, appears much more distinct than a similar object, whose length is perpendicular to the plane of the horizon: thus, the cross-rigging of a ship appears much more distinct than the mast and perpendicular ropes. I have since been led to make experiments, first on my naked eye, and then on it, in connection with my glass, which I send you, and the result at which I have arrived has been universally the same.

"Suppose I stand in an erect posture, then let *f h*, *e g* [Fig. 92] be any object, the parts of which are equal and similar, and of which *f h* is perpendicular and *e g* parallel to the horizon. Then the part *f h* will appear plain, but the part *e g* will not. Now if I turn my head from a perpendicular to a horizontal position, the reverse takes place, that is, *e g* appears plain, but *f h* does not.

Fig. 92.

"Again, let *a b c d* [Fig. 93] be a circle; then if the above statement be correct, when I stand erect the parts *a c* and *b d* will appear plain, but *a b c d* will not, which is the fact. Furthermore, if I turn my head a right angle, (that is, to a horizontal position,) then *a b*, *c d* become plain, but *a c*, *b d* do not.

Fig. 93.

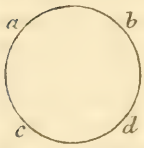

"It seems almost superfluous to add that a figure like *k l m n* [Fig. 94] appears uniform in both the lines *k n* and *l m* when the body is in an erect posture.

"These facts would lead me to conclude that the crystalline lens of my eye is cylindrically convex, or perhaps, oblately convex, and that its greatest length is in a perpendicular direction, (that is, in a line parallel with the length of my body,) consequently I would conclude that a glass whose shape resembled the probable shape of the crystalline lens of my eye, placed before my eye, so that its greatest length would be at right angles with the lens of the eye would produce a perfect image.

Fig. 94.

"All that I have said in relation to the diagrams above is strictly true in relation to my naked eye, and if I could here wind up the difficulty, I should stand in some hope, but the fact is, the moment I put on my concave glasses everything is exactly reversed, the line *f h*, which before appeared more distinct than the line *e g*, now becomes as much less distinct, and in relation to the circle the parts *a c*, and *b d*, which before were more distinct than the parts *a b*, *c d*, now become as much less so.

"The figure *k l m n*, of course, will appear much as it did to the naked eye, except that it is a little more distinct, and, perhaps, a little smaller, but what I mean is that it appears uniform through the glasses as it did to the naked eye. If it be true that my eye requires a glass

whose shape does not correspond to a portion of a true sphere, but rather to a portion of a spheroid or perhaps a cylindric, I cannot tell from any observation I have yet made on my eyes, whether the glasses should be of the concave or convex form. The great difficulty is, why should the appearance of objects be entirely changed by the interposition of a concave glass? When I purchased my glasses I was not aware of this curious fact, in regard to my eyes, either with or without glasses. I only knew that I got those through which, on the whole, I could see best. If it be asked whether I consider the glasses in question an essential assistance to my sight, I answer that if my object be to examine a horizontal object they truly are an assistance, and they are so in the examination of a perpendicular one, provided I turn my head a right angle."

Mr. McAllister provided this gentleman with a glass ground plane on one surface, and to a section of a cylinder on the other. This corrected the irregular refraction, and much improved his vision.

Mr. Prevost, at the age of 81 years, published (*Annales de Chemie et de Physique*, tom. li. p. 210,) an interesting account of his own case of double vision, with a single eye, which he thought might perhaps arise from a fracture, bruise, or partial flattening of the lens, or separation of its laminæ. Mr. Prevost also communicated with Mr. Babbage, who is affected in either eye singly with double vision, a defect, however, which he finds himself able to remedy by looking through a small hole in a card, or through a concave lens. (Mackenzie, op. cit., p. 795.)

We have met with a curious case of change in the refractive powers of the eye, in which the lenses acquired refractive properties analogous to those of Iceland spar. In this case, all perpendicular lines appeared double, while horizontal ones were seen accurately. This condition occurred during the progress of a severe catarrhal ophthalmia, and ceased on recovery from the disease.

Chrupsia, or colored vision.—"Patients," Dr. Mackenzie remarks, "who are partially amaurotic, complain not unfrequently of luminous objects, as a lighted candle, appearing to be surrounded by the colors of the rainbow. This symptom has been called chrupsia, and has been supposed to depend on some derangement of the lenses of the eye, by which the achromatic power of the organ becomes impaired. A young lady whom I attended for choroiditis, saw brilliant blue, green, and red colors playing over the objects she regarded, such as the face of a person sitting before her, or a white handkerchief held in her hand. In supposed cases of this sort, it would be proper to guard against our being deceived on the one hand, by those causes which might induce a decomposition of the rays of light by inflection merely, such as contraction of the eyelids, and, on the other, by such as might bring on ocular spectra.

"Another variety of chrupsia consists in seeing objects of a different color from that which is natural to them. Some patients see objects as if tinged of a yellow, green, or bluish color. Dr. Parry relates* four cases of this sort. In one of these, an old general, just before the lighting of the candles in the evening, and for an hour on first waking in the morning, saw all white objects of a deep orange color, approaching to scarlet. In another, a lady often saw white objects of a very bright blue color."

"A patient under my care with prolapsus of the nasal portion of the iris through an accidental wound of the cornea, saw all objects of a greenish hue." (*Practical Treatise*, p. 801.)

* Collections from the unpublished Medical Writings of C. H. Parry, M. D., vol. i., pp. 560, 568, and 569; London, 1825.

Photopsia.—Various sensations of light are sometimes perceived, as the result of disease in the optic apparatus. Flashes of light, the appearance of shining stars, a glittering as if from the points of innumerable needles or prisms, and a variety of other lucid spectra attend retinitis, and occur, as has been already observed (p. 508–9), in the commencement of certain kinds of amaurosis. "In some peculiar and distressing cases," Dr. Mackenzie observes, "the patient is annoyed by the sensation as if his eyes were directed towards globes of light swimming or revolving before him, or as if he were looking at a sea of molten gold."

"The distress," he adds, "which patients affected with such false sensations experience, varies greatly in degree; but, on the whole, these lucid spectra are both less supportable by those who experience them, and ought to be regarded as of a more alarming nature, than the semi-transparent or dark *muscæ volitantes*, which so frequently occur. Flashes of light are often the precursors of convulsive attacks, such as epilepsy; subjects inclined to apoplexy, on raising their heads after stooping, see showers of shining spectra; those who have suffered from internal ophthalmia are often troubled with such sensations as that of a luminous wheel rapidly revolving before them; and phrenitis is attended by false impressions of the same sort, which often continue long after all the other symptoms have ceased. In some instances, photopsia is merely a sympathetic effect produced from disordered digestion. After fever, or any disease in which the patient lies long in a horizontal position, photopsia is liable to occur. It generally subsides, as the patient becomes able to sit up.

"It is of great importance to ascertain the cause of photopsia, and to distinguish it accurately from photophobia. The latter often stimulates the former, especially in scrofulous, hypochondriacal, and hysterical patients. The cause of photopsia being discovered, the line of treatment can scarcely be mistaken. Sir David Brewster tells* us he knew of a case in which the patient had constantly the sensation of a luminous circle before him, in consequence of an excrescence on the inside of the eyelid, which produced a continued pressure on the eyeball. The removal of the excrescence would afford a cure in this case. When photopsia is owing to cerebral congestion, depletion will be necessary; when dyspepsia is the cause, purgatives, followed by tonics, will be proper.

The following interesting case of photopsia has been recorded by Mr. Ware, in the words of the patient himself, a medical practitioner.

Case.—"About 10 years ago, when about 48 years of age, I experienced the first attack of the malady which I mean to describe; and it has repeatedly returned at irregular periods, from that to the present time. The first notice that I have of the attack is a peculiar indescribable sensation at the bottom of the eye, which does not amount to pain, and is so slight that its reality is not to be determined, unless I direct my attention very particularly to it. After a few seconds the objects, in a small point, nearly in the centre of the field of vision, become indistinct; and, shortly afterwards, invisible. * * * * * * * * In a few seconds more, that is, in about half a minute from the commencement of the attack, the point that was invisible becomes lucid, appearing to be a circular spot, about the eighth of an inch in diameter; in which a yellow flame seems to undulate from the centre to the circumference with almost corruscating quickness and splendor. This spot increases by the extension of the undulating flame until it acquires an apparent diameter of about three quarters of an inch, which takes place

* Philosophical Magazine, for August, 1832, p. 90.

generally in about six or eight minutes. The fiery veil, which conceals objects, becomes then thinner in the centre, and objects are there seen through it. The vision increases, until at length a ring of light only remains, which continues to enlarge until it is lost by seeming to extend beyond the field of vision.

"The returns of the attack have been very irregular. Sometimes they have occurred daily for a week or ten days together; at other times more than a month has elapsed between their appearance. During one forenoon they returned almost every hour; but of late the intervals are much lengthened; and I have been now exempted from the malady more than three months.

"At first no pain was felt; but during the last 12 months, a slight uneasiness under the forehead, on the opposite side to that of the affected eye, has generally accompanied and succeeded the attack.

"The disease is common to both eyes, though it has never yet occurred in both at the same time. My sight is not injured, though the sensibility of the retina appears to be morbidly increased: a strongly illuminated object producing a more brilliant spectrum than it used to do.

"About six weeks ago, I first saw the unpleasing appearance of a small dark circular spot, which, varying its situation with every motion of the eye, showed how appropriately the term musca volitans had been applied to it. The possibility of its being a partial paralytic affection, resulting from the frequent morbidly increased action of the retina, naturally alarmed me; but six weeks having elapsed without any return, I am become easy concerning it. In this instance the immediate cause of the affection appears to have been an irregularly increased action of the retina; and the remote causes were an over eager exercise of the mind, joined with too long continued employment of the eyes, and a disordered state of the stomach and bowels.

"With regard to the means of cure, reprehensible as it may appear, I for a long time employed none. About three years ago, however, having been harassed repeatedly at short intervals, and sometimes two or three times in the day, by the above mentioned appearances, I called on you, and, by your advice, took a dose of five grains of calomel. After this the spectrum did not appear for several months; and when I again saw it, it yielded to a repetition of the same remedy. In the following year, having travelled two days together, and taken food of an improper kind, and in an irregular manner, the attacks on the third morning were so frequently repeated, that I was unable to see my way without difficulty and danger. I therefore stopped and took my dose of calomel; after which the spectrum immediately disappeared, and it did not return for many months. That which was black, as well as those which were lucid, were equally removed by the use of this medicine; and I have not now perceived either of them for a considerable length of time."*

* Medico-Chirurgical Transactions, vol. v., p. 274; London, 1814. See case of M. Savigny, Archives Générales de Médecine, Août, 1838, p. 495.

CHAPTER XXI.

CATARACT.*

SECTION I.—GENERAL DESCRIPTION OF THE DISEASE; ITS CAUSES AND TREATMENT; VARIOUS OPERATIONS.

CATARACT is a partial or general opacity of the crystalline lens, of its capsule, or of the MORGAGNIAN fluid, separately or conjointly, with a corresponding diminution of sight. BEER includes, in his definition of cataract, all those impediments to vision, which are situated in the posterior chamber, between the uvea and the front of the vitreous humor, (*Lehre*, vol. ii. p. 279,) whether arising from opacity of the lens, of its capsule, or of the aqua MORGAGNI; from the effusion of lymph under the inflammatory condition of the iris, and its subsequent organization into an adventitious membrane; from the effusion of blood or pus; or from depositions of the coloring matter of the uvea upon the capsule. He then divides cataracts into *true* and *spurious*. (*Ibid.*, p. 285.) Under the former head are comprised the opacities of the lens, capsule, and aqua MORGAGNI; while the latter comprehends all the others, which he has named *cataracta, lymphatica, membranacea, purulenta, grumosa*, and *dendritica*. (*Ibid.*, p. 303.) Under the last name, or those of *cataracta arborescens* or *choroidalis*, has been designated the deposition of the coloring substance from the uvea upon the front of the crystalline capsule. (See the remarks on this subject in Chapter XVI. p. 386.)

These *false cataracts* are various results of injury and disease, affecting the chambers of the aqueous humor generally, or the iris in particular; and their consideration belongs to other parts of this treatise. To call them cataracts, and thus assimilate them to the peculiar change of the lens and capsule, which has been usually and properly designated by that term, is a combination under a common name of affections totally distinct in their causes and nature, and likely to produce, especially with students, confusion and obscurity in pathology and treatment. I therefore employ the word cataract, in its old and more limited sense, to denote opacity of the lens, of its capsule, or of the MORGAGNIAN fluid, either separately, or combined.

The most striking circumstances observable in cataract are, an opacity placed behind, or in the pupil, and the impaired state of vision, which is the result of that change. The opacity, however, may be so inconsiderable in extent, as not to affect sight, though it comes under the technical denomination of cataract. In both the circumstances just mentioned, cataract agrees, in its incipient stage, with glaucoma and some forms of amaurosis; but as the treatment is essentially different in these several affections, it is necessary to discriminate them accurately. In incipient cataract we can do little or nothing; we must wait until the opacity has become complete, before we perform an operation: but active means must be resorted to in the earliest stage of amaurosis; if we should leave the case to itself under the

* The Greek word καταρακτης, from καταρασσω, to throw down violently, was not applied to this disease, which was called γλαυκωμα, υποχυμα, or υποχυσις. The Latin terms are equivalent, *suffusio*, the designation of cataract by the Latin writers. *Caligo lentis, gutta opaca*, in contradistinction to *gutta serena*, are synonymes. See the notes, at p. 490 *ante*.

supposition of its being cataract, loss of sight would be inevitable and irremediable.

Thus it is important to distinguish cataract from other affections; in doing which, under circumstances of doubt, we shall be much assisted by artificial dilatation of the pupil. Hence we should examine the eye in such cases, after the application of belladonna, so that we may obtain a clear view of the changes which may have occurred behind the pupil.

Cataract is usually formed slowly, requiring some weeks, months, or years for its complete development; it may, however, come on much more quickly, even in a few hours.* It seldom destroys sight completely, even when fully developed. Sometimes sight is hardly injured. In many forms of the disease a considerable degree of vision remains; and in the worst cases, the patients can distinguish light from darkness if the retina be sound.

It may appear in one eye, or in both. In the former case, the second eye is generally affected, sooner or later. In a few instances the complaint is confined to one eye.

* [Dr. Wendelstrom relates a case of cataract completely formed in a few hours. The subject of it was a robust peasant, sixty years of age, who enjoyed excellent health, suffering only occasionally from slight attacks of gout, eyesight very good. While felling wood he experienced a dimness of sight, which gradually increased, and within a few hours terminated in complete blindness. He had not the slightest pain or external inflammation. He was seen by Dr. W. a few days after this occurrence, at which time both lens were opaque, and were extracted. (*Am. Journ. of Med. Sci.*, Aug. 1829, p. 502.)

The following remarkable case of suddenly formed cataract in both eyes was communicated to the Surgical Society of Ireland (April 6th, 1842) by Dr. Martin, of Portlaw.

"Mary Grant, aged 35, of a miserable cachectic habit, after sitting up for several nights with her invalid mother, suffering much bodily and mental distress, and crying a great deal, fell asleep in the sitting posture, by the fireside, at about twelve o'clock, on the night of Friday, October 15, 1841. About four or five o'clock she awoke, and (although her vision was before perfect) she then found herself unable to distinguish any object around her, and when the clearer light of day came, she was but able to trace the outline of the window-sash. Having applied to me for advice, three days after, I was surprised on examination to find the lens of both eyes semiopaque, and presenting the appearance of being starred from the centre, as if breaking up during maceration. She complained of severe pains in the forehead, jaws, and shoulders—pulse 80, full and hard—tongue loaded with white fur —bowels confined. By means of blue pill, bitters, and blisters to the temples, the pains were removed, and her general health improved, but the lenses gradually became more opaque, and she is now unable to trace outlines of objects passed before her eyes, although the retina is perfectly sensible to the impression of light. That she had perfect vision up to the night on which she states she became blind, I feel perfectly satisfied, as on that evening, having been in attendance, I saw her moving about, and nurse-tending her mother, and I had seen her frequently during the previous month."

Dr. Martin also stated that he remembered, when a pupil, to have seen a somewhat analogous case. The man was a patient in Sir P. Dunn's Hospital, and the following was the history which he gave: he said that he had been married to a farmer's daughter, and after the usual fun of an Irish wedding, he retired to bed, his sight being perfectly good. Very early in the morning he was called by the necessities of nature to the outside of the house, when he became conscious of the loss of sight. Fearing the ridicule of his friends he made his way into the house to where his clothes lay, which he found with some difficulty, and left his bride to wonder at his loss for the next two months. He came up to Dublin, and was admitted into Sir P. Dunn's Hospital, where he was successfully operated on by Dr. Jacob. I need not add that his story was laughed at and disbelieved at the time; but I have little doubt now that it was analogous to that of Mary Grant. In his case also, as in that of Mary Grant, the blindness was not complete at once; in the end, however, both lenses became densely opaque. (*Dublin Med. Press*, May 4, 1842.)]

Color and situation of the opacity.—The color of the opacity in cataract may be described as gray, passing on one side into a milk white or bluish-white, and on the other into a yellowish-brown, or the color of amber. The opacity of the pupil in glaucoma is green, a dull green, or yellowish-green. Incipient cataract sometimes exhibits a similar tint, so that the mere circumstance of color is not sufficient to establish the diagnosis between the two affections.* The situation of the opacity is a better ground of distinction; in cataract it is near the pupil, and in many instances immediately behind that aperture; but in glaucoma and amaurosis the discoloration is deeper seated; it looks as if it were at the bottom of the eye. Hence, when we view the eye laterally in glaucoma, we lose sight of the opacity; it is only when we look directly into the opening that we see the discoloration, which also is equally diffused, the pupil appearing uniformly opaque. The opacity has generally a concave appearance in glaucoma, while in cataract it is convex.

Some observations are made on the distinction between cataract and glaucoma in the description of the latter affection; see Chapter XIX. § 3: in the first section of the same chapter, deficiency of the pigment is mentioned, causing a change in the appearance of the pupil, which may be mistaken for cataract.

State of vision.—In cataract the opacity generally begins in the centre of the pupil, and extends to the circumference; consequently, it is more dense in the centre and less so towards the sides. Hence light passes through the circumference of the pupil, enabling the patient to see objects laterally, when he cannot see them directly in front of the eye. For the same reason the mistiness of vision, accompanying the early stages of cataract, is greater in a bright than in a dull light. Dilatation of the pupil, by exposing the margin of the lens, which is sometimes transparent when the centre is opaque, and at all events is much thinner, and therefore less densely opaque, improves vision considerably, especially in incipient lenticular cataract. Such patients see best in the dusk or twilight, or when the pupil has been artificially dilated. They see best when the back is turned toward the light; in that position, and with the eye shaded by placing the hand above it, the pupil is so much dilated that a person with imperfect cataract may be able to read, while if he turns round and opens the eye against a strong light, he may be unable to distinguish a letter. These circumstances distinguish cataract from glaucoma and amaurosis; for in the latter affections, the sensibility of the retina being impaired, the individual sees best in strong lights, his sight is not improved by dilatation of the pupil, and he sees better when looking towards the window, than when his back is turned to it. Such differences are characteristic, and often sufficient of themselves to establish the diagnosis.

The mode in which vision is impaired by cataract is this: objects appear at first as if surrounded by a mist or fog; the patient fancies that something is interposed between his eye and what he looks at, whilst haziness or cloudiness increases gradually in proportion to the degree of opacity. The cloud becomes more dense, and conceals objects completely, and the affection advances so as to destroy all useful vision. Irregularity and confusion of sight, distortion, and multiplication of objects, which are sometimes

* [M. H. Cunier, in a report of the diseases treated at the Ophthalmic Dispensary of Brussels, invites attention to this form of cataract, which is often confounded with glaucoma, and the unfortunate patients thus abandoned to darkness. Dr. C. says, that he has met with eight cases of green cataract, which had been mistaken for incurable glaucoma. Seven of these patients were operated on and were restored to sight. (*L'Examinateur Médical*, 12th September, 1841.]

experienced in the beginning, probably arise from the striated or partial character of the opacity in certain cases. The various modes in which sight suffers in amaurosis have been particularized in a preceding chapter. A cataract patient sees a lighted candle as if it were involved in a cloud, which becomes thicker as the opacity proceeds, and ultimately shrouds the flame so completely, that its position only is discernible; to one with amaurosis, the flame of a candle appears as if scattered into rays like a star, or surrounded by a halo, or confused with prismatic colors. The sight is impaired in cataract in proportion to the degree of opacity; but there is no such direct ratio in glaucoma and amaurosis; for, with only a slight greenish discoloration of the pupil, there may be considerably impaired vision, such as the opacity would not account for; indeed, sight may be entirely destroyed, when there is only a slight discoloration of the pupil.

Iris and pupil.—The iris and the figure of the pupil are not affected by cataract, at least in the early period of its formation: the iris continues to move as usual; the pupil retains its natural figure. In some cases the lens is increased in bulk, which causes it to press upon and protrude the iris, and consequently impede its motions. The changes of the pupil and iris in amaurosis and glaucoma form a striking point of distinction. In the affections last mentioned, the pupil is generally more or less dilated, the iris motionless or sluggish, and the pupillary aperture not perfectly round, sometimes angular. In cataract with adherent iris, there may be want of motion in the latter, and irregularity of the pupil. It must be observed, however, that the pupil presents a black margin in cases of cataract; and that is to be explained by the circumstances of the white, or grayish-white ground, which the opaque body furnishes behind the pupil. The margin of the aperture is black, being formed by the uvea; but as the pupil also is black in the natural state, we do not observe this black edge until some light colored substance is placed behind it.

Beer (*Lehre*, vol. ii. p. 281), says that the dark ring round the pupil is principally owing to the black edge of the aperture, and hence that it is most conspicuous in light irides; but he adds that the iris throws a shadow on the cataract which contributes to the appearance. (See fig. 95.) This shadow is more strongly marked in proportion as the cataract is whiter, and placed at a greater distance behind the pupil. In a large capsulo-lenticular cataract, which fills the posterior chamber and projects against the iris, no shadow is formed.

Fig. 95.

In doubtful cases the nature of the affection is sometimes elucidated by its history. Cataract forms without any uneasiness in the eye or in the head, or any disturbance of the health; it has even been completely developed in one eye, without the patient being aware of its existence. Glaucoma and amaurosis are often preceded and accompanied by various uneasy sensations, by changes in the state of vision, which attract the patient's notice, and by functional disorder in other quarters.

[In the diagnosis of cataract, the catoptric examination of the eye affords the most unerring test.

In the early stages of lenticular cataract the brilliancy and distinctness of the inverted image are diminished; it has no longer a sharp and well defined margin, but its outline appears shaded off. This image gradually fades with the increase of the opacity, and long before the cataract is mature, the inverted image is obliterated. The deep erect image is also indistinct in the advanced stages, the anterior surface of the capsule giving only a general reflection.

In capsulo-lenticular cataract the inverted image fades much earlier

than in mere lenticular cataract, a very slight degree of opacity of the capsule sufficing to destroy its function of reflection.

Among the numerous cases we have seen, in which we have derived great assistance in our diagnosis from the aid of the catoptric test, we shall relate two which will serve to show its utility and to justify the confidence we repose in it.

In September, 1839, I was invited by my friend, Dr. G. W. Norris, to examine a mulatto man named Peter, in the Pennsylvania Hospital, who was supposed to be affected with glaucoma. The pupils had been dilated by the application of belladonna. There was opacity in both eyes, which was denser in some parts than in others. This opacity seemed more deep seated than is usual in cataract, and its color was of a greenish gray. Vision was, however, quite as good, perhaps better, than might have been supposed from the degree of opacity.

On holding a lighted candle before the eyes, the three images were visible. The anterior upright image was natural in all respects. The deep seated upright and inverted images were dull, their margins indistinct and of an unusual reddish tint. The inverted image in one eye, disappeared as the candle was moved opposite to the more nebulous portion of the lens, and when the observer looked at the eye of the patient obliquely, the second inverted image seemed to have a double point like the letter W. I did not hesitate from these phenomena to pronounce it to be a case of cataract.

A few days afterwards this man died suddenly and we were afforded an opportunity of examining his eyes.

The transparency of both capsules was impaired. A narrow streak at the posterior part of one lens, extending from near the margin to the centre, was quite opaque, and on applying a needle to this portion, we found it quite soft so as to be readily removed, leaving a depression. On carefully washing both lens so as to remove their superficial layers which were softened, as well as partially opaque, the remaining portion of each was found perfectly transparent and of a beautiful amber color. This color was the same whether the lens was viewed by transmitted or reflected light.

The second case was that of a man named Christian Minster, forty years of age, admitted into Wills' Hospital, October 7th, 1841. This man stated that he had recently come from the country, that he had been admitted in one of our public institutions, where he was pronounced to be laboring under cataract, and it was determined to operate upon him; but that, being unwilling to submit to this, he had eloped. In a letter which he showed from his physician in the country, his disease was said to be cataract.

The opacity behind the pupil had certainly great resemblance to that of cataract. The degree of vision he enjoyed corresponded to the degree of opacity—the independent and associate motions of the iris were tolerably active—and the patient saw best by twilight.

On applying the catoptric test, however, it was at once found to be a case of amaurosis and not of cataract. The three images were visible and of their natural appearance. The history of the case led me to ascribe the amaurotic affection to congestion of some portion of the nervous apparatus, and a course of treatment corresponding to this view was directed, consisting of counter-irritation to the back of the neck, purging, stimulating pediluviæ, &c. Under this course he improved so rapidly that in a week he could read with one eye a diamond print Bible. He subsequently had a relapse, but by the application of cups to the

head, pustulation with tartar emetic on the back of the neck, and afterwards ptyalism, he was completely restored. He was discharged cured in January following.]

Various species of cataract.—There are numerous sorts of cataract; different species more or less distinguishable from each other. They vary in the seat, color, and consistence of the opacity; in its complication with other affections of the eye, or particular states of constitution, and according to the age of the individual. An attentive consideration of these various circumstances is necessary, in reference to the choice of operation, and the chance of its success.

The difference of seat forms a natural basis of arrangement, in conformity with which, we may distinguish them into the *lenticular*, the *capsular*, the *Morgagnian*, and the *capsulo-lenticular.*

Lenticular.—The most frequent species of lenticular cataract is that called *hard* or *firm: cataract dura* or *tenax.* In this state of the lens, the opacity has a grayish appearance, with more or less of the yellowish brown or amber tint toward the centre. In the firm and darker colored portion, it resembles wax slightly softened by heat; the circumference is lighter colored, and softer, being about the consistence of soft jelly. The more we see of the amber color, and the deeper the tint, the harder is the cataract; the grayer its appearance, the softer is the consistence. What is called a hard cataract, is not in general hard throughout; the healthy lens differs in consistence, the circumference being much softer than the centre, and so it is with the opaque crystalline; the central portion is more firm than the rest. A grayish matter occupies the external part of the lens, while the centre, or nucleus, is of a yellowish color, and much more firm. Sometimes this brownish tint occupies the whole of the pupil; and the color of the lens has even been found of a dark brown, like the husk of the chestnut, or dark mahogany; and in these cases it is hard throughout; they are not, however, very common. An ordinary firm cataract, when extracted, presents the consistency and hardness of wax. I have never had an opportunity of seeing a cataract of a darker color than mahogany, but WENZEL* and BEER† speak of *black* cataracts; if they mean cataracts literally black, I have never seen any such.‡

* *Manuel de l'Oculiste*, vol. i. 109. WENZEL's *Treatise* translated by WARE, in *Observations on the Cataract, &c.*, 3d edition, p. 50.

† "In very old and thin persons we sometimes find the extracted lens in a state of marasmus senilis, as hard as wood, chestnut-brown, and flattened on its surfaces as if it had been squeezed. This, which has been called by some *cataracta nigra*, is difficult to recognise before the operation, and is often confounded with amaurosis."—*Lehre*, vol. ii. p. 309. ROSAS speaks of black cataract as being a blackish-brown or blackish-gray state of the lens.—*Handbuch*, vol. ii. p. 681.

‡ The second volume of AMMON's *Zeitschrift*, part 2, contains an essay on black cataract, by Dr. G. H. WARNATZ. It is a German version, in a more extended form, of the inaugural dissertation of Dr. WARNATZ, *de Cataracta nigra*, Leipsic, 4to, 1802. It contains a complete assemblage of the facts hitherto recorded on the subject; but it leaves the question respecting the existence of literally *black* cataracts just where it was before. P. 295—324, and 411.

[About four years ago M. MAGNE communicated to the French Academy the following case as an example of black cataract. It does not appear to us to be a perfectly conclusive case.

A female, above sixty years of age, had labored under some affection of the eyes, for which she had consulted a great number of oculists. She was quite blind; the eyeballs were prominent; the sclerotica appeared to be thin; the iris well shaped, but perfectly immovable; bottom of the pupil dark, as in the healthy state.

From these and other symptoms the disease was supposed to be amaurosis; but a second examination of the patient was made in a darkened chamber, and with the

The lens may be converted into an osseous or cretaceous substance; but such a case is very uncommon, and can hardly be said to come within the general description of the complaint; such changes have hardly been found except when the eye has been rendered amaurotic or completely disorganized by internal disease. Further details on this subject will be found in Chapter XIX. § 5.

The common firm cataract, which I have now spoken of, presenting the amber tint in the middle, gradually shaded off into a gray, is the ordinary form of the complaint in advancing age. We meet with it occasionally in perfectly healthy old individuals, in whom it is a strictly local affection, the constitution being sound, and no texture of the eye altered besides the lens and capsule. The lens is generally smaller than natural, and the capsule being unaffected, the opaque body appears at a small distance behind the pupil. There is a marked interval between that aperture and the cataract; the iris has its full play, and the patient retains the power of distinguishing objects during the formation of the cataract, by the passages of light through the less opaque circumference of the lens.

There is sometimes a hard nucleus with a soft circumference, so soft indeed as to be almost fluid; this has been called *cataracta fluido-dura.*

Lenticular cataracts are sometimes *radiated*, the opacity appearing in streaks or radii, with the intervals comparatively transparent. Those radii generally begin in the circumference of the lens; a circumstance which forms a striking contrast to the former species, in which the opacity first appears in the centre. In the ordinary state of the pupil, we can hardly see the radiated opacity, because the centre remains transparent; perhaps, a small white streak or two may be distinguished; it is not until we have dilated the pupil by belladonna, that we detect the opaque streaks in the circumference of the lens. These cataracts are slow in their progress, occupying two or more years in rendering the whole of the lens opaque. I have known instances in which very little change has taken place in the lens in three years. In some radiated lenticular cataracts the lines radiate from the centre, presenting an appearance similar to that which occurs when the lens becomes opaque after death.

Another species is the *soft cataract;* not soft in the circumference only, but the whole texture of the lens is changed, having various degrees of consistence. In firmness, the cataract may resemble cheese (*c. caseosa*), or jelly (*c. gelatinosa*), or milk (*c. fluida* or *lactea*). These are all degrees of consistence, from the hard to the fluid cataract.

Soft cataracts are larger than the hard; they occupy a greater space, so that they push against the iris, make its anterior surface convex, and interfere with its motions. Soft cataracts are gray, grayish-white, bluish-white, or

aid of a candle, as recommended by M. Sanson. The deep-seated images were absent, and M. Magne accordingly declared the case to be one of black cataract, with adhesion of the iris. The diagnosis having been confirmed by M. Cruveilhier, the lens on the right side was depressed, on the 25th of March, 1843. The adhesions of the iris were numerous; but as soon as the capsule was lacerated, the dark color of the lens became evident, and, on depressing it, several black fragments were detached.

On the second day after the operation the pupil appeared to be less contracted, the base being quite dark, but on the following day it was closed by a white substance. M. Cruveilhier regarded this as the lens, which had come forwards, after having lost its dark color in the vitreous humor. The operation was unsuccessful, and was, therefore, repeated in a fortnight; but the first touch of the needle showed that the body supposed to be the lens was, in reality, the capsule, which was extremely soft and elastic. A few shreds were removed with much difficulty, and the patient recovered but a very imperfect power of vision.]

milky, without any mixture of the yellow or amber color. The opacity is not uniform, but presents a streaked, cloudy appearance, especially in the beginning, so that we can see into, and almost through the lens. It is equally diffused through the latter, and the discoloration is consequently equal in the whole pupil. In the commencement of this kind of cataract, there is a partial reflection of light from the central or posterior part of the lens, producing a partial yellowish and almost shining metallic appearance, varying in apparent position as the light and the eye change their relative places. As the cataract is large, the opacity extends uniformly to the circumference of the crystalline; it intercepts the light more completely than the hard cataract does; and the patient at last retains merely the power of distinguishing light from darkness.

In fluid cataract the opacity presents an uniform appearance throughout. It is as dense in the circumference as in the centre of the pupil. It presents a dull gray cast, like that of thick gruel; or it may be yellowish gray, approaching to the appearance of cream. Sometimes it is a bluish-white, the cataract being then of milky consistence. In fluid cataracts the heavier parts may subside, so that after rest, with the pupil dilated, we can sometimes distinguish two distinct strata, of which the inferior is the most opaque.

Cataracta centralis.—The *opacity* of the lens is sometimes *partial*, being the form of a central gray spot, like a pin's head; or it may occupy a larger portion of the centre, as one-third or two-thirds of the diameter, leaving the circumference transparent.* This partial opacity is only known as a form of congenital cataract. In such cases the patient may see perfectly with the pupil so dilated, as to denude the transparent part of the lens; while he will be blind in a strong light, when the contracted pupil is completely obstructed by the central opacity.

In the ordinary firm lenticular cataract, where the change begins in the centre, and gradually extends, it is sometimes difficult in the beginning to distinguish the case from glaucoma, especially when the pupil is contracted. Under similar circumstances central opacity of the lens may escape observation. The real state of the case is easily recognized when the pupil is largely dilated. Hence the use of belladonna should not be neglected whenever we find it difficult to establish the diagnosis.

Morgagnian *cataract.*—Opacity of the fluid situated between the lens and its capsule, has been called *Cataracta* Morgagniana. I doubt the separate existence of such an affection. How can we determine that this fluid is opaque and the lens transparent? Can we suppose that this fluid could undergo such change, and the capsule and lens remain transparent? I think, therefore, that in a practical consideration of the subject, this kind of cataract may be safely omitted.

Beer states that the Morgagnian cataract is one of the rarest species; that it exists for a short time only in its pure form, as an opacity of the Morgagnian water; and that the lens itself is soon converted into a milky fluid, while the capsule generally becomes opaque. He says, that, according to his experience, it occurs suddenly, and only in consequence of the immediate influence of mineral acid vapors on the eye.† On another occasion he mentions, in addition to these acid vapors, those of naphtha and alcohol as capable of acting immediately and powerfully in producing cataract; and he then relates the following case: "In a woman of fifty-two I saw a pure Morgagnian cataract, perfectly developed within a few hours,

* Saunder's *Treatise*, pl. 4, figs. 3 and 5. Von Ammon, *Klin Darstellungen*, pt. i. tab. 9, figs. 13, 14, tab. 10, fig. 5.

† *Lehre*, vol. ii. p. 292.

from exposure of the eye for not more than a quarter of an hour to a fluid of which I did not know the nature. At the urgent demand of the patient, I operated on this cataract the following day, when I found the lens firm, but perfectly transparent, as was the capsule also."* The particulars of this strange occurrence are not stated in sufficient detail to enable us to estimate it pathologically. There can, however, be only one opinion on the extraordinary practice of operating the day after the cataract appeared, and when it should seem that one eye only was affected.

[The following is the only example of a condition of things at all resembling the description of Morgagnian cataract, which I have met with.

Drs. Neil and Kerr brought to me for examination, on the 30th of April, 1840, the eye of a woman, who had died the day before, in the Philadelphia Hospital, Blockley. They had not been able to ascertain the history of the case. They had divided the eye by a perpendicular incision through the centre of the sclerotica; and being struck with the unusual appearance of the lens, they placed the eye in water and brought it to me.

I found the lens covered with its capsule, which was more convex than natural; renitent as if distended by a fluid; somewhat opaque and very firm. Whilst squeezing it to ascertain what pressure it would bear, it broke, and some yellowish white fluid resembling thin pus, or milk and water, and equal in quantity to about one-fourth the bulk of the lens, was discharged. The lens was of a light amber color, somewhat smaller than natural, but perfectly transparent.

The opacity of the capsule may possibly have been merely owing to its having been immersed an hour or two in water, but the fact of the capsule being much stronger than usual does not favor such a supposition.]

Capsular cataracts (*membranacea* or *capsularis.*)—These have been divided into the *anterior* and *posterior*, in which the front or back of the capsule alone is affected, and the *complete*, in which the whole capsule is opaque. The capsule is very different in texture from the lens, and it may therefore be expected that an opacity of the former will present different appearances from that of the latter. The former does not begin in the centre, but in any part of the membrane indifferently; it is not uniform, but in spots or streaks, with less opaque or transparent intervals. These opaque portions are of a glistening chalky or pearly white, the dense structure of the capsule giving a different character to the opacity from the jelly-like substance of the lens. The position of the opaque capsule distinguishes it sufficiently from a lenticular cataract; the latter is situated at a little distance behind the pupil; there is a recognizable interval between them; but the anterior capsular cataract is on a level with the pupillary margin of the iris, and we see that the opacity is on a level with the edge of the pupil itself, sometimes passing into the aperture. The capsule cannot become extensively opaque, without the lens also being affected. There may be a single streak of opacity in the capsule after iritis; but that does not constitute a cataract: the capsule may be more extensively but yet partially covered by a new adventitious membrane, the rest remaining clear. We know of no such case as a capsule generally opaque, containing a transparent lens.

The posterior part of the capsule may become opaque, the anterior portion and lens remaining transparent; in this case there is an opacity situate at a marked distance behind the pupil; its situation corresponds to the

* Lehre, vol. ii. p. 327. In the *Repertorium* he says that he had twice seen a healthy lens with opaque Morgagnian fluid, p. 61, 62.

known position of the capsule. We can even perceive that it presents a concave surface, and this deep-seated concave opacity is in partial streaks, the intervals of which are transparent. The small opaque striæ, with which the affection commences, are sometimes found on the circumference of the membrane, in a nearly circular arrangement, and are concealed from view until the pupil is dilated. The posterior capsular cataract has not that glistening white color which distinguishes the anterior, because it is seen through the lens, and thus acquires a yellowish and rather dull appearance. This change in the capsule is followed by opacity of the lens; it may exist, however, a considerable time before the lens begins to lose its transparency. Although the affection is comparatively rare, I have seen many cases of posterior capsular cataract; the patients are still able to read large, or even ordinary print, long after the existence of disease has been clearly ascertained. They can see much better when the eye is shaded, or when the pupil is artificially dilated. In the latter state we see distinctly the transparent spaces between the opaque radii, through which light passes to the retina. When opacity of the lens commences, which may not be for two, three, or more years, vision is more seriously impaired.

Mr. Tyrrell represents that the radiated opacity just described is seated, not in the capsule, but in the posterior hemisphere of the lens; and that he had ascertained the fact in performing the operation of extraction in cases presenting such appearances. (Vol. ii. p. 363.)

The existence of *perfect capsular cataract* cannot be easily ascertained; for if the anterior portion of the membrane be opaque, it will prevent us from knowing whether the posterior be so or not. With a slight opacity of the anterior, it may be practicable to see also the opaque posterior part of the capsule. But the lens will participate in the affection, and the case may be considered as a capsulo-lenticular cataract.

[A catoptric examination, when the opacity is slight, will often enable us to detect these several forms of cataract.]

A membranous or capsular cataract often remains when the lens has been absorbed, as in traumatic cases, or after needle operations, when it constitutes a form of secondary cataract. The opaque membrane is of a chalky or milky white according to its density; the opacity may be so inconsiderable, as to present a difficultly distinguishable film; it is usually unequal in degree in different parts. The surface is sometimes more or less irregular. This opaque membrane is generally near to the pupil, the margin of which is often adherent at one or more points. The opaque substance may fill up the entire space behind the iris, its circumference being connected to the ciliary body, or it may be deficient, in a greater or less extent, from laceration, or detachment at its circumference. According to these varieties, there may be either good vision or loss of sight.

Capsulo-lenticular cataract.—The *capsulo-lenticular* is a very frequent form of the complaint. Partial capsular opacity is frequently combined with firm lenticular cataract; the two strata are readily distinguished, not only by their color, but also by their position. Sometimes the lens is soft in capsulo-lenticular cataracts, and the capsule itself, having been the seat of disease, is more or less thickened and indurated. Hence the cataract is generally large, often pushing forwards the iris, and making it bulge against the cornea, so as to destroy for the time the anterior chamber. In these cases there is a combination of circumstances, which cannot fail to point out the nature of the cataract. The streaky appearance of the anterior portion of the capsule is seen on a level with the edge of the pupil; and we distinguish the opaque lens of a different tint through the less opaque portions of the capsule. As the lens is large, and as both it and the cap-

sule are opaque, vision is completely lost, except the mere distinction of light from darkness. The motions of the iris are often impeded by the bulk and mechanical pressure of the cataract.

The capsulo-lenticular cataract is sometimes caused by a chronic and almost insensible inflammation, or at least determination of blood to the eye, accompanied not unfrequently with symptoms of congestion in the head, with muscæ or flashes of light, and some degree of intolerance. Under this disturbance of the circulation, the color of the iris is sometimes altered, and the capsule undergoes changes from interstitial deposition, or from effusion of lymph on its surface, which lead to peculiar subsequent appearances. These vary greatly in different instances, and have been named as if they were so many distinct species of cataract; there is the *c. marmoracea* or *variegata*, with a marbled appearance; the *c. fenestrata*, with bars compared to those of a window; the *c. striata*, or streaked cataract; the *c. stellata*, the *c. punctata*, with spots of the capsule, and so on.

In severe purulent ophthalmia, especially in infants, the inflammation sometimes extends to the capsule of the lens, and produces a single central opaque spot, *c. capsularis centralis*. (Von Ammon, tab. 9, figs. 1—5.)

There is a *c. dimidiata*, in which one half of the capsule is opaque.

In the *c. trabecularis* (*c. capsulo-lenticularis cum zona* of Schmidt,* *cataracte barrée* of the French), a thick opaque bar stretches across the pupil, either in the perpendicular or horizontal direction, and adheres firmly to the pupil or uvea. Beer† says that this cataract is produced by violent internal inflammation, and that the bar is firm, or even cartilaginous. In a boy of twelve years old, in whom he extracted such a cataract from each eye, the bar was of osseous texture, and the capsule, which was almost cartilaginous, contained a small firm nucleus of lens.

In the *c. pyramidalis* a dense opaque mass of pyramidal figure projects into the pupil.‡

It happens, not uncommonly, that the lens begins to be lessened in bulk by a natural process of absorption; and in proportion as it shrinks, the capsule contracts upon it, and shrivels up. This shrunk capsule, which is much thickened and corrugated, more or less separated from the ciliary body, and containing a diminished or small lens, is called *cataracta arida siliquata*, or the *dry shelled cataract*, although no cataract can be dry, in the proper sense of the term.§

In some instances, where the opacity of the lens and capsule is combined with other affections of the eye, the latter not only shrinks up, but becomes detached from the ciliary body, so that a clear black margin surrounds it. In this state, it may oscillate backwards and forwards when the eye moves (*c. tremula*, or *shaking cataract*); it may even become quite loose, float-

* Ueber Nachstaar und Iritis, p. 21. † Ibid., 302

‡ Mr. Wardrop has represented such a cataract in the 2d volume of his Essays, pl. 12, fig. 6. It is "a lateral view of a conical-shaped opaque body, whose base rests on the capsule of the crystalline lens, and whose apex reaches the cornea. The pupil was quite movable, vision was impaired, and both eyes have been affected from the time of birth. The drawing was taken from a boy four years of age."

A pyramidal capsular opacity in conjunction with conical cornea is represented by Von Ammon, Klinische Darstellungen, pt. i. tab. 10, fig. 8.

§ This name was given to the cataract in question by J. A. Schmidt, who represents that it is found in young persons who have suffered from convulsions in infancy. He ascribes to the convulsive movements of the eye that partial separation of the capsule at its circumference, to which he refers the peculiarities of the cataract. The *cataracta arida siliquata* occurs in young subjects, and as a congenital affection; but I have not traced the action of the cause mentioned by Schmidt. Ueber Nachstaar und Iritis, p. 20.

ing behind the iris, or passing into the anterior chamber (*c. natatilis, swimming* or *floating cataract*). In the latter case there is generally a tremulous motion of the iris.

There is a *cataracta gypsea*, or change of the capsule into a kind of cretaceous substance; it forms a thin shell, brittle, and of a yellowish hue. See Chapter XIX. § 5.

Under the name of *c. capsulo-lenticularis cum bursa ichorem continente*, BEER (*Lehre*, vol. ii. p. 301) and SCHMIDT (*Ueber Nachstaar*, p. 20, 21) have described a cataract of yellow color, in which a cyst of matter, sometimes stinking, is found between the lens and the posterior portion of the capsule. If the capsule be extracted, this cyst comes out of the eye entire, "containing," says SCHMIDT, "a thick, yellow, badly smelling ichor." He observes, that extraction is always followed, in these cases, by iritis and loss of sight, and that such was the result in eight cases in which he operated. I have never seen this cataract, and BENEDICT states that he has not met with it. (*Handbuch*, vol. iv. p. 64.)

The varieties now described arise from the partial and irregular distribution of the newly deposited substance which causes the opacity; from partial thickening of the membrane; or from adventitious external deposits on its surface during inflammation, becoming afterwards organized. These changes for the most part render the capsule thicker and firmer than in the natural state. Hence, in operations it is tough, and resists the knife, so that we often find a difficulty in dividing it.

Varieties of color.—The lens may lose its transparency in consequence of internal ophthalmia, and present appearances more or less similar to those I have already enumerated. It may be of a dull green, a yellowish green, or a brighter yellow color; sometimes it is of a dirty white. All such cataracts are the consequences of internal disease of the organ, and in that respect are to be distinguished from those changes in the lens and capsule which are not preceded or accompanied by other diseases of the eye. In the latter, or cases of simple cataract, the color of the opacity, according to the foregoing description, is gray, yellowish gray, or grayish brown, to dark brown, milky or chalky white, sometimes pearly or silvery.

In young persons, the cataract is almost invariably white or gray; generally of milky, or bluish-white tint. When a brownish or yellowish state of the lens is seen in a young person, it may almost certainly be ascribed to internal disease of the eye; for example, to the commencement of the medullary fungus; although a similar color in an old person would not indicate the existence of any such disease.*

Varieties in consistence.—The varieties of consistence in cataracts are of great practical importance, as they principally determine our choice of operation. The firm lenticular cataract is the only one to which the epi-

* Attempts have been repeatedly made to represent in colored figures the characteristic appearances exhibited by the various species of cataract; for example, by Mr. SAUNDERS, in his posthumous Treatise on some Practical Points, &c., pl. 4—7; by Mr. TRAVERS, in the Medico-Chirurgical Transactions, vol. iv. pl. 2; by BEER, in his Leitfaden, vol. ii. pl. 3; by Mr. WARDROP, Essays, vol. ii. pl. 9, 11, 12, 13; by VON AMMON, in the first part of his Klinische Darstellungen, tab. 9, 10, 11, 12, containing 129 figures; and by Mr. TYRRELL, vol. ii. pl. 4.

Of the appearances attempted to be represented in these engravings, some are readily observed and easily depicted; while it is impossible to convey any clear notion of many others in this way, since they are only recognizable in the living body on close inspection, even by those who understand the subject. The figures given by BEER and WARDROP are the best on this, as well as on the other morbid affections of the eye represented by them. Those of BEER were colored by himself. Among the numerous figures of VON AMMON there are several instructive and useful representations.

thet *hard* can be properly applied; the lens is never found osseous in cases proper for operation. The consistence of the lens in this form of the complaint, is too firm to admit of its being divided or broken by the needle; and it undergoes absorption so slowly, that its removal by that process is extremely tedious. The *cataracta gypsea* may be enumerated among the hard; and several of the capsular, or capsulo-lenticular cataracts are at least dense and tough, so as not to be easily torn or cut by instruments employed within the eye. The caseous and gelatinous cataracts form a transition from the hard lenticular to the milky, which is quite fluid. The needle moves freely through the gelatinous lens, which is milky white; and the crystalline is found in this or in a fluid state in infants, and in young persons to the age of twenty or thirty.

Mature and immature.—Cataracts have been distinguished as *mature* and *immature.* The former term may be used when the change is fully developed, according to the nature of the case. This distinction, however, has been made chiefly in reference to the time for operating; and a common notion prevails, that the operation ought not to be done till the cataract is ripe. This opinion is not altogether unfounded; certain cataracts are the result of vascular congestion, if not of inflammation, and in these cases it is unfavorable to operate early. We should wait until the change has been completed, and until all symptoms of fullness are at an end.

Complications.—Cataract may be purely local, the morbid affection being strictly confined to the lens and capsule; it may be accompanied with various affections of other parts of the eye, particularly of the iris and pupil, the vitreous humor, and retina; or it may be complicated with unhealthy states of constitution. According to these differences, cataracts may be characterized as *purely local*, *locally complicated*, *generally complicated*, *complicated locally* and *generally*. These points must be carefully inquired into before we can recommend an operation, or determine what mode of operating may be most advisable.

Adhesions of the pupil.—When we consider that the uvea, if it does not touch the capsule, is separated from it only by the thinnest pellicle of fluid, and that the capsule may become inflamed, thickened, or covered by an effusion of organizable lymph, we can easily understand how adhesions may be formed between it and the uvea or pupillary margin. Such preternatural connexions take place in traumatic cataracts, and still more in those consequent on acute internal ophthalmia. In the latter, the capsule is covered by a thick tough adventitious membrane, which is the medium of a close general union between it and the uvea. The adhesions consequent on inflammation may be partial or general, and they are often accompanied with change of color in the iris. The same internal ophthalmia which has produced these effects, will generally be found to have caused change of structure in the retina, with great injury, or loss of sight. For this reason considerable or general adhesion is an unfavorable complication. Indeed adhesions, under all circumstances, produce more or less difficulty in operation. We sometimes see slender partial adhesions by dark threads, from which we infer that there has been a slight degree of inflammation, although it may not have been manifested by other signs. The large soft cataract, which pushes forwards the iris, is not usually adherent. Opacity of the capsule is frequently combined with adhesion, but not necessarily so. The pupillary margin is sometimes connected by one or more slender dark threads to a capsule apparently clear.

Glaucoma.—Cataract may be combined with glaucoma; and this is a combination of which we can hardly be aware, unless we have seen the case previously to the occurrence of the cataract. The glaucoma occurs

first, and the lens is affected subsequently; but a careful examination of the history of the case will generally lead us to discover the previous existence of disease in the vitreous humor and retina. If the iris is altered in color, if the pupil is dilated, and fixed in the dilated state, if the sight was lost with considerable headache and pain in the forehead, and if it was gone before the cataract formed, we may fairly infer that the eye is glaucomatous.

The existence of synchisis in conjunction with cataract will be shown by a tremulous state both of the iris and cataract, by softness of the globe, and complete loss of vision. BEER, (*Repertorium*, vol. i., p. 61,) however, says that he has extracted tremulous cataracts with a large efflux of fluid vitreous humor, and recovery of sight. Of course an operation should not be performed, unless there is clear evidence that the retina is sensible.

Amaurosis.—It is not uncommon to have cataract complicated with amaurosis: in these cases, the amaurosis will be indicated by the complete state of blindness, by the patient not being able to discern light from darkness. This, however, is only seen in complete amaurosis: imperfect vision may remain, the sensibility of the retina being impaired, but not wholly destroyed. We must attend to the symptoms under which the loss of sight has occurred, as well as to the present state of the eye. In cataract, objects are concealed by a mist or cloud gradually increasing in density: the amaurotic patient is troubled by the sight of imaginary objects, of muscæ, scintillations, or other luminous appearances. If these latter symptoms have existed, or are still present, we may infer that in addition to the cataract there is, or has been, affection of the retina. Simple cataract comes on without pain, while in amaurosis there is often considerable pain in the head, or neighborhood of the eye, and generally more or less uneasiness. In cataract the iris has its natural power of motion; while in amaurosis the changes in the pupil take place imperfectly, or are suspended, and the opening itself is often dilated. A motionless iris, therefore, would excite suspicion, and lead us to examine the case minutely, if it should be observed where the cataract is not large, and the pupil unadherent. A dilated state of the opening would be an additional evidence of amaurotic affection. We shall generally derive assistance, in estimating the state of the retina, from comparing the two eyes. It seldom happens that both are affected in the same degree; the earlier stage in one eye may throw light on the more advanced complaint of the other.

Varieties dependent on age.—All ages are subject to cataracts; children are even born with them, and they may occur at any age from infancy to the remotest period of life; perhaps elderly persons are most liable to the complaint, especially at the age of fifty, sixty, or upwards. Cataracts are never hard in children; we scarcely meet with a hard lens below the age of puberty; they are not always hard in old persons: we may have soft cataracts in the old, and hard ones in the middle period of life.

The complication of cataract with diseases in other parts, and with unhealthy states of constitution, is obvious enough. The latter is an important point in reference to operation and its results. We must proceed very cautiously with the gouty, for fear of iritis.

Causes.—The well-known effect of inflammation, in producing opacity of parts naturally transparent, would lead us to expect that inflammation is a common cause of cataract. In some instances it is obviously the result of inflammation; internal ophthalmiæ will produce opacity of the lens and capsule; arthritic inflammation of the posterior tunics will render the lens opaque. Wounds of the lens and capsule produce opacity of these parts, and as such injuries generally give rise to severe inflammation, it might be

inferred that traumatic cataract could be traced to the inflammation produced by the wound. The opacity consequent on a wound may, however, occur without any evidence of inflammation. Soft capsulo-lenticular cataracts often form in consequence of congestion in the organ. Their formation is attended, in many instances, with all the signs indicating an unusual determination of blood to the head, and general fullness of the system. We cannot, however, generalize the observation, and say that inflammation is invariably the cause of cataract; we cannot suppose that inflammation has produced the cataract which we see in new-born children. We see that cataracts are common in old persons of healthy constitution, who are not sensible of any uneasiness in the eye, in whom there is no appearance of vascular excitement, nor any other disorder. We cannot refer the change to inflammation, and we must acknowledge that the cause has not hitherto been satisfactorily elucidated in such instances. In fact, the nutrition of the lens, the mode of its connection with the surrounding parts, and its manner of growth, are not understood. The lens undergoes some natural changes in age; its convexity is lessened, and it loses that colorless transparency which distinguishes it in the early and middle periods of life. Its nucleus is of a light yellow color at thirty; the tint gradually becomes deeper, until the lens resembles a portion of amber at seventy or eighty. In most cases of cataract, the direct cause of this particular change in the lens is unknown. Neither do we know that any peculiar state of constitution is favorable to its development.

[The discovery of Sir David Brewster, of a singular change of structure, which takes place in the crystalline lens after death, consisting in the development of a negative polarizing band or ring between the two positive rings nearest the centre of the lens; the gradual encroachment of this new structure upon the original polarizing structure of the lens; and the final bursting of the lens after it had swelled to almost a globular form by the absorption of distilled water, has led this eminent philosopher to entertain some peculiar views relative to the cause, prevention, and cure of cataract, which are of sufficient interest to deserve a notice.

"As the crystalline lens floats in its capsule, there can be no doubt," Sir David Brewster observes, "that it is nourished by the absorption of the water and albumen of the aqueous humor, and that its healthy condition must depend on the relative proportion of these ingredients. When the water is in excess, the lens will grow soft, and may even burst by its over absorption; and when the supply of water is too scanty, the lens will, as it were, dry and indurate, the fibres and laminæ formerly in optical contact will separate, and the light being reflected at their surfaces, the lens will necessarily exhibit that white opacity which constitutes the common cataract.

"This defect in the healthy secretion of the aqueous humor, as well as the disposition of the lens to soften or to indurate by the excess or defect of water, may occur at any period of life, and may arise from the general state of health of the patient; but it is most likely to occur between the ages of 40 and 60, when the lens is known to experience that change in its condition which requires the use of spectacles. At this period the eye requires to be carefully watched, and to be used with great caution; and if any symptoms appear of a separation of the fibres or laminæ, those means should be adopted which, by improving the general health, are most likely to restore the aqueous humor to its usual state. Nothing is more easy than to determine at any time the sound state of the crystalline lens: and by the examination of a small luminous image placed at a distance, and the interposition of minute apertures and

minute opaque bodies of a spherical form, it is easy to ascertain the exact point of the crystalline where the fibres and laminæ have begun to separate, and to observe from day to day whether the disease is gaining ground or disappearing.

"In so far as I know, cataract in its early stages, when it may be stopped or cured, has never been studied by medical men; and even when it is discovered, and exhibits itself in white opacity, the oculist does not attempt to reunite the separating fibres, but waits with patience till the lens is ready to be couched or extracted.

"Considering cataract, therefore, as a disease which arises from the unhealthy secretion of the aqueous humor, I have no hesitation in saying that it may be resisted in its early stages, and in proof of this I may adduce the case of my own eye, in which the disease had made considerable progress. One evening I happened to fix my eye on a very bright light, and was surprised to see round the flame a series of brightly colored prismatic images, arranged symmetrically, and in reference to the septa to which the fibres of the lens are related. This phenomenon alarmed me greatly, as I had observed the very same images in looking through the lenses of animals partially indurated, and in which the fibres had begun to separate. These images became more distinct from day to day, and lines of white light of an irregular triangular form afterwards made their appearance. By stopping out the bad parts of the lens by interposing a small opaque body sufficient to prevent the light from falling upon it, the vision became perfect, and by placing an aperture of the same size in the same position, so as to make the light fall only on the diseased part of the lens, the vision entirely failed.

"Being now quite aware of the nature and locality of the disease, though no opacity had taken place so as to appear externally, I paid the greatest attention to diet and regimen, and abstained from reading at night, and all exposure of the eyes to fatigue or strong lights. These precautions did not at first produce any decided change in the optical appearances occasioned by the disease; but in about eight months from its commencement I saw the colored images and the luminous streaks disappear in a moment, indicating in the most unequivocal manner that the vacant space between the fibres or laminæ had been filled up with a fluid substance transmitted through the capsule from the aqueous humor. These changes took place at that period of life when the eye undergoes that change of condition which requires the use of glasses, and I have no doubt that the incipient separation of the laminæ would have terminated in confirmed cataract had it not been observed in time, and its progress arrested by the means already mentioned. Since that time the eye, though exposed to the hardest work, has preserved its strength, and is now as serviceable as it had ever been.

"If the cataract had made greater progress, and resisted the simple treatment which was employed, I should not have hesitated to puncture the cornea, in the expectation of changing the condition of the aqueous humor by its evacuation, or even of injecting distilled water or an albuminous solution into the aqueous cavity."

The above views were presented to the British Association for the Advancement of Science, at their sixth meeting (1837). Since that period the author has not, so far as we know, extended his researches, nor have others repeated or verified his observations. The investigation, it is to be hoped, will, however, be pursued. Until this is done, and experiments upon animals shall show its safety, it will hardly be considered prudent to resort, in any case, to the measure suggested by Sir

David for the cure of cataract,—the injecting of distilled water or an albuminous solution into the aqueous cavity.

The opaque crystalline lens has recently been examined by Dr. Julius Vogel,* with the aid of a microscope, and his very interesting investigations show that, at least in the lenses examined by him, the opacity resulted from a change in the structure of the prismatic fibres of the lens. In these instances there was no *separation of the fibres*, as was conceived to exist by Dr. David Brewster, in cases of cataract. Neither was there any deposit of lymph, so that the opacity could not have been the result of inflammatory action, but may be inferred to have been the consequence of some defect in nutrition.

The lens in one case examined by Dr. Vogel, was extracted from the right eye of an old man. The cataract was complete, the lens being turbid, perfectly opaque, and of a reddish or brownish-yellow color. Portions from the surface of the lens, when examined under the microscope, presented the remains of the prismatic fibres peculiar to the lens, which were clear, transparent, and perfectly normal in all other respects. Scattered between these fibres was a considerable number of small, very dark granules, possessing a distinct molecular movement; they were probably black pigment granules which were accidentally adherent to the fibres.

In order to find out the seat of the opacity, thin slices were made of the substance of the lens with a double knife; these sections were made parallel with the axis of the lens, in the direction from before backwards. Under the microscope, on these sections were seen the prisms of the peripheral strata of the lens perfectly clear and colorless; whereas towards the middle of the lens these prisms became more and more dark. They had a granular appearance, and presented a number of dark longitudinal striæ, arranged, for the most part, in a parallel direction. From this it appears that the prismatic fibres of the substance of the lens had themselves become darkened and opaque. There were seen all the intermediate stages between the perfectly clear and transparent fibres at the margin of the lens, and the completely turbid and opaque ones in the centre. When treated with the acetic acid, the fibres were not in reality altered; the dark opaque ones, however, after the long-contined influence of the acid, manifestly became clearer, though the turbidity did not entirely disappear. With ammonia, also, the opaque fibres became clearer, yet without the opacity entirely disappearing.

A microscopic examination of many other opaque lenses, which were extracted and examined immediately after the operation, gave exactly the same results. The prismatic fibres themselves in the substance of the lens invariably appeared turbid; there was never detected any foreign opaque substance deposited between the fibres. As a rule the turbidity of the different fibres was extended equally over the greater part of one and the same fibre, so far as the microscope could trace it, yet the degree of turbidity varied considerably, so that there were constantly observed all the intermediate degrees between the perfectly transparent and the perfectly opaque fibres. In all cases the opacity was greatest towards the centre, and gradually diminished towards the circumference.

Among the predisposing causes of cataract, may be enumerated hereditary tendency. Instances of the occurrence of this disease in individuals whose parents had been affected with it about the same age, are not un-

* Erläuterungstafeln zur Pathologischen Histologie. Translated by W. S. Kirkes, in London Medical Gazette, May 2, 1845.

common. Mr. S. S. Dyer, records (*Provincial Medical and Surgical Journal*, Aug. 19th, 1846), an instance in which the disease was transmitted to the male subjects of three generations, none of them escaping. The females were all exempt.]

Treatment.—In central capsular cataract, where the opacity is a white spot not larger than a pin's head, vision is not affected, and no treatment is required. The same observation is applicable to central lenticular cataract in certain cases.

The effect of the latter on vision will depend on the extent of the opacity. If this is greater than the size of the pupil in its contracted state, sight will be imperfect when the eye is exposed to strong light, although it may be perfect under opposite circumstances. The remedy here is in the regular use of belladonna, which keeps the pupil permanently enlarged beyond the extent of the cataract. If the latter, whether lenticular or capsular, is more considerable, occupying, for example, the central two-thirds of the pupil, or even more, vision will be still more imperfect; the patient will examine objects with his back to the light, and will look at them obliquely. Sight will probably be sufficiently improved under artificial dilatation of the pupil, to render an operation unnecessary.

During the progress of cataract, especially of the lenticular species, more or less benefit to vision will be derived from the use of belladonna, which is thus, in such cases, both an aid to diagnosis, and an important measure of palliative treatment.

General or local measures may occasionally alleviate particular symptoms, or remove concomitant affections, but they have no influence whatever on the cataract. It may be asserted, without any qualification, that no external application nor internal medicines with which we are at present acquainted, can alter the condition of the opaque lens and capsule. When lymph has been effused upon the capsule, as in iritis, its absorption may be effected, while it is still recent, by proper means; but what I am now speaking of, is the opacity of the capsule and lens constituting cataract, which cannot be changed by any treatment hitherto discovered. We must then come to the operation, as the only means of restoring vision in such cases. However, as the state of the eye, in other respects, is so various, and as these several complications of cataract materially influence the chances of success from operation, we must, in the first instance, inquire carefully into all the particulars of the case, to ascertain whether complete or only partial success may be expected, or whether there is no reasonable prospect of benefit.

[" During the years 1834 and 1835, twelve patients, with confirmed cataract, were treated at the Hotel Dieu, by external and internal revulsives, and the other medicines recommended for the cure of cataract. This treatment was persevered in for four, five, six and eight months, and in two cases for eleven months, without any benefit. Dr. Caffe, however, states, that physiology, as well as some cases of disease which he has witnessed, leads him to believe in the possibility of sometimes arresting the progress of forming cataract, and even causing them to retrograde, in persons in early life, and in good health."—*La Presse Médicale*, May 27, 1837.

We do not know of any well-attested facts to justify Dr. Caffe's belief in the possibility of arresting cataract or causing to retrograde by medical treatment.]

Prognosis.—The prognosis is completely favorable when the affection is confined to the lens or capsule; when the sensibility of the retina is undiminished; when the motions of the iris are unimpaired: when the con-

stitution of the patient is sound, and the health is good at the time of operating; and when the patient is of a spare rather than a full habit. Under these circumstances success may be confidently anticipated if the operator understands the subject well, if he selects the kind of operation most suited to the particular species of cataract, and possesses sufficient manual dexterity for performing it in the most advantageous way. The prognosis is particularly favorable in congenital cataracts, in those of young persons, in whom, however, it seldom arises except in consequence of injuries, and in the firm lenticular cataract of elderly persons.

It is bad when the cataract is complicated with glaucoma or amaurosis; with a fluid state of the vitreous humor; with a varicose condition of the blood-vessels; with dropsy of the eye, or with a contracted or closed pupil. Indeed some of these circumstances would form decided objections to the operation. It is also bad when the cataract has been preceded or accompanied by severe pains in the head, or in the eye, by muscæ volitantes, sparks or flashes of fire before the eye; as all these circumstances indicate affection of the nervous structure.

The prospect is doubtful when cataract is the result of internal inflammation of the eye, or of that vascular disturbance which comes under the head of congestion.

Adhesions of the pupil are unfavorable, since the laceration and removal of them may excite inflammation in the iris and internal tunics, particularly in gouty individuals, in whom such adhesions are most frequent, and who are the most likely to suffer from inflammation after the operation. The prognosis is doubtful in cases of cataract affecting one eye, when the other is amaurotic or glaucomatous. If amaurosis or glaucoma should have occurred in one, there is great probability that the other may be affected in the same way. Before advising an operation in such a case, we should satisfy ourselves fully that the retina is sensible; we should carefully prepare the patient for the operation, and speak doubtfully of the result. If the evidence respecting the sensibility of the retina be not clear, it is better not to advise an operation, but to put the patient in possession of the state of the case, and let him determine between submitting to blindness and trying the doubtful experiment of operation.

The probable result of the operation is in some measure influenced by the age of the patient; the congenital cases are particularly favorable, as inflammation seldom follows; it is easily controlled if it should occur. In young persons the risk is less than in those at the middle period of life; the latter is perhaps the most dangerous time, excepting very advanced age.

The result of the operation is so important to the patient, the question being whether he shall regain sight or not, that it may seriously involve the reputation of the operator. It is, therefore, necessary that the most minute inquiry should be made into all the circumstances of the case, before the operation is undertaken; the history of the affection and the present state of the eye, the constitution, the previous and present state of the patient's health, should be well considered before advising or attempting any operation.

There are some cases in which it is better for the patient to be content even with imperfect vision, than to submit to an operation which may end in total blindness. The restorative powers are feeble in very old persons; in them, and in cases where the propriety of operating may be doubtful for other reasons, it is best to employ the palliative aid of belladonna, so long as it will procure any degree of useful vision. We should not, therefore, operate in such cases until the patient is quite blind; until his sight is in that state in which the failure of the operation cannot make him worse.

We cannot lay down a uniform rule respecting the time of operating. In general we should wait until the patient is blind, understanding by that expression the loss of useful vision. At all events, in doubtful cases, this rule is absolute. One exception may be mentioned, viz., where the cataract is mature in one eye and immature in the other. The former may be operated on, so as to give the patient the use of that eye, while the cataract is forming in the other. He will thus escape the irksomeness and the injury to health inevitably consequent on passing several months in a state approaching to blindness.

Another question is, whether we should operate when the cataract is confined to one eye; the general rule has been not to do so. The objection to operating in this case is, that the patient is no better off after, than he was before, and thus that he incurs a risk without an object. The other eye generally becomes affected sooner or later, and it will be time enough to operate then. It has been surmised that the removal of the cataract, when confined to one eye, may prevent its formation in the other. It would be difficult to prove the point; and there is as yet no sufficient proof of it before the public.

Himly* has questioned the propriety of the general rule. He inquires whether the occurrence of cataract in the second eye ought to be ascribed to the continued action of the cause which has produced it in the first, or whether it is owing to the sympathetic influence of the disease in the eye first affected. If the latter were the case, the removal of the cataract when it appears in one eye, might be expected to prevent the disease from occurring in the other. He quotes two instances, in which the removal of the opaque lens from the eye first affected, arrested the progress of an incipient opacity in the other eye. Beer (*Repertorium, &c.*, vol. i. p. 29), makes the following statement: "For a period of seventeen years I have closely observed those cases in which the operation for cataract had been performed in one eye, before any sign of the disease had been noticed in the other. In all such cases, I have found that the other eye has remained free from disease to the present time." In his last and great work, Beer adheres to the ordinary rule without even mentioning the other opinion. I consider that rule to be well founded, and act upon it generally. There may, however, be cases of exception; for instance, in young persons, especially females, where personal appearance may be materially affected by cataract in one eye. I have operated in some such cases, proceeding always with great caution, both as to the kind of operation, and the circumstances under which I have done it.

[Mr. Nunneley of Leeds, has discussed with much ability, the question of the propriety of operating in cases of cataract, where one eye only is affected, in a paper read before the Provincial Medical and Surgical Association. (*Provincial Journal*, Sept. 2d, 1843.)

Mr. N. conceives that the propriety of operating or not, must be mainly determined by "the state of vision after the operation," for he remarks, "I suppose, although it be granted a person sees sufficiently well with one eye, no one will deny, that, *cæteris paribus*, two eyes are better than one; and from the well-known fact that when the function of any organ or structure is long suspended, the power of exercising the function becomes ultimately lost, it is, as a mere result of precaution, extremely important to keep the affected eye in such a state

* Soll man den Staar nicht operiren, so lange der Kranke noch mit dem andern Auge gut sieht? in Ophthalmologische Beobachtungen und Untersuchungen. Bremen, 1801, p. 148.

of activity, that in case any accident or disease happen to the other, its powers, even though somewhat impaired, may then be taken advantage of; which can only be safely and effectually secured by having removed the opaque crystalline lens, and permitting the light to keep up the activity of the retina. The fear of the sound eye being injured or lost by the operation upon the cataractous one, though possible, is, I consider, hardly deserving of notice; because, when the operation is properly performed, it must be so rare, as to be rather amongst the possibilities than the probabilities. While, on the other hand, the sympathy between the two eyes, not only in their healthy state, but in their morbid condition, is so strong, that those who have been accustomed to watch ophthalmic affections, will at once admit the validity of the argument of removing any diseased condition of one eye, lest the other also partake of it, for the singularity is, that when disease exists in one eye, not only is the other apt to become impaired, but for the corresponding structure to assume the very same morbid condition. Thus, if the conjunctiva in one eye is affected, that of the other is also very apt to assume the same diseased action; if the cornea, the cornea; if the iris, the iris; the lens, the lens; and so on; while it is also incontrovertible that the morbid condition of the eye primarily affected being removed, that of the one sympathetically or secondarily involved, is also frequently remedied. Indeed, cases are on record where cataract having been removed in one eye, commencing cataract, or even amaurosis, in the other has been cured; and there must have been many, if not identical, at least analogous, instances. Indeed, in some cases where I have operated upon an eye in which cataract was fully formed, being only in an incipient state in the other, I have strongly suspected the progress of this latter has been much delayed by the removal of the opaque lens of the opposite eye.

"Now, although every one may not be inclined to think the remote risk of the sound eye being lost from injury or accidental affection very great, nor the danger of sympathetic disease so imminent as to justify our incurring any immediate hazard to it, by operative interference with the affected eye, yet no person will deny, that if, in reality, there is no such danger to the sound eye by operating upon the affected one, the possibility of these remote contingencies is solid argument in favor of active measures being at once resorted to. The last argument, of confusedness of vision being the result of an operation, is so very plausible, and, indeed, imposing, that it is this which has, I presume, principally determined the general practice of not interfering, when only one eye is affected, and which, I confess, formerly decided my practice; for I have sent many persons away without doing anything, which, with what I have since seen, especially in the three cases to which I shall now shortly allude, I should certainly not do. Indeed, the fact itself, that traumatic cataract sometimes disappears, as mentioned by Pott and Hey, rather than an argument against operating, is, in reality, a strong argument in favor of it; for, if not in all, at least in such of those cases, where traumatic cataract disappears, the capsule of the lens has been ruptured, and subsequently has been absorbed, thus occurring what it is the object of an operation to accomplish; yet in these cases no mention is made of inconveniences resulting from the cure; and when the lens had been so displaced as to press upon the iris, everybody agrees as to the necessity of manual interference, lest not only the one eye be altogether lost, but the other be implicated in the change."

Mr. N. relates three cases to show that "in point of fact, the double confusedness of vision, so much feared, does not occur," and concludes,

that "considering, on the one hand, the ease with which the operation may be performed; the little or no disturbance produced, either to the other eye or general health; that in many cases of traumatic cataract, where the capsule is ruptured, the lens is ultimately removed, even when the surgeon does not interfere; and that what has been so much feared, and in my opinion constituted the only valid argument against the operation, the difference in the refractive powers of the two eyes producing confused or double vision, in reality does not occur; and considering, on the other hand, the arguments above mentioned in favor of operating, I think we are fairly justified in recommending that, not only in traumatic, but in all cases where a young person, one who is under middle age, has cataract in one eye, the lens should be broken up, and removed by absorption."

Mr. Nunneley, it must be confessed, has controverted some of the arguments which have been adduced against operating for cataract in cases where one eye only is affected, but he has not been equally successful in presenting reasons in favor of the operation. The weightiest one he adduces is, that from long disease the power of the retina may be lost. This, though exceedingly plausible in theory, wants positive facts to confirm it; and we have numerous cases recorded, where vision was restored, after the existence of cataract for many years. Thus, Dr. Dubois of Neufchatel, (*Gaz. Méd. de Paris*, Nov. 1845, p. 721,) has operated for cataract in a case of 44 years' standing, and vision was restored. M. Serres has operated for cataract with success in a case where the disease had existed for sixty years, and Wenzel and others have operated in cases of fifteen and twenty years' standing, with the same favorable results.

Whether these cases form the exception or the rule, must remain to be determined, when more facts are collected. In the present state of our knowledge, we conceive the course pursued by Mr. Lawrence, to abstain, as a general rule, from operating, where one eye only is affected, is the safe one.

When useful vision is lost in one eye, and vision has become misty in the other from cataract, the question is a different one; and here we think, as a general rule, it is better to operate on the blind eye, principally on the score of the convenience of the patient, who will thus be preserved from entire blindness, which would take place by following the advice usually given, to wait until the cataract in the second eye is fully matured.]

OPERATIONS FOR CATARACT.

Preparation of the patient.—The success of surgical operations depends, in many cases, on preventing the subsequent occurrence of inflammation, and in none is this more important than in cataract. Hence it is necessary, not only to discriminate the several kinds of cataract, and know the operation best fitted for each, but also to inquire into the patient's health, and bring it into the state most favorable for operation.

The question is, what kind of preparation is necessary? One rule is very obvious; that is, not to operate on a patient with a foul tongue. A clean tongue shows that the alimentary canal is in a healthy state, and consequently leads us to a favorable conclusion as to the general health. For some days previous to the operation the patient should abstain from fermented liquors, and in certain cases from animal food also. The bowels

should be evacuated by some mild aperient every other day during this time: they should also be cleared on the morning of the operation. These remarks will apply to the majority of cases; and, usually, this is the only preparation necessary.

Some patients, however, require other preparatory measures; in plethoric subjects, and such as manifest determination of blood to the head, direct depletion is necessary. If the pulse were full, and the patient young and strong, it might be advisable to take blood freely, and even to repeat venesection before operating. In general it is sufficient to take some blood from the arm on the morning of the operation. Free depletion is occasionally necessary even in old persons. I remember the case of a woman, seventy years of age, who had amaurosis of one eye and cataract in the other; she was corpulent, with a full, bloated, and reddish countenance. She complained particularly of what she called weakness and nervousness, which she had endeavoured to counteract by the free use of animal food, porter, and other stimulants. She had considerable headache, with trembling hands and infirm legs; she was bled from the arm, the blood being strongly buffed, and cupped. The headache and nervousness were diminished by the bleeding, and she felt stronger. I kept her fourteen days before she was in a fit state to undergo the operation; and during that time she was bled four times, the first three portions of blood being buffed, and cupped, and the last free from these appearances. In addition to this direct depletion she was well purged, and kept on broth and gruel, with bread. After a fortnight's discipline of that kind I operated on the eye, and extracted the cataract, from which she recovered without one untoward symptom, and regained excellent sight. Another patient, who exhibited the highest degree of general plethora and particular determination to the head, was obliged to lose nearly 120 ounces of blood before he was in a fit state for the operation. He had not an uneasy feeling afterwards, and his recovery was rapid and perfect. These are examples of the preparatory measures which it may be necessary to adopt in particular instances. The great risk of failure is from the occurrence of inflammation; and in a matter of so much consequence, it is better to err on the side of caution. In some cases I have regretted that I had not attended sufficiently to these preparatory measures; but I have never seen reason to consider them superfluous or injurious.

The operation for cataract is sometimes required in those who are weak from delicacy of constitution or advanced age; in whom it would be inexpedient to institute any preparatory measures of depressing influence. This remark is particularly applicable where it is intended to perform extraction, as the recovery of the organ requires a certain degree of constitutional power. The operation has sometimes failed from deficiency in the restorative processes. It will be enough if we take care that the tongue be clean and the alimentary canal cleared on the previous day or the morning of the operation.

The existence of anxiety or distress at the time of the operation might have an unfavorable influence on its result: it would be safer to wait till tranquillity of mind was restored.

The next point for consideration is the choice of the operation. From the time of Celsus, in whose work we find the first account of an operation for cataract, until the last century, only one method was practised, that of introducing a small needle into the eye behind the iris, and pushing the lens downwards out of the axis of vision. That operation, inasmuch as it displaces the lens downwards, has been called *depression*: it is also called *couching*. It is accurately described by Celsus, and his manner of

performing it is nearly the same as that now practised. About the middle of the last century it happened, in consequence of an opaque lens having escaped through the pupil into the anterior chamber, that DAVIEL, a French surgeon, thought of making a cut through the cornea to let it out, which he did. Hence he was led to propose, and practise generally, this method of removing an opaque lens from the eye, which has since been called *extraction*,* and much improved. This operation consists in making an incision through the cornea, lacerating the crystalline capsule, and forcing the lens out through the pupil and the opening made in the cornea. When this operation was introduced, a controversy arose as to the merits of the two operations, extraction and depression, each of which had its warm advocates. The writers on this part of surgery have frequently drawn up, in parallel columns, the advantages and disadvantages of the two methods, and have usually endeavored to demonstrate the general superiority either of extraction or depression, as if it were necessary to choose one or the other, and practise it exclusively. More recently a third mode of operating has been introduced, and extensively employed, in which the lens is neither extracted nor depressed, but disturbed or divided, and left in its place to be removed by absorption. It is called the operation by *solution* or *absorption*. In this latter mode of proceeding, the needle may be either carried through the cornea and pupil, or be introduced behind the iris, as in the operation of depression. These two methods are distinguished by the names of the *anterior* and *posterior* operations. No person who understands the subject, would advise any one operation to be employed exclusively. Each method has its advantages, and is eligible under certain circumstances; our object then should be, not to adopt one operation with the view of practising it in all cases, but to consider the circumstances which give a preference to one or the other, and to select in each instance that which is best suited to the particular form of the complaint.

SECTION II.—EXTRACTION OF THE CATARACT.

The operation has usually been performed at all times of the year indifferently; but some operators have confined themselves to particular seasons. Mr. TYRRELL expresses himself strongly on this point. He says, "I am perfectly satisfied that the operation is most hazardous during the cold and damp seasons; so much so, that it is only under very particular circumstances that I now operate for extraction, in the period from October to March; the proportion of unsuccessful cases has been very much lessened since I have discontinued to operate in the cold and damp periods of the year."

I think it best to operate on one eye only at a time. If we restore sight in one, it is sufficient for all useful purposes, and the patient will generally be satisfied: the other may be operated on afterwards, or be retained as a reserve in case the restored sight should fail, or be lost by disease or acci-

* It seems probable that the Arabians were acquainted with extraction. At all events it is certain that the operation had been performed in France, long before the time of DAVIEL. MERY gives an account of its performance by J. L. PETIT in 1708. De la Cataracte et du Glaucome, par M. Mery; Mem. de l'Acad. des Sciences, 1708, p. 241. The honor, however, of expressly proposing extraction, as a regular operation for cataract, and of introducing it into practice, belongs undoubtedly to DAVIEL, whose proposal, communicated to the Academy of Surgery, is printed in the second volume of their Memoires; Sur une nouvelle Méthode de guerir la Cataracte par l'Extraction du Cristallin.

dent. When both are operated on together, they are not necessarily involved in any unfavorable subsequent occurrences; yet they are likely to suffer together from common causes, and under such circumstances the patient loses all chances of regaining sight. Again, serious inflammatory disturbance occurring in one eye may affect the other sympathetically. Thus, in many cases, both eyes, when operated on together, have been lost. On the other hand, if things go on unfavorably, it is a great consolation both to the patient and surgeon to know that one eye only is risked. Supposing the operation in the first eye to be unsuccessful, the progress of the case may afford us information respecting the individual, of which we may avail ourselves usefully in operating on the second eye.

Various circumstances contributing to the convenient and easy performance of the operation, and to the patient's comfort after he has gone through it, consequently exercising a more or less direct influence on its event, should be attended to previously; for example, an apartment with good light for the operation; a seat or couch on which the patient may sit or lie; an airy sleeping room, in which the light can be moderated or excluded; and a provision of bolster or pillows by which the shoulders and head can be supported at a proper height.

It is a matter of some consequence to have an attentive and intelligent assistant. The duty he has to perform, and the mode of performing it should be clearly explained to him.

The instruments employed in the operation should be prepared and carefully examined beforehand. They consist of two or more knives for dividing the cornea [fig. 96]; two narrow curved knives with blunt extremity, one cutting in the concavity, [fig. 97,] the other on the convexity, [fig. 98,] for the purpose of enlarging the incision, should that be required; a curette [fig. 99] for opening the capsule; it is a narrow, sharp-pointed, and slightly curved steel instrument. To the opposite end of the handle, a minute silver scoop is attached, sometimes called the spoon of Daviel. A small and fine hook, [fig. 100,] and a slender pair of probe-pointed scissors [fig. 101] may also be required.

A great variety of knives has been employed: the operation is undoubtedly difficult, and a hope has been entertained of removing or lessening the difficulty by some peculiarity in the instruments. We need not expect to overcome the difficulties inseparable from the operation by mechanical contrivance. One knife may be better calculated for the purpose than another, but a beginner will not find the operation easy with any instrument, and dexterity can only be acquired by repeated practice. The particular form of the knife is perhaps of no great importance. Lancet-shaped knives have been most commonly employed, of various breadths; such were used by Richter, Wenzel and Ware. The knife first used by Barth, the founder of the Vienna School of Ophthalmic Surgery, and now more commonly known as Beer's knife, [fig. 96,] is of triangular shape, straight on the back, with an oblique or slanting cutting edge, and gradually increasing in breadth as well as thickness, from the point to the handle. In my opinion it is the knife best adapted for the extraction of the cataract. It is ground lancet-shaped at the point, by which means it enters the cornea more readily; but it is blunt in the rest of the back.*

* Dr. F. Jaeger, of Vienna, has devised a new cornea knife, by which he proposes to obviate the inconveniences and dangers experienced in the ordinary mode of opening the cornea. The instrument is described and delineated by Dr. Loudon, in a quarto pamphlet, entitled A short Inquiry into the principal Causes of the unsuccessful termination of Extraction by the Cornea, &c., 1826. The instrument consists of a Beer's knife fixed to a handle, and of a smaller blade connected to the other by a but-

Fig. 96. Fig. 97. Fig. 98. Fig. 99. Fig. 100.

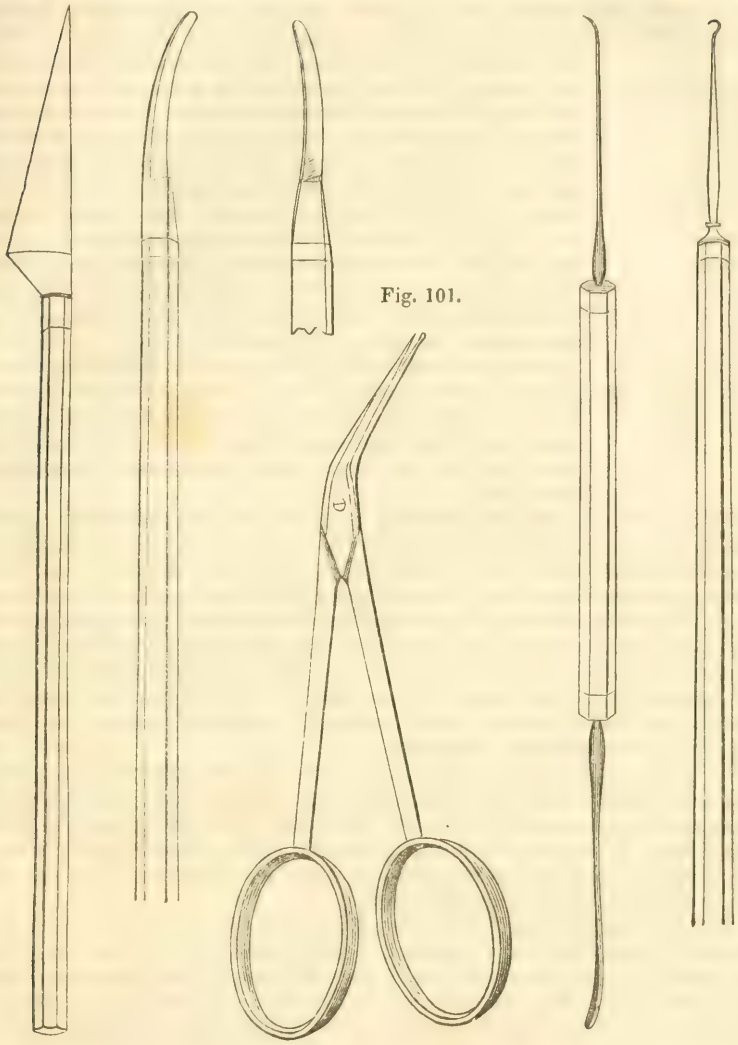

Fig. 101.

ton screw, so that it can be pushed forward upon it, or withdrawn. The knife is introduced, carried across the eye, and through the cornea on the opposite side, in the same way as Beer's. By pressing on the button with the thumb, the smaller blade is now pushed forwards, so as to complete the section of the cornea, while the globe is kept steady by the fixed blade.

From the contemplation of this double knife, Mr. Guthrie was led to construct another of a blunt silver blade, and a lancet-shaped knife to slide along it. He makes an opening in the cornea with a large Wenzel's knife; he then introduces his double knife with the blunt silver blade towards the iris, and the cutting-blade retracted; he carries it across to the inside of the cornea, and then presses forwards the cutting-blade so as to complete the section of the cornea.—Lecture on the Operative Surgery of the Eye, second edition, p. 344, plate 6.

These instruments, which take up much room, and are difficult to manage, can hardly be employed without great risk of injury to the iris.

Mr. Tyrrell has judiciously advised that the blade of Beer's knife, retaining the same depth at the shoulder, should be shortened, so that the breadth will increase more suddenly from the point to the shoulder. "The advantage of this alteration is, that the section of the cornea can generally be completed by a single thrust, before the point of the knife reaches the nose; whereas, in using Beer's knife, when the point has been carried as far as the nose will allow of, a considerable portion of the cornea still remains to be divided, beneath the edge of the instrument; and it is difficult to complete the division of this part." (Vol. ii. p. 392.) Beer's knife, as figured by himself, (*Leitfaden*, vol. ii. pl. 5, fig. 14,) measures one inch and three-eighths along the cutting edge. [See fig. 96.] The corresponding measurement of Mr. Tyrrell's instrument is one inch. [See fig. 102.]

Fig. 102.

Previous dilatation of the pupil by belladonna, is employed by some operators, while others object to it. I think that the iris is more out of the way of the knife, when under the influence of this narcotic; however, the pupil quickly contracts when the anterior chamber is punctured.

The patient should be placed near a window, which affords a good steady light: a northern aspect is preferable; at all events we must select a window which does not admit sunshine. He must not, however, be exactly opposite the window; because the light in that case will be reflected from the centre of the cornea, so as to prevent us from seeing clearly the point of the knife in its passage across the anterior chamber; this inconvenience will be obviated, if he is placed a little obliquely, with the eye to be operated on rather nearer to the window. One window only should be open; and the lower half must be closed by the shutters, as it is advantageous to have the light from above.

The operation may be performed with the patient either sitting or lying; the latter position is now most generally adopted. An ordinary couch answers the purpose very well, the end being about the proper height for the head. A convenient position may be easily obtained by placing a cushion or pillow under the body or head, or the patient may lie on a table, with the pillow under the head.

If the sitting position is preferred, the patient should be seated on a chair or stool, lower than that occupied by the operator, that the latter may have the free and easy use of his arms, without being obliged to elevate them inconveniently. The patient may be placed on a seat, with a back or without one; a chair with a sliding back is convenient; it can be adjusted to the height of the patient, who rests his head firmly against it. This is a preferable mode to that of fixing the patient's head against the breast of an assistant: it can be more depended on for steadiness. The operator easily adjusts his own height by sitting on a music stool, or placing one or more books on the seat of a common chair. If the operator is in front, he places his legs one on each side of the patient: if he wishes to give additional steadiness to his arm and hand, he may rest the elbow on his knee, raised to a proper height by placing the foot on a stool at the patient's side. The patient's head may be so inclined over the back of the seat, especially if it be a sliding one, as to allow of the surgeon operating from behind.

It has been the general practice to bind up the opposite eye, and this was recommended by Celsus; I believe it is a matter of little consequence. It has been said that if you keep the opposite eye quiet, that which is ope-

rated on will remain still also: I do not find that to be the case. It is sometimes advantageous to leave the opposite eye open, and direct the patient to look steadily at an object so situated as to bring the eye into a convenient position for the purposes of the operation.

Various instruments have been devised for keeping the eye steady, specula of different shapes; they are now entirely abandoned, as not only inefficient, but absolutely injurious. Some of these instruments have been made with little hooks intended to be stuck into the sclerotic coat. Figures of such are to be found in RIGHTER's elements of surgery, and in other works. I can conceive nothing more calculated to alarm the patient, to increase spasmodic action of the muscles of the globe, and thus to render the eye unsteady. Hence all contrivances of this sort are now laid aside, and the operator trusts to his own fingers, or to his assistant, for giving to the globe the necessary degree of steadiness. In accomplishing this point he must act merely on the anterior part of the organ, taking care that no general pressure is made on the globe either by himself or his assistant. Such pressure is injurious, both by pushing the iris forwards against the cornea, and prematurely forcing out the aqueous humor, and also by endangering the premature and forcible expulsion of the lens, with the vitreous humor.

The operation of extraction consists of *three parts:* the division of the cornea; the laceration of the capsule; and the removal of the lens through the openings made in the capsule and cornea.

The division of the cornea must be ample enough, that the lens may escape readily through it; we divide, therefore, a certain portion of the circumference, carrying the section along the edge of the cornea, as near as may be to the sclerotic coat. There are various reasons for making the section at the margin of the cornea, and the principal of these is, that we shall not otherwise have sufficient room for the passage of the lens. There is the further advantage that the subsequent cicatrix will not interfere with vision. The section of the cornea must embrace an extent corresponding to the transverse diameter of the lens, and that is nearly equal to the diameter of the cornea itself, so that the section of one half of the cornea is required to allow the lens to escape. We must puncture the cornea on the temporal side of the eye, [fig. 103,] carry the knife across

Fig. 103.

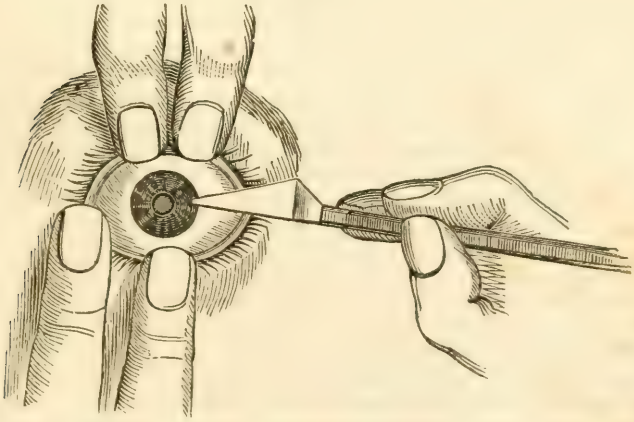

the anterior chamber, bring it out at the nasal side opposite to its entrance, [fig. 104,] and then continue the incision, so that the knife may cut itself out. The chief difficulty in the section of the cornea arises from the iris getting in the way of the knife. When the anterior chamber is penetrated, the aqueous humor readily escapes, and then the iris comes immediately against the knife, so that we cannot carry it on without wounding that part. In order to prevent the escape of the aqueous humor, the cornea knives are so shaped as to fill up the wound; that is, they increase in thickness gradually from the point to the handle.

Fig. 104.

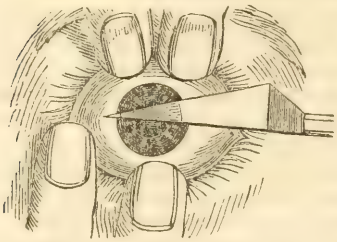

The cornea may be divided in its upper [fig. 105], or lower half, [fig. 106,] or in its lower and outer portion. [Fig. 107.] The lower section is

Fig. 105.

Fig. 106.

Fig. 107.

the most objectionable: the aqueous humor escapes easily; prolapsus iridis takes place readily; and the edge of the lower lid is apt to interfere with the adjustment of the corneal flap. Against these advantages we may perhaps place the recommendation of its being rather easier in performance. In the superior section the operator has a more complete control over the globe; he can fix it perfectly; the aqueous humor does not escape so readily, and the iris is consequently less likely to fall against the knife; there is less fear of prolapsus iridis; and the pressure of the upper lid keeps the flap of the cornea in its right place. The exterior and inferior section is equally eligible with the superior. [Fig. 107.] This was the method employed by an operator of great celebrity, Baron Wenzel.

When the superior section of the cornea is performed on the right eye, the patient should be in the recumbent position, and the surgeon seated behind him, so that the head is on a level with the lower part of the operator's chest. The fore and middle finger of the operator's left hand are employed to raise and fix the upper lid, at the same time steadying the globe, so that it shall not turn upwards or inwards. The fore-finger, placed below the eyelashes, on the ciliary margin of the lid, raises it and presses it firmly against the margin of the orbit, keeping the edge still in contact with the globe, though without pressure. The end of the finger comes against the eye at its lower part. The middle finger is in contact with the globe at the inner angle. The assistant gently depresses the lower lid by means of his fore-finger placed on the integuments. The knife is to be held between the first two fingers and the thumb of the right hand: and the hand itself rests on the temple with the two other fingers half bent. The hand is thus steadily supported, and we have the free use of the fingers and thumb for opening the cornea, which is to be effected by such a movement, and not by that of the whole hand.

The eye is often rendered unsteady by these preliminaries, and we wait till this goes off. Perhaps we engage the attention by a question or remark, when the eye will become quiet, and assume a position favorable for

the operation. This object may sometimes be accomplished by desiring the patient to look in a suitable direction with the other eye. It may be well to touch the cornea slightly once or twice with the flat surface of the knife, before beginning the section, to give the patient warning, and to steady the eye. We should apprize him of the painful sensation caused by puncturing the cornea, recommending him not to hold his breath, nor to resist, or contract the lids if he can help it.

The point of the knife should be entered at the margin of the cornea, [fig. 103,] and the section should be continued, as nearly as possible, in the same direction. If we cut in front of this point, the opening will be insufficient [fig. 108]; if behind it, we interfere with the attachment of the iris, and increase the probability of prolapsus.

Fig. 108.

In making the incision of the cornea, four points are to be attended to, viz., the puncture, by which the anterior chamber is entered; carrying the knife across the chamber; the puncture at the opposite side; and lastly, the completion of the section upwards. In entering the knife at the temporal side of the eye, we must be careful to carry its point through the cornea, directly, not obliquely. Without due caution the knife may go between the corneal laminæ without entering the anterior chamber; or the cut may be so oblique, that the inner line of the section will be much smaller than the outer, and consequently there will not be sufficient room for the cataract to pass easily. The instrument is then to be carried on, by a continued and steady movement of the finger and thumb, with its flat surfaces parallel to the iris, across the anterior chamber. The more quickly this is done, the less chance is there of the aqueous humor escaping, and the iris falling against the knife. A principal difficulty in performing this section of the cornea is that the eyeball is involuntarily turned inward towards the nose. To prevent this, we must steady the globe by means of the fore and middle finger, while the knife is carried through the anterior chamber, and brought out at the nasal side of the cornea. Unquestionably the unsteadiness of the eye, the motions which a person involuntarily makes, are great impediments to the performance of this operation.

We must not be afraid of touching the globe, but fix it firmly between the fore and middle finger, while we are entering the knife, carrying it across, and bringing it out on the nasal side; when the latter point is accomplished, there is no further difficulty in completing the section. Let the operator puncture the cornea, and traverse the anterior chamber quickly and steadily, keeping his eye on the point of the knife, and not attempting to cut upwards: as soon as the knife has been brought out on the nasal side, all pressure on the globe must be discontinued; and it may be well to pause shortly, that muscular spasm may subside. We then push the knife gently onwards, without any remission, towards the nose, and its breadth should be such that it may cut its way out; but we generally find that a small portion of the cornea must be divided by an upward motion, unless we push it onwards, so as to wound the nose or the internal canthus. This must be accomplished by a gentle sawing motion of the knife, immediately upon which the lids should be left free. It is safer in some cases to wait a few seconds before completing the cut, that spasm of the muscles may subside.

Some recommend that the knife should be withdrawn before the cornea is completely divided, and that the section should be finished with a narrow curved knife, [fig. 98.] It would be better to do this than to run the risk of wounding the iris.

The object we have in view, is to make a clean cut of the cornea by one single incision, employing only one instrument; we thus accomplish the purpose in a manner the most favorable to subsequent speedy union. I have already observed, that the presence of the iris affords the principal obstacle to the easy and exact execution of this important step in the operation. The preparatory measures of fixing the lids and exposing the globe, and the act of cutting this very sensible part, bring on a spasmodic action of the muscles, both of the globe and lids, by which the aqueous humor is quickly expelled, and the loose floating iris pushed against the knife, or even propelled, so as to bulge under its edge. If this should happen when the point of the knife has traversed only half, or even the whole anterior chamber, and the point should be completely enveloped by the iris, it will be best to withdraw the instrument, close the eye, allow the section to heal, and repeat the operation afterwards. But, if we should have carried the knife not only across the anterior chamber, but through the nasal side of the cornea, the iris may then be forced under its edge; we may complete the section without withdrawing the instrument, although we must not immediately press it forwards, as we should then shave off a piece of the iris. It is better to rest for a few seconds, that the spasm may subside; then to bring the knife forwards while we gently press the iris back with

Fig. 109.

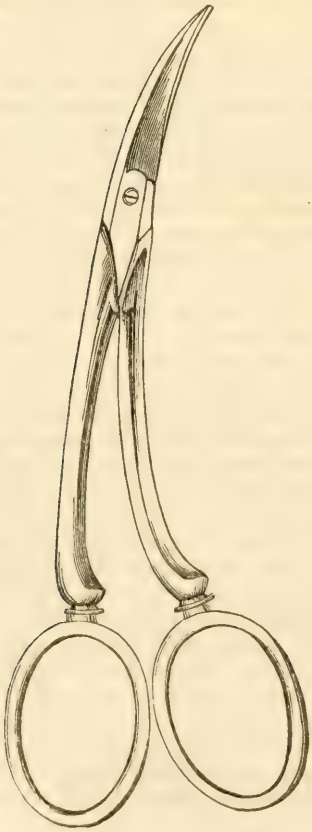

Fig. 110.

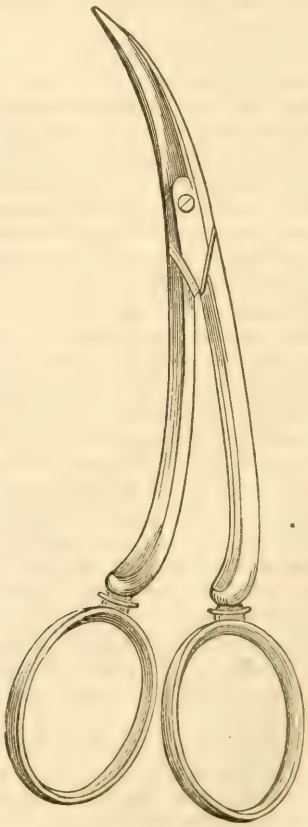

the forefinger, and, keeping up the pressure, slowly complete the section. As the knife advances, its broader portion enters the anterior chamber; thus the chance of protrusion is diminished by lessening the space in which it can occur.

When the section of the cornea is finished, it may not be large enough to allow the easy escape of the lens. A common cause of failure is in bringing the point through the cornea, before it has reached the inner edge; and this arises from the rolling of the globe inwards. We see cicatrices, in which we find that the knife has come out only a little beyond the centre of the cornea. It is most desirable to make the opening of full size at first; that is, to divide one-half of the cornea close to its circumference. When, however, this is not accomplished, what course should be taken to remedy the failure? Scissors curved on the edge, and with one blade blunt at the end, have been employed, [figs. 109 and 110.] They are regularly used in the method originally proposed by Daviel, who merely punctured the cornea with the knife, and did the rest with the curved scissors.* The contused wound thus made is less favorable for union by adhesion. The mode now commonly employed, is the best; that of enlarging the incision by means of the narrow, curved, blunt-ended knife, [figs. 97 and 98.] This instrument is introduced into the anterior chamber, keeping its end against the cornea, and carrying it in to the full extent; the cutting is effected by withdrawing the instrument, and repeating the process until the necessary enlargement is effected. This method is sometimes used as the regular way of operating; a partial section of the cornea is made with a broad knife, carried across the anterior chamber, but not brought out on the other side; it is then enlarged in any eligible direction, with one of these curved knives.

Fig. 111. Fig. 112.

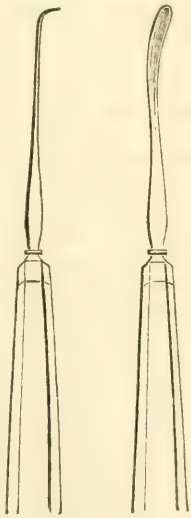

When the section of the cornea is finished, the great difficulty of the operation is passed; the rest is easy. All that remains is to rupture the capsule of the lens. The lens might be forced out without previously opening the capsule; but the vitreous humor would probably be expelled with it.

The capsule is generally lacerated by the curette. [Fig. 111.] This is introduced under the flap of the cornea, with the convexity turned upwards, till the point is opposite the pupil; we then turn the point inwards, sink it through the capsule, and draw it from side to side, so as to divide that membrane freely, and withdraw it with the convexity of the instrument downwards.

The third part of the operation is the removal of the lens; this is accomplished by directing the patient to open the eye, and then making a little steady and gentle pressure upon the upper lid, with the small silver spoon at the other end of the

* [Daviel's scissors have a double curve to adapt them to make as direct an incision of the cornea as possible, and two pairs [figs. 109, 110], curved in opposite directions are therefore required. One pair, supposing the section downwards, so bent as to serve for dividing the temporal side of the right cornea and nasal side of the left; or supposing the section downwards, to serve for incising the temporal side, of the left cornea and nasal side of the right. The other pair to meet the opposite circumstances. The pair must always be used which, when applied, will present its lateral curve towards the cornea.]

curette, [fig. 112,] while we press gently against the lower lid with the forefinger, until the lens rises up out of its socket. The pressure must be continued gently until we see the edge of the lens rising in the pupil and distending the iris. This part of the process cannot be performed too slowly and cautiously. The iris is stretched to the utmost, and appears as if it must inevitably be torn through; but it yields gradually, and allows the largest lens to escape through the pupil. Bring the upper lid over the eye, and close it immediately on the exit of the cataract, otherwise the vitreous humor may follow the lens. Sometimes the violent contraction of the muscles forces out the lens on the completion of the corneal section, and sometimes it escapes spontaneously, when the capsule has been opened. The operation is now finished: let the eye remain shut for a short time, and then open it to see that the pupil is round and clear, and the corneal flap in the right place. The edge of the iris is often engaged in the wound; gently press on this part of the eye through the upper lid, then open both eyes to the light, and the pupil will recover; or the prolapsed iris may be replaced with the silver spoon. The after treatment of the case will be subsequently considered.

Adhesions of the pupil would prevent the exit of the lens, even where the cornea has been opened to the full extent. Their presence is indeed a reason against operating by extraction, and will be discovered if the eye is previously examined, as it ought to be, under the influence of belladonna. If, however, the escape of the lens should be prevented by adhesions discovered at the time of operating, it would be proper to enlarge the pupil by a slight cut with the slender scissors, [fig. 101,] or the adhesion might perhaps be separated with the curette.

If the section of the cornea have been made in the way described, the lens will pass through it with great facility; but it often happens that a portion of the soft circumference of the lens remains behind, so that the pupil is not of its natural clear black color. We are generally directed to remove carefully from the pupil or anterior chamber all such portions of the lens, and the little silver scoop or spoon of Daviel [fig. 112] was made for the purpose of fishing them out. This is a bad practice. It is essential to the success of the operation, that the lens should be removed with as little injury to the surrounding parts as possible; the repeated introduction of instruments is obviously at variance with that object, and nothing is more likely to cause inflammation, especially of the iris, than the contact of those foreign bodies with that delicate texture. It is, moreover, unnecessary, because the soft portion of the lens left behind will be removed by absorption. Then, again, little forceps and little hooks have been provided for seizing and removing portions of opaque capsule. If we were to try, we could not accomplish this, or at least not without the certainty of letting out the vitreous humor; and besides, it must be seen on a little reflection, that the opening in the capsule, which is sufficient to allow the escape of the lens, must also be large enough to admit of good vision. If there were in the pupil or anterior chamber a considerable mass of lenticular substance, and it could be removed easily, let it be done; but otherwise, make no attempt of the kind.

Sometimes the vitreous humor rises up into the pupil under the edge of the cataract; and if we were to continue pressing on the globe, that humor would be forced out instead of the lens. We must introduce the curette [fig. 111], or the slender hook [fig. 100], and hook out the cataract. The escape of vitreous humor is not to be regarded in itself as a very serious circumstance. The space which it before occupied is filled up by aqueous

secretion. There is no doubt that one-fourth or one-third, and perhaps even one-half of the vitreous humor may be lost in this way, without interfering with the result of the operation. In many instances it seems rather to contribute to success: it lessens the bulk of the globe, and thus prevents the tension which occasionally succeeds to the operation. Sometimes there is a spasmodic action of the muscles, propelling the vitreous humor against the cornea, and preventing the apposition of the flap. I have in such cases introduced the curette through the pupil, and let out some of the vitreous humor purposely.

It is desirable not to wound the iris; but a clean cut of this part is not in itself of any consequence. I have seen a portion of it shaved off in making the section of the cornea, a few times, without any injurious result; the case has proceeded much more favorably than it would have done if the knife had been withdrawn, and the section completed with other instruments. The pupil is afterwards larger, and of irregular figure. If the portion shaved off should not embrace the margin of the pupil, the new opening and the natural pupil should be laid into one by a snip with the slender scissors.

Superior section of the cornea on the left eye.—If the operator can employ both hands equally, the superior section of the cornea will be made on the left side in the manner already described, except that he will elevate the upper eye-lid and fix the globe with the fore and middle finger of the right hand, and hold the knife with the left. If he is not ambidexter, he will sit in front of the patient, manage the lower lid with the left, and hold the knife in his right hand, cutting from himself, while the assistant raises the upperlid and fixes the globe. This is not an eligible mode of proceeding. The way of using the knife is unusual; and the globe cannot be so effectively fixed by an assistant as by the operator.

[We have not experienced the difficulty of operating under such circumstances, intimated as existing by Mr. Lawrence. We always place the patient on his back, depress the lower lid, and *steady the globe* with the fore and middle fingers of our left hand, while the assistant raises the upper lid with the fore and middle finger of his right hand; see fig. 122, p. 660.]

Exterior and inferior section of the cornea.—Division of the cornea at its outer and lower part [fig. 113] is equally advantageous in other respects, with the superior section, and it presents the additional advantage pointed out by Mr. Tyrrell, that the pupil, if displaced by prolapsus iridis, is in a position more favorable to vision than in the case of the superior section. It is performed on the left eye, by the operator sitting in front of the patient, and using his right hand, while the upper lid is elevated by the assistant. It may be executed in the same manner on the right eye, if the surgeon can use the knife with his left hand; otherwise he sits behind the patient, using the right hand and cutting away from himself.

Fig. 113.

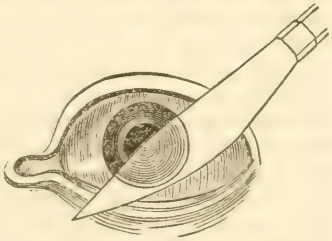

The section of the cornea will in general be best performed with the right hand; the operator may therefore divide it above in the right eye, downwards and outwards in the left.

Inferior section of the cornea.—As the division of the cornea in its lower portion [fig. 114] is liable to objections, from which the two other

Fig. 114.

modes of operating are free, it will only be practised in certain cases for particular reasons. It may be executed with the patient either in the recumbent or sitting posture. In the latter case he should be seated on a chair or stool, rather lower than that occupied by the operator, that the latter may have the free and easy use of his hands, without being obliged to elevate them unpleasantly. The operator should be seated at such a height that he may be able to use his hands with perfect facility at the level of the patient's eyes. Further directions respecting the relative positions of the surgeon and patient have been given already at pages 638 and 640.

The duty of the assistant is to fix the head, to keep it perfectly steady, to elevate the upper lid, and to keep it elevated, without pressing on the globe while the section of the cornea is made. If a chair with a sliding back be employed, all the assistant has to do is to elevate the lid; otherwise the assistant must fix the patient's head against his own breast by one hand placed under the chin, while he elevates the lid with the other. The assistant should be aware of one point, which should be decided upon between him and the operator before the operation is commenced, namely, to let the lid go before the section of the cornea is completed; and the operator should just give a sign or motion to the assistant as soon as he has nearly finished the section. In elevating the upper lid, one finger is generally sufficient; let the assistant fix the lid against the upper margin of the orbit, the end of the finger being placed on the ciliary margin of the lid: he should hold it firmly against the orbit until the operator tells him to let it go. The end of the finger should project over the margin of the eyelid, towards the upper and inner part of the globe, so as to prevent the eye from rolling in that direction when the section of the cornea is begun. It is not material whether the assistant employs his right or left hand; but it will be less in the way if he employ the hand opposite to that which the operator is using.

In operating on the left eye, the surgeon depresses the lower lid and fixes the globe with the fore and middle fingers of the left hand, holding the knife in the right. As the eye would roll inwards when the knife touches it on the temporal side, the operator must not be afraid to fix it effectively by the fore and middle fingers of the left hand. The inferior section of the cornea must be performed on the right eye with the left hand.

[This necessity may be avoided by the surgeon who is not ambidexter, by placing the patient in the recumbent position.]

Operation of extraction without an assistant.—Some operators perform extraction of the cataract without an assistant, fixing the lids and the globe with the fore and middle fingers of one hand, and using the knife with the other.* There is an obvious advantage in having the combined movements necessary to accomplish a single purpose executed by one and the same

* This method is strongly advocated by Mr. Guthrie in a pamphlet on the operation of Extraction; London, 1834.

individual, if it can be done effectively; and we know that extraction can be performed in this way most successfully; for it is the plan followed by Mr. ALEXANDER. To acquire this method, great manual dexterity and abundant opportunities of practice are necessary. It increases the difficulties of an operation in itself difficult, and therefore is not likely to meet with general adoption. At all events, the best course for beginners will be to operate with the aid of an assistant.

Treatment after the operation.—Our object is to keep the flap of the cornea in its place, so that the wound may unite by adhesion. The eye, therefore, must be perfectly at rest, and the occurrence of inflammation must be prevented. After the operation is concluded, the lids of both eyes must be closed, and kept in that state. The coverings necessary for this purpose should be light. Sound eyes would be heated and rendered uneasy if thickly covered. A soft rag, doubled and wetted, may be placed over each eye, and gently confined by the simplest bandage. This consists of a stripe of linen doubled lengthways. The middle of it should be pinned to the back of the night-cap; each end is then brought forward along the corresponding side of the head, and obliquely across the eye and forehead; the two ends, after crossing on the forehead, being pinned to the sides of the cap. The patient may find it more comfortable to have the rags confined by a simple circular band carried across the forehead, so that there shall be no pressure on the eyes.

[A very convenient bandage, and the one we generally use, may be made by sowing a couple of folds of soft linen to a strip of the same, or to a piece of tape; see fig. 115. The band is to be tied around the head,

Fig. 115.

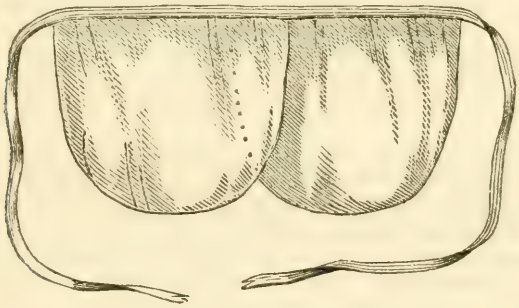

and the folds of linen allowed to hang over the eyes. If desired, a third band of linen may be placed over the hanging folds of linen.]

Nothing can be more objectionable than the method recommended by BEER, and followed by many German operators, of closing the lids by stripes of sticking-plaster carried from the forehead to the cheek.

The application of bandage to the eye is not to be regarded as an essential point of treatment; it is rather employed to keep the eye quiet, and to guard it from any slight accident. On this account gentle confinement during the night is expedient; but the part may be left uncovered or with a damp rag over it, while the patient is awake. The rag may be moistened occasionally, if the patient should find it comfortable. If, however, the eye is cool and easy, this will not be necessary; nor should the application of cold in this way be persevered in, unless the patient's feelings indicate

its propriety. The bandage should be immediately removed, if heat or pain come on.

Soon after the conclusion of the operation, the patient should go to bed, and lie with the head and shoulders raised, in order to moderate the flow of blood towards the head, and to facilitate its return. The apartment should be darkened; at least the light should be sufficiently excluded to produce no unpleasant effect on the eye. Mr. Tyrrell has suggested that, when the patient has the advantage of a good attendant, he might remain for a few hours on a couch or easy chair; that he will be less likely to fall asleep than in bed, and thus have a better chance of sleeping at night.

The food should be soft, not requiring mastication, that the muscles of the jaws may not be called into action. For the same reason, the patient should not talk.

Considered merely as an operation, extraction of the cataract is a slight affair, not serious, nor attended with much pain. Patients have often expressed to me that they had suffered as much pain from venesection. It is, however, a most important matter in its consequences, involving the alternative of restored sight or continued blindness. Anxiety and alarm must often be felt; the patient will be nervous and agitated, and restlessness may come on towards night, with pain in the organ not dependent on inflammatory excitement. An opiate, in tolerably full dose, is the best remedy for this state. We may administer from twenty to forty minims of laudanum, or the liquor opii sedativus, one-third or one-half a grain of the muriate of morphia, with a little of the spiritus etheris sulph. comp. Where opium has been found to disagree, hyoscyamus, although a less certain and efficacious narcotic, may be substituted.

An uneasy sensation will be experienced in the eye, a kind of smarting or aching, for twenty-four hours after the operation or longer; sharper pain will be felt on any movement, sometimes with the feeling of a foreign body. Fluid will escape occasionally, leaving the eye easier. These, in various degree, are the usual results of the operation, and indicate nothing unfavorable.

The lids should be gently cleansed with tepid water, and freed from any mucous secretion, from time to time. This must be done slightly, with the softest sponge or rag, and without any pressure on the lids.

The bowels should be effectively cleared on the morning of the operation, so that the patient may not want to move, on this account, for the next day or two. Then, if they should not act naturally, a mild aperient should be given, to empty the canal without purging.

If things go on favorably for four or five days, the eye being free from pain, and the upper lid neither swollen nor red, we may conclude that the operation has succeeded. We may gently raise the lid to ascertain the state of the organ: it will be a great satisfaction to the surgeon and patient to find that there is no unnatural redness, nor prolapsus iridis, that the pupil is regular, and the vision good. We just try the latter point, and then close the eye again. Bandage and coverings may now be laid aside; at least a light rag pinned to the night-cap, allowing it to hang over the eye, or a common green shade, will be sufficient.

The patient may now leave his bed, and sit in a moderately lighted room, walking about occasionally. He may go on thus for ten days or a fortnight more, opening the eyes now and then for a short period. The long confinement to bed, heretofore enjoined after the operation of extraction, is unnecessary, and must be injurious to health. The patient should

remain in bed for the first twenty-four hours; he may then in many cases sit up during a part of each day; and there can be no advantage generally in confinement to bed for more than four or five days.

If things go on favorably, the eye may be opened in a weak light, in a week or ten days, and may be used more freely as it becomes stronger. After some time, generally in about a month, it is expedient that the patient should be suited with spectacles; the loss of the lens diminishes the refractive power of the organ, so that it becomes necessary to supply its place by convex glasses. The patient must select those with which he can see best. He will require two pairs of spectacles, one for ordinary vision, the other for reading, writing, and the other purposes in which accurate near sight is required; the latter must be more convex than the former. Some weeks should still elapse before the patient begins to use his glasses, and he should at first proceed cautiously. Indeed, he will act prudently in employing the spectacles at all times sparingly; in many cases the cataract is not the sole imperfection in the eye, and vision may decline and be lost at some length of time after the operation, without any obvious reason.

Attention should be paid for some time to the state of the bowels, the diet, and the general health; the eye should not be much used, nor exposed to strong light, nor should the patient run any risk of getting cold; the organ remains weak and irritable after the operation, and therefore liable to inflammation from slight causes.

The wound of the cornea is considerable; there is a large surface to be united and cicatrized, and numerous red vessels will be seen upon the conjunctiva and sclerotic opposite the section; these enlarged vessels are employed in repairing the breach made in the corneal structure, just as is observed in the healing of an ulcer of the cornea.

I have supposed that everything is going on favorably after the operation; however, we unfortunately find, as we might expect, that so large a penetrating wound of the globe often produces serious inflammation. If the patient should not have been bled before hand, he should lose from eight or ten to fourteen or sixteen ounces of blood on the evening of the operation, unless there be a reason to the contrary. If, however, there should be pain of the eye, or head, with accelerated circulation and general heat, a large venesection is absolutely necessary. This is a safe kind of precaution; I have never seen it injurious; but in some cases I have had occasion to regret that it was neglected.

Bleeding should on no account be neglected under such circumstances; and it is necessary either that the operator should do it himself, or that he should entrust it to some one in whom he can place confidence. If the pain should not be removed, or if it should recur, the bleeding must be repeated, and the further use of cupping or leeches may be necessary. The greatest attention should be paid to the patient for the first forty-eight hours after the operation, the object being to prevent the occurrence of inflammation. It will not do to wait till inflammation arises, and then adopt measures for reducing it. If this process be allowed to take place, the success of the operation is either frustrated, or rendered less perfect.

The occurrence most to be dreaded after the operation is that of active inflammation, attended with sharp pain in the eye, swelling, redness, and great tenderness of the upper eyelid. Sometimes the local action necessary for adhesion fails, and inflammation of more chronic character occurs, with pain in the organ, and swelling of the eyelid without redness. The pulse is small and feeble; the patient depressed and restless. Stimuli with opi-

ates, cordials and good nourishment are required in such cases, and are employed with the most favorable effect both on the general and local symptoms. In the two cases now under consideration the disorder and the treatment are of opposite character. The consequences of a mistake would be serious; hence, under doubtful circumstances, the organ should be carefully examined, while the state of the constitution is attentively considered.

When we consider the violent distension of the iris in the escape of the lens, its exposure by the large section of the cornea, and the mechanical irritation which it sometimes undergoes from the contact of instruments used in the operation, we shall not wonder that iritis should occasionally follow the operation. It generally commences about the fourth day, with severe pain in the head; this pain is aggravated during the night, remitting in the day. The iris changes its color, lymph is effused into the pupil, there is great sensibility to light, and increased lachrymal discharge. Closure of the pupil, or obstruction of it by an adventitious membrane, is its consequence, if it is not arrested. Free venesection in the beginning, when the pain is first felt, cupping and leeches, and afterwards the active use of mercury, are the best means of combating this affection. But the latter remedy is not so efficacious here, as in iritis from internal causes.

Prolapsus of the iris occurs not unfrequently in connection with extraction. It may happen at the time of the operation, the iris being distended to the utmost, and then forced through the opening in the cornea by the advance and the exit of the lens. It may be replaced, at the moment, by gently rubbing the upper lid, and then opening the eye so as to cause contraction of the pupil; or it may be pushed back under the flap of the cornea into the anterior chamber with the small silver scoop. If the iris should be forced out again, while continued spasmodic action of the muscles prevents the correct apposition of the corneal flap, it may be expedient to let out a little of the vitreous humor. This may be done by introducing the curette through the pupil, and lacerating the crystaline capsule. Great care is necessary to prevent too large an escape of the humor.

Prolapsus of the iris often takes place within the first three or four days after the operation, in consequence of some sudden incautious or involuntary effort, such as that of coughing or sneezing, or, without any accidental cause, from internal changes, probably of congestive or inflammatory character, producing general fulness, and distension of the structures towards the front of the eye. The prolapsus is followed by pain and irritation in a greater or less degree. The protruded part suffers from the pressure of the opening, and causes an inequality of surface, which irritates the lids. We endeavor to tranquilize the eye, and thus to prevent the increase of mischief. When the organ is in a quiet state, the prolapsus may be punctured with a cataract needle, so as to let out the aqueous humor. This lessens the protrusion, and facilitates cicatrization; it may be repeated with advantage. In this way the case will be brought to a favorable termination, the iris remaining adherent to the cicatrix of the cornea, and the pupil not being much contracted or displaced. If it should appear that adhesion of the iris to the cornea has not taken place, after puncturing the prolapsus, we may touch it with the nitrate of silver, or apply a strong solution to the part with a camel's hair pencil. The escharotic should not be employed without necessity; in the majority of cases the means before mentioned accomplish all we want. A protrusion sometimes takes place from the cicatrix of a thin delicate membranous substance, which may be distended with aqueous fluid. According to circumstances, it may be punctured with a cataract needle, touched with a solution of nitrate of silver, or snipped off with scissors.

Cases for extraction.—The operation of extraction is particularly applicable to cases of firm cataract, especially in persons advancing in years. The cataract being hard and less susceptible of absorption, is removed from the eye; the incision of the cornea may be healed in twenty-four or forty-eight hours after the operation, the object of which is then accomplished, though it would not be prudent to employ the eye at that time. Thus the advantages of the operation are the complete removal of the cataract, and the speedy restoration of sight.

Cases in which extraction is unadvisable.—Under certain circumstances, there are objections to extraction, whether employed for hard or any other cataracts. A small anterior chamber increases the difficulty of the operation; it is not easy to make an adequate section of the cornea without wounding the iris. The cataract is sometimes so large as to push forwards the iris, so that a very small space is left between the latter and the cornea; but as firm cataracts are generally smaller than natural, this objection does not usually apply to such cases.

A sunken eye is unfavorable for the operation of extraction; and the eye may be in this state either from an absorption of the adipose matter in the orbit, or from a great projection of the brow: the globe cannot be denuded sufficiently for the easy execution of the operation, or at least not without subjecting it to pressure. Unusual smallness of the palpebral fissure may cause similar difficulty.

Very advanced age is unfavorable for the performance of extraction; the restorative powers of the system are enfeebled, and the union of the cornea does not readily take place. A weakened state of constitution, independently of age, would form an analogous ground of objection. I have seen some cases, in which no progress towards union was observable four or five days after the section had been made. It would be difficult to specify any exact age at which we might deem it objectionable to perform the operation; we should rather consider the general powers of the individual, for some persons are as young at seventy as others are at sixty. I performed extraction on a late member of our profession at the age of ninety-two; the cornea united as quickly and favorably as it could have done in the youngest subject, and the patient subsequently enjoyed the power of reading with a suitable glass the smallest print with perfect facility.

Adhesions of the pupil prevent the exit of the lens, and thus render extraction ineligible. Extraction would be contra-indicated by affections of the chest attended with cough or difficulty of breathing.

Another objection to the operation of extraction has reference rather to the operation than to the patient; it is the difficulty of performing it, the degree of manual dexterity required for its successful execution. Unless a person has frequent opportunities of operating, he will not become familiarized to the various difficulties of the proceeding, nor acquire that confidence which is essential to success. The unsteadiness of the eye, the little control which the patient has over it, the alarm which the dread of the operation, and still more the preliminary measures occasion, and the convulsive or spasmodic exertion which the actual contact of the instrument often excites, are sources of real difficulty. The eye is rolling incessantly from one side to the other, and it immediately turns away from the instrument, so that the greatest care and caution are necessary even to perform the section of the cornea. Undoubtedly extraction is an operation of considerable nicety; and unless it has been frequently performed on the dead eye, the expectation of success on the living subject would be as absurd as the attempt would be unjustifiable. The opera-

tion of depression, on the other hand, is easy, and requires no particular practice beforehand.

Beer, who is a great advocate for extraction, mentions the following circumstances as contra-indications of the operation, and consequently as reasons for preferring depression or reclination. A considerable adhesion of the iris to the cornea. A very flat cornea, in consequence of which the anterior chamber is so small, that an opening of sufficient size cannot be made. A very broad arcus senilis, which we cannot venture to divide, because the wound will not heal. Habitual contraction of the pupil (*myosis*). Deeply lying eyes with narrow fissure of the lids. The eyes very unsteady, and easily thrown into convulsive movements. Excessive and insuperable timidity of the patient. Early age or great stupidity, rendering the patient unmanageable during and after the operation. (*Lehre*, vol. ii. p. 364, 365.) I have found by repeated experience, that the notion expressed above of the corneal section not healing when it has been made in the arcus senilis, is incorrect.

Fig. 116. Fig. 118. Fig. 117.

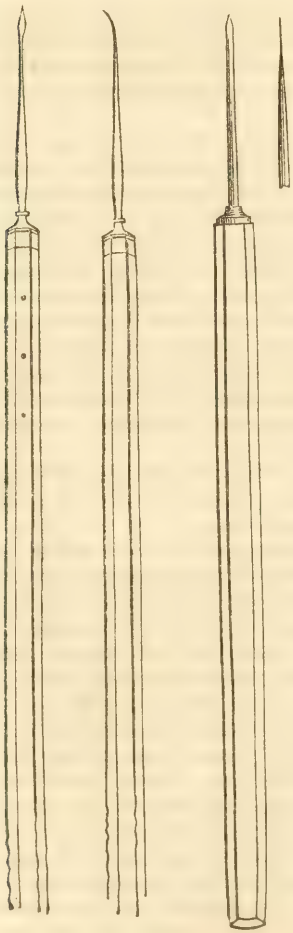

SECTION III.—DEPRESSION, OR COUCHING.

The patient should be prepared for this operation in the same way as for that of extraction. In all instances, before operating with the needle, it is expedient to dilate the pupil by belladonna: this enlargement of the aperture enables us to see exactly what we are doing. Permanent dilatation after the operation is generally advisable, in order to allow free access of the aqueous humour to the lens, as well as to prevent adhesions of the pupillary margin.

Various needles have been used for depression: the spear-shaped needle, which has been commonly employed, is made straight, and terminates at the end in a spear point. [Fig. 116.] The needle employed by the late Mr. Saunders is straight also, but instead of being spear-pointed, is ground flat at the extremity, [fig. 117: the small figure at the side, is a lateral view of the same instrument:] it is just such an instrument as might be made by grinding a knitting needle flat at its end, and giving it a sharp point: the sides of the end are also sharp. The needle of Scarpa is slightly curved at the end and is sharp upon the edges of the curve, [fig. 118.] There is a needle strongly recommended by the late Mr. Hey, but it is now out of use; it is the worst of all I have tried. I think that Scarpa's needle will be found to answer the purposes of the operator best.

The patient is placed on a low seat, and the operator occupies a rather higher one in front of him. The assistant, standing between, supports the head, elevates and fixes the upper lid. The operator depresses the lower lid and steadies the globe with one hand, while he uses the needle with the other.

The needle should be carried through the sclerotica, at the distance of a line and a half or two lines behind the margin of the cornea, [fig. 119,] and nearly, but not exactly, in the middle of the eye, because the long ciliary artery runs on each side along the middle; the needle, therefore, should be entered a little above the middle line. It is to be introduced on the temporal side of the globe, and then carried forwards and upwards, so as to place it on the upper and front part of the lens, and then the business of depression begins. The needle must be steadily pressed upon the cataract, so as to move it downwards and backwards, [fig. 120,] out of the axis of vision; and this is to be done, not by any sudden motion, but by a slow and gentle pressure, continued until the lens sinks below the pupil. The needle should be held on the lens for a short time to fix it steadily in that position, and then having been gently rotated to disengage it from the lens, it should be lifted up a little to see if the lens rise; if it do not, the needle is withdrawn. If the lens should rise, it must be again depressed and kept down for a short time, after which the needle is withdrawn.

Fig. 119.

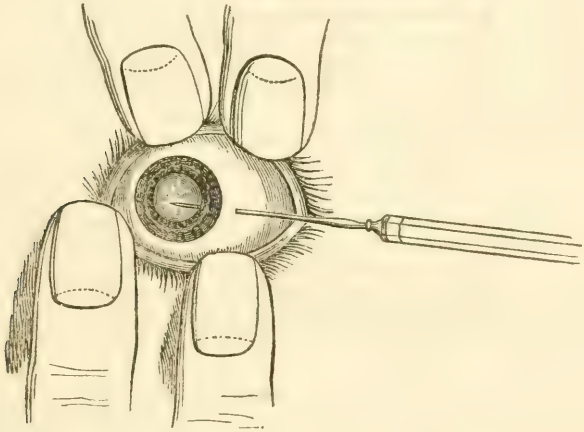

Fig. 120.

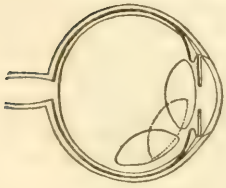

Fig. 121.

Reclination.—In the modification of depression termed *reclination*, the lens is not pushed downwards in a straight direction, [as in fig. 120,] but is turned on its axis, so as to be placed horizontally, [see fig. 121,] in the

vitreous humor, behind the lower part of the iris. When this kind of displacement has been effected the posterior surface of the lens is turned downwards, the anterior upwards; the superior margin is backwards, the inferior forwards. In order to operate in that way, a particular instrument was devised by WEINHOLD.* It consists of two needles, which, when closed together, appear, and may be used as a single needle. It is employed in this state to puncture the sclerotica; but when the instrument has entered the eye, and been brought in front of the lens, the operator separates the two component parts, of which the junction corresponds to the puncture of the sclerotica, and then there are two needles placed in front of the lens, by which we can completely command it, and *recline* it, or place it in the situation already described. The reclination may be accomplished with the common simple needle, but the lens may revolve under the needle instead of taking the desired direction.

In reclination the curved needle is carried through the tunics in the same situation as in depression, the convexity being forwards. It is then brought over the upper edge of the crystalline in front of that body, and placed a little above its centre, with the concavity backwards. The needle is now moved slowly backwards, so as to place the lens in the position already described, care being taken to prevent it from rolling under the instrument. The needle should then be rotated between the finger and the thumb to disengage it; and further pressure may be made on the centre of the lens, so as to sink it just below the level of the pupil. If the inferior edge of the lens should have come too far forwards, in the process of reclination, so as to press against the iris or ciliary processes, it should be moved gently backwards before the needle is taken out of the eye.

[Reclination through the cornea has also been performed, but has not been found to answer so well as that by sclerotic puncturation, and is now seldom resorted to.]

SCARPA's *mode of depression.*—The operation of depression as performed by SCARPA is nearly the same as that which I first described; his needle is to be introduced with its convexity forwards, the point of the needle is then carried in front of the upper part of the lens, when it is to be depressed, pushing the lens downwards and backwards; having done this SCARPA turns the needle, and carries it quite through the front of the capsule into the anterior chamber, and makes a point of lacerating the capsule very freely, so as to let the aqueous humor upon the depressed lens; and he advises the removal of any soft or loose fragment of the cataract into the anterior chamber.

The advice of SCARPA in the last two points is by no means judicious. When performed in the most careful manner, and confined to the simple object of removing the cataract from the axis of vision, depression often excites serious and dangerous inflammation. This will be more likely to occur when we add to the displacement of the lens laceration of its capsule, and the passage of fragments into the anterior chamber.

After-treatment.—In the operation of depression, there is a punctured wound through all the coats of the eye, and a forcible displacement of the lens; the cells of the vitreous humor are lacerated, the capsule of the lens is torn, so that the internal structures of the organ are extensively injured. Although the operation at first sight appears to be simple, it cannot be un-

* Anleitung den verdunkelten Krystallkörper im Auge der Menschen sammt seiner Kapsel umzulegen with two plates, second edition, Meissen, 1812. Reclination had been already proposed in preference to depression by Willburg; Betrachtung über die bisher gewöhnlichen Operationen des Staares, sammt einer leichten und verbesserten Art dieselbe zu machen. Nürnberg, 1785.

attended with the risk of inflammation; indeed inflammation is at least as common after this operation as after extraction. The inflammation too, occurring in the most internal part of the organ, is generally serious; consequently the patient requires as much care as after extraction. It is necessary to pay strict attention to the state of health previously to the operation, and the treatment for the removal or prevention of inflammation must be equally active. Internal inflammation commencing in the iris, and proceeding slowly, is a common occurrence after depression; it must be treated actively by antiphlogistic measures, and afterwards by the use of mercury.

Pressure on the retina is a further source of danger. We must take great care to prevent this. There is but a small space to move the needle in, and we must not depress the lens further than is absolutely necessary to clear the edge of the pupil. Pressure of the lens on the retina would probably produce amaurosis.

When the controversy existed between the advocates of extraction and depression, among the disadvantages of the latter was enumerated the subsequent rising of the lens; and this was considered a formidable objection to depression. If such a circumstance should happen, which is seldom the case, the operation may be repeated. Depression admits of repetition; in extraction, on the contrary, the fate of the eye depends on one effort; if that fails there is no further chance. The operation with the needle may be performed many times, and the eye will bear it without any serious injury, so that we may accomplish ultimately what we have failed to effect in the first instance.

The hard nucleus of the lens may pass, at a shorter or longer period after the operation, into the anterior chamber, where it excites a most painful inflammation, which goes on as long as the cause of irritation continues to act. I saw a gentleman, in whom depression had been performed twelve or fourteen months previously: the operation had succeeded perfectly, and vision had been excellent until within a recent period. A small, amber-colored portion of lens, in the shape of a flattened disc, now lay in the bottom of the anterior chamber. For some time it caused little inconvenience, but inflammation slowly arose with great pain, and serious sympathetic disturbance of the opposite eye. I found it necessary to open the cornea and take out the cause of irritation. The eye recovered, excepting partial nebulous opacity of the cornea, and the pupil was clear; but vision was nearly lost. A lady who had cataract in one eye, the other being unaffected, was persuaded to undergo an operation with the needle. Not long after its performance, the centre portion of the lens passed into the anterior chamber, and there excited violent inflammation with excessive irritation and pain. There was the greatest intolerance of light, so that neither eye could be opened, and the patient's sufferings were incessant, day and night, hardly mitigated by any of the various measures used for her relief. I saw her after many weeks of suffering. Although the state of the eye, from inflammation and intolerance, was very unfavorable to such a proceeding, I opened the cornea and removed a hard nucleus of lens. The operation was followed by immediate relief: the inflammation and intolerance of light, however, abated but slowly, and a considerable time elapsed before they were completely at an end. Contrary to my expectation, tolerable vision was recovered.

[Dr. De Abren records in the *Annales d'Oculistique*, a case in which the crystalline lens which had been couched, reascended twenty-two months after the operation and passed into the anterior chamber. It had lost about one-sixth of its original size. No irritation of the iris followed from the

presence of the lens in its new situation, and its absorption was there rapidly effected.]

Absorption of the depressed lens.—The old opinion that the lens, when removed from the axis of vision, and sunk in the vitreous humor, remains unchanged, so that it may at any moment, by rising up again and resuming its place behind the pupil, deprive the patient of sight, seems to have been implicitly adopted by BEER, who thereupon represents depression and reclination as mere palliative proceedings of uncertain ultimate result. "Depression and reclination," says he, "offer only a palliative cure in cases of perfectly hard or in tolerably firm cataracts, in the cystic, and the tough membranous cataracts. For none of these are ever dissolved and absorbed after the operation, but they remain in the eye as unorganic foreign bodies, capable of rising on any occasion, and thus again destroying sight partially or completely." In a note on this passage he makes the following additional statement. "I have neglected no opportunity of examining carefully after death the eyes of those who had undergone depression or reclination during life. Some of the cases had been operated on twenty years and more previously. In almost all, I have found the firm undissolved lens generally much diminished, either with or without capsule. Membranous cataracts have been but little corrugated; they have completely lost their toughness, and been converted into a firm white mass. In a living person I saw the cataract, which had been depressed thirty years before by an itinerant operator, HILMER, raised again by a fall on the head. It was small, angular, and floated from one chamber into the other when the pupil was dilated. It was successfully removed by extraction, being then nearly ossified. In 1805, I extracted for a woman forty years old, a large, hard, yellowish-white lenticular cataract, which had been in the anterior chamber twenty-six years. It was displaced by a blow on the eye from the bough of a tree. I have never seen even a half firm cataract dissolved and absorbed. Before I can believe the possibility of the occurrence, I must have ocular demonstration that a depressed hard cataract can disappear." (*Lehre*, vol. ii. p. 363, 364.)

Some of the expressions in this very quotation partly admit the fact which BEER is arguing against. But the investigations made by others completely contradict BEER's statements; show that the displaced lens becomes absorbed, the process requiring a longer or shorter time in proportion to the firmness or softness of the body; and consequently prove that the fear of its rising again into its original position is in a great measure groundless.

ACREL dissected the eye of a peasant who died some time after he had undergone depression. The lens had completely disappeared. (*Chirurgische Vorfälle*, vol. i. p. 109.)

SCARPA examined the eye in three instances after depression. "The first was in a nobleman of Pavia, aged sixty, who died precisely a year after he had undergone the operation of couching for a cataract in the right eye; the other was in a woman forty-three years of age, who died three years after depression of the cataract: and the third, in a man fifty-seven years of age, who died about three years and a half after the same operation had been performed. In the first of these three subjects, I found the crystalline deeply imbedded in the vitreous humor, and reduced to about one-third its natural size; and in the other two in which the crystalline was deeply situated in the vitreous humor below the axis of vision, there was only the nucleus remaining of a size a little larger than the head of a common pin. (*Treatise*, &c., p. 326, 327.)

Dr. WILLIAM SOEMMERRING has examined several eyes after the operation

of depression, and has described what he found, in an interesting work,* to which he has added a series of beautiful figures, representing most satisfactorily the changes observed. In eight years and a half after the operation the lens had completely disappeared. In another case it was completely absorbed in three years. After two years, the firm nucleus of the lens, as large as a lentil, was found at the bottom of each eye; and it was in the same state in another eye at the end of thirteen months.

Mr. Jules Cloquet found the crystalline reduced to one-third of its natural volume in two years after the operation.†

For the lens to be absorbed in these cases, it is necessary that it should be exposed nakedly to the vitreous humor. If it continue covered by its capsule, no absorption occurs. In a case where the operation had been performed three years before death, Dr. William Soemmerring‡ found the lens completely inclosed in its capsule, situated between the lower edge of the pupil, and the margin of the retina, unaltered as to size, but rather unequal on its surface M. Cloquet§ observed an analogous fact at the end of two years. The absorption of the lens in the anterior chamber, is equally prevented by the presence of the capsule, as is seen in the case mentioned at p. 183. In the instance of non-absorption in the anterior chamber mentioned by Beer in a recent quotation at p. 656, the lens was probably covered by its capsule. This membrane seems to be little, if at all, susceptible of absorption.

An interesting physiological fact was observed by Dr. W. Soemmerring in his examinations: viz., that when, after depression, the capsule remains in its place, and with its natural connections, a partial reproduction of the lens takes place. When the eyes were recent, he saw no appearance of capsule or lens; but after they had been immersed in spirit, the capsule became very obvious, and it was found to contain a varying quantity of soft gelatinous matter, analogous to the exterior substance of the lens, and rendered opaque by the spirit. Messrs. Cocteau and Leroy D'Etiolles‖ had already shown that the lens is reproduced in animals, as in the rabbit, cat, dog. This reproduction took place to a considerable extent in six weeks after the part had been extracted; but it was still more complete at the end of six months. In a rabbit killed at that period after extraction of the lens on both sides, "the crystalline capsules were perfectly transparent, and no cicatrix could be discovered: they contained crystallines perfectly similar in size and consistence to those which had been extracted. To be more certain of their nature, we plunged them in boiling water, when they became opaque, hard and friable, just like the original lens."¶

The cases, to which depression is best suited, are the hard cataracts, in which, for some of the reasons before mentioned, extraction might not be advisable; or, when the operator does not feel sufficient confidence in himself to perform the last mentioned operation. The advantages of depression are its facility, the less degree of risk to the organ, and the power of repetition.

* Beobachtungen über die organischen Veränderungen im Auge nach Staaroperationen; mit drey Steindrucktafeln. Frankfort am Mayn, 1828.

† Pathologie chirurgicale, p. 135, plate x. fig. 15.

‡ Lib. cit., p. 36, plate ii. fig. 5.

§ Ibid., p. 135, plate x. fig. 14.

‖ Expériences relatives à la Reproduction du Cristallin, in the Journal de Physiologie, tom. vii. p. 30.

¶ Ibid., p. 43.

SECTION IV.—THE OPERATION BY SOLUTION OR ABSORPTION.

It was found by casual observation, that the lens occasionally disappeared from the pupil without being depressed. For instance, in some cases in which depression had been attempted, but not accomplished, on leaving the eye quiet for a certain time, the cataract disappeared. Mr. Pott and Mr. Hey, who were advocates for depression, found, when attempting to operate on soft cataracts, that the needle passed through them; and they observed in these cases, in which the operation was supposed to have failed, that after a time the pupil became clear: this of course showed that absorption went on after the capsule had been lacerated, and the aqueous humor admitted to the lens. Hence arose the idea of operating designedly in this manner, viz., to disturb or break the lens, and perhaps to lacerate its capsule, and then leave it for absorption. This mode was afterwards called the operation by solution; it might, perhaps, be more correctly called that by absorption. The lens is neither depressed nor extracted, but placed under such circumstances, that it disappears from the eye, being either dissolved in the aqueous humor, or taken up directly by the absorbents. It is a very useful operation, and easy of performance.

The mode of proceeding is to introduce the instrument in the same situation as for depression. We generally use a needle which cuts a little further on the sides than that of Mr. Saunders, the only difference between that and the former being the addition of a cutting edge extending not more than a quarter of an inch from the point. The object is to divide the anterior layer of the crystalline capsule. If the cataract be fluid, its contents will pass into the anterior chamber, and render the aqueous humor turbid: but if it should be only soft, not fluid, we move the needle gently once or twice through it, after having freely lacerated the capsule, and then withdraw the instrument. The object is to lacerate the anterior capsule, without displacing the lens from its natural situation.

This operation may be followed by inflammation, just as any other punctured wound of the globe; but if we proceed carefully, and are content to do little at a time, it does not excite much inflammation. The absorption of the lens goes on to a certain extent: probably some of its exterior soft substance will pass through the opening in the capsule into the anterior chamber, and then be absorbed. After a lapse of some weeks we may operate again, dividing the substance of the lens, but taking care not to dislocate it. We may at last proceed more freely, breaking up what remains into fragments, and carrying them into the anterior chamber.

The points to be attended to in this mode of proceeding are, first, not to displace the lens; for if we do, it will bulge against the iris, press upon and irritate that part, and thus occasion great mischief; secondly, not to attempt too much at once, but rather to repeat the operation, and at last, when the lens has been diminished and softened by absorption, to divide the capsule more extensively, and perhaps after breaking up the lens to carry the fragments through the pupil into the anterior chamber.

The cases particularly fit for the operation by solution are fluid and soft cataracts; in them it is sufficient to lacerate the capsule, and let in the aqueous humor upon the lens. It is also applicable to caseous cataracts: and may even be performed on those of firmer consistence. But in the latter, much longer time is required for absorption, as might naturally be expected. The operation, however, is objectionable in such cases from the possible passage of a hard portion of lens, after the softer substance has been absorbed, into the anterior chamber, where it would excite serious inflamma-

tion. The less inflammation is excited, the more rapidly does absorption go on. The removal even of a soft or caseous lens is often tedious; and this circumstance forms a real objection to the operation. Patients are anxious to get sight restored, and the surgeon is equally desirous of accomplishing the point. Delay is, however, unavoidable in this method of proceeding, in which weeks, and even months, sometimes elapse before the cure is finished. The only compensation to the patient for the extension of time, is the diminished risk of inflammation.

In attempting to remove cataract by absorption, it may be advantageous to begin by simply puncturing or slightly lacerating the anterior portion of the capsule. This is done by the anterior operation, or keratonyxis, which will be described presently. We carry the point of the needle through the capsule, make a small perpendicular laceration, and then withdraw the instrument. When the size and firmness of the lens are diminished by the absorption thus excited, we may operate behind the iris, and divide the cataract more freely.

[This operation is the one usually performed at Wills' Hospital by the editor and his colleagues, and the results have been remarkably satisfactory. It is applicable we are convinced, from ample experience, to a larger number of cases than has usually been supposed, and may be successfully resorted to even in hard cataracts, by adapting the mode of operating to this condition of the lens.

This operation has the great advantage over extraction and depression, that it is far less liable to be followed by destructive inflammation; and in healthy individuals when the operation is well performed, the patient suitably prepared, and proper precautions subsequently taken, the risk from inflammation is exceedingly small. Of all the operations performed at the Wills' Hospital, we cannot learn of more than two that proved unsuccessful from inflammation. One was the first operation performed at the hospital, on a patient whose eye was in a very unsuitable condition, and the surgeon, with the knowledge we now possess, would not, we are convinced, think of operating under similar circumstances. The other was a patient upon whom we were induced to operate contrary to our own judgment, and the result confirmed our predictions.

It has also been urged in favor of this operation, that little manual dexterity is required for its performance. This may be true, in comparison to that required for extraction; but we protest against the inference. The merest bungler may perform it, nay we have seen them do so, and sometimes even with success. But what would be the results of a large number of their operations? assuredly disastrous in a great proportion. To perform this operation well, requires skill, experience, coolness and judgment. No one should attempt it, until he has studied well the relations of the parts involved, and has fully considered all the difficulties he may encounter, and is prepared to obviate them.

The pupil should be previously well dilated. The best position for the patient is recumbent on his back, on a table, his head supported by a round hair pillow. The lids should be separated and the ball steadied as shown in the annexed figure, (fig. 122,) which represents the left eye, the lower lid depressed and the ball steadied by the first and middle finger of the left hand of the operator; the upper lid raised by the first and middle finger of the assistant's right hand.

The point of puncturation of the sclerotica should be a line and a half or two lines from the temporal margin of the cornea, and in the line of its transverse diameter. We generally use a straight needle, which should be introduced perpendicularly to the surface of the eyeball, the

Fig. 122.

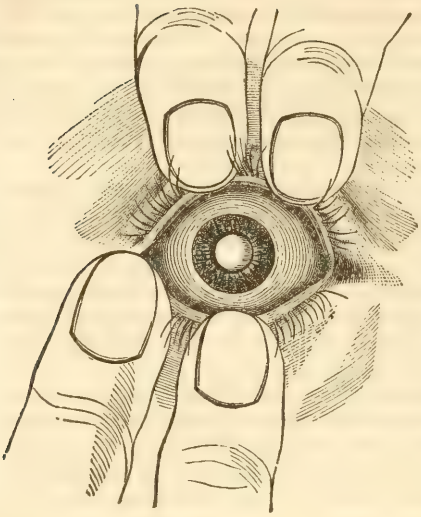

edges looking upwards and downwards. The puncturation should be made quickly, and the needle introduced only a short distance. This accomplished, the surgeon should steady the eye with the neeedle and wait an instant until the patient has recovered from the shock. The direction of the needle should then be changed, so that its point may be advanced between the iris and the lens, when the instrument should be steadily pushed on until its point reaches the opposite pupillary margin of the iris. In executing this step, care must be taken not to wound the ciliary body, or iris on the one side, or to spit the lens on the other. If the former accident happens, injurious inflammation may result; if the latter, especially if the lens be hard, it will probably be dislocated, and in this case it must be either at once depressed, or extracted; the latter is the preferable alternative. When the needle is pushed into the lens without dislocating it, the instrument should be carefully withdrawn until its point is free, and then pushed on again in a better direction.

This step being accomplished, the needle should be rotated one quarter round its axis, so as to present a cutting edge towards the lens. If the lens is hard, several incisions should be made in the anterior capsule and then this membrane freely lacerated crossways with the point of the instrument; this accomplished the instrument should be withdrawn. The lens exposed to the aqueous humor will become softened, partly absorbed, and at a subsequent period the operation may be repeated and the lens completely broken up.

If the lens is not very hard, in addition to lacerating the anterior capsule, more or less of the anterior portion of the lens may be broken up and placed in the anterior chamber; and if the lens is sufficiently soft, the whole of it may be broken up at the first operation. It is advantageous to push as many as possible of the fragments into the anterior chamber, absorption being more speedily accomplished there, than in the posterior. The pupil should be kept dilated for several days after the operation. If any fragments of a hard lens press upon the iris, producing irritation and threatening destructive inflammation, they should be removed through a small incision in the cornea.

If a fragment of opaque capsule remains, which impairs vision, it should be, at a future time, removed in the same way. An incision is to be made in the cornea as in the first step for extraction; and when the incision extends to one-fourth or one-sixth the circumference of the cornea, the knife is to be withdrawn. A small hook, formed something like the barb of a fish-hook, or a crotchet needle, is then to be introduced with its hook in the direction of the incision, and being carefully advanced opposite to the fragment, it is then to be rotated one-quarter round its

axis so as to present its point to the fragment, and having hooked the latter, the instrument is to be rotated back again and withdrawn in the direction it was introduced.]

Whether the lens is removed by absorption or solution.—It is not yet determined whether the lens is removed from the chambers of the eye by absorption, or whether it disappears by solution in the aqueous humor. Removal by the absorbents is a matter of common occurrence in other parts of the body; but I know no instance in which a solid is dissolved. Analogy would therefore lead us to consider the occurrence as an exemplification of absorption. When a portion of lens is in the anterior chamber, no changes occur in it like the action of a solvent; nor is the transparency of the aqueous humor affected. The solvent action, if it be such, is very different from ordinary solution; for fragments of lens lie in the supposed menstruum often for weeks or months with little change. Sometimes, however, the lenticular substance gradually wastes and is removed at points where it is not in contact with any surface, as in the case of a fragment protruding through the capsule and pupil into the anterior chamber, also on the upper surface and sides of fragments resting in the bottom of the chamber.

However the process is effected, it goes on more actively, and is therefore accomplished more quickly in the anterior than in the posterior chamber. Some time ago I operated on both eyes of a boy, between two and three years of age, for congenital cataracts: they were lenticular and gelatinous, the crystallines being of their natural size, and of a pure milky-white. In the eye first operated on, I divided the capsule and lens with the needle, and gently disturbed the latter, which remained in its situation behind the pupil. At the end of a fortnight I operated on the other eye. The lens revolved when I pressed the needle against it for the purpose of dividing it, and passed entire into the anterior chamber, which it nearly filled. Slight irritation occurred on the second or third day, requiring the application of three or four leeches; there was no subsequent redness or uneasiness, and the removal of the lens was complete by the end of the sixth week, leaving a clear black pupil, an iris with full power of motion, and perfect vision. The opaque body still filled the pupil in the opposite eye, apparently but little diminished. "I saw," says Professor Walther, "an entire firm dirty yellow lens pass into the anterior chamber, in a young man: it was completely absorbed in seven weeks. The presence of the foreign body at first excited considerable inflammation; and I thought it would be necessary to imitate the proceeding of Daviel, and extract it. But the parts gradually became accustomed to the irritation; the inflammation passed off, and I enjoyed with my pupils the interesting spectacle of an entire firm lens undergoing gradual removal by absorption, which was followed by complete recovery of sight."*

We must, however, proceed cautiously in passing fragments of opaque lens into the anterior chamber, because they act as foreign bodies, and often excite considerable and obstinate inflammation, during which the process of absorption is suspended. This is particularly the case when the fragment is of firm consistence: a small particle of hard lens will cause so much irritation as to render its removal by a section of the cornea necessary, while even a considerable piece of the soft or gelatinous kind may be introduced into the chamber with impunity.

The mischief produced by the passage of a hard lens into the anterior chamber is exemplified by a case related and figured by Dr. Farre in the work quoted below, (Plate 7, fig. 6, and page 231.) "Fig. 6 is added to

* Merkwürdige Heilung eines Eiterauges, &c., p. 59, 60.

show the effect of making too large an aperture in the anterior lamella of the capsule. WHEATLEY, admitted into the infirmary in 1810, was dismissed with a free aperture in the capsule, and a lens partially dissolved, so as to leave a segment of the pupil clear, the eye was perfectly free from inflammation, and his vision was very useful: but as the solution went on, the large nucleus lost its support, and dropped into the anterior chamber, as it is represented. From that moment inflammation was excited, and has been kept up in different degrees for more than twelve months, by which the process of solution has not only been considerably retarded, in consequence of the effusion of coagulable lymph around this nucleus, but the cure has been rendered doubtful." In the figure, to which the preceding account refers, a lens not much below the natural size is seen in the anterior chamber of an inflamed eye.

The opaque capsule does not undergo absorption behind the iris; perhaps because it retains more or less completely its natural connections. Thus we see it remaining in the eye unaltered for years. From the case, related at p. 183, it should seem that the capsule is not liable to absorption even in the anterior chamber. In his account of Mr. SAUNDERS' operation for congenital cataract, Dr. FARRE states generally that the opaque capsule is never removed by absorption: "all that is capable of being absorbed, nature herself removes, and she only fails to accomplish her purpose, because the capsule cannot be destroyed by this process."* In the same work, the 1st and 2d figures of the 6th plate "represent the eyes of CHAPPLE, a girl twelve years old, in whom the central aperture was affected in both eyes; and as the cataract was capsular, the aperture would have been enlarged, if the capsule had not been so tough as to render it impossible. This thickened capsule is incapable of being dissolved or absorbed. A margin of it behind the pupil, and some portions of it which were detached into the anterior chamber, presented the same appearance at the end of three years which they did immediately after the operation."† I have seen this patient more than once, many years after the description just quoted was written: the fragments of capsule remained unaltered in the anterior chamber.

Keratonyxis.—The operation by solution or absorption, has been sometimes performed by introducing the needle through the cornea, and lacerating the capsule of the lens. This, which is called *keratonyxis*, was first practised by a German surgeon named CONRADI.‡ It was introduced

* A Treatise on some Practical Points, &c., by the late J. C. SAUNDERS, 2d edit. p. 156.

† Ibid., p. 225.

‡ GLEIZE opened the capsule with a needle introduced through the pupil, when he had been foiled in an attempt at extraction; a sudden movement of the patient having withdrawn the eye from the knife after the cornea had been punctured. The cataract was completely dissolved by the twentieth day. He subsequently repeated this proceeding intentionally in other cases, and always with good result. The solution of the lens takes place in fifteen to fifty days; the softer the cataract the shorter is the time required for solution. He observes that depression might be accomplished in this way.—Nouvelles Observations pratiques sur les Maladies de l'Œil et leur Traitement.—Paris, 1796.

CONRADI, who was stadt-physicus (town-physician) in Northeim, proposed the introduction of the needle through the cornea as a regular mode of operating, in his Vorschlag zu einer einfachen Methode den Staar zu stechen, contained in his Chirurgische Beobachtungen, printed in ARNEMAN'S Magazin fur die Wundartzneywissenschaft, vol. i. stück i., 1797. He was obliged to withdraw the knife after opening the cornea in an attempt at extraction; he punctured the capsule with a needle, and in eight to twelve weeks the pupil was clear. He has stated fairly the advantages of the method, and observes that if the cataract does not dissolve, any other operation may be performed. He operated on a woman of seventy; at the end of

into practice in this country by Mr. SAUNDERS. It is an essential circumstance in the performance of keratonyxis, that the pupil should be fully dilated by belladonna. Mr. SAUNDERS, who employed this mode of proceeding in congenital cases, proposed to make an opening in the centre of the capsule, and having slightly acted on the lens, to leave it for absorption. He used his straight sharp-pointed needle, which should be carried through the cornea at a small distance from its margin, with the flat surfaces directed forwards and backwards, [fig. 123;] it should be so constructed as to fill the wound in the cornea, and thus prevent the escape of the aqueous humor. LANGENBECK extended the use of this method, and resorted to it for the purpose of depression and of breaking up the lens for absorption. He used a curved needle, nearly like SCARPA's, cutting on its edges, and filling the puncture as it entered. He introduced this needle from below. In a tract on the subject in which the mode of operating is minutely described and illustrated by figures, as well as by numerous cases, LANGENBECK gives the most favorable account of the operation and its results.* It has not been viewed in the same light by others. BEER tried it extensively soon after its proposal by CONRADI; but his cases turned out badly;† and the result of the several trials by JAEGER‡ was equally unfortunate. There is much less power of acting on the lens and capsule, whether for depression or division, when the needle is introduced through the cornea in the *anterior operation*, as keratonyxis is also called, than in the posterior, when it is entered behind the iris. This method, therefore, is altogether ill suited to the purposes of depression or division of the lens. Escape of the aqueous humor at the puncture of the cornea often occurs, being followed by protrusion of the iris and lens against the needle, and sometimes by dislocation of the latter. At least it prevents us from prosecuting the operation. That it frequently gives rise to severe internal inflammation is shown by the cases in the dissertation of Professor JAEGER. The same point is illustrated by the circumstance of an essay§ having been written expressly to describe the phenomena and treatment of a chronic iritis frequently consequent on the operation. It appears clearly that the author had seen the affection repeatedly. I think that the anterior operation should be abandoned as a general mode of proceeding, that it should be confined to the laceration of the capsule, and the consequent admission of the aqueous humor to the substance of the lens, as the first step in the proceeding by absorption or solution, the operation being subsequently completed by the needle introduced behind the iris.

Fig. 123.

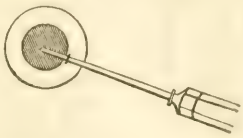

twenty months there was no change. Probably it was a hard lens. BUCHHORN gave to this method the name Keratonyxis (from κερας, horn, and νυξις, puncture,) and made it the subject of his inaugural dissertation at Halle in 1806, under the title "De Keratonyxide, nova Cataractæ aliisque oculorum morbis medendi methodo chirurgica." He afterwards published a full account of the subject in the German language; Die Keratonyxis, eine neue gefahrlosere Methode den grauen Staar zu operiren.—Magdeburg, 1811.

* Prüfung der Keratonyxis, einer neuen Methode den Staar durch die Hornhaut zu operiren, ihn zu zerstückeln, &c.—Göttingen, 1811.

† Einige praktische Bemerkungen, &c., in ARNEMAN's Magazin, vol. i. stück 3.

‡ Diss. inaug. de Keratonyxidis usu, Vienna, 1812. It is reprinted in RADIUS, Scriptores ophthalmologici Minores, vol. i.

§ Commentatio ophthalmica de Iridite chronica ex Keratonyxide suborta, a H. B. SCHINDLER; Vratislaviæ, 1819. An abstract is given in LANGENBECK's Neue Chirurgische Bibliothek, vol. ii.

[Dr. Jacob of Dublin has contrived a needle which he conceives particularly applicable to the anterior operation, and which Dr. Mackenzie pronounces to be preferable to all others; combining the advantages of a small blade, with great strength and fine temper, inflicting so minute a wound that no mark remains in the cornea, capable of effectually opening up the texture of the lens, and from its conical form, not permitting the aqueous humor to escape during the operation. (*Practical Treatise*, p. 713.)

Fig. 124.
Fig. 125

This instrument consists of a common needle of the size "known in the shops, as number *seven*, being the forty-fourth part of an inch in diameter, about one half the size of the finest Saunders' needle which is made. The point can be turned to the requisite curve by means of a pair of cutting forceps, or the ward of a small key; of course without heat, which would destroy the temper. It must not, however, be expected that all needles are so soft as to be bent thus cold: there may not be ten in a hundred of this temper, but when once turned they retain the curve without any danger of bending or breaking, and certainly possess a degree of strength and temper never observed in needles separately forged and finished by the best cutlers. They should always be tried before use, by passing them repeatedly through thick calve's-skin leather. After they have received the requisite curve, the point should be cut flat on each side, on a fine hone, and carefully examined with a magnifying glass, to ascertain that it is perfect. [See fig. 124. Figure 125 represents a magnified view of the point, and a part of the blade.] The extent to which the point should be curved, may be left to the choice of the surgeon, reminding him that the greater the curve the more effectual the needle will be when introduced, but the difficulty of introducing it through the cornea will also be greater. I therefore recommend those who use it for the first time to choose one slightly curved. After the point has been turned, the needle, held in the jaws of a pair of pliers or a vice, is to be run down into a cedar handle, without cement, leaving only *half an inch* of blade, which I have found to answer every purpose. If the blade be left longer it will yield and spring when opposed to a resistance. The handle should be about a fifth of an inch in diameter, and four inches long. I use the handles made for camel-hair pencils, and find that a metallic ferrule, which increases the weight, is unnecessary and objectionable. A needle thus constructed, and preserved free from rust, will retain its point for a great length of time: I have used the same one a dozen times without sharpening." (*Dublin Hospital Reports*, vol. iv.)

Dr. Jacob operates with this instrument in the following manner:

"The surgeon, provided with such a needle, places himself in the usual position with respect to the patient, availing himself of whatever assistance he may find necessary to secure the lids.* He then brings the

* "Some ophthalmic surgeons recommend that the left hand be employed to operate on the right eye, supposing the operator to sit in front of the patient. I operate on the left eye sitting opposite to the patient, on the right standing behind him with the head resting against my chest; this latter position I find by far the most favorable and convenient."

point of the needle within a very short distance of the eye, and when the cornea is brought into an advantageous position, he suddenly strikes the needle into it near its circumference. As I do not apprehend any opacity from the wound, I am not very particular with respect to the precise point, where the needle pierces; I generally, however, enter it sufficiently near the margin to obviate defect from this cause. The point of the needle once fastened in the cornea, the surgeon has complete command of the eye; no action of the muscles can disengage it, and there is no danger of the needle slipping into the anterior chamber; an elevator or ophthalmostat is therefore altogether useless. The operator now pushes the needle through the cornea, which frequently yields like wet leather, and the eye often turns so much toward the inner canthus that the pupil is hid, and he must rely upon his knowledge of the course which the needle necessarily takes, in order to conduct it to the lens. This is the principal difficulty to be surmounted. If the surgeon does not now steadily push the needle forward, whatever resistance he may feel, he will find, when the eye returns to its proper position, that the point of the needle is still merely entangled in the cornea. This also is the period of danger to the iris: if the operator does not keep the flat of the needle to that membrane, with the point down, and the convexity up, he will be very liable to injure it. Should it happen that the point of the needle has passed through the iris, it may be easily extricated by gently drawing back the instrument without removing it from the eye. After the needle has been fairly entered, and the operator sees its point at the opposite side of the pupil, he brings the cornea forward, merely by pulling it upon the needle, to which it is completely secured, in consequence of the blade being wedged into its texture. He now turns the point directly back, and gently tears open the capsule, picking and scratching the surface of the lens with a rotatory or drilling motion of the instrument; not with the lever or cutting movement, which is necessary when SAUNDERS' needle is used. If the lens be soft and friable, the fragments fall like snow into the anterior chamber, and the surgeon may deal very freely with it, pushing the needle deep into its structure, and twirling the point round so as to mash it into a pulp. If, however, it proves hard, and that he attempts to deal thus with it, he fixes his needle in its tough and glutinous structure, turns it out of the capsule, drags it against the iris, and makes it necessary either to extract it or force it back into the vitreous humor. If the cataract be hard, the capsule should be opened, and the centre of the lens cautiously scratched with the point of the needle, so as to expose its texture to the contact of the aqueous humor, by which it is softened and fitted for breaking up on a future occasion. In withdrawing the needle the surgeon has to encounter the same description of difficulty which attends its introduction; it is tightly held by the cornea, requiring to be turned on its axis in order to extract it as an awl is drawn from the leather. It must not, however, be forgotten that this wedging of the instrument is attended with the great advantage of enabling the surgeon to operate on the most unsteady eye without an ophthalmostat or elevator."—*Dublin Hospital Reports*, vol. iv.

Fig. 126.

We have ourselves always employed in this operation, either

a small Scarpa's needle (fig. 118,) or one such as is represented in the accompanying figure, (fig. 126,) both of which have cutting edges, and therefore operate more favorably in cutting up the lens and capsule, when a rotatory or drilling motion is given to the instrument, than Dr. JACOBS', which, under such circumstances, present its flat sides. Dr. JACOBS' instrument would perhaps answer better if it were ground above and below instead of on each side. A good edge is not so readily, however, given to it in that way, but perhaps this might be accomplished by grinding it before bending.]

Operation when the capsule is opaque, and the pupil adherent.—In cases of capsular or capsulo-lenticular cataract complicated with adhesions of the pupil, Mr. TYRRELL (vol. ii., p. 464—476) has frequently employed with advantage a modification of the anterior operation by solution, which he calls the operation of drilling. A fine straight needle is carried through the cornea near its temporal edge, it penetrates the capsule, and enters the lens to the depth of about one-sixteenth of an inch. The handle of the needle is then rotated between the finger and the thumb so as to make the point act like a drill; and the instrument is withdrawn. The operation is repeated every three, four, or five weeks, the capsule being punctured, if it can be so managed, in a fresh place on each occasion. It has usually been necessary to repeat the operation seven or eight times. It causes no inflammation, but excites absorption, by which the lens is slowly removed, the pupil being in many cases cleared and vision restored. If the retraction of the pupil is considerable, it may be necessary, after the lens has been absorbed, to make an artificial pupil.

SECTION V.—CONGENITAL CATARACT.

This is sometimes lenticular, but more frequently capsulo-lenticular. The lens is usually opaque throughout, generally of its natural consistence, which is gelatinous, sometimes softer or even fluid, but seldom, if ever, hard. After losing its transparency, the crystalline frequently undergoes absorption: hence we often find it lessened, reduced to a small fragment, or as thin as a wafer; it may even be removed entirely. Central opacity of the lens seems to be known only as a form of congenital cataract. Here, one-fourth, or a larger proportion of the diameter presents a grayish opacity, and the circumference is completely transparent, so that, when the pupil is dilated, there is good, or even perfect vision, although under other circumstances the patient is nearly blind. This partial central opacity sometimes presents exactly the appearance of a small opaque lens, surrounded by an opaque capsule: this appearance, however, is quite deceptive; the opacity in such cases affects only the nucleus of the crystalline, and it is surrounded by the rest of the organ in a transparent state. In this form of the affection the lens retains its natural magnitude; it does not become reduced by absorption.

The lenticular cataract of infants is generally attended with opacity of the capsule, which, as in the adult, is usually partial, in streaks, dots, or specks. Sometimes there is an opaque central portion, more or less considerable, and thick, so as to project above the general level. In proportion as the lens is absorbed, the anterior and posterior layers of the capsule approach each other, shrink, and become corrugated. At last a thick tough capsule alone remains (*cataracta arida siliquata*).*

* The kind of cataract was noted by Mr. SAUNDERS in forty-four cases; and the following enumeration exhibits the relative numbers of the different species:—

I am not able to state whether the affection is strictly congenital, not having seen it either within a few hours or a few days of birth. In the cases which I have seen, the complaint has not been discovered till some weeks after birth.

In a recent number of his interesting *Journal of Ophthalmology*, Professor Von Ammon has recorded some cases, which not only remove all doubt on the subject, but also elucidate the pathological anatomy of the affection.*

Case I.—The eyes of a female child were observed by the midwife to have a dull appearance immediately after birth. The child was consequently shown ten days afterwards to Von Ammon, who found a lenticular cataract in each eye. It died at the age of eight months, and the eyes were examined. The capsule was perfectly transparent in both. The lenticular substance was gelatinous, opaque, and large, with some firmer semi-transparent portions here and there. No trace could be observed of red vessels or spots, or red color of any kind in the lens or capsule. The retina, iris, and choroid were perfectly natural.

Case II.—Professor Haase, director of the lying-in-institution of Dresden, saw cataracts in the eyes of an infant born in the establishment, and gave Professor Von Ammon an opportunity of examining them immediately after birth. There was a lenticular cataract in each eye; in the left, the lens exhibited the threefold division which belongs to firm cataract. In the right there was a soft lenticular cataract, with slight capsular opacity. The child died when four months old. In the right eye there were nebulous spots on the anterior portion of the capsule: portions of the lens towards its middle, were opaque, but the circumference possessed its natural consistence and transparency, and the corresponding portion of the capsule was transparent. Four entozoa of the genus *Distoma* were found in the lens under microscopical examination. The capsule was transparent in the left eye. The centre of the lens, which had exhibited the threefold division, constituted an opaque and almost horny nucleus, while the circumference was transparent and of natural consistence. Professor Von Ammon had two opportunities of examining congenital central capsular cataracts in the eyes of the fœtus. Both were born about fourteen days before their time; one lived a few hours, and the other came into the world dead. The opacity was a central speck in the anterior portion of the capsule, without any

Solid opaque lens, with or without opacity of the capsule. Three single, two double cataracts	5
Solid lens, opaque in the centre, transparent in the circumference, with capsule in the same state. Five double	5
Soft opaque lens, with or without opacity of the capsule. Two single, two double	4
Soft opaque lens, with solid nucleus. One single, two double	3
Soft opaque lens, with dotted capsule; the spots white, the spaces transparent. Two double	2
Fluid cataract, with opacity of the capsule. Two single	2
Fluid cataract, with opacity of the capsule, and closed pupil. Two double	2
Opaque and thickened capsule, the lens being completely absorbed, or the remains of it being thin and squamose. Six single, twelve double	18
Opaque and thickened capsule, with only a very small nucleus of the lens in the centre. Two single	2
Opaque and thickened capsule in the centre, remains of the lens in the circumference. One double	1

—Lib. cit., p. 159.

The expression "*solid* lens," in the foregoing enumeration, must be understood to denote that the crystalline possessed its natural consistence; for it does not become firmer in congenital cases.

* Die angeborne Cataracta in pathologisch-anatomischer in pathogenetischer und in operativer Hinsicht. Zeitschrift für die Ophthalmologie, vol. iii. p. 70.

elevation of surface; the opaque part was, however, thicker than the rest of the membrane. The lens in both cases was transparent, but of reddish color.

It often appears in more than one child of the same family. It is stated by Dr. FARRE that sixty cases were submitted to the care of Mr. SAUNDERS. "Of these, two brothers, between whose ages there was a difference of six years, were both affected with congenital cataracts. In a second family, two brothers, twins, became blind with cataracts at the age of twenty-one months, each within a few days of the other. It is remarkable that the four cataracts had precisely the same character. In a third family, a brother and two sisters were born with this disease. The eldest sister was affected with it only in one eye, the brother and youngest sister in both eyes. In a fourth family, three brothers and a sister had all congenital cataracts. (*Lib. cit.*, p. 158.)

I had under my care, at St. Bartholomew's, two brothers, between two and four years old, with cataracts. They were lenticular in one, the crystallines being of their natural size; in the other, the lens was diminished on each side to a thin scale, the capsule presenting in each eye a thick dense central opacity, and a few small spots scattered around it.

Congenital cases differ much in the degree of vision enjoyed by the patient. In central lenticular or capsular cataract there may be good sight, especially when the pupil is dilated. In some cases, objects and colors can be distinguished; while in others the patient can merely distinguish light from darkness.

*Operation on infants.**—While extraction is not only altogether unsuitable to the various forms of congenital cataract, but absolutely impracticable without the greatest risk, or rather certain destruction of the organ, the cure can be accomplished with facility and safety by means of the needle. The smallness of the palpebral fissure, the unsteady movements of the eye, and the resistance of the child to all attempts at opening the lids, produce some difficulty in fixing the head and denuding the surface of the organ sufficiently for the purpose of the operation: this indeed is the only real difficulty in the process. The pupil should be fully dilated by the previous application of belladonna.

A narrow table is the most convenient for the operation. The child must be laid on its back, with the head on a small pillow, which should be so placed that the head may fall rather over it, in order that we may have a good light on the eye. One assistant must hold the legs and lower part of the trunk; another, the arms and chest; while a third, placed behind, fixes the head between his two hands, applied one on each side. A fourth assistant, who depresses the lower lid with the forefinger of one hand, may also, if necessary, use the other under the chin, to prevent any forward movement of the head. The operator, who is placed behind the head, raises the upper lid by the elevator of PELLIER, with which he holds it securely against the margin of the orbit; it cannot be so properly elevated and securely fixed by the fingers. With the other hand he pierces the tunics with the needle in the same situation as in the operation of depression. A small, straight, sharp pointed needle cutting on its edges for about

* On the use of the Couching-needle in Infants of a few months old, by B. GIBSON: in the Edinburgh Medical and Surgical Journal, vol. vii. 1811, p. 394.

On the operation of largely puncturing the Capsule of the Crystalline Humor, in order to promote the Absorption of the Cataract, by Mr. WARE, in his Observations on the Cataract, &c. 3d edit., 1812, p. 363.

On the Congenital Cataract, by Mr. SAUNDERS, in his posthumous work edited by Dr. FARRE, chap. vi.

one-eighth of an inch, should be employed. The purposes of the operation may, however, be accomplished with SCARPA's needle, which was used by the late Mr. GIBSON. (*Edinb. Med. and Surg. Journal*, vol. vii., p. 398.)

In operating on the right eye, the elevator is held in the left hand, and the needle in the right; when we proceed to the left eye, the employments of the hands are reversed. If the surgeon should prefer it, he may place himself in front of the patient to operate on the left eye; he will then depress the lower eyelid with his left hand, and hold the needle in the right, while an assistant, placed behind the patient, elevates the upper eyelid. I consider the first-mentioned method to be preferable, because the operator, holding the speculum, can exert with it a little pressure, so as to steady the eye, if it should be necessary. If the speculum is entrusted to an assistant, he must not venture to press on the globe.

After the coats have been punctured, the instrument must be passed through the thin edge of the cataract into the anterior chamber, and carried on till its point reaches the opposite edge of the pupil. The lens and capsule may now be divided transversely by a backward movement of the instrument, with which we may still further break up the lens, and push the fragments into the anterior chamber, where, on account of their softness, they excite little or no irritation, and are speedily absorbed.

Operation on opaque capsule.—When the lens has been removed by absorption, an opaque capsule usually remains, occupying more or less of the pupil proportionally impeding vision, and requiring another operation. If the capsule is transparent, sight may be restored by one operation. In the case of this secondary membranous cataract, or where we have to operate in the first instance on an opaque capsule, we proceed in the infant as we should do in the adult. There are various modes of proceeding applicable to the circumstance of different cases. The membrane that we have to operate on is found in different states. In texture it is usually firm; it may be thin, semi-transparent, and easily lacerable; often it is of considerable thickness, particularly in its shrunk and collapsed state, after the spontaneous absorption of the lens. It may be densely opaque, tough and strong, so as to resist the instrument, and to require considerable force before its division or detachment can be accomplished. It may be a continuous membrane, filling the space behind the iris, or it may occupy that space only partially. There may be openings in it, or it may consist merely of one or more larger or smaller shreds. Not unfrequently it is thick and perfectly opaque in one part, thin and semi-transparent in others. It may be attached at the circumference, and consequently tense; or it may be separated to a greater or less extent, so as to be loose, and even to move backwards and forwards. The edge is usually fixed to the ciliary body; it may be attached to the pupil also, or solely; and this pupillary attachment may be general or partial.

A central opening may be made in the capsule, with the needle, introduced either through the cornea or the sclerotica, in the mode recommended by Mr. SAUNDERS for the operation on congenital cataract.

Another mode of proceeding is to make a straight transverse incision through the opaque capsule with the cutting needle, leaving its connections at the circumference undisturbed. Indeed, care must be taken not to detach it from the ciliary body. The edges of the incision retract and separate, so as to leave ultimately a sufficient pupillary aperture.

A third method consists in introducing the needle with cutting edges behind the iris, detaching the opaque membrane at its circumference on the upper part and sides, for about three-fourths or four-fifths of its whole

extent, separating it as completely as we can from the ciliary body, and depressing it. When thus detached and depressed, it rises up after the needle is removed, and seems to fill the pupil as before; but it shrinks when no longer connected at the circumference, and is gradually withdrawn behind the lower edge of the pupil.

The greatest difficulty is experienced in dealing with a loose or floating capsular cataract. We can depress it; but it rises again. If we can pierce it with the curved needle, and especially if we should be able to carry the needle through it twice, we can roll it up by rotating the needle between the finger and thumb, and in this state it will be removed from the axis of vision as the instrument is withdrawn.

The anterior operation, or keratonyxis, may be performed on the infant; and was generally preferred by Mr. SAUNDERS. Pressure on the globe must be carefully avoided in adopting this method, as it would favor the escape of the aqueous humor, an occurrence which either renders further proceedings difficult, or prevents them altogether. The power of acting on the lens and capsule, for the purposes just described, is so much less in this method than in the posterior operation, that I consider it particularly unsuited to congenital cases, and have consequently long abandoned it in them.

The operation of keratonyxis was well enough suited to the particular object which Mr. SAUNDERS attempted to accomplish in congenital cataracts; viz., the formation of an opening in the opaque capsule. His mode of proceeding is thus described by Dr. FARRE. "The surgeon gently introduces the bow of the speculum under the upper eyelid, his assistant at the same time depressing the lower, and at the moment he is about to pierce the cornea, he fixes the eye by resting the speculum with a moderate pressure on the eyeball. The position of the operator enables him to do this with perfect safety; and by that consent which can only exist between the hands of the same person, he not only discontinues the pressure, by using the speculum merely as an elevator of the lid, as soon as his purpose is accomplished, but he with facility renews or regulates the pressure at any moment in which it may be required. He penetrates the cornea as near to its junction with the sclerotica as will admit the flat surface of the needle to pass, in a direction parallel and close to the iris, without injuring this membrane. When the point of the needle has arrived at the centre of the dilated pupil, he does not boldly plunge it through the capsule into the lens, and perform any depressing motion; it is a material object with him not to injure the vitreous humor or its capsule; neither does he lift the capsule of the lens on the point of the needle, and by forcibly drawing it forward into the anterior chamber, rend it through its whole extent. Such an operation would dislocate the lens, deliver it into the anterior chamber, or leave it projecting in the pupil, and stretching the iris; and, although its soft texture in the child should exempt him from any disorganizing inflammation, the most favorable result will be a permanently dilated iris, deforming the eye. He proceeds with a gentle lateral motion, working with the point and shoulders of the needle only on the surface and centre of the capsule, in a circumference which does not exceed the natural size of the pupil. His object is *permanently* to destroy this central portion of the capsule; merely to pierce it would not answer his intention, because the adhesive process will speedily close the wound. Having acted on the centre of the anterior lamella of the capsule to the extent which he wishes, he gently sinks the needle into the body of the lens, and moderately opens its texture."* "A

* A Treatise on some practical Points relating to the Diseases of the Eye, by the late J. C. SAUNDERS, p. 163—165.

single operation sometimes suffices, and the cure is completed in the space of a few weeks; but if the process does not advance with sufficient rapidity, the operation may be repeated once or oftener, interposing at least a fortnight between each operation. If the adhesive process has counteracted his former operation on the capsule, he may take care now to effect the permanent aperture in the centre, and he may use greater liberty than at first in opening the texture of the lens." (*Ibid.*, p. 166.)

Mr. SAUNDERS acted in the same manner on the lens and capsule, when he introduced the needle behind the iris. "As soon as the needle has penetrated the tunics, he gently depresses its handle, so as to direct its point towards the capsule through the thin edge of the lens; and steadily projecting its flat surface between the capsule and lens, he arrives at the centre of the capsule, which he opens, taking the same precaution as in the anterior operation, not to rend it extensively, lest he should dislocate the lens. He now cautiously opens the texture of the lens, and withdraws the needle. In his subsequent operations he will complete the central aperture in the capsule, and then loosen the texture of the lens, suffering the flocculi to fall into the anterior chamber, but not projecting into it any considerable portions of the lens, for the process of its solution and absorption is best accomplished in its natural position." (*Ibid.*, p. 170.)

If the operation on the infant be performed with the requisite gentleness, it is rarely followed by inflammation.* Hence both eyes may be operated on at the same time. The patients, however, must be closely watched; their bowels must be kept open, and leeches must be immediately applied if redness and pain should supervene. A cloth dipped in cold water may be kept on the eyes, if it can be easily done: but if its application annoys the child, and the eye is not inflamed, it need not be persisted in.

Permanent dilatation of the pupil should be kept up after the operation by applying the moistened extract of belladonna on the brow.

Two or more operations are sometimes necessary to accomplish the point of clearing the pupil. Dr. FARRE recommends that a fortnight at least should intervene between each operation. (*Lib. cit.*, p. 166.) Mr. WARE tries to promote absorption "by dropping on the eye once or twice in the day a small portion of powdered sugar"! If this should not succeed, he operates again at the end of a week or ten days; and repeats the operation, if necessary, after a similar interval. (*Lib. cit.*, p. 375.) I consider both these periods to be much too short. If the lens be left in its situation behind the iris, its absorption will occupy many weeks.

What is the proper age for the operation?

It was formerly the practice to defer the operation, in cases of congenital cataract, till patients had grown up; at least, until they had attained an age at which they might be supposed to understand the necessity and importance of the operation, and be able to exercise self-constraint in submitting to the proceeding. Unfortunately, however, when a person is born blind, the eyes oscillate irregularly from side to side. They seem to be equally acted on by various muscles, which, from the want of external perception, do not acquire the power of directing them, or fixing them on objects sufficiently for distinct vision. If the blindness continues long after birth, this unsteady rolling motion becomes confirmed and inveterate, so that, even if we succeed in giving sight by the operation, the patient has not the power of controlling the muscles of the eye by the exercise of volition. Years

* If the patient suffer much pain either during the operation or after it, it may be advisable to take blood from a vein in the arm, or by leeches from the temple; but in my own practice I have not found this once necessary in infants, and, very rarely, in persons under twenty years of age."—Mr. WARE, in the book before quoted, p. 371.

may elapse without any progress in gaining such a power; and probably persons thus circumstanced never become able to fix the eyes sufficiently for good vision. I operated at the London Ophthalmic Infirmary, for congenital cataract, on a girl fourteen years old. The operation was completely successful, and both pupils were as clear as if she had been born with perfect eyes. At the end of some months the rolling motion still continued, so that vision was not of much use. In a case mentioned by Dr. Farre, he says, "the disadvantage of a protracted operation was very manifest. It was performed on both eyes at the age of ten years, but such a tremulous motion of them had been acquired, that she cannot even now, although three years have elapsed since she was cured, direct her eyes to objects with sufficient precision." (*Lib. cit.*, p. 225.) While this sheet is passing through the press, I have seen a youth of fifteen, in whom the eyes were operated on seven or eight years ago; they still oscillate irregularly from side to side as before the operation.

Dr. Farre also thinks that the power of the retina becomes impaired by want of exercise. "The retina, too, by a law common to all the structures of an animal body, for want of being exercised, fades in power. Its sensibility, in many of the cases cured at the ages of four years and under, could not be surpassed in children who had enjoyed vision from birth; but at eight years or even earlier, the sense was evidently less active; at twelve it was still more dull; and from the age of fifteen and upwards, it was generally very imperfect, and sometimes the mere perception of light remained." (*Ibid.*, p. 176.)

Mr. Saunders operated on five cases, at different ages from two to nine months; and on nine, from thirteen months to two years. His other patients, amounting altogether to sixty, were of various ages from that last mentioned to twenty-eight. "The greatest success attended the operation between the ages of eighteen months and four years; and if any intermediate time be selected, the Editor is inclined to recommend the age of two years. The parts have then attained a degree of resistance which enables the surgeon to operate with greater precision than at an earlier period, yet the capsule has not become so tough and flexible as it does at a later period after the lens has been more completely absorbed." (*Lib. cit.*, p. 175.)

I have operated with perfect success on infants of six weeks: in general two months would be early enough. Thinking it of consequence that the education of the eye should begin early, and wishing to avoid all risk of the involuntary movement of the globe becoming confirmed, I have always operated in the first year, when I have had the choice.

Secondary cataract.—When an opaque body is seen in the pupil after an operation for cataract has been performed, the case has been called secondary cataract. In the proceeding by absorption or solution, the lens is generally left in its situation, and consequently is seen behind the iris after the operation: this is not called secondary cataract, that name being given to opacities in or behind the pupil subsequent to extraction, depression or reclination. A fragment of lens, or more frequently some of its exterior soft substance, may remain in or behind the pupil after either of the operations last mentioned: they will be removed sooner or later by absorption. After the lens has been removed from the axis of vision, an opaque capsule may remain behind; or the capsule may become opaque after the operation. Such secondary membranous cataracts must be treated in the manner already described (see p. 669). In the case of a floating piece of capsule, which can neither be depressed nor disposed of in any other way, if it should impede vision, we must make an opening in the cornea, and extract

it by means of a small forceps or hook.* This, however, being a hazardous proceeding, must be executed very cautiously. Another kind of secondary membranous cataract results from inflammation of the iris, when it produces effusion of lymph, and its subsequent organization into an adventitious membrane. This may be remedied by the method already mentioned of operating for capsular cataract, or by the operation for artificial pupil.

CHAPTER XXII.

GENERAL AFFECTIONS OF THE GLOBE.

SECTION I.—INFLAMMATION OF THE GLOBE (OPHTHALMITIS).

Common inflammation may attack both the external and internal structures of the eye at once. This affection, which is by no means of frequent occurrence, is called by Beer *ophthalmitis idiopathica*. It occurs chiefly in robust individuals of full habit under the influence of some serious exciting cause; and it is most frequent in the right eye.†

Symptoms and progress.—When this general inflammation of the globe is fully developed, it is characterized by very considerable pain, increased external redness, and more or less swelling of the part; by increased lachrymal discharge, and by redness and swelling of the upper lid. In the earliest stage we can see the sclerotica red as well as the conjunctiva; the pink redness of the former membrane, and the distended network of its vessels are seen through the latter. But vascular congestion rapidly increases in the conjunctiva; its texture swells, and thus the fainter pink tint of the sclerotica is concealed. The conjunctival redness, at first slight, becomes deeper and deeper, and at last reaches the full intensity and brightness of scarlet cloth.

The pain is always a leading symptom, and one to which the patient immediately adverts. It is exceedingly severe, and is described sometimes as acute, sometimes as of a dull aching kind, and sometimes as conveying a sense of throbbing and burning. Very commonly the patient feels the eye tight, as if it were too large for the orbit, and about to burst from it. The pain is by no means confined to the front of the eye, but is deep-seated, and extends to the surrounding parts, as the brow, cheek, temple, and back of the head.

The redness is inconsiderable at the commencement, but it gradually increases, and ultimately the surface of the eye assumes a bright red color.

The conjunctiva, which is at first the seat of mere vascular fullness, begins to swell from effusion into its texture, and into the copious cellular

[* We have several times performed this operation with success, at Wills' Hospital, by the method recommended at p. 660–61, and have not found any great difficulty in accomplishing it. In one patient, a girl of 12 years of age, who had had congenital cataract, we extracted an opaque capsule from each eye. Not the slightest inflammation followed.]

† This seems to be the case with ophthalmic inflammation generally. Of one hundred and thirty-four cases commencing in one eye, ninety-five began in the right, thirty-nine in the left. Mr. Macgregor observes of purulent ophthalmia, "It is found that the right eye is more frequently affected than the left. It is also in general more severely affected, and the sight of it is more frequently lost." Transactions of a Society for the improvement of Medical and Surgical Knowledge, vol. iii. p. 55.

tissue, which connects it to the sclerotica. It is raised above the level of the cornea, forming a broad firm ring on the front of the eye; it rises higher and higher, often overlapping the edge of the cornea, so as to hide a part of it. This bright scarlet, broad, and elevated ring of conjunctiva projecting beyond, and surrounding the cornea, is acutely sensible; it is technically called *chemosis*, and in the affection which I am now describing, it may be termed *true inflammatory chemosis*. The distension of the conjunctiva is limited in front by its adhesion to the corneal laminæ, behind by the pressure of the surrounding parts; hence its form of a broad ring on the front of the eye, where the swelling of the membrane is not effectively opposed by the lids. The appearance depends on an interstitial effusion of lymph or fibrine from the vessels of the inflamed membrane under high excitement analogous to that which takes place in other acute inflammations; the swelling, therefore, is firm.

The tumid state of the conjunctiva is not owing to the effusion of blood into the cellular texture, as Scarpa* very unaccountably supposes, confounding the inflammatory symptom called chemosis with ecchymosis. He has, upon this erroneous supposition, proposed the making of incisions through the tumefaction to allow the escape of effused blood. There is in some treatises a distinct chapter upon chemosis, as if it were a particular disease of the eye; it is, however, merely an effect of acute inflammation affecting the conjunctiva, and its characteristic form is derived from the loose sclerotic and firm corneal adhesions of the membrane. In the present case, the tumefaction is caused by the interstitial effusion of fibrine, and is firm: when inflammation of the conjunctiva is less active, the effusion is serous and the swelling less firm.

The access of light is offensive to the patient in general inflammation of the globe; the pupil contracts to exclude it, and the palpebræ are spasmodically closed. The motions of the eye and lids are interrupted or prevented; the whole external surface becomes exquisitely sensible, and as the slightest attempt at exertion occasions great pain, the patient keeps the eye as much as possible at rest. The surface of the organ, at the commencement of the affection, is rather stiff and dry; but this dryness goes off, and is succeeded by increased flow of tears, especially if the eye is exposed to light or any external irritation. A little mucous discharge may be seen about the edges of the lids and the eyelashes.

Such are the circumstances which characterize inflammation of the whole globe in its first stage; as it proceeds to the second period, we begin to see various alterations of structure. The iris becomes changed in color, loses its brilliancy, and no longer exhibits its usual motions. The pupil contracts, and loses its clear black color. The cornea becomes more or less opaque, and vision is lost. The alteration in the cornea, and in the state of the pupil, would account for imperfection or loss of sight; but, as the latter often occurs while the cornea is sufficiently clear for the transmission of light, and the pupil is still open, it must be explained by inflammatory disturbance and consequent change of structure in the retina. The patient still sees, or fancies that he sees, luminous sparks and flashes of fire before his eyes, when there is no light in the chamber, or during the night, in consequence of the disturbed state of the retinal circulation.

As the inflammation continues, the globe swells, and the sense of its being too large for the bony cavity in which it is contained is not erroneous. We cannot say positively that all the internal tunics of the eye

* Treatise, translated by Briggs, 2d ed., pp. 145 and 148. Trattato delle principali Malattie, &c., Ed. 5. v. i. pp. 191 and 193.

are in a state of inflammation, because we cannot see them; but when we find that the globe is actually increased in size, that the iris is changed in structure, and that the retina has lost its sensibility, there is little reason to doubt that the internal parts of the eye generally are inflamed. The congestion within distends the globe, and causes the sense of bursting.

The internal swelling, joined to the chemotic tumefaction, occasions the globe to fill up the front of the orbit, protruding the lids, everting the inferior, and appearing externally as a red fleshy mass. Motion, which is impaired in the early stage, is now quite lost, for the swelled globe is fixed, and the upper lid is so protruded and swoln as not to be movable by the patient's will.

The eyelids swell from the beginning. They are at first red on the edges. The conjunctiva palpebralis becomes inflamed like that of the globe, hence the internal surface of the lids is intensely red. The integuments become red, and effusion occurs into the cellular texture of the lids generally, effacing the fold of the upper, and raising it into a convex protuberance.

In a local disease of such violence, affecting a very vascular, nervous, and highly sensible organ, situated in the immediate vicinity of the sensorium, marked constitutional sympathy may be expected; accordingly we find inflammatory fever of a decided character from the commencement of the affection. General indisposition is felt at the very outset. The appearance of the local symptoms is preceded by a longer or shorter attack of shivering, followed by general heat of skin, thirst, pain of the head, and lassitude. When the complaint is developed, there is a quick, hard, and full pulse, dry and hot skin; a white and rather dry state of the tongue, deficiency of appetite, severe headache, restlessness, and generally want of sleep at night. The face is flushed, and perhaps swelled on the affected side, with a sensation of throbbing in the neighborhood of the eye.

Effects.—If the disorder is not checked, the local pain, and the feverish state of the constitution proceed to a great height. Under such an aggravation of the local and general symptoms, the pain changes in character, it becomes throbbing, rigors are felt, and suppuration of the globe takes place; the cornea turns of a dull white and then yellow, and the globe is ultimately converted into an abscess. The occurrence of suppuration does not produce the relief usually experienced from that change, in consequence of the firm, unyielding nature of the sclerotica and cornea; the pain, together with the sense of bursting and throbbing, continues for some days, until the cornea bursts externally, and gives an exit to the matter contained in the interior of the eye. The patient then experiences relief; matter is discharged for a time; the tunics of the eye collapse into a small space, shrink into the orbit, and the original form of the organ is lost. The vitreous and crystalline humors of the eye generally escape when the bursting of the globe first gives an exit to the confined matter.

Such is the termination of this affection in its worst form; when it does not proceed so far, and when its progress has been checked by treatment, the cornea becomes opaque, and remains so; the pupil is either closed or very much contracted, and the aperture filled by a newly-formed adventitious substance, the consequence of effusion into the opening during the inflammatory stage, and the subsequent organization of the effused matter. In this case vision is either impaired or completely lost, but the form of the eye remains. The most favorable termination that can be expected is the recovery of the organ, with the cornea clear and the pupil open; still, in this case, the retina has generally suffered so much as to produce greater or less imperfection of vision.

Diagnosis.—The affection which I have now described may be considered as common, true, or proper inflammation, seated in the whole eyeball; for the circumstances which I have enumerated sufficiently prove that all the component parts are inflamed. It is characterized by commencing at one and the same time in the external and internal tunics of the eye. Internal inflammation may spread to the external coats, or external inflammation may extend inwards: but, in this affection, both sets of parts are inflamed at the same time.

This *common*, or *idiopathic* inflammation, is distinguished from the *specific*, or *sympathetic* inflammations by the following circumstances:—1st. The principal symptoms, that is, redness, pain, swelling, intolerance of light, and lachrymal discharge, are equally developed, and present a correspondence in degree. In the specific inflammations one symptom is commonly predominant over the rest. Intense external redness is often seen in catarrhal ophthalmia without pain or intolerance of light; in scrofulous cases, the highest intolerance, with hot and acrid lachrymation and spasm of the palpebral muscles, with hardly perceptible redness; in the arthritic and syphilitic, severe pain in the eye and its neighborhood, with the other phenomena in a slight degree. In the forms just enumerated the swelling is inconsiderable in comparison to the particular symptoms now pointed out; but it is excessive in the purulent and gonorrhœal ophthalmiæ. 2dly. The symptoms commence at the same time, and in an equal degree, and continuing in this equal proportion to each other throughout. Each symptom also exhibits this uniformity in degree and extension. The redness occupies equally the whole surface of the organ. In catarrhal and strumous cases it is partial, consisting in distension of some fasciculi of vessels, or confined to some part of the organ. In syphilitic, rheumatic, and arthritic ophthalmiæ, the redness is in the sclerotic coat, and usually forms a zone round the cornea. The pain in ophthalmitis occupies the whole globe and orbital region, and thence extends equally to all the surrounding parts. In other ophthalmiæ it is often less in the eye itself than in the parts round the orbit. 3dly. The course of the complaint is very regular, proceeding, when it has once begun, without intermission or remission, to its full development, unless it should be interrupted by active treatment. In the other ophthalmiæ, the complaint altogether, or particular symptoms, often undergo increase or diminution; in some, remissions, and in others complete intermissions are observed. In catarrhal cases the patient is often free from suffering during the day, the symptoms return in the evening, and are again less severe in the morning. The symptoms of syphilitic ophthalmia undergo a marked diminution during the day, and show themselves again in severe nocturnal paroxysms. Scrofulous patients, on the contrary, suffer in the day, and are greatly relieved towards evening. In these cases, too, recoveries and relapses often occur suddenly, and succeed each other frequently. 4thly. True ophthalmitis is attended with considerable constitutional disturbance of inflammatory character, while the sympathetic ophthalmiæ are generally without fever, even in many instances where the inflammation runs high.

Treatment.—The active inflammatory character of both the local and general symptoms demands the most energetic antiphlogistic measures; and if, by their timely employment, we should succeed in checking the vascular disturbance, the subsequent administration of mercury may prevent injurious changes of structure, and thus enable us to restore or preserve sight. If, however, the pupil should have become closed by an adventitious membrane, vision is extinguished without hope of recovery; while, if the globe should have suppurated, its very form is destroyed.

When general suppuration of the globe has occurred, in consequence of acute ophthalmitis, and we see the anterior chamber full of matter, the evacuation of it by a free opening of the cornea will put a stop to the patient's sufferings, which would be protracted if we left the matter to make its own way through the firm textures of the sclerotica and cornea. As the eye must inevitably be lost, we need not be deterred from adopting this course, by the injury to the form of the organ which it involves.

Ophthalmitis arthritica.—This name is given by some writers to the disease described in Chapter XIX. § 3, as *arthritic inflammation of the internal tunics.* The disease commences in the latter, and is for some time confined to them in milder cases; in its more acute form, the external coverings are either affected from the beginning, or soon become involved in the inflammation.

SECTION II.—INFLAMMATION AND DESTRUCTIVE SUPPURATION OF THE EYE, OCCURRING AS A SECONDARY EFFECT OF PHLEBITIS.

Mr. Arnott has pointed out the connection between this affection of the eye and phlebitis, in his comprehensive and valuable *Pathological inquiry into the secondary effects of inflammation of the veins*, published in the fifteenth volume of the *Medico-Chirurgical Transactions.*

In a patient, who had undergone the operation of cutting out a portion of varicose vein in the right leg, inflammation of the posterior saphena ensued, and the case terminated fatally on the ninth day. It had been observed, the day before, that the eyes were kept constantly closed; the conjunctiva was found red, and the cornea opaque on both sides. The following circumstances were noticed on examination of the body: the vein partly plugged with lymph, partly filled with pus; fluid pus in several muscular branches. Deep-seated abscesses under the fascia of the left forearm and leg, and sero-purulent effusion between the muscles of the right forearm. A recently formed abscess in the upper lobe of the right lung. Serous infiltration of the pia mater, particularly towards the basis of the brain. Effusion of lymph round the trunks of the carotid arteries. The nerve of the third pair on the left side flattened, and softer than that of the right; a similar change, to a greater extent, in the fifth nerve of the right side. "It has been remarked, that during life great opacity of both corneæ had taken place; the surface of which had become rough. On removing the right eye, destructive changes were found to have taken place within the globe; the crystalline was so soft as to yield to the slightest touch; the vitreous humor was of a reddish yellow color, and red vessels could be distinctly seen traversing its membrane. The retina was of a deep red color." (*London Medical Gazette*, vol. ii., p. 284—286.)

The following case is related by Mr. Arnott:—"A young man had a ligature placed on the left carotid artery, for an aneurismal disease of one of its temporal branches. Considerable difficulty was experienced in passing the needle round the vessel. Venous hemorrhage took place during the operation, recurred at night, and occasionally afterwards for nine days. On the fifth day after the operation, the patient had a severe rigor, succeeded by heat of skin and general febrile symptoms. These increased, the pulse rose to one hundred and twenty, and the constitutional disturbance assumed a very violent character. About the tenth day, the vision of the left eye became impaired, and was quickly lost; the pupil was contracted, the iris immovable, and the cornea had a somewhat hazy appearance; effusion took place under the conjunctiva, and the eyelids

were greatly swoln, giving the appearance of the globe being much protruded; at the same time there was a degree of deafness, considerable stupor, with occasional slight delirium. In the course of a few days the coats of the eye sloughed at the upper part, and its contents were evacuated. Whilst these changes were occurring in the eye, collections of matter formed, without pain, in different parts of the body, in both shoulders above the insertion of the deltoid muscles, over the sacrum, &c. The constitutional disturbance abated, the collapsed eye healed over, but he never recovered his health. Five months subsequently he died, laboring under lumbar abscess, and worn out by hectic. On examination of the body, a portion of the jugular vein, to the extent of two inches, was found wanting; the upper and under extremities being shrunk, ligamentous, and gradually lost in the cellular substance. On opening the head, pus was found effused in great quantity between the tunica arachnoidea and pia mater, along the base of the brain, and the whole length of the spinal cord. The intermuscular cellular substance of the loins was loaded with pus. The viscera of the abdomen and chest were not examined." (*Med. Chir. Trans.*, vol. xv., pp. 118—120.)

When this narrative is compared with the circumstances of the case previously quoted, we shall have no difficulty in concurring with the conclusion suggested by Mr. Arnott, that the affection of the eye, in this instance, was a secondary effect of inflammation in the vein.

In a case of puerperal ophthalmitis seen by Mr. Mackenzie, the affection of the eye was ushered in by rigors, followed by fever and feelings of sinking, with quick irritated pulse. The conjunctiva was much chemosed, the lids swoln, and the lower everted. "There was severe pain in the eye and head, and excessive intolerance of light; so much so that she was obliged to keep her face covered with a handkerchief, although the window shutters were constantly closed. At first, tears ran from the eye, but, after a time, purulent mater. The cornea became opaque, but the eye did not burst." The patient died, but an examination was not allowed. (*Practical Treatise*, ed. 3, p. 511.)

Dr. Graves saw severe inflammation of one eye in a case of phlegmasia dolens consequent on parturition. The patient had also bronchitis, with great disturbance of the stomach and intestinal canal. On awaking one morning, she experienced intense pain in the eyeball, and complete blindness, so that she could not distinguish light from darkness. The cornea was almost concealed by immense nearly white serous chemosis, so exquisitely tender that touching the lids could not be borne: the cornea was opaque, as far as it could be seen. This case ended fatally. The popliteal, femoral, iliac veins, and the inferior vena cava, as high as the junction of the renal veins, were thickened and lined with fibrine. On examining the eye the iris was found changed in color, and covered, on both surfaces, with long flakes of lymph. Portions of lymph were floating in a turbid aqueous humor. The lens was light brownish and opaque; the vitreous humor, dull yellow, thick, and ropy. (*Ibid., from London Med. and Surg. Journ.*, vol. iii., p. 360.)

In another case, observed by Mr. Mackenzie, phlegmonous erysipelas of the upper extremity was induced by whitlow. Rheumatic pain supervened, after which the erysipelas subsided. Now dimness of sight came on without pain. The irides were inflamed, the pupils contracted and hazy: in three or four days from the commencement, deposition of lymph was observed in the bottom of each anterior chamber. Protrusion of the eye, and great chemosis occurred successively in both eyes, both of which remained completely amaurotic. (*Ibid.*, p. 512.)

Death ensued in another case after the successive occurrence of scarlatina, phlegmasia dolens, typhus, and ophthalmitis. Protrusion of the eyes had occurred, and purulent matter had been seen in the anterior chambers the day before death. The adipose and cellular texture of the orbit were indurated and infiltrated with serum; the cornea transparent; the sclerotica reddish and thickened; the aqueous humor reddish, and containing flaky matter. The pigment of the iris and choroid deficient, and some portions of lymph effused in the latter. Reddish fluid, with whitish puriform flakes effused between the choroid and retina. The latter and the hyaloid membrane closely adherent, and forming a whitish thickened mass, inclosing a small quantity of reddish fluid, the remains of the vitreous humor. (*Ibid.*, p. 513.)

The inflammation of the eyes in the cases now under consideration, which has received from Mr. Mackenzie the appropriate name of *phlebitic ophthalmitis*, is analogous in its nature to the other secondary inflammations consequent on phlebitis. It leads to similar effusions of pus and lymph; and, as these occur in the important internal parts of the eye, for example, the chambers of the aqueous humor, the iris. choroid, retina and vitreous humor, serious disorganization is quickly effected. The prognosis is most unfavorable. The cases generally terminate fatally from causes independent of the ocular affection; if this should not happen, complete amaurosis results.

The *treatment* would consist of antiphlogistic means, mercury, and counter-irritation, employed in such manner and extent, and with such combinations as the local symptoms and the general state of power might indicate.

[In the twenty-eighth volume of the *Medico-Chirurgical Transactions*, Dr. Robert Lee, in an instructive paper "on the ophthalmia of puerperal women," has given a brief history of the literature of this disease, and notices three cases which occurred in his practice.

A very interesting case of destructive inflammation of the eye after phlebitis consequent on inflammation, is related by W. Bowman, Esq., in the *London Med. Gaz.*, Oct. 1846.

The subject of it was a young man whose leg had been amputated on account of disease of the ankle and tarsus. The patient had a shivering fit on the fifth day from the amputation, followed by decisive symptoms of inflammation of the veins of the stump, advancing even above the groin. He was already in a state of high irritative fever, with a sallow and exhausted countenance; and on the fifth he was attacked with diarrhœa, which required starch and opiate enemata, with small doses of gray powder and Dover's powder. This symptom soon ceased, but bed-sores were appearing, and he had repeated rigors, with parched tongue, very rapid pulse, a hot skin, and an anxious and sunken look, which indicated serious internal disease. The stump itself was meanwhile assuming a more healthy action, and the ligatures had separated; yet there was some projection of the bone in spite of our efforts to prevent it.

On the morning of the sixth he complained of his left eye smarting and aching, and it appeared to be affected with slight catarrhal ophthalmia. There was superficial redness, with mucous discharge. Alum lotion was applied.

On the following day the inflammation had increased with frightful rapidity; there was excessive florid chemosis, partly concealing the cornea; the lids were turgid, and the eye wanted none of the characters of a severe attack of purulent ophthalmia, except the purulent discharge. The pain in the globe was of an aching, darting kind. The cornea re-

mained clear, but the aqueous humor and iris were muddy, and sight was totally lost. The chemosed membrane was scarified, and four leeches were applied, which had the effect of speedily reducing the scarlet color of the conjunctiva to a pale yellowish-pink tint, and the chemosis became of that sort which is known as "serous." This speedy change was accelerated by his weakened state, and showed that active depletion was inadmissible. Fomentations were then applied. The general treatment was continued, with an opiate at bed-time.

On the 8th dull pain in the eye continued, and the chemosis had increased and projected between the lids, but was pale and serous. The cornea had become cloudy, the chambers were yellowish, the iris obscured by lymph, the pupil occupied by a yellow mass of lymph, which looked like an opaque lens. The lids had become less œdematous, so that the condition of the interior of the organ could be more exactly noted. Meanwhile the local symptoms of phlebitis in the stump were on the decline, and the stump assumed a more healthy aspect, the bones still protruding slightly. But the rigors now recurred daily, with considerable regularity, attended with much exhaustion; and about the 15th he was seized with pleurisy of the right side, for which he was blistered, and took a grain of calomel with opium every four hours for two days. At the end of this period the pain in the side had nearly subsided, and (what is interesting) the lymph was absorbed from the iris and the pupil, which resumed very nearly their natural appearance, the latter only remaining rather turbid. He had lost almost all pain in the organ, and the morbid action within it seemed entirely checked. Some pale chemosis remained, but the cornea was clear and the globe wore no appearance of internal suppuration. All pain in the organ had likewise ceased.

On the 20th he died, after an aggravation of the symptoms betokening internal phlebitic abscesses.

Mr. Bowman examined the eye before twenty-four hours had elapsed, and had appointed an hour for the inspection of the rest of the body; but this was unfortunately prevented by the interference of the friends.

The following is the result of a careful and deliberate examination of the eye itself.

"The *iris*, seen through the transparent cornea, was clear green, without lymph on its surface, but firmly adherent by its entire posterior surface to the capsule of the lens, which presented only a partial opacity near its centre. This posterior synechia and opacity of the capsule appeared of old standing (and the patient had stated that this eye had been a poor one, and vision imperfect with it for many years).

"The *lens* itself was *perfectly transparent*.

"Under one of the recti, immediately behind its insertion, the sclerotic (and also the choroid) was much bulged, and so distended as to be almost giving way, evidently by pressure from within. It formed what would have been termed, from its shape and circumscribed figure, a staphyloma scleroticæ. In order to ascertain its nature, I carefully cut all round it through the sclerotica only, and in detaching this coat I found that it was extremely thin, and its fibres as it were unraveled, at the apex, where also the choroid was adherent to it by a film of recent lymph, and, like the sclerotica, distended from within. The outer surface of the choroid was perfectly natural, except at the apex of the swelling. On now cutting through the choroid, a whey-like fluid, with particles of lymph floating in it, escaped in abundance; and I found that this effused fluid was filled with nucleated and other irregular granules, hanging together in little masses, and resembling lymph rather than pus. In this turbid fluid there

lay loosely a great number of smooth, round, or oval beads of soft yellow lymph, of every size up to that of a rape-seed, and these consisted of an agglomeration of nucleated lymph-particles, with many shapeless granules in the connecting material. Scarcely any fibres could be discovered. I emptied the cavity between the choroid and retina, in which this effusion had collected, by syringing it under water, and the inner surface of the choroid then exhibited a coating of yellow lymph, which appeared to be deposited not merely on the surface, but also in the interstices of the capillary network which lies under the epithelium forming that surface,—almost all trace of this epithelium (the "membrane of the black pigment" of Mr. Wharton Jones) being lost. The vitreous humor, in its enveloping hyaloid membrane, together with the broken remains of the retina, had been thrown by the effusion to the central part of the globe, where they occupied only about half their natural space. The retina was not at all coated with lymph, and its capillary network was perfect, but the nervous substance was in a great measure destroyed, as though macerated; yet what remained exhibited the characteristic elements of the nervous substance of that part. In particular, I discovered several well-marked examples of the caudate nerve-vesicles, which I had never before unequivocally seen in that membrane, although strongly suspecting their existence. Jacob's membrane was nowhere visible.

"The hyaloid capsule (that homogeneous glassy membrane which forms the outer covering of the vitreous humor, and in the adult eye shuts it off, as the capsule does the lens, from the capillary blood-vessels of surrounding parts, and constitutes it a non-vascular texture)—the hyaloid texture was everywhere entire, but thrown into innumerable minute folds, in consequence of its collapsed form. A good many lymph-globules were accumulated on its exterior in certain parts, and the nuclei naturally present on its inner surface were very distinctly visible. But what I wish specially to notice was the state of the vitreous humor itself. This highly delicate structure, from its transparency and exquisite texture, displayed with remarkable clearness the morbid changes that had been taking place within it. In a state of health the vitreous body presents no corpuscles, and only in certain parts can even that fibrous web which forms its basis be accurately seen. Such parts are specially the neighborhood of the ciliary processes, and the border and posterior surface of the lens; where this tissue is strong, and is implanted in the capsule of the lens to aid in maintaining it in position. Now every part of the vitreous humor was here turbid and cloudy, from a finely granular and amorphous deposit in its fibrous meshes. This deposit might be supposed to be a simple coagulation of albuminous matter; no trace of organization could be detected in it. But, in addition to this, there were disseminated through the vitreous humor innumerable nucleated cells, like those of the lymph already described. These nucleated particles were much more numerous immediately within the hyaloid capsule, in the superficial portions of the vitreous humor, than towards its centre, where they very gradually ceased. They were all distinct from one another, placed apart in the vitreous tissue, and had everywhere the same appearance and size. Mingled with them, however, were several smaller, more granular, and irregular particles, which might be in process of development. I could perceive no appearance indicating a multiplication of the particles by splitting or division. In the central part of the vitreous humor there were none of the nucleated particles, but in the neighborhood of the optic foramen and yellow spot, and particularly within the ciliary processes of the vitreous (or the zone of Zinn), at the border of the lens, and near

its posterior surface, they were so abundant as to render the vitreous humor perfectly opaque and yellow: yet even here they only differed in number from those found elsewhere."]

SECTION III.—SYMPATHETIC OPHTHALMIA.

The intimate connection between the two eyes, *consensus oculorum*, as it has been commonly called, is so frequently manifested in disease, under circumstances of ordinary occurrence, that it is hardly necessary to mention, and certainly not to enlarge upon the subject. Whenever disease shows itself in one eye, there is great probability that it will occur in the other also, especially if the causes or circumstances, under which the first affection appeared, are continued. And there is sometimes a curiously exact coincidence in nature between the diseases of the two eyes.

The sound eye does not suffer invariably under such circumstances. There are many instances in which, after one eye has been lost, the other, although used unsparingly, retains its powers unimpaired through life. Beer makes the following statement: "I know many persons, who have lost one eye from the most painful affections, in which the whole head and the other eye suffered greatly at the time; yet they see most perfectly, even after ten, twelve, and fifteen years. A miniature painter in this city, in advanced age, paints the smallest miniatures with the greatest excellence, though he lost the left eye by painful inflammation and suppuration seventeen years ago. Yet it is true, more particularly in cataract and amaurosis, that both eyes generally either suffer at once, or within a short time of each other." (*Repertorium*, vol. i. p. 29.)

The intermixture and partial decussation of the fibres of the two optic nerves may probably account for the sympathy between the eyes. There is no such connection between the ears, the nerves of which are completely distinct in their whole course.

Penetrating wounds of the globe, unless judiciously managed from the very beginning, are generally followed by internal inflammation, which destroys sight, and not unfrequently ends in atrophy of the organ. Often the sound eye is attacked by similar internal inflammation, which affects the iris, lens, retina, and vitreous humor, and thus may be arranged among the general diseases of the globe.

This sympathetic ophthalmia may come on during the active period of the original disorder, or after its cessation. The former is likely to occur if the injured eye be neglected, and especially if employment and exertion of the sound organ be continued. The constitution, state of health, and habits of living, will also influence the result. The sympathetic disorder generally comes on slowly, and with symptoms at first not strongly marked; but it may be more acute. It is characterized, when fully developed, by redness of the sclerotica, change of color in the iris, contraction and adhesion of the pupil, cataract, diminution or loss of sensibility in the retina. Atrophy of the globe is often the ultimate result.

I have already alluded to this subject, and mentioned some cases in illustration, in Chapter III., at p. 187—189, where I have also pointed out the protective precautions in respect to the sound eye, which ought to be observed for a considerable time in all the serious injuries, that might otherwise lead to such lamentable results. Our efforts should be directed to prevention of this sympathetic affection, which, when it has once occurred, generally proceeds to the destruction of sight. Its serious consequences are sufficiently evidenced in the cases which I have already shortly men-

tioned in Chapter III. Mr. MACKENZIE, who has seen and recorded several instances, gives the following discouraging view of the subject: "The prognosis is so unfavorable, that it is our duty to guard the patient who has suffered any severe injury of one eye, against the exciting causes of sympathetic ophthalmia, from the very first. When this disease is actually present, even the most active treatment is generally ineffectual. Indeed, I have never seen an eye recover from sympathetic ophthalmia. Renewed attacks have generally terminated in extinguishing vision." (*Practical Treatise*, p. 533.)

The only probable chance of saving the second eye is to make a free incision in the coats of that which has been injured, so that they may collapse, and the eye consequently shrink in the orbit. Where one eye had been lost by disease, and the other had suffered from sympathetic irritation so much as to induce apprehension that more serious mischief might ensue, I have had recourse to this proceeding in two or three instances with the best effect. Mr. BARTON, of Manchester, opened the cornea largely, and excised a part of it where portions of percussion caps had penetrated and remained in the eye. (See *ante*, p. 71—72.) This operation was not only completely successful in its immediate object of removing the foreign substance, and thus arresting the inflammation, under which the wounded eye labored; but, by causing collapse of the globe, it effectually relieved the sound eye from the sympathetic affection, which was always serious, and had been in one instance fatal to vision.

[Instances of restoration of vision after an attack of sympathetic ophthalmia are so extremely rare, as to fully justify the very unfavorable prognosis given by Mr. MACKENZIE. Still, like all other rules, it has its exceptions, and the following case, successfully treated by Mr. WALKER, of Manchester, is of this character. This case is unusually interesting from this circumstance, and we shall therefore give it with all its details as reported in the *Provincial Medical and Surgical Journal*, for May 28th, 1842.

Mary Brown, ætat. 6, in Feb. 1839, received a severe lacerated wound of the right eye from a piece of slate, which had been thrown with considerable force from a short distance. She was brought to the Manchester Eye Hospital in a day or two after the receipt of the injury, when, on examination, a wound was discovered extending across the centre of the cornea and part of the sclerotica at the external canthus. The pupil was obscured by an effusion of blood into the anterior chamber. She complained of much pain in the eye, and vision was entirely lost. The eyelids were approximated and kept together with strips of adhesive plaster, and the usual precautionary treatment was advised. The wound healed and the eye had got into a tolerably quiet state at the end of about six weeks, but vision was destroyed and the organ rendered atrophic.

It was not until six months had elapsed that the patient began to complain of the *left* eye. Symptoms of inflammatory action were then developed: these, however, were never of an intense character, but the pink zone, the discoloration of the iris, the fixed and contracted state of the pupil, and the gradually extending opacity of the capsule of the lens, ultimately terminated in an almost total loss of vision, notwithstanding the prompt employment of the usual remedies, especially leeches, mercurials, belladonna, and counter-irritation. She had occasional relapses of inflammatory action, so that it was not until the spring of the year 1841, and two years from the receipt of the injury, that it seemed proper to propose an operation.

July 17, 1841. At this period she had been free from inflammatory attacks for several months. The sclerotica and cornea had both a healthy aspect, and the anterior chamber was of undiminished size, but the condition of the iris, and that of the pupil and capsule of the lens, remained as before described. She had a very small amount of vision, being only able to discern a lighted candle or some luminous or brilliantly colored object. As there appeared reason to hope that the retina retained a certain degree of sensibility, it was deemed advisable to give her the chances of an operation.

A puncture was accordingly made by Mr. Walker at the inferior margin of the cornea with an extraction knife, the point of the instrument being carried into the pupil so as to perforate the capsule and facilitate the exit of the crystalline lens. The scoop was next introduced through the wound into the pupil, and the opaque body, which was simply the thickened capsule (the lens having been evidently previously absorbed), was readily removed. The eyelids were then closed, and kept in apposition by means of the plaster dressings. A slight attack of inflammation succeeded, and was several weeks before it entirely subsided, when the pupil, which was drawn somewhat down towards the wounded part of the cornea, was found closed by either a portion of capsule which remained, or, more probably, by an adventitious membrane, the product of the inflammatory action. No improvement to vision had hitherto resulted.

Nov. 6. All irritation from the previous operation having long since subsided, it was agreed to proceed to the formation of an artificial pupil. The alarm and unsteadiness of the girl seemed to forbid the attempt at removing a portion of iris by excision. Accordingly, the iris knife was passed through the sclerotica, and, having perforated the iris, appeared in the anterior chamber; the instrument was then made to cut through the opaque membrane and adjoining portion of the iris, leaving a tolerably clear, though somewhat irregular pupil. The eye was then dressed in the usual manner.

9. The dressings having been removed, the lower portion of the eyeball, near the site of the puncture, was observed to be very vascular; the opaque membrane was no longer visible; the pupil appeared of moderate size, of an oval shape, and situated near the centre of the iris, but was evidently occupied by some effused matter. She had a very strong sense of light, and could observe the black marks on some writing paper held before her. There had been no pain in the eye since the first day after the operation. The dressings were reapplied, and a purgative ordered to be taken occasionally.

13. Had gone on favorably since last report; there was less vascularity, and no uneasiness about the eye; the pupil looked somewhat clearer, but was still occupied by effused matter, which had probably become organized; vision had not improved; the same treatment was continued.

After this time the inflammatory action soon subsided, and it became evident that some further operative proceedings would be required before any useful vision could be expected. It was thought advisable, however, to give time to enable the eye to recover itself, and accordingly another operation was deferred until the following spring.

April 9, 1842. There had been no undue amount of vascularity about the eye for some time past. The general appearance of the organ continued favorable, there being no opacity of the cornea, except at its lower margin, the site of the former incision; the sclerotica still maintained a healthy aspect, and the iris had not undergone any material change, the

pupil being still obliterated or occupied by some effused and organized matter.

This day the cornea was punctured at the lower margin with an extraction knife, and a small iris hook introduced through the wound into the centre of the iris and former situation of the pupil. A portion of iris was then endeavored to be drawn out by means of the hook, but its texture, or perhaps rather that of the organized deposit, was so fragile, that it tore through, leaving, however, an aperture of ample size and nearly in the usual situation of the pupil. She was able immediately to discern the persons of those around. The eyelids were then secured with strips of plaster in the usual manner.

12. On the removal of the dressings, but little increased vascularity was observable; the incision had apparently healed; the pupil remained open, of an oval form, and of about the medium size. She could readily discern objects around. The dressings were renewed, and the usual treatment recommended.

16. Proceeding very favorably. She had suffered no pain in the eye, and the vascularity was trifling. The pupil continued open and of undiminished size, a small portion of opaque matter occupied its lower margin. Vision remained fully as good as before.

May 7. The eye had now completely recovered from the operation. The pupil remained open, of good size, and situated nearly in the centre of the iris. She was supplied with a powerful convex lens, which increased her powers of vision very materially, and was discharged well satisfied with the result and in excellent spirits.]

Mr. Wardrop has described an internal inflammation incidental to the horse's eye, in which vision is lost by opacity of the lens and capsule, and other changes of structure. It affects the two eyes successively. He says, "It occurred to me that if the eye first affected were to be altogether destroyed, the progress of disease in the other would be arrested, and one eye thus preserved. An opportunity of making the experiment soon occurred. A valuable race-horse had one eye considerably injured from repeated attacks of this disease, and the other eye, during one of these, appeared tender. I made an incision through the cornea of the bad eye with a sharp-pointed bistoury, through which the aqueous humor escaped. The lens was then squeezed out, and along with it the whole vitreous humor, which seemed in a healthy state. A poultice was applied over the eyelids, the eye suppurated, and ultimately completely sunk. The other eye resumed its natural lustre and transparency, and I heard of this horse upwards of six years afterwards, when he was a very valuable hunter; the eye having remained perfectly well. Since making this experiment I found that there was nothing new in the observations I had made; for many conversant with horses were aware, that if one eye be so severely affected that it is quite destroyed, they consider that there is a great chance of the other remaining sound. I have even heard some farriers remark, that if the bad eye happen to meet with an accident, and the injury hasten its destruction, the other will be saved; and further, that aware of this, some have even ventured to adopt the practice of destroying the diseased eye, which they have rudely done by putting quick lime between the eyelids, or by thrusting a nail into the eyeball, so as to excite violent inflammation, suppuration, and destruction of the organ." The operation consists in making an opening in the cornea, at its circumference, sufficiently ample to allow of the lens and vitreous humor being evacuated.*

* Essay on the Diseases of the Eye of the Horse, and their Treatment; in the Communications to the Board of Agriculture; vol. i. new series.

SECTION IV.—HYDROPHTHALMIA.

The globe of the eye may be enlarged, partially or generally, by increase in the quantity of the humors, or by effusion of an aqueous fluid. The affection is called *dropsy of the eye, hydrops oculi; hydrophthalmia, hydrophthalmus.* Systematic writers have divided it into three kinds:—1st. *Dropsy of the cavities containing the aqueous humor; hydrops cameræ anterioris;* 2d. *Dropsy of the vitreous humor; hydrops corporis vitrei;* 3d. *General dropsy of the eyeball; hydrophthalmia*, properly so called; *hydrops oculi mixtus; buphthalmus* (ox eye, from βους, ox, and οφθαλμος, eye, to denote the enlargement of the organ).

The name of dropsy, which has been applied to this state of the eye, from the mere circumstance of the globe containing a collection of watery fluid, has misled some writers into the supposition, that the causes and nature of the disease are like those of other dropsies, that it owes its origin to a morbid state of constitution, and requires the use of anti-hydropic remedies. "Dropsy," says Beer, "arises in the eye, as it does in any other part of the body, from a disproportion between the processes of secretion and absorption. Hydrophthalmia seldom exists as a local disease; it is at least always connected with a more or less obvious cachectic state of body; or it is symptomatic of a previously existing dropsy, for example, of anasarca, of external or internal hydrocephalus, of dropsy in the cerebral ventricles. Sometimes it appears in chlorotic girls as a symptom of that cachexia." (*Lehre*, vol. ii. p. 616.) In his further remarks on the particular species of the complaint, he enumerates, among their causes, the sudden healing of cutaneous eruptions, particularly tinea capitis and itch, and the unhealthy states of constitution produced by scrofula, syphilis, and scurvy. In the same way Juengken regards it as resulting from morbid states of constitution, such as the scrofulous, rheumatic, and gouty, from severe colds, from serious abdominal disturbances, particularly those connected with menstruation in women; from disorders of the abdominal viscera, hemorrhoids, the healing of ulcers of the legs, and the suppression of perspiration in the feet, in men. He also considers that it may happen from metastasis. (*Lehre von den Augenkrankheiten*, p. 540, 541.) The facts which have come under my observation, have not afforded the slightest support to these pathological views, nor to the measures of treatment founded on them.

Dropsy of the cavity containing the aqueous humor, is considered in Chapter XV. § 6.

Dropsy of the vitreous humor.—I know no external signs, by which it can be determined whether enlargement of the globe, at its posterior part, is caused by an effusion of watery fluid, or by increase of the vitreous humor. In an example of the latter kind, which came under my observation. I did not discover the nature of the case, until I had made a puncture behind the cornea, for the purpose of lessening the size of the globe.

In all the other instances of hydrophthalmia which I have seen, the globe has been distended with aqueous fluid; my experience, therefore, would coincide with that of Scarpa, as expressed in the following passage. "The generality of surgeons teach, that the immediate cause of the dropsy of the eye is sometimes the increase of the vitreous, at other times of the aqueous humor. In all the cases of dropsy of the eye, which I have operated upon, or have examined in the dead body, in different stages of the disease, I have constantly found the vitreous humor, accordingly as the disease was inveterate or recent, more or less disorganized and in a state of disso-

lution; nor have I been able in any instance to distinguish, on account of the increased quantity, which of these two humors, vitreous or aqueous, had had the greater share in the formation of the disease." (*Treatise, &c.*, p. 418.)

General hydrophthalmia.—Dropsical enlargement of the globe generally, to which the terms *hydrophthalmia* and *hydrops oculi* would be properly applicable, results from changes of structure caused by serious and long-continued inflammation, such as the strumous, variolous and purulent. The cornea is partially or generally opaque; the external tunics are distended and rendered thinner; the front of the enlarged globe, which sometimes protrudes between the lids, is often irregularly protuberant. The interior is usually filled with aqueous fluid. This state of the globe is attended with the same inconveniences as staphyloma, and with equal or greater deformity. By its enlargement, irregular figure, and unusual protrusion, it causes irritation of the lids, or experiences mechanical irritation from them; and the inflammation thus excited, irritates and weakens the sound eye. Under such circumstances, we may try the palliative relief of evacuating part of the fluid by puncture of the cornea or sclerotica. By repeating this proceeding, we may produce a sufficient diminution of the enlarged globe. If this plan does not succeed, we must perform the same operation as in staphyloma; the coats of the eye will then collapse, and the deformity may be remedied by the adaptation of an artificial eye.

I lately saw a child, four years old, in which both eyeballs were dropsically enlarged. The cornea and anterior chamber on both sides were nearly twice the normal diameter. Through the cornea, which was a little hazy, the iris with an enlarged pupil could be seen pretty clearly. The back of the globe was enlarged, though not to so great a degree as the front. The child could merely perceive the presence of light. The parents said that the child could see until the age of three months, when the eyes began to alter. They had been occasionally inflamed, and had slowly enlarged. The child was thin, with a pallid and sickly look. The head was rather misshapen, as if there had been some watery effusion within; but there had been no symptoms to indicate such an affection.

In morbid conditions of the globe fluid has been effused sometimes between the sclerotica and choroid, sometimes between the choroid and retina.

SECTION V.—ATROPHY OF THE EYE.

A kind of change exactly opposite to that last considered is not unfrequently observed in the eye: the organ undergoes absorption, and is slowly reduced in size, without suppuration, or any obvious alteration of structure; all the textures are equally diminished, so that the globe is lessened in all its dimensions by this kind of shrinking, which is called *atrophy of the eye* (*atrophia, aridura bulbi*). It frequently occurs in consequence of internal inflammation following penetrating wounds (*see page* 189). Sometimes it is an effect of serious internal ophthalmia, arising from other causes. As soon as the absorption commences, the globe loses its natural tension; it is soft and flaccid when felt through the upper eyelid. A diminution of the ordinary convexity and prominence is obvious, when the lids are closed. The shrinking goes on till the organ is reduced to the size of a nut or bean, in which we still perceive the proper component parts of the eye in miniature. There is a perfectly transparent cornea, one-half or one-third of the natural size, with an iris behind it, of which the pupil is closed. The

state of atrophy, which only takes place when the internal textures have been so changed as to destroy vision, is not an unfavorable termination, inasmuch as the shrunk globe is no longer subject to inflammation, and therefore never produces in that way, or by sympathetic influence on the sound eye, those inconveniences which are often experienced from staphyloma, or hydrophthalmia. There is no remedy for atrophy of the globe. We can neither arrest the progress of absorption, nor restore the diminished eye to its normal dimensions.

Collapse of the globe from suppuration.—Atrophy is quite a different state from the diminution of the globe consequent on general suppuration of its interior, which has been called, *phthisis*, or *consumptio purulenta oculi*. In the latter case, the coats collapse, and the eye shrinks to a small size, the cornea being scarcely, if at all, distinguishable. The small tubercle, to which the shrunken eye is now reduced, is subdivided into four parts by four superficial impressions, corresponding to the situation of the four recti muscles, and meeting together in the centre. The same collapse of the tunics, and fourfold division, of the tubercle, which they form, is seen after escape of the humors consequent on sloughing, general suppuration, or extensive ulceration of the cornea, as in purulent or gonorrhœal ophthalmia; also after the operation for staphyloma or hydrophthalmia.

In a collapse of the coats from suppuration, the deformity may be remedied by wearing an artificial eye. I have not seen this proceeding adopted in cases of atrophy. Beer says, that it is prejudicial in such instances, and that the mechanical irritation of the foreign body causes pain and more rapid diminution of the globe. (*Lehre*, vol. ii. p. 271).

After general suppuration or extensive ulceration of the cornea, the remains of the texture, which are opaque, adhere to the iris; the anterior chamber is abolished, and the front of the eye is flattened. This state has been called *consumptio purulenta corneæ*. If the united iris and cornea are pushed forwards by the collection of aqueous humor behind, staphyloma is produced.

SECTION VI.—EXOPHTHALMIA.

When the eye is pushed out of the socket, and more particularly when it has been thrust between the lids, so as no longer to be covered by them, the case is called *exophthalmia;* it has sometimes been denominated *proptosis*. The eye may be suddenly displaced by a penetrating wound with the introduction of a foreign body into the orbit (see Chap. XXV.); it may be more gradually protruded by suppuration in the orbit, or by changes of an obscure nature in the parts behind it (see Chap. XXV.); and a still slower displacement may result from enlargement of the lachrymal gland (see Chap. XXVI.), from adventitious growths of various kinds within the orbital cavity (see Chap. XXV.), from disease of its parietes, or from preternatural growths originating in the neighborhood, and making their way into the cavity. Further, the eye may be so enlarged by the various malignant diseases (see Chap. XXIII.), or by dropsical distension (Section IV. of this chapter), as to project between the lids. Thus it appears that exophthalmia is not a particular disease, but merely a change of position, which may be produced by various dissimilar causes. The term denotes an effect, but gives us no information respecting the cause.

Beer proposes to call the affection *exophthalmus*, when the protruded eye is in its natural state; *exophthalmia*, when it is inflamed; and *ophthalmoptosis*, when the displacement is caused by division of the nerves and muscles of the orbit, or by paralysis of the latter.

I have mentioned the displacement of the globe, in describing the symptoms of those affections to which it is incidental.

In the twenty-fourth chapter, on diseases of the orbit, I have mentioned protrusion of the globe as caused by changes in the soft parts around and behind it.

CHAPTER XXIII.

MALIGNANT DISEASES OF THE EYE.

Of the inflammatory affections incidental to the eye and the changes of structure which they produce, many are injurious to the organ, so far as vision is concerned; but they are not dangerous to life. The eye is subject to other diseases, which not only impair and put an end to its function, but completely disorganize it; and, by the progress of the local mischief, by the appearance of similar disease in other contiguous or remote parts, and by the constitutional disturbance connected with these changes, either separately or combined, ultimately destroy life. It may be affected with cancer, and with those peculiar changes in which the component tissues are converted, either into a texture sometimes resembling the substance of brain, or into a soft dark black mass. In these affections there is ultimately more or less change in the figure of the globe, more particularly by the appearance, on its anterior surface, of unnatural protrusions denominated fungus. Hence has arisen the somewhat vague and indefinite expression of fungoid diseases.

There are affections of the eye, attended with the formation of fungus, which are not of malignant character, though they commonly prove destructive to the part as an instrument of vision. I shall first describe some of these.

SECTION I.—DISEASES IN WHICH FUNGOID OR OTHER GROWTHS, NOT OF MALIGNANT CHARACTER, TAKE PLACE FROM THE ANTERIOR PART OF THE EYE.

Sometimes innocent fungous excrescences arise from inflammation affecting the anterior part of the globe. After external ophthalmia, more or less severe, a fleshy vascular substance may spring up from the surface of the sclerotic coat, from the orbiculus ciliaris, or from the cornea; or such a production may proceed from the iris, and cause ulceration of the cornea. Vascular or fungous growths, arising in this way, may assume a formidable appearance for some time, and then gradually subside, the eye going into a state of atrophy. After the existence of severe inflammation, a bluish prominence may arise in the seat of the orbiculus ciliaris, apparently proceeding from within outwards, so as to induce the suspicion that it may be a fungus arising from the interior of the globe. This swelling may become yellow, break, and discharge matter; after which the globe shrinks, without further injury to the patient. In the following instance, such swellings subsided without giving way externally.

Case.—*Acute ophthalmia, with the formation of yellow prominences in the situation of the ciliary body; spontaneous disappearance, and atrophy.*—A child about six years old came under my care at the London

Ophthalmic Infirmary, with serious external inflammation of one eye, attended with so much swelling of the palpebræ, that the exact state of the globe could not be ascertained. Quickness of pulse, heat of skin, furred tongue, great pain in the eye and head, restlessness and want of sleep, showed that the local inflammation must be serious. At the end of three or four days, when this had been reduced by leeches and suitable internal means, I succeeded in obtaining a view of the eye, in which there was vivid external redness, with a dull state of the cornea; the iris was pushed forwards and the pupil partially opaque. In spite of the antiphlogistic measures, the child continued to suffer. A tumor gradually arose behind the edge of the cornea; it was of a yellowish color, and acquired the size of a horsebean. Subsequently two or three other projections took place, of smaller size, arranged with the first, in a regular series, at a short distance from the margin of the cornea. The inflammation continued severe, although leeches and aperients had been frequently used. The mother said that the child still suffered from "inward fever," which did not yield to the measures employed. When several weeks had elapsed, the inflammation abated; the pain became less, and the protuberances round the cornea diminished in size. At last, the latter completely shrunk, the eye became atrophic, and the child recovered without any further ill consequences.

Two cases are quoted in Chapter XVII., from the work of Mr. Saunders, of fungous excrescences from the iris and corpus ciliare coming to a natural termination: see pp. 423—4.

The following two cases, related by Scarpa, (*Treatise on the Principal Diseases of the Eyes*, p. 515—518,) were apparently analogous to those just mentioned.

Case.—Pietro Campari, aged forty-eight, a husbandman of unhealthy constitution, subject to intermittent fever, and afflicted with chronic rheumatism, was suddenly attacked with pain in the left eye, which he attributed, without reason, to the entrance of some extraneous body between the eyelids. Violent inflammation soon took place in the eye, and was succeeded by total opacity of the cornea. Shortly afterwards, an excrescence of the size of a split bean arose from this opaque membrane, surrounded by blood-vessels highly turgid. In the course of a fortnight the sarcoma increased to such a degree as to project beyond the edges of the eyelids. In this state the patient was brought into one of the wards of the hospital, where the excrescence was removed by means of the ligature, and afterwards the application of caustics and the ointment of Janin. The patient went out, supposing himself cured; but in a short time afterwards the sarcoma returned, and became larger than before, with an extensive base, which, however, was soft and flexible in every part of it. Darting pains, extending to the head, disturbed the patient night and day, notwithstanding the use of opium internally, and externally of anodyne cataplasms. In order to remove the disease effectually, Scarpa considered the excision of the anterior hemisphere of the eyeball necessary. The operation was performed by the late Professor Jacopi. The recovery was speedy and permanent. The state of the excised portion is not mentioned.

Case.—Giovanna Gandini, a peasant girl, fourteen years of age, of weak constitution, had experienced in her sixth year, a violent inflammation of the left eye, followed by complete opacity of the cornea and staphyloma. Lately, after a still more severe inflammation, the anterior hemisphere of the eye had been converted into a reddish painful fungus, of cancerous aspect, except that it was everywhere soft and yielding. Complete extirpation of the globe was performed by Professor Morigi.

The cure was completed in two months, and no return of disease had occurred at the end of a year and a half. The soft fungus was found to be confined to the conjunctiva, cornea, and a portion of the sclerotic coat anteriorly; and the fundus of the eye, sound in every respect as to its membranes, contained only a limpid fluid instead of the vitreous humor.

Scarpa (*Lib. cit.*, pp. 518—521), quotes from other writers four instances, more or less similar to the preceding, in which extirpation of the globe was practised. The view which he takes of the subject is, that the fungous excrescences from the conjunctiva and cornea, although indolent and benign at their commencement, become, when left to themselves or empirically treated, in process of time, malignant, and really cancerous. (*Lib. cit.*, p. 512.) He says, that even in the course of six months, such a complaint may pass from the state of softness to that of scirrhous induration with hard warts, and afterwards of carcinoma, contaminating the lymphatic glands behind the angle of the jaw and in the neck, and, finally, in this short period, rendering the bones of the orbit carious. Hence, he considers it important not to neglect the opportunity of extirpating the disease in its early stage. (*Lib. cit.*, p. 525.) This notion of cancerous disease beginning with acute inflammation, and with the production of an excrescence, which, being at first innocent, afterwards acquires malignant characters, is totally at variance with my experience, and with the course of the disease in all the recorded instances of carcinoma, where its progress has been followed throughout. I consider the treatment founded on it to be equally objectionable. A comparison of the cases observed by Scarpa with that which I have related previously at p. 689, and with those quoted from Mr. Saunders in another chapter, p. 423, will lead to the strong suspicion that the operations performed in the former were unnecessary; and that the disease in these cases would have come to a conclusion from the resources of nature, alone, or aided by antiphlogistic treatment.

Partial or entire extirpation of the globe may, however, be advisable in some fungous growths which are not malignant. An example of this kind, in which a congeries of dark purple roundish masses grew from the cornea, is quoted from Mr. Travers, in Chapter XII., at p. 323.

Mr. Travers has also mentioned a case in which the globe was extirpated by Sir Astley Cooper, and has given a figure representing the appearance of the part on a section.

The patient, forty-six years of age, and the mother of nine children, had generally enjoyed good health. Two years before she underwent the operation, the cornea of her left eye had become opaque from chronic inflammation. "In this case, after a severe attack of fever, the surface of the eye began to throw up a vascular fungoid tumor. On her admission it was of the diameter of a shilling, covering the cornea and a part of the sclerotica, and protruding between the eyelids. It was slightly lobulated, of a dark purple color mingled with red: it sometimes bled, but was never painful." The recovery from the operation was speedy. *Dissection of the eye.* The tumour is situated without the globe: it appears pulpy, vascular, and of an unequal dark color. It is of a square figure, formed of various lobes, separated by delicate fibrous bands, and adheres to the sclerotic and the margin of the cornea. These two membranes could be traced entire beneath the tumor. The globe being divided, the vitreous humor escaped in a liquid state and of a yellow color. The lens had disappeared. Within the globe and opposite to the outer tumor, is another and a smaller morbid growth, which has no communication with the former, and is of a softer and very vascular substance. It occupies the lower

and anterior part of the globe, raises and compresses the retina, and is distinctly situated between the layers of the choroid coat." (*Synopsis*, &c., pp. 416, 417, plate vi. fig. 2.)

The same point is illustrated by an example recorded by Mr. WARDROP, in which it is to be regretted that the exact nature of the disease was not ascertained. He says, "I have had an opportunity of seeing other diseases of this organ, at a time when my attention was not particularly directed to the investigation of the present subject, which were, perhaps, neither of the nature of fungus hæmatodes nor cancer. I am led to form this opinion from the final result of the cases; and from thinking it highly probable, from analogy, that when the eye bursts, tumors may arise from its internal parts, resembling more some kinds of polypi, than either fungus hæmatodes or cancer. There are several cases of tumors of this kind described and delineated by BEER; and in the works of FAB. HILDANUS, there is an accurate account of a case, which was successfully extirpated, in which a prodigious tumor grew from the eyeball. A remarkable case, very analogous to that given by F. HILDANUS, I had the opportunity of seeing, ten years ago, under the care of Dr. WARDROP. A gentleman, who resided in England, consulted many respectable surgeons about a very large excrescence which grew from the eyeball; but as they supposed it to be of a cancerous nature, and as the disease had extended far, they declined making an attempt to remove the diseased parts. When he came to Edinburgh, a very large excrescence was found projecting from the orbit, and extending beyond its bony margin. As Dr. WARDROP was assured, from a careful examination of the parts, that the whole diseased mass was within the reach of the knife, and doubtful of its cancerous nature, he undertook to extirpate it. The operation was accordingly performed, and, the eyelids being excoriated, they were also taken away along with the tumor. The parts healed in the most rapid manner, and the gentleman returned home to England in a month after the operation. A short time ago, Dr. WARDROP heard that the disease had not returned. No account was taken of this case; but Dr. WARDROP particularly remembers, that the optic nerve was found quite sound. (*Observations on Fungus Hæmatodes*, p. 88—90.)

Morbid productions, sometimes under the form of fungus, may arise from the conjunctiva (see the remarks on *polypi, warts, and other excrescences of the conjunctiva*, in Chapter XII. at p. 319); from the sclerotica (Chapter XIII. p. 33, *on cysts and tumors of the sclerotica*); from the iris or corpus ciliare (see the observations on *fungous excrescences from the iris and ciliary body*, and *on tumors growing from the iris* in Chapter XVII., pp. 414, 435). If the apparent cause, the original seat and progress of the malady, and the condition of the eye in other respects be investigated with even moderate care, there can be no risk of confounding such cases with malignant diseases of the organ.

The active inflammation preceding and accompanying some of the affections now alluded to, sufficiently distinguishes them from malignant affections, which exhibit no marks of vascular excitement in their early stage: and, although often very painful, are not usually accompanied by active inflammation at any period.

Cancerous ulceration of the eyelids has been already described in Chapter II. § 3, p. 127.

SECTION II.—CARCINOMA OF THE EYE.

If the eyeball is susceptible of scirrhous induration and subsequent cancerous ulceration; that is, if it can undergo changes similar to those which characterize cancer of the female breast, the disease is very rare, and has not as yet been clearly described or delineated. I have seen the globe converted into an apparently scirrhous mass, having a knotted surface, with enlarged vessels distributed over it, in which there was no trace of the natural structures. There was no material increase of size, nor was the altered globe more fixed in the orbit than in the natural state. An excavated ulcer, about as large as a shilling, had taken place, but without offensive discharge. The disease was of long standing, in a person of middle age, and did not disturb the general health. The palpebræ were free from disease, and there was no reason to suppose that the other contents of the orbit were altered in structure.

"I much suspect," says Mr. WARDROP, "whether cancer ever affects the globe of the eye in its primary form; at least, I have never met with an example of this kind. I have had repeated opportunities of observing a cancerous sore, beginning in the integuments of the eyelid or tarsi, and spreading along the conjunctiva, till it reached the globe of the eye, the structure of which is ultimately destroyed, and contaminated the neighboring absorbent glands; but I have never been able to obtain an accurate account of a single case, where any of the coats or contents of the eyeball were the primary seat of cancer." (*Observations on Fungus Hæmatodes*, p. 87.)

We may conclude that the affection is rare from the circumstance of its not being noticed in the work of Mr. TYRRELL: Mr. MIDDLEMORE, however, speaks of it as if it were of frequent occurrence. He gives a long general account of the subject, without any details of cases or dissections. The result of his experience is stated shortly in the following passage:—"Of the many thousand persons, whose diseased eyes I have examined and treated, I have never yet seen a single case of genuine carcinomatous ulceration of the globe of the eye, but I have, on several occasions, witnessed a state of disease, which I have termed scirrhus, because it is attended with great local pain, occurs in advanced life, is connected, in general, when of long continuance, with a constitutional affection, has a tendency to involve surrounding parts, and is, from the first, characterized by a shrinking and uncommon induration of the affected organ. The term scirrhus of the eyeball is, then, intended to apply to a shrunken, indurated state of the eyeball, which, on minute examination, is found to be converted into a solid compact mass, the section of which exhibits the membranous striated appearance so peculiarly characteristic of scirrhous induration in other situations." (*Treatise*, vol. ii. p. 370.)

We have no pathological materials for a history of the disease; the structure in which it begins, its progress and ultimate effects on the globe and on the constitution are not known to us. I am not acquainted with any well-marked histories and dissections of true cancer of the eyeball.

The following case, recorded by Dr. FARRE, may have been carcinoma; but the exact nature of the change, which the structure of the globe had undergone, is not pointed out, either, in the description or delineation, with sufficient clearness for us to determine the point, or to decide positively whether it ought not to be referred to fungus hæmatodes.

"In the year 1803, Mrs. L. gradually, and without any pain or apparent disease, lost the sight of her right eye. About two years after, she was attacked with violent pains in that eye, and in the head, on the same side;

and, from this time, became subject to occasional ophthalmia. In June, 1807, the ophthalmia was extremely severe, attended with violent pain both in the head and right eye. The cornea was considerably opaque, the iris was rather contracted, not perfectly circular, and quite immovable; though the eye was sensible to the action of light. The other eye was also, at the same time, slightly inflamed. The inflammation and pain in the latter soon subsided, and were removed in the former in about a month; and no more was heard of the patient till the latter end of April, 1808. There was then a very perceptible and rapidly increasing enlargement of the contents of the orbit of the eye. The cornea had lost all its transparency, and was thickly covered with minute red vessels. The inflammation of the conjunctiva had obscured almost the whole of the sclerotica; but a distinct view of a small segment of its circumference, clearly showed the globe of the diseased eye to be smaller than that of the sound one. This circumstance, when combined with the great prominence of the diseased eye, furnished strong reason for suspecting that it was constantly pressed upon and protruded by a tumor in the interior of the orbit. In this state of the disease an operation was judged the only means of relieving the excruciating pains of the patient, which, though in some degree constant, experienced the most violent exacerbations every evening. On the 9th of January, 1809, the whole contents of the orbit were removed by Mr. Saunders, with the greatest care and ability: on this occasion the os unguis was found slightly diseased. For two days after the operation the patient enjoyed perfect ease. On the third day some pains in the head returned; and though the parts healed well, were considerable, till within the last seven weeks of her life. About that time, after a sleepless night, in which she had experienced much more pain than usual, all pain suddenly left her, and she sank into a state of mental imbecility, in which she was often unable clearly to distinguish her most intimate acquaintance. The appetite was excellent, and her sleep sound, but more than natural; when awake, she was animated with such high spirits, as generally induced her to address and reply to her friends in a facetious, though not always appropriate or completely intelligible manner. This state continued till she died, on the 11th of July, 1809, in the seventy-seventh year of her age. (*A Treatise on some Practical Points, &c.* pp. 150—153.)

Figure 5, of Plate III. represents a section of the extirpated mass. The sclerotica is nearly filled with the morbid growth: it has undergone absorption at one part, near the optic nerve, and the disease, passing through this opening, has been communicated generally to the adipose membrane in which the eye is imbedded. The medulla of the nerve is discolored at the point where it had been cut through; but it was sound between this point and the globe. (*Lib. cit.*, p. 218.)

Beer gives the following description of scirrhus and cancer affecting the eye. As he does not mention fungus hæmatodes, or melanosis, we cannot receive this account as applicable to carcinoma of the eyeball, in the limited sense in which I have employed that designation. No cases corresponding to these descriptions have come under my observation.

"Scirrhous exophthalmia attacks the proper textures of the eye, and destroys entirely, or in greater part, their normal structure and form. It is characterized by an unequal and very hard swelling of the entire globe, which is of a reddish-white color, by a troublesome sense of weight, impaired or destroyed motion of the part, without pain or fever. Glandular swellings, in various parts, as in the neck, axilla, and breast, often accompany the complaint in the eye. A perfectly scirrhous eyeball consists of

a brownish, very firm mass, in which the proper textures of the eyeball are lost, or at least some traces of the sclerotica only can be distinguished.

"Carcinomatous exophthalmia, which is usually developed from a preceding scirrhous change of structure, rapidly involves all the textures, to such a degree, that in a short time no trace of the original organization remains. The cases are more rare, in which this formidable degeneration of the globe, which sooner or later destroys the patient's life, commences with the development, in the conjunctiva corneæ, and scleroticæ, of single, wart-like, very painful, and dark red tubercles, which have been called, by writers on ophthalmology, *papulæ*, or *caruncularæ malignæ* or *rebelles*. When carcinoma proceeds from scirrhous exophthalmia, it does not immediately break out into an open sore: acute lancinating pain is previously felt in the scirrhous eye, and extends into the head; vessels are seen on the surface of the diseased organ, and in the eyelids, in a state of varicose enlargement; the part constantly increases in size, and becomes exquisitely sensitive to the slightest touch, while the addition to these symptoms of considerable fever, denotes the complete formation of an occult cancer. This, sooner or later, breaks out into one or more true carcinomatous ulcers, marked by the ordinary characters: the pain now becomes intolerable, experiencing only short, occasional mitigations, by spontaneous and active bleedings from the distended vessels. Such hemorrhages may be so profuse as to cause fainting, with considerable subsequent debility; and, commonly, the fatal termination is immediately produced by an occurrence of this kind. The strength is further exhausted by the daily and hourly excessive discharge of a stinking sanies, streaked with red and green, from deeply corroding ulcerations of the eye, with hard, leaden-colored, uneven, and everted edges, whereby the cachectic state of the constitution is aggravated, and the slow, hectic fever is kept in a state of constant progression." (*Lehre*, vol. ii. p. 225—227.)

The opinion of Mr. Travers will be seen from the following quotations. "I had formerly been led to suppose, that the malignant disease termed cancer, affected the ball or globe of the eye. Such is the doctrine of most writers on the subject. I have, however, satisfied myself that as regards the eye, this disease is peculiar to the lachrymal gland, conjunctiva, and eyelids; and I have classed it accordingly." (*Synopsis of the Diseases of the Eye*, p. 216.)—"There is a malignant fungus of the conjunctiva; for, like the mucous membrane of other parts, this is sometimes the seat of carcinoma; and, excepting the lachrymal gland, I believe no other texture related to the organ of vision is ever primarily so affected. I have removed the contents of the orbit for a painful tubercular fungus, with ulcerated depressions containing an ichorous discharge. The coats and humors of the eye were for the most part absorbed, the lachrymal gland scirrhous. The disease afterwards returned upon the palpebræ, and destroyed the patient. I have at this time a similar case under my observation. The fleshy tubercles grew from the conjunctiva, both on the cornea and sclerotica, and the inferior palpebra is extensively ulcerated. It is accompanied by lancinating pain in the supra-orbitar region, and an unhealthy discharge." (*Ibid.*, p. 100.)

The appearance of the disease in the last-mentioned case is delineated in Plate II. fig. 1, which I should have supposed to represent the carcinomatous affection of the eyelid already described. I conclude, indeed, from the further description by Mr. Travers, in the *Medico-Chirurgical Transactions*,* that the cancer of the eyelids, which he represents as an affection originating in the conjunctiva, is not different from the disease in the same

* Vol. xv. pp. 234, 235.

part, which I have found to commence in the skin. For he strongly represents one striking feature of the complaint in its advanced period, namely, the resistance of the globe to the progress of the destructive disease. "For a long time the globe remains (I have even seen the cornea and humors clear) suspended, as it were, geometrically in the centre of the ruin." Other points of this description have not, however, been exemplified in the cases which I have seen; such are, a luxuriant fungus overshooting and burying the eye; exposure of the malar and temporal bones; and an immense fungous mass encircling the orbit, and in part springing from it, everted over the supercilium, nose, temple, and cheek.

Causes.—On this subject I may refer to the remarks already made, in reference to that point, in speaking of carcinoma of the eyelids, and particularly in regard to its supposed origin from injuries, external irritants, common inflammation, or the consequent thickening and induration.

Treatment.—Internal remedies and external applications are of as little avail in cancer of the eye, as in other affections of similar nature. The only question is, whether extirpation can be undertaken, in an early period of the disease, with reasonable prospect of success. The operation would not be advisable, unless the affection were confined to the globe, and that were freely moveable in the socket. If the disease should have extended to the surrounding parts, and the eye should have become fixed, the operation would be unavailing; at least relapse of disease might be confidently expected. Such was the unfavorable termination of cases operated on by Desault,* Scarpa,† and Mr. Travers.‡ When the eye, although altered in texture, is not much enlarged, when it is still movable in the orbit, when the palpebræ and the absorbent glands are unaffected, and the general health is good, the removal of the diseased organ may be proposed, although we cannot guarantee the permanence of the cure. After mentioning that he had found medicines altogether useless in scirrhus of the globe, Beer proceeds to say that extirpation remains as the only resource. "However," he adds, "I cannot positively promise a completely favorable result, even under the most auspicious circumstances. Knowing that this operation, although performed by excellent surgeons with the greatest care, has generally turned out unfortunately; and having experienced failure in two cases out of seven, where I had undertaken it on the clearest indications, I can place no great confidence in its essential benefit to the patient, unless a temporary relief from a change of structure, attended with great deformity, should be regarded as such." (*Lehre*, vol. ii. p. 230.) The conclusion in this passage, is singularly at variance with the premises. Five cures out of seven cases, if they were permanent, constitute an encouraging result, and would justify a much stronger recommendation of the operation than could be warranted by general experience. Perhaps Beer may have intended to

* Œuvres Chirurgicales, par Bichat, tom. ii. p. 115—117.

† In the preface to the first edition, Scarpa says, that he had seen only two instances of cancer of the eye. The first, in a boy of thirteen, seems to have been an example of fungus hæmatodes. "In the second, that of a man fifty years old, robust, and perfectly healthy in all other respects, the cancerous fungus included not only the globe, but also a portion of the upper eyelid. I removed, with the greatest accuracy, the contents of the orbit and the upper eyelid, cutting along the edge of the orbit, where the parts appeared perfectly healthy. Everything proceeded very favorably till the fortieth day, and the cicatrix was advancing gradually from the margin of the orbit towards its fundus. The wound now became stationary, and at various points fungous growths shot up, which I endeavored in vain to destroy with powdered savine and caustic. Severe pain of the head and nervous fever came on: the patient lost his senses, and died."—Saggio di Observazioni, &c. Pavia. Prefazione, p. 9, 10.

‡ Synopsis, p. 100.

speak merely of recovery from the operation; I can hardly suppose that permanent cure would have been effected in so large a proportion of cases truly cancerous.

If the case should have proceeded so far, that we do not think the operation advisable, we can only palliate the mischief, mitigate the pain and distress of the patient, and thus render his condition more comfortable. When the suffering is considerable, we must administer narcotics, increasing the dose in proportion as the constitution becomes habituated to them. The local application of opium often gives relief, especially in the ulcerated stage, and the *liquor opii sedativus* of Mr. Battley is a form well suited to the purpose. We may begin with two drachms to an ounce of distilled water, and gradually increase the strength, until we use at last the undiluted liquor. Lint, moistened with the fluid, may be applied to the part under a dressing or poultice. Opium may be used in the form of ointment, made by incorporating one or two drachms of it finely powdered, with an ounce of lard. The internal use of the same remedy is necessary to relieve pain. The progress of these cases is often slow: the affection may be clearly marked and completely developed, and yet continue much longer than might have been expected, without destroying life. In a patient who used to come to the London Ophthalmic Infirmary, cancer of the globe had existed for a long time. During three or four years that I saw him occasionally, it made but little progress. We are not therefore to infer, because this disease destroys life, that it does so rapidly.

Scirrhus of the caruncula lachrymalis and of the lachrymal gland.—What I have to remark on these affections will be found in the chapter on diseases of the lachrymal organs.

SECTION III.—FUNGUS HÆMATODES OF THE EYE.

Of the malignant affections, incidental to the organ of vision, this is by far the most frequent; its nature, progress, and fatal termination being similar, in all essential points, to what we observe when the disease attacks other parts of the body. The globe of the eye is gradually converted into a soft texture, approaching more or less nearly, in color, appearance, and consistence, to the substance of the brain. This adventitious growth, after distending and enlarging the globe, makes its way externally through the cornea or sclerotica, and appears as a fungus, distending the lids, or projecting between them. Ulceration and sloughing ensue, with fetid discharge, hemorrhage, and great pain; and these, with severe constitutional disturbance, soon destroy the patient. The absorbent glands are generally affected; and secondary affections, similar in character to the primary disease, are usually found after death within the cranium and in other parts.

The morbid growth, which appears first at the back of the globe, gradually comes forwards, and makes its way externally by ulceration of the cornea or sclerotica. In the first stage of the affection, the pupil exhibits a deep-seated, whitish, yellowish, amber-colored, or even greenish discoloration of brilliant appearance, causing a reflection of light, as if a metallic plate were at the back of the eye, and soon noticed even by unprofessional persons. In the very early period, this discoloration is so small, that its limits can be distinguished. We soon find that it is owing to an adventitious deposit in the eye, of which the surface is usually uneven, and sometimes exhibits vascular ramifications, which have been supposed to be those of the central vessels of the retina. At first the iris may be sluggish, and the pupil large; the latter soon becomes fully dilated and fixed. There is

no change of figure in the globe, no unusual vascularity, nor any evidence of pain; but vision is destroyed. In the second stage, the diseased production increases in size, distends the globe, advances to the front of the eye, pushes the lens and iris against the cornea, and destroys the transparency of the former, which assumes a light amber-color; the tint of the iris also is more or less changed. The sclerotica is manifestly distended; it has a bluish or leaden color, and partial bulgings are sometimes seen on its anterior part. The distension of the globe is further evidenced by enlargement of the cornea, which loses its clearness. The eye is now inflamed and painful, and sympathetic disturbance of the constitution takes place: inflammation and pain sometimes occur at an earlier period; they may be removed for a time and come on again. The fungous growth, which most strongly characterizes the affection, is now lost sight of, being concealed by the opaque state of the lens. "In this stage of the disease," says Mr. WARDROP, "I have known two cases which were mistaken for cataract, and in one of them an experienced surgeon attempted to couch it."* He observes further, that "in some cases a quantity of purulent matter collects between it (the adventitious growth) and the cornea."

In the third stage, the inflammation of the eye increases, with augmented vascularity, and lachrymal discharge, with redness, swelling, vascular distension of the lids, severe pain of the eye and head, excited circulation, hot skin, restlessness, and want of sleep, white tongue, thirst, and loss of appetite. Having caused more or less considerable enlargement of the globe, the tumor now makes its way externally, the cornea or the sclerotica, after previous distension, giving way by absorption, with temporary relief of the local and general suffering. The escape of the crystalline lens through the cornea, just before the external appearance of the tumor, has been sometimes observed.† A soft reddish, reddish-white, gray, brownish or livid fungus now protrudes from the surface of the eye, and the organ, increasing in size, but without any trace of its normal structures, projects between the lids, if it should not have done so previously. The fungus, which is soft and easily lacerated, bleeds spontaneously, or on the slightest injuries; it discharges a fetid ichor or sanies, which excoriates the lower lid and cheek. Portions of the most prominent part, slough away with increase of the discharge and fetor, the separation being often attended with profuse bleeding. Under the various combinations of ulceration, sloughing, and hemorrhage, with the presence of discharge, or blood in a fluid or dried state, the color and external appearance of the disease may exhibit considerable varieties. It increases rapidly, soon acquiring the size of a small apple or of an orange; it may become as large as the fist, or even attain a greater magnitude.

If the fungus should burst through the sclerotica, it will distend the conjunctiva, and thus acquire a mucous covering, under which it may enlarge considerably before ulceration, and the subsequent processes of sloughing and bleeding commence. It grows more slowly in this case, and sometimes greatly distends the lids, without projecting between them.

The disease may have its origin exterior to the globe, which it partially surrounds and pushes forwards. The tumor is covered by the conjunctiva, and in the centre of its anterior prominence are seen the cornea and iris not much altered. It grows slowly, expanding and enlarging the lids, then pushing out between them, acquiring a great magnitude without ulceration. When it is larger than the fist, the cornea and iris may still be recognized of their natural size, and nearly normal structure. Mr. TRAVERS gives a

* Observations on Fungus Hæmatodes, p. 11.

† Observations on Fungus Hæmatodes of the Eye, by Mr. MIDDLEMORE. London Med. Gazette, vol. vi. p. 879.

colored engraving of such an affection in an infant of eight months, in whom the disease was congenital, the eyeball having been as large as a walnut at the time of birth, and equal to the fist when the figure was taken. He observes that "the disease in this infant, from the central position of the cornea, and from the enormous protrusion and equal figure of the ball, was supposed to be seated on the orbitar appendages. It is remarkable that the child was well nourished, and apparently suffered little constitutional disturbance. The other eye was sound." (*Synopsis*, pp. 205 and 410. Plate v. fig. 2.)

Although it seems probable that, in the cases now alluded to, the disease is of the same nature as in those where the growth begins in the globe, the point has not yet been ascertained by dissection; nor do we know at what period, nor in what manner or degree, the proper textures of the eye may become involved in a disease which is at first foreign to them, supposing our notions on that subject to be correct.

The neighboring lymphatic glands sometimes enlarge, and become diseased; sometimes they are unaffected. Those which I have seen diseased have been on the cheek in front of the parotid, under the lower jaw, and at the side of the neck over the large blood-vessels. They have sometimes formed tumors of considerable size. Mr. Wardrop says, "The absorbent glands become also affected during the progress of the disease; they swell and inflame, and sometimes grow to an enormous size. In some cases the swelling of the glands commences at a very early period, whilst in others they are not affected until the disease is far advanced. Most commonly those glands swell which lie in the immediate neighborhood of the parotid gland, or lower jaw. In two cases, I found a small hardened gland close to the optic nerve; in a third case, glands were found near the nose, and on the supercilia; and, in another case, a diseased gland was found adhering to the os malæ, within the margin of the orbit."*

"I have not," says Mr. Middlemore, "often seen the superficial glands much affected; they have been in two instances slightly enlarged and tender, but it has not fallen to my lot to witness them changed into a medullary mass, or proceed to ulceration. Such an occurrence seldom takes place, and then only, as far as my observation extends, at the close of the disease." (*Lib. cit.*, p. 882.)

When the disease has reached the ulcerative stage, the child soon sinks under the profuse discharge and bleedings, the severe pain, and constitutional disturbance, and dies emaciated. Affection of the brain may come on in the latter stage and cause convulsions; more frequently it is of a comatose character, and the patient dies insensible: sometimes the sight of the sound eye has been lost, either gradually or suddenly, before death. These circumstances are explained by the extension of disease through the back of the orbit into the cranium, and by the internal disease being sometimes so situated, as to press on the opposite optic nerve.

Seat and nature of the disease.—The examination of eyes affected with fungus hæmatodes, in its early period, has led to the conclusion, that the disease consists in organic change of the retina, or in a growth from the retinal extremity of the optic nerve. This would account satisfactorily

* Observations on Fungus Hæmatodes, p. 13, 14. The first plate of this work contains two figures, representing the external appearance of the disease. In one, where it had returned after extirpation of the globe, there are three glandular swellings, in front of the parotid, and below the jaw, as large as walnuts. In the other, the absorbent glands under the jaw are increased to a mass half as large as the child's head, although the original disease is not of large size. See p. 33 and 43.

for the appearance, exhibited in the commencement, of an adventitious growth in the fundus of the eye, and for the simultaneous loss of sight.

Mr. Saunders examined after death, a case in which the left eye had become affected with fungus hæmatodes at the age of nine months, and the right at that of fifteen months. The child died soon after the latter period, when the left eye had become completely disorganized, but the disease on the other side was still confined to its original seat in the vitreous humor. In this eye, which is figured, both in Mr. Wardrop's *Observations on the Fungus Hæmatodes*,* and in the posthumous work of Mr. Saunders,† the optic nerve, sclerotica, and choroid were sound, the latter being thin. The retina had degenerated into a soft mass of lobulated appearance, connected only to the optic nerve.

Mr. Wardrop removed the eyeball in an infant under three years, in whom the morbid growth was still confined to the interior of the globe. A fleshy-looking mass, about the size of the little finger, surrounded the optic nerve, adhering firmly to it, and to the adjacent part of the sclerotica. A section was carried through the diseased mass and the eyeball. The former and the optic nerve were now seen to be distinct; the nerve was larger and firmer than usual, and altered in color; "after the nerve entered the sclerotic coat, nothing like retina could be distinguished, but it seemed to swell out and form a mass resembling that which surrounded it externally. This mass filled the posterior chamber in such a manner, that the choroid coat was pushed from its natural situation towards the anterior chamber, in the form of an irregularly shaped bag."—The tumor could be separated from the sclerotic coat at every part, except near the entrance of the optic nerve. There it adhered to it so firmly that it could not be dissected from it without being torn. The different parts of the mass much resembled common medullary matter, intersected in an irregular manner with cellular fibres, which rendered it rather firmer, and less easily divided than brain." (*Lib. cit.*, p. 37; plate ii. fig. 1.)

Mr. Ware extirpated the left eye of a child six years old, on account of fungus hæmatodes. The disease soon returned with glandular enlargements on the face near the parotid, and in the neck, and the right eye began to exhibit the same affection, which, however, had not proceeded beyond its first stage, when death ensued. "The right eye did not appear to be enlarged; but on cutting through its tunics, almost the whole space, usually occupied by the vitreous humor, was found to be filled with a steatomatous substance, which in general was of a white color, but in some few places was red and bloody. When this substance was removed, a white smooth tumor was discovered behind it, perfectly distinct from the steatomatous substance above mentioned, and appearing to be a morbid alteration of the tunica retina itself. The tunica choroides had very little of the nigrum pigmentum spread over its surface. The crystalline humor, as well as its capsule, was perfectly transparent; and the optic nerve and every other part connected with the eye, appeared to be in a healthy state." (*Remarks on the Ophthalmy*, &c., p. 229—232.)

The following description of an eye removed during the first stage of the disease is given by Mr. Mackenzie. "I have now before me an eye, extirpated by the late Dr. Monteath, during the first stage of this disease. Immediately after the operation, I divided the cornea and sclerotica by a crucial incision, and laid back the four flaps. The iris and choroid were entire. I divided them in like manner, laid them back, and along with the

* Page 193; the case is given at p. 47.
† Page 145—147; fig. 6 of plate 2.

choroid, I found that I reflected also the retina, which, though broken, and here and there deficient, is still sufficiently entire to give a white coating to the whole internal surface of the choroid, and has evidently nothing to do in this instance with the medullary tumor, which occupies the whole space of the vitreous humor and crystalline lens, and springs from the optic nerve as from a root. The tumor, enveloped in a membrane similar to the hyaloid, was of the consistence of brain, and of a yellowish-white color. The optic nerve, exterior to the sclerotica, did not appear diseased." (*Practical Treatise*, p. 547.)

"The retina," says Mr. WARDROP, "becomes so completely changed, that in no instance could I detect any remains of its natural appearance; and a tumor is formed in the posterior chamber, extending from the entrance of the optic nerve forwards, in such a manner as to displace and promote an absorption of the vitreous, crystalline, and aqueous humors. (*Lib. cit.*, p. 14.)

Professor PANIZZA examined an eye which had been extirpated in an early period of the affection, and found an adventitious growth immediately involving the retina, although that tunic and the optic nerve were not changed in structure. The case was that of a lively, robust, intelligent infant, twenty months old, of swarthy complexion, in whom fungus hæmatodes had existed for a month in the left eye, having originated from a serious internal inflammation of short duration, following severe suffering from dentition on the corresponding side of the upper jaw. The eye was natural in size, motion, and state of vessels; the pupil excessively dilated and motionless. Behind that opening appeared a spot of pale yellow, or canary color, divided into three tubercular eminences, with a red vessel creeping between them. It was best seen by looking latterly at the eye, when it appeared near the pupil; while to an observer placed in front it seemed in the fundus of the globe. Vision was extinct. The diseased organ was removed by Dr. DONEGANA six weeks after the beginning of the disease. The result was most favorable, and the child from that time enjoyed perfect health. The globe was perfectly natural in size and form, but rather firmer than usual; no change was observable in the optic nerve. Through the cornea, which was still transparent, the discoloration behind the pupil was visible, as before the operation. The removal of the cornea, which allowed the escape of the aqueous humor, and that of the iris, which was healthy, exposed the crystalline in its capsule, still perfectly transparent. On looking through the lens, the yellow spot seemed in the fundus of the eye; but when it was removed, we were surprised to see the diseased mass immediately behind, forming part of the excavation in which the posterior convexity of the lens is lodged. The substance was soft and elastic, and its three eminences could be separated a little by pressing with the end of a probe. In order to ascertain more exactly its origin and nature, a portion of the sclerotica and choroid was removed from the back of the eye.

As soon as the latter tunic was opened, a yellow fluid escaped with some force, and the tubercular eminences became less prominent. The fluid was yellowish and glutinous; it coagulated in spirit so as to form a pale yellow homogeneous mass. The eye was now placed in spirit to prevent the further escape of this substance. After removing a portion of the sclerotica and choroid, both of which were natural, the interior of the eye seemed full of the yellow matter, which was granular, and reduced into a fine powder by rubbing between the fingers. As the retina did not come into view after removing the choroid, it seemed as if that tunic had degenerated into this yellow matter, which appeared continuous with the optic nerve at its entrance into the globe. Indeed, on lifting the nerve gently, it

appeared like a cord gradually expanding into the yellow mass. On carefully removing the latter, I found in the midst of it the retina, shrunk, folded, and reduced into a conical form, extending from the entrance of the nerve to the eminences already described, which were merely prominences of the tunic caused by pressure of the yellow fluid. Hence it appeared that the yellow spot was not a change of structure in the retina, but produced by a yellow fluid collected between it and the choroid, and pushing the retina towards the middle of the eye and forwards. The vitreous humor became diminished in proportion as the morbid deposit increased, and the eye contained only a very small portion. The firm connection of the retina to the corpus ciliare prevented the yellow fluid from entering the posterior chamber. We can thus perceive how the retina, pressed on all sides by the morbid deposit between it and the choroid, was pushed forwards so as to form the three tubercular prominences which caused the yellow appearance in the pupil.*

In an eye examined by Mr. Wardrop, appearances were found analogous to those described by Professor Panizza in the foregoing case. I have subjoined an account of the dissection, although there is some obscurity in the statement respecting the situation and connections of the morbid growth.

Case.—A boy, two years and eight months old, became dropsical, and died after having been twice tapped. It had been remarked some weeks previous to his decease, that there was a peculiar appearance in the left eye; the bottom of the posterior chamber having a metallic lustre produced by a yellowish opaque body. The dropsical fluid had been contained between the laminæ of the great and lesser omentum. "The optic nerve of the affected eye was found to be perfectly similar to that of the opposite side, from the thalamus till it entered the globe. The consistence or density of the sclerotica was not perceptibly altered. The choroid coat appeared rather paler than natural, and being lacerated at one small point, during the dissection, a quantity of a creamy fluid escaped. On turning back the choroid coat, the posterior chamber appeared filled with an opaque white mass, on the anterior part of which lay the crystalline lens. By immersion in spirits the retina was rendered more opaque than the new production, and was found of its natural appearance, and enveloping the diseased growth. The hyaloid membrane also surrounded the tumor, and had become opaque in a few points where the diseased production was found firmly adhering to it. This presented a mass consisting of granules or lobules, united by fine reticulated membrane. It seemed to have commenced at the point where the optic nerve pierces the sclerotic coat; at least it was connected to that point by a small pedicle, which was continuous with the larger mass attached to the hyaloid membrane, the structure of the whole being perfectly identical; viz., small granules, about the size of a millet-seed, connected together by reticulated membrane." (*Lancet*, vol. xi. p. 87.)

In all the cases of genuine fungus hæmatodes, which I have seen, and in all the recorded instances, which have been examined with sufficient care and accuracy to convince us that nothing had been overlooked or mistaken, except the two cases last quoted from Panizza and Mr. Wardrop, disease has been found in the optic nerve or retina, or the latter could not be traced at all, its place being supplied by the morbid growth. In Mr. Wardrop's, there seems to have been a morbid change of the vitreous humor; in that

* Sul Fungo midollare dell' Occhio, appendice, Pavia, 1826. Page 9—13, tab. 1, fig. 3—7.

recorded by PANIZZA the disease was anomalous; I think it was not fungus hæmatodes.

The posthumous work of Mr. SAUNDERS contains a figure representing the section of an eye removed on account of organic disease developed in the globe. (Plate ii. fig. 4, p. 147—150, 207.) The diseased growth, which occupied nearly one-half of the common seat of the vitreous humor, "seemed to be composed of a yellow-colored coagulable lymph, streaked with black, and to have originated from the inner part of the sclerotica, for the choroid coat was ascertained by dissection to quit the sclerotica, and pass on the inner side of the tumor." The exact condition of the optic nerve and retina cannot be satisfactorily ascertained either from the figure or the description. The age of the patient (thirty-five), and the black streaks of the morbid growth, lead to the suspicion that the case may have been melanosis.

Mr. TRAVERS is of opinion that the origin of fungus hæmatodes is not confined to any one texture of the eye. He says, "sometimes one, and sometimes another of the proper textures appears to be the matrix of the disease. The fungus, in one instance, adheres intimately to the sclerotica, and detaching the choroid and retina, throws these and the vitreous humor to the opposite side of the globe. Frequently it splits the sclerotica into two lamellæ, distinctly originating in the interstitial substance of that coat." "But in other cases, the disease unquestionably begins in the choroid, and that tunic gradually degenerates into the diseased mass, which, occupying a large portion of the globe, is throughout deeply tinged with the black pigment. Sometimes the sclerotica has a morbid growth externally, and the choroid in the interior." Sometimes these tunics are only affected secondarily, the vitreous humor being the nidus of the diseased growth. "The iris and the corpus ciliare evidently degenerate in the same manner as the choroid. Again, the disease has seemed to originate at the point of entrance of the optic nerve into the globe, pushing the humors before it; and the nerve itself has upon dissection been found diseased, both contiguous to the sclerotic, and at the distance of three-quarters of an inch from that tunic, where the intermediate portion has preserved its healthy aspect." "It appears to me, therefore, that this is not a disease of this or of that texture, as writers would insinuate, but of all the textures, the crystalline and cornea excepted, which yield to its progress, but never exhibit a specific change of texture. (*Synopsis of the Diseases of the Eye*, pp. 220—222.) Mr. TRAVERS represents that the choroid is the most strongly disposed to assume this diseased action, the retina the least so. He considers that the common nidus of the morbid deposit is the cellular structure, whether that of the adipose membrane, the common, connecting tissue, or that belonging to an organ. Hence it may be deposited either on the surface or in the substance of the various tunics, or in both situations at once. (*Lib. cit.*, pp. 421—423.) The varieties in color, texture, rapidity of growth, and other characters, are referred by Mr. TRAVERS to the differences of texture in the source of the disease. "The deep blue and black tubera characterize the choroid fungus; the medullary, the substantia alba of the optic nerve or brain; a more dense fibrous brown tuber, clear of stain, is the production of the sclerotica." (*Lib. cit.*, pp. 222, 223.)

In explanation of these opinions, it must be observed that, under the name of fungus hæmatodes, Mr. TRAVERS includes melanosis, a change of structure incidental to the adult, and differing essentially from the medullary disease of children. Also, that the dissections, from which these conclusions have been drawn, seem to have been made principally in cases of comparatively advanced disease, which were less calculated to show the

primary seat of the affection, than to illustrate its rapid and destructive extension to contiguous parts.

The growth of the morbid substance alters in various ways the form and relative position of the parts within the globe, sometimes pushing forwards the choroid and vitreous humor, sometimes distending the former; sometimes destroying entirely or in great part the characteristic appearances of that tunic, and causing partial or general absorption of the vitreous humor. The sclerotica suffers the least, retaining its natural structure even when the disease has made considerable advance, and though the morbid growth may cover and closely adhere to both its surfaces. The crystaline lens is merely pushed forwards by the growth from behind. As the pressure increases, it becomes opaque, having a light brownish or amber tint. It may be found in this state, and a little flattened, on dissection of the disease before the period of ulceration; and its escape when the cornea gives way, may sometimes be observed.

In the advanced stage of the affection, the contents of the orbit, and the projecting fungus, constitute a mass of morbid substance, in which we can trace little or nothing of the normal structures. The sclerotica can still be detected; some remains of muscle may be discovered; the optic nerve may be distinguishable, or lost in the morbid structure.

The diseased production itself, as in the analogous affection of other parts, approaches in color and consistence to the substance of the brain. It is whitish, yellowish, or reddish; firmer on the exterior, and softer, even to the consistence of cream, internally. Portions thus differing in consistence may be found in various parts of the mass. A soft creamy matter may be squeezed or scraped from the cut surface of the firmer part. Mr. Wardrop observes, that "like brain, it becomes a soft pulp when exposed for a short time to the open air, mixes readily with cold water, and dissolves in it, and it becomes firmer and harder when boiled, or when immersed in alcohol or acids. When the softer parts are washed away in water, or when the mass is forcibly compressed, the more firm and solid parts remain. These consist of a filamentous substance, resembling cellular membrane, which varies in its quantity, and in the closeness of its texture." (*Lib. cit.*, pp. 16, 17.)

The optic nerve exhibits various changes in size, color, and consistence, being generally softened, and even pulpy; it may be enlarged, and confounded with the surrounding diseased mass: the neurilemma and inclosed medullary matter are confused together, and it is generally redder or yellower than natural.

The alteration in the nerve extends to the part within the cranium. Indeed, after passing the foramen opticum, it sometimes is lost in a mass of medullary disease developed within the skull, and pressing upon, or otherwise involving the neighboring portions of the basis of the brain. This internal disease may extend towards the middle of the basis cranii, and pressing upon the united optic nerves, cause blindness of the opposite eye. The thalamus nervi optici, or some contiguous part of the brain, may be diseased and pulpy, with coagula of blood intermixed.

I have seen depositions of the morbid structure in a pulpy state, of gray color, both on the exterior and interior surface of the skull, at various points, the bony texture being rough and discolored. A considerable growth of the same kind has been met with on the surface of the dura mater, covering the sphenoid bone behind the orbits. In a case mentioned by Mr. Wardrop, there appeared, on the external surface of the dura mater, two dark red-colored spots; and two spots similar to them were also observed in the corresponding portions of the pericranium. Between the tunica

arachnoides and pia mater, there were numerous white spots, scattered in a very irregular manner over almost the whole surface of the brain, which, when cut into, were found to be small bags, or abscesses, containing a viscid white fluid like cream.* VON AMMON has delineated the external appearance in the case of a child, of a year and a half old, who had fungus hæmatodes of both eyes, and has also represented the change of structure in one of the eyes as well as in the frontal bone. On both surfaces of the latter there was an extensive deposition of medullary structure, principally of red color.†

When the absorbent glands are affected, the morbid change is closely analogous to that of the original affection; the texture of the gland being gradually converted into a medullary mass of pulpy, or even creamy consistence. These secondary swellings, although similar in nature to the primary disease, do not ulcerate and throw out fungus. But the integuments have inflamed and sloughed from distension in some instances, where the swelling had reached an unusual magnitude.

Medullary depositions have sometimes been found in the viscera of the abdomen and thorax; particularly in the liver: and I have seen the diseased substance deposited on the surface of the ribs. Our information on this subject is scanty, as this important circumstance in the pathology of the disease has been hitherto strangely neglected. The examination was confined to the eye and head in all the cases recorded by Mr. WARDROP, as well as in those mentioned by Mr. TRAVERS, and in the posthumous work of Mr. SAUNDERS.

Diagnosis. Cancer and Melanosis.—When we consider the characteristic features of this formidable disease, namely, the formation of a soft adventitious production of white or yellow color, within the globe, its progress by ulceration through the front of the organ, so as to form a fungus which bleeds, ulcerates, sloughs and produces a fetid discharge, there seems no probability of its being confounded with cancer, in which there is a succession of induration and ulceration, or with melanosis, in which the morbid growth is first dark livid and subsequently black.

Age of the patient.—A further ground of distinction may be drawn from the age of the patient. Cancer and melanosis attack those in the middle period of life, or persons advanced beyond that age. Fungus hæmatodes occurs in children: it has been seen as a congenital affection, (see *ante*, p. 699;) it has commenced in a few months after birth, and has usually appeared in the first five or six years of life. I have seen it in the incipient state, in a healthy infant at the age of six months. Mr. MIDDLEMORE (*Treatise*, vol. ii. p. 387), saw it fully developed at the same age, having ruptured the cornea and projected externally. Mr. WARDROP says, that in a list of twenty-four cases, which had come to his knowledge, twenty were under twelve years of age. It may be doubted whether the disease in the four older subjects was fungus hæmatodes, because Mr. W. does not distinguish between this affection and melanosis. Thus of the seventeen cases, either related from his own observations, or quoted from others, in his observations on fungus hæmatodes, only two were above twelve years of age. In one of these cases, (case xvi.) the affection was obviously melanosis; and it is almost equally clear, that the other case (case xvii.) was of the same character. "I have never yet," says Mr. MIDDLEMORE, "seen fungus hæmatodes of the eye occur in an individual more than five years old." (*London Medical Gazette*, vol. vi. p. 880.)

* Lib. cit., p. 23; see also case ii.

† Klinische Darstellungen, pt. 1, tab. 21, fig. 11; tab. 22, figs. 1 and 2; and figs. 6 and 7.

In the posthumous work of Mr. SAUNDERS, three cases of malignant disease affecting the eyeball, in persons more or less advanced in years, are related. In an unmarried lady thirty-five years of age, disease began with loss of vision and slight dilatation of the pupil in the middle of August, 1809. On the 15th September, a tawny substance, covered with a vascular plexus, was observed behind the pupil, and the eye was extirpated on the 21st. The cavity of the globe was half filled with a morbid growth, of which the consistence and origin are not clearly described. "It seemed to be composed of a yellow-colored coagulable lymph streaked with black, and to have originated from the inner part of the sclerotica, for the choroid coat was ascertained, by dissection, to quit the sclerotica and pass on the inner side of the tumor." In this patient, who was supposed to have recovered, unpleasant symptoms subsequently occurred, and the following particulars of her state were noted on the 26th of February, 1811. "Frequent giddiness; pain of the head shooting into the left orbit, from which there is a considerable discharge; a tumor on the eyelid, several tumors in the breast, three on one side of the abdomen, and one on the other, one at the scrobiculus cordis, and another at the bend of the elbow; shortness of breath, cough, great pain in the right kidney."* The origin of the affection in the interior of the globe, its first appearance behind the pupil, its rapid growth, and the subsequent formation of secondary tumors in various situations, prove this to have been fungus hæmatodes.

In another case, which I have already quoted, (see pages 693–4,) where disease commenced at the age of seventy-one, and six years before the globe was extirpated, I consider that the disease was not fungus hæmatodes. The details of a third case, in which disease commenced at the age of sixty-six, and ended fatally at seventy-four, are too scanty to enable us to form any satisfactory conclusion respecting the exact nature of the affection. (*Lib. cit.*, p. 153.) The external appearance is shown in plate 3, which exhibits an enormous red fungous mass, with tubercular prominences and fissures projecting between the lids.

Effusion of lymph from inflammation consequent on injury.—A deep-seated yellow shining opacity, which is sometimes seen in the pupil, after the internal inflammation consequent on penetrating wounds of the globe, cannot be distinguished by its appearance from the medullary fungus in the same situation. A boy, about ten years old, came under my care at St. Bartholomew's Hospital, a year ago, in consequence of a wound in the eye received three or four days previously, for which nothing had been done. The point of a table fork, which had been thrown at him by his sister, had passed through the upper eyelid and the cornea. The eye was inflamed and painful, and the pupil was occupied by a thin grayish film, which I supposed, on the first cursory inspection, to be opacity of the lens caused by the accident. The use of leeches and other antiphlogistic measures lessened the inflammation and removed the opacity from the pupil. The inflammation, however, recurred, and soon after a bright yellow appearance was seen, which gradually extended over the whole fundus of the globe. The iris was changed in color, the pupil fixed in the middle state and clear; vision extinct. In a short time, the globe felt soft and began to shrink, and atrophy was considerably advanced, when the lens became opaque, and completely concealed the change in the back of the eye; the globe became completely atrophic.

"A young lady," says Mr. TRAVERS, "was brought to town from

* Treatise on some Practical Points, &c., pp. 147—150, 217. The appearance of the pupil before the operation, and a section of the globe after its extirpation, are represented in plate ii. figs. 3 and 4.

Northamptonshire, in whom it was so strongly marked, viz., the fawn-colored resplendent surface with red vessels arborescent upon it, that I should certainly have considered it the nascent malignant disease, but for the circumstance of its having followed a wound with a pair of fine scissors a fortnight before. The instrument had passed between the margin of the iris and the ciliary body obliquely. Deep-seated inflammation ensued, and blindness, after three days, became complete. The lens remained transparent, so as to permit the observation of the appearances described for months. At length a cataract with a constricted pupil ensued upon the chronic inflammation of the iris, and the eyeball, which had never enlarged, gradually shrunk." (*Medico-Chirurgical Transactions*, vol. xv. p. 237.)

Cases, in which a bright yellow or greenish yellow appearance has been seen in the interior of the globe after accidents, have been recorded by Messrs. Mackenzie (*Practical Treatise*, ed. 3, p. 607) and Arnott. (*London Medical Gazette*, vol. xxiv., p. 21.) In the latter instance, at the bottom of the eye, a yellow substance was observed, over the surface of which a number of the most delicate red vessels could be seen running.

The origin of the affection in a serious injury, the preceding and accompanying inflammation, the circumstances of the globe never being enlarged, and soon passing into the opposite state of atrophic diminution, will sufficiently distinguish this bright yellow discoloration which is probably caused by effusion of lymph, the consequence of inflammation, from the change in the pupil caused by fungus hæmatodes.

Effusion of pus from spontaneous internal inflammation.—Mr. Mackenzie has related a case of acute internal inflammation, proceeding to suppuration, in which the appearances were so exactly similar to those of the medullary fungus, that the operation of removing the eye was recommended. The patient, eleven years of age, was admitted at the Glasgow Eye Infirmary on September 27, 1832, with an inflammation of the eye, which had existed ten days. Four days before its commencement he had been exposed to a storm of thunder and lightning, and much frightened, being attacked immediately afterwards with pain in the right side of the head. The conjunctiva and sclerotica were injected, the cornea hazy, the pupil dilated and fixed, the iris changed from bluish-gray to yellowish-brown, the anterior chamber enlarged; vision extinct; a tawny appearance in the fundus of the eye, exactly similar to that in the incipient stage of medullary fungus. Mr. Mackenzie and his colleagues recommended extirpation of the eye, to which the mother would not consent; calomel and opium were administered. On November 10, the external redness had increased; the eyeball was enlarged; the lens projected against the cornea, and there was a bulging towards the internal canthus. The eyeball continued to enlarge, so that the lids could not be brought together; the prominent part gave way on December 31, and a quantity of thick purulent matter was discharged. The eye subsequently became atrophic.

In acute internal inflammation with suppuration, the inflammatory symptoms are violent from the first. In fungus hæmatodes, the change of color in the pupil is unattended with vascular disturbance or pain for weeks or months. When at last the globe suffers from distension, the redness and other inflammatory symptoms are comparatively mild.

Change of structure in the vitreous humor.—A singular case of such change, in which the appearance in the pupil could not be distinguished from that of fungus hæmatodes, is mentioned in chap. xix. sect. 4, p. 486.

Yellow appearance in the pupil of unknown seat and nature.—In other cases, where the nature and seat of the affection have not been ascertained, a brilliant discoloration has been seen in the back of the globe, and the disease has been considered fungus hæmatodes. The affection after some time has become stationary; the eye has not inflamed or enlarged as in fungus hæmatodes, nor has the crystalline become opaque or been protruded; on the contrary, atrophy has taken place. Examples of this kind came under my observation at the London Ophthalmic Infirmary; and Mr. Travers communicates his experience on the same subject in the following passage. "I have since seen several cases of a convex (?) and permanently dilated pupil, with a deep-seated opacity of a splendid yellow tint in children, and doubting, from the preceding history, and the child's freedom from indisposition, that such appearances indicated a malignant disease, I have abstained from operating. To my surprise, the appearances have continued stationary for years, unaccompanied with any disorder of the health. One, a child of four years old, I have very recently examined, having seen it at intervals during that period, since the first notice of the disease at the age of three months. I can discover no difference in the appearance of the eye at this time, from that which it then assumed. The bright yellow tint occupies the temporal hemisphere of the globe, supposing it were bisected in a vertical direction; the figure of the globe is slightly conoidal, the pupil much dilated, as if from pressure, not perfectly circular, and its edge apparently everted, forming a narrow white line, while small detached flakes of the pigment lie behind it next the lens. The pupil of the other eye is constricted, and closed by an opaque capsule. The child is well grown, and in perfect health." (*Lib. cit.*, pp. 203, 204.)

On another occasion (*Medico-Chirurgical Transactions*, vol. xv. pp. 235, 336), Mr. Travers observes, in reference to the same subject, that "the peculiar metallo-lustrous or tapetum-like appearance of the fundus of the eye is not diagnostic: this is a fact highly important to be known. I have seen several cases, in which that appearance was stationary, and the eyeball dwindled, which might therefore fairly be presumed not to have been instances of malignant disease. It so happened, however, that long alterative courses of mercury, or protracted salivations, had been used in these cases, and the fact was consequently open to another explanation, viz., that they were examples of malignant disease, which had been arrested by this treatment. That the appearance I allude to is very analogous to that of the medullary tumor, will be inferred, when I inform the society that, (in the case of a lady who, several years since, recovered with the loss of sight, but is still in perfect health,) at a consultation, including some eminent members of the profession, the extirpation of the organ was over-ruled by one dissentient, although I had sat down to perform it on two several occasions."

Von Ammon has represented, in several figures, the successive stages of a disease in the eyeball, bearing all the characters of fungus hæmatodes strongly marked. After a certain time the vascularity abated, and the enlargement began to subside. The globe gradually shrunk, and was in a state of complete atrophy at the end of six years. (*Klinische Darstellungen*, pt. i. tab. 21, figs. 1—10.)

We cannot establish the diagnosis between such cases as those now described, and true fungus hæmatodes in its early stage; though we cannot but believe that they are essentially different. The stationary condition of the former, with the absence of enlargement and inflammation of the globe, will sufficiently distinguish them from the malignant disease in the second period.

The opaque substance growing in the situation of the vitreous humor in

the medullary disease, presents an appearance so totally different from the simple discoloration of the very back of the globe in the amaurotic cat's eye, and from the slight semi-transparent greenish and grayish appearance behind the pupil in glaucoma, which is lost sight of in looking at the eye laterally, that the disorders could not be confounded, even if the ages at which they respectively occur did not sufficiently distinguish them.

The color and situation of the opacity distinguish cataract from fungus hæmatodes. When opacity of the lens supervenes on the latter affection, the nature of the case is clearly pointed out by the preceding development of the fungous growth behind the lens, by the protrusion of the latter, with the iris, against the cornea, by the concomitant inflammation, and by the dull yellowish or amber tint of the part, which forms a strong contrast to the pure white of simple cataract in children.

Treatment.—This disease has been generally considered as intractable as cancer, and equally, or rather more, destructive. External and internal remedies may relieve particular symptoms and palliate suffering, but they have little effect on the progress of the disorder, which proceeds usually to the destruction of the organ, and ultimately of life itself.

The practical question of principal importance is, whether extirpation of the globe is advisable; and if so, at what period it ought to be undertaken. Our present experience is very discouraging, and leads to the inference that the operation, even in an early stage, is unavailing.

Mr. Wardrop extirpated the globe in an infant twenty-seven months old, in whom the disease had begun at the age of twenty months, and had not, at the time of operating, made its way through the front of the eye. The optic nerve was surrounded by a mass of disease, which was divided with the nerve in the operation: the part left behind could be felt passing into the foramen opticum. The child died in twenty-five days with symptoms of diseased brain, and reproduction of disease in the orbit; the sight of the opposite eye having become imperfect a few days before death. Small deposits of soft matter were found on both surfaces of the cranium, and under the arachnoid coat. From the diseased mass filling the orbit, the optic nerve proceeded through the optic foramen, and then was lost in a medullary tumor as large as a hen's egg, extending into the brain towards the thalamus nervi optici of the affected side, from which it was separated by a cavity containing black blood.*

"In all those cases," says Mr. Wardrop, "in which I have removed the eyeball, and in those, the history of which I have been able to learn, where the operation has been resorted to, it has been attended with the same unfortunate failure, excepting in one doubtful case—[an example probably of melanosis;] and even in this, as only ten months have elapsed since it was performed, we cannot speak of its effects with certainty." He adds; "but as we know of no instance of the operation being performed at a very early period of the disease, or in any case where the optic nerve was found in a healthy state, there is still room to hope for success under such circumstances. It is an experiment, at all events, which well merits trial: and were I in any case to be assured of the existence of the disease in the early stage, I would have no hesitation in urging the performance of the operation. Past experience proves the impropriety of attempting any operation, when the disease has advanced so far that the posterior chamber is filled with the diseased growth. An operation at this period has, in

* Lib. cit., case ii. pp. 35—40. The appearance of the extirpated eye (which has been already described at page 700) is represented in plate ii. fig. 1; and that of the united orbital and cranial tumours, in a figure inserted in page 40.

many instances, alleviated the patient's sufferings, but I have no hesitation in saying, that it has, also, in many cases, hastened the patient's death."*

In the following passage, Mr. TRAVERS bears a similar testimony, from his own experience, to the constant failure of the operation. "I have extirpated the eye affected with medullary cancer in several instances; but I am not acquainted with any case in which the patient, who has survived two years, has not been revisited by the disease."†

In the nineteenth volume of the *Edinburgh Medical and Surgical Journal*, Mr. WISHART has published a *case of fungus hæmatodes of the eyeball, cured by extirpation of the eye.*‡

The patient, a boy nine years old, was seen by Mr. W. on the 12th of May, 1821. The left eye was dull, and presented a general turbid appearance: the cornea was transparent, but numerous vessels passed into it over the sclerotica. The pupil was moderately dilated and fixed; its margin slightly serrated. In the posterior chamber an opacity was observed, resembling a yellow dusky membrane, lining the whole posterior part of the eyeball, and perceived more distinctly when the eye was viewed laterally. Vision was nearly extinct; lachrymation and pain were produced by exposure to light; and there was occasional shooting pain in the upper edge of the orbit. The pulse was natural and the general health good. Two months previously a blow had been received on the eye. He felt no uneasiness the same afternoon, but great pain came on the next morning, and vision was almost entirely lost. The effects of the injury were apparently removed by antiphlogistic treatment, and he returned to school. About the 10th of May the eye again became inflamed and painful: leeches were twice applied: opening medicine was administered, and afterwards a grain of calomel night and morning. 19th of May: The mouth is considerably affected. The red vessels are large and numerous, especially at the upper part of the eyeball. Pain has been experienced in the eye and orbit: there is slight effusion of fluid in the anterior chamber. 13th of June: The pupil is smaller, and its edge more irregular. The opaque substance has advanced close to the iris, which is nearly in contact with the cornea. The intolerance of light continues, but pain is gone, and the health is good. 3d July: The inflammation, intolerance of light, and pain are increased; and febrile symptoms have come on. Blood was taken by venesection and leeches, and aperients were administered. 9th of July: The inflammation is less, but the disease increases. The iris is in contact with the cornea, and the pupil completely closed by the opaque matter. The removal of the globe, which had been previously determined on, was performed this day. The recovery was rapid and favorable, and the patient continued perfectly well at the end of eighteen months. The appearance presented in a section of the globe is said to have been precisely similar to that delineated in a figure of Mr. WARDROP's work, (p. 193.) "The origin of the disease in the retina was finely and satisfactorily illustrated. The optic nerve was quite healthy. The sclerotica and choroid coats were of natural texture. The cornea was a little softer than natural, and not perfectly transparent. The lens was pushed into contact with it, and seemed smaller than natural, and flattened. The diseased mass, into which the retina had been converted, connected only to the optic nerve, floated loosely in various folds, occupying both chambers of the eye. The eyeball did not appear to be at all enlarged."

When the result of a single case seems to contradict the uniform tenor

* Lib. cit., p. 90—92.

† Medico-Chirurgical Transactions, vol. xv. p. 239.

‡ Article VII. p. 51—55.

of experience in all other instances, we naturally examine the details closely, to ascertain whether the exception is real or only apparent. If the narrative of Mr. WISHART be thus scrutinized, a doubt arises whether the disease described by him was fungus hæmatodes, and the want of a precise description of the morbid appearances leaves us in the dark on this subject. In its origin from the violent inflammation consequent on injury, and in the circumstance of the globe not having been enlarged, the case is more analogous to those instances of brilliant deep-seated discoloration following serious accidents, than to the unequivocal examples of the medullary fungus.

Professor PANIZZA has recorded a case in which the eye was removed at a very early period of the disease; he says, that the success was perfect, (see page 701.) The operation was performed in December, 1822, and his work bears the date of 1826. He gives no particulars; not even mentioning whether the child was alive when he wrote. The state of parts found on examination of this eye, was so different from what has been noticed in any other instance, that a doubt may be entertained whether the disease was fungus hæmatodes.

Our present experience warrants the conclusion, that the operation of extirpation would not be justifiable except in a very early period of the affection; and that the result of the case even then would probably be fatal.

Mr. MIDDLEMORE considers the disease to be an affection of the retina, confined, in the first instance, to that tunic, and strictly local: he therefore recommends removal of those parts only which are implicated in the mischief, as soon as the disease is detected, observing that they cannot be removed too soon. He states that "Mr. WARDROP has recommended the excision of the entire organ, as being most likely to ensure the patient's safety, on the presumption, probably, that a portion of the optic nerve ought to be removed as well as the retina; an operation so painful and so hazardous to the patient, (at that period of life, at least, when, to render it at all useful, it must be performed,) and so revolting to the feelings of friends, is not likely to be permitted; and as so extensive a removal of parts is, in many instances, unnecessary, I have thought it advisable to recommend merely a section of the cornea, (rather larger than that usually made in the operation of extraction,) and the evacuation of the humors, and the choroid and the retina; or, if the fungus be large and the cornea be small, the whole of it, (that is, the cornea,) and a portion of the surrounding sclerotica, may be taken away; an operation so little painful, and not at all dangerous, and by a skilful surgeon so easily performed, that it would require, in the majority of instances, very little rhetoric to recommend it to the majority of parents, who would at once refuse to allow the extirpation of the entire organ. It is only necessary to state to them that it will be less painful, dangerous, and disfiguring to their infant, than the continuance of the disease, to obtain generally their consent to the performance of an operation, which, at the outset of the malady, has all the advantages without the horrors of that usually had recourse to; and, if performed at a later period, does not preclude the extirpation of the eyeball, if that measure be deemed necessary."*

It remains for future experience to decide on the merits of this proposal, which had not been reduced to practice at the time of its publication, and has not, so far as I know, been tried since. One objection to it is, that in some cases of the disease the morbid growth has been found exterior to

* Observations on Fungus Hæmatodes of the Eye. London Medical Gazette, vol. vi., p. 914.

the globe, as well as within its cavity, and that the optic nerve has been diseased, even in incipient cases. Again, in operations on malignant diseases, it is an imperative rule to remove not only all the altered structures, but some of the surrounding healthy parts; unless this is satisfactorily accomplished, the patient has not a chance of safety. How can we feel satisfied on this important point in such a mode of proceeding?

The bare proposal of cutting out the eye is repugnant and almost revolting to the feelings of the surgeon and the patient's friends; and we could not think of subjecting a child to this frightful operation unless compelled by necessity, and encouraged by the certain prospect of benefit; unless fully convinced that the painful mutilation will not only remove or prevent suffering, but be effectual in preserving life. The operation is not, however, dangerous, according to my experience. On the other hand, to cut away the front of the globe, and scoop out its contents, does not appear to me so completely free from all risk of unpleasant consequences, so slight and unobjectionable a proceeding as Mr. MIDDLEMORE represents.

The strong objections to an operation in cases of fungus hæmatodes, are, the circumstance of its having failed to save life in most, if not all the instances in which it has been performed, and the spontaneous cessation of disease in many patients, in whom the eye had presented appearances not distinguishable from those of fungus hæmatodes. (See pages 706—709.) If we are not warranted in concluding that an operation is absolutely hopeless in all cases of fungus hæmatodes affecting the eyeball, we could consider it justifiable only in a very early period of the affection. Complete removal of the orbital contents seems to me the only proceeding of this kind that offers even a chance of permanent cure, while, in respect to pain and other immediate results, as well as to danger, it is not much more objectionable than the minor operation.

Mr. TRAVERS recommends a surgical proceeding in order to discover the nature of the affection in cases where that may be doubtful. Speaking of fungus hæmatodes, he says, "deeply-seated disorganizing inflammation is very liable to be mistaken for this disease. The deep transverse section of the globe from the outer to the inner canthus, so as completely to evacuate its contents, and sink the enlarged eyeball, is an efficient remedy in this case, which is one attended with great disfigurement from protrusion, excessive vascularity of the conjunctiva, and agonizing sympathetic hemicrania on the same side with the diseased eye. In the medullary cancer this proceeding is of no avail. But, if a doubt of the nature of the case exist, it should be practised. In the malignant disease the globe remains firm, and the section is followed by a small discharge of blood and black pigment, or coagula stained with it; but if a discolored fluid escapes, and the globe collapses, the disease is not malignant, and the cure is complete." (*Medico-Chirurgical Transactions*, vol. xv., p. 239.) I consider this severe proceeding altogether inapplicable. In suppuration of the globe, which I never saw in a child, and which can never be confounded with fungus hæmatodes, relief may be afforded by opening the cornea; but where can matter be confined, to require for its evacuation a section of "the cornea, iris, ciliary ring, and some extent of the sclerotica?" (*Synopsis of Diseases of the Eye*, p. 306.) The cases of deep-seated discoloration in the pupil resembling that caused by fungus hæmatodes, are not attended with excessive vascularity, protrusion, or disfigurement; while in the latter assemblage of circumstances, the deep incision which Mr. TRAVERS recommends so freely, could be neither necessary nor advantageous.

If the result of experience, and the other considerations now explained, should lead us to think the operation of extirpation unadvisable in cases of

fungus hæmatodes, we must be contented with palliative measures, or with a trial of mercury. Occasional attacks of inflammation may require leeches, lotions, fomentations, and other antiphlogistic treatment. In the stage of ulceration, narcotics, especially opium, will be required both internally and externally. For the latter purpose the liquor opii sedativus, diluted or otherwise, has appeared to me the most advantageous. I have found it completely effectual in controlling the severe pain attendant on the sloughing and ulceration of the fungous stage. For correcting the fetor, which is often very offensive, the chlorides may be used in the form of lotion, but not in immediate contact with the ulcerated surface.

Use of mercury.—As the changes behind the pupil, which belong to fungus hæmatodes, are also found in other affections not of malignant character, we conclude that the internal parts of the eye are subject to disease, which, although in our present state of knowledge not distinguishable by external appearance, are quite dissimilar in their nature. Hence we may properly make trial of such means as are found efficacious under other circumstances. Among these mercury holds the foremost rank. If the morbid appearance in the fundus of the globe be the result of common or of scrofulous inflammation, this remedy may probably put a stop to the mischief; and it is worth while to give it a fair trial, even in the fungoid disease. The milder preparations should be selected, and they should be administered in small doses so as to avoid all risk of injuring the health: the quantity may be gradually increased if the patient bears it well. With the mercurial plan we should combine a nutritious but not stimulating diet, and such other means, as the local or general symptoms may require. In the following case the disease, which was seated in the retina, and had all the characters of fungus hæmatodes, was completely arrested by this treatment.

Case.—In October, 1835, it was accidentally discovered that a boy, nearly six years old, who had always enjoyed excellent health, and who had at the time every appearance of health and strength, had lost the sight of the right eye. He had felt no uneasiness in the part, nor had any change in the appearance of the organ been observed by his parents. I saw him at this time, when the only visible alteration was a light yellow discoloration of the pupil, not very readily discovered. After the application of belladonna, a morbid growth was seen rising up in the back of the globe, with tubercular irregularity of surface, and red vessels ramifying on it. Mr. Travers, who was consulted in the case, agreed with me in thinking it an unequivocal example of fungus hæmatodes; indeed, no other opinion could be entertained. A mild mercurial course was directed, and followed up for several months. In less than a year the lens and capsule had become opaque, the eye presenting in other respects a natural appearance. He was attacked with violent pain in the head in December, 1836, the case being regarded as acute inflammation of the membranes of the brain. Free leeching, blisters, and mercurial medicines were the remedies employed, without any apparent effect for three weeks; the symptoms gradually abated, and the patient left his room at the end of six weeks. He continued well for three months, when he had influenza, and suffered severely in the head. No violent seizure occurred subsequently until the time of death, although headache was occasionally experienced. No further change took place in the eye. Mercurial powders were given occasionally until a year before death, when they were discontinued on account of his being in perfect health. A violent headache, which was experienced ten days before the fatal event, was quickly removed by an active aperient. On the day before he died he was examined by an intelligent and well-informed sur-

geon, who told his father that the eye was so little disfigured, and the health so good, that there would be no risk in sending him to school. The following day (May 30, 1840), he had a little headache after breakfast: the pain increased, and he seemed inclined to doze. The surgeon who saw him in the middle of the day found him feverish, faint, and incoherent. The bowels were freely relieved. At four o'clock the pain was very severe, particularly at the back of the neck, and the patient urgently requested that very cold water might be poured on the head. He died at five o'clock.

The left lateral ventricle contained two ounces of coagulated blood; at its lower part the cerebral substance was soft and of reddish color. In this softened part there was a firm oval tumor about an inch in length; it was a tough but thin cyst, with dark contents, like coagulated blood. The right ventricle contained blood, which seemed to have entered from the left side: and the cerebral substance was pulpy and discolored at its lower part. There was considerable effusion of blood at the basis of the brain, between the arachnoid and pia mater. The form and size of the affected eye, and the sclerotica were normal; the choroid was of reddish color. The whole retina was thickened and opaque. In its posterior portion, around the insertion of the optic nerve, there were six or eight white tubercles of cartilaginous hardness; the largest was equal in size to a radish seed. The vitreous humor was fluid; the lens and capsule opaque; the iris and uvea natural. The optic nerve was smaller from the eye to the point of junction, but not otherwise altered.

The use of mercury in these affections has been strongly recommended by Mr. Tyrrell. He details two cases of fungus hæmatodes, in an infant and in a boy three years and a half old, in which the progress of the complaint was checked, and a decided diminution of all the symptoms ensued under the gentle but long-continued use of mercury. The complaint was ultimately fatal in both cases. (Vol. ii. pp. 165 and 172.)

In two adult patients, affected with amaurosis and with a deep yellow discoloration behind the pupil, similar to that of fungus hæmatodes, the disease ceased under the action of mercury, and the eyes remained shrunk and amaurotic. (Vol. ii. p. 179 and 182.)

Mr. Tyrrell states farther that he has "known several other cases in children, in whom the disease has subsided, and the globe has become atrophized, under steady mercurial treatment, with great attention to the condition of the general health; and, in all cases, the cure has been very gradual: in very few of these cases has a full mercurial influence been established, or has the remedy even affected the mouth; for it has not been pushed, after a decided change has been perceived in the local disease; and this has generally taken place before mercurial action could be detected by the mouth." (Vol. ii. p. 185.)

A few cases are subjoined, to illustrate particularly the symptoms, progress, effects, and character of the disorder.

Case I.—*Fungus hæmatodes in an infant of one month.*—"James Taylor, one month old, a fine healthy-looking child, of robust parents, has a peculiar shining appearance of the right eye, which I noticed whilst examining the eyes, in consequence of an attack of purulent ophthalmia: on viewing it attentively, it seemed to be situated at the bottom of the eye, to occupy only a small space, and to yield an extremely brilliant appearance; the iris was sluggish in its action, and the pupil rather large: but the sclerotica was not discolored, nor was the eyeball at all altered in figure. The mother of the infant said she had had many children before, all of whom were healthy, and that her baby only wanted my advice for the running of the eyes; and certainly, judging from appearances, no child could be in

better health, (with the exception of the ophthalmia,) or in possession of a stronger constitution. I could not convince the woman of the importance of her child's disease, and the propriety of a trifling operation for its removal, and she accordingly left me under the belief that I wished to make her child the subject of some extraordinary experiment." In the course of a fortnight the child died of small-pox, and was not examined.*

As the operation alluded to is that described at page 711, consisting in a large opening in the cornea, or its entire removal with part of the sclerotica, and the subsequent scooping out of the contents of the globe, it may not be thought by every one so trifling as it seems to Mr. MIDDLEMORE. Some may deem it a serious proceeding, and one of doubtful propriety. As it has not yet been tried, its employment in any case may not improperly be called experimental. The refusal of the proposition by the parent, in the foregoing case, does not seem to me to have been altogether unreasonable.

CASE II.—*Fungus hæmatodes of the right eye, with tumors of the scalp and temple, and protrusion of the left eye. Extensive medullary deposit between the bone and dura mater at the base of the skull; disease of the ribs, liver, kidneys, and mesenteric glands.*—"WILLIAM FOREMAN, six months old, has several small slightly elastic tumors beneath the scalp, unattended with cutaneous discoloration; considerable enlargement at the front and upper part of each temple, and protrusion of each eyeball. The child is generally drowsy, and becomes quite comatose when the temporal tumours are compressed. On examining the eyes, that on the left side appeared healthy, although evidently pushed forwards by some substance behind it; the pupil of the right eye was exceedingly large, the iris inactive, and the crystalline lens slightly opaque, and pressed against the neural [concave] surface of the cornea by a yellow shining substance, of a rugged, uneven appearance; the sclerotica was generally of a dark-brown color, and irregularly enlarged; the cornea attenuated, and so extended as to appear twice the size of that in the opposite organ. The mother says that her former children were quite healthy, and that the patient in question was also a fine strong child for many weeks after its birth; she does not remember that the infant has received any blow on the eye, but had remarked a peculiarity of appearance, as if something bright was in the eye, (occasioned, as she thought, by the sun,) before it enlarged, and long before the appearance of the swellings about the head: she further stated, that when four months old, it had a fit in the night, and since that time has been getting gradually more drowsy, the eyes have been protruding, and the tumors of the scalp have been increasing in size, being prior to that period so small as almost to escape notice. In a few days the attenuated cornea gave way, allowing the evacuation of the lens, (which was slightly diminished in size, and somewhat opaque,) and the protrusion of a soft red fungus, which occasionally bled. Although the patient's sufferings were by this means slightly relieved, the irritation and discharge, joined to the occasional hemorrhage, quickly exhausted its vital energies."

After death, nodules of medullary structure, somewhat firmer than brain, white and homogeneous throughout, were found, connected by cellular membrane to the pericranium. "At the back of the orbit on each side, and covered by, or rather external to, the dura mater, was a reddish medullary mass, in some places of a deep-red color, surrounded by an irregularly formed circle of a fainter appearance; the orbitar plate of the frontal bone was partially absorbed, and the remainder of it altered, as though

* Observations on Fungus Hæmatodes of the Eye, by R. MIDDLEMORE. London Medical Gazette, vol. vi. p. 878.

partaking of the same morbid character as the surrounding parts. The bulk of the tumour in each orbit was about the size of a very small orange, connected by a transverse portion of the same diseased structure, which extended backwards, still covered by the dura mater, (which was raised from the bones,) as far as the anterior clinoid processes; and on the right side to the petrous portion of the temporal bone. I could discover no trace of the optic nerve of the right side, except where it was united to the sclerotica; it was then a soft and reddish mass, at the ocular extremity of which was a similar substance, slightly altered by incipient mortification. The sclerotic coat appeared healthy, but the major part of its contents had sloughed away a few days before; indeed no part of the eyeball remained, with the exception of the ruptured and attenuated cornea, the sclerotica in many places thin and sacculated, and the medullary and partially mortified mass attached to the extremity of the optic nerve.

"The heart, lungs and pleura were healthy; many of the ribs on each side, as far as their cartilages, were red and swollen, and when cut into were found soft and pulpy, evidently approaching to the state of medullary change, which has just been described as affecting the interior of the eyeball and the bones of the orbit.

"The liver was enlarged, and converted in many places into a medullary mass of a pale red color; both kidneys had undergone the same kind of alteration, and were greatly enlarged; the mesenteric glands, although somewhat augmented in size, had not experienced much change of structure; the other viscera were moderately healthy." (*Mr. Middlemore*, lib. cit., 879.)

Case III.—*Fungus hæmatodes in the left eye in a child three years old. Extirpation of the eye and return of disease—the united portion of the optic nerves converted into a medullary tumor.*—A female child, three years old, was said to have received a blow on the eye a fortnight before Mr. Wardrop saw her; but the eye had previously appeared sore and painful. "On examining the eye," says Mr. Wardrop, "it was slightly inflamed, and had the peculiar expression of a blind eye. But what appeared remarkable was, that the pupil was much dilated, and that behind it, and at the very bottom of the posterior chamber, there was a tawny, yellow-colored, flaky-looking mass, the surface of which was unequal, and formed into folds, and a large blood-vessel, which I supposed to be the central artery of the retina, was seen running across the pupil. The anterior chamber had lost its natural transparency, apparently from the aqueous humor being slightly tinged with blood." The eye was inflamed and painful. At the end of eight months, the new growth in the eye had moved forwards, so as to be on the same plane with the iris; it appeared like a layer of lymph. The eyeball was irregularly swollen, the sclerotic dark-blue, and the pupil excessively dilated. In five or six months more, the globe was so swelled that the eyelid could not cover it; the boundary between the cornea and sclerotica was no longer visible; a small spot of purulent matter was observed behind the cornea, which ulcerated, and in a few days a small tumor rose out from the ulceration, which bled freely. The globe was now extirpated.

The whole anterior chamber was destroyed, and occupied by a soft fungous mass, having no defined structure. The optic nerve was enlarged, firmer and darker than usual, and showed no distinction between neurilemma and medullary fibres. The sclerotica was unaltered, and separated readily from the choroid; the latter was unusually red, and could not be separated from the retina; it adhered firmly to a solid substance, on the surface of which nothing like nervous expansion could be detected. On making a

vertical section of the globe, the posterior chamber was found to be completely filled with a solid mass, having the general appearance of brain. Some parts were pulpy, and easily washed away in water, leaving behind a filamentous substance, like loose cellular membrane. On tearing the mass, some parts were much harder and firmer than others, and at one point there were many gritty particles. The portion of the tumor occupying the posterior chamber had very much the character of medullary matter; but the anterior portion forming the external fungus, was as soft as jelly.

The case went on favorably; but in six weeks, the lids began to be elevated, and pain occurred in the orbit. The swelling gradually increased, produced by a morbid growth in the cavity, which soon projected beyond the palpebræ. A glandular swelling now appeared on the cheek, in front of the ear, and two smaller ones under the lower jaw. These swellings, and the orbital tumor gradually increased, the general health failed, and death ensued about six months after the operation, having been preceded by a state of stupor.

The lateral ventricles contained between four and five ounces of transparent colorless fluid. The optic thalami were natural. At the union of the optic nerves in front of the sella Turcica, a tumor was formed as large as a chestnut. It was nearly globular, more yellow than common medullary substance, a little unequal, but smooth. On removing a delicate transparent membrane, which surrounded the tumor, it was found to consist of a white pulpy matter. It soon became softer on exposure to air, and was readily dissolved in water. Nothing resembling nerve could be found in it; although the optic nerves were seen entering it at one extremity, and passing out at the other, to go into the foramina optica. Where the nerve of the left side had been divided, in removing the brain, a similar matter issued from the divided extremity. The contents of the orbit were a mass of diseased structure containing portions of blood and round masses of soft matter like that of the tumor in the sella Turcica. The glandular swelling contained pulpy matter exactly similar to that of the tumor within the skull.*

Case IV.—*Fungus hæmatodes of the eye in an infant; operations of extirpation; relapse of disease and death; various morbid changes in the brain and membranes.*—In this case, which was that of a child twenty months old, the progress and symptoms nearly resembled those of Case III. There was the same brown or yellowish color observed in the bottom of the posterior chamber, with great dilatation of the pupil. The disease had existed seven months before the globe underwent change of figure. At last, however, it enlarged so that the eyelids could hardly cover it; the conjunctiva became inflamed, and the opaque body approached very close to the cornea, having the same deep yellow tinge as when it was first observed. At this time the operation was performed. In removing the ball a firm mass was cut through adhering to the optic nerve; and a continuation of it could be felt with the finger passing through the optic foramen. The dissection of the eyeball is described at page 701.

In ten days violent convulsions occurred, but did not return. A few days after, the formation of a tumor in the orbit was apparent. Twenty-five days after the operation, death ensued, having been preceded by symptoms of violent cerebral disorder. Some days before death, the vision of the left or sound eye became indistinct. On the external surface of the cranium, there were several circular white spots, and two of deep red with

* Mr. Wardrop's Observations on Fungus Hæmatodes, pp. 30—35. Plate i. fig. 2, and plate ii. fig 3.

the bone rough, the pericranium thickened and easily separable. In the dura mater and arachnoid there were morbid depositions, described at pages 704–5. On removing some of the cerebral substance contiguous to the thalamus of the right optic nerve, a cavity was brought into view containing a considerable quantity of black blood, and a tumor could be felt in this cavity, composed of a firm substance, about the bulk of a hen's egg, the upper surface of which formed the bottom of the cavity. As this tumor was firmly connected to that in the orbits, the parts were removed in one mass, and then divided by a perpendicular section. The cerebral and orbital tumors were connected by the optic nerve. The posterior part of the former was soft, and resembled common brain, but the rest consisted of a reddish vascular mass of firm consistence, very much like liver in appearance. Nothing like nerve could be distinguished in any part of the mass, until it approached the optic foramen, at which point there was an indistinct appearance of nervous structure. The portion of nerve, contained in the bony canal, seemed to have been prevented from enlarging by the confinement of the bone. The tumor in the orbit resembled the firmer portion of the other.*

Case V.—*Fungus hæmatodes of the left eye; secondary disease of the brain, ribs, and liver.*—A boy, six or seven years of age, was under my care at the London Ophthalmic Infirmary for an affection of the left eye, attended with a bright yellow appearance behind the iris, dilated and fixed pupil, loss of vision, and intolerance of light. After some time the crystalline lens lost its transparency, and the yellow growth was concealed; the vessels of the conjunctiva and sclerotica became turgid. The globe soon enlarged and distended the lids; the cornea then ulcerated and gave issue to a bleeding fungus, which increased rapidly and soon projected between the eyelids. Partial sloughings occurred with copious discharge of fetid ichor. In the early stage there was little suffering; severe pain was experienced, with irritability and impaired health, before the cornea gave way; and these symptoms were much aggravated in the ulcerative stage, when ease could only be procured by covering the fungous growth with a lotion of the liquor opii sedativus. The pain was completely controlled by this remedy, and regularly recurred within a certain time, if the application was not renewed. Febrile symptoms with delirium came on three weeks before death, and it was found that the child could not see with the right eye. The cerebral disturbance increased, and death occurred at last rather suddenly. The fatal termination took place in a few weeks after the appearance of the fungus.

The arachnoid and pia mater were somewhat thickened by serous infiltration; the substance of the brain was soft; and the lateral ventricles contained more than four ounces of fluid.

The fungus and the orbital contents formed one mass of medullary structure, in which nothing could be seen of the normal parts except a trace of one or two muscles, the sclerotica, and the optic nerve. The latter was enlarged and converted into medullary texture. The enlargement increased as it proceeded towards the thalamus. The thalami, corpora striata, pons Varolii, and adjacent parts, were so softened by medullary degeneration, that no detailed description of them can be given. The right optic nerve was not diseased; it was quite distinct from the left. The membranes at the basis of the brain were inflamed, with partial purulent infiltration.

* Wardrop, lib. cit., pp. 35—40. Plate ii. fig. 1. The cerebral and orbital tumors are represented in a small engraving inserted in page 40.

The absorbent glands, in the course of the internal mammary vessels, on both sides, were enlarged and converted into medullary texture.

The pleura lining the fourth, fifth, and sixth true ribs on the right side was thickened, highly vascular, and raised into a small swelling, which was found to consist of a reddish gray soft medullary deposit. This growth, arising from the substance of the rib, which was much diminished, had made its way through the periosteum. The interior of the other ribs was unnaturally red. The liver was of a pale yellow color; the other viscera were healthy.*

Case VI.—*Fungus hæmatodes of the right eye, with extensive disease of the brain.*—A boy, born of unhealthy parents, (the father being advanced in years with unsound viscera, and occasionally suffering from fever; the mother scrofulous and cachectic,) was slender, but reached the age of six without much illness. In the summer of 1818 he had considerable external ophthalmia with headache. Weakness of sight, redness of the conjunctiva, and dilatation of the pupil remained in the right eye after this attack. The headache increased, his strength diminished, and he passed the winter with gradual loss of flesh, diminution of sight in the right eye, and dilatation of the pupil, behind which an opacity was observed. The motions of the globe became impaired, and squinting took place. A surgeon, who saw him in the spring, pronounced the case to be cataract. Pain in the head was still severe; vision became more imperfect, and was entirely lost in August. Imperfection of sight began to be observed in the left eye, which appeared quite healthy; this affection increased, and sight was lost by Christmas. The right eye now began to enlarge and project; it became knotted on the surface, and the cornea was rendered opaque, so as to conceal the progress of the internal changes. Feverish symptoms came on, with further loss of strength; the boy gradually became taciturn, stupid, and sleepy, and represented, when questioned on the subject, that his pain was seated in the head, not in the eye. The latter in the mean time enlarged, and the palpebræ became everted by the swelling of the conjunctiva. Early in February, the cornea, which had been prominent and opaque, gave way, with a copious discharge of bloody fluid and temporary relief: a fungous substance then issued from the opening, and continued to yield an ichorous discharge. He was received into the hospital of Pavia in March, 1820, that is, about a year and a half after the beginning of the complaint. At this time, there projected between the lids a tumor equal in size to a large nut, deep red, with one or two black points in the middle, which was fissured, and poured out a sanious ichor. It was soft to the touch, and frequently bled; it appeared to belong to the conjunctiva rather than to the globe of the eye. The other eye was perfectly blind, although apparently healthy; the boy was deaf and deprived of taste, taking indifferently sweet or the bitterest fluids; he had also lost the power of articulation; for he merely uttered cries in the first three days after he came to the hospital, then fell into a state of coma, which lasted till his death on the 29th of March.

There were no external glandular tumors. The contents of the thorax and abdomen were healthy, excepting the mesenteric glands, which were enlarged to four or six times their natural size, and might have been truly called strumous, both from their consistence and the atheromatous substance which they contained.

The bones of the cranium were very thin, particularly at the coronal

* The morbid parts mentioned in this case, that is, the contents of the orbit, the diseased brain, and the swelled ribs, are preserved in Mr. Langstaff's museum.

suture. The membranes, and the brain viewed externally, presented the normal appearance, excepting an extraordinary volume transversely in the situation of the sella Turcica. The ventricles contained between four and five ounces of bloody serum. A large adventitious growth was developed in the middle and anterior part of the brain, under the ventricles. Its superior surface projected into those cavities, forming a considerable tumor on each side between the corpus striatum and thalamus nervi optici, pushing the fornix and septum lucidum upwards, and separating the optic thalami from each other, so that they were half an inch apart at the point where they are naturally in contact. The morbid growth occupied below a large part of the anterior cerebral lobes, the union of the optic nerves, the inferior surface of the corpus callosum and third ventricle, a part of the right middle lobe, and the interval between the crura cerebri. Its color differed in different parts; it was generally whitish, particularly between the optic thalami, where it presented small roundish elevations, in some parts yellowish, and in others red. Its consistence was less firm than that of the brain, particularly at the basis of the right corpus striatum, where it gave way when touched with the finger, giving issue to some thin fluid with portions of soft cerebral matter. On a section it was found to be composed of an inorganic (?) matter, marbled with red and white. It seemed to be a fungous degeneration of the medullary and cineritious substance of the basis of the corpora striata, of the inferior surface of the third ventricle, and of the parts near the optic thalami. The right optic nerve, enveloped in the diseased portion of the middle cerebral lobe, was enlarged, red, and very soft: the left was quite natural. The united portion was expanded to twice its ordinary breadth, changed into a soft reddish substance, and firmly adherent to the dura mater. The right optic nerve presented within the orbit an enlargement of oval form equal in size to a small walnut. It consisted of a reddish substance, without any trace of nervous fibres, soft and pultaceous in the centre, firmer at the circumference, and covered by the usual fibrous sheath. The left nerve had a similar enlargement. On dividing it, the nerve was found in the centre, of natural size and color, while the tumor consisted of a soft caseous matter deposited between the fibrous sheath and the surface of the nervous filaments. The left eye was sound; the right enlarged, changed in structure, ulcerated, and pushed forwards by morbid deposition in the cellular substance of the orbit. On a section of the eye, its cavity was found filled with a very soft, whitish, and reddish substance, which probably consisted of the retina changed in structure; for no trace of that membrane could be discovered, although the sclerotica and choroid could be clearly made out; and the morbid growth was continuous with the anterior extremity of the optic nerve. The nerves of the third pair, pressed upon by the tumor, presented, each of them, a small oval enlargement near their origin.*

Malignant growths of medullary structure may occur in the orbit as distinct tumors. Such cases are related in Chapter XXV. on diseases of the orbit.

SECTION IV.—MELANOSIS OF THE EYE.

In this disease a soft adventitious production is developed within the globe which it distends and enlarges; it then makes its way outwards by gradual

* Annotazioni Anatomico-Chirurgiche sul Fungo midollare dell' Occhio, e sulla depressione della Cateratta di B. Panizza; Pavia, 1821, pp 8—19. The various changes in the brain and the optic nerves are represented in three plates.

absorption of the tunics, and presents a dark livid or black fungous mass, which ulcerates, sloughs, and bleeds. The affection is particularly characterized by the dark livid color of the new formation in its earliest period, and by its deep sooty blackness in the fungous stage; hence its name of *melanosis* (from μελας, gen. μελανος, black).

The occurrence of the affection is often ascribed to injury; but it may appear independently of any external cause; and we are quite unable to assign the circumstances which impress on the disease its peculiar character.

It begins with inflammation of the eye and pain in the head; amaurosis comes on. The globe begins to swell, and the sclerotica, as far as can be judged through the plexus of distended vessels covering it, assumes a dark livid cast. The lens loses its transparency, and, together with the iris, is pushed forwards against the cornea, the latter becoming dull. The enlargement of the globe increases, and deep livid tubercles show themselves on its circumference at various points.* The morbid mass, in which all appearance of the normal structures is now lost, is deep livid, or black throughout, distending the lids, or passing between them. The ulcerative or sloughing processes now begin, and a thin dark-colored ichor, or thick black fluid, as if produced by dissolution of the texture, is discharged abundantly. Masses of the growth are separated at intervals by sloughing; great pain in the eye and head, and constitutional irritation accompanying the process; symptoms of cerebral affection frequently occur, and the patient dies comatose or insensible.

The absorbent glands have not been affected in the cases which I have seen.

When an eye, which has been thus disorganized, is examined, we find the globe, with other contents of the orbit, converted into a morbid mass, which in texture and consistence is analogous to the medullary growths. Some part may even have the grayish color of fungus hæmatodes. But it is principally, if not wholly, of the deepest sooty black; at all events, the anterior fungous portion is of this color, though the posterior or deeper-seated part is lighter. The tumor imparts a black stain to the finger, or to white paper; it breaks down readily under pressure, and communicates to water a dark turbid discoloration, like that of Indian ink, after which the substance presents a loose fibrous texture of brownish hue.

The optic nerve is sometimes discolored in an early period of the affection, before the figure of the globe is changed. Its substance, as exposed in a vertical section, is seen of a blackish gray, like that of the morbid growth within the globe, in the first figure of Mr. Travers' fourth plate.

When the orbital contents have undergone the change of structure just described, the disease spreads through the foramen opticum into the skull, and leads either to the formation of a melanoid tumor under the anterior lobes of the brain, or to the production of similar growths in the interior of the organ. At the same time the disease shows itself in various other parts of the body, such as the contents of the thorax and abdomen, the bones and skin. These secondary affections may appear as tubercular masses, more or less firm in consistence, as depositions of black substance in a nearly fluid state, or as infiltrations of the texture of an organ with the same matter.

I have not seen melanosis before the age of thirty; it usually occurs at

* The appearances of the disease, in its earliest stages, are represented by Mr. Travers, in the first, third, fourth, fifth, and sixth figures of his fourth plate.

Professor Von Ammon has devoted to this subject a plate (pl. 23), containing several figures, which represent the commencement and progress of the disease, with sections of melanotic eyes. Klinische Darstellungen, pt. i.

or after the middle period of life. Its progress is more rapid than that of scirrhus; it may go through its whole course in twelve or eighteen months.

As melanosis agrees with fungus hæmatodes and cancer in pursuing its destructive progress in spite of our treatment, whether internal or external, the only questions are, whether the diseased parts may be removed with a reasonable chance of permanent cure; whether life can be prolonged by the operation; at what period it may be performed with the greatest advantage; and under what circumstances it would be hopeless. There is every reason to believe that the extirpation of the disease has been permanently successful in many instances; hence the prognosis of operations is by no means so unfavorable in melanosis of the eye, as in fungus hæmatodes. The earlier it is performed, the better is the patient's chance: the most favorable time is before the coats of the eye have given way, when the disease, being confined to the organ, admits of entire removal. When a sloughing and ulcerating fungus has projected externally, there is great fear that the optic nerve may have become diseased, that morbid changes may have taken place within the skull, or in some internal organ, or that disease may recur in the orbit. As we cannot be secure against these various sources of risk, we should only undertake the operation under a doubtful prognosis. In some instances, patients have died soon after the operation, apparently from the existence of secondary disease in the liver; in other cases death has ensued after a longer period from melanosis of the brain.

Case I.—Warren, a native of Ireland, rather more than thirty years of age, came under my care at St. Bartholomew's Hospital in May, 1825. Although he stated that the eye had been diseased for nearly two years, the morbid structure had not yet shown itself externally. The globe was somewhat enlarged; this circumstance being distinctly observable when the two eyes were compared, with the eyelids closed. An opaque lens of muddy brownish hue was pushed into the pupil, and closely squeezed, together with the iris, against the cornea, which was dull. A dark discoloration was obscurely perceptible on the surface of the globe, at some distance behind the cornea: it was completely covered by a dense arrangement of large vessels, apparently filled with venous blood.* Although the form of the globe was not altered, and its size but little increased, and although the morbid structure could not be actually seen, I could only refer the appearances just enumerated to the development of melanoid disease within the globe. The dark discoloration behind the cornea, and the plexus of large turgid livid vessels covering it, were appearances that I had not before seen, and indicated, as I thought, organic disease in the eye; while the state and situation of the lens and iris showed the existence of some distending and protruding cause in the back of the globe. The patient readily assented to my proposal of removing the eye, which was performed in the usual manner. The progress of the case after the operation was favorable, and the patient was soon able to leave the hospital. I saw him in June, 1826, when the contents of the orbit were sound, and the general health excellent.

A vertical section was made of the eye, which is preserved in the museum of St. Bartholomew's Hospital. The sclerotica presents its normal appearance, except that it is a little prominent at two or three points, and that it has undergone absorption in one situation, not far from the optic nerve, so as to allow a small knotty protrusion of the internal growth, as

* The first figure in the plate of Professor Von Ammon before quoted, represents tolerably well the appearances exhibited in the eye of this patient, except that it does not sufficiently portray the close arrangement of large venous vessels which covered the dark protuberant portions of the sclerotica.

large as a horse-bean. The cornea is natural; the lens and iris are in contact with it. The cavity of the globe behind the latter is filled with a tolerably firm adventitious growth, the section of which exhibits a somewhat lobulated arrangement: it is generally black, but one or two points are of a dusky gray. This melanoid deposit, which distends the sclerotica, holds the place of the textures naturally contained within that tunic. An imperfect remnant of the choroid is discerned on its surface; but there is no trace of retina or vitreous humor. The optic nerve was sound at the part where it had been cut through.

Extirpation of the eye, on account of melanosis in a rather more advanced stage, was performed by Mr. Tyrrell at the London Ophthalmic Infirmary, in the year 1825. The patient recovered favorably from the operation, and was in good health in the country at the distance of a year from her convalescence.

Case II.—*Melanosis of the eye; operation; death from disease of the liver.*—In 1825, I removed, in St. Bartholomew's Hospital, the eye of a patient sixty-five years of age, in whom the organ had become enlarged, and was completely disorganized by melanosis, so as to present a livid, and black mass, with projecting inequalities and partial ulceration. The patient's countenance was sallow and unhealthy, like that of a free liver. The disease had existed about twelve months at the time of the operation, which was performed at his own request. He went on well for ten days, when his strength began to fail, without any obvious cause, and he gradually sunk.

The sclerotica and the optic nerve were the only parts of which any trace could be observed in the extirpated mass. The latter consisted of a dull grayish texture approaching to the medullary character, with a slightly marked lobular arrangement, surrounding and compressing the remains of the sclerotica. This grayish and tolerably firm substance was gradually changed towards the front into a softer deep black melanoid texture, which composed the anterior tubera and fungus. At some points a slight infiltration of the black matter is observed in the morbid mass. The cavity of the sclerotica is filled with melanoid deposit. The optic nerve on the operated side was diminished in size as far as the commissure, behind which both nerves were natural. There was no disease in the brain or membranes. The liver was enlarged to at least twice its ordinary size, and diseased throughout, being filled with adventitious deposits, varying in size from that of a pea to a large orange. In texture and consistence they resembled the depositions of fungus hæmatodes. Some were white or reddish, some of the deepest black, and others presented all the various intermediate shades.

No disease was discovered in any other part. The eye, a portion of the basis cerebri, and specimens of the liver, are preserved in the museum of St. Bartholomew's Hospital.

Case III.—*Melanosis of the eye ending fatally; melanoid tumor within the skull; disease of the liver.*—A corpulent woman, forty-five years of age, came under my care at the London Ophthalmic Infirmary, for melanosis of the eye, by which the organ had become enlarged and disfigured by projecting black tubera. The globe was movable in the socket, and I proposed extirpation, to which she would not consent. At the end of some weeks, when she was willing to undergo the operation, I deemed it unadvisable from the great increase of bulk in the disease. The globe was now more than half the size of my fist, distending the palpebræ enormously, and projecting between them. It had ulcerated, and a thick black fluid flowed from the part. The general health was not much disturbed

until a few weeks before death, when symptoms of cerebral disease came on, and the patient died comatose about eighteen months from the commencement of the complaint.

The globe and other orbital contents were converted into a uniform soft mass of sooty blackness, from which a thick fluid could be scraped or squeezed out, similar to that which had flowed from the fungus during life. The skin or linen applied to the cut surface of the morbid growth, became soiled with an inky mark. The disease was continued by the optic nerve into the skull. The nerve itself was converted into a soft black substance, and expanded, after passing the foramen opticum, into a tumor of similar character, as large as a small orange, situated under the anterior lobe of the brain, and partially penetrating into its substance. In the liver we found two depositions of melanoid nature, one about the size of a walnut, the other that of a pea.*

Case IV.—*Melanosis of the left eye; extirpation of the globe; relapse of disease; secondary affections of the liver and other parts.*—A female, forty-one years of age, of delicate constitution and sallow complexion, found the sight of her left eye imperfect two years and a half before she came under the care of Mr. A. Burns; a milkiness was at this time observed behind the pupil. The opacity of the lens increased, and in four months the vision of that eye was lost. Two months after the eye became inflamed without any obvious reason. By the use of leeches and other means, the inflammation was lessened, but the redness and pain did not cease entirely. Six months before the operation a tumor began to form on the lower part of the sclerotica, just behind the cornea. It was as large as a musket-ball, and numerous red vessels were seen on its surface. There was hysteria with pain in the back, and severe lancinating pain in the eye, which interrupted sleep. In four months after, there was confirmed hectic, with emaciation, debility, and broken state of health: the patient had been confined to bed two months. The cyst had increased to the size of a pigeon's egg, and formed a solid fungous mass, covering the under eyelid. Towards the external angle there was a hard tumor, adhering firmly to the bone. The eyeball was extirpated, but the tumor adhering to the cheek-bone could not be completely removed, the bone itself being carious.

When the eyeball and optic nerve were divided, a thick viscid matter of dark brown color covered the knife. The tumor seemed at first sight composed of a similar dark-colored matter, which was of the consistence of thick oil paint; it soiled the fingers of a dark brown color, and dissolved readily in water, leaving the solid parts more distinct. The cornea and sclerotica were sound, but the latter had given way opposite to the malar bone so as to allow the substance within the globe to pass out and form an external tumor. The lens was opaque and amber-colored. There was no trace of the iris, or of the retina. The choroid was thickened and more vascular than in the natural state. The contents of the eyeball, and of the tumor exterior to it, consisted of pulpy substance, variously tinged in different places by the dark brown coloring matter. The medullary substance of the optic nerve was of black color, like that of the matter in the globe.

The patient, who had been greatly emaciated, regained appetite, flesh, and strength, after the operation. The orbit gradually filled up with a soft substance of dark color, which skinned over. Her health soon declined again; she experienced most severe pains in the loins, which confined her to bed; and an elastic fungus began to protrude the lower lid, and to project between

* The diseased mass which filled the orbit in this case, and the melanoid growth within the skull are preserved in Mr. Langstaff's museum.

the lids. This disease caused no uneasiness: but the pain in the back and loins was so excruciating, as to make her scream from agony. After lingering two or three months, with the tumor below the orbit increasing, and the pain of the loins not relieved, she died extremely emaciated, having become suddenly comatose twenty-four hours before death.

The tumor in the orbit proceeded from the antrum, the parietes of which had given way above and in front. The morbid growth also projected into the nostril. It presented externally small knobs of dark livid color. It was composed internally of a soft matter, of inky color, intermixed with a grayish substance and ragged fragments of bone. The floor of the orbit was elevated so as to be nearly in contact with the orbital plate of the frontal bone; the fungus was therefore exterior to the orbit. The substance of the optic nerve, from the point where it had been divided, was of black color. Within the cranium, the nerve was as large as the little finger, and black. The junction of the nerves was enlarged into a tumor, which projected into the third ventricle. The dark color was continued beyond the union, along the nerve of the same side. On the opposite side the nerve was natural in size and color, and the two were only connected by cellular shreds.

The liver contained tumors similar in structure to the contents of the eyeball, and a cyst filled with grumous purulent matter. Above the kidneys, there were considerable tumors of similar nature. The uterus was of cartilaginous density. (Mr. Wardrop, in lib. cit., pp. 74—80, and plate iii. fig. 1.)

Case V.—*Melanosis of the eye; extirpation of the organ; death from secondary affection of various parts.*—In the spring of 1822, John Henston, a shoemaker, aged fifty, labored under a severe affection of the right eye, attended with pain in the orbit and head, for which extirpation was deemed necessary. There was no return of disease or pain in the part after the operation. On the 18th of March, 1823, he was received into the Royal Infirmary of Edinburgh, with symptoms of pleurisy, for which he was bled, blistered, and purged with considerable benefit. The symptoms had disappeared on the 23d, excepting a cough, which yielded in a few days to gentle means. On the 1st of April he complained of weakness merely, for which generous diet with wine was ordered; but he died in the course of the night, without any suspicion of serious organic disease having been entertained.

In the extirpated eye, "the situation of the vitreous humor was completely occupied by a black-looking fibrous mass, pushing the choroid coat and retina into the posterior chamber. These tunics had undergone no sort of alteration, and the sclerotica was entire. The cornea had sloughed; but this was to be attributed to the general distension of the globe, and by no means to any alteration in the texture of the tunic, since it was nowhere in contact with the morbid matter lodged behind the iris. There was a considerable mass of black matter lodged posteriorly to the globe, and deep in the orbit, apparently in the fat and cellular tissue surrounding the optic nerve. When we examined the orbit after death, we observed that the disease had been reproduced in its old situation, and at the expense of the cellular tissue; for the muscles and nerves, so far as we could trace them, had undergone no alteration." There were "a number of black globular bodies lying in the cellular tissue, between the pectoral muscle and third and fourth ribs of the left side, about the size of peas, and some of them adhering to the periosteum. The substance of the rib itself was completely black, as was also the sternal third of the clavicle of the same side; but these bones were in no other way altered from their natural state. Upon opening the chest, the pleura was found studded with similar tumors, here and there insulated, but in general aggregated, so as to resemble a cluster of purple

grapes. The last-mentioned phenomenon was particularly remarkable on the right lung, along the bodies of the vertebræ on both sides, and upon the surface of the diaphragm on the left. Many of the tumors were hardly raised above the pleura, but others had long slender necks, so that they were like polypi. In color most of them were jet black, others of a deep purple, or even of a reddish hue, while a third sort seemed to contain portions of a peculiar white color, blended with black. The lungs were extensively beset with these tumors; and several of an exceedingly small size were detected under the mucous membrane of the bronchiæ. The pericardium, and the very substance of the heart were studded with melanose bodies. As the cause of the symptoms under which the patient labored during life, upwards of three pounds of fluid were found in the cavities of the pleura, and there was a thin pellicle of albuminous matter covering the surface of the lungs. In the abdomen, the liver, spleen, kidneys, omentum, and peritoneum in different places, were affected in this manner; but the tumors in the liver contained a considerable portion of white cerebriform matter. Similar tumors were found connected with the internal table of the skull, where they had formed for themselves little excavations; in the subcutaneous cellular substance of the thorax and abdomen, so as to be discernible through the integuments; and, lastly, among the fibres of the intercostal muscles." "The tumors consisted of a cyst, separated by a loose cellular tissue from the surrounding textures, and containing the peculiar black matter of the disease in different states of consistence. In some pretty large tumors the matter was nearly solid; and in others, those exceedingly small, nearly fluid. No external differences were to be observed in these two species; there was no regular gradation in size, no difference in vascularity, that could have led us to suppose they were different states of the same disease, or in different states of development. In the liver only a remarkable variety was noticed. The tumors here were as large as chestnuts, some of them white, consisting of cerebriform matter, others were pure melanose; and others again contained melanose and cerebriform matter together; but all of them had cysts tolerably distinct from the surrounding hepatic texture."*

The history and dissection of a case, in many respects analogous to the foregoing, form the subject of an interesting narrative by Mr. Fawdington, illustrated by several lithographic figures, which represent with great fidelity the characteristic appearances of the disease.

Case VI.—*Melanosis of the eye; extirpation of the globe; death from secondary affection of various textures and organs.*—The patient, Thomas Peckett, thirty years of age, a robust, healthy-looking man, was at first under the care of Mr. Wilson, surgeon to the Manchester Eye Institution, whom he consulted in January, 1824, for a violent and incessant pain in the left eye. Six months previously he had received a blow on the organ, which caused little pain and no alteration in the external appearance of the part. A fortnight after the accident a sensation of fullness with imperfection of vision was experienced, and gradually increased, the former to a most distressing degree. The vessels of the conjunctiva and sclerotica were distended, and the latter tunic seemed to be undergoing absorption, as the dark choroid was just visible towards the internal canthus. The iris was dilated and immovable, and a slate-colored opacity occupied the centre of the pupil. The symptoms were relieved by antiphlogistic means; but the pain returned, and became violent and incessant. At the end of March, the sclerotica had become very thin at the upper and inner part of the globe, and the bulging

* Cullen and Carswell on Melanosis, in the Transactions of the Medico-Chirurgical Society of Edinburgh, vol. i. pp. 271—275.

part was covered by the choroid. The opaque appearance in the pupil had now a dirty red color. Mr. Wilson removed the contents of the orbit on the 19th of April.

A section of the eyeball discovered a black pultaceous tumor, occupying more than one-half of the interior of the globe, in the situation of the vitreous humor, of which no trace could be discovered. There were two cavities filled with a brownish-red fluid, one at the side of the tumor, the other between the front of it and the lens. The choroid was entire, except at one part, where it was blended with the tumor. The sclerotica was reduced to an extreme degree of tenuity. The retina was separated from the choroid by the interposition of the disease, and gathered into a folded mass, placed in the axis of the globe, and connected anteriorly to the back of the crystalline capsule. The lens was opaque and amber-colored. The optic nerve was sound at the part where it had been divided. He recovered from the operation. In August small black tumors, about the size of a shot, appeared in the skin of the face and back, and he became affected with pain in the side, cough, and difficulty of breathing. The abdomen soon began to enlarge; melanose tubercles showed themselves on the face, scalp, and lower lid of the extirpated eye, where it threatened ulceration; blue elevations, apparently from subcutaneous melanosis, appeared all over the chest and abdomen; the abdomen became exceedingly protuberant from enlargement of the liver, and death took place in November.

The subcutaneous stratum of adipose substance was beautifully granulated with melanose matter, in small encysted masses, up to the size of a pea. The liver was four times its natural size, and filled with melanose masses of various bulk, as well as with black infiltration. On making a section through the diseased organ, several ounces of dark fluid escaped, resembling deep chocolate paint in color and consistence. This softer matter occupied the centre of the diseased masses. The peritoneum lining the parietes was covered with minute black dots; and melanose tubercles were found abundantly in the cellular tissue on the spine, in that of the various duplicatures formed by this membrane and in the omentum, around the kidneys, and on the concave surface of the diaphragm. The pancreas, spleen, and kidneys were thickly studded with black spots, some of which, especially in the pancreas, were as large as a Spanish nut; and similar depositions had taken place under the serous membrane of the stomach and intestines. The back of the sternum was superficially spotted. The cellular substance of the mediastinum and that connecting the pleura costalis to the parts which it covers, contained melanose tubercles. Groups of small black cysts with slender pedicles were scattered over the pleura costalis. Melanose matter was deposited interstitially and in spots under the pleura pulmonalis, and in tubercular masses through the lungs. Almost the whole surface of the heart was covered with black spots. The brain was not examined. No disease was observed in the nerves or blood-vessels.*

Case VII.—*Melanosis of the right eye; extirpation of the diseased organ; death at the end of three years from secondary melanoid disease of the brain.*—The right eye of a farmer, fifty-five years of age, having been diseased for ten years, and converted into a growth completely filling the bony cavity, was removed by Mr. Wardrop. No remains of any of the natural structures of the globe were recognizable, except the sclerotica, which had burst asunder, and was distended by the different portions of the tumor. This consisted of a dark brown or blackish substance, rather

* A Case of Melanosis by Th. Fawdington, London, 1826. There are eight lithographic plates representing the primary disease in the eye, and the secondary affections of the skin, liver, kidneys, intestines, pancreas, heart, and lungs.

firmer than brain, but in some parts so soft as readily to be washed away with water. The patient recovered quickly after the operation, and remained in good health about two years. He then had a fit, which left no effect but that of weakness, and on the following day he went about his farm as usual. Six months afterwards he had a second fit, which was followed by great weakness, and some difficulty of speech. In a few months he had a third fit, followed by paralysis of the right arm and loss of speech. The fits now became more frequent; the right leg was paralyzed, and the limbs of the left side, excepting the right hand, which was never affected, and which he employed in making signs till the time of his death, at the end of fifteen months from the first attack. The vessels of the meninges were distended. The substance of both hemispheres at their posterior part was unusually soft, and readily yielded to slight pressure with the finger. In the left hemisphere, on a level with the corpus callosum, a large mass presented itself of dark bloody color, having at first the appearance of coagulated blood, but found, on minute examination, to be of firm consistence, with numerous small vessels passing through its substance. This mass seemed to have no connection with the surrounding brain, which was quite natural, and formed a sort of bed for it. By immersion in water a quantity of blood was extracted, and the mass which remained was of a dark brown color, consisting of very loose cellular tissue. In the substance of the right hemisphere there were several dark-colored masses of the size of a pigeon's egg, very similar in texture to that found on the left side. The optic nerve on the right side, from its bifurcation to the orbit, was much wasted, having no medullary matter, and seemed to consist only of neurilemma. At the extremity of the nerve, where it had been divided during the extirpation of the eye, there was a hard black granular tumor of the size of a small nut. (*Lancet*, vol. xi. p. 88.) It seems that the cavities of the thorax and abdomen were not examined.

Case VIII.—*Extirpation of the eye for melanosis; relapse at the end of two years.*—Mr. Wilson, of Manchester, has shortly mentioned a case analogous to the preceding, in which relapse of the disease took place at the end of two years. He says: "Two years ago I removed the eyeball of a middle-aged man affected with melanosis; and I entertained sanguine hopes that no other organ would become affected, as such an interval had elapsed; but last week he called upon me, complaining of great general debility, loss of flesh, and mentioned that he had experienced frequent discharges per anum of a dark-colored fluid. Upon examining the orbit, from which the globe had been removed, I perceived upon the granulations a portion of black matter the size of a currant, of a pyriform shape. He said he had at times lost some blood from the orbit, but very trifling in quantity. Upon dividing the peduncle, two or three drops of dark blood, if blood it could be called, issued from the wound. The case is still under my observation, and I hope, at some future time, to be enabled to communicate it to the profession." (Mr. Fawdington, *Case of Melanosis*, p. 3.)

[The following highly interesting clinical lecture delivered by Mr. Lawrence* at St. Bartholomew's Hospital, since the publication of his work, we think proper to append to this section, as it contains the results of his later experience.]

Case I.—*Melanosis of the left eye—Extirpation of the globe at an early period—Death in three years and three quarters after the operation, from secondary disease of the liver, pancreas, ovaries, and other parts.*—Elizabeth Rute, a female of rather stout frame, and healthy appearance, who had

* Reported by Holmes Coote, Esq., in London Med. Gaz., Oct. 1845.

always enjoyed good health, was admitted into St. Barholomew's Hospital, Oct. 7, 1841, as a venereal patient, on account of superficial ulcerations and mucous tubercles of the external organs. She said that her age was 20, but she was probably two or three years older.

A few days afterwards, she called my attention to the state of her left eye, of which she had made no complaint at the time of admission. It was red, watering, and painful, and presented serious changes in the state of the iris and lens. It appeared on inquiry, that six months ago, without previous suffering, she had discovered accidentally that she was blind on that side. She experienced no inconvenience, until three months after, when pain came on in paroxysms so severe as to induce her to become outpatient at the Ophthalmic Hospital in Moorfields. She discontinued her attendance after two months, in consequence of her confinement, during which time the paroxysms were less frequent and severe.

We found the conjunctival vessels, and those of the sclerotica, slightly injected; the cornea transparent; the iris dark-colored, dull, and motionless; the pupils widely dilated; the crystalline lens of a dull dingy hue: both iris and lens were in contact with the cornea. Three small staphylomatous projections, one above and two below the middle of the globe, occupied the outer part of the sclerotica, close to the edge of the cornea. Large tortuous vessels of venous character ran over the two lower. Vision was totally lost; there was constant pain, which was occasionally very severe. The suspicion of melanosis immediately occurred to my mind. The presence of a morbid growth in the back of the globe would account satisfactorily for the changes of appearances and position in the iris, pupil, and lens, as well as for the partial absorption of the sclerotica. Leeches were applied three times to the left temple, with benefit; but the pain was not entirely removed.

As the appearances above described might be accounted for by the formation of fluid within the globe, although I did not think it probable, I punctured one of the staphylomatous projections with a grooved needle. No fluid escaped. Entertaining no further doubt respecting the nature of the complaint, I explained to the patient the necessity of the operation, to which she readily consented. The globe was extirpated on the 23d of October, the lids being separated by a free incision at the external commissure, and turned backwards, so as to expose fully the front of the orbit, and the posterior connections being divided as far back as could be accomplished conveniently.

Examination of the eye.—The globe, not unnaturally soft, was divided through the centre. There was no trace of vitreous humor; a dark and blackish mass, of soft consistence, occupied nearly the whole interior of the globe, pressing the retina, which was healthy, and formed a flattened mass, towards its inner side, and the crystalline lens, which was semitransparent, against the posterior surface of the cornea. During the examination, the diseased mass dropped out from one half of the section, leaving the inner surface of the sclerotica smooth, but slightly darkened in color. In that part of the globe which was occupied by the diseased mass there was no trace of choroid membrane, and the growth therefore filled the space between the sclerotica and the retina, which was folded into a small compass. That portion of the sclerotica towards which the retina was pressed was lined by healthy choroid. The optic nerve was healthy. The eye is preserved in the museum of the hospital.

There was but little subsequent bleeding: no vessels were tied. Four hours after, she had cold chills, and vomited several times.

24th.—Passed a restless night, but slept after taking some laudanum;

the pulse is quiet; the skin cool and moist. The lids are distended, apparently by effusion of blood into the orbit: no swelling around.

25th.—Bowels not open. Pil. hydrarg. chloridi c. jalap. gr. x. statim.

27th.—There is œdema of the face and eyelids on both sides, with slight reddish blush; skin cool; tongue clean; pulse quiet; bowels open.

28th.—The œdema and redness of the face and lids have lessened: she complains of pain in the abdomen. Pil. hyd. chloridi c. jalap. gr. x. statim. Haust. sennæ co. post sex horas.

November 4th.—She continued well to this date, when a severe attack of erysipelas came on. The face is red and swollen; there is general heat of skin, and headache; the tongue is furred; the bowels are purged. Radatur caput. Admoveantur hirudines xviii faciei. Sumat. hyd. c. cretâ, gr. iiss 6tis horis. Haust. ammon, acet. c. liq. ant. pot. tart. ℥ss ter die.

6th.—The erysipelas is spreading to the scalp.

7th.—She has been very sick; the erysipelatous redness is lessened. Omittatur liq. ant. pot. tart. Contin. haust. ammon. acet. et pilulæ.

10th.—The swelling and redness of the scalp have much lessened; skin cool; tongue cleaner; bowels less purged; pulse feeble. To leave off medicine.

12th.—Swelling and heat of the scalp have returned; tongue furred. ℞.—Haust. ammon. acet. c. liq. ant. pot. tart. ℥ss 6tis horis.

13th.—The inflammation has extended to the back of the head and the upper part of the neck.

14th.—The scalp has resumed its natural state; the neck is but slightly affected; tongue clean; pulse quiet; bowels regular.

19th.—She is convalescent, and has left her bed.

December 6th.—Discharged. She was not delirious during either attack of erysipelas; nor was she in either so depressed as to require stimuli. On the 16th of October, nine days after admission, her mouth became sore from the mercury administered for the venereal complaints: the remedy was then discontinued. The sores had healed, and the tubercles had disappeared previously to the operation.

September 6th, 1842.—She was seen in good health: there was no return of disease in the orbit. From the time of her leaving the hospital she was in a laborious situation as domestic servant, and remained well to the latter end of 1844, when she called upon me, complaining of pain and fullness in the abdomen. Suspecting that internal disease might be forming, I advised her to leave her situation, and to come into the hospital.

December 12th.—There is a small swelling on the right side of the navel, covered by healthy skin, of which the appearance is slightly altered by the dark color of the subjacent growth. There is general fullness of the abdomen in the right side and upper part. The liver is enlarged and uneven on the surface, extending below the margin of the chest. Towards the confines of the lumbar and iliac regions, there is a tumor on each side, somewhat movable, of indefinite size and extent. Pain is experienced occasionally. The several functions of the body are performed naturally, but she sleeps badly. Pil. saponis c. opio, gr. v omni nocte. Meat diet.

17th.—She complains of pain in the abdomen, and says that the pills make her feel ill. ℞.—Morphiæ acetatis, gr. ½, in haustu, omni nocte. Emp. opii abdomini.

18th.—Bowels purged. Haust. cretæ co. 6tis horis.

20th.—Bowels still purged; she is faint and exhausted. ℞.—Ammon. carb. gr. v ex. Mist. Camphoræ, 4tis horis. Cont. Mist. cretæ co.

22d.—Hyd. c. creta, gr. iiss ter die. Pulv. ipecac. co. gr. x vespere.

23d.—Bowels still purged. Enema amyli c. tinct. opii, ♏xxx. statim. Pulv. ipecac. co. gr. x vespere.

25th.—The diarrhœa is stopped, but she complains of uneasiness about the head; she is faint; pulse feeble; tongue clean. ℞.—Spir. ammon. aromat. ℥ss; tinct. opii ♏x. 4tis horis. Balneum calidum, vespere. Emplast. lyttæ parvum tempori dextro. Rep. pil. saponis c. opio gr. v omni nocte.

Jan. 7th.—Vini rubri, ℥iv quotidie.

11th.—Beef, lbij for beef tea, daily.

22d.—Vini rubri, ℥vj quotidie.

Feb. 3d.—She has return of pain in the head. Emplast. lyttæ parvum nuchæ.

4th.—The pain in the head, which comes on in paroxysms, is not relieved. Hirudines vj pone aurem utramque. Opii gr. i hâc nocte, et rep. si opus sit.

17th.—The head feels easy, but the bowels are again purged. Mist. cretæ co. 6tis horis.

18th.—She complains of renewed pain in the head. Hirudines iv. pone aurem utramque.

19th.—The application of leeches seems to aggravate the pain. ℞.—Morphiæ acetatis, gr. ½ (in haustu) omni nocte.

25th.—She is suffering considerable pain in the abdomen. Liniment. saponis ℥iij; tinct. opii ℥j ft. linimentum. Wine and meat diet continued.

March 8th.—Emp. belladonnæ abdomini.

13th.—During this time the disease has been making rapid progress. Five dark-colored subcutaneous tumors, the size of nuts, can be counted upon the chest, and in the right mamma. The abdomen, which equals in size that of a woman at the full period of utero-gestation, is distended laterally by the enormously enlarged and tuberculated liver, below which other masses may be felt. With the exception of menstruation, the different functions are properly performed. She is collected in mind, and suffers pain, either in the head or abdomen, at times only; in the intervals she is quite easy. Small blisters and mustard plasters on the abdomen afford temporary relief.

20th.—The opium was altered for hyoscyamus.

25th.—She has return of pain of severe character in the head, and especially about the right temple. Hirudines iv. tempori dextro. Rep. ext. hyos. gr. v nocte. Meat diet and wine continued.

March 26th.—Emplast. lyttæ regioni epigastricæ. The hair to be thinned.

April 22d.—Brandy ℥iv daily.

The disease advanced steadily, attended by occasional pains either in the head or abdomen, and eventually by purging of blood, at times in considerable quantity, until June 6th, when she died.

Mr. Coote has drawn up the following account of the examination after death:

There were two or three small black tumors in the scalp; the skull-cap, thicker and heavier than natural, contained in the diploë, similar deposits, each about the size of a large pea. Black matter was found about the optic foramen, in the lesser ala of the sphenoid bone, and along the inferior margin of the left orbit. The bony substance was not swelled, nor apparently altered in structure, in the situation of these deposits.

The brain was healthy; there was a small black spot lying upon the surface of the anterior cerebral lobes under the pia mater. The left optic nerve, from the orbit up to the commissure, was shrunk into a slender membranous chord, without trace of nervous matter; the state of atrophy was continued in a slighter degree along the right, or opposite optic tract, into the optic thalamus.

There were five dark-colored spherical tumors, about the size of nuts, visible through the integuments of the chest, situated chiefly about the right mamma. Three similar tumors were noticed under the integuments of the abdomen; they were loose and seated in the cellular tissue; some were firm and black, others of a brownish hue, consisting of thick fluid contained in a cyst.

Black matter was deposited in the cancellous texture of some of the left ribs; a mass of black matter the size of a musket-bullet was lodged upon the anterior surface of the dorsal vertebræ.

The lungs were healthy.

There were numerous black tumors upon the outer and inner surface, and in the muscular substance of the heart; two of considerable size projected into the cavity of the left ventricle.

The liver, enormously enlarged, 17½ lbs. in weight, occupied the greater part of the abdominal cavity; although much of the surface presented the natural color, consistence, and organization of the hepatic substance, the enlarged gland consisted principally of a morbid deposit, in larger or smaller masses, which occupied the entire thickness of the organ, and projected from the surface in rounded tubercles of various magnitude and generally of black color. In the interior the color varied from a deep black to a light yellowish-brown. The consistence varied; it was generally softish, so as to break down under the pressure of the finger. When passed over paper, linen, or the skin, a black, or brownish coloring matter was left behind; the morbid substance was contained in a kind of cyst, from which it could be turned out. The larger masses presented a kind of slight lobular arrangement on section.

The gall-bladder was healthy, and contained bile.

Upon the mucous membrane of the jejunum were seen several small black patches; larger patches were found in the fold of the mesentery, and on the peritoneal covering of the pancreas.

The pancreas was filled with numerous deep black deposits of irregular form, some as large as a musket-bullet.

Smaller deposits were found in the kidneys; two cysts resembling in size and shape the human testicle, each containing a mass of black matter, were attached to the right kidney.—The uterus was healthy.

The ovaries were greatly enlarged and converted into irregular lobulated masses, about eight inches in length, which retained no trace of natural structure; each of these masses consisted of a thin but dense cyst, filled with melanotic structure of soft consistence, and of the deepest black color. The ovaries with the uterus are preserved in the Museum of the Royal College of Surgeons of England.

Some minute black spots were seen upon the mucous membrane of the vagina, near the os tincæ.

The blood-vessels were healthy.

Under the microscope this morbid deposit was found to be composed of irregularly shaped cells, of larger size than in common medullary disease, and containing dark granules, varying in quantity according to the color of the part.

In those parts which were soft, and brownish in color, the cells had given way, and allowed the granules to escape. The granules had everywhere a kind of molecular movement.

Case II.—*Melanosis of the right eye—Extirpation of the globe—Death at the end of six months from melanotic disease within the cranium.*—Sarah Keeble, æt. 43, married, of spare habit and swarthy complexion, but of healthy family, and the mother of six healthy children,

never suffered from any illness until two years ago, when, without obvious cause, the right eye became inflamed, the lids swelled, and vision was lost. The inflammation subsided readily under proper treatment, but the sight did not return. Her friends, however, remarked that the eye had a more bright and glistening appearance than the other, and seemed the best of the two. About nine months ago, she had severe pain in the globe, which induced her to examine it in a glass, and on raising the upper lid, she discovered a black spot in the white part. This slowly increased, and projected slightly till about eight weeks since, when it grew more rapidly, pushing the eye downwards behind the lower lid. For three months after the discovery of the black spot she was free from pain, but it then occurred in paroxysms, increasing in frequency and being particularly severe at night. Yesterday (Jan. 9th) the tumor began to bleed.

Jan. 10th, 1845.—There is a dark-colored tumor, the size of a walnut, with four black tubercular prominences, protruding from the upper part of the right eye, partially covered by the upper lid, which is stretched over it, and rests in a groove on its upper surface. The portion exterior to the lids, directed outwards, is ulcerated, and bleeds freely when touched. In every other part the conjunctiva is entire, but its vessels are large and tortuous. The development of this tumor above the eye has pushed the globe downwards and outwards. When the lids are separated by voluntary effort, the palpebral aperture is entirely occupied by the morbid growth. On depressing the lower lid, the cornea is brought into view quite transparent, but pushed down to the very lowest part of the orbit. The iris is unaltered and pressed against the cornea, together with the lens, which is discolored and opaque. Vision in the opposite eye is perfect; appetite good: no disease is apparent in any other part. The history of the case, with the appearances just detailed, left no doubt that melanotic disease had formed within the eye, and had made its way through the coats at the upper part of the organ, so as to constitute the dark tumor which projected between the lids. Extirpation of the diseased organ offered the only prospect of benefit.

Jan. 11th.—The operation was performed in the usual manner. There was some trouble in separating the upper lid, which was tightly stretched over the tumor, but the globe was satisfactorily removed. The cut surface of the optic nerve presented a dark discoloration in slender streaks; as it had been cut through close to the sclerotica, it was thought advisable to take out another portion. Some discoloration was noticed in the situation of the second division. There was no bleeding of consequence; no vessels were tied; wet lint was placed over the orbit, and the patient was carried to bed.

Upon making a vertical section of the eye and tumor, it was found that a morbid growth of soft consistence, brownish in color with black portions interspersed, had proceeded from between the sclerotica and choroid in front of the optic nerve, and pushing forwards the iris, which was healthy, and the lens which was opaque, against the cornea, had made its way through the upper part of the sclerotica, just behind the ciliary ligament, and formed a tumor the size of a walnut, covered by conjunctiva. A shred of retina was discovered among some loose fibrous substance. No trace of choroid was seen, nor of vitreous humor, although the morbid growth did not fill the interior of the globe.

No unfavorable symptom occurred after the operation. The swelling of the lids subsided when suppuration was established; the wound healed, and she was discharged in perfect health on Feb. 3d. The unfavorable result of the case, however, is apparent from this portion of the brain,

which has been forwarded to us by Mr. S. Freeman, of Stowmarket, the gentleman who attended her at the time of her death, which took place in the early part of this month (July), after a few days illness. Within a week of her decease she had been able to walk a distance of fourteen miles.

The brain, as might be expected in this weather, reached us in a state not admitting minute examination; you see, however, a mass of black matter the size of a large walnut, in a kind of cyst at the base of the brain behind the orbit, pressing the left optic nerve and stretching the commissure. The carotid arteries are imbedded in its substance; the right is pervious, the left apparently obliterated at one point. The growth is partly of a grayish-brown color, and partly black, and resembles the original disease in the eye. The soft parts remaining in the bottom of the orbit were sent with the brain; the remnant of the optic nerve formed a firm mass with dark streaks in its substance, about as large as a small horse-bean. The remaining portions of the other orbital nerves were healthy.

The thorax and abdomen were not examined.

The two cases of melanosis now detailed present to your view the most striking features of the disease, as it occurs in the eye; and afford the necessary data for determining on the proper course of treatment, more particularly in regard to the important question of operation. You see the malady developed in the interior of the globe, and destroying sight; making its way through the tunics so as to constitute an external tumor, appearing in a secondary form in various other organs, and thus terminating fatally. You see the eye removed, and the patient recovering from the operation; remaining well for a shorter or longer period and apparently cured, but sinking ultimately under the reappearance of the disease in its secondary form.

The primary seat of the affection is between the sclerotica and the retina, which suffer at first merely from the pressure of the morbid growth. Where the melanotic substance is deposited, the choroid cannot be traced; but it is seen, of natural appearance, lining the sclerotica in the part free from the disease.

Although no trace of melanotic degeneration had been observed in the retina, in either of these cases, the optic nerve was discolored in the second; and the dark tumor within the cranium was probably connected with the continuation of the optic nerve. In a case, which I examined after death many years ago, where the contents of the orbit were converted into a uniform mass of sooty blackness, the same structure was continued through the foramen opticum, and connected with a large deposit of similar color, at the basis of the brain. The preparation is in the Museum of the Royal College of Surgeons.

The extirpation of the globe in fungus hæmatodes has been long abandoned in London, because the operation has been followed speedily and invariably by the return of disease: it is, at least, doubtful, whether there is a single well-established exception to this statement. The results of the operation have been more favorable in cases of melanosis; and it has been considered that, if the morbid growth has not made its way through the coats of the eye, the operation may be performed with the prospect of perfect success. The two cases now reported show that patients may survive the operation some months, or even some years. We learn, however, from the first case, that a long period must elapse before a patient can be pronounced completely cured, if we understand by cure security from the reappearance of melanosis in any of its forms. Here the eye was removed at an early period, under the most favorable circumstances; the patient

continued well for more than three years, and then died from secondary manifestations of disease obviously dependent on the original affection.

Dr. Argyll Robertson, of Edinburgh, has published in the *Northern Journal of Medicine*, (November, 1844,) an interesting collection of cases, in which the eye was extirpated on account of various malignant affections. He has operated six times on account of melanosis; he states that five of the patients were cured, and that the result in one case was doubtful. After considering attentively the facts stated by Dr. R., and comparing them with the case of Elizabeth Rute, I doubt whether any one of his patients can be said to have been completely cured in the sense specified above; and I therefore conclude that in saying these persons were cured he merely means to imply that there was no return of disease in the orbit. In Case I. death took place two years after the operation from disease of the heart. Was it melanosis? Were any other organs diseased? Case II. remained well six months after the operation. Case III. died from melanosis affecting the hip and surrounding parts three years after the operation. Case IV. was well at the end of two years. Case V. died with symptoms of apoplexy ten months after the operation, having had fetid discharge from the orbit for two months before death. It is most probable that melanotic disease had occurred within the cranium in this case. In Case VI. death occurred two years after the operation. The liver was enormously enlarged and of soft texture; there was no melanotic deposit in any part of the body.

Dr. Robertson gives an enumeration of twenty-three cases from other authorities, stating that twenty were cured, while three terminated fatally from secondary melanotic formations. We cannot estimate such cases from a mere enumeration without particulars. Indeed, in order to elucidate the point now under consideration, we require complete histories of the cases embracing a considerable period of time after the performance of the operations.

If it should be found, as I think it probable, that cases of melanosis affecting the eye, always terminate fatally, sooner or later, even although the organ should be removed at an early period, by secondary formations of the disease in other parts, the malignant character of the disease will correspond to what occurs in the skin, the only part besides the eye in which I have seen melanosis as a primary affection. In all the instances that I have known, of cutaneous melanosis removed by operation, death has ensued from subsequent affection of internal organs, generally with return of disease in the part.

Although the removal of the eye in melanosis cannot be undertaken with the promise of permanent success, it may be resorted to, should the patient wish it, as a means of prolonging life. The benefit in this respect will be greater in proportion as the operation is performed at an earlier period. Thus the patient in Case I. enjoyed perfect health for more than three years after the loss of the eye; while Sarah Keeble (Case II.), in whom the disease had made its way through the coats of the eye, survived only six months.

There may be some difficulty in recognizing the presence of the disease previously to the time at which it comes through the coats of the eye. I have not seen it in the first stage, in which there is total loss of vision, with little if any change in the appearance of the eye. In Case I. sight was lost without pain or inflammation; while in Case II. there was considerable inflammation with swelling. The eye remains without further change for some months, when the increase of the morbid growth distends the globe, causing severe pain and redness, and pushes forwards the lens and iris.

We find at this time the iris in contact with the cornea and motionless, but not otherwise changed; the pupil rather dilated; the lens opaque, and somewhat dingy. The sclerotica soon gives way at some point or points not far from its anterior margin. In one case there was a general bulging of the tumor below the margin of the cornea. This distended portion presented a dull discoloration from the dark color of the melanotic deposit, and its surface was occupied by large straight vessels, apparently containing venous blood arranged as closely as possible so as to cover the membrane completely. These appearances show clearly that there is an increase in the contents of the globe, and leave little doubt that the increase is a morbid growth, which must be referred either to fungus hæmatodes or melanosis. There may be effusion of fluid into the eyeball, causing staphyloma scleroticæ. The previous history of such a case will be different from that of the disease under consideration. The iris would probably be changed in color, but not pushed against the cornea; the crystalline not opaque nor pressed forwards. In staphyloma scleroticæ from effusion of fluid the pupil is dilated to the utmost opposite to the swelling, and the iris may even disappear at that part. Should there be any doubt respecting the nature of the case, an exploratory puncture with a grooved needle should of course be resorted to before operation.

[Mr. Lawrence's suspicions that it will be found "that cases of melanosis affecting the eye always terminate fatally, sooner or later," receives strong support from the researches of Mr. Holmes Coote. This gentleman, in an interesting paper on melanosis (*Lancet*, Aug. 8th, 1846), expresses his conviction that this disease cannot be radically removed by operation, an opinion in the correctness of which we fully concur.

"It has been commonly stated," he remarks, "that by the early and complete removal of a melanotic tumor the patient is afforded a good chance of permanent cure. This opinion has been recently supported by Dr. Argyle Robertson, in a short pamphlet upon melanosis. My own observations lead me to a totally opposite conclusion. Thoroughly convinced of the inefficacy of any operation in radically removing the disease, I doubt much whether we can affirm that it even prolongs life. Patients may fairly be recommended to submit to the removal of superficial tumors, which, by their position or size, produce inconvenience; but the more serious operation of extirpation of the eye ought never to be undertaken, except at the patient's express desire, and after he has been fairly made acquainted with the circumstances of the case. I shall conclude with a table of fifteen cases, watched for a period of at least four years. This table shows the average duration of human life, after the primary tumor has been successfully removed, to be about thirteen months.

"*Table of cases in which the observations have been extended over a period of above three years from the date of the operation.*

Name of the Operator.	Case.	Result.	Cause of death.
Mr. LAWRENCE*	1	Died.	Eighteen months after operation; secondary melanosis.
Ditto	2	Died.	Six months after operation; secondary melanosis.
Ditto	3	Died.	A few days after the operation.
Mr. FAWDINGTON†	4	Died.	Seven months after operation; secondary melanosis.
Mr. A. BURNS‡	5	Died.	Three months after operation; secondary melanosis.
Dr. HOLSCHEN§	6	Died.	One year after operation; secondary melanosis.
CULLEN & CARSWELL‖	7	Died.	Thirteen months after operation; secondary melanosis.
Mr. WILSON	8	Died.	Two years after operation; secondary melanosis.
Mr. LANGSTAFF¶	9	Died.	Five months after operation; secondary melanosis.
Dr. D. WILLIAMS**	10	Died.	Twelve months after operation; secondary melanosis.
Mr. MONTGOMERY	11	Died.	Five months after operation; secondary melanosis.
Dr. A. ROBERTSON	12	Died.	Two years after operation; disease of heart?
Ditto	13	Died.	Three years after operation; melanosis of sacrum and pelvis.
Ditto	14	Died.	Ten months after operation; secondary melanosis.
Ditto	15	Died.	Two years after operation; disease of the liver.

Total number of months, 200.
Average duration of life after the operation, $13\frac{1}{3}$ months."

Some cases might be added to this table, which would increase the average duration of life after the operation. Thus a case was communicated to the Surgical Society of Ireland by Dr. BYRON,†† where the patient lived nearly four years after the operation and then died of fever, and another was alluded to by Dr. HOUSTON, in which the patient survived the operation seven years. Other cases were mentioned, but the details are too imperfect to enable us to tabulate them.‡‡

[*Melanotic deposit beneath the conjunctiva.*—Melanosis of the eye usually commences between the choroid and retina, but we have seen three cases in which the melanotic deposit took place in the subconjunctival cellular tissue.

The first case was a coachman, 34 years of age, dark hair, florid complexion, who consulted me in the year 1840. He stated that since his boyhood he had had a minute black spot on the outer corner of his left eye. About five years ago (May, 1835), he had received a blow on that eye; some time afterwards the spot began to enlarge, and in June, 1836, a surgeon of this city had cut it off. Ten or eleven months afterwards the disease returned, and between that period and July, 1838, he had been operated upon by the same surgeon nine times; caustic being applied to the eye in the intervals, and blue pill given until slight ptyalism was produced. His general health is now and has always been good. Thirteen years ago he had syphilis, which was followed by nodes on the tibia. These have disappeared.

* LAWRENCE on Diseases of the Eye, and Clin. Lectures, Med. Gaz., Oct. 3, 1845.
† FAWDINGTON: Case of Melanosis. ‡ A. BURNS: Anatomy of Head.
§ HOLSCHEN: Hanover Ophthal. Observ.
‖ CARSWELL and CULLEN: Ed. Med. and Surg. Transactions.
¶ LANGSTAFF: Med. and Chir. Trans., vol. iii.
** Dr. D. WILLIAMS, Prov. Med. and Surg. Transactions, vol. i.
†† See American Journal of the Medical Sciences, July, 1842, p. 206, et seq.
‡‡ Ibid.

On examination, I found a melanotic deposit beneath the conjunctiva of the left eye, principally at the outer and inner angles, most dense at the latter. This deposit formed an irregular border around the upper margin of the cornea, and extended down over this part to the distance of about one-third its surface. At the inner angle of the eye, the conjunctiva was raised at points, forming slightly elevated tumors. On the sclerotica, at the lower margin of the cornea, there was a dark vascular tumor.

The pupil was natural and the sight nearly perfect, but the light is painful, the eye soon becomes fatigued, and there is considerable lachrymation. The right eye was unaffected.

I candidly explained to the man the malignant nature of the affection, suggested some hygienic means for the promotion of his comfort, and expressed my conviction that no surgical operation would avail for the cure of the disease. In this opinion my friend Dr. Norris, who was the man's family physician, and at whose recommendation he had consulted me, fully concurred. I did not see this man again until after his death, but I learned from Dr. Norris that the disease increasing, and the patient being anxious to have something done, he had applied to the surgeon under whose care he had first been; that he again several times operated, but that the disease seemed to be renewed with increased vigor after each operation; bleeding fungous growths sprouted up, from which the hemorrhage became so profuse that the life of the patient was in extreme jeopardy. In this condition he was persuaded by a friend to go with him to New York to consult a countryman, (the patient was an Irishman,) an oculist in that city. This gentleman declining to operate, the patient applied at the New York Hospital, into which he was admitted in a very exhausted condition from the excessive loss of blood. To protract his life, but without any expectation of a cure, the eye was extirpated by Dr. Kearny Rogers. The man some time afterwards returned home, the wound healing, his strength recruited and in good spirits. This favorable condition of things was unfortunately only of short duration; and on the 30th of March, 1841, he was admitted into the Pennsylvania Hospital. The subsequent history of the case, and the post-mortem examination, at which I was present, has been politely furnished me by my friend Dr. Edward Hartshorne.

"G. G., aged 34, was admitted March 30th, 1841, delirious, and in great pain. Found him rolling about his bed in agony from a pain in the head, the principal seat of which appeared to be at a point on the left side below and behind the vertex. Six or eight ounces of blood were taken from the scalp over this region, which was then covered with an anodyne poultice. Morph. sulph. gr. $\frac{1}{4}$ was administered internally. The pain began to abate soon after the cupping; in the course of an hour the man fell asleep and appeared to rest well throughout the night.

"Cephalalgia much less severe the next morning, and the pain in the eye moderate. Mind more collected but evidently much impaired, the memory being especially enfeebled. Continued to suffer less that day and the next. Gently purged. On the fourth day the pain returned on whole left side of head and in left eye. Patient extremely restless and incoherent. Continue anodyne cataplasm. ℞.—Liq. morph. sulph. ℥j. q. h. t. p. r. n. Tumor of orbit dressed with lint saturated with slippery elm mucilage.

"5th day, suffering unabated; partial paralysis of right arm. Emp. bellad. over seat of pain. Liq. morph. sulph. continued, with nutritious diet, and rest in bed.

"Day before death, pupil fixed; intellect more disordered. The next

morning coma; stertor; general and complete paralysis; occasional frothing at the mouth, with convulsive clenching of the jaws. Subsequently stertorous respiration, with mouth wide open; mouth then slightly drawn to right side; cerebral symptoms present gradually increasing, at least 20 hours, until death, April 6th, 1841.

"*Sectio cadaveris* 10 hours after death. Body not much emaciated; left orbit filled with a soft homogeneous disorganized mass, of a dull olive black color. Head alone examined; dura mater nearly healthy, the veins being perhaps slightly distended; arachnoid and pia mater presenting no evidences of recent inflammation.

"Substance of brain rather soft; although examined within 12 hours after death in cool weather, yet it flattened out by its own weight.

"Color of cortical and medullary substance in left hemisphere very pale, and section unusually marked with vascular puncta. This paleness less distinct in right hemisphere.

"A tumor 3½ inches long, 3 wide and 2 thick, about the size and shape of a medium turnip, soft, but tenacious like firm cellular tissue, and of a dark purple color, resembling a large fibrinous coagulum, was discovered occupying a kind of sac in the anterior part of the middle, and posterior part of the anterior lobe of the left hemisphere. Purulent matter of a peculiar greenish-yellow hue was found lining the anterior wall of this sac. Serosity in ventricles slight; velum interpositum a little injected. No coagulum or other abnormal condition could be found in the cerebrum. Cerebellum apparently healthy; spinal cord not examined. Permission to open other cavities of the body could not be obtained."

The two other cases came under our care in Wills' Hospital, but we are able to give only a very general account of them, having unfortunately mislaid our notes.

The subjects of both cases were short, rather stout females, past the middle age. In the first case there was a considerable deposit of brownish-black matter between the conjunctiva and sclerotica of one eye, giving it a dark mottled appearance. She was kept in the house with a view of watching the progress of the disease, but not subjected to treatment. Her health seemed good. After being in the house for some months she was suddenly attacked with a fit, from which she, however, soon recovered. Subsequently she had several more. After my term of service had expired, she was, I learned, discharged, and after her return home had a recurrence of fits in one of which she had died.

In the other case the melanotic deposit was in the same situation as the preceding, but much less in quantity. It existed in one eye only. The patient's health seemed good. I retained this patient also under observation during my term of service, but afterwards she was discharged, and I was informed that some months afterwards she had died, but I could not learn any satisfactory particulars in regard to her.

The following case occurred in the Hospital of Surgery, Panton Square, St. James', under the care of Mr. Wardrop.

"A. B., aged 40. The form of the anterior chamber is changed, the cornea having become prominent and irregular on its surface, and it has lost its natural transparency, having an appearance as if it were filled and distended with a dark blue substance. These changes of the anterior chamber came on about six years ago, after an attack of puriform ophthalmia, and are nothing more than the usual appearances of staphyloma. But the peculiarity of this case consists in a portion of the conjunctiva covering the nasal side of the sclerotica, being converted into a dark-colored mass, precisely the shade of Indian ink. The tumor is not

larger than the nail of the little finger, but of an irregular and angular shape, and flattish. It seems to consist in a mere thickening of the conjunctiva, which membrane is still movable on the sclerotic coat. It was first observed twelve months ago, in the form of a small black spot, a part of which was removed by a surgeon, since which it has increased in size. This is considered by Mr. WARDROP as an example of melanosis affecting the conjunctiva, of which he has seen a few examples, some of which are delineated in his *Morbid Anatomy of the Eye*, vol. i."—*Lancet*, Oct. 21, 1846.

Some other cases are recorded, which were probably examples of melanosis of the subconjunctival cellular tissue, but the accounts of them are wanting in precision, and we will merely refer to them.*]

SECTION V.—EXTIRPATION OF THE EYE.

Careful preparation of the patient, by regulation of the diet and attention to the state of the bowels, for some days previously, is advisable, in order to prevent the occurrence of inflammation, which, if produced, would probably extend from the orbit to the important connected and contiguous parts.

The operation itself, although its bare mention is distressing and shocking to the feelings of patients and their friends, is neither difficult, tedious, nor dangerous, when executed properly, and under the requisite precautions of previous measures and subsequent management. The lids must be divided at their external commissure, and turned back so as to expose completely the anterior opening of the socket; the conjunctiva must then be cut through at its reflection from the palpebræ, and the diseased mass must be detached from the socket, to which it is connected by cellular tissue, more or less loose; the third and last portion of the operation consists in severing the orbital contents thus insulated, at their posterior attachment, by cutting through the muscles of the globe and the optic nerve. The instruments required are scalpels and forceps; some of the former should be double-edged and pointed; a strong curved needle, armed with a stout thread; a double-edged knife, curved on the flat; and a pair of strong scissors similarly curved.

The patient should be placed in the recumbent position, with the head a little raised on a pillow. The separation of the eyelids, at their temporal junction, would be expedient, in order to give room, even if the globe were of its natural size, but it is absolutely necessary in the more or less considerable enlargement, which exists almost invariably when the operation of excision becomes necessary. This point is accomplished by a straight incision, which should be an inch or an inch and a half long, or at least sufficiently extensive to admit of the palpebræ being completely turned back so as to expose the margin of the orbit. After dividing the commissure of the lids, they must be dissected from the base of the tumor above and below, by a few strokes of the knife, by which the conjunctiva is divided more or less completely, at its reflexion over the globle. The curved needle is now carried through the diseased mass, and the ligature thus introduced, held either by the operator or an assistant, allows of its being moved in any convenient direction as the dissection proceeds. The eye

* See TRAVERS, Synopsis of the Diseases of the Eye, pp. 102, 394. London, 1820.

RŒDERER, Thèse, quoted by ROGNETTA, Traité Philosophique et Clinique d'Ophthalmologie, p. 376. Paris, 1844.

MIDDLEMORE, Transactions of Prov. Med. and Surg. Ass., quoted in Med.-Chirurg. Rev., July, 1837, p. 277.

being drawn gently upwards, a semicircular incision is carried from one angle to the other, along the inferior margin of the orbit, and we proceed, by cutting in the same direction, to detach the contents of the orbit from the bony cavity, as far as we can conveniently carry the knife. In this dissection, we cut through such part of the conjunctiva as had not been divided in turning back the eyelid and the inferior oblique muscle. The two extremities of this first incision are now united by a second semicircular cut carried along the upper edge of the orbit, and the mass is detached above; here we first cut through the conjunctiva, and then the tendon and pulley of the trochlearis muscle. The object is to remove the entire orbital contents, which is most effectually and conveniently accomplished by dissecting close to the bone, and employing a double-edged scalpel. As the roof of the orbit is naturally as thin as paper at some points, and as it sometimes undergoes absorption in consequence of pressure especially when long continued, the cavity of the cranium might easily be penetrated by the sharp point of the knife, if it were used incautiously. To avoid this risk, the eye should be drawn downwards, and the dissection conducted very carefully at the superior part of the orbit. When the diseased mass has been detached all round, it merely remains to cut through the muscles and optic nerve behind; and this division may be accomplished with the straight scalpel, the curved scalpel, or the curved scissors. As the external side of the orbit slants from without inwards, while the internal goes directly backwards, this last step of the operation can be accomplished most conveniently by introducing the instrument at the outer side of the cavity.

The surface of the orbit should be gently and carefully examined with the finger; if the lachrymal gland, or any portion of the disease has been left behind, it should be removed.

The vessels divided in the operation bleed freely; when the wound is sponged, it fills again directly with blood, so that we cannot direct our dissection by the immediate sight of the parts, which we are dividing. Profuse hemorrhage generally takes place from the ophthalmic artery; it usually ceases spontaneously; but if it should proceed to an alarming extent, it must be stopped by pressure. A piece of lint rolled firmly into the shape of a conical plug may be held on the vessel until the blood ceases to flow, when it may be gently removed. If the bleeding should require it, a compress of folded linen might be placed over the plug, and secured by a circular bandage for a short time.

The practice, sometimes recommended and followed, of filling the orbit with lint, sponge, or other matters, seems to me decidedly objectionable. From this introduction of extraneous substances into a recent wound, we can expect no other result than irritation and inflammation. We should use every precaution to avert such results, which would become dangerous in this case from the direct connection between the sheath of the optic nerve, the periorbita, and the dura mater, and the immediate contiguity of the brain and its membranes with a large portion of the wound. It will be sufficient to unite the divided commissure of the lids by one or two sutures, to cover the part with a soft rag dipped in cold water, renewing it as often as it becomes dry or warm. The patient should be kept quiet in bed, and restricted to a spare diet, until all risk of inflammation is past. The bony cavity granulates, and becomes filled, to a certain extent, with a newly-formed vascular mass; the eyelids sink inwards, and become concave. There is no support for an artificial eye, nor indeed sufficient cavity for its reception; a green or black patch must therefore be worn over the orbit to conceal the deformity consequent on the operation.

[The attention lately paid to the orbital capsule of Tenon, has led Dr.

Bonnet, of Lyons, to an improved method of extirpating the eye, in those cases in which nothing but the eyeball requires to be removed. In the ordinary mode of operating, the instrument is buried in the fat of the orbit, and the muscles are divided at a considerable distance from their insertion into the eyeball; the trunks of the nerves are cut across, as well as considerable branches of the ophthalmic artery. All this is avoided, if the muscles and the optic nerve are divided at their insertion into the sclerotica, and the eyeball removed, leaving Tenon's capsule entire. In this mode of operating, all risk of hemorrhage is avoided, the optic nerve only is divided, and the wound is separated from the remaining contents of the orbit by the capsule. Separating the eyelids, Dr. Bonnet proposes to divide the rectus internus, as in the operation for strabismus; next, sliding the scissors through the wound, they are to pass between the sclerotica on the one side, and the subconjunctival fascia and muscles on the other, and to divide the remaining three recti close to their insertions; the two obliqui are to be divided as near as possible to the eye; then, the optic nerve. The eye is now removed, without implicating any vessel, or any other nerve than the optic, and without penetrating into the fat of the orbit.

The cases suitable for this mode of operating, must be few, the textures surrounding the eyeball being in general too much implicated in the disease to be left behind. Gensoul had a case, in which Bonnet's plan might have sufficed. The eye was changed neither in form nor size; vision was destroyed; but the excruciating pain suffered by the patient, and which no means were found to mitigate, was the only circumstance which determined the question as to an operation. A melanotic tumor, confined to the retina, was found to be the disease.

Dr. Stœber, of Strasburg, has removed an eye affected with melanosis, nearly on Bonnet's plan. Having cut the rectus internus, he drew the eye forwards, divided the optic nerve with curved scissors, and finished the operation by separating from the eye the conjunctiva and the muscles. The eye, thus removed, looked as if nicely dissected, the sclerotica being perfectly free of cellular substance. The operation required much less time than the ordinary extirpation, and very little blood was lost. Dr. Cunier has removed an eye according to the same method. The eyeball was not changed in form; the disease was medullary fungus. The suppuration was very great, and the granulations excessive. Experience must determine, whether these effects are generally to be expected when this mode of operating is adopted.—*Brit. and For. Med. Rev.*, Jan. 1843, from *Annales d'Oculistique*, April, 1842.]

CHAPTER XXIV.

OSSIFICATIONS.—CALCULOUS CONCRETIONS.—ENTOZOA IN THE EYE.

SECTION I.—OSSIFICATION OF VARIOUS PARTS OF THE EYE.

Most of the textures belonging to the eye, if not all of them, have been found converted into bone, more or less extensively; the change having seldom been observed, except in eyes which had been seriously disorganized by acute inflammation many years before death, and had then remained collapsed, shrunk, or at all events deprived of vision. The subject, therefore, gene-

rally speaking, is of no practical importance. The recorded instances of these ossifications have been, for the most part, collected by SCHÖN, in his work on the Pathological Anatomy of the Human Eye, (*Handbuch der pathologischen Anatomie des menschlichen Augues;* 8vo. Hamburg, 1828;) and some of the following references have been borrowed from him.

Cornea.—In the opaque cornea of an eye changed in form, Mr. WARDROP found, between the laminæ, a small piece of bone. Another was met with between the choroid and retina of the same eye. In another case, Mr. W. found gritty particles and inequalities on the internal surface of the cornea. In a case, communicated to him by Mr. ANDERSON, of Inverary, a substance of whitish appearance was seen in the under part of the globe of the eye, arising from the inside of the sclerotic coat, and extending upwards behind the cornea, over a great part of the iris to very near the pupil. It had begun to grow fifteen years before, in consequence of a blow on the eye from a fall, and had been attended with much irritation and pain, which had increased so as to render relief by operation necessary. Mr. ANDERSON, therefore, made a section of the cornea, as in extraction of the cataract, and then readily turned out a small piece of bone, which was as thin as paper above, thicker, porous, and brittle below. It adhered slightly in the lower part, but was unattached above. (*Essays on the Morbid Anatomy of the Human Eye*, vol. i., chap. 10; pp. 74—77.)

WALTHER found a small piece of bone in the cornea of a man sixty years of age. (*Anat. Museum*, Th. i., 139, No. 274.)

A case recorded by MONOD (*Nouvelle Bibliothèque Méd.*, May, 1827), of ossification of the entire cornea, in an old man, is mentioned by SCHÖN as the only instance of the kind.

Sclerotica.— According to SCHÖN, only one instance has been observed; it is recorded by BLASIUS in a rare work. (*Observationes medicæ rariores; Amstelod.* 1677, p. 78.)

Choroid coat.—"I have met," says Mr. WARDROP, "with a few instances where a thin cup of bone was found between the sclerotic coat and the retina. The ossifications in all these cases were exactly similar. At the bottom of the cup, there was a small round perforation, through which the retina passed to expand on the interior surface of the osseous shell. The retina was in immediate contact with the interior surface of the bone, but between the sclerotic coat and the ossification, there was a very thin, tender, and pale-colored membranous expansion, the only vestige of the choroid coat." (*Lib. cit.*, vol. ii. p. 69, plate xiv. fig. 3.)

WALTHER found the posterior half of the choroid ossified in the eye of a man thirty years old, who had been long blind; the eye being in other respects healthy. In a man of sixty, who had been blind twenty-eight years, the globe was collapsed, and the interior portion of the choroid ossified. In another instance, where the bulb was diminished, the choroid formed a firm excavated hemisphere, in which there was a hole for the passage of the optic nerve. In an older man, the choroid was completely ossified in both eyes. (*Lib. cit.*, Nos. 292, 293, 294, 295.)

Iris.—Two instances of its ossification are mentioned by WALTHER. (*Lib. cit.*, pp. 146 and 148.)

Retina.—Ossification of this part has been already mentioned in two notes at page 506. SCHÖN speaks of this change as a rare occurrence, and quotes, besides an instance mentioned by MORGAGNI, (*Epis.* xiii. No. 10,) another related by ZINN in the *Hamburg Magazine*, vol. xix. p. 441.

Lens and capsule.—Ossification of these structures is spoken of in Chapter XIX. § 5, p. 487.

Membrane of the aqueous humor.—Mr. WARDROP saw a case in which

thin laminæ of bone, which he supposes to have been formed in this membrane, were discharged from the anterior chamber through ulcers formed in the cornea. He mentions, that in a patient, under the care of Mr. WISHART, that portion of the capsule of the aqueous humor, which is reflected over the iris, was almost entirely converted into a bony shell. (*Lib. cit.*, p. 18.)

Vitreous humor.—This humor, and the membrana hyaloidea may become ossified. "In one case," says Mr. WARDROP, "besides the capsule of the lens being ossified, I found several large, but thin, scales of bony matter, dispersed in an irregular manner, throughout the vitreous humor, which, in all probability, were ossifications of the hyaloid membrane." In another eye, extensively disorganized by serious disease, and shrunk, the cavity of the globe, within the choroid and iris, was occupied by an irregularly-shaped bony mass, composed of two distinct portions, slightly connected. The anterior was spherical, and consisted of a thin hollow shell of bone; it appeared to be the capsule of the lens ossified. The other, occupying the situation of the vitreous humor, was unequal on its surface, and composed of numerous osseous laminæ irregularly disposed. (*Lib. cit.*, p. 128, plate xiv., fig. 1.)

[Dr. GRILLO, Prof. of Anatomy in the University of Naples, exhibited at the meeting of the Medico-Chirurgical Academy of Naples, on the 11th of March last, two eyes, the vitreous humors of both of which were completely ossified. The individual from whom these eyes had been taken, was an old sailor, who had been for twenty-five years tormented with gout in his feet. The disease became displaced, and the eyes were affected with obstinate inflammation, followed by opacity of the cornea, atrophy of the eyeballs, complete blindness, and the gradual conversion of the eyes into two white hard balls. Finally the patient died of apoplexy. The ossification of the vitreous humor is exceedingly rare, this degeneration being usually confined to the hyaloid membrane. Dr. G. met with this last-named pathological condition, in the eye of a subject dead from phthisis.—*Osservatore Medico di Napoli.*]

SECTION II.—CALCULOUS CONCRETIONS.

Calculous concretions have been met with in the eye. SCARPA has described and delineated an adventitious formation of this kind. The globe was shrunk to one half its natural size. The sclerotica and choroid were nearly natural. Within the latter, there were two calculous, cup-like substances (*scodelle*), of which one occupied the back of the eye, the other was in the situation of the ciliary body and the lens. The optic nerve, degenerated into a thread, went through an opening in the centre of the posterior calculous portion, and was then continued as a soft cylinder, through the axis of the globe, and was fixed to the anterior calculous mass.*

HALLER met with a similar change of structure, which he has described in his *Opuscula Pathologica*, Obs. 65, under the title of *lapideus scyphus in oculo*, that is, a cup-like calculous concretion in the eye. In dissecting the nerves of the eye, he observed that the cornea was opaque, and the globe hard. "Within the choroid, and concentric with that tunic, in place of the retina, there was a hollow, osseous, or rather stony hemisphere, for

* Saggio di Osservazioni e d'Esperienze, &c., cap. xx., plate ii., fig. 8. Treatise, &c., p. 534. The morbid structure is delineated in plate ii. fig. 8.

no bony fibres were discernible, to which the choroid adhered, as it usually does to the retina: it consisted of two layers, and was excavated on one side so as to form two small recesses. That this sort of cup was the retina, in an indurated state, was further proved by the circumstance of its being perforated by an accurately round opening at the entrance of the optic nerve. No proper vitreous body was found in this osseous cavity, but a kind of nerve, that is, a white cylinder, which, entering through the foramen of the bony cup, passed along its axis, and adhered in front to a confused mass of bone, which might have been taken for a degenerated crystalline. In this same mass, the iris, ciliary processes, and cornea, were firmly consolidated." (*Opera minora*, tom iii. pp. 366, 367.)

Panizza minutely examined an eye, which contained a large calculous formation between the choroid and retina; a description and good delineation of the parts are given in his work on fungus hæmatodes of the eye.* The left eye, in which vision had been lost in youth from internal inflammation, was taken from the body of a farmer, sixty years of age, who had died of peripneumony. The cornea was opaque, flattened, and shrunk; the globe generally, was rather diminished, and firm to the touch. When the sclerotica and choroid, which were natural, had been cut through, a white, stony, and somewhat rough substance was exposed, covering the globe completely within the choroid, and connected behind, at the entrance of the optic nerve, by a small white cord, which was the nerve passing through an opening in the calcareous substance. In front, the latter, the iris, cornea and lens, which was diminished and stony, were consolidated into one mass. A portion of the calcareous stratum, including part of the opening for the passage of the retina, was broken away to expose the interior. It was hard and brittle externally, about a line in thickness, and disposed in layers, of which the internal were less firm, and at last almost membranous. The cavity was filled with a whitish gelatinous substance deposited in laminæ. In the midst of this the retina was found contracted and folded together, ending behind in the thin cord which passed through the calcareous shell, and spreading out in front into a broad attachment, connecting it to the ciliary body. An incision was made into the conical portion of the retina, and the edges separated. The cavity contained the vitreous humor, shrunk, folded, and reduced into a small conical mass.

A specimen in the museum of St. Bartholomew's hospital resembles very nearly the two examples of disease last mentioned. Within the sclerotica and choroid, which are healthy, there is a cup-like, calcareous deposition, a line in thickness; its exterior surface, which was in contact with the choroid, is a little rough; the interior concavity is smooth. I do not know what it contained internally, nor whether it was perforated by the optic nerve. It was an old, diseased eye.

Walther says, "I possess a really stony vitreous humor, which was still covered by the retina, when I took it out of the eye; the concretion possesses completely the size and form of the vitreous body, and sounds when struck with a metallic probe." (Graefe and Walther's *Journal*, vol. i. p. 164.)

SECTION III.—ENTOZOA (INTERNAL OR PARASITIC ANIMALS) IN THE EYES OF MAN AND OF OTHER VERTEBRALIA.

In the next chapter, on affections of the orbit, will be found an example

* Sul fungo midollare dell' occhio. Appendice; Pavia, 1826. pp. 22, 23, tab. i. fig. 7.

of a cyst in that cavity containing a large number of the simple globular hydatid (*echino coccus*).

Filaria in the anterior chamber of the horse's eye.—It has been long well-known that a species of filaria (thread-worm) is occasionally found in the anterior chamber of the horse's eye, moving rapidly about in the aqueous humor. The circumstance, though rare in these climates, is by no means uncommon in India, where it is only seen during the cold months, not having been observed before the beginning of October, or later than the end of February, or the commencement of March. The heavier the rains have been during the periodical rainy season, and particularly towards its close, the more numerous have cases of worm in the eye been during the subsequent cold season. They occur chiefly in low districts, being hardly known in the upper provinces, where the soil and climate are drier. Mr. Gibb, surgeon to the East India Company's stud at Poonah, used to see about twenty cases annually. Thirty cases occurred in one season at Poonah among the young stock, while in another depôt, situated higher (Ghazepoor), not a single case occurred during the same time. Two worms have sometimes, but rarely, been seen in the same eye at one time; and a second worm has made its appearance in an eye from which one had been extracted some months before. Similar worms are met with in the stomach and intestines of the horse; also, according to some reports, in the cellular substance of the loins. The animal, which has received the name of *filaria papillosa*, is about an inch long, equal in size to a sewing-thread, white or darker colored. It causes inflammation of the eye, with uneasiness, watering, and turbidity of the anterior chamber. Opacity of the cornea comes on, and blindness ensues. These results may be prevented by extracting the animal. A small incision is made in the cornea with a lancet, and the worm comes out with the aqueous humor.*

This worm has been seen in the horse's eye in Europe,† [and also in the United States.‡]

In the work just quoted, Dr. Nordmann, of Odessa, describes the circumstances which led him to discover the existence of entozoa in the eyes of several vertebralia; and he gives a minute account of them, illustrated by beautiful figures, representing their form and internal structure. His researches, which were carried on during eighteen months, from March, 1830, to September, 1831, embraced numerous eyes of horned cattle, sheep, pigs, frogs, lizards, and fishes, with some from the human subject, and birds. He found entozoa of the genus *filaria* in the human eye, and in that of the gadus æglefinus (haddock), of the genus *ascaris* in the frog, of the genus oxyuris in the perch, or the genus cysticercus in the pig, and *trematoda* in great abundance in other fishes. The genera examined for this purpose were muræna, gadus, perca, gasterosteus, cobitis, silurus, cyprinus, salmo, esox, pleuronectes. In the fish he first found entozoa in the vitreous

* On the Worm found within the Eye of the Horse, by P. Breton, Esq. Observations on the Filaria or Thread-worm found in the Eyes of Horses in India, by W. Twining, Esq. In Transactions of the Medical and Physical Society of Calcutta, vol. i. A short statement of Mr. Twining's observations will be found in the Edinburgh Medical and Surgical Journal, vol. xxv., pp. 240, 241.

† Nordmann, Mikrographische Beiträge zur Naturgeschichte der Wirbellosen Thiere; Erstes Heft, p. 11—13. A delineation of the worm is given by Gurlt, in his pathological anatomy of the horse.

Leuckart has collected all that is known respecting this *filaria* of the horse's eye, in his Versuch einer naturgemassen Eintheilung der Helminthen, Heidelberg und Leipzic, 1827, pp. 28, 29.

[‡ See Trans. Am. Philos. Soc., 1st series, vol. 2. And Am. Journ. Sc. and Art., vol. 39.]

humor, but he subsequently met with them in the crystalline, between the lens and the capsule, between the laminæ of the cornea, in the iris and retina, in the choroid gland, between the sclerotica and retina, and in the aqueous humor. (*Lib. cit.*, pp. 1—6.) In the crystalline lens of some fish they are so numerous as to render it more or less opaque, and thus to impair or injure sight. (*Lib. cit.*, pp. 19, 20.)

Filaria under the conjunctiva in the human subject.—A species of filaria (*filaria medinensis?*) has been seen under the conjunctiva oculi in the West Indies. SCHÖN has quoted some facts of this kind. A case was related to him by Dr. GAERTNER, who had resided long in the West Indies. A blackish thread-like streak, which moved, was seen in the conjunctiva of a negro girl. In a little time it had disappeared, and a slender bluish line was observed in the upper eyelid. It appeared like a small cutaneous vein, and moved in various directions. Dr. GAERTNER considered it to be the guinea-worm: he made an incision, and extracted the animal.*

Filaria in the crystalline lens.—Dr. NORDMANN examined two lenticular cataracts taken from an elderly man, half an hour after they had been extracted by Professor VON GRAEFE. In one of these, which was still partially surrounded by the capsule, he observed in the MORGAGNIAN fluid two very small and delicate rings, which he clearly recognized under the microscope as convoluted filariæ. One of the two had been injured in the middle, probably by the cataract needle, so that the intestines had come out of the body, and were visible as slender threads. The other was uninjured, of uniform thickness, three-quarters of a line long, and extremely narrow. It was spirally convoluted and completely dead. A simple intestinal canal, a mouth without visible papillæ, a uterus, and a prominent anal aperture, could be distinguished. In the other lens, which, as is usual, was completely free from the capsule, nothing similar could be discovered. Dr. NORDMANN calls this entozoon *filaria oculi humani*. He adds, that he had since examined several cataracts, and human eyes under various circumstances, without discovering any entozoa. (*Lib. cit.*, p. 7, 8.)

Filaria and monostomata in the lens.—In a second part of the same work, the author recites two additional instances of entozoa found in the opaque lens. He says, "In the month of May, 1832, I was present at two operations of extraction performed on old women by Professor JUENGKEN. I found a living filaria, five lines and a half long, in the act of casting its skin (*in der häutung begriffene*), in one lens of the first patient, a case of green lenticular cataract. No extraneous living body was discovered in the other lens. The second case was more interesting, as it presented the first example of microscopical entozoa possessing suckers (*Trematoda*, RUDOLPHI), being found in the human eye; eight individuals of the genus *monostoma* were found in the substance of the lens. These minute beings were situated in the upper strata of the crystalline; they were one-tenth of a line long, and moved sluggishly when placed in warm water. The examination took place immediately after the operation. In both cases the opacity was not yet complete, and the lenticular substance was soft. (*Lib. cit.*, *Zweites Heft; Vorwert*, p. 9.)

VON AMMON found a filaria in a lenticular cataract, of which the nucleus was firm, the exterior pulpy. The cataract was extracted. He has figured the animal, of its natural size, and magnified. (*Klinische Darstellungen*, pt. i. pl. xii. figs. 22 and 23.)

Dr. GESCHEIDT and Professor VON AMMON found, in the crystalline lens, four entozoa of the genus *distoma*, in a case of congenital cataract. (*Zeit-*

* Handbuch der pathologischen Anatomie des menschlichen Auges, pp. 226, 227.

schrift für die Ophthalmologie, vol. iii. pp. 75, 76. Also *Klin. Darstell.*, pl. xii. figs. 24 and 25.)

Cysticercus cellulosæ in the anterior chamber of the human eye.—This hydatid, consisting of a small globular vesicle, with a slender neck, of which the end is a little enlarged, so as to form a kind of head, which is found all over the body of the domestic pig under certain circumstances,* occurs also in the eye of the animal, where it has been seen both in the anterior and posterior chamber. It has been twice observed in the anterior chamber of the human eye, floating in the aqueous humor. Dr. W. Soemmering communicated the first instance to the assembly of German naturalists at Heidelberg, in the year 1829: it was published in the *Isis*, 1830, p. 717, from which Dr. Nordmann has taken the following account.

"A living *cysticercus*, of the size of a vetch, was found in the anterior chamber of the left eye of a girl eighteen years old, and otherwise healthy. It was said to have shown itself after an acute inflammation of the organ. I saw, and delineated it, two months afterwards, when no trace of inflammation remained, excepting a slight blush of red round the cornea, on excitement of the organ. It caused no pain, or merely a transient uneasiness when it moved considerably; and interfered with sight only when it came before the pupil. Usually it lay at the bottom of the anterior chamber, like an imperfectly dissolved lens, where it appeared as a partially transparent sphere, from which there was, at one point, a milk-white opaque prominence. In this situation the thick wrinkled portion of the neck occasionally projected, sometimes spontaneously, sometimes in consequence of gently rubbing the upper eyelid. Then slowly came out the thinner thread-like half, ending in a head with four suckers and a double circle of hooks. (The latter circumstances, however, were not distinguished till the animal, after extraction, had been examined with the microscope.) The body of the animal changed its figure, more or less quickly, from the ordinary globular to an oval or pyriform shape. It generally lay half a line from the margin of the cornea, on account of the narrow interval between the two parts at their circumference. The neck hung downwards like a leaden plummet; it was not attached, but moved freely, and changed its position according to the movements of the head, always passing downwards. In the course of seven months it had become twice as large as when first observed, and had attained the magnitude of a pea, when it was extracted alive by Dr. Schott, through a small incision of the cornea. It was put in lukewarm water, and continued to move more than half an hour; it then became gradually opaque and white, and we could plainly distinguish with the microscope the four prominent suckers with their orifices, and the double circle of hooks in the middle of them. As it corresponded in all respects, not only with the delineations of Göze and Bremser, but with other similar specimens from the human body, which I compared with it, I could have no hesitation in considering it as a *cysticercus cellulosæ*, which, so far as I know, has never been observed in the human eye, although, according to Van der Hooven, it is found in that of the pig." (*Lib. cit.*, *Erstes Heft*, pp. 8, 9.)

The case of another patient, in whose eye there is a living cysticercus, has been recently published, by Mr. Logan of New Lanark, in a pamphlet which I have not seen. A description of the appearances, illustrated by

* The pigs, in whom these hydatids or cysticerci are found, are said to be *measled*: and their flesh is called *measly* pork. The French term the affection *ladrerie*; while the Germans call these parasitic creatures *Finnen*. Hence Blumenbach has derived the name of *hydatids finna*, under which he has described this hydatid, in his Abbildungen Naturhistorischer Gegenstände, No. 39, with an engraving of the creature, both of the natural size, and in an enlarged view.

two wood-cuts, has been sent to the *London Medical Gazette*, (Vol. xii. p. 110–112.) by Mr. MACKENZIE of Glasgow. The disease exists in a lively and otherwise healthy girl seven years of age. From the month of August, 1832, to the following January, there had been repeated attacks of inflammation in the left eye, which had rendered the cornea nebulous, and still continued so severe as to threaten loss of sight: the inflammatory symptoms, however, subsided, leaving a slight opacity of the cornea. "After a week the child was again brought to Mr. LOGAN, who, on examining the eye, discovered, to his great surprise, a semi-transparent body, of about two lines in diameter, floating unattached in the anterior chamber. This body appeared almost perfectly spherical, except that there proceeded from its lower edge a slender process, of a white color, with a slightly bulbous extremity, not unlike the proboscis of a common house-fly. This process Mr. L. observed to be of greater specific gravity than the spherical or cystic portion, so that it always turned into the most depending position. He also remarked that it was projected or elongated from time to time, and again retracted, so as to be completely hid within the cystic portion, while this, in its turn, also assumed various changes of form, explicable only on the supposition of the whole constituting a living hydatid." Mr. MACKENZIE found the cornea slightly nebulous: he adds, "When the patient kept her head at rest, as she sat before me, in a moderate light, the animal covered the two lower thirds of the pupil. Watching it carefully, its cystic portion was seen to be more or less spherical, and then to assume a flattened form, while its proboscis I saw at one moment thrust suddenly down to the bottom of the anterior chamber, [see fig. 127], and at the next drawn

Fig. 127.

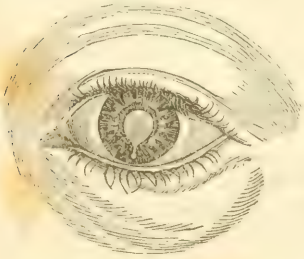

Fig. 128.

up so completely as scarcely to be visible. [See fig. 128.] Mr. MEIKLE turned the child's head gently back, and instantly the hydatid revolved through the aqueous humor so that the proboscis fell to the upper edge of the cornea, now become the more depending part. On the child again leaning forward, it settled like a little balloon in its former position, preventing the patient from seeing objects directly before her, or below the level of the eye, but permitting the vision of such as were placed above." As the child was healthy, and the eye free from inflammation, it had not been thought advisable to institute any treatment in reference to this parasitical inhabitant of the anterior chamber.

In a few weeks after the preceding account had been drawn up, it was thought proper to make an incision in the cornea for the purpose of removing the hydatid, which had become larger, and caused vascular disturbance and pain in the eye. Violent action of the muscles ensued by which the lens was forced out and the hydatid ruptured. The remains were removed in shreds, being so delicate as scarcely to bear the slightest touch.

After the eye had recovered, the patient could merely distinguish the presence of light. (*Practical Treatise*, edit. iii. p. 912.)

The *cysticercus cellulosa* has also been found in the subconjunctival cellular tissue, and under the integument of the eyelid. Mr. ESTLIN removed one in the former position near the internal canthus in a girl six years old. The small tumor caused by its presence had been unattended with pain or inconvenience. (*London Medical Gazette*, vol. xxii. p. 839.)

In a boy of fourteen, there was a swelling in the left temple communicating with an elevation of the mucous membrane in the mouth. The latter was punctured, when several hydatids came out with glairy fluid. Afterwards swelling and suppuration of the upper eyelid took place, and the part was punctured. Pus was discharged with six or eight cysticerci cellulosæ, about the size of small peas. (Mr. MACKENZIE's *Practical Treatise*, edit. iii. p. 909.)

[Dr. HŒRING of Louisburg, relates a case in which a *cysticercus cellulosa* of the size of a pea existed, under the conjunctiva at the external angle of the eye. The patient, a girl of seven years of age, had hurt the eye against the edge of a tub. Dr. H. thinks that the development of the hydatid is to be ascribed to this hurt. (*Journ des Conn. Med. Chirurg.*, Dec. 1841.) Dr. BAUM of Dantzic, and Dr. FLORENT CURIER of Brussels, have each met with this parasite; the former in a tumor, under the conjunctiva, at the internal angle of the eye; the latter in a similar tumor in an individual seventeen years of age.]

CHAPTER XXV.

AFFECTIONS OF THE ORBIT.

SECTION I.—INJURIES.

FRACTURES of the orbit, whether simple or compound, single, comminuted or attended with displacement; gun-shot injuries of the same part, and diseases of the bone or of its membranous covering, such as enlargement, (*hyperostosis*,) exostosis, caries, periostitis, whether simple, syphilitic, or scrofulous, must be treated according to the general principles applicable to the management of such injuries and diseases, which, however, are more serious here than in many other situations, from the near neighborhood of the eyeball and brain. Diseases originating in various neighboring parts, such as the brain, the antrum, the nose and its sinuses, may make their way into the orbit, and cause displacement of the globe. This circumstance must be borne in mind when we are endeavoring, in a case of obscurity, to ascertain the cause on which protrusion of the eyeball depends.

Penetrating wounds of the orbit.—When wounds occur within the margin of the cavity, their depth is of more consequence than their extent; indeed, the smaller are the more dangerous, as a small pointed instrument is more likely than a larger one to penetrate into the orbit. Here the external wound affords no criterion of the internal injury and danger. A slender and sharp instrument may easily pierce the bony roof of the orbit, which is as thin as paper at some points, and thus wound the brain. Some of the muscles or nerves, contained in the cavity, may be divided or injured, the position of the globe being consequently changed, and its motions more or less affected.

Lastly, the entrance of a foreign body into the orbit often displaces the globe, pushing it out between the palpebræ, where it remains in the state technically termed exophthalmia. It is thus protruded by pressure of the thumb at the external angle, in the barbarous practice of gouging, which is still allowed in fighting, in some parts of the country. The globe itself escapes injury from its spherical figure; it can hardly be wounded, except on its anterior surface.

All penetrating wounds of the orbit are to be regarded as serious cases, when we do not know how far the injury has extended, and should be treated accordingly until the period of danger is passed. The patient should be kept quiet and should not employ the eye; the bowels ought to be emptied and a light diet enjoined, the symptoms being carefully watched, so that the earliest indications of danger may be noticed and properly treated.

[*Wound of the orbit; Rupture of the Optic Nerve.*—A very curious example of this very rare injury, is recorded by Mr. PHILLIPS, in the *London Medical Gazette* for Jan. 1841.

A man, standing at the head of a horse which had fallen in the street, was suddenly struck in the face, upon the animal raising itself up unexpectedly: the blow was so violent that he was thrown down by it. He was of opinion himself, that it was not the head of the horse, but some part of the harness that struck him. There was a bleeding wound between the *left* eye and the nose, extending for about three-quarters of an inch from the internal canthus, to about an inch below the eyebrow. The lachrymal ducts, and the tendon of the orbicular muscle were divided across; but the eyeball had not suffered. The sight of the opposite, or the *right* eye was lost from the moment of the accident; and yet no alteration could be perceived in any part of it, except extreme dilatation of the pupil, which did not contract, even upon the approach of a lighted candle. The patient complained of a slight headache, but nothing indicated the existence of any lesion within the cranium. Delirium, however, and stupor supervened on the following day; and as these symptoms were attributed to the invasion of meningitis, the patient was accordingly bled, purged, and treated with repeated doses of calomel and antimony. In the evening, convulsions came on; while the left arm and leg were stiff and contracted, the right extremities were in constant motion; the pupil of the right eye was now found to be contracted. As the patient could no longer swallow pills, calomel was applied on the tongue; a blister also was applied to the nucha. The left side and extremities became subsequently paralytic, while the right were tranquil. He died convulsed on the fifth day after the accident.

Dissection.—There was a marked vascularity also, and a copious effusion of lymph, between the arachnoid membrane and the pia mater. A quantity of serum and pus were found in the lateral ventricles. Upon lifting up the anterior lobes of the cerebrum, they were observed to adhere by their lower surface to the dura mater, in consequence of effused coagulable lymph. The right optic nerve was found to be fairly torn across; the two ruptured ends adhering together only by a thin membrane, close to the optic foramen. The base of the brain, from the medulla oblongata to the commissure of the optic nerves, was invested with a thick covering of plastic lymph, which partly concealed the roots of the nerves. At the posterior part of the right anterior lobe, and near to the seat of the lacerated nerve, there was a small spot where the cerebral substance was in an ecchymosed and softened state. This injury of the encephalon, as well as the laceration of the nerve, had been caused by a spicula or fragment of bone, detached from the circumference of the optic

foramen. Upon examining the orbitar wound attentively, there was found a small aperture, by which a probe could be made to pass through the breach in the ethmoid bone into the cranium. This showed that the instrument, which the horse's head had driven in the direction of the opposite orbit, had been pointed, and that it must have struck with force on the *os planum*, passing from below upwards to the cerebral lamina of the ethmoid bone of the opposite side.

Dr. Rognetta appends the following observations to the history of the preceding case.

"Although there are several analogous cases recorded in surgical works, the present one is in some respects, almost unique. The most remarkable circumstance connected with it, is the direct lesion of the optic nerve, of the side opposite to that of the wounded orbit. We know that the optic nerve may be wounded directly in the orbit, by a pointed instrument entering by its external canthus; for, as it describes a curve with its convexity outwards, it is readily accessible from this part. But, before the case related by Mr. Phillips was made known, we had never heard of an injury of the inter-cranial portion of one optic nerve by an instrument which had entered by the internal canthus on the other side.

"It is worthy of notice that in this, and in other somewhat similar cases, where the optic nerve alone has been injured, the ball of the eye usually does not exhibit any outward marks of the lesion; the only symptom present being amaurotic blindness. In a dissection made by Cheselden, and in another by Morgagni, the optic nerve had been for a length of time disorganized from spontaneous disease; and yet the eye in both instances retained its normal features in every respect. Do not such facts show that the optic is purely a sensory nerve, and has nothing to do with the nutrition of the eyeball?

"Dupuytren used to mention the case of a fencing-master, who met with his death in the following manner. His adversary's foil, though guarded with a button, pierced through the wire fence of his mask, and struck him at the base of the right upper eyelid, making a small wound there. He fell down, and was carried to the Hôtel Dieu. On the morrow, alarming encephalic symptoms, delirium, convulsions, coma and fever, supervened, and he died two days afterwards. On dissection, the orbitar plate of the frontal bone was found to have been pierced by the point of the foil, which had penetrated so deep as to wound the anterior lobe of the brain. Another case very similar to this one, occurred in one of the pupils of the Polytechnic school; he remained hemiplegic.

"The same sort of accident has been known to be caused by a blow with the point of a cane, of an umbrella, of a fork, of an awl, &c. &c. In a few rare instances, the optic nerve has been lacerated by a violent luxation of the eyeball itself."]

Protrusion of the globe; exophthalmia.—If the globe should have been thrust out between the lids, the nerve is rendered insensible. We should ascertain whether any foreign substance remains in the orbit, and if so, remove it. The globe is then to be gently replaced; it returns easily and remains in its situation. If the latter should not be the case, it must be retained by a soft, folded linen rag, dipped in water and confined by a light bandage. Rest of the eyes, and of the body generally, and antiphlogistic treatment with spare diet, will be proper. Vision is soon restored in these cases, if the globe should have been merely thrust between the lids: such a displacement involves no considerable stretching of the nerve. Beer mentions the case of a young man, who had received a blow on the external angle of the eye by a tobacco-pipe, violently thrust in his face by a

fellow-student. When BEER came, there was complete exophthalmia, and the cornea was turned towards the nose. He found and extracted from the orbit a piece of the pipe, nearly an inch long, when the globe returned of itself into the cavity, the cornea being still turned inwards, and the patient having a very feeble perception of light. In five weeks vision was perfectly restored, but the eye was still directed towards the nose, and could scarcely be moved in the opposite direction, probably from injury to the external straight muscle. (*Lehre*, vol. i., § 167.)

Penetrating wounds of the orbit, without apparent injury of the globe, or optic nerve, when neglected, have sometimes given rise to violent inflammation, involving the eye, and ending in loss of vision.

Cases of exophthalmia from accident are recorded, in which replacement of the globe has not been effected for some days, or even weeks, but has been accomplished ultimately, with restoration of vision, when there has been simple protrusion without any other injury.

If the muscles and nerves should be extensively wounded, the globe may be loose, and insensible to light; it will probably slip out of the organ again, after being replaced. It should be restored, and gently confined in its situation.

SECTION II.—ACUTE INFLAMMATION AND SUPPURATION OF THE ORBITAL CELLULAR TEXTURE.

Phlegmonous inflammation and abscess may occur in the cellular texture behind and around the globe. If, according to some descriptions, the affection should be combined with inflammation of the globe, the combination must be very rare; for I have not seen an instance of it.

When we consider the vascular and nervous structures which compose the contents of the orbit, their close contiguity with the sensorium; further, the direct membranous continuation between the periorbita and the fibrous sheath of the optic nerve on one side, and the dura mater lining the cavity of the cranium on the other, we shall not be surprised to find, that inflammation of the orbital contents is characterized by the most violent and agonizing pain deeply seated in the orbit, extending over the whole of the head, and accompanied by a sensation of tension and bursting, as if the contained parts were too large for the cavity in which they are lodged. As the bony socket cannot give way, the swelling of the parts behind, pushes the globe forwards, distending the lids, and making them unnaturally protuberant. The inflammation soon extends to the palpebræ, which become red and swollen by œdematous effusion. The slightest attempt to move the eye excites acute pain, and the patient therefore keeps the organ perfectly still. In conjunction with the local symptoms, there is violent inflammatory fever; the patient is delirious at night, and continues so for several nights in succession. As the disease proceeds, all the symptoms are aggravated to a pitch which is almost intolerable. The globe of the eye is thrust further out, often beyond the palpebræ. Under such circumstances the retina is rendered insensible to light. The pain intermits a little; throbbing and rigors are felt; suppuration takes place, and an abscess is formed, without, however, any material relief to the patient, since the bony parietes of the orbit cannot yield. Ultimately the matter makes its way to the surface, either presenting at some part of the orbital margin, or under the lid, in which latter case it pushes forwards the fold of the conjunctiva passing from the lid to the globe.

BEER* has described this affection as involving the globe of the eye, together with the surrounding soft parts. Should such a combination occur, symptoms denoting inflammation of the external and internal tunics of the eye will be added to those already described. The eye is thrust out, the sclerotica becomes red, the conjunctiva is inflamed, the iris changes its color, and the sufferings of the patient are of course aggravated.

Treatment.—If we see the complaint in an early stage, the violent pain, and the general febrile disturbance, clearly point out the necessity of vigorous antiphlogistic measures. When the presence of fluctuation shows that matter has formed, an opening should be immediately made into the collection; by this proceeding we shall relieve the patient, and limit the extent of the local mischief. When the symptoms point out that matter has formed, although we may not feel fluctuation, it is best to make an opening, by means of a lancet or double-edged bistoury, in the situation where the matter appears to be deposited, taking care not to injure any part of consequence.

Some time ago I saw two instances of this affection, in which the local and general symptoms were characterized by a degree of violence seldom seen in other cases. One was that of a young man between twenty and thirty years of age; he came to me accompanied by his wife, who told me that he had suffered such agonizing pain for three or four preceding nights, that she feared he would have gone out of his mind. In this case matter was presenting just under the superciliary ridge; after making a free opening, a large quantity issued out, and a probe introduced at the puncture went to the bottom of the orbit.

In the other case, that of a child between three and four years old, the local and general symptoms were equally severe; the matter presented between the lower lid and the globe, but the quantity discharged on making an opening was not considerable. In both instances the globe of the eye was protruded, but not actually thrust out between the palpebræ; and after the matter had been discharged it receded to its natural situation. In the child, vision was restored; but in the adult, the eye, although it had not been inflamed, remained amaurotic.

I am indebted for the following report of a case of abscess of the cellular tissue of the orbit, with inflammation of the eye, treated by me in Wills' Hospital, to Dr. G. W. BURWELL of Buffalo, formerly resident physician of the hospital.

Maria Scanlin was admitted into Wills' Hospital Nov. 9, 1842, service of Dr. HAYS, with general inflammation of the tissues of the left eye, iritis, &c., and for an abscess of the cellular tissue of the orbit, which, at the time, was discharging by two openings through the conjunctiva on the temporal side of the ball and some three lines from the edge of the cornea. These openings were also about three lines apart, one above the other, and elevated. The eye was of the natural prominence at this time. The previous history of the case is as follows: She had always been a healthy girl until May, 1841, when she had the small-pox, which was immediately followed by inflammation of both eyes. She was confined to a dark room for three months—the symptoms were the usual ones and the treatment antiphlogistic—various eye-waters were applied to the eye, the nature of which she does not know. In Sept., 1841, she was so much better that she could go out into the air. From this time,

* Lehre, vol. i. § 346—353. He states that it is one of the most uncommon forms of ophthalmic inflammation (p. 340), and that the prognosis, even in the first period, is never favorable, at all events very uncertain (p. 344). The affection was not of this formidable character in the cases detailed in the text; but it will be observed, that in them the globe was not involved.

until Oct. 12, 1842, she suffered from a number of slight attacks of inflammation, especially during the winter and spring, but all of which soon yielded to the treatment followed. At this last-mentioned date the left eye got sore, the right one being but little affected. It became very much injected, "was as red as blood," with supra-orbital and temporal pains, so severe as to prevent sleep, and became swelled to the size, she thinks, of a hen's egg, extending an inch beyond the brow. It remained in this state about two weeks, when a discharge of matter commenced, accompanied with a mitigation of the pain and a reduction of the prominence. At the time of her entrance it had been running profusely for two weeks; this continued, but gradually decreasing, for about four weeks more, accompanied with a sinking in of the eye, until now the lids cover it almost entirely, even on an effort to open them. The ball is also much atrophied with several irregular indentations about it; the closure of the pupil complete and the cornea nebulous.

Treatment.—On account of the iritis she was, at her entrance, placed upon the use of the blue-pill carried to slight ptyalism, and an ointment of equal parts of belladonna and ung. hydrar. camph. directed to be applied around the brow and temple. On the occurrence of ptyalism there were no signs of dilatation of the pupil, although a reduction of the inflammation of all the tissues and of the remaining pain was the consequence. It was soon after repeated without effect. She was then, on account of the strumous and weakened condition of the system, placed upon preparations of iron, sulphate of quinine, a meat diet, &c., under which she rapidly recovered strength and tone of constitution. No treatment was directed to the right eye except sol. argent. nit. gr. ij to f℥i for a slight ulceration of the cornea, and afterwards sulphate of cadmium gr. j to f℥i for a nebulous opacity, which had existed from the time she had the variola.

A very curious and unusual circumstance in this case is, that the pus forced itself away between the conjunctiva and sclerotica, and was then discharged through the former coat.

Two interesting cases of subacute abscess, in the cellular tissue of the orbit, are related by Dr. O'Ferrall, in the *Dublin Hospital Gazette*, March 1, 1846.

Case I.—Ellen Moran, aged 20; black hair, brown complexion, and well nourished; presented herself at the Hospital, on the 4th of May, 1844.

History.—She was always healthy, until the autumn of 1842, when she had fever. From the effects of this disease she recovered very slowly, and with some interruption to the menstrual functions. At the end of a year she was completely restored to health, and continued well until about six months ago, when she had sore throat, with fever, which confined her to her bed for sixteen days. From this also she recovered, and regained her usual health.

About a fortnight since, after exposure to night air, she felt a severe pain in the eyebrow and eye of the left side. The pain was always very severe in the evening and night, but in the early part of the day was so much mitigated, that she, every morning, hoped the pain was about to subside altogether. This induced her to defer seeking for medical advice, until, after seven days, she observed the upper eyelid to "bulge out." She now lost her appetite, and occasionally vomited her food. She became unable to attend to her business of a dress-maker, and came to St. Vincent's Hospital for relief.

Present state.—There is swelling, with redness, of the superior eyelid of the left eye. It engages the portion of the lid, superior to the trans-

verse fold. The part of the lid below this fold is of the natural appearance in every respect.

The most prominent part of the swelling occupies a place beneath the eyebrow, and about midway between the external and internal angle of the lids, perhaps a little nearer to the latter. The centre of the tumor yields to the finger—the remaining portion is firmer, and the integument, covering it, is red and œdematous. The motions of the lower or movable portion of the lid, that which is below the fold, are perfect, and the eye can be completely covered at will. The globe of the eye is, manifestly, on a plane lower than the eye of the opposite side, by a quarter of an inch. There is no visible projection of the organ; vision is perfect. The eye is more sensible than usual, to light, and sparks have been once or twice perceived, when in the dark.

She is not conscious of having had rigor. The bowels are irregular; renal secretion turbid; pulse 86; skin rather warm. Menstrual functions undisturbed.

There could be no doubt, that the globe of the eye was depressed by a tumor in the adipose and cellular tissue of the orbit; and it was nearly certain, that this swelling, of comparatively recent origin, was of an inflammatory nature. The diagnosis, then, was, *abscess in the orbit, depressing the globe of the eye.*

Treatment.—A mild aperient was administered, and a diaphoretic anodyne prescribed at bed-time. On the following day, a straight bistoury was passed into the most prominent part of the tumor. An immediate gush of healthy pus took place; the quantity was near half an ounce.

The opening was dilated, and a dossil of fine lint laid between its edges. The whole was covered with a bread poultice.

On the following day, the report states, that she had slept well; the usual nocturnal pain was relieved. A free discharge was maintained, by due attention to the opening. At the end of four days the discharge began to lessen in quantity, and the eye had already ascended in a slight degree. At the end of a month, the opening was permanently closed, and the globe of the eye was on a level with the other eye. A slight depression marked the situation of the opening made by the bistoury. The motions of the eyelids were performed as usual, but she described a sort of stiffness, as accompanying the elevation of the upper lid.

Case II.—Mr. T——, of Summer-hill, came to consult me, in October last, under the following circumstances:

He was returning to town, from Londonderry, in the night mail, a fortnight before, when, the coach being full, and feeling oppressed, he was tempted to keep the window near him open, for nearly two hours, during which time he occasionally slept. He felt chilled, and his right eye became tender, and he then closed the window. The soreness of the eye subsided; and on his arrival in town, he dressed, ate his breakfast, and went abroad, thinking no further of the occurrence of the night. The following night he went to bed, much fatigued, and soon slept. He was disturbed, however, about midnight, by severe pain in the ball of the right eye, which completely prevented sleep for the remainder of the night.

In the morning, he had leeches applied to the temple, by his apothecary, who also administered aperient medicines. He was relieved for a time, but the pain returned at night. Leeches were again applied, with the same relief, but the nocturnal exacerbation recurred as before. He now consulted a medical gentleman, who, he states, told him he had inflammation of the globe of the eye, and recommended calomel and opium.

This plan he continued until the gums became sore, but the pain at night still destroyed his rest.

His condition, when he consulted me, was as follows. He held a large pocket-handkerchief to his face, partly to protect the eye, and partly to catch the saliva, which flowed freely from his mouth. The upper eyelid was red and swollen. The globe projected at least half an inch beyond its natural limits. It descended, also, on the cheek more than half an inch below the level of the other eye. There was no chemosis, and the conjunctiva presented only a few stray vessels. The iris was of the natural color,—the pupil regular in shape, but larger than on the other side. Vision was imperfect—sparks were occasionally visible—light was not complained of, and it had little effect upon the pupil, when the other eye was closed. The redness of the upper eyelid commenced at the line of the eyebrow, and terminated rather abruptly at the natural fold of the lid, leaving a space of integument, between that line and the ciliary margin, of the natural color, and capable of covering the eye.

The inflamed portion of the lid was œdematous. When pressed, it gave the sensation of a firm swelling underneath, and this swelling extended from one angle of the orbit to the other. No soft point or fluctuation was perceptible. The examination occasioned very great pain. His tongue was white, swollen, and moist. His skin hot, pulse 110, full and soft. He had some slight diarrhœa during the night. He had occasional chills.

Considering the absence of inflammatory redness on the conjunctiva, sclerotic, or iris, and the limitation of this state, in the lid, to the upper or orbital portion, I had no hesitation in deciding, that the swelling was located in the orbit, *above the fibrous investments of the globe.* It was, also, probable that this inflammation had already ended in the formation of matter. There was no distinct yielding at any point, but the patient winced more when pressure was made about the centre of the swelling.

Having explained to him the nature of his case, I passed an exploring needle into the most prominent part of the swelling. A small stream of well-formed pus oozed along the groove of the instrument. Without disturbing the latter, I then passed a very narrow bistoury along its groove, and having reached the cavity of the abscess, withdrew the exploring needle, and turned the blade of the knife, so that its flat surfaces looked upwards and downwards. The incision was then dilated, and free exit given to the matter. Immediate relief followed this proceeding. The edges of the wound were kept apart by a slip of lint, and a poultice laid over all. The quantity of pus discharged was certainly more than half an ounce.

From this period, his sleep returned, and his appetite and spirits improved. The opening continued to discharge for nearly a month—the quantity gradually lessening, until it ceased altogether. The probe could not detect any evidence of disease in the bone.

The eye gradually receded, as the obliteration of the cyst was accomplished, and ultimately seemed to occupy its proper place. Vision, also, improved, and, when I last saw this gentleman, was scarcely less perfect than that of the other eye. A slight indentation marking the situation of the puncture, was much concealed by a natural prominence of the eyebrow.]

SECTION III.—CHRONIC ABSCESS IN THE ORBIT.

The inflammation is sometimes of more chronic character, with less severe symptoms: matter forms, and advances to the surface more slowly. I saw a child, two years old, for an affection of the right eye, which was

said to have existed for a week. The globe projected half an inch further than the left, and was pushed outwards. The internal angle, the neighboring part of the lids, and the side of the nose, were red and swelled. On careful examination, I thought that deep-seated fluctuation was obscurely perceptible; the gentleman who accompanied the patient could not feel it. The child had not suffered much; its rest had not been interrupted. Leeches had been applied twice. From a consideration of the history and symptoms, I concluded that suppuration had taken place in the orbit, and that an opening ought to be made. I accordingly punctured with a lancet, which entered to the depth of three-quarters of an inch, when a dessertspoonful of thick well-formed pus flowed out. A small bit of lint, spread with simple cerate, was introduced to maintain the opening. At the end of a week, the puncture had closed; the eye had regained its natural position; and the swelling at the internal angle had disappeared.

Mr. Ware has observed, that the suppuration in these cases is sometimes slow, so that, if the matter be deep-seated, the eye will be protruded before fluctuation is discovered. In a child, six years old, thus affected, he says, "I passed a lancet on the side of the eye next the nose a little below the commissure of the eyelids, at least an inch into the orbit, before I reached the matter. On withdrawing the instrument, its point was evidently marked with pus. I therefore enlarged the puncture with a blunt-pointed bistoury, and discharged a considerable quantity, which was thick and putrid. It was necessary to preserve the opening by the insertion of a small dossil of lint: on the removal of which, a vent was given daily to new matter for a fortnight. Its quantity gradually decreased, together with the prominence of the eye; and at length it wholly ceased, the wound healed, and the child became well. The motion of the affected eye, however, was not quite free towards the nose for several months afterwards." (*Observations on the Treatment of the Epiphora*, &c. &c., 1811, pp. 292—293.)

A case of orbital abscess, singularly slow in its progress, is related by Mr. Mackenzie.

A lady received a severe blow over the right eyebrow, by coming suddenly in contact with a lamp-post. Four years after, one of her relations observed a difference in the appearance of her eyes, but she herself noticed no change for another period of four years, when she observed that the right eyeball protruded. The protrusion gradually increased, and was attended with photopsia, double vision, dimness of sight, and sense of tension. At the end of twelve years from the accident, there was a tumor with obscure fluctuation at the upper and inner part of the orbit: no pain had been felt in it: the eyeball was pushed downwards and outwards. The eyelids, particularly the upper, were distended, but not discolored. Rigors had never been experienced. A large quantity of pus, first flaky, then healthy, was let out by puncturing the tumor. Discharge of matter continued for six months. The eyeball ultimately regained nearly its natural position, and vision was perfect. (*Practical Treatise*, edit. 3, p. 299.)

Propagation of inflammation from the orbit to the contents of the cranium.—Inflammation in the orbit may involve the fibrous membrane lining the bone, and affect the bone itself; it may then extend to the dura mater, and even to the brain: thus serious and fatal disease may be excited within the cranium. The possibility of such an occurrence renders it imperatively necessary to use active antiphlogistic means in the first instance, and to evacuate matter as soon as we can satisfy ourselves of its existence. The following case mentioned by Borsieri illustrates these points.

Case.—*Abscess in the orbit, with suppuration of the anterior lobe of the brain.*—A lady, twenty-five years of age, was seized with acute pain in the

left side of the head, which lasted fifteen days. At length the left eye became red and swollen, and, in a few days, the eyelids and neighboring parts formed a large red swelling, which was attended with considerable feverish disturbance. Antiphlogistic measures were adopted, but suppuration occurred in a few days, and a large quantity of fetid pus came out of a spontaneous opening near the external angle of the eye. The swelling now subsided, so that the eye could be seen. The conjunctiva was intensely red, and very tumid, the cornea transparent, the pupil dilated, and vision destroyed. On the fourth day after the rupture of the abscess, general and strong convulsions came on, followed by paralysis of all the limbs, loss of the senses, languid and stertorous respiration, small and intermittent pulse, and death. The space between the globe and the orbit was filled with fetid pus, which extended also under the eyelids and cheek. The left anterior lobe of the brain had suffered by suppuration almost as far as the lateral ventricle. The optic nerve was surrounded with pus, but not diseased; the matter communicated with the cavity of the orbit. (*Institut. Medicinæ Practicæ*, vol. iii. pp. 14—16, note.)

An instance somewhat similar has been recorded by Professor FISCHER of Prague.

A man twenty-seven years old, had an upper molar tooth of the left jaw extracted. Severe pain in the part followed. In a few days, profuse flow of tears took place from the left eye, and discharge from the left nostril with pain in the head. Soon rigors came on, with severe pain in the head and intolerance of light; then swelling of the cheek and eyelids, with fixed state of the eyeball, which was somewhat protruded, and agonizing pain of pulsating character; these symptoms being accompanied by intense fever. An opening was made at the inner angle, and a considerable quantity of offensive matter was discharged. Considerable relief was experienced, and copious flow of matter continued. In a few days, symptoms occurred denoting affection of the head; convulsions ensued with stertorous respiration and insensibility, and the patient died apoplectic. The blood-vessels of the dura and pia mater covering the left anterior lobe of the brain were distended, and the membranes themselves discolored. There was a large collection of pus in the anterior lobe, communicating with the lateral ventricle, which, as well as the fourth, contained matter. The suppuration in the anterior lobe, communicated with the abscess of the orbit through an opening in the orbital plate of the os frontis, which was dark-colored, and broke down under slight force. (*Klinischer Unterricht*, p. 9.)

In a case recorded by Mr. GUTHRIE, of a bayonet wound, followed by inflammation of the orbit, and of the eyeball, the latter "was protruded, the lid could not be raised so as to explore the eye, which was highly inflamed; chemosis had taken place, vision was indistinct, the iris was discolored, the pupil contracted, the pain was excruciating, both in the eye, which felt as if it were too large for the orbit, and all over the forehead and temple of that side; flashes of light, of various colors, darted through the eye, in consequence of the surrounding pressure upon it; the swelling increased, the patient became delirious, and an abscess burst in the upper eyelid on the fourth day, without any alleviation of the symptoms. He soon after became comatose and died, I have little doubt, from the formation of matter within the head. The eye had previously been lost by sloughing of the cornea." (*Lectures on the Operative Surgery of the Eye*, p. 146.)

"I have known," says Mr. MACKENZIE, "deep-seated abscess of the orbit to prove fatal, the patient having for a day or two shown symptoms of pressure on the brain, and in fact dying apoplectic." (*Practical Treatise*, p. 34.)

SECTION IV.—PROTRUSION OF THE GLOBE FROM CHANGES IN THE CONTENTS OF THE ORBIT OF OBSCURE NATURE.

I have mentioned displacement of the globe, or exophthalmia, in describing the symptoms of those affections to which it is incidental. I shall, therefore, now advert shortly to the cases, in which the causes producing the protrusion are obscure.

It sometimes occurs as a temporary affection, under circumstances which lead us to refer it to inflammatory swelling of the orbital contents, not sufficiently active to cause suppuration, or to effusion into the orbital cellular texture.

Case I.—*Partial protrusion of the left eyeball, after erysipelas of the face consequent on fever.*—Charles Hutten, a sailor, aged forty-two, was received into the London Fever Hospital the 10th of July, 1831, laboring under feverish symptoms, which had commenced without any obvious cause, three weeks before. On the 3d of August, as he was recovering from the fever, erysipelas of the face came on. The palpebræ were considerably swollen on the 6th, although the parts affected with the erysipelas were not much reddened. The eye became slightly protruded on the 12th, the erysipelas having disappeared on the preceding day. He was admitted into St. Bartholomew's Hospital on the 16th, when the projection of the globe had considerably increased. The left eye was now more prominent than the right by three-quarters of an inch. The conjunctiva covering its lower half, considerably distended with serous effusion, overlapped the under lid, so as to present, at first, the appearance of ectropium. No inflammatory symptoms were present; the eye and orbit were free from pain; vision was a little impaired. The patient, being weak, was placed on broth diet; a rag dipped in cold water was applied over the lids and brow. A saline aperient draught was directed occasionally. 22d. Twelve leeches near the eye. 7th September. The eye has regained its natural position and aspect. Vision is perfect; a small glandular tumor is seated below the jaw; six leeches to the swelling, and poultice afterwards. 14th. Discharged perfectly well.

Case II.—*Protrusion of the eyeball, with impaired vision.*—Richard Gilbert, a healthy young sailor, thirty years of age, came under my care, at the London Ophthalmic Infirmary, on the 18th of February, 1826, with the complaint above-mentioned. The displacement had come on gradually, and had not existed long; without being considerable, it was quite conspicuous, and produced an unpleasant appearance and expression. The health was perfectly good. Blood was twice abstracted by cupping; mercurial alteratives and aperient medicines were afterwards administered and continued till May. He was then dismissed cured, with vision perfectly restored, and the globe nearly in its natural position.

I have seen some instances, in females, of protrusion of the globes, so that the palpebræ would not come together. The eyes, unusually denuded in front, have had an unpleasant appearance of enlargement and projection. Surgical treatment has alleviated the symptoms and checked the progress of the complaint, without entirely removing it.

Mr. Middlemore has recorded an instance of the foregoing description, in which protrusion of the eyes was preceded and accompanied by severe pain in the head, attended with something like a slight epileptic attack every five or six days. The pain was moderated after several months of active treatment by bleeding, and the administration of mercury; but the protrusion continued, so that a large part of the sclerotica is exposed, and

the patient, a young woman, has a remarkably disagreeable staring appearance. (*Treatise*, vol. ii., p. 504.)

"In some instances," says Mr. WARE, "a projection of the eye appears to be occasioned solely by a morbid accumulation of the substance on which the eye rests in the orbit. The repeated application of leeches on the temple and forehead has been found of great use in subduing this morbid tendency. In one case, that came under my own care, the projection was speedily diminished by opening the temporal artery; and, after the hemorrhage had ceased, by converting the orifice into an issue, the discharge from which became soon very considerable. In another case in which the protrusion occasioned great pain, and nearly destroyed vision, a perfect cure was accomplished by the application of a large caustic behind the ear. The discharge which it occasioned, when the eschar separated, was profuse; and it was kept up nearly a month, by the insertion of a dozen peas daily."

"I have occasionally met," says Mr. TRAVERS, "with cases of proptosis to such an extent, as to occasion a morbid change upon the cornea, with a varicose state of the vessels of the conjunctiva; and with others in which, although the cornea remained clear, the vision was materially deranged, when the cause of the protrusion was altogether obscure, and the progress of the disease had been so slow as to occupy a period of several years. In these cases both eyes are equally affected; they are attended with a distressing degree of deformity, obtuse pain in the forehead, and other occasional signs of determination of blood to the head. It is probably a morbid increase of the adeps contained in the orbit, obstructing its circulation, as well as protruding the eyeball."

CASE III.—*Protrusion and destruction of the globe, from acute inflammation in the orbit: subsequently, induration of the adipous and cellular substance, and extirpation of the orbital contents.*—A young man of thirty, previously healthy, came under my care in St. Bartholomew's Hospital, on the 4th of April, 1827. He had travelled from Brighton to London in an open cart, on one of the coldest days of the preceding January, and had suffered most severely. The left arm and leg were benumbed, so that he could not move them, and he did not recover the use of them for three or four days. He also experienced pain in the left eye; but in a fortnight the lids swelled and closed, with distracting pain in the eye and side of the head. He was in constant agony night and day, and he got no rest until he was completely exhausted by suffering. Cupping on the temple, repeated leechings, shaving and blistering the head, gave only partial and temporary relief. When he came to the hospital, the eyeball was pushed forwards and upwards, projecting, by comparison with the other, about three-quarters of an inch. The upper lid slightly inflamed and protruded, could not be elevated by the patient. The lower lid was everted by a considerable swelling of the conjunctiva, which was red, and loaded with serous effusion. The globe was natural; the iris moved freely, but vision was so imperfect, that the largest letters could not be seen. Nothing issued from a deep puncture, made on the supposition of matter having formed in the orbit; but at the end of three or four days pus was discharged copiously. The pain now ceased, the swelling of the lids and the protrusion of the globe lessened, and sight improved, so that the patient could read small print. After some time bare bone could be felt towards the bottom of the orbit, and matter was discharged from the left nostril; on holding the nose and expiring, air came freely through the puncture. This subsequently closed, when the pain and protrusion of the eye returned; the latter, indeed, became more considerable than before, and vision was lost. In August

another free incision was made, with temporary relief, and air again passed through the puncture. The probe entered deeply, and discovered a large excavation below the eye.

Severe pain about the orbit and side of the head continued; numbness of the cheek and jaw came on, with increased redness of the eye and lids, and greater protrusion, these symptoms receiving only a temporary alleviation from local bleedings and narcotics. The protrusion of the globe was now more than an inch; the pupil largely dilated, the iris motionless, and vision lost, except the mere power of distinguishing light from darkness. In November, the conjunctiva of the globe, which had hitherto remained nearly natural, became of a deep red, while the cornea lost its transparency, and then sloughed, the humors escaping, and the iris protruding in an irregular dirty-looking mass. The inflammatory, sloughing, and ulcerative process, by which the cornea had been destroyed, in this case, resembled what Magendie has described as the consequence of dividing the nerve of the fifth pair in animals; it was probably owing to an analogous cause, as the morbid growth which caused the protrusion, must certainly have compressed, or otherwise injured the infra-orbital, and perhaps the ophthalmic branch of the nervus trigeminus. The evacuation and subsidence of the globe did not diminish the patient's sufferings, nor the external swelling, which, on the contrary, still increased. As the complaint had now been progressive for many months, in spite of active treatment, both local and general, and as the health, although in other respects good, was suffering under the constant severe pain, I proposed to remove the contents of the orbit, being persuaded that the operation afforded the only remaining chance of relief: the patient readily assented to the proposal, and the operation was performed on the 6th of December. The palpebræ were freely separated at their external commissure, and then turned aside, so as to expose fully the anterior aperture of the orbit, the entire contents of which were detached from the cavity, by dissecting close on the surface of the latter, first below, then above and at the sides, until the posterior connection alone was left. The latter was then divided by a knife curved on its flat surface, the patient experiencing excruciating but momentary agony when the muscles and nerves were divided. The mass, which was hard, completely filled the orbit, so that the dissection was necessarily carried on close to the bone, and performed slowly. As the ophthalmic artery bled profusely, a conical compress of lint was introduced into the cavity, and held for some time on the vessel. This was removed in the evening, without renewal of hemorrhage. The divided commissure of the lids was united by two sutures, and the tumid upper eyelid closed the front of the orbit. He took thirty drops of laudanum at night. 7th. He slept at intervals, and passed a comfortable night; bloody fluid had oozed between the lids, but there had been no actual bleeding. The palpebræ are swollen and bright red; the face is flushed, and he has slight headache, thirst, and foul tongue. (Twelve leeches round the margin of the orbit; saturnine lotion; a dose of calomel and jalap.) The inflammatory and febrile symptoms had disappeared on the next day, and the pain of the brow, head, and cheek which had distressed the patient for so many months, was almost gone. Recovery now proceeded rapidly and uninterruptedly, the surface of the orbit granulating, and producing a vascular substance, which filled up a large part of the cavity; rest and appetite returned, and the patient soon regained his flesh, strength, and good looks. He left the hospital perfectly well on the 28th of December. The right eye, which had been sympathetically affected before the operation, regained its full strength.

The mass removed from the orbit consisted of the collapsed and shrunk

eyeball in front, with a hard and incompressible substance behind, extending to the point at which the nerves and vessels had been divided. The recti muscles, unaltered in color or texture, covered this substance, the exterior of which had the usual appearance of the orbital fat, except that it was more dense. An incision was carried from before backwards, directly through the centre of the entire mass. An apparently recent coagulum of blood separated the sclerotica from the choroid coat, the latter, with the retina, being compressed by the coagulum into a thick cord, extending from the optic nerve to the iris. There was no trace of the humors. The sclerotica was unchanged: the morbid growth adhered to it closely behind, and the optic nerve proceeded through the centre of the mass. The latter was a dense compact structure of scirrhous firmness, resisting the edge of the knife; its exterior consisted of a light gray texture, very much like that of a scirrhous breast, while in the interior this was intermixed with a light yellow, yet firm substance, resembling what is seen in scrofulous diseases. I use the term "scirrhous" merely to describe the sensible characters of the structure, and not to convey an opinion that it was of carcinomatous nature. I did not entertain the slightest apprehension that disease would return: yet, on reviewing the history of the case, and comparing with its course the bulk and texture of the morbid growth, I could not doubt that the latter would have continued to enlarge, and the sufferings of the patient to increase had the disease been left to itself.

Mr. Mackenzie has related a case in which the globe was occasionally protruded, the cause and nature of the affection being quite obscure.

"The patient was a cooper by trade, and was admitted at the Glasgow Eye Infirmary, for catarrho-rheumatic ophthalmia affecting chiefly the right eye. After he had attended for a few days, it was discovered that if he stooped forwards, although only for a few minutes, he felt as if something was filling or pressing above his right eye, which immediately began to protrude: on raising his head the protrusion was very striking. In this state he saw indistinctly with the eye. It soon began to retire, and in a few minutes was in its natural place. He had the complete power of moving the eye, when in its natural situation, and moved it considerably even while it was displaced. The iris moved naturally. He complained of considerable pain in the orbit, which was relieved by venesection, and the use of mercurial purges. He stated that the protrusion of the eye commenced about five years before his application at the Eye Infirmary, after carrying a heavy load on his back. It was difficult to assign any satisfactory explanation of the case." (*Practical Treatise*, edit. 3, p. 280; note.)

SECTION V.—INDURATION OF THE ORBITAL CELLULAR TEXTURE FROM SLOW INFLAMMATION.

"I have repeatedly seen," says Mr. Mackenzie, "the cellular substance near the front of the orbit become hard and tuberculated, in consequence of slow inflammation, occasioned by an injury. In one instance a piece of limestone struck the outer edge of the orbit, producing a lacerated wound of no great extent, and which readily healed. Some time after, a small hard swelling formed at the site of the injury, was extirpated, and was found to contain a minute fragment of limestone. After some months, another small tumor made its appearance in the same spot, and in connection with it another, attached so firmly to the edge of the orbit, that it was taken for an exostosis. In a few weeks, a third circumscribed swelling was discovered running along the lower edge of the orbit, more movable

than that last mentioned, but firm to the touch as a piece of cartilage. The patient was under the care of Mr. SAMUEL CLARKE of this town, whom I assisted at the removal of the tumors. The two which felt so like exostoses, lay partly within the orbit, and adhered firmly to its periosteum. On making a section of them, they presented a white striated texture of scirrhus. The extirpation was accomplished after a semilunar incision, running parallel to the outer and lower edge of the orbit, and every particle of indurated substance was carefully removed. Nearly a year has elapsed since the operation, and there has been no return of the disease." (*Practical Treatise*, p. 265.)

SECTION VI.—TUMORS IN THE ORBIT.

The cellular texture in the orbit, like that in other parts, may become the seat of the various adventitious growths called tumors. These may be sarcomatous, steatomatous, or encysted, the latter being met with much more frequently than the two former kinds. Sometimes, but rarely, tumors in the orbit have been of malignant character.

The encysted tumors may contain watery fluid, a viscid fluid like white of egg, or various thicker matters, so as to come under the technical denominations of meliceris, or atheroma: in two or three recorded instances they have contained hydatids.

From the limited space which the orbit affords for their increase, these productions interfere with the other important contents of the cavity, and often seriously injure the optic nerve or the globe by their pressure. They may arise in various parts of the orbit; and they grow not unfrequently at some distance from its anterior aperture. As they enlarge, they push the globe forwards, and stretch the optic nerve, at the same time displacing the former downwards, upwards, outwards, or inwards, according to the part of the cavity in which they are produced. Ultimately they may thrust the eye out of the orbit and between the lids, so as to cause complete exophthalmia. According to the degree of pressure or displacement, imperfection or loss of sight takes place. Sometimes they are attended with pain from the first; in other cases we do not suspect the disorder until sensible displacement of the globe, and impaired vision have occurred. Finding no other sufficient cause for these symptoms, we carefully examine the anterior aperture of the orbit, when we may be able to discover obscurely the presence of a swelling. The enlargement of this, with the aggravation of the other symptoms, in process of time renders the nature of the affection unequivocal.

When the existence of a tumor in the orbit has been ascertained, the most advisable course, indeed the only effectual means of removing the complaint in the great majority of instances, is that of extirpation by a surgical operation. The sooner this is accomplished the better. The growth of the disease, and its consequent pressure on the globe and optic nerve, may not only thrust the eye out of its socket, with more or less considerable deformity, and injury or loss of sight, but may also cause absorption of the orbit, at its upper part, and thus affect the brain.

The mode of proceeding in the operation will vary according to the position and size of the tumor. If it should not be large, nor extend deeply, an external incision may be made through the integuments near the edge of the orbit, and parallel to the course of the fibres of the orbicularis. This incision should be ample, in order to facilitate the exposure and dissection of the tumor. In some instances, when the swelling is large, it may be

necessary to resort to the expedient of slitting up the external canthus, as in the extirpation of the globe, and to remove the tumor from the inside of the lid. We must then detach it from its surrounding connections by a cautious dissection, keeping the knife close on the surface of the tumor, that the neighboring parts may not be injured. As the wound is deep when we come to the back of the tumor, and speedily fills again with blood after sponging, the operation is conducted by feeling and anatomical knowledge, rather than by sight. The danger and difficulty, however, are not considerable enough to induce us to follow the example which some have set, of separating the part behind by dragging with the fingers or by the blunt silver knife. We must proceed slowly, and the object may then be accomplished with the ordinary scalpel without risk. Firm hold may be taken of the swelling when it is exposed, with a double hook or ligature passed through it, and thus the detachment will be facilitated. If hemorrhage should continue after the operation has been concluded, the patient should go to bed, and have the lids and neighboring parts sponged with cold water until the blood ceases to flow. The edges of the wound may then be approximated, either by means of sutures or otherwise; and the best dressing will consist of a soft rag or doubled piece of lint kept damp with cold water, or a portion of lint thinly spread with spermaceti cerate. To fill such a wound with extraneous substances, such as lint or sponge, is the most likely way to produce secondary hemorrhage, or inflammation, and suppuration; it cannot answer any useful purpose. The impropriety of such proceedings in the treatment of wounds generally has been long recognized; why should a remnant of the ancient practice be preserved in wounds close to the eyeball, and very near the brain, and its membranes?

Steatomatous tumors.—Morbid growths removed from the orbit have sometimes been mentioned under the name of steatoma, but without an exact description of their composition and nature. Hence, as that term is often used loosely, we cannot determine whether these steatomatous orbital tumors were properly so called, being encysted and containing fat, or whether they were of the sarcomatous kind.

Dr. Hope removed from the orbit, in a girl of eighteen, a tumor which had been growing seven years. At first it did not appear outwardly, but it increased gradually, and formed a firm swelling, reaching from the internal to the external angle, protruding the lower lid, and thrusting the globe upwards and outwards, so that the pupil was three-quarters of an inch further from the nose than that of the other eye. Vision was imperfect, but not lost. It was removed by an incision carried through the integuments of the lower eyelid. It proved to be a spherical swelling, smooth and even, about the size of a small pigeon's egg, extending nearly to the back of the orbit, and of "carnous substance." The eye gradually receded to its natural position, and vision was completely restored. (*Philosophical Transactions*, No. 474, p. 194. *Phil. Trans.*, abridged, vol. x., p. 251, fig. 61.)

Dr. Monteath has shortly mentioned two cases, in one of which there was relapse of disease.

"The first was in a young girl. The tumor was in the upper and outer side of the orbit. In order to get at it, I was obliged to cut across, perpendicularly, the whole breadth of the upper eyelid, and dissect back the two flaps. The tumor was nearly the size of a plum, and reached as far back as the eyeball. It was slightly encysted, perfectly organized, and of anomalous texture. The healing of the wound was rapid, and, contrary to my expectation, the eyelid united perfectly, and regained very nearly its natural power and extent of motion. The eyeball did so also, and the vision was perfect. This girl went to England some months after, and I was con-

cerned to learn from the surgeon under whose care she was, that the tumor had begun to grow again.

"The second case was in a young adult woman. The disease was of two years' standing before I was consulted, and had produced hideous exophthalmos. It was found impracticable to extirpate the tumor without also removing the eyeball, which was accordingly done. The tumor exceeded the size of the eyeball, lay directly behind it, and so completely encircled the optic nerve, that the latter was diminished one-half in thickness by the pressure of the tumor. The vision had been rapidly declining previously to the operation. This tumor was exceedingly hard, of anomalous texture, and surrounded by a layer of condensed cellular substance. The anterior aspect of the tumor touched and pressed upon the posterior aspect of the eyeball, but had no connection with it, except through the medium of the optic nerve and of the cellular substance. This young woman has continued well for twenty months, and is in perfect health." (*Translation of Weller's Manual of the Diseases of the Eye*, vol. i., p. 195, note.)

Langenbeck removed from the orbit of a woman forty years of age, a "steatomatous tumor," which was connected to the globe and its muscles. The swelling, situated behind the lower lid, reached from the inner to the outer angle, and extended to the upper margin of the orbit: it was firm to the feel, and somewhat movable. The eye was pushed upwards and inwards, but natural in appearance; the iris exhibited its usual motions, but vision was lost. The lids were separated at the external commissure, and the tumor was then dissected away by cutting through the conjunctiva. The globe gradually returned to its proper position, the deformity caused by its displacement was completely removed, and the patient was able to see the smallest objects before she left the hospital. (*Ein Beytrag zu den abnormen Metamorphosen in der Orbita, mit der Erscheinung von Exophthalmos;* in the *Neue Bibliothek für die Chirurgie und Ophthalmologie*, vol. ii., pp. 238—240. Tab. i., fig. 1.)

Another case of steatomatous swelling, related by Langenbeck, exemplifies the serious results which occasionally follow the operation. The patient was a healthy robust man, forty years of age. The operationpresented no difficulties, and after its performance, the globe, which had been considerably protruded, returned to its natural situation. In the course of the day restlessness, loss of speech, involuntary discharge of feces and urine took place, and the patient died comatose on the following morning, in spite of large bleeding, and cold applications to the head. It was afterwards discovered that he had been intoxicated with spirits the evening before the operation. No morbid appearances were discovered, except in the anterior lobe of the brain, on the side of the operation, and in the corresponding superior surface of the orbit. They showed all the traces of inflammation, such as change of color and purulent exudation. There was no communication between the tumor and the cavity of the cranium. (*Lib. cit.*, pp. 241—244.)

Langenbeck removed from a lady of thirty, a steatoma, which had caused not only considerable protrusion of the eye, but also a conspicuous enlargement of the external side of the orbit. Violent pain of the head had attended the origin and development of the deformity. The patient recovered favorably from the operation; the headache ceased; the eye partly returned to its situation in the orbit, but the unnatural prominence of the latter, in its temporal region, was unaltered. After some months, periodical pains in the head returned, and became more and more violent; coma and

death ensued. The body was not examined. (*Lib. cit.*, p. 244. Tab. i., fig. 3.)

Medullary tumors in the orbit —Case.—T. Larkin, sixty-five years of age, a laborer from the county of Kent, of swarthy complexion, and spare habit, who had generally enjoyed good health, excepting that he had experienced two attacks of ague, which is common in his part of the county, came under my care in St. Bartholomew's Hospital, on May 10, 1838. Two years previously he had observed a swelling coming forwards from under the upper edge of the left orbit, which, as it increased, pushed the eye forwards and inwards, causing dimness of sight, and sometimes double vision. A year ago he began to feel pain in the region of the orbit, particularly towards the inner canthus: it was worse at night than in the day. The eye had not been dry. At the time of admission there was a tumor under the upper and outer edge of the left orbit, nearly as large as the last joint of the thumb. The eye, still covered by the palpebræ, was pushed forwards and inwards; vision very imperfect; objects situated laterally could be seen indistinctly; the lachrymal secretion normal. The tumor was even on the surface, with a sense of fluctuation, or, at least, of softness. It obviously passed back into the orbit, and might be presumed, from the protrusion of the globe, to occupy the posterior portion of the cavity. There was pain at night, sometimes preventing sleep. We considered that the case was either encysted tumor or medullary growth. A small puncture was made in the softest part of the swelling on the 12th, when a dessert-spoonful of turbid yellowish fluid was discharged. A director introduced into the opening passed nearly to the back of the cavity. No hemorrhage ensued: the apparent bulk of the swelling, and the position of the eye were not altered. The puncture soon healed; and I proceeded on May 19th, to remove the swelling. When denuded by division of the skin and orbicularis palpebrarum, it was found of reddish color, very vascular, and of soft consistence, so that it quickly gave way when I attempted to insulate it by dissection. The handle of the scalpel passed with perfect ease through the swelling to the back of the orbit. I therefore scooped out the soft substance with the finger and the knife handle, as perfectly as I could, leaving a large excavation between the roof of the cavity and the orbital contents. There had been profuse bleeding throughout the operation, and blood flowed freely from the surfaces exposed. The sides of the external wound were brought together; the patient placed in bed; and cold cloths, frequently renewed, were laid on the eye and forehead. The oozing of blood had ceased before night. The case went on quite favorably; the eye did not pass back into the orbit, but its projection was lessened, and the patient represented that his vision was improved. He left the hospital in the beginning of July. I saw him again more than a year after. There was a little preternatural fullness in the former situation of the swelling, but no distinct morbid production. He promised to come to me immediately if there should be any ground of alarm; but I have not seen him since.

The morbid growth in this case was so soft, that it broke down under slight pressure of the finger or instrument. A director or the handle of a knife passed through it almost without the feeling of resistance. It was rather friable than of brain-like consistence. The color was reddish gray; the vessels numerous and large, and blood issued from all points as if from a sponge. In color, consistence, and vascularity, it closely resembled some soft malignant growths, which came under my observation about the same time in other parts of the body; particularly one in the thigh, and another in the forearm, both of which ended fatally after operation.

In the following two cases, fungus hæmatodes, or a disease equally malig-

nant, occurred in the orbit as a separate tumor, which affected the eyeball merely by pressure.

Case I.—*Large medullary tumor in front of the orbit, extirpated; relapse of disease in the neck, and death.*—A man, thirty years of age, of good constitution and health, was received into the surgical clinic of Heidelberg, in February, 1831, had a large tumor occupying the front of the right orbit, which had begun to grow nine years before. He had at this time an inflammatory affection of both eyes, with impaired vision. The left recovered; but the sight of the right became worse and worse, and was at last entirely lost. At the same time a small excrescence appeared between the eye and the lower lid, and gradually increased. It was as large as two fists when the patient came under the care of Professor Chelius at Heidelberg. It was of a deep red, ulcerated at various points, and bleeding freely, even when slightly touched. The mass was extirpated in February, 1831. Its structure was medullary or cerebriform, firmer at one part, softer, to the consistence of jelly, in another; it was partly dark colored, partly lighter. The eyeball entire, but diminished in size, was found at the upper and anterior part of the tumor. The sclerotica was not perforated at any point, but it had become thick and hard at the entrance of the optic nerve. The cornea could be still distinguished, and a portion of the iris. The crystalline was shrunk and ossified, the ciliary processes still distinguishable, as well as remains of the pigmentum and retina. The optic nerve was considerably elongated and reduced in size, but healthy in structure. The healing process went on favorably, and the patient was allowed to leave the clinic in April. In September of the same year he was seen in excellent health, without any return of disease. Intelligence was afterwards received that this patient died from a swelling, which appeared in the lower part of the neck, and extended in front of the chest.*

Case II.—*Medullary tumor in front of the orbit, extirpated; relapse of disease.*—A Hebrew girl, seven years old, struck the right side of the head against the ground in a fall, receiving no other injury than a slight graze of the skin, near the external angle of the eye. Three weeks after, a small swelling, not differing in color from the rest of the skin, appeared on the middle of the right upper eyelid. This increased rapidly, and soon became reddish, instead of white, which it had been originally. It was twice punctured without any other effect than the escape of some clear blood. When the patient entered the surgical clinic at Heidelberg, eighteen weeks after the fall, the swelling was as large as a goose egg, deep red, with a shining surface, which exhibited numerous vascular anastomoses. It was movable, and soft. It covered the eye completely, but there was no reason to suppose that the organ was involved, as the patient had been able to see a little fifteen days before. The tumor was removed, together with the eyeball, on the 13th of October, 1820. It was solid, of sarcomatous and medullary composition, in some parts even cartilaginous; it contained numerous vessels. In three weeks the cicatrization was nearly completed, but in the fourth week a small tumor showed itself near the internal angle of the eye, and increased so rapidly that it was again removed on the 27th of December. It was now discovered that the tumor extended through the orbital parietes towards the nose. In a few days the growth reappeared; but the termination of the disease was not known. (*Lib. cit.*, pp. 45—48, plate 2, fig. 2.)

Encysted tumors.—Encysted tumors are much more frequent in the

* Dissertation sur le Fongus médullaire de l'Œil; thèse présentée à la Faculté de Médecine, &c., par F. Bauer, Paris, 4to. 1830, pp. 41—44. The external appearance of the swelling is represented in plate 2, fig. 1.

orbit than those of the sarcomatous kind. In the greater number of cases, the cyst is thin, and its contents are an aqueous or glairy fluid:* under such circumstances, the nature of the disease may be indicated by the characters of softness and fluctuation in the swelling. If the cyst should be thick, and the contents of greater consistence, the case cannot be distinguished from that of a fleshy tumor. Encysted growths of the latter kind must be extirpated. The serous cysts which contain watery fluid or hydatids, may be obliterated by the inflammation consequent on puncture and exposure of the cavity. A knowledge of this circumstance, which will be fully proved by cases subsequently related, is of great importance where cysts, in consequence of their magnitude, and close connection to the globe and other surrounding parts, cannot be extirpated without sacrificing the contents of the orbit generally. BEER removed the globe with the cyst in such a case. (*Lehre*, vol. ii. p. 589, note.) That this severe proceeding is not necessary, will appear clearly from facts to be adduced presently.

LANGENBECK had under his care a young man with a swelling under the upper and outer part of the orbit, which pushed the eye downwards and inwards. It projected externally, and fluctuation could be felt in it. When an incision had been made through the integuments, and the tumor was denuded, it proved to be a shining white transparent bladder, as large as a pigeon's egg, which was removed entire. It contained fluid. (*Lib. cit.*, p. 241. Tab. i. fig. 2.)

An interesting case of orbital encysted tumor is related in the fourth volume of the *Medico-Chirurgical Transactions*,† by Mr. BARNES, of Exeter. The patient was a healthy youth of seventeen. "The tumor was situated beneath the eye, occupying a very considerable portion of the orbit; the eye in consequence being pushed into the upper part of that cavity, so as to be almost wholly hidden behind the upper lid. On turning it backwards, it appeared to extend to a very considerable depth; and it projected so much in front, as to constitute a very striking deformity."—"The ciliary edge of the lower tarsus, with a few scattered hairs in it, crossed the front of the tumor, rather above its middle; the conjunctiva, drawn forwards from the eyeball, greatly stretched, but not apparently much altered in structure, investing it above; and a thin skin of a deep red, loaded with purple vessels, covering it below; but neither of them closely adherent to it. The portion of the tumor in front was soft, and could be moulded into different shapes by the fingers; the posterior division felt more elastic." He could not elevate the upper lid, but when it was lifted, so as to expose the pupil partially, objects could be imperfectly distinguished. There was scarcely any power of moving the eye to different points. "The swelling was first observed in early infancy and was at that time not much larger than a pea. It increased but slowly, until about four or five years since, when it began evidently to enlarge, and for some time it grew rapidly. Latterly it had not advanced much. The sac adhered firmly to the outer angle and part of the lower edge of the orbit; elsewhere its connections were loose. It was found to extend almost to the bottom of the orbit, and to occupy more of the cavity than the eye itself did. The contents were evacuated by a puncture in order

* "The encysted tumors which I have found between the globe and the orbit have always been of the aqueous kind (*hygroma*), and have appeared, either as a swelling of the lachrymal sac (*dacryops*,) or as an hydatid of the lachrymal gland." BEER, Lehre, vol. ii. p. 589. He mentions, however, in a note, that he had met, in one instance, with a large watery cyst external to the lachrymal gland.

† Case of a double encysted Tumor, the posterior cyst of which, situated deeply between the eyeball and the floor of the orbit, was attached to, and partly contained a tooth, pp. 316—321. Plate 1, figs. 1 and 2.

to get room. On the inner side, and about an inch from the edge of the orbit, the sac seemed to embrace a sharp bony process arising from the surface of the cavity, but slightly movable, as if attached to the periosteum only. This body was removed without difficulty, together with the connected portion of the cyst; it turned out to be a tooth. The tumor was made up of two cysts, separated by a deep groove all round, but indissolubly united in the centre. The interior of the front cyst was rough, with a little chalky matter adhering to it. The contents were a compact lardaceous substance. The inner surface of the posterior sac was smooth, excepting a part near the tooth, where it had much the appearance of coarse skin with many pores in it. The contents were partly a whey-colored fluid and partly a yellow curdy substance. The eye gradually sunk to its natural situation, so that, within a fortnight, it was nearly on a level with the other. The vision of this eye was perfect, but its motions were very limited.

Dr. Bushe published in the Lancet, "*a case where the right eye, and a large encysted tumor, were successfully removed.*" In November, 1826, J. Albatt, seven years of age, was, without any known cause, affected with protrusion of the right eye, which gradually increased. In April, 1829, there was considerable exophthalmia, with total loss of vision, and a great tendency to torpor. A tumor could be felt above the globe, which was pushed downwards and forwards. Some of those who saw the case supposed, from the situation of the swelling, its rapid growth, and the accompanying cerebral symptoms, that it was a fungus from the anterior lobe of the brain. As there was no affection of the brain in the commencement, Dr. Bushe considered that the alarming symptoms arose from the pressure of the tumor on the brain, and proposed extirpation, to which the parents consented when the progress of the disease had caused more serious symptoms, viz., coma, partial paralysis of the left side of the face and upper extremity, with a dilated and immovable condition of the pupil. The commissure of the lids was divided, and the tumor partially separated from the orbit: it was found so closely connected to the globe, that it could not be removed without the latter. "I, therefore," says Dr. Bushe, "drew the contents of the orbit downwards and forwards, by inserting a curved needle, armed with a strong ligature, through the edge of the tumor and globe of the eye; I now cautiously proceeded to detach the tumor at its posterior part; but, before I had proceeded far, I was not a little surprised to find, that what I had anticipated was correct, viz., that the tumor pressed on the anterior lobe of the brain, the posterior and superior part of the roof of the orbit being absorbed; however, I cautiously pursued the separation of parts to the foramen opticum, and finally divided the optic nerve and recti muscles with a curved scissors. Slight hemorrhage followed the operation, but was easily restrained by a portion of sponge. In ten days the wound had nearly healed, and the little patient was walking about without any inconvenience." (*Lancet*, 1827–8, vol. ii. p. 430.) No description is given of the extirpated parts; an omission which detracts greatly from the value and interest of the case.

Case.—*Immense cyst in the orbit, containing serous fluid, treated by incision and obliterated by subsequent inflammation and granulation.*—The following case, which is related by Delpech, in the second volume of his *Chirurgie Clinique*, (pp. 92–98, plate xxxv.,) is that of a girl, twenty-four years old, in whom the disease began at the age of three, after a fall, in which the back of the head struck the ground. The accident was followed by pains in the head, which soon went away; but the right eye began to project, and became inflamed; sight was lost, the globe was thrust out of the orbit and between the lids, so as to form the apex of a large tumor.

When this patient was received into the hospital Saint Eloi, at Montpellier, a conical tumor, more than six inches in height, seemed to issue from the right orbit. Its circular basis measured nearly twelve inches in circumference, and contained a bony ridge, which was easily distinguished as the anterior aperture of the orbit enormously enlarged. Corresponding alterations had necessarily occurred in the form and position of the superciliary ridge, the temple, cheek, and upper jaw, as well as in the angle of the mouth, which was depressed, and in the nose, which was strongly turned towards the left. The eyebrow and the eyelids, singularly stretched, were seen at the circumference of the swelling. A line, scarcely perceptible above and below, marked the ciliary margin of the latter, in which there were a few cilia. The tumor, with the exception of its central and prominent part, was covered by the conjunctiva, converted, by exposure to the air for twenty-one years, into an artificial cutaneous texture, but still delicate and susceptible of occasional inflammation. The situation of the cornea was marked in the apex of the cone, by a small surface of a light blue tint. The tumor generally was elastic and fluctuating, and the fluctuation was more manifest at the apex, and in the situation of the lower lid. Professor Delpech concluded, from the good constitution and perfect health of the patient, together with the history of the case, and the state of parts just detailed, that the disease was a cyst developed in the bottom of the orbit; and that an attempt to procure its obliteration might be made with a fair prospect of success. He punctured the swelling a little behind the situation of the ciliary margin of the lower lid, when a limpid or rather slightly yellow serosity escaped. He then enlarged the opening horizontally, to the extent of two inches, and introduced his finger into the cavity, which he found to be lined throughout by a thick membrane consolidated with the parts on which it was expanded. Towards the centre, the parietes of the swelling were scarcely thicker than elsewhere, so that the globe must have been shrunk and nearly effaced. The swelling subsided considerably after its evacuation. The interior of the cyst was filled with bundles of charpie tied with waxed thread, which were renewed every six days. The discharge, at first serous, became opaque, and then purulent. The febrile disturbance, concomitant on the suppuration, was attended with pain in the stomach and bowels, thirst, and occasional vomiting; and these symptoms lasted, in spite of all remedies, until the introduction of foreign substances into the cyst was prevented by its obliteration. For the first month, the cavity underwent no diminution. On the sixtieth day the swelling had shrunk to one-half its former size, and the cavity was reduced to a small sinus. In three months the cicatrization was complete; the swelled parts then shrunk rapidly, and were retracted towards the orbit; she left the hospital in good health at the end of four months. When she was seen after the lapse of twelve years, the parts had completely retired within the orbit, of which the dimensions were greatly reduced; and she wore a simple black patch.

Case of hydatid in the orbit, with protrusion of the globe, and blindness; removal of the hydatid by an operation; recovery of sight.—A peasant, twenty-five years of age, experienced, in the beginning of 1820, sharp pain in the right eye, which he compared to that caused by a foreign substance under the eyelid. It disappeared soon. In January, 1821, he had a severe pleurisy, with inflammation of the same eye, which went off, but left the sight weakened. It is probable that the protrusion had begun then, though the patient had not observed it. In a short time inflammation of the eye returned, with swelling of the lids and pain. Ultimately sight was lost. The patient came to the hospital Saint Eloi in November, 1822.

The eye was then considerably displaced, distending the lids, which covered it imperfectly. The iris was motionless, the pupil fixed, and vision was gone. There was a little redness of the conjunctiva. The integuments of the palpebræ were raised by a tumor, which was particularly distinguishable towards the external angle, and distended the upper more than the lower lid. There was a deep-seated and rather equivocal fluctuation in the swelling, from which, together with the other circumstances of the case, Monsieur DELPECH thought it probable that the swelling was caused by a serous cyst. He made a curved incision along the outer half of the upper lid, the external angle and one-third of the lower lid. After the orbicularis had been divided, the lachrymal gland came in view, displaced from its fossa, and enlarged. The projecting part was removed to give room. A serous cyst was soon discovered, but it could not be completely denuded until the levator palpebræ superioris had been cut through in half its width. The cyst was now punctured, and about three ounces of nearly colorless serous fluid escaped. Immediately a white membranous mass presented at the opening; when seized, it readily came out, and proved to be a large hydatid (*acephalocyste*). The cyst was found, on examination, to be merely a condensation of the cellular membrane. The eye now returned to its situation. The cavity was gently filled with pieces of agaric, tied with waxed thread. The pain and fever in the evening required bleeding from the arm. On the fourth day some of the agaric had been pushed out of the wound: the dressings were renewed, and were repeated every day till the twelfth, when the wound would only admit a small bit of lint. On elevating the upper lid, which had been swelled after the operation, and was now reduced in size, the patient discovered that he had regained his sight; the iris now moved again, and the pupil exhibited the usual variations in size. On the fifteenth day the sinus was obliterated, and the patient left the hospital, completely cured, in a month after the operation. The eye had regained its natural situation, and its vision was nearly equal to that of the other. (DELPECH in *lib. cit.*, pp. 99–104.)

I consider the practice followed by Professor DELPECH in these cases, of filling the cavity, after the operation, with charpie or agaric, highly objectionable, as likely to excite and keep up serious inflammation. That the objects we have in view can be accomplished without it, is obvious from a case which I have related elsewhere, (*Medico-Chirurgical Transactions*, vol. xvii. pp. 44–46,) as well as from the following example.

Case of cyst in the orbit, containing hydatids, and causing protrusion of the globe; puncture of the cyst, and subsequent obliteration.—" Charles Rowell, forty-two years of age, was admitted, under my care, into the London Ophthalmic Infirmary on the 3d of January, 1820, with protrusion of the globe from the orbit by a deep-seated tumor, which had been growing for seven years. He had applied at the infirmary in an earlier period of the affection, when the unnatural prominence of the eyeball was distinctly marked, but vision had not become impaired. I could then feel obscurely, under the superciliary arch, a small firm protuberance, which seemed to be part of a deeply-seated swelling, and I considered that extirpation of this growth by an operation afforded the only chance of relief. The patient was averse to this measure, which was not strongly recommended, and he discontinued his attendance. The complaint had slowly increased, its progress having been attended with great pain, which for some months had been so severe, both day and night, as to cause emaciation and general weakness. When this patient was admitted into the infirmary, the tumor had advanced so far between the upper and inner portion of the eyeball and the eyelid as

to have thrust the globe completely out of the orbit. The upper lid, greatly stretched and inflamed, covered the eye and the tumor; the lower was completely everted, and its membranous lining appeared as a thick fleshy mass. The conjunctival covering of the globe was thickened by chronic inflammation, the consequence of exposure. The structure of the eye was uninjured; the pupil round, and about in the middle state; the iris motionless. Vision was destroyed. The tumor was firm, and apparently fixed to the orbit: it afforded, on pressure, an obscure sense of fluctuation. To relieve the distension and pain, and acquire some further insight into the nature of the disease, a puncture was made into the most prominent part of the swelling, and about a dessertspoonful of clear watery fluid escaped. Considerable diminution of suffering ensued. When I examined the part two days afterwards, I found a soft opaque white substance in the puncture, and proceeded to remove it with a pair of forceps; it proved to be an hydatid, and a few others escaped when pressure was made on the swelling. Some more came away on the following day, and I afterwards cleared out the whole collection, amounting to half a teacupfull, by enlarging the puncture and injecting water forcibly into the sac. The hydatids varied in size, from that of a filbert to that of a small pea; some were entire, others collapsed. Inflammation and suppuration of the cyst followed without much pain; the discharge then gradually diminished, and the opening closed in about a month. The eye returned to its natural situation, and all uneasiness ceased. In March, the only traces of the complaint were a loose and wrinkled state of the integuments of the upper lid, and the eversion of the lower, which was gradually diminishing by the application of lunar caustic to the thickened conjunctiva. A little motion of the iris and slight perception of light had returned." (*Lib. cit.*, pp. 48—50.)

[Some interesting cases of tumors in the orbit are related by Dr. O'Ferrall in the *Dub. Hosp. Gazette*, Jan. 15, Feb. 1 and 15, 1846.]

SECTION VII.—ANEURISMAL AFFECTIONS IN THE ORBIT.

In the following two cases the disease called *aneurism* by *anastomosis*, of which the nature is hitherto imperfectly understood, existed in the orbit, and was remedied by a surgical operation.

Case I.—*Aneurism by anastomosis in the orbit, cured by the ligature of the common carotid artery.*—"Frances Stoffell, aged thirty-four, a healthy active woman, of fair complexion, middle stature, and the mother of five children, on the evening of the 28th of December, 1804, being some months advanced in pregnancy, felt a sudden snap on the left side of the forehead, which was attended with pain, and followed by copious effusion of a limpid fluid into the cellular substance of the eyelids on the same side. For some days preceding, she had complained of severe pain in the head, which was now increased to so great a degree, that for the space of a week she was unable to raise it from the pillow. The œdematous swelling surrounding the orbit was reduced by punctures; an issue was set in the temple for a smart attack of ophthalmia, which supervened, and leeches and cold washes were applied. She now first perceived a protrusion of the globe of the eye, which affected the sight, and a circumscribed tumor, elastic to the touch, about as large as a hazelnut, appeared upon the infra-orbitary ridge. Another softer and more diffused swelling arose, at the same time, above the tendon of the orbicularis palpebrarum. The lower tumor communicated, both to the sight and touch, the pulse of the larger arteries; the upper gave the sensation of a strong vibratory thrill. The swellings grew slowly, and

the skin between the eyes and that of the lower eyelid became puffed and thickened. The globe of the eye was gradually forced upwards and outwards, and its motions were considerably impeded. She had a constant noise in her head, which, to her sensation, exactly resembled the blowing of a pair of bellows. The pulsatory motion of the tumors was much increased by agitation of mind, or strong exercise of body. But the most distressing of her symptoms was a cold obtuse pain in the crown of the head, occasionally shooting across the forehead and temples. She was compelled to rest the left side of the head on her hand when in the recumbent posture, and found the beating and noise to increase sensibly when her head was low and unsupported. Mr. Travers found that the thrilling tumor at the inner canthus had a loose woolly feel, was very compressible, and when firmly compressed, offered slight pulsation. The veins of the superior lid were distended and varicose, and those on the sides of the nose were turgid. "The lower tumor could be emptied or pressed back into the orbit, but the pulsation then became violent; and from the increased pressure of the globe upon the roof and side of the orbit, the pain was insupportable. Careful compression of the temporal, angular and maxillary arteries produced no effect on the aneurism. Upon applying my thumb to the trunk of the common carotid, I found the pulsation cease altogether, and the whiz of the little swelling was rendered so exceeding faint, that it was difficult to determine whether it continued or not." The common carotid artery was tied on the 23d of May, 1809; the pain in the head was immediately numbed, and the noise in the head entirely ceased; the small tumor over the angle of the eye still thrilled, but very obscurely. The recovery from the operation was favorable, and at the end of four months the tumors were smaller, and their motion materially diminished; the eye was less projecting, and the dull pain but rarely felt. On the 28th of October, she experienced miscarriage with profuse hemorrhage. This was followed by diminution of the swellings, and entire cessation of pulsation; the projection of the eye was also lessened. In May, 1811, no vestige of the disease remained, but a knob of the size of a pea, over the inner angle of the eye. I saw this patient two or three years after the date last mentioned; she continued perfectly well. (*Medico-Chirurgical Transactions*, vol. ii., pp. 1—16. Plate 1.)

Case II.—*Aneurism by anastomosis in the left orbit, cured by tying the common carotid artery.*—Dinah Field, aged forty-four, delicate and sickly, being then pregnant with her sixth child, was seized in the middle of the night with an intense pain in the left eyeball, accompanied by a whizzing noise in the head, which grievously distressed her. The attack was instantaneous: hearing a noise as of the cracking of a whip, and feeling an extraordinary pain in the left eye, she awoke in great pain, and leaped out of bed. Inflammation of the eye and swelling of the lids came on, with almost intolerable anguish in the left eyebrow and at the bottom of the orbit, and acute pain over the whole side of the head. The extreme violence of the pain abated the following night, but the swelling of the lids was rather increased. No further change took place in the next seven weeks, at the end of which she was delivered. Subsequently she lost the power of elevating the upper eyelid, and became totally blind on the diseased side. At the end of eight or nine months, there was constant and acute pain, chiefly referred to the bottom of the orbit: but the greatest suffering arose from an unceasing noise in the head, compared to the rippling of water, and becoming insupportable whenever the head fell below a certain level. The left eyeball was protruded, so as to distend the upper lid, and immovable. The cornea was transparent, the iris motionless, the pupil fixed, and a fawn-colored appearance was seen behind the lens. The

palpebræ were swollen, and the lower everted so as to form a bright red convex swelling. The tumid parts were soft and elastic to the touch, but contained portions of a firmer feel, which communicated a vibratory thrill on pressure. The integuments of the forehead, above the inner end of the eyebrow, and those on the inside of the nose, were elevated into a soft undefined tumor, giving a faint tremulous motion to a finger placed upon it. The veins of the face generally were turgid. Pressure on the common carotid artery nearly stopped the pulsation about the eye. The common carotid artery was tied by Mr. DALRYMPLE, on the 7th of April, 1813. "The effects of the operation were immediate and decisive. As soon as the ligatures were tied, the pulsatory motions of the tumors on the forehead and cheek entirely ceased; but a slight thrilling was still perceptible in the tumid upper eyelid. The red swelling of the lower eyelid became paler, and its surface shrivelled. A few minutes after the patient was placed in bed, she was quite free from pain, and the noise by which she had been so long tormented having now also ceased, she declared that her head no longer felt like her old head." At the end of two years from the operation, Mr. DALRYMPLE says that the cure appears complete, with the exception of the sight which is irrecoverably lost. No pulsation can be felt in any of the branches of the temporal and fascial arteries on the side of the operation. (*Medico-Chirurgical Transactions*, vol. vi. pp. 117—122.)

Mr. GUTHRIE has recorded an example of true aneurism of the ophthalmic artery on both sides, which terminated fatally. "The globe was protruded, but vision was scarcely affected. Hissing noise in the head was distinctly heard, and attributed to aneurism. On the death of the patient, an aneurism of the ophthalmic artery was discovered on each side of about the size of a large nut. The ophthalmic vein was greatly enlarged and obstructed near where it passes through the foramen lacerum orbitale superius, in consequence of a great increase of size the four recti muscles had attained, accompanied by an almost cartilaginous hardness, which had been as much concerned in the protrusion of the eye as the enlargement of the vessels." (*Lectures on the Operative Surgery of the Eye*, 2d edition, p. 168.)

[My friend Dr. JOHN C. WARREN, of Boston, relates, in his valuable work on Tumors, a very interesting case of aneurism in the orbit which occurred spontaneously in a servant girl 18 years of age, who was admitted into the Massachusetts General Hospital May 4th, 1829. Little more than a year before, she began to experience a strange feeling in the internal angle of the right eye, at the anastomosis of the fascial ophthalmic and frontal arteries, which soon extended to the head, and was accompanied with a pain so severe that though otherwise in perfect health, she was obliged to give up work.

At the period of her admission into the hospital, "there was a small tumor at the internal angle of the right eye, just above the lachrymal sac, as large as a hazelnut. It had an active pulsation which extended into the surrounding arteries. The pulsations of the fascial were very strong; and by compressing it, the vibrations of the tumor were much lessened. Compression of the temporal artery produced no change. The skin over the tumor was slightly reddened, and there was a sensible increase of heat; the carotid artery had an increased pulsation; pressure on this artery suspended the pulse of the tumor. The stethoscope applied to the carotid and fascial arteries, gave the saw-mill sound.

"Having observed the case for a few days, I performed the following operation on the 11th of October. A small incision was made between the tumor and the cavity of the orbit, the pulsation of the anastomosing

branch of the ophthalmic was discovered, and a ligature passed round this branch. Next an incision was made across the fascial artery below the tumor, and after allowing it to bleed about eighteen ounces, a compress was applied to include the artery and sac. On the division of the fascial the pulsation ceased, and the patient was relieved from her bad feelings. On removing the compression, three days after, a slight pulsation was perceived. The wounds healed immediately, and the patient finding herself very comfortable, was discharged on the 1st of June, although the pulsation had not wholly ceased. This was done at her own request, and I was disposed to believe that the cutting off the supply from these two vessels, must be followed by a disappearance of the tumor. The frontal branch was not divided at this time, because there was no pulsation in it.

"My expectations were disappointed. In the latter part of October of the same year, she entered the hospital again; a very slight pulsation was discernible in the tumor. The internal angle of the other eye had a pulsation somewhat stronger than that in the right eye. The arteries leading into it, had strong pulsations; the carotids on both sides, especially on the right, throbbed violently, so that she said she felt sometimes as if 'the top of her head was flying off.' The upper part of the face and forehead were red and swollen; and on the whole, there was a great aggravation of disease. I was at a loss how to proceed under these circumstances, as the disease now appeared equally on the left and on the right sides, and extended apparently to the whole arterial system of both. It seemed, therefore, proper to begin the effect of general remedies. The patient was ordered to be kept perfectly quiet, to live as low as possible; to have blood taken from the arm and leeches applied frequently to the head; and she also took the tincture of digitalis. These measures were followed by no favorable effect. I therefore laid bare and penetrated the temporal artery of the right side, allowed it to bleed freely, and then divided it. No permanent mitigation of symptoms followed; the vibrations and their distressing consequences remained unmitigated. There seemed but one course remaining—that of tying both carotids, or rather of tying one, and if this did not answer, the other. On the 2d of January, 1830, I tied the right carotid. The pulsations of the right side were immediately relieved. Those of the left side continued for a time, then slowly subsided, and on the 3d of March, she was discharged perfectly well.

"There are two important pathological facts brought into view by this case. The first is the sympathy of the arterial system of one side of the head with that of the other. The vibratory action of the vessels of the right side produced corresponding vibrations in those of the left. Hence arose some embarrassment in the treatment of the case, since it seemed probable that the cure of the original affection would leave behind it a disease equal in amount to itself; and it never could be determined whether this would be the fact, but by actual experiment. In the period of disease which succeeded the operations on the fascial, ophthalmic, and temporal arteries, the phenomena were in truth more conspicuous on the left than on the side originally deranged. So very striking were they, that I was entirely at a loss whether the ligature of the right or left carotid would be most likely to be useful. The perfect success from tying the right carotid, showed that the affection of the left side was altogether sympathetic; yet certainly it is remarkable that the two great arteries like the carotids, should seem to be so much under the influence of the nerves, as to take on this sympathetic action; unless we

deny the doctrine that the pulsations of the great arteries are dependent principally on the action of the heart, and allow that they act from their own power." (Pp. 400—4.)

Dr. WARREN briefly alludes also to a similar case in which there was a pulsating tumor at the inner angle of the right eye following a blow on the part. This tumor affected the vision of that eye; and extended into the orbit so that he could not reach the ophthalmic branch within the tumor; he therefore tied the carotid artery, but without any alleviation of the disease. He would then have attempted the angular arteries; but the patient refused, left the hospital, and he lost sight of her. (*Op. cit.*, p. 407.)

My colleague, Dr. ISAAC PARRISH, has also recorded an interesting case of aneurism in the orbit, resulting from a blow, in a boy admitted into Wills' Hospital.—See *Amer. Journ. of the Med. Sci.* for Oct. 1841.]

[PERIOSTITIS OF THE ORBIT.

The periosteum lining the bones of the orbit may become inflamed. 1st, from injuries, 2d, from cold and the other causes of inflammation, and 3d, from certain constitutional diseases, as syphilis, rheumatism, or scrofula.

The characteristic symptoms of this affection, which seems to be a rare one, are, severe pain in the orbit, supra-orbital region, temple and side of the head, with periodical nightly exacerbations; a peculiar shrinking tenderness when pressure is made upwards on the roof of the orbit, an œdematous swelling of a pale red color, of the eyelids; and in the advanced stages, often displacement of the eye and impairment of vision. The diagnosis of the disease is often very difficult.

The following cases, related by Mr. JOHN HAMILTON,* of Dublin, show the symptoms of the disease, and the difficulty of diagnosis.

CASE I.—Mary Falkner, aged 33, of a florid complexion, married, and who had had three children, the first two alive and healthy, the last a miscarriage at seven months, applied to Mr. HAMILTON, at the South-Eastern Dispensary, Dublin, complaining of great pain in the left eye, and side of the head, with impaired vision. There was a considerable protrusion of the eye; the left eyelids, and especially the upper, were swoln and puffy, so as to fill up the usual depression beneath the eye-brow; they were of a dull red color, and streaked with veins. The eye-ball presented no marks of inflammation, only a few tortuous veins being seen at its upper and inner part. The iris was of a greenish hue; the pupil was natural in size, but not in form, being transversely oval; while at its upper and back part, a bright green spot, of irregular shape and metallic lustre, was very distinct. The pain was most intense, and was referred to the eyeball, but darted also into the head, the whole left side of which was affected; it was worse at night, and deprived the patient of sleep, and was aggravated by the least motion of the body or eye, and by lying on the affected side. There was a distressing feeling of sand in the eye, probably produced by the friction of the tense eyelids over the protruded ball. Sight was much impaired, and on looking down objects were seen double. Muscæ volitantes were constantly before the eye. The patient complained of giddiness. Pulse quick and full. Tongue furred.

* Dublin Journal of Med. Sci., May, 1836.

Three months before consulting Mr. H. she had miscarried, and supposed she had got cold, as the eyes became painful, and the eyelids red and swoln. From that period, the pain gradually increased, and vision diminished.

At first sight, Mr. H. was inclined to regard the case as one of incipient fungus hæmatodes; but the woman's healthy appearance, and the circumstance of vision, though impaired, being still retained, led him to doubt the soundness of this opinion. He next suspected the presence of matter, or of some tumor in the orbit, but the most careful examination failed to detect either.

As the symptoms were such as warranted the conclusion that some of the tissues of the eye were inflamed, he resolved to try antiphlogistic treatment. Leeches, cupping, blisters, and active purgatives were resorted to, without the least benefit. Finding the symptoms daily becoming worse, Mr. H. asked the advice of another surgeon, who declined giving any decided opinion as to the nature of the disease, pronounced a most unfavorable prognosis, and recommended a trial of small doses of oxymuriate of mercury. As the stomach was now so irritable that this medicine could not be borne, it was given up; and after some little time, the patient was admitted into the Meath hospital.

The prominence of the eye was now so much increased, that it had the appearance of being larger than the other, and the eyelids could not be completely closed. The protrusion was downwards and outwards. The pupil having been dilated by belladonna, it did not return to its natural size, and appeared to be prevented from contracting by the lens being pushed against it. It had still the same oval form, and its lower edge was turned in. The metal-like spot now appeared much more forward, and seemed to occupy the whole of the pupil, giving it a greenish and rather opaque look, while a small brown waving line, like a blood-vessel, was seen crossing it. The patient had no relief from the pain, night or day. Mitigated for a short time by leeching, it soon returned worse than ever. The stomach became so irritable that nothing would stay on it. Vision was reduced to a perception of light and shade. The irritability of stomach was allayed by the application of a blister, but the other symptoms became worse, and she left the hospital despairing of relief.

Although different views were taken of the case by the surgeons of the Meath hospital, yet the general impression was that it was malignant. The extent and severity of the deep-seated pain of the head, giving rise to the suspicion of the brain being implicated, seem to have deterred the medical attendants from proposing excision of the eye, an operation to which the patient, from her suffering, would readily have consented.

About a week after she had left the hospital, Mr. H., on carefully examining the eye, pressed hard on the orbit, which gave so much pain, that the existence of periostitis instantly struck him. Further examination showed the whole upper and inner part of the orbit, as far as the swoln lid allowed him to ascertain, to be equally tender, leading to the conclusion that the disease extended still farther back. On the supposition of inflammation of the periosteum, and consequent effusion between it and the bone, the pain, swelling, and protrusion of the eye seemed fully accounted for. The patient now, for the first time, confessed that she had been infected by her husband eight years previously, and had taken mercury, soon after which an eruption had showed itself, and subsequently sore throat. She appeared also to have had iritis, and, for the last four years, had been occasionally troubled with pains in the bones.

The disease being understood, the treatment became obvious. She was

put on calomel and opium, with decoction of sarsaparilla. Salivation took place, and by the end of six weeks, she had lost all pain, and had regained her health and spirits. The eye had nearly returned into its place in the orbit, the swelling had left the lids, and vision was sensibly improved.

Nine months after the time she first consulted Mr. H., there was no difference between the two eyes in appearance; her sight was tolerably good, though still misty; and she had experienced no return of pain.

Mr. H. conceives the inflammation, in this case, to have terminated in an effusion of serous fluid, between the bone and periosteum, which effusion had finally become cartilaginous. Had the disease been a mere thickening of the periosteum, he thinks the protrusion of the ball would scarcely have been so great; had it been a bony swelling, though the pain might have been subdued, the bony mass would have remained, and kept up the exophthalmos, or would have yielded only to a protracted treatment; had it been a purulent deposition, the disease would have run a more rapid course, and the exhibition of mercury have probably proved ineffectual.

Case II.—*Periostitis of left orbit, with paralysis of left eyelid, and of the right arm and leg.*—Mary Williams, aged twenty-seven, a thin, delicate, working-woman, was admitted into the Richmond Hospital, Sept. 11, 1844. She had complete paralysis of the left eyelid, with pain in the forehead above the left eyebrow, which extended occasionally over the whole head; on a careful examination, under the edge of the orbit a slight swelling of the floor of the orbit was discovered towards the inner side, and rather deeply situated, which was very tender on pressure, exhibiting the true shrinking tenderness on pressure. The patient had weakness of her right arm and leg, and some pain in right shoulder. There was a depressed cicatrix over the right side of the forehead, where, the patient says, a swelling formed, and matter was let out.

Five years previously, she had venereal ulcers, followed by eruption, pains in the bones, and iritis.

Mr. Hamilton conceived that there could be little doubt, that the inflammation of the periosteum of the orbital plate of the frontal bone, was beginning to affect the membranes covering the corresponding portion of the bone within the cranial cavity, hence the paralysis of the arm and leg of the opposite side; the ptosis might possibly arise from the local effects of the disease on the palpebral muscles, or on the breach of the third pair of nerves which supplies it. The necessity of prompt treatment was clear, and although she had taken a good deal of mercury at different times, Mr. Hamilton did not feel justified in trying a less certain remedy, but put her on the following pills: ℞.—Pil. hydrarg. ʒss; iodine gr. iiss. M. In pil. x sumat j ter in die. A blister to be applied on the left side of the forehead above the eyebrow.

On the 16th she had taken all the pills, felt better, and could raise the eyelid a little; tenderness under the edge of the orbit less, and no pain. Repeat pills.

23d. A few days previous to this, her mouth having become slightly sore, the pills were omitted, and she was put on a pint of the compound infusion of sarsaparilla, with 15 grains of the hydriodate of potash, in the day. She was at this date much better, could half raise the eyelid; had regained the power of the arm and leg; suffered no pain in the head, and felt no tenderness from pressure over the affected part of the roof of the orbit. Repeat medicine.

25th. When the affected eyelid was raised, the eyes were seen to be on a different level, the left being depressed and rather more prominent than

the other. She saw dark things before the eye, and also saw double, one object appearing *above* another.

October 5th. Left hospital at her own request, well in every respect, except that she is not able to raise the left eyelid completely. A week after she returned in consequence of feeling a deadness and loss of power of the other (the left) hand and arm, with a tendency to stagger in walking, and some headache. Mr. H. ordered her one-twelfth of a grain of the oxymuriate of mercury, in a drachm of the tincture of bark, three times a day, and at the end of ten days she was quite well of these symptoms: the ptosis was less, for though the lid hung down, she had the power of nearly quite raising it; the eye less prominent, but still on a plane anterior to the other. In this state she left the hospital of her own accord.

Case III.—*Periostitis of the orbital plate of frontal bone; caries of the bone; extension of the disease to the brain, and death.*

Jan. 4th, 1838.—Mrs. B., aged about 30, had considerable tumefaction of both upper and lower lids, particularly of the upper, which so completely overhung the eye, that scarcely any of it could be seen. The swelling was of a pale red colour, and œdematous looking. She was unable to move the lid, and it could only be raised by another person to a slight extent, in consequence of the great swelling; the little of the eye that could be seen, did not appear inflamed, except to a trifling degree, but it was obviously pushed downwards and outwards; she had scarcely any sight with the eyes, all objects appearing black. Pressure on the orbital ridge, and on the forehead above it, for some distance, gave much pain; there was also excessive tenderness under the orbital ridge, within the orbit, on the orbital plate of the frontal bone, a feeling as if the usual space above the eyelid was filled up with a tumor. The œdematous swelling extended a little down the cheek and across the nose to the right eyelids.

About three years before she had contracted syphilis from her husband, and when Mr. H. saw her, eight or nine months after that period, she had a chronic phagedænic ulcer on the vulva, which had resisted a great variety of treatment; mercury always made it spread; fumigation, extract of hyoscyamus, blackwash, &c., only seemed to keep it in check. Mr. H. succeeded in healing it by the hydriodate of potash in large doses. Since then, at different periods, she had had periostitis over the tibiæ, the fingers, and metacarpal bones, which yielded to the same remedy. Mr. H. felt convinced that her present symptoms were caused by inflammation of the periosteum over the lower part of left side of forehead, over the orbital ridge, and for a certain distance beneath that ridge, on the orbital plate of the frontal bone; that the tumor formed by effusion beneath the bone and periosteum, in this last situation had protruded and pushed downwards and outwards the eye; that the redness and œdematous swelling, which we observe in this disease in other parts, was more remarkably situated here, on account of the loose cellular tissue of the eyelids.

Mr. H. blistered the temple, and as she had been taking the hydriodate of potash, it was stopped; and the oxymuriate of mercury, one-tenth of a grain in a drachm of tincture of bark, was given thrice daily.

8th. Much better; she can now raise the eyelid sufficiently for vision, having previously raised it with her finger; the eyelid is still, however, much swollen, but the œdematous swelling of it can be distinguished from a well-marked tumor under the eyebrow, which is hard, but now only tender on strong pressure, and she scarcely suffers any pain. The other orbit is quite well.

11th. Improving, but cannot yet raise the eyelid on account of the swelling. In the tumor below the eyebrow, distinct fluctuation can be felt. Having taken two mixtures of the oxymuriate, containing altogether two grains, Mr. H. put her on the hydriodate of potash again, six grains three times a-day.

18th. The redness and œdematous swelling have left the eyelid, but she can only imperfectly uncover the eye, which is still below the level of the other, this being caused by the well-defined tumor, now more evident in consequence of the disappearance of the surrounding swelling. It occupies more than the inner half of the roof of the inner orbit. Mr. H. ordered it to be rubbed each night with a small quantity of mercurial ointment. This had an excellent effect on the tumor, which diminished rapidly. But in the beginning of February she caught a severe cold, when the tumor became larger and more painful; and though she recovered from the other effects of the cold, it continued to increase and become more fluctuating. A few days after, she called Mr. H.'s attention to a small tender, periostitic tumor, on the edge of the other orbit. A week after, from exposure to cold, she suddenly became affected with acute laryngitis, so severe, that rapid mercurialization was demanded. The moment the mouth became sore, the tumor began to diminish, finally to the size of a small bean, soft and fluctuating; she could nearly raise the eyelid quite well.

August 3d. Since the last report the tumor in the left orbit burst, and discharged a thin matter, after which it did not close; the little tumor in the other orbit remained stationary. She went to the country and returned with her general health improved; but the sore under the edge of the orbit remained open, and the eye a little displaced downwards. To-day Mr. H. got a note, requesting him to see her immediately, as she was out of her mind. He found her sitting in a state of lethargy, her head hanging down, and the expression of her face dull and heavy. When roused she answered questions imperfectly and sluggishly, and then relapsed into the previous lethargic state. It appeared she had been more or less in this condition for some days, and that she occasionally raved. Pulse slow and laboring, 76; she put out her tongue when told to do so; with much difficulty Mr. H. got her to go to bed. Two grains of calomel were ordered to be given every third hour, and a blister to the forehead, above the eyebrow, when she complained of pain.

"6th. The mercury has affected her gums, but the only change is for the worse. She is, in fact, and has been for the last two days, in a state of coma; she lay with the eyes open, both distorted downwards by the tumors below the eyebrows, (the right very little so;) occasional stertor; and passes under her; pulse 68. After this she regained her senses to a certain extent, answered questions, and put out her tongue when desired; but this amendment lasted only a short time; she again relapsed into coma, gradually sunk, and died."

Mr. Hamilton could only obtain leave to open the body forty-three hours after death, when, from the extreme heat of the weather, and, perhaps, the cause of death, it was far gone in putrefaction. There was no congestion of the brain; the bone on the inside of the cranium, which corresponded to the periostitic tumor in the orbit, was slightly carious, rough, and soft; the dura mater over it thickened, as was also the corresponding portion of the arachnoid; the substance of the brain was too far gone to judge of any pathological change in it. What has been ascertained, however, was sufficient to prove that the inflammation of the periosteum over the roof of the orbit, had produced inflammation and

caries of the bone, which, being exceedingly thin, had become affected quite through, so as to engage the membranes of the brain itself over the diseased spot.

Mr. HAMILTON also relates a case in which there was a tumor in the roof of the orbit, displacing the eye, which he believes to have arisen from inflammation of the periosteum.*]

[RHEUMATIC INFLAMMATION OF THE TUNICA VAGINALIS OCULI.

The eyeball, we have already stated, (*see page* 94,) is invested with a membranous tunic, which, like fibrous tissues in other situations, is liable to rheumatic inflammation, an affection to which attention was first drawn by Mr. FERRALL in a paper published in the *Dublin Journal of Medical Science* for July, 1841.

The ordinary symptoms of this affection are intense racking pain in the ball of the eye, forehead and temple; protrusion of the eyeball; swelling and œdema of the lids, and serous chemosis.

Mr. FERRALL thus explains the mechanism of the production of the protrusion, and of the chemosis.

"There are here no soft parts to receive and divide the pressure or protect the globe. The tunic is supported by other fibrous layers, on its outside, as well as by the muscles, of which they constitute the sheaths. Inflammation of this capsule must, then, be immediately followed by pressure, and when we recollect its conical form, and that, as happens in case of inflammation of other fibrous tissues, *effusion at once takes place* into the cellular membrane, connecting it to the ball of the eye, we perceive there is nothing to prevent the dislocation of the latter."

"This effusion into the cellular tissue will make itself evident in another way. The conjunctiva, at the place where it forms the fold, in being reflected from the eyelid to the eye, closes up the tunica vaginalis in front. At this point it will not only receive the pressure of the effused serum, but will become separated from its connection with the sclerotic coat, by the extension of the infiltration: hence the amber-colored chemosis without vascularity of the conjunctiva. Chemosis, originating in conjunctivitis, always presents, in addition to serous infiltration beneath, one or other of the forms of hyperæmia. The chemosis of which we treat is, in uncomplicated cases, the consequence of effusion from a deeper source."

This disease resembles periostitis of the orbit, and the diagnosis presents many difficulties. In inflammation of the tunica vaginalis oculi, when the upper third of the superior lid is pressed in such a manner that the pressure is directed backwards towards the apex of the orbit, the sufferings are greatly increased; but when it is directed upwards towards the periosteal covering of the orbit, no increase of pain is experienced.

In distinguishing periostitis of the orbit from inflammation of the tunica vaginalis oculi, Mr. FERRALL says, "I would not be supposed to mean, that inflammation of this tunic is a disease apart, and never combined with a similar condition of the periosteum or cellular tissue, on the one hand, or inflammation of the eyeball itself, on the other. I am aware they may exist together, for I have seen such cases. All I mean to assert is, that inflammation of the tunic described, may be the primary affection, and the point of departure from which the diseased action may

* Dublin Journal of Medical Science, July, 1845.

spread to the other fibrous layers in the orbit, and finally reach the periosteum; and that the attack may even be limited to the tunica vaginalis oculi—that it may here produce a train of symptoms of the most dangerous kind, and which have been hitherto supposed to reside in the periosteum, because the existence of other fibrous membranes in the cavity was not suspected."

The following case, related by Mr. FERRALL, illustrates the symptoms of this disease.

"Laurence Grant, ætat. 32, a carpenter, of dark complexion, and rather strong constitution, presented himself at St. Vincent's Hospital, in February, 1838, on account of violent inflammation and protrusion of the right eye. The globe of the eye projected considerably beyond its natural situation; the cornea and iris were healthy in appearance, but vision was much confused. The conjunctiva projected remarkably around the cornea, but its color was pale amber, and without any trace of vascularity. The eyelids were both swollen and red; the lower part of the upper lid was so much tumefied, that the ciliæ appeared to grow at an unusual distance from each other; and its transverse diameter was considerably increased. The color of the lid was of a dusky red, and its surface was marked by a number of distended veins. Although the swelling of the palpebra had increased its vertical diameter, and caused it to descend, the protrusion of the eyeball was so great as to cause it to be uncovered. From the superciliary ridge to the inflamed portion of the eyelid, an interval could be seen, where neither redness nor swelling existed. This space was about half an inch broad, and extended the whole length of the lid transversely.

"He complained of agonizing pain in the ball of the eye, and felt as if it were 'dragged out of the socket.' This latter sensation he described as never ceasing; but the pain was liable to severe exacerbations. He seemed to derive some comfort from keeping the palm of his hand pressed moderately against the whole tumor, although he could not bear the finger of another to be laid upon it. The upper portion of the superior palpebra, which was free from redness, could however bear pressure, provided it was not made suddenly, or so as to shake the whole lid, and that the pressure was directed upwards towards the roof of the orbit. When asked, he admitted that he perceived an occasional flash of light before his eye; but this appearance was more frequent in the beginning of the attack. It was now five days since the complaint commenced. He went to bed free from pain in the eye, and was disturbed about three o'clock in the morning. He had been unable to work for the last week from rheumatism in his knees and legs; the limbs were improving at the period of the recent attack. He had rubbed the parts affected with turpentine, but had used no internal remedy. There was still remaining slight fullness from effusion into the capsule of the left knee-joint, and tenderness with tumefaction about the middle of the right tibia.

"This man had suffered severely from syphilis six years before, and had used mercury largely. He was now married, but his habits of intemperance, as regarded the use of ardent spirits, were little altered.

"The temporal artery was opened, and sixteen ounces of blood removed, with relief. The improvement, however, was transient, and the pain returned almost immediately. The hospital being quite full at the time, and his lodging near, and not uncomfortable, he was allowed to take his medicine at home. Calomel and opium, three grains of the former, and half a grain of the latter, were administered every third hour.

"There was very little amendment until the constitutional effects of

the remedy were established. This happened on the fourth day, when the disease began to give way. The pain first diminished, the eye then receded, and the redness gradually disappeared. The tumid condition of the palpebra, and the distorted appearance of the eyelashes, were the last to yield. When the disease in the orbit was removed, it was found that the tenderness and swelling of the knee and tibia were also gone."

Mr. Ferrall esteems the hydriodate of potass as the best remedy for this affection, and relates the following case, which was treated with that salt.

"Mary Smyth, ætat. 48, was admitted into Joseph's ward, April 16, 1840, on account of rheumatism, with effusion into the capsules of both knee-joints. She was a fat, unwieldy person, and was rendered quite helpless by the synovitis, although enjoying tolerable health before the attack. No other joint was affected, and she was free from fever. Some degree of restlessness attended the pain; and the renal secretion was scanty and high-colored. Fomentations were employed after the application of leeches, and colchicum administered internally. At the end of a week, and when the swelling was nearly gone, she complained of acute pain in the right eye. There was no appearance of inflammation during the first twenty-four hours, and it consequently attracted little attention, except that an active cathartic was exhibited. On the second day, the upper eyelid was inflamed and swollen, and the ball of the eye was observed to project a little; the pain was increased, and she was annoyed by occasional flashes of light before the eye. Blood was taken from the temple by cupping, and antimonials with purgatives were prescribed. She passed a wretched night, suffering great agony; and the next day the phenomena of the disease were fully developed. The eyeball projected three quarters of an inch; the cornea and iris were healthy, and looked brilliantly clear in the midst of a very prominent chemosis. The color of the latter was a yellow amber, without any vascularity or redness. The lids were swollen but did not cover the eye; the upper lid presented the dusky-red color and tumid appearance described in the last case. The superior portion of its surface, or that next the superciliary ridge, did not participate in this change, and the two portions were separated by a very abrupt line of demarkation. Pressure on the upper division, when directed upwards towards the roof of the orbit, produced no pain. She could see as distinctly with the affected eye as with the other. The resemblance to the other cases was too striking to be overlooked; and as it was obviously not an affection of the periosteum of the orbit, and yet was connected with rheumatism, there could be little hesitation in making a diagnosis. I was desirous to know whether any other fibrous tissue was engaged, and therefore requested Mr. M'Sweeney, the gentleman who noted the case, to uncover the tibiæ. Here, although she had not noticed it to us, we found distinct swelling, and great tenderness over the left tibia, about an inch below its upper end. She then admitted that it gave her considerable pain, but her sufferings in the eye were so much greater, that she disregarded it altogether.

"Being at this time satisfied from researches* already published, of the superior efficacy of the hydriodate of potass in periostitis, I determined to trust to it alone in combating this formidable disease; but as the organ of vision was in danger, I directed that this powerful salt should be administered at shorter intervals than usual. Ten grains were given every third hour.

* London Medical Gazette, April 10, 1840.

"At visiting hour next day, she had taken seventy grains of the hydriodate. She declared herself better, and suffered much less pain, but we could not perceive much difference in the eye. On the day following, however, every person who saw her was struck with the improvement: the whole tumor was greatly reduced; the ball of the eye had receded considerably; the chemosis was lessened, and the swelling as well as redness of the lids was diminished. On the fifth day from the commencement of the treatment, there was hardly any trace of the complaint, and the medicine was therefore discontinued. The tibia had now also recovered its healthy state, when, just as we congratulated ourselves on the rapid subsidence of so severe an affection, the left eye became the seat of pain, and in thirty-six hours presented all the symptoms of the disease. The same protrusion of the eyeball, the same chemosis and swelling of the palpebræ, and, as in the previous attack, the same integrity of vision and intolerance of light. The hydriodate of potass was resumed in doses of fifteen grains every third hour, with a resolve to persist in its use (if it succeeded) for some days after the disease appeared to be removed.

"On the day following, I had the satisfaction to perceive that the symptoms had received a check; and in three days more, to find them altogether nearly removed. The hydriodate was continued in diminished doses, and gradually lengthened intervals, for ten days after every symptom had disappeared."

The following interesting case of this affection following scarlet fever, is related by Dr. Isaac G. Porter, of New London, in the *American Journal of the Medical Sciences* for January, 1845.

"Early in October, 1841, a daughter of P. S———, six years of age, was attacked with scarlatina, then sporadically prevalent. The efflorescence was but slight, and the soreness and redness of the fauces transient, and of so little account, that medical advice was not then sought. No unusual exposure, or error in diet, could certainly be regarded as the occasion of what followed, though from the slight illness of the child, both may have occurred without the knowledge of her parents. Ten days, however, from the appearance of the rash, there were slight febrile indications, followed by symptoms of jaundice, the skin and albuginea being discolored, urine red and sparing, feces ash-colored. This continued about a week, and, doubtless, arose from gastro-duodenal inflammation; and as it subsided, marks of irritation in other portions of the intestinal canal were evidenced by fever, picking the nose, grinding the teeth, discolored and offensive dejections, with other indications of infantile remittent fever. Profuse diarrhœa followed, and, as this yielded, severe rheumatic pains attacked the extremities. These made their appearance about two weeks after the rash, and were thenceforth intermingled with other symptoms, affecting sometimes the wrists and arms, and then migrating to the ankles—the part affected being so tender and painful as to forbid all pressure or motion. Moderate swelling was the only external sign of inflammation. The treatment, thus far, consisted in meeting symptoms as they arose. The jaundice yielded to counter-irritants and fomentations over the stomach and liver, with calomel, pulv. ipecac. comp., and laxative enemata.

"The diarrhœa, as in other cases following scarlatina, was speedily checked by one or two mild cathartic doses of pulv. rhei, two parts, and hydrarg. chlor. mit., one part. The rheumatic pains were alleviated by anodyne fomentations and sinapisms, and pulv. ipecac. comp.

"One month from the appearance of the rash, these pains, which had

continued for a fortnight, began to diminish, when the right eye became swollen and painful. At first it was supposed to be confined to the lid, but it was soon evident that other structures were affected. The eye soon protruded one-half or three-fourths of an inch, giving a hideous aspect to the countenance, and was very hard and firm to the touch.* The lids became of a dark-red or purple color, and so great was the projection of the eye, that they were forcibly separated from each other one-fourth of an inch; the eyelashes, from the same cause, being removed far asunder. The conjunctiva assumed a peculiar aspect, lying in folds, surrounding or overhanging the cornea, as in chemosis, though 'amber-colored,' being filled with serum instead of blood. The iris was scarcely visible, and the cornea, so far as seen, was dull and hazy, though, owing to the encroachment of the conjunctiva, no satisfactory view of it could be obtained. The sight of the eye was probably early lost, yet from the age and debility of the child, it was impossible to settle the point. The amount of pain did not seem *very* great, perhaps from her being constantly under the influence of anodynes. A sense of distension, or, perhaps, of itching, seemed almost constant in the swollen lid, and very slight friction, with a brush, seemed grateful, though pressure gave extreme pain. As the eye was reduced to its ordinary size, the hands and wrists became again painful, stiff and swollen. Soon they were entirely relieved, when evident symptoms of pericarditis appeared. The countenance became indicative of extreme distress, and there were severe darting pains in the region of the heart, with palpitation, difficult, catching respiration, with inability to lie on the left side. At times, there were paroxysms of faintness and distress, resulting in profuse cold perspirations. Occasionally there was febrile action, but the pulse was so weak as to forbid bleeding. A blister was applied to the region of the heart, and under the administration of calomel, opium and colchicum, the disease soon left her, since which time, after recovering her strength, she has enjoyed her usual health."

On the supposition of the dropsical origin of the protrusion of the eye, "while anodyne and mucilaginous fomentations and poultices were applied to the part affected, nitre and digitalis were administered without advantage to the eye, or in increasing the quantity of urine; and it was not until after calomel had been continued for some days that any benefit was perceived. The protrusion, however, continued nearly three weeks.

"But the internal structure of the eye had received irremediable injury, and the sight was lost. The organ is now (November, 1844) smaller than its fellow, its atrophied condition being manifest, not only by inspection, but by laying the fingers, alternately, on each globe covered by its lid. There is, also, a duskiness of the conjunctiva, which has been persistent, except as it gives place to evident vascularity, from the effects of exposure to cold."

The following case, related by Dr. J. D. C. Cain, in the *Southern Journal of Medicine and Pharmacy*, Jan. 1846, is also probably an example of the disease we are considering, although it differs in some of its phenomena, from the cases of it previously described.

"Louisa Cochran, a woman of color, aged about 32, was attacked, on Sunday, 2d March, 1845, with intense pain in the head. Having repeatedly experienced attacks of sick headache, and been relieved by vomiting, she concluded that this was a similar case: but in this instance, there was

* Though not a case of hydrophthalmia, yet, from its appearance, it might justly receive one of its synonymes "buphthalmus," or ox-eye.

not even the slightest degree of nausea present. The pain had so far abated on Monday, as to permit of her getting up and attending to her usual avocations. On Tuesday, however, it returned with equal, if not greater intensity, and on Wednesday, becoming still more acute, she went to bed.

"Thursday I saw her for the first time. The pain was seated in the occipital region, from which there were occasional radiations to the frontal. She described it as of a most distressing kind, insupportable, almost causing delirium. It was more severe than in the attacks which she had previously had, and of a different nature. The photophobia from the beginning was great; the curtains were drawn around the bed, and, indeed, scarcely a ray of light was allowed to enter the chamber.

"Under the impression that these symptoms were indicative of one of the numerous morbid conditions of the brain or its membranes, classed under the general term nervous headache, I prescribed a little tinct. opii denarcot. with tinct. valerian, to tranquilize the nervous system. In the afternoon, I returned to see her, and finding that the pain had not in the slightest degree abated, I applied several cups to the nape of the neck, the mastoid processes, &c., and abstracted about from two to three ounces of blood. Gave her a pill of ext. lactucar. grs. iv, to be taken at bedtime.

"*Friday.*—The cupping and lactucarium having afforded her a certain degree of relief, she slept for some time last night, which she had not done for the three previous nights. Patient experiences much less pain, and that only in the frontal region. ℞.—Mur. morph. gr. $\frac{1}{3}$, aquæ ℥ss, to be taken at bedtime.

"*Saturday.*—Patient passed a comfortable night; feels very slight pain in the head. Intolerance of light continues. Prescribed hydrarg. chl. mit. grains viii.

"*Sunday.*—Same state. The calomel procured her two stools during the night.

"*Monday.*—The pain in the head has become general. This induced me to apply a blister three by four inches to the back of the neck. Repeat the mur. morph. at bedtime.

"*Tuesday.*—Blister drew well. The pain has left the occiput, and is seated in the temporal and frontal regions of the left side, but not severe. Repeat the mur. morph.

"*Wednesday.*—This morning at my visit, I was utterly amazed to see her left eye protruded at least half an inch beyond its fellow, and presenting a hideous aspect. The eyelids were enormously swollen and tumefied, completely closing over the eye, and the lashes separated widely. The conjunctiva was very much distended with serum, which gave to it an amber-colored appearance; it was lying in folds around, and overhanging the cornea, forming a true chemosis, but without vascularity. There was a slight oozing of serum from the conjunctiva. She represented this state of the eye as having taken place suddenly, or in a very short time, on last evening. She says that there was an exacerbation of pain on the approach of night, which became more and more acute, until about 8 P. M., when she felt a most excruciating, lancinating pain in the temporal region, corresponding with the bottom or back part of the orbit, as if the blade of a penknife or other sharp instrument had been plunged into the brain. At that instant, she felt something distinctly burst or give way in that part, internally, which induced her to apply her finger there and exert pressure, in order to relieve the pain. The eye from that moment began to swell, become painful, and protrude, until it presented the

appearance which I have described. I directed her to keep a piece of linen, moistened with a solution of acet. plumbi on it, and over that a bandage, to exert a firm but gentle pressure.

"By 6 o'clock, P. M. (the time of my afternoon's visit), the eye had acquired a most horrible appearance; the protrusion existed to a greater degree, it now being fully three-quarters of an inch in advance of the other. The lids, being no longer able to close over the ball, exposed to view the whole cornea. The conjunctiva was enormously distended with serum, drops of which seemed ready to start or burst from the membrane, as if forced through mechanically, by pressure exerted from the posterior and lateral portions of the orbit. The lower lid was so much swollen, as to be completely everted, the conjunctiva lining the tarsal cartilage of the lid was red and injected. The injection presented, however, rather a passive than an active character. In consequence of the great protrusion of the eye, keeping the optic nerve, the first branch of the fifth pair, the muscles, &c., on the stretch—there was a deep-seated, heavy pain in the ball, extending from thence into the frontal and temporal regions of the left side, but not crossing over to the opposite hemisphere. Vision was unimpaired, there were no retinitis, iritis, sclerotitis, corneitis, or conjunctivitis, and if I except the small portion of the latter membrane lining the tarsal cartilage of the lower lid, which I have already stated to have been red, but which seemed to have been congested from mechanical causes. Not the slightest degree of fever accompanied this affection; the tongue was clear, and the digestive organs in good condition. It is true that when the pain was very acute, she felt no appetite, but during the remissions she took light nourishment.

"A blister was placed on the left temple, and no sooner had it begun to draw, than a profuse discharge of serum took place from the conjunctiva. * * *

"The next day the transudation of serum continued abundant, to the great relief of the patient. The eye diminished considerably in volume, the succeeding days, and with its gradual return to its place in the orbit, the pain abated, so that on Monday, the 17th, she was well, and resumed her work."

Dr. Cain conceives, that in this case, the disease had not its point of departure in the tunica vaginalis oculi, but that it was seated in the dura mater, and, perhaps, in the arachnoid, for the following reasons:—"The pain was confined to the cavity of the cranium during the whole time, and none was felt in the eye, until the protrusion of the organ from the infiltration of serum, caused the nerves, muscles, &c., to be put on the stretch. There was no appearance of vascularity in any of the tissues of the eye, which would have been the case had it been primarily affected. The intolerance of light from the beginning of the attack, when no affection of the organ of vision exists, proves either the brain or its membranes to be in a morbid state. There were no flashes of light before the eye, indicative of this organ being implicated in the inflammatory process. Finally, the infiltration of the orbital cellular tissue took place suddenly.

"In conclusion," Dr. Cain observes, "I will simply state, that I may have erred in my diagnosis; I may be wrong in locating the disease in the membranes of the brain, which after all may have had its seat in the 'tunica vaginalis oculi,' or in the periosteum of the orbit. If such was the case, one of two things must have happened—either the pain in the orbit was masked by the more violent pain in the cranium, the inflammatory action in the former going on until effusion took place; or, there

was a sudden translation of the inflammation, from the membranes in the brain to the structures in the orbit, followed by an unprecedently rapid effusion of serum."]

SECTION VIII.—AFFECTIONS OF THE MUSCLES IN THE ORBIT.

Injuries.—The muscles may be injured in penetrating wounds of the orbit; and hence the movements of the globe may be subsequently impaired, or it may be turned in some unnatural direction. An example is afforded in a case quoted from BEER in the first section of the present chapter.

Paralytic affections.—Paralysis of the levator palpebræ superiorus has been already considered under the head of *Ptosis*, Chap. II. § IV. p. 133.

I have mentioned incidentally paralysis of the muscles supplied by the nerve of the third pair. (See p. 81.) In this affection the upper eyelid falls, and cannot be raised by voluntary effort. The eye cannot be moved upwards, downwards, or inwards; it is drawn outwards by the unopposed action of the external straight muscle. As the ciliary nerves, of which the source is derived principally from the nerve of the third pair, are involved in the paralytic affection, the iris is motionless, and the pupil dilated. This state of the pupil causes imperfection of vision, more or less serious; if, however, the disease is confined to the third nerve, the patient will be able to see well by looking through a small aperture in a card. The optic nerve is sometimes involved, with considerable and alarming injury of sight.

Under the circumstances now mentioned, the eyeball is nearly motionless; and as it cannot move in accordance with the sound eye, squinting exists.

If the pupil should not be largely dilated and the retina should be unaffected, sight may not be materially impaired, but there will probably be double vision.

If the external straight muscle should be paralyzed as well as the others, the globe will be quite fixed. Sometimes, but rarely, this muscle is paralyzed alone; the eye will then be turned inwards by the action of the adductor.

Loss of power in the muscles of the eye, like other paralysis, is generally caused by sensorial disorder, either of apoplectic character or of milder nature; and it is then frequently combined with other paralytic affections. It may arise from organic disease, such as change of structure in the brain, tumors or other diseases affecting the nerves at their origin, or in their course to the orbit. If it ever depends on slight external causes, such as exposure to cold, the occurrence is rare.

When all the muscles of the orbit are paralyzed, the globe is no longer supported and maintained in a proper position; it falls forwards, pushing out the lids, and might possibly bulge between them. This state, which is very rarely seen, is called *ophthalmoptosis;* probably it might also be produced by division of the muscles from external injury.

As paralysis of the muscles of the globe, considered pathologically, is analogous to other paralytic affections, the treatment must be conducted on the same principles. Our attention will be directed in the first instance to the state of the sensorium; and any disorder in that quarter must be rectified. Should the failure of the means adopted for that purpose, or other indications lead to the belief that organic mischief has occurred, the prognosis will be very unfavorable. If the complaint should owe its origin to any obvious external agency, or to disorder in any other quarter not seriously involving the head, we shall probably be able to remove or at least to relieve the affection.

Irregular motions.—An irregular movement of the eyes from side to side, of involuntary character, is seen in those born blind, or who have lost their sight at an early age. This is a consequence of blindness; the habit of fixing the eyes either has not been acquired, or has been lost. Unsteady and involuntary movements of the eyes are sometimes seen where vision has been lost at a later period. Such motions, either oscillatory or of irregular character, may occur in conjunction with sensorial or other nervous affections, or may be symptomatic of irritation in remote organs; they have been designated by the term *nystagmus.**

Spasm of the orbital muscles, with more or less severe pain, (*tetanus oculi,*) is a very rare affection: it would probably not be idiopathic, but symptomatic of disorder in some other quarter. The treatment, depending on the cause, would be the same as that of other spasmodic diseases.

The harmony of motion between the two eyes may be disturbed in so slight a degree as to be perceptible only in its effect on sight. Thus double vision (*diplopia*) may arise without that conspicuous want of correspondence between the eyes, which constitutes squinting. We are generally able to discover, on close inspection, that the two eyes do not move accurately together.

Patients sometimes see well with one eye, but experience confusion when both are open. This state, which has been called *monoblepsis*,† and the preceding condition of diplopia, are merely symptoms of sensorial or retinal disorder, not distinct diseases.

[The following very interesting case of double vision, occurred in a professional friend, who consulted us in the latter part of the summer of 1845, and afforded us the opportunity of watching the disease until its cure. Not the slightest deviation of parallelism in the eyes could be detected; and what was very singular was, that in looking at a horizontal line, a stick for example, the two lines were not seen parallel, but more remote at one extremity than at the other. When the head was held erect and steady, there was a certain elevation at which the stick appeared single, but if it was raised above or depressed below this place, it was seen doubled, and the distance between the two images became greater the further the stick was raised or depressed from the plane of single vision. It was a very curious feature in the case also, that by inclining the head to the left side, the divergency of the lines was diminished, and in certain cases they were brought to coincide, so that double vision ceased. We give the case in the words of the patient himself.

"During the months of June and July 1845, I was much exhausted by the excessive heat; which, in connection with arduous duties, entirely destroyed my appetite, and induced great nervous restlessness with occasional headaches. My bowels were constipated, and never moved except by enemata or laxative medicine; the urine was turbid, high-colored, and contained a large quantity of mucus. About the middle of July I went to Schooley's Mountain, and there took active exercise on foot and horseback; but this course only increased my prostration and sleeplessness. About the 29th of August, after dinner, on attempting to read, I for the first time perceived that my sight was affected—the letters were confused and doubled to such a degree, that I was obliged to desist. The pupils, however, were perfectly natural, nor could the least strabismus be per-

* The meaning of this word, which is derived from νυσταζω, to wink, is rather vague. Blanchard defines it "vel palpebrarum, vel bulbi oculi, imo iridis, seu uveæ, alternus motus rapidus et continuus, vel oculorum instabilitas." Lexicon Medicum, à Kuhn.

† From μονος, single, and βλεψις, sight. The latter word, which seems regularly derived from βλεπω, to see, has been coined for the occasion; it is not in the dictionaries.

ceived. When I looked over the fields, every object was doubled, and even the ground under my feet had an undulated appearance greatly embarrassing my walking, and causing some giddiness. I soon ascertained, however, that by closing one eye, I could see perfectly well with the other; and this induced me to wear a green shade to be applied over either eye. By this contrivance I was enabled both to see and walk with ease. What appeared to me most singular, was the fact that no object placed directly in front or to the right, and on a level with the axis of vision, appeared double; whereas, when I looked to the left, or downwards, or upward, every object was doubled. Thus when my eyes were directed to the heavens, I could see two moons, and when I looked at my watch, (held in the usual position), I could see two hands and two watches. By frequent experiments I also ascertained, that I could see most accurately by inclining my head slightly towards the left shoulder; and such was the relief obtained from this position, that I gradually acquired the habit of carrying my head permanently to that side. A strong light was somewhat painful, causing stricture of the brow; and the same sensation was produced by the act of reading, or examining minute objects. At the commencement of my attack, I was disposed to ascribe the peculiar affection of sight to the action of a strong infusion of hops, which I had been taking for several days on account of its sedative and tonic properties. I was, however, soon convinced that it was purely sympathetic with the disordered state of my nervous system, in connection with dyspeptic symptoms. My pulse, when in the recumbent position, fell to 50, and upon the least exertion it immediately rose to 85 or 90 per minute; I also suffered with occasional numbness of the arms and legs, twitching of the brows and eyelids, and also with ringing in the ears; my tongue continued loaded, and, as before mentioned, my bowels were constipated —the urine still remaining turbid and high-colored. But the effects of treatment more particularly convinced me that nervous prostration was the cause of the peculiar affection of my sight. At first I took an active purge, under the impression that there might be some congestion at the base of the brain; I also abstained from food, and lost a few ounces of blood by cups applied to the back of the neck. By the above treatment, however, all my symptoms were greatly aggravated. When returning from my summer's trip (48 hours after the commencement of attack) I was much exhausted by the journey, and had considerable increase of *giddiness* and confusion of sight, so that I was induced to take about ℥j of brandy in water; to my great surprise and delight all my uncomfortable feelings disappeared, and my sight was temporarily restored. From this time I felt convinced that the active exercise and abstemious diet I had been pursuing during the summer, had constantly increased and confirmed my indisposition.

"The symptoms continued much the same as described up to the beginning of November. I may, however, mention that whilst I suffered no local pain, either of the head or abdominal viscera, (excepting an occasional sense of fullness and uneasiness in the region of the ileo-cœcal valve,) I was a constant prey to indescribable feelings of wretchedness. My appetite and strength had by this time decidedly improved, though the disordered vision had not undergone the same amelioration. The treatment to which I had been chiefly subjected, consisted of small portions of blue pill, followed by pulv. rhei et zingiber, āā grs. vi, or the same dose of rhei combined with a few grains of ext. gentian. I also tried the various preparations of iron, but they produced gastric irritation, and had to be discontinued. I derived some benefit from small doses of

quinia and tinct. gentian comp.—grs ss of former, with ʒj of latter, three times a day. Dry cups were frequently applied to spine, and more or less permanent counter-irritation was kept up on back of neck. The hot mustard foot-bath was used every night, and I also took grs. v ext. hyoscyam. occasionally at bedtime with the view of inducing sleep. My diet consisted chiefly of small portions of animal food three times a day, and I used but moderate passive exercise, carefully avoiding fatigue. By March 1st I was enabled to attend to the duties of the profession, but still suffered with constipation, occasional sleeplessness, and some confusion of vision, particularly when fatigued. I now commenced with the cold shower-bath, followed by frictions with the flesh-brush, continued daily up to this date, July 6, 1846. My health has steadily improved, and in fact my vision has been perfectly restored for the last two months, and I am now enabled to partake of every variety of food.

"As you were the observer, and I the sufferer, in the present case, you may have noted many facts which have escaped my attention."

We will only add that our friend continues free from his very unpleasant affection up to the present time, 1 Feb. 1847.]

Squinting; *strabismus.*—If the want of harmony between the two eyes proceed to such an extent that one of them does not move with the other, but is turned away involuntarily, the case is termed squinting, or a cast in the eye, technically, *strabismus.* (The term is Greek, στραβισμος, from στραβιζω, to squint.)

The affected eye may be turned to the inner angle, in which case the cornea is directed towards the nose, or to the outer angle when the cornea has the opposite direction: these states are called respectively strabismus *convergens* and *divergens.* The former is by far the most frequent; of the latter there will probably not be more than one or two cases in a hundred.

Mr. Lucas says, that in some hundreds of cases of squinting, submitted to his observation, there was only one of the divergent kind. (*Practical Treatise on the Cure of Strabismus*, p. 47.) Mr. Duffin had seen only three out of upwards of four hundred cases. (*London Medical Gazette*, vol. xxvii. p. 48.) He makes, however, a different statement in another passage (*ibid.*, p. 79), viz., "out of upwards of four hundred cases that I have examined, I have only met with fifteen examples" (of divergent squint).

[Of 100 cases reported by Mr. Estlin of Bristol, 92 were affected wtth convergent and 8 with divergent strabismus. (*Provincial Medical Journal*, July 23d, 1842.) Of 200 cases operated on by Mr. C. R. Hall of Manchester, 148 had convergent, and 32 divergent squint. (*London Med. Gaz.*, Jan. 1841, p. 642.) Of 72 cases operated on by Dr. F. A. Ammon of Dresden, 63 had convergent, and 9 divergent strabismus. Of about 40 cases observed by ourselves, one only was of divergent strabismus.]

The greater frequency of the converging squint may in some degree be accounted for by the circumstances that the internal rectus is stronger than the outer recti, that its insertion advances nearer to the margin of the cornea, and that in our habitual employment of the eyes they are turned inwards much more frequently than in any other direction.

The eye may be directed a little upwards or downwards in converging strabismus.

Deviation of the globe upwards or downwards is extremely rare; the former has occurred after the operation of dividing the internal straight muscle. (*London Med. Gaz.*, vol. xxvi. p. 977.)

If the sound eye be closed, the squinting ceases; the affected organ re-

sumes its proper direction, and can be moved freely in obedience to the will. When the sound eye is re-opened, the squint is immediately reproduced by an involuntary movement of the globe.

There are instances in which the eye is fixed in the abnormal position, and remains unmoved even when the sound one is closed: this state has been called *luscitas*. Sometimes the motions of the squinting eye are limited, even when the other is closed; for instance, in the converging squint, the patient may be able to bring the eye into the centre of the orbit, but not to move it outwards.

The vision of the squinting eye is generally more or less defective; but this is not invariably the case. Speaking of the cases in which he had operated, Dr. Franz says, "In all the affected eyes, weakness of sight existed to a greater or less extent; many of them were perfectly myopic. Muscæ volitantes, photopsia, nystaxis or nictitatio palpebrarum, occurred in a few cases. Where the eye was much inverted, the pupil was observed to be dilated when the eye was in this state." (*Medical Gazette*, vol. xxvii. p. 41.)

[Of the 200 cases observed by Mr. C. R. Hall, in all but two the power of vision of the squinting eye was more or less impaired; and in a very large proportion of the cases of permanent strabismus we have met with, there was a difference in the power of vision of the two eyes.]

Inequality of power in the two eyes is said to be the cause of squinting, in the numerous instances of young persons more especially, where it cannot be traced to any other obvious influence. It is said that the stronger of the two eyes is used in vision, the impression on the weaker organ being neglected; hence the latter is turned aside, so that it does not interfere with the correct sight of the other. The validity of this explanation is at least doubtful. In young persons, who are the most frequent subjects of the complaint, it is difficult to ascertain satisfactorily the comparative powers of the two eyes. In the numerous cases of amaurosis confined to one eye, we have the opportunity of seeing defective vision in all its degrees; generally, without squinting. In the exceptional instances, the wrong direction of the eye may be referable to sensorial affection, and not to the state of sight. Disparity of power in the two eyes is common; and one is often considerably weaker than the other; yet strabismus does not occur.

The imperfection of visual power is probably in most cases the effect, and not the cause of strabismus. The squinting eye becomes weakened by want of employment. Hence we account for the improvement of sight represented as a frequent result of the operation by which the proper direction of the eye is restored. If the eyes should have been previously unequal in power, and the squinting should have been caused by such disparity, no benefit to vision can be expected from that operation.

Another cause of imperfect vision in squinting is that the rays of light do not strike on the most sensible part of the retina, viz., that which corresponds to the visual axis: they come in contact with the membrane towards its circumference. An operation which restores the eye to its natural position, improves sight by remedying this source of imperfection.

A person who squints, seems to be near-sighted, because he cannot see an object in the most distinct manner, that is, with both eyes at once, unless he brings it near to his face. When farther off, it is seen with the sound eye only. This kind of near-sightedness ceases after the operation.

Double vision generally attends squinting on its first occurrence: it goes off in a few days.

The degree of squinting differs in different instances. The eye may be a

little turned inwards, so that the deviation escapes notice without close observation: the inner edge of the cornea may correspond to the internal canthus; a part or nearly the whole of the cornea may be buried in the internal angle.

The abnormal direction of the eye may be constant, except when the sound organ is closed. In other and numerous cases, it is only occasional, being observed under certain circumstances, especially when the patient looks attentively at objects, or under various states of mental excitement; at other times the appearance and movements of the eyes are natural, and we can see no defect.

Squinting is generally confined to one eye. The motions of both may be irregular, so that sometimes one squints, sometimes the other. Occasionally, there is a general want of control over the ocular movements, so that we are puzzled to determine which eye squints, and on which an operation should be performed. When, by binding up the sound eye, the defective organ has been brought into exercise, and has regained its natural power of motion, squinting has sometimes taken place on the other side: under the like circumstances, the complaint may again change sides.

Squinting may occur in both eyes, which are in such cases defective, usually near-sighted, and limited in their mode and extent of exertion.

Squinting is sometimes a temporary defect, owing its origin to causes of short duration, and disappearing when they cease to operate. The double vision of drunkenness is probably caused by slight strabismus. More frequently it is permanent, even though it should have originated in temporary causes. It is often aggravated by occasional circumstances, such as mental affections, disorders of the digestive organs, and determination of blood to the head.

Causes.—Preternatural contraction of one of the recti may be brought on by disorder in the sensorium; which may be vascular congestion, as in impending apoplexy, acute or chronic inflammation, as in the various forms of hydrocephalus, organic change, such as softening, the development of various new growths in the form of tumors or tubercles, irritation or pressure from disease of membrane, bone, or other contiguous structures. Strabismus with double vision is a frequent premonitory sign of apoplexy. It sometimes occurs in the beginning, sometimes at a later period of hydrocephalus; or it may be seen occasionally in conjunction with heat and pain of the head, and other evidences of vascular fullness, as a forerunner of active mischief, and an indication for the employment of preventive measures, in children who have shown a disposition to hydrocephalus.

The origin of the disease is frequently dated from an attack of convulsions at an early age; or from some other circumstance involving determination of blood to the head, such as violent coughing, particularly in the hooping-cough. It has sometimes followed serious injuries of the head or the orbit.

Mental emotions are considered to have brought it on in some instances; and they cause temporary aggravation of the affection where it exists already.

In young children it is seen not unfrequently in conjunction with indisposition caused by teething: here the muscles of the eye are probably affected through the medium of the sensorium. In such cases it sometimes disappears with the cessation of the cause. Disorder of the stomach or of the intestinal canal is a frequent source of the complaint, particularly in children, causing temporary strabismus, which becomes permanent if neglected. The irritation of worms and an overloaded stomach will act in this way, also costiveness, with the general imperfection in the digestive and assimilative process, which that implies. These disorders of the digestive organs may disturb the head, and thus influence the muscles of the eyes: but they may

also act directly on the latter; at least, we see squinting produced when the alimentary canal is out of order, without any evidence of cerebral disturbance.

Squinting may be induced by causes acting directly on the eyes, such as injuries of the globe, chronic inflammatory complaints, particularly strumous ophthalmia, and the inflammations consequent on the exanthemata. DIEFFENBACH says that in most of his cases "the strabismus had commenced in very early childhood after ophthalmia neonatorum, scrofulous inflammation of the eyes with ulcers of the cornea, or after acute exanthemata, &c. In many there were cicatrices on the cornea or cataracta centralis."* It may be brought on by affections of the cornea and pupil, either singly or combined. Such corneal opacities as leave an access for light on one side only will cause the eye to be so turned, that light may pass through the transparent portion of the membrane. Displacement of the pupil from accident or disease, its partial obstruction by opacity of the lens or capsule, or the formation of an artificial pupil, will have a similar effect. In these cases the patient sees imperfectly, or not at all, so long as the eye is directed normally: the squint improves or restores vision.

Squinting occasionally attends the commencement of amaurosis, when it is seated in one eye. Perhaps the disparity between the two organs, when suddenly produced, may cause the want of harmony in their motions. It is accompanied with double vision; the latter being a temporary inconvenience and going off after a time, even although the cause continues. Squinting may coexist with confirmed amaurosis.

The habit of turning the eye inwards, to see an object on the nose, such as a wart, pimple, or nævus, has appeared to produce squinting in some instances; and tumors or other diseases on the edges of the lids have had a similar effect.

Causes of more doubtful agency have sometimes been assigned for the occurrence of the complaint; for example, imitations by children of a squinting associate; covering one eye for a long time with bandage or shade; such a position of the child's bed that the light comes on one side or falls obliquely. If the danger of imitation be a real one, it may be obviated by avoiding the society of those who squint: this is a safe and advisable precaution.

The affection is sometimes apparently spontaneous; it begins imperceptibly and increases gradually in healthy children, in whom we can neither discover disturbance in the sensorium or the alimentary canal, nor trace the action of any injurious influence on the eye.

[Mr. C. RADCLYFFE HALL (*loc. cit.*), in an interesting analysis of 200 cases of strabismus, enumerates the following, as the causes assigned and believed by the patients themselves, or their parents, without vouching for the correctness of the testimony, except where physical conditions yet remained to substantiate the opinions given.

"1. Convulsions during infancy, in nine cases; falls on the head, in seven; severe concussion of the brain, in one; difficult dentition, in three; hooping cough, in two; intestinal worms, in three; epilepsy, in two; a severe thrashing, in one; excessive fright, in one.

"2. Ophthalmia which had left no opacities, in fourteen; opacity of the cornea, in five; opacity said to have existed formerly, in one; wound of the cornea, by a stocking needle, in two: by a fork, in one; by a thorn, in two; blow on the eye, in five; burn of the eye from a piece of metal flying into it, in one; a habit of looking at the sun, in two; crush

* CASPAR's Wochenschrift, July, 1840, quoted in the British and Foreign Medical Review, vol. xx, p. 570.

from a cart-wheel going over the orbit, in two; amaurosis, in two; imperfect cataract, in three; exposure during infancy to the light and heat of a blazing fire, in three.

"3. Imitation of a squinting person, in thirty-nine; watching the motion of a shuttle, in one; voluntarily trying to squint, in one; a habit of looking at a scar on the eyebrow, in one; at a scar on the nose, in two; at a scar on the cheek, in two; at a small encysted tumor at the inner canthus, in one; at a small nævus in the same situation, in one; at a mole on the nose, in one; a habit of sucking the thumb, and looking steadfastly at it at the same time, in one; holding the head sideways whilst knitting, in three.

"4. Measles, in four; small-pox, six.

"5. Severe burns of the abdomen, in two.

"In four instances, I was assured that the squint was congenital. In the remaining cases of the two hundred, no causes were assigned."

Mr. Hall makes the following judicious remarks on the manner in which these different classes of cases produce strabismus.

"Under the first set of the above, are included cases in all of which, probably, the strabismus occurred consecutively to some affection of the brain. From the anatomical relations of the vessels and nerves within the cranium, Mr. Lucas has well remarked, we may account for many of those cases of strabismus which follow determinations of the blood to the brain. The nervus abducens is more especially in close contiguity to several important blood-vessels. During the long-continued paroxysms of hooping-cough, and in the convulsive struggles of epilepsy, the cerebral circulation must be obstructed, and we cannot feel surprise, that as one of the effects of congestion, strabismus should occasionally result; it may also happen in these cases, that the retina of the affected eye has itself suffered from the disordered circulation, and thus a difference of visual power in the two organs has arisen. Compression of the sixth nerve in any part of its course, or at its origin, as in apoplexy, hemorrhage from fracture of the skull, &c., so long as it affects no part of the third nerve, will of course, by inducing paralysis, occasion convergent strabismus. In cases of cerebral hemorrhage, there is often a temporary squint, which disappears as soon as the origin of the nerve supplying the antagonist muscles has become affected by the effusion.

"When strabismus depends on irritation of some distant part, as where it is caused by constipation, worms in the intestinal canal, irritation of the fifth pair of nerves in dentition, or, as it is stated, by severe burns of the abdomen,—the whole nervous system becomes morbidly sensible, and more or less diseased action is often set up in the brain, as proved by the occasional occurrence of effusion in such cases, if neglected. We can do little more than surmise whether the over-action of the *ad*ducting muscle arises in the first instance from spasmodic contraction, or from impaired contractile power of the *ab*ductor. But, it is certain that, in the majority of cases, after some years have elapsed, the overpowered muscle is only weaker than its antagonist, not completely paralyzed, though the degree of deficiency varies very considerably. The habit of squinting once formed, interstitial changes of the muscles engaged result, the over-acting one being not unfrequently hypertrophied, whilst it is rather assumed than demonstrated that the other is in an opposite condition.

"Causes residing in the eye itself must act in different ways in the production of strabismus. When a mechanical impediment obstructs the passage of light through the pupil, except in a certain position of the eyeball, any variety of squint may result from the instinctive effort of the

individual to accommodate his eye to the rays of light: *e. g.* dense opacities of the cornea, capsular cataract where a portion has been removed, detachment of the ciliary border of the iris with obliteration of the natural pupil from injury, a partially depressed opaque lens half blocking up the pupil, &c. When the strabismus is occasioned by ophthalmic inflammations, it may arise from the cornea of the affected eye being directed upwards and inwards so as to exclude the light as much as possible, and at the same time, as Dr. MACKENZIE observes, to lessen friction from motion of the eyelids. I have seen four cases of double convergent strabismus, where the patient attributed the defect to having had sore eyes for a considerable time during childhood; the disease, from general marks of scrofula, having been, I presume, strumous ophthalmia. In many instances of strabismus, the central part of the cornea has appeared slightly nebulous; here the obliquity must certainly be ascribed to other effects of inflammation than the slight haziness it has left. When one eye is inflamed for a length of time, its retina becomes morbidly sensitive, partly from sympathy with the tissues more especially the seat of disease, and partly from the prolonged exclusion of light, so that, when once more exposed, the natural stimulus proves too powerful, and the eye is habitually inverted; just as, when the power of the retina is suddenly impaired, as by looking at the sun, the other eye being closed, by amaurosis of one eye occurring rapidly, or by one of the eyes of an infant being exposed to a bright fire, it is turned out of the proper axis, to prevent the impression made upon it from confusing that conveyed to the sensorium by the more perfect organ. I have not seen a case of divergent strabismus from any of these causes.

"Blows on the eye may lead to strabismus either by the inflammation they occasion, or by injury to the retina from the mere concussion of the eyeball. Muscles habitually called into action gradually obtain an increase of power at the expense of their antagonists. The tendency to copy abnormal muscular actions, so strong in children, is manifest in chorea, epilepsy, and hysteria, and we can scarcely hesitate to admit imitation as an occasional cause of squint. In one family, where the mother squinted, each of her five children presented a similar defect; in another, where the father, who was much from home, was the subject of strabismus, not one of his seven children acquired it. In many instances, several children in the same family have had squints, which, if we credit the testimony of the parents, the younger 'learnt' from the elder child. I was unable to ascertain any other cause than the one assigned in every case enumerated as occasioned by imitation.

"I have not seen an instance of divergent strabismus produced by the habit of directing the eye towards some personal mark in the immediate vicinity.

"In measles and small-pox, the conjunctiva participates more or less, and strabismus may occur from one eye having suffered a higher degree of inflammation than the other; or, in variola, from a pustule having left a corneal opacity. But without any dense opacity of the cornea, there is, occasionally, after small-pox, a more or less opaque condition of the capsule of the lens; or, without this, considerable impairment of vision, so that, in some cases, it is probable that inflammation implicates the deeper-seated structures, and by injuring vision of one eye more than of the other, may give rise to strabismus. In three instances, where the eyes appeared perfectly healthy in structure, the squint was attributed to a habit of constantly looking at a deep pit left on the side of the tip of the nose."]

State of the affected muscles.—Hitherto we know little respecting the pathological condition of the muscles in squinting eyes. Sometimes paralysis exists, but these are exceptional cases. As the affected eye comes into its proper position, and can be moved freely outwards, when the other is closed, the abductor muscle possesses its normal power in the ordinary cases of convergent squint. I have seen no instance of this affection caused by paralysis of the abductor. In most of the cases under my own observation, external squint has depended on want of power in the abductor muscle, the parts supplied by the motor nerve having been generally paralyzed. Mr. Duffin (*Medical Gazette*, vol. xxvii., p. 18) mentions a case of paralysis "in which the eyes are both turned outwards, the left completely, although the loss of muscular power in the limbs is on the right side of the body. The affection of the eyes occurred at the moment of paralytic seizure, and singularly enough, is limited to the abductor muscle." When this muscle is paralyzed, the faulty direction of the eye does not cease on closing the sound one: the deviation is permanent, and comes under the denomination of luscitas. In other cases the divergent squint is analogous to the convergent, the power of the abductor being unimpaired, so that the right position is resumed when the sound eye is closed.

It can hardly be doubted that convergent strabismus is caused by abnormal contraction of the internal straight muscle, which, having been spasmodically affected in the first instance by some temporary cause, remains permanently in a state of morbid contraction. Although this muscle is commonly spoken of as being "contracted" or "shortened," no actual shortening has been ascertained by direct examination; and the power, which still exists, of moving the eye outwards when the other is closed, shows that the muscle can be elongated to the natural extent. Generally speaking, the internal rectus is not increased in bulk; nor is the external deficient in power, for it draws the eye outwards, and retains it in a proper position when the other is closed.

When the complaint has lasted for a long time, hypertrophy of the abductor, and shrinking or atrophy of the adductor might be expected as consequences of the affection. If the latter should exist in any marked degree, the power of drawing the eye outwards would be impaired or lost. Mr. Middlemore had the opportunity of examining, after death, a child who had been affected with divergent squint. The external rectus of the diseased eye was much larger than it ought to have been, larger in proportion to the other muscles of the same eye, and larger than the corresponding muscle of the opposite side. (*Practical Treatise*, vol. ii., p. 561.) Mr. Lucas has frequently found the inner rectus preternaturally large in convergent strabismus: in one case he considered it to be twice the usual size; it was also red and powerfully contracted, so as to have a rounded appearance. (p. 30.) In another case of convergent strabismus, which had existed five years in a child eight years old, with very slight power of everting the eye, the internal rectus "consisted of three times the natural quantity of muscular and tendinous structure." (p. 58.) This hypertrophy, which seems analogous to the increase of bulk produced in other muscles by constant exertion, must be the effect and not the cause of the disease. Squinting occurs suddenly; muscular hypertrophy comes on very slowly. If one rectus were in a state of atrophy, squinting would probably be produced by the unopposed action of its antagonist, and the eye would not be brought into the proper position when the other was closed. Such a morbid condition has never been ascertained by direct observation. Actual injury of a muscle by a penetrating wound of the orbit may cause squinting: it is

a fixed squint, for the injured muscle is incapacitated. See the case of wound in the orbit at pp. 752–3.

The numerous instances, in which squinting is merely occasional, the eye having at other times its normal direction and power of motion, and the cases of double squinting, in which the normal and abnormal position and movements alternate on the two sides, are sufficient to show that there cannot be any permanent change in the condition of the muscles. Nor do we see any such change so far as the muscle comes under our view in the operation. It must be remembered that visible changes of structure are extremely rare in the voluntary muscles, and thus that we could not expect to meet with such alterations in the present instance; the disorder, which seems to be purely functional, must be produced in the first instance through the medium of the nervous system.

It is represented by Mr. Duffin that the cellular texture around the affected muscle is frequently found condensed and unyielding, so as to hold the eye in its faulty position, even after the tendon has been divided. He states that thickening and contraction of this tissue may come on gradually as an accommodation to the shortened state of the muscle and its tendon, and to the new position of the eyeball; while a more considerable change is produced if inflammatory affections of the membranes of the eye should supervene during the existence of squinting. The cellular texture under the conjunctiva and between the muscles of the globe loses its softness and pliancy, and becomes condensed. It is subsequently elongated by the motions of the eye into bands of adhesion between the sclerotica and the tendon of the adductor. "It is these bands of fibro-cellular connection passing between the sclerotic tunic and the under surface of the muscle and its sheath, that in such numerous instances retain the eye in an abnormal position after the tendon has been divided, and render so many cases only partially successful. I have met with these bands very far back, even beyond the greatest diameter of the globe of the eye; and in two cases found them almost cartilaginous, and so unyielding that the patients were wholly unable to move the pupil out of the inner canthus."—"When either of these morbid alterations of structure is fairly established, we may rely on it that nothing short of their complete separation will effectually liberate the eye from bondage." (*London Medical Gazette*, vol. xxvii., pp. 48, 49.)

Mr. Duffin observes, further, that when the eyes during childhood have been repeatedly affected with strumous or other inflammation, the whole of the muscles and investing cellular tissue of the eye may be found in a morbid condition, condensed, and extremely adherent to the sclerotica. (*Ibid.*, p. 16.)

Squinting is an acquired, not a congenital defect. If it is ever seen at all in the latter shape, the occurrence is extremely rare. "I have not," says Mr. Duffin, "met with a single case of congenital strabismus, though, in many instances, the deformity is reported to have supervened a few days after birth." (*Ibid.*, p. 48.) Mr. Lucas (*Ibid.*, p. 46) states that he has only met with one case; we must regret that he has furnished no details of so rare a fact. He says that it seldom appears until two or three years after birth. He mentions a lady who squinted: she gave birth to two children with perfectly straight eyes; one of them began to squint at the age of three, the other at five.

Treatment.—In a disease which may be produced by causes so numerous and various, the treatment cannot be uniform. Before we determine on remedial measures, the history of the affection must be closely investigated, in order to discover the particular cause. When this has been accomplished, the proper treatment will be obvious. The strabismus and double vision, which sometimes attend the commencement of amaurotic or

apoplectic affections, will disappear if we succeed in removing the primary disorder. The same remark is applicable, where the disease is brought on by teething, by vascular congestion, inflammation, or other irritation of the sensorium, by disordered stomach, costive bowels, or worms.

Where squinting has been induced by injury of the head or eye, or by some morbid affection of the latter, such as conjunctival inflammation or speck of the cornea, it will probably cease, if we can succeed in remedying the cause.

[We have had under our care a number of cases of strabismus resulting from some affection of the brain, the precise nature of which, generally, cannot be determined during life. In one case it was caused by injury to the brain, produced by a fall on the head. In two cases it followed excessive mental labor. In several it seemed to be occasioned by derangement of the digestive organs. In one case it appeared to be the result of excessive venery. In others the precise lesion, though evidently cerebral, could not be made out satisfactorily. In all these cases vision was perfect with either eye separately, but when the patients attempted to look with both eyes, it occasioned such a sense of confusion, that they were compelled to cover one eye to enable them to find their way about.

The patient in whom it resulted from a fall, a man treated in Wills' Hospital, was cured by repeated cupping to the head and back of the neck, purging, stimulating pediluviæ, and irritation to the back of the neck.

The same remedies were successful in another case, a patient also in Wills' Hospital, in whom the affection resulted from some obscure disease of the brain. This patient, after continuing well for some time, had an attack of hemiplegia, from which he recovered, and though several years have elapsed, he has not had any return of his diplopia.

In those cases in which the strabismus resulted from derangement of the digestive organs, correcting this condition has generally relieved the affection.]

In the numerous cases which arise spontaneously in young persons, we are at a loss on the subject of treatment, because we do not detect the cause of the mischief. As the affection is often excited sympathetically by disorder in the abdomen, we try the effect at first of an active purgative or two, and then employ such mild aperients or other remedies as circumstances may require, with a careful regulation of diet, and the general management most favorable to health.

When the squint remains after cessation or removal of the cause, and after attention to the several circumstances just pointed out, we should endeavor to strengthen by exercise the muscle of which the action is deficient; and we shall be particularly encouraged to persevere in such efforts when the vision of the affected eye is good, and when it can be readily brought into the proper direction by shutting that of the opposite side. We may close the sound eye by tying a light handkerchief over it during a part of the day, so that the patient may be obliged to exercise the squinting eye. At first this may be done for a quarter of an hour at a time, two, three, or four times in the day; and the period of exercise may be gradually lengthened to an hour or more. Sometimes, when the diseased eye has ceased to squint under this treatment, the other has become affected.

Another mode of exercise may be adopted by older patients. The sound eye being closed, the other is fixed on some object, at which the patient looks attentively. He then slowly opens the sound eye, endeavoring to keep the other fixed. This kind of trial fails at first, but the point may be accomplished by perseverance.

I have seen no advantage from the use of goggles, black patches on the nose, or other similar contrivances.

Operation for the cure of squinting by dividing one or other of the recti muscles.—When, according to the nature of the case, the several means already specified have been employed for the removal of squinting, without success, and the disease may thus be regarded as confirmed, the eye may be brought back to its normal direction by dividing the internal or external rectus, according as the strabismus is convergent or divergent. This operation, of which the idea was suggested and the practicability asserted by Dr. STROMEYER of Hanover (in his *Beiträge zur Operativen Orthopädik:* Hanover, 1838), was first performed towards the end of last year, 1839, by Professor DIEFFENBACH* of Berlin, who has since employed it in some hundreds of cases. In the spring of the present year it was introduced into practice in this country, and has now been performed in great numbers of instances.†

Cases proper for the operation.—The operation is applicable to cases of confirmed squinting only. If the disease be of occasional and temporary character, and accompanied by other irregular movements or contractions, such as those of chorea; if it be induced by causes still in action, such as disease or injury of the orbit or its contents, disorder of the sensorium, nervous excitement, derangement of the digestive organs; or if it is of recent origin, and there is a reasonable prospect of removing it by the means already specified, division of the muscle is neither necessary nor advisable.

Nor would it be proper in strabismus from corneal opacity or changes in the pupil. The misdirection of the eye in these cases renders it available for vision; this advantage is lost, if the squint is removed. Since the operation is submitted to as a remedy for deformity, it is hardly applicable where the cornea is opaque, as that opacity will still cause an unpleasant appearance even if the normal direction of the eye is restored. The removal of the squint in such a case might, however, improve the appearance of the eye: hence, the operation might be performed, if it should be found that the eye could be brought into its normal position without injury to vision.

Where the squint is slight in degree, the effect on personal appearance is inconsiderable, and the operation consequently not necessary. We must remember, too, that although the squint may be removed, the operation not

* See the Berlin Medicinische Zeitung, No. 46, November, 1839, and February, 1840. The subject is mentioned, with a notice of these cases, in the British and Foreign Medical Review, vol. ix., p. 558. A short description of the operation by DIEFFENBACH himself will be found in the London Medical Gazette, vol. xxvi., p. 109. He has given a more detailed statement, with the results of his experience, in CASPER's Wochenschrift, July 4, 1840. There is an account of this paper in the British and Foreign Review, vol. x., p. 570.

† The Medical Gazette and the Lancet of the present year (1840) contain several communications on this subject, detailing cases in which the operation has been performed in various parts of England, and describing modifications in the instruments employed, and in the mode of proceeding. Those of Dr. FRANZ, Mr. LUCAS, and Mr. DUFFIN, may be particularly mentioned. In a series of papers entitled An Inquiry into some of the Consequences and Causes of the Failure of the new Operation for the Cure of Strabismus or Squinting, the gentleman last named has examined scientifically the principal physiological and pathological points relating to the disease and the operation; he has given judicious directions for the latter, and has pointed out the more frequent causes of failure.

The only express publications on the subject are the following two:—On the Cure of Squinting by the Division of one of the Straight Muscles of the Eye; by C. W. G. GUTHRIE; with a plate, 8vo. London, 1840. A Practical Treatise on the Cure of Strabismus, &c., by P. B. LUCAS; with plates, 8vo. London, 1840.

[A number of publications on the subject have since appeared in France, Germany, and England, the titles of which it is unnecessary to give.]

unfrequently causes changes in the appearance of the eye quite as conspicuous as a slight squint; also, that consequences rather serious have sometimes ensued from the operation itself; for example, acute inflammation of the conjunctiva with chemosis, inflammation and abscess in the orbit, suppuration of the globe, and bleeding to so dangerous an extent as to render transfusion necessary. [This has occurred in a single case only, and that was in a boy of hemorrhagic diathesis, whose life had previously been in danger several times from hemorrhage after slight injuries.]

If the squinting eye does not resume its proper position when the other is closed, the operation is contra-indicated. The unnatural direction of the eye here depends on paralysis, or on other changes, which the operation will not remedy. The divergent squint connected with paralysis of the parts supplied by the motor nerve is a case of this kind.

If the eye, in convergent squint, can be brought only into the centre of the orbit, but not turned outwards, the operation will not be completely successful, that is, it will not give perfect freedom of motion; it may produce partial improvement. [In these cases complete success may be obtained by operating on both eyes.]

The propriety of performing the operation is doubtful when the cellular texture under the conjunctiva and around the muscles has been condensed and indurated by repeated inflammations, as mentioned at p. 799. These parts, says Mr. Duffin, may be "so extremely adherent to the sclerotica, that it would be imprudent to detach them to the extent necessary to liberate the globe in a sufficient degree to admit of its assuming the proper position, even were the rectus, and membranous attachments on the exterior of the organ to have escaped the ravages of the disease, but which, under such circumstances, seldom happens. When, then, we find the motions of the eye very limited, and that the patient is incapable of bringing the pupil by an effort of his will to the centre of the orbit, having previously suffered inflammation, either during childhood, from accident or other causes, we should consider well the probable degree of success before we operate." In a case, where both eyes were operated on, "the whole of the investing structures of the inner periphery of the eye were found to be thickened, contracted, and infiltrated to such a degree, that they cut like cartilage, and required both extensive and careful dissection from the sclerotica. Fortunately the mischief was confined to the inner portion of the sclerotic surface, so that when the eye was liberated at this part, the external muscle had power to draw the pupil into its proper situation, and the case did well. This man had two small specks on one eye, and a nebulous opacity on the other. Notwithstanding this disadvantage, his vision was much improved by the operation, as his eyes were previously buried in an unusual manner in the nasal canthus, from which position he could move them but in a very slight degree, being only able to bring the pupils, by the greatest effort of the will, to a point scarcely midway between the inner canthus and the centre of the orbit." In other analogous cases operated on by Mr. Duffin, the abductor muscle has not been able to draw the pupil into the centre of the orbit at the time; it has regained the power gradually in the course of some days. (*Medical Gazette*, vol. xxvii., pp. 16, 17.)

The operation.—If the patient is adult, or younger, but not unruly, the best position is sitting on a chair with a back, against which the head is gently reclined: the recumbent position on a couch, with the head resting against the higher end, is equally convenient. A younger patient who cannot be depended on for steadiness, must be placed on a narrow table, and confined by a sheet passed over the body and limbs; the head being rested on a pillow, and well secured, as well as the body, by a sufficient number

of assistants; or the arms may be strapped to the body by a broad belt, and the patient held by a strong man, who secures the lower limbs between his thighs, allowing the head to rest on his shoulder or chest.

The following are the steps of the operation: separation of the eyelids, which must be held apart so as to denude the globe on its inner or nasal aspect; drawing the globe outwards, to bring the situation of the internal rectus within the view and reach of the operator; incision of the conjunctiva; division of the muscle. There are differences, more or less important, in the mode of executing each of these steps, and in the instruments employed. The upper lid may be raised and fixed by the finger of an assistant, or a small silver wire speculum may be used, either passed under the lid, or applied on its external surface. The lower lid is managed with the finger, by an assistant or by the operator, or it is depressed and kept out of the way by a speculum. A simple but ingenious contrivance for this purpose is represented by Mr. Lucas. (Pl. 3, fig. 3.) It is a bowed speculum, with a curved steel spring, fixed to the speculum at one end, and having a small pad at the other. When the speculum is placed on the eyelid, the pad comes under the edge of the lower jaw, and the action of the spring keeps the instrument in place without the help of an assistant. Some use a large spring artery forceps, seizing the conjunctiva in the fold between the lid and globe, towards the internal angle, and then letting the forceps hang by the membrane on the cheek: thus the lower lid is effectually kept out of the way. The conjunctiva may be divided with the knife or scissors; the latter is generally found the most convenient instrument for this purpose. The rectus muscle may be cut through with either instrument. The latter is generally raised by a small curved director, or by a slender blunt hook, before it is divided. Hooks, directors, and knives, of very various shapes, have been used by different operators.

In Mr. C. Guthrie's mode of proceeding, an assistant raises the upper lid with a silver elevator or speculum, holding it with one hand nearly perpendicularly to the forehead, and confining the lid gently against the edge of the orbit, so that it may not slip, nor allow the upper conjunctival fold to bulge out below it. He then fixes a strong double hook with the other hand into the tunica albuginea, through the conjunctiva at a little distance from the cornea, in the middle line of the eye. The operator, having depressed the under eyelid with the fore or second finger of the left hand, directs the assistant to draw the eyeball gently outwards with the hook, until the semilunar fold of the conjunctiva begins to yield to the traction, when it should be held perfectly steady on the middle line, the centre of the pupil being directly under the shaft of the hook. He then makes an incision nearly equidistant from the hook and the edge of the semilunar fold, through the conjunctiva and the cellular membrane, which may intervene between it and the tendon of the rectus muscle, directly upwards and inwards towards the orbit. Some surgeons use a small straight knife for this purpose, some a pair of scissors, in which case the membrane is raised by a pair of eye-forceps at the semilunar valve, and the fold thus formed between it and the hook divided; but Mr. G. generally cuts through the conjunctiva at once with a small curved knife, which is introduced under the membrane from below the line of the hook, the point being brought out upwards; or with scissors curved on the lower edge, and cutting sharply up to the points, which are blunt. The incision is to be enlarged upwards and downwards, if necessary, to at least three-eighths of an inch, which exposes the tendon of the rectus. This may be made more distinct by the point of the knife or scissors, whichever is used, or by the blunt end of the small flat, curved, and slightly grooved director, for which the knife is to be exchanged. The

director is now to be introduced by a gentle steady motion beneath the tendon, carrying it inwards rather deeply through the cellular membrane and fat, so as to be passed under the muscular as well as the tendinous part, which causes the eye to roll a little inwards: this should not be prevented by holding the hook too firmly. The point is then to be raised by depressing the handle, when it will appear at the upper part of the incision, having the muscle on its grooved surface: this elevation of the tendinous attachment turns the eyeball outwards, so that the hook is no longer necessary, and may be dispensed with after the first incision is made through the conjunctiva, while in very determined persons it need not be used at all. The director being now held in the left hand over the lower eyelid, the curved knife is to be run along the slightly marked groove so as to divide the tendon. The operation may be done throughout with the same pair of blunt ended curved scissors with which it was begun, the lower convex limb being gradually introduced under the muscle in the same manner and with the same precautions as the director. The eyelid now falls, and the eye should be sponged clean. If, when the patient opens the eye, he is unable to turn it inwards, the operation is completed; but, if he can do it in the slightest degree, the muscle, or its lateral cellular or tendinous attachments, have not been entirely divided. The scissors or director must be again used, and the undivided part sought for and incised. A very small portion of undivided attachment, either on the under or upper part, will give the power of turning the eye inwards. This effect may be produced from connection either with the rectus superior above, or the inferior below. In five of the cases performed the eyes would not at first turn outwards, although the sclerotic coat was rendered distinct to all present for nearly three-eighths of an inch every way, which, indeed, ought always to be done to ensure success in doubtful cases; and it was only by dividing the additional band of membrane or tendinous expansion I have alluded to, in three cases upwards, and in two downwards, that the operations were perfectly completed. The posterior cut end of the muscle is to be pushed backward by the director away from the other portion, and from the ball of the eye, so that it may unite indirectly to the posterior part of the globe, and not to its side, and the edges of the incision in the conjunctival membrane are to be adjusted by the same instrument. (*On the Cure of Squinting, &c.*, pp. 12—14.)

If the method with the scissors is preferred, it will be most convenient to use a rather long pair with strong blades, cutting sharply to the ends, which are just blunted. The conjunctiva, raised by common forceps, is divided with these in the inner side of the globe, and the sclerotica is then dissected clear for the space of a finger-nail, care being taken to divide every fibre and even cellular attachment upwards and downwards.

Mr. Lucas recommends that the operation should be performed without the elevator under the upper lid, or the double hook fixed into the globe. When the sound eye is closed, the patient can avert the affected organ voluntarily. Mr. L., therefore, binds up the former with a pad of lint, and a silk handkerchief, trusting to the voluntary eversion of the eye for procuring a sufficient exposure of the globe on its inner side. He places the patient on a chair with a back sufficiently high to allow of the head being moderately reclined. An assistant, placed behind the patient, raises the upper lid and fixes it against the edge of the orbit, and gently depresses and draws outward the lower lid, taking care not to cause eversion of the tarsus. A sharp-pointed hook and a common sharp-pointed pair of scissors are used for dividing the conjunctiva. "By having the hook fixed in a cedar handle, a great degree of lightness is given to the instrument, so that if the patient should start suddenly, or in any other way struggle, so as to interfere with

the operation, the operator may let go the instrument, while it is still fixed in the conjunctiva, without doing injury to this membrane, endangering the eye itself, or losing its hold.

"The operator takes the hook in his right hand, and inserts it into the tunica conjunctiva about two lines or two lines and a half distant from the cornea, and in a line corresponding to its transverse axis. He then transfers the hook to his left hand, and taking in his right hand the sharp-pointed scissors, he first gently draws forward the conjunctiva, and makes a semicircular incision of this membrane from below upwards, on the outer side of the hook, to an extent varying from four to six lines. It may sometimes even be desirable to make the incision longer.

"When the required section of the conjunctiva is made, the fine sharp-pointed hook should be withdrawn, the eyelids be permitted to meet, and the further progress of the operation be suspended for a few moments; during which time, if there be any hemorrhage, the sponge and tepid water are to be used; indeed, whether there be hemorrhage or not, the application of tepid water is always agreeable to the patient. The eyelids are next to be carefully wiped dry with a handkerchief, and the assistant is to secure them as before, when the lips of the incision of the conjunctiva will be found more or less separated from each other. The operator then takes the blunt hook in his right hand, and, inserting it between the edges of the divided conjunctiva, he insinuates it from below upwards, between the tendon of the muscle and the sclerotica. This being effected, either totally or partially, the eyeball and the muscle are at the complete command of the operator.*

"The cellular tissue immediately behind the conjunctiva, and the subconjunctival and submuscular fasciæ, often afford resistance to the passage of the blunt hook. The former can be easily separated by the point of the instrument, and the fascia also, but with more difficulty. The blunt hook being inserted beneath the muscle, the operator transfers it to his left hand, and having brought the tendon into view, he divides it with a sharp-pointed pair of scissors held in his right hand, as close to its insertion as is compatible with the safety of the sclerotica.

"If the eye be not immediately everted, or if the patient has the power of turning it so far inwards as to conceal any portion of the cornea, or to hide completely the white of the eye between the cornea and the inner canthus, in all probability some of the tendinous fibres of the muscle have not been divided. To ascertain if this be the case, I have found the blunt hook the best instrument; it should again be inserted between the edges of the incision of the conjunctiva, and by directing its point upwards and down-

* In operating on either of the recti, the exact situation of the tendinous insertion should be borne in mind. Mr. Lucas makes the following statement on this point, which he has taken the trouble to ascertain.

"In the well-proportioned eye of an adult, the centre of the tendon of the superior rectus, and that of the inferior rectus, are at an equal distance from the cornea, viz., four lines; the inner edges of each are about the same distance, whilst the outer edges are considerably more removed, being distant seven lines. In consequence of this arrangement, both muscles will fairly antagonize each other, in their alternate actions of raising the eye upwards and downwards; but in consequence of the close proximity of the internal fibres of their tendons to the cornea, in comparison with the distance of their external fibres from this point, the former have much greater power in directing the eye inwards than the latter have in directing it outwards.

"The centre of the tendon of the internal rectus muscle is distant from the cornea about three lines, its superior edge is distant four lines, and its inferior edge five lines. Contrasted with the tendon of this muscle, that of the external rectus is distant at its centre from the cornea nearly five lines, and its superior and inferior edges are distant nearly six lines." P. 20. [For full details of the anatomical relation of the muscles of the eye, see p. 93, et seq.]

wards, keeping it at the same time close to the sclerotica, the most minute tendinous filament, if undivided, can be detected, and its section accomplished." Should the eye be still inverted, it must be from condensation of the subconjunctival and submuscular fasciæ, with which there is usually combined an unnatural firmness of the conjunctiva, and of the cellular stratum under it. Any condensed cellular tissue or fascia, which still draws the eye inwards, must be freely divided with the forceps and scissors.

Mr. Lucas says, "that he has found no necessity for instruments to fix the eye, provided the patient can evert his eye when the other is closed; and, except in the most extreme cases of convergent strabismus, he can do so; this is all that is necessary; he can keep it so sufficiently long to allow the slowest operator to insert the sharp hook into the conjunctiva, and when once this is accomplished, its section is easy. Occasionally the eye will at this time turn in, but this is of no consequence, the operator has only to wait a moment or two, and with the assistance of the hook and the patient, the eye can be readily turned sufficiently out to enable him to make the necessary section of the conjunctiva. This being effected, the blunt hook can be readily passed under the muscle, and then the eye and the muscle are under our perfect control."

In a few cases, where the inversion was very great, and the patient could not evert the eye to a sufficient degree, the simple sharp hook was quite sufficient.

Mr. Duffin performs the operation recommended by Mr. Lucas, considering it to be decidedly the best in every respect. He has never found it necessary to depress the lower lid by means of artery forceps, nor to use sharp hooks for fixing the globe. For separating and fixing the lids, he recommends the silver wire specula proposed by Mr. J. N. Thompson of Nottingham. (They are figured in the *Medical Gazette*, vol. xxvii. p. 51.) These are applied on the external surface of the lids, and thus cause no pain; and they are fixed in handles, so that the hands of the assistant, by whom they are held, are removed to a distance, and the region of the eye is thus left free for the operator. "The patient is desired to direct his eye outwards; the conjunctiva is then to be pinched up by means of a fine forceps, and cut across with a pair of strong scissors, nearly midway between the edge of the cornea, and the semilunar fold of the membrane. This opening should be made freely, and care taken in making it to completely divide the subconjunctival loose cellular tissue, so as to fairly expose the tendon from its upper to its lower margin. The blunt hook is then to be inserted under it, so that when raised and drawn to the external opening, a small portion may be snipped out of it. Should the pupil, when this is done, be found not to occupy its proper situation, the hook should be introduced again, and any bands of fibro-cellular tissue that still fix the eyeball, should be brought to the external opening in the same manner as the tendon has been divided; this being repeated till the eye is perfectly liberated. The only point in the operation that requires more precise instructions is the direction in which the blunt hook should be introduced, and the manner in which it should be made to gently sweep the sclerotica in search of adhesions. This is the grand step in which most surgeons in their early operations fail. They generally introduce the hook by holding it at a right angle with the eye, its concavity looking upwards, and thus almost invariably miss inserting it under the tendon; whereas if introduced by holding it almost parallel with the eye, the point being directed downwards, until it reach the inferior margin of the tendon, and then the handle be turned carefully upon its axis, and the hook next swept gently over that portion of the sclerotica which it is necessary to clear, no difficulty will ever be experi-

ceed in passing it under the tendon, or anything else it may be necessary to divide. After its point is turned upwards, all that requires attention is to keep the flat side of the instrument towards the eyeball, and its extremity in gentle contact with the sclerotica, taking care to make it emerge through the external wound, by keeping the handle well depressed, and causing it to obliquely cross the nose. I have seen a great many operators at first thrust the extremity of the hook against the globe of the eye; and some, I am informed, have actually pushed it through the sclerotic coat, and allowed the humors to escape; whilst almost every one, from want of attention to the last direction, that of making the handle obliquely to cross the nose, catches its extremity under the superior tarsal cartilage, from whence only after numerous ineffectual efforts, they finally disentangle it." (*Medical Gazette*, vol. xxvii., pp. 51, 52.)

The maxim of avoiding all unnecessary roughness and violence, which ought to be observed in operations generally, is more especially imperative in those performed on the eyes. Experience has shown that the adductor muscle can be easily divided without the painful application of specula under the lids, without fixing a spring forceps in the conjunctiva to depress the lower lid, and without inserting hooks into the globe of the eye. The latter are said to be fixed into the conjunctiva, or into the tunica albuginea; the latter expression is obscure; however, if the hooks are to be effective in everting and fixing the globe, they must penetrate the sclerotica, and I cannot doubt but they pierce the choroid and retina also. If the patient possesses moderate steadiness and control over the movements of the eye, the hooks are unnecessary; they are dangerous in the case of such unruliness as to require that he should be overpowered by main force. In general, however, no unpleasant results have followed the use of the hooks.

A fold of conjunctiva may be seized and held by the spring artery forceps; in this way the eye can be drawn outwards and fixed, sufficiently for the purpose of the operation in many cases. Dr. Franz employs a simple sharp hook like that used in dissection: a small sheath for its point is connected with the handle, so that it can be moved up or down. When the hook has been passed under the conjunctiva, so as to take up a portion of the membrane, the sheath is pushed down, covers the point of the hook, and thus gives a secure hold on the membrane.

The best proceeding, in my opinion, is to separate and fix the palpebræ, by means of the specula employed by Messrs. Thompson and Duffin, and to elevate the tendon, as well as any cellular connections that may require to be divided, by the blunt hook devised by Mr. Lucas. The latter is made as thin as it can be to preserve a blunt edge, and is flattened on the sides.

On the exterior aspect of the globe we can denude a larger surface, and with greater facility than on the nasal side. Hence the division of the external rectus is easier than that of the internal. Diverging squint is caused most frequently by paralysis of the adductor, and cannot then be benefited by the operation. This may explain in part the unfavorable statement made by Mr. Duffin, respecting the result of such cases when submitted to operation. He says, "I have only met with fifteen examples; and of the operations performed upon them, not one has been, strictly speaking, successful, although they have been all improved in a trifling degree." (*Medical Gazette*, vol. xxvii., p. 59.)

Double convergent strabismus.—When this affection exists in both eyes, it will be found more strongly marked in the one than in the other. The obliquity in the eye least affected is secondary, and affords evidence of the harmony or co-operation between the two organs in the exercise of vision.

If the operation be performed on the most defective eye, the other will afterwards gradually come right. This, however, is not always the case. Possibly both eyes may be affected in equal degree from the beginning; or the disease in the second eye, although owing its origin to the influence of the other, may have become fully established. Here it is necessary to operate on both eyes, but an unpleasant result has ensued in some cases; "when the second eye is thoroughly relieved, the external recti are apt to assume an ascendency of power; and when the patient looks at all outwards, to draw the eye so much to the external angle as to produce a very unpleasant leer, and at the same time to render vision double." (Mr. Duffin, *in the Medical Gazette*, vol. xxvii., p. 47.) This happened to a lady in whom the operation was performed in the left or worst eye with satisfactory result. As the defect in the right eye continued very marked, the tendon was divided on this side three weeks after the first operation. The external rectus of the left eye now turned the pupil so much outwards that vision became double, and a very unpleasant leer supplanted the original squint. Both eyes were directed properly in looking at an object directly before the patient; but if the object were removed only a few inches to either side, and she looked at it without turning the head, the external rectus of the side to which it had been moved, immediately drew the pupil to the external angle, causing double vision, and a most ungainly cast. This defect is now confined to the left eye, and not so marked as at first, so that a hope of its ultimate removal may be entertained. (*Medical Gazette*, vol. xxvi., p. 978.) Mr. Duffin considers that this unpleasant result may be obviated by leaving undivided, in the second operation, a portion of the restraint that confines the eye, in order to control the action of the opposite abductor. (*Ibid.*, vol. xxvii., p. 47.)

[The method of operating which we adopt for convergent strabismus is the following:—

The patient is seated facing the light, on a chair without a back or on a stool, of such a height that his or her head will rest upon the breast of an assistant seated on an ordinary chair behind. The eye not to be operated on is to be bound up with a compress and bandage. The surgeon is to be seated on a common chair facing the patient.

Fig. 129.

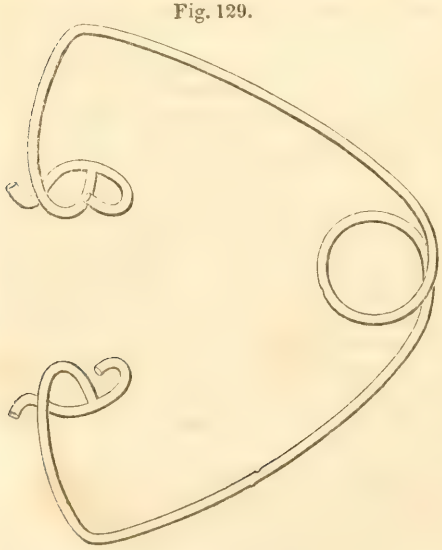

The first step of the operation consists in the separation of the eyelids. This may be effected by the assistant, if he is a skillful one. For this purpose, if the left eye is to be operated on, he should raise the upper lid with the forefinger of his right hand, and depress the lower lid with the forefinger of his left hand. When the right eye is to be operated on, the upper lid is to be raised with the forefinger of the left hand and the lower one depressed with the forefinger of the right hand.

When the assistant cannot be depended on, the lids may be separated by a speculum; and the best for this purpose we have seen, is the elastic steel wire speculum, represented in the accompanying figure, [fig. 129.] The two branches are to be pressed together, one end introduced under the upper and the other under the lower lid; the force of the spring then separates the lids. An instrument, which also answers extremely

Fig. 130.

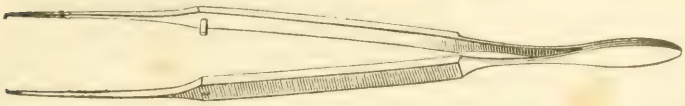

well, has been devised by Drs. P. B. Goddard and W. W. Ruschenberger. It is made of silver wire, somewhat similar in form to that just figured, but it is constructed in two separate pieces, to one of which is attached a cylinder, and to the other a rod which slides in the former. When this instrument is applied, and the branches separated, the friction of the rod against the cylinder will effectually resist any effort of the patient to close the lids.

Fig. 131.

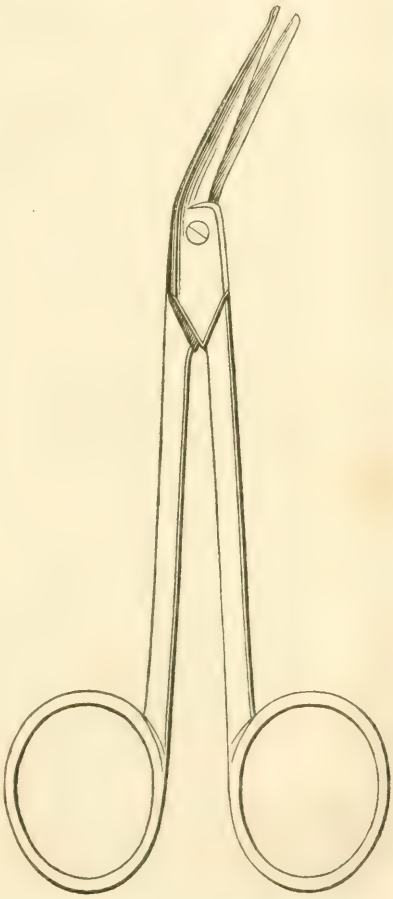

The second step is the division of the conjunctiva. The patient being directed to turn the eye outward, the surgeon takes the small toothed forceps, (fig. 130,) and seizes the conjunctiva, about midway between the edge of the cornea and the caruncula lachrymalis, or rather a little nearer to the latter, so as to make a horizontal fold, which is then snipped across with the scissors, (fig. 131,) close to the forceps, and between them and the cornea. When the left eye is operated on, the forceps should be held in the left hand, and the scissors in the right, with the probe-pointed blade upwards. When the right eye is operated on, the forceps are to be held in the right and the scissors in the left hand. If the first incision is not sufficiently large it may be extended above and below. A very good method of dividing the conjunctiva is with the small

iris knife, (fig. 132.) If the point of this be thrust through the fold of the conjunctiva from below upwards, with a single cut a sufficiently extensive incision may always be made. The conjunctiva being divided, the surgeon still holding the inner flap with the forceps and drawing it forwards, is to separate it to a sufficient extent from the sclerotica, either by dissection with the scissors, or what is more convenient, with one of the small knives represented at p. 637, figs. 97 and 98. Some surgeons object to this dissection under the belief that it subjects the patient to protrusion of the globe. We have never found this to result in any of our operations, and the dissection we recommend, much facilitates the subsequent steps of the operation. If blood now flows so as to obscure the parts, which does not often happen, it is to be carefully wiped away with a small sponge, attached to the end of a probe, and tepid water.

Fig. 133.

Fig. 132.

The third step in the operation consists in the introduction of the blunt hook under the muscle. This sometimes presents difficulties to the inexperienced operator, which may be obviated by the use of a hook such as is represented in fig. 133. It is formed of silver wire, as small as is consistent with the necessary strength, set in a bone handle, and is bent at the end so as to accommodate itself exactly to the curvature of the eyeball, and flattened at the point on its convex surface. The globe of the eye being a sphere of $\frac{19}{20}$ths of an inch in diameter, the proper curve may be given to the hook by bending it on a cylinder of that diameter. The surgeon takes this blunt hook in his right hand when operating on the left eye, and in his left hand when operating upon the right eye, and applying its concave surface to the eye, he inserts the point beneath the conjunctiva, the handle being elevated, and pushes it backwards and downwards until the point is below the muscle and behind its insertion. He then rotates the instrument so as to turn the point backwards and upwards, and at the same time depressing the handle, the point glides under the muscle and appears at its upper edge covered with the fascia which has been pushed before the instrument: some surgeons recommend that the fascia should now be cut so as to bring the point of the hook entirely out; but this is not necessary. The muscle is now secure and the surgeon gently draws the eye outwards.*

The last step in the operation consists in the division of the muscle. Incomparably the safest and best instrument for this purpose is the scissors represented in fig. 131. The surgeon takes the instrument in the hand which is disengaged, so that the probe-pointed

* Mr. T. Wharton Jones (Principles and Practice of Ophthalmic Medicine and Surgery, sect. 1996), recommends that the probe be passed under the tendon from above downwards, which seems to be preferable to the mode we have adopted, as it secures the ball from rolling upwards, during the division of the tendon with the scissors, and we shall try this method the first opportunity which presents.

blade is towards the eye, passes that blade beneath the muscle close to the convex surface of the hook, and with a single cut divides the muscle. The patient may now be allowed to close the eye, and to rest awhile. After the lapse of a minute or two the lids should be separated and the condition of the eye examined. If the pupil is now in the centre of the orbit and the patient cannot turn the eye horizontally inwards, the operation may be considered as complete. If the patient can, however, rotate the cornea into the inner canthus, it will be found that a portion of the muscle or some tendinous fibres remain to be divided. These are to be sought for with the blunt hook, and being raised on it, divided with the scissors. This is the part of the operation which requires most judgment and tact. If the fascia is too extensively divided the eye will become too prominent, or an external squint may result; both of which are more disagreeable deformities than internal strabismus. On the contrary, if the muscle is not completely divided with any adventitious fibrous bands which may exist, the squint will be but partially corrected, or when the muscle reunites may be reproduced. The muscle and fasciæ should be simply cut across, and all dissection and separation of these parts from the globe of the eye avoided, except where the defect has resulted from repeated attacks of inflammation which have consolidated the cellular tissue, fasciæ and muscles, giving rise to adventitious bands, &c.

No dressing is required to the eye operated on, except a rag wet with cold water. We recommend the patient to use it exclusively for a few days, and to turn it outwards, as far as possible, many times during that period, the other eye being kept bound up. Afterwards we desire him to look with both eyes at distant objects, so as to acquire parallelism of the eyes. This may be aided by holding a large book against the nose, and directing both eyes to some remote object.

We have never found any inflammation follow the operation requiring treatment; but as a matter of precaution advise the patient to keep in a darkened room, to abstain from stimulating articles of food for two or three days, and to take a dose of salts the night after the operation.

This mode of operating causes very little pain, is perfectly simple, and three instruments, a pair of forceps (fig. 130), a pair of scissors (fig. 131), and a blunt-pointed probe (fig. 133), are all that are absolutely required. The hooks employed by surgeons to evert the eye, always give pain, sometimes inflict injury, and are never necessary in cases suitable for the operation.

This method is, of course, not applicable to young children, but such, we conceive, to be very improper subjects for the operation. The deformity is of little consequence to them, and it is sufficiently early to attempt its removal when they have arrived at an age to appreciate the importance of the operation, and have acquired sufficient firmness to offer no resistance.]

Treatment after the operation.—The eye should be managed after the operation, as it would be in the case of accidental injury affecting the same parts. It should be kept at rest, and covered lightly with a piece of wetted lint or folded linen. Patients have sometimes returned to their usual occupations the next day; this must be considered imprudent, as incurring the risk of inflammation, of which the effects might be serious. Suppuration in the orbit, inflammation and suppuration of the globe, inflammation of the conjunctiva with chemosis, are among the effects which the operation has caused in some instances.

Mr. Duffin mentions that the division of the tendon is often attended

with pain in the forehead, similar in degree and kind to what would be produced by pressing the finger very firmly on the part. This pain sometimes lasts for several hours, and is best relieved by warm fomentations. In a few instances he has seen vomiting induced and last for twelve hours. Temporary confusion or giddiness of a few hours duration has occurred not unfrequently. He recommends that the patient should be kept quiet in a dark room. Effervescing saline medicines have not been of service, and opiates have been injurious. (*Ibid.*, vol. xvii., pp. 52, 53.)

The dragging of the muscle by the hook, previously to its being severed, and the injury of the ciliary nerves when the sclerotica is extensively swept with the hook, in order to discover and raise cellular adhesions for the purpose of dividing them, are the probable causes of the symptoms first mentioned.

The edges of the wound in the conjunctiva remain a little apart; they become red, and slightly swelled, and cicatrization takes place in about three weeks. Frequently there is more or less ecchymosis, particularly on the under part of the eye. A fungous granulation sometimes rises from the wound, and protracts healing: it may be snipped off with curved scissors.

[When scissors are employed for the removal of this fungous granulation, it cannot be completely extirpated, and it soon shoots up again. It may be wholly excised by raising it with the forceps (fig. 130), and cutting it off with the small knife (fig. 97 or 98). It may also be removed by the application to it of nitrate of silver or sulphate of copper. In some cases, after a time, it disappears spontaneously.]

It is said that relapse of the affection is sometimes produced by contraction of the cicatrix at the internal canthus: and that the evil can be remedied by a free division and detachment of the contracted parts.

Effects of the operation for dividing the adductor muscle.—The immediate effect of operation is to bring the eye into its proper position in the centre of the orbit. The patient cannot turn it horizontally inwards, but he is able to carry it further outwards than in the natural state. The eye sometimes is more or less everted; this eversion goes off in a few days. The detached muscle becomes re-united to the sclerotica behind its original insertion in about a fortnight, and its natural action is then restored.

If the success of the operation is complete, the patient should not have the power of turning the eye inwards either directly or diagonally; and this will take place when the defect is confined to one eye. It is stated by Mr. Duffin that, where both eyes are implicated, that which has been operated on still turns a little inwards, when both eyes are directed to an object immediately in front. He refers this action, which is probably effected by the inner fibres of the superior and inferior rectus to the sympathy existing between the two eyes; and he says that it will cease in a day or two, if no permanent obliquity exists in the other eye: if, however, there is a confirmed squint in the other eye, it should be operated on, and both will become straight. (*Medical Gazette*, vol. xxvii., p. 46.)

If the position and motions of the eye should not be satisfactory after the effectual performance of the operation, the other may be bound up occasionally, so as to bring into exercise that which has been diseased and enfeebled.

Mr. Duffin states that some time is necessary, in certain cases, for the external rectus to recover its contractile power, which has probably been weakened by long continued extension. The weakness of the muscle was indicated in three cases by inability to bring the pupil to the centre of the orbit before the operation. (*Ibid.*, p. 17.)

The effect of the operation on the position and movements of the eye, as observed in fifty-three cases, is thus stated by Dr. Franz. "The pupil occupied its normal position in most cases immediately after the operation: in some it was first directed a little outwards, or was not on a level with the pupil of the other eye, but in both instances righted itself within the first four or eight days. In a few cases where the pupil occupied its proper position immediately after the operation, it became slightly inverted a week afterwards, but regained its normal position in a space of from four to six weeks, by proper exercise of the eye. In three cases the pupil of the operated eye is yet slightly inverted, but even then only when the persons look at objects near them. This may be attributed to the squinting, which was very marked, having been of sixteen, twenty-three, and forty-four years' standing in these respective cases, besides being complicated with a considerable degree of amblyopy, short-sightedness, and weakness of the external rectus. Neglect of proper exercise of the eye in the one case, in the other a catarrhal inflammation, which attacked the eye a week after the operation, greatly contributed to this result, that may yet in time be remedied by judicious exercise of the eye, and the treatment of the weakness of the external rectus which is still continued. In the third case the use of caustic, which was three times employed to destroy a tumescence of the conjunctiva, seems to have contracted this membrane, and have caused the slight cast yet to be observed. A case, where the inversion had originated in hydrocephalus, presents also some peculiarities. After the division of the shortened muscles, the squinting yet remained in the same degree as before the operation. By a proper exercise of the eye, by treatment of the almost paralytic state of the abductors, and by a second division of the adductor in the one eye, I however succeeded in bringing both eyes into a perfect normal condition." (*Medical Gazette*, vol. xxvii. p. 41.)

In reference to the effects of the operation on vision, Mr. Lucas says, "in no case was the sight of the eye injured. In many, the vision remained as imperfect as before; in some it steadily but gradually improved as the organ was exercised, and in all these cases where double vision, inability to adapt the eye to distance, or any other disagreeable consequence followed the operation, it disappeared in a few days."

Of the patients operated on by Dr. Franz, "many saw objects situated towards the temporal side of the operated eye more distinctly than those in other situations. In all, double vision of objects towards the nasal side was remarked: in some this occurred immediately after the operation, in others after the lapse of a week or more. Some few saw objects double only when placed in a particular position. This distinctness of vision towards the temporal side, and double vision towards the nasal, remained in some cases only a few days; in the most, however, several weeks." *Medical Gazette*, vol. xxvii. p. 42.)

In a few instances, great improvement of sight has followed immediately on the operation. Mr. Duffin says of a patient, who had undergone the operation on both sides, for bad convergent strabismus, "she was almost entirely amaurotic before the operation, and recovered her vision, so as to distinguish small objects, within an hour afterwards." (*Ibid.*, p. 17.) In reference to such cases, Mr. Duffin inquires whether the optic nerve may not suffer inconvenience from being slightly bent on itself: partial amaurosis being a frequent attendant on squinting.

Dieffenbach represents that "all those who had strabismus of only one eye saw more weakly with it than with the other." "The operation completely cured the weakness of sight; some who had actually amaurotic

amblyopia, could see clearly directly after it was performed." (*British and Foreign Review*, vol. x. p. 570.)

Mr. C. Guthrie mentions instances in which the operation was followed by great improvement of vision. (P. 3.)

Dr. Franz says, that where slight weakness of sight had existed, full power of vision was recovered in a few weeks; but where amblyopia was present in a greater degree, this improvement did not take place till after a longer time. Where muscæ volitantes, photopsia, nystaxis, or nictitatio palpebrarum existed, these affections decreased in proportion as the centre of the posterior hemisphere increased in acuteness of sensation. (*Medical Gazette*, vol. xxvii. p. 42.)

[In nearly all the cases in which we have operated, with the exception of those in which the defect had not impaired sight, and these were few, vision was improved. In one case a young lady, who with her left eye had not been able to read long primer, read fluently, a few minutes after the division of the internal rectus, a sentence in diamond type. This improvement was permanent. In another case a gentleman who was presbyopic, requiring for vision with his left eye a magnifying glass No. 14, had this defect so far lessened by the operation as to require a glass No 11.

In all the cases also, the fatigue and uneasiness which was experienced from using the eye, ceased after the operation.]

The results of the operation, as generally reported, would seem to be uniformly and completely successful. It is performed in hundreds of cases, and, as it is alleged, without any failure. If, by complete success, we are to understand that the eyes, whether one or both be operated on, recover their normal direction, freedom of motion, and harmony of action, without exhibiting any unusual appearance that could attract attention, I believe that, of the entire mass of cases, a large proportion do not come up to this mark. Mr. Duffin, who has had great experience on the subject, and who writes with perfect candor, commences his "*inquiry into some of the consequences and causes of failure of the new operation for the cure of strabismus or squinting*, with the following judicious observations:

"The few cases thus far reported have all been so highly colored, and so remarkable for their complete success, that were we to credit implicitly their various authors, we should be led to the happy conclusion that failure is next to impossible, even in the hands of the most unskillful; and that in no instance will any visual deformity remain when once this devoted tendon is severed from its attachment to the eyeball. That it is a very scientific, beautiful, and highly satisfactory operation, in dextrous hands, no one can deny, perhaps the most so of any in surgery: but that cases both of complete and partial failure are of daily occurrence, though vaunted as successful, will, I imagine, be readily conceded by every candid surgeon whose field of observation has been sufficiently extensive to enable him to arrive at any really accurate, practical, and legitimate conclusions on the subject. Indeed, so far from being universally successful, there is too much reason to fear the operation will, ere long, fall into unmerited disrepute, in consequence of the imperfect and injudicious manner in which it is often performed, and the inauspicious results that have been occasionally observed to proceed from it.

"To divide the tendon of the adductor oculi really well, and to liberate the eye with certainty, and in an efficient manner, so as to secure the utmost benefit capable of being conferred, at the smallest possible cost of suffering and inconvenience to the patient, requires much more dexterity, neatness, and address, than is commonly believed. At first sight the simplicity of

the operation is such, that almost every one is induced to attempt it, but comparatively few succeed to the full extent, in conformity with the principles just inculcated. To attain this delicacy and excellence, it is essential that the surgeon perform this operation a vast number of times. That the first attempts, therefore, of the unpractised almost invariably prove only partially successful, cannot surprise us. I have myself operated one hundred and seventy times, and assisted others to an almost similar extent, as well as had opportunities of examining a variety of cases operated on by individuals of every degree of talent, and feel satisfied that the statements I make will be found correct by every impartial inquirer. Many of my own early cases were only partially successful, and some of them were decided failures. The original obliquity of vision, it is true, may be removed; but if, in its stead, there be substituted a staring, vacant, projecting eye, of apparently disproportionate size, or a disagreeable leer, or if a mere alteration only in the nature of the obliquity be effected, it is very questionable how far the expression of the eye is benefited by the change." (*Med. Gaz.*, vol. xxvi. pp. 940, 941.)

Mr. Duffin considers that partial failure of the operation arises frequently from the tendon not being completely divided, or from preternatural adhesions by condensed and indurated cellular membrane being left unsevered. To obviate this occurrence the surface of the sclerotica must be carefully swept by the blunt hook, so that any such adhesions may be discovered, drawn forwards, and divided. The operation must not be concluded until this has been satisfactorily accomplished.

The power of turning the eye inwards and upwards, or inwards and downwards, after the tendon of the adductor has been severed, has been ascribed to the inner fibres of the superior or inferior rectus; and a partial or complete division of one or other of these muscles has been resorted to as a remedy. Mr. Duffin has never pursued this plan, having found it sufficient to remove all tendinous and cellular attachments in the inner aspect of the globe.

The eye has sometimes been unduly everted after division of the adductor muscle. The circumstance has been mentioned at p. 812. I saw one case in which divergent strabismus had been produced in this way to such an extent that it had been thought necessary to divide the external rectus a fortnight after the first operation. (Dr. Franz, *Med. Gaz.*, vol. xxvii. p. 41.) Mr. C. Guthrie performed the same operation for external squint consequent on division of the adductor. (P. 16.)

Mr. Duffin operated on a patient, in whom the eye was turned upwards and inwards, so much that, when it was at rest, one-fourth of the cornea was concealed from view. When the eye had been completely liberated on its inner aspect, it immediately darted directly upwards, so that one-third of the cornea was concealed under the superior palpebra; it remained fixed, and the patient could not look downwards sufficiently to obviate double vision. The tendon of the superior rectus was divided on the third day after the operation: the pupil assumed its proper central position in the orbit, vision became single, and the cure proceeded favourably in all respects. (*Med. Gaz.*, vol. xxvi. p. 977.)

A very frequent result of the operation is to render the globe more prominent; the palpebræ are more widely separated, and thus the eye appears larger than the other. This change occurs in a greater or less degree in most cases of operation on one eye, so that we can generally determine, by attention to this point, which eye has been operated on. According to our present experience, this change seems to be permanent. I saw a female, in October, who had been operated on in April: the eye was so much

larger than the other as to cause a conspicuous deformity quite equal to that of a slight squint. In a gentleman who had undergone the operation about three months before, the apparent difference of size in the two eyes was such as to attract notice immediately.

The position of the eye in the orbit is determined by the combined action of antagonist powers; the recti drawing it back, the obliqui pulling it forwards. The division of the adductor lessens the former of these forces, and thus comparatively increases the latter. If this explanation be well-founded, it would constitute a strong objection to dividing a second rectus in the same eye.

Mr. Duffin speaks of the projection of the eye as trifling, but varying in extent according to the manner in which the division of the tendon has been accomplished. "When the operation has been performed without injuring the conjunctival and other coverings more than is absolutely essential, the increased prominence of the eye that results is scarcely appreciable, and, in some instances, cannot be at all detected. If, on the contrary, the eye has been liberated by submitting the sclerotic to a clean dissection by means of the forceps and scissors, and the investing membranes have been removed to an unnecessary extent, the globe is much more liable to start forward than when attention is paid to preserve the appendages and unoffending textures entire." (*Medical Gazette*, vol. xxvi. p. 977.)

If the faulty eye should be already smaller than the other, the increased projection of the globe will bring the two eyes to the same size; if, however, it should be larger, a conspicuous deformity may result.

Mr. Lucas mentions the same circumstance, stating that the increased prominence sometimes disappears in two or three weeks, while in other instances it is permanent. In the latter case, he recommends that the adductor of the sound eye should be divided in order to make it equally prominent with the other; and he relates a case, in which this was done with a perfectly satisfactory result. (P. 52.)

When the eye is still turned a little inwards, either in the straight or diagonal direction, after the adductor has been divided, it has been recommended that the inner fibres of the superior or inferior rectus should be divided also. Mr. Duffin recommends in preference that the adductor of the opposite eye should be cut, if, as is most likely, there should be a slight cast in it. He says, that by the former proceeding "the eye would be very prone to start forward, and impart an ungainly appearance to the individual; whereas, by operating on the other organ, we not only obviate the risk of this occurrence, but completely rectify both eyes; and should the eye first liberated be a little enlarged by the operation, we have it in our power to make both correspond in this particular." (*Medical Gazette*, vol. xxvii. p. 46.)

If this increased prominence should be found to occur frequently, causing such deformity as to render a subsequent operation on the sound eye advisable, it will probably be deemed a serious objection to the operation. Many might be willing to have the adductor muscle divided, in order to set straight a squinting eye, who would hesitate if they feared that so much deformity might still remain as to require that the perfect eye should be submitted afterwards to the same process.

The time that has elapsed since the introduction of this operation is so short that we are as yet unable to appreciate it fully: its ultimate influence on the motions and position of the eye is not yet ascertained. I have seen some cases in which the result, up to the present time, is perfectly successful, and several others which have succeeded partially. I have heard it stated that in some cases, among those first operated on, where the effect

had appeared completely successful, there has been relapse of the squinting. From the number of cases, in which the operation has now been performed, we shall be able, in the course of a few months, to ascertain its final effects, and thus to determine its real value. In the mean time, as the reasons for submitting to it are not very urgent, I should be inclined, if I were the subject of this defect, to wait for the further and conclusive evidence which the lapse of time will soon produce.

[Since the above paragraph was written, numerous publications have appeared, professing to give the results of the operations of their respective authors for strabismus, but no small portion of these statements seem little entitled to credit, being manifestly put forth to obtain notoriety and assert claims to extraordinary success.

The operations of those who have written most candidly on the subject do not fully realize the hopes at first raised.

Mr. Estlin (*Provincial Med. Journal*, 23d July, 1842), gives the following general statement of the results of 100 cases of strabismus, at a period of time varying from 6 to 14 months after the operation:—

In 91 patients with internal squint, the recovery was—

Perfect or very satisfactory in	44 cases
Satisfactory	21 "
Very satisfactory a week or two after, but no later report .	9 "
Improved, but requiring an operation on the other eye .	7 "
Squint returned, requiring an operation on the other eye .	4 "
Improved, but the cases unfavorable . . .	5 "
Some degree of external strabismus following the operation for internal	1 case

In 8 cases of external squint, the result was—

Perfect in	1 case
Much improved	3 cases
Slightly improved	2 "
Not improved	2 "

M. Velpeau states that in about 300 cases in which he has operated, in one-half the result has been perfectly satisfactory. Of the other half, in one-third the cure has been imcomplete; and in the remaining two-thirds the operation was entirely unsuccessful, either the eye being drawn in an opposite direction to that caused by the original defect, or in some other unnatural direction; or being immovable, or too prominent, &c. (*Du Strabisme.* Paris, 1842, p. 116.)

These results are, doubtless, the most favorable which the facts will warrant; and infinitely more so than would be presented, could the true statistics of all the operations performed be ascertained. The correctness of this inference will be at once assented to, when it is considered, that such a mania has prevailed among some surgeons for operating that they have seized upon every case suitable or not, and that almost everywhere, the greater number of cases have fallen under the knife of unprincipled operators, attracted to them by false statements of success widely circulated in the public papers, with the certificates of cures given to them by those whom they had duped.

In cases, however, judiciously selected and the operation being skillfully performed, much greater success has been attained, and this operation must now be considered as an established surgical means for the relief of certain forms of strabismus.

M. Velpeau observes, and the remark is equally applicable here, that "after having enjoyed unprecedented repute, this operation has become in Paris, as elsewhere, the subject of serious distrust. In fact the public

having seen daily in the newspapers, that the cure of squinting was simple, easy, exempt from all inconvenience, and invariably successful, gave full credence, and rushed in crowds to be operated on. These statements being unfounded, the truth did not fail in time to manifest itself. Then the public learned that they had been duped—that a large number of those who squinted were not cured by the operation, or had only their original deformity changed for another. Passing quickly from unbounded confidence to extreme distrust, they no longer believe even in the actual benefits of the operation; and now many persons who squint and might be cured have abandoned all hope of relief from their deformity."

Another circumstance which has tended to discredit this operation, especially in France and Germany, is the return of the deformity in some cases at first supposed to be cured. M. Velpeau observed the defect to return in some of the cases operated on by himself, after a lapse of eight, fifteen, twenty, and thirty days, (*op. cit.*, p. 104,) and M. Cunier has seen the same occur at the end of one, two, three, and four weeks, and after two, three, four, and even five months. A lady of high rank, Madame A., who had been operated on by Dieffenbach at Berlin, and had been announced to be cured, six months afterwards squinted as badly as ever. (*Ibid.*)

If the deformity does not, however, reappear when the muscle reunites, the cure is generally permanent. Nearly seven years have now elapsed since our first operation, and we believe the first in this country, was performed (23d of August, 1840,) and the cure has continued permanent.

Mr. Estlin remarks on this subject, "whatever may be the opinion of those who have not had the opportunity, or taken the trouble, to watch cases in which the muscle has been divided, for the cure of strabismus, as to the liability of the defect to recur, I have only to say, that as far as my observation has gone, the tendency is to improve. I do not remember a case in which any change for the worse has taken place after a month had elapsed from the operation. In many cases where I expected it would be necessary to divide the muscle of the second eye, so regular an improvement has gone on during the course of some months, as to indispose me to recommend the measure. In two of the preceding cases reported as unfinished, the squint in both eyes was so bad that I attempted to operate on the second eye a week or two after the first had been done; but the patients, little girls, were so unsteady, that I was obliged to desist; and now, after an interval of eight months in one case, and of ten in the other, the eyes are so much more parallel that I think it questionable whether the children or their parents will ever desire to have anything more done." (*Provincial Med. J.*, 23d July, 1842, p. 305.)

When the inversion of one eye, after having been for a time rectified, returns, the defect may be generally remedied by dividing the internal rectus of the other eye, as recommended by Mr. Elliot, of Carlysle. (*Edinburgh Med. and Surg. Journal*, April, 1841, p. 376.) M. C. Radclyffe Hall states that in twenty-nine instances in which the inversion, though completely removed for the time, returned, he adopted this practice, and in every one with complete success. (*Lond. Med. Gaz.*, Jan. 1841, p. 647.)]

Luscitas.—The eye may be distorted and fixed in its unnatural position by injuries or paralytic affection of one or more of its muscles, by tumors in the orbit, or other changes near the globe. This state, which resembles squinting in the wrong direction of the eyeball, but differs from it in the want of power to move the affected eye when the other is closed, was called,

by BEER, *luscitas*. I have seen it caused by paralysis of the muscles supplied by the nerve of the third pair; in which case the external straight muscle kept the globe permanently in the state of diverging squint. The mode of treatment will be determined by the nature of the cause.

CHAPTER XXVI.

AFFECTIONS OF THE LACHRYMAL ORGANS.*

SECTION I.—INJURIES OF THE LACHRYMAL APPARATUS.

THE lachrymal canals and sac are so small, so protected by their situation in the corner of the eye, and by the surrounding bone, that they seldom suffer from external violence. If they should be injured, we can do nothing more than close the wound accurately, keep the parts at rest, and employ the means most likely to avert inflammation. I have seen one of the lachrymal canals, and its correspondent punctum, obliterated by accidental injury without any observable defect in the absorption of the tears. Even where this has happened to the lower canal, and the nasal half of the eyelid has been at the same time drawn down and partially everted, the person had suffered no inconvenience from watering of the eye.

I have seen three or four instances of the lachrymal sac being burst by a blow, with escape of air into the cellular texture of the lids; the emphysematous swelling, which has been considerable, but not extending beyond the palpebræ, has disappeared spontaneously in a few days.

Foreign substances in the puncta lachrymalia.—I have not seen cilia in these openings, though the occurrence should seem from the following quotation not to be uncommon. Dr. MONTEATH saw inflammation of the semilunar membrane and caruncula lachrymalis caused by a loose eyelash, of which the thick end had entered the upper punctum and lachrymal canal: the opposite extremity, pointing downwards, constantly irritated the caruncula. (*Weller's Manual*, vol. i. p. 191.) "This little accident," says Mr. MACKENZIE, "I have met with in a number of instances, in some of which the eyelash was in the lower punctum, and in others in the upper." (*Practical Treatise*, ed. 3d, p. 240.)

SECTION II.—DISEASES OF THE LACHRYMAL GLAND.

The lachrymal, like the other conglomerate glands, is rarely diseased. SCHIMDT states that acute inflammation of this gland, with inflammatory swelling of the upper eyelid, is not uncommon; and that he had often treated such cases. (*Lib. cit.*, p. 134.) BEER represents that the disease is very uncommon; that he had seen it only a few times in the course of twenty-seven years; and that, when it occurs, it is very seldom an idiopathic affection. (*Lehre*, vol. i. p. 349.) He describes, however, acute inflammation of the gland, as sometimes proceeding to suppuration, and occa-

* J. A. SCHMIDT; Ueber die Krankheiten des Thränenorgans. Wien. 1803.
W. MACKENZIE; Essay on the Diseases of the excreting parts of the Lachrymal Organs. London, 1819.
C. H. TODD, on Diseases of the Lachrymal Gland; in Dublin Hospital Reports, vol. iii. p. 407.

sionally leaving behind, under the superciliary ridge, a capillary fistulous opening, from which clear lachrymal fluid is discharged; he calls this a true *fistula-lachrymalis*.* According to the representation of Mr. Todd, acute and chronic inflammation, and suppuration of the lachrymal gland, are common occurrences. I do not remember having seen either of these affections; if, therefore, the preceding representations are correct, I must either have overlooked diseases of this organ, which have been noticed by others, or have mistaken them for other affections. In twelve of the annual reports of diseases, treated at the London Ophthalmic Infirmary, which I am able to refer to as I am writing, embracing an amount of about 40,000 cases, the lachrymal gland is not even mentioned in the list of diseases.

I have met with some recorded cases in which inflammation and suppuration of the lachrymal gland are said to have occurred. The mischief began in these instances with a blow. I believe them to have been merely abscesses of the eyelid; at least I see no circumstances to prove that the lachrymal gland was involved in the affection.

Enlargement and induration of the lachrymal gland.—A change of structure in this part, accompanied with increase of size and hardness, has been denominated scirrhus by some writers, who have represented the affection as cancerous. I doubt the correctness of the latter opinion, never having seen any evidences of malignity in such cases. The gland is converted into a knotted swelling, of firm consistence, with an obscurely lobulated appearance on a section. It has not the incompressible hardness and compact cartilaginous texture of scirrhus, although nearly resembling it in color and general appearance. It does not become adherent, like scirrhus, to the surrounding parts; it does not contaminate the absorbent glands: nor does it return after extirpation. The texture of the diseased mass is similar, in consistence and color, to that of the knotty swellings which are formed in the neighborhood of the parotid gland. (*Medico-Chirurgical Transactions*, vol. xvii. p. 19.)

Beer represents that a fully developed scirrhus, affecting the lachrymal gland only, is one of the very rarest effects consequent on inflammation of the eye; and that, in most cases, where this part is the seat of true scirrhus, other surrounding textures, and the globe itself, are usually involved in the affection. In describing the symptoms, where the gland alone is affected, he mentions, in addition to the displacement of the globe by the swelling, and to the absence of pain, dryness of the eye, opacity of the cornea, and a shrivelled state of the conjunctiva, making the eye look like that of a half decayed corpse. He says that he never saw cancerous ulceration confined to the lachrymal gland. He advises that no attempt at extirpation should be made, because the extent of mischief cannot be ascertained previously to an operation, and because the periosteum or the bone may be affected. He adds, that he has seen many cases, in which the complaint, having been left to itself, under favorable circumstances, has remained for several years without disturbing the health or comfort of the patient. (*Lehre*, vol. ii., pp. 243—246.) The foregoing statements respecting the symptoms and treatment of the affection, are quite at variance with my experience, as will appear from the cases subsequently related.

Using the term scirrhus in its strict sense, and not including under it

* Lib. cit., vol. i. p. 356; and vol. ii. p. 184. In the latter place, Beer says that this minute, and sometimes scarcely visible opening, from which a clear lachrymal fluid escapes through the day, is one of the rarest consequences of ophthalmic inflammation. He recommends rubbing the fistulous track with lunar caustic, brought to a fine point; and he once introduced into the opening a knitting needle, made red hot, with success.

enlargement and induration consequent on inflammation, SCHMIDT says that he had never seen it as an affection confined to the lachrymal gland. (*Lib. cit.*, p. 130.)

Mr. TRAVERS represents that cancer is peculiar, in the organ of vision, to the lachrymal gland, conjunctiva, and eyelids. (*Synopsis*, p. 216.) He says, "I removed the lachrymal gland, greatly enlarged and in a state of true scirrhus, from the orbit of a middle-aged man, a merchant's clerk in this city. The vision of that eye had suffered considerably during the growth of the tumor; in other respects, he continued quite well when I last saw him, after an interval of some years." (*Lib. cit.*, p. 228.)

Mr. TODD mentions the affection of the lachrymal gland as scirrhous or carcinomatous, and relates two instances of successful extirpation.

CASE I.—A woman, seventy years of age, who had received a blow on the eye seven years before, and had been subject since that time to frequent discharges of tears, perceived a tumor under the eyebrow a year before she came under the care of Mr. TODD. Pain and headache soon came on, and became very severe. The tumor, which was knotty, projected more than half an inch beyond the superciliary ridge; it was hard, and slightly movable in the transverse direction. The eyeball was pushed downwards, so that the cornea was nearly on a level with the ala nasi; and the lower lid was everted. The cornea was slightly obscured; and vision was lost. Severe lancinating pains extended from the tumor to the globe, accompanied with a sense of heat, and frequent discharge of hot scalding tears. The diseased gland was removed by Mr. TODD, on the 30th of August, 1831, in the Richmond Hospital. It was so firmly wedged into the orbit, that the handle of the scalpel was with difficulty introduced between it and the superciliary ridge, to detach the mass from the roof of the orbit. Its surface towards the eye was irregularly lobulated, and the lobes had insinuated themselves among the muscles and other contents of the orbit, so as to render their disentanglement embarrassing and hazardous. "The diseased gland was found, on examination, much larger than a walnut; it presented, on the surface which had been turned towards the eye, three considerable eminences or lobes, with deep fissures between them; it was almost as firm as, but more elastic than, cartilage. A section of the gland exposed several small cartilaginous cysts, which contained a glairy fluid, and the interspaces consisted of a firm fatty substance, traversed by a few membranous bands." The patient recovered from the operation, and was discharged from the hospital on the 10th of September. The eye appeared sound, and had nearly regained its natural position; vision was extinct. The patient continued perfectly well in the following December. (*Lib. cit.*, pp. 419—426.)

CASE II.—A strong and athletic man, twenty-two years of age, was received into the Charitable Infirmary, Dublin, by Mr. O'BEIRNE, on the 21st of December, 1830. The globe of the right eye projected more by its semidiameter than the opposite, yet was covered by the upper lid hanging loosely over it. The pupil was dilated and fixed, the cornea turned towards the nose. A tumor, with indistinct outline, occupied the upper and outer part of the orbit. There was considerable pain in the side of the head and face, with watering and uneasiness of the eye from external excitement. He saw double, and vision was in other respects so imperfect that he could not work as a laborer. Two years previously he had first perceived, occasionally, sparks and mists before the eyes, with pain in the side of the head and face. In about a year, slight prominence and inversion of the globe were observed. The tumor, of which the real nature had not been suspected, was removed on the 23d, and turned out to be an enlarged

and indurated lachrymal gland. "The surface was granular, and of a pink color. When cut into, it presented a hard membranous, or rather cartilaginous centre, from which septa passed to the circumference. No sanies could be perceived. The gland was enlarged to at least six times its natural size." The wound was healed on the 14th day after the operation, when the eye had returned to its natural position, the iris had regained its power of motion, vision was perfect, and all uneasiness was gone. (*Lib. cit.*, pp. 426—429.)

In the two following instances of successful extirpation, the lachrymal gland, in respect of its hardness, might have been called scirrhous; I saw no reason for suspecting the disease to be malignant. In both these cases, as well as in those quoted from other authors where extirpation was practised, the gland was greatly enlarged. The female breast, when affected with scirrhus, is not usually augmented in bulk; sometimes, on the contrary, it is diminished.

Case I.—*Enlarged and indurated lachrymal gland successfully extirpated in a young man.*—John Clifton, twenty-four years of age, from Market Street, Hertfordshire, came under my care at the London Ophthalmic Infirmary, on the 14th of March, 1826. Seven years ago he was struck violently on the left upper lid, by an apple thrown at him; swelling followed, and gradually subsided. Two months afterwards the lid swelled again, with considerable pain, which having lasted a month, went off entirely. With the swelling the eye began to water, and there was a constant copious lachrymal discharge, rendered still more abundant by exposure to the air. The swelling of the lid and the lachrymation continued, and the globe was gradually protruded from the orbit, with loss of all useful vision. A fortnight before admission, inflammation of the eye took place, with considerable pain. There is now a general fullness of the upper lid, which is more particularly swelled and increased in breadth near the external angle. The eyeball and lower lid, pushed downwards and inwards, reached about half way between the orbit and nose; but though the former is out of its socket, the lids are so extended as to cover it completely. The external tunics are considerably inflamed; there is a broad red zone in the sclerotica round the cornea, with general dullness, and small ulcer of the latter. A hard unyielding tumor, with tuberculated surface, projects a little beyond the margin of the orbit, at its upper and outer part. This seems to admit of being moved a little, from side to side, upon the bone; but the point is rather doubtful. Blood was abstracted by cupping and leeches, and opening medicine was administered. The tumor was removed on the 25th of March, the external incisions being ample, as it obviously filled a large portion of the cavity. The longest, of about three inches, extended from the root of the nose, along the fold of the upper lid, to the temple; a second, of about two inches, passed perpendicularly over the forehead and upper and outer part of the orbit, to meet the other at right angles: it was necessary to make a third cut from the first incision towards the anterior part of the zygoma. When the flaps made by this crucial incision were turned aside, the seat of the tumor was completely exposed. No other difficulty was experienced except that inseparable from the size and hardness of the swelling, its deep extent backwards, and close contact with the orbit and its contents: the surrounding connections were, however, merely cellular. The tumor was found to be the lachrymal gland, increased to the size of a large walnut, and of compact homogeneous texture. It had a light yellow color, with an appearance of radiated fibres at one point; it approached in firmness to cartilage, and altogether bore a near resemblance to the firmest part of a scirrhous mammary gland. A large quantity of blood was lost

during the operation: as it filled the deep cavity left by removing the tumor, so that its source could not be readily discovered, the patient was left quiet in bed, with the wound open, in the hope that the bleeding would cease; it went on freely for more than half an hour, rendering the patient very faint; an artery was then tied. The edges of the wound were now approximated by five small silk ligatures, and three narrow slips of adhesive plaster, and the parts were covered with a wet rag dipped out of cold water, and occasionally renewed. 26th. The wounds had united by adhesion; the sutures and adhesive plasters were removed, the lids thoroughly cleansed, and the parts then covered with a wetted rag. The eye had receded to its natural position, and the inflammation of the sclerotica had ceased. The patient, having been quite well for some days, left the infirmary on the 9th of April. The wound united completely by adhesion; no suppuration occurred. The globe had regained its natural position and moved freely, its surface, and that of the lids, being as moist as usual. The external inflammation had ceased; the cornea had nearly recovered its transparency, and vision was much improved. I saw this patient again in 1839, when a hard swelling had formed about the middle of the cicatrix, under the superciliary ridge. As he felt no inconvenience from it, he declined my proposal of coming into the hospital.

Case II.—*Enlarged and hardened lachrymal gland successfully extirpated.*—A gentleman, twenty-seven years of age, came under my care in the summer of 1828, for a tumor in the orbit, which had caused displacement of the eye and loss of vision. The complaint had begun five years previously, with considerable headache, slight pain about the eye, which did not last long, and almost continual flow of tears, which was increased on exposure to the air. At the end of a year and a half the globe began to be protruded, so that a sensible difference of position was observed between the two eyes. In three years, with increasing displacement of the globe, sight became impaired. When I saw this gentleman, the left eye projected about an inch beyond the level of the right, and was at the same time thrust downwards. The upper eyelid was swelled; it covered the eye, and still retained its power of motion. A hard tumor could be felt in the situation of the lachrymal gland, projecting under the edge of the orbit, close to the bone, and hardly movable. The largest print could not be distinguished with the left eye. I removed the tumor in June, making a long incision from the nose to the temple, and a shorter one over the forehead, meeting the former at right angles. The diseased gland was equal in size to a large walnut, slightly tuberculated on the surface, of a light yellowish-brown color, firm, and nearly homogeneous in texture, but not so hard as scirrhus, connected by loose cellular tissue to the surrounding parts, and by a short close texture to the bone. Free bleeding took place during the operation, but no vessels were tied. The wound was united by sutures, and covered with a rag dipped in cold water. It united throughout by the first intention, and the patient was able to go out and attend to his affairs in a week, at which time the globe had receded into its place. At the end of November the position of the eye was nearly natural, and the patient could read with it the leading article of a newspaper. It was not deficient in moisture; but no tears came from it in weeping. When I saw this gentleman, between one and two years after the operation, he continued perfectly well: as he resides in London, I should, no doubt, have seen him, if there had been any return of disease.

Mr. Mackenzie has recorded two cases, in which the lachrymal gland was enlarged and altered in structure. In one of these the globe had been pushed out of the orbit and had burst many years before death. A tumor

was found after death as large as a man's fist, occupying a much expanded orbit, and passing down into the spheno-maxillary fissure. The roof of the orbit had been destroyed by absorption, and even the dura mater was gone at some points, so that the tumor and brain were in contact. The anterior and middle lobes of the cerebral hemisphere had been pressed on and altered in figure by the swelling, which had also obliterated the nostril. From the size and progress of this swelling, we should have supposed it rather a new formation than a disorganization of the lachrymal gland. Mr. Mackenzie, however, states that it was white and granular, the grains being evidently the enlarged acini of the gland.

The other case was that of a child eight years old, in whom protrusion of both globes with ulceration and sloughing of the cornea, had occurred a few weeks before death. The lachrymal gland on each side was converted into an oval lobulated tumor of greenish color and firm homogeneous consistence, two and a half inches long, and one and three-quarters thick. Several small growths of similar color proceeded from the dura mater, and had caused partial absorption of the cranium." (*Practical Treatise*, edit. iii. p. 391.)

[Dr. Halpin, in an interesting paper on Extirpation of the Lachrymal Gland (*Dublin Quarterly Journal of Med. Sci.*, vol. i., N. S., p. 79) relates a case of enlarged lachrymal gland. In extirpating that organ in this instance, Dr. H. made what he conceives to be important deviations from the modes hitherto practised, and we therefore subjoin an account of the case.

Andrew Smith, a field laborer, about 40 years of age, first applied to Dr. H. for advice in Nov. 1844. He then stated that about eighteen months before, his attention was first attracted to the state of his eye, by what he calls "a wonderful flow of water to it," especially when the eye was irritated, or when walking against the wind: there was then no swelling in the parts, at least none sufficient to inconvenience him, nor did it appear until about twelve months ago. The "flow of water" continued as before. The upper eyelid then became stiff and swelled, so much so that it required exertion on his part to raise it and keep it open; about six months before he applied to me he had lost the power of raising it, save with his fingers; the swelling gradually increased; the eye was at length protruded from the orbit, still covered permanently by the distending lid, producing great deformity. He did not suffer much pain in the parts at any stage of its progress.

As the case was clearly that of an enlarged lachrymal gland, Dr. H. advised its immediate removal by operation; however, the patient would not consent. Dr. H. then lost sight of him until the 2d of April last, when, having made up his mind to submit to the operation, he again applied to Dr. H. The deformity had greatly increased. The eyeball was protruded completely from the orbit, lying outside the orbital ridge of the malar bone; the cornea, which presented a healthy appearance, was turned upwards and outwards; the iris contracted moderately on the admission of light, but vision was very much impaired by the straining of the optic nerve, and the pressure of the entire globe by the tumor: the eyelid was of a dusky, almost purple color, irregular on its surface, and traversed in various directions by enlarged veins. On the 4th of April, Dr. H. removed the gland, assisted by Mr. Brice, of Cavan.

"In operating on this case," says Dr. H., "I determined to avoid wounding the eyelid, thinned, discolored, and traversed by large veins. I drew down the tumor with the fingers of my left hand until I had about one half of the eyebrow below the edge of the superciliary ridge: Mr.

Brice then fixed the integuments against the forehead. In order to insure the largest possible space for the dissection of the gland from its deep attachments, I swept round nearly two-thirds of the orbit with my first incision, which commenced immediately above the tendon of the orbicular muscle, and terminated half an inch below the external commissure. In this course I divided the eyebrow through its entire length, leaving about two-thirds of its breadth on the forehead; the ligamentum palpebrarum was then divided. The flap was next dissected down; and ample room was obtained; a ligature was passed through the gland, and it was dissected entire, partly with the index finger of the right hand, and partly with the scalpel, from its deep connections. There was no hemorrhage. The edges of the divided eyebrow were now brought together by four points of interrupted suture; the patient was put to bed, and the cold water dressing applied. Union by the first intention took place along the entire line of incision. Seven days after the operation he was able to return home; the eyeball gradually regained its normal position; at the termination of four weeks there was no deformity whatever to be observed, and it would require the closest examination to discover the line of incision amongst the hairs of the eyebrow. On the 4th of May last, a month after the operation, he declared that his sight in that eye was quite as good as it had been. In order to ascertain whether tears would flow from an eye deprived of its lachrymal gland I dipped the blunt end of a probe in tr. opii, and touched the conjunctiva with it—immediately the *right* eye became suffused with tears, which flowed over the cheek. At the end of thirty seconds I applied the probe a second time; in sixty seconds after this second application, a drop of fluid fell from the left eye, and in thirty seconds more, another; this fluid was opaque and whitish; doubtless this appearance was caused by the tincture: the conjunctiva remained red for a considerable time after the application of the tincture. He did not experience any feeling of unusual dryness of the eyeball since the operation. The disease in this gland, which had become enlarged to the size of a hen's egg, does not appear to me to be malignant; I think it presents a good specimen of simple interstitial enlargement of the gland; it is smooth on its surface; and the section presents a regular homogeneous mass of a yellow colour."]

Hydatid of the lachrymal gland (*hydatis glandulæ lachrymalis; glandula lachrymalis hydatoidea*). SCHMIDT, and after him BEER, have described the formation of true hydatids as occasionally occurring in the lachrymal gland. It must be difficult, if not impossible, to determine the exact nature and original seat of such a disease, or of a simple watery cyst developed in the gland. Nor is the diagnosis important; as the symptoms and treatment will be essentially the same, whether these diseases have begun in the gland or in the neighborhood. When the swelling, by its increase, causes displacement of the eye and imperfect vision, it must be treated on the same principles as other orbital tumors.

SECTION III.—EPIPHORA, OR WATERY EYE.

The quantity of lachrymal fluid may be greater than is necessary for moistening or clearing the surface of the organ; the eye is over-filled, and the redundant tears, which sometimes partially obscure vision, flow over the lower lid, and run down the cheek, especially on exposure to cold wind. This state is called a *watery eye*, or technically, *epiphora*. The latter

term, however, is properly applied to the redundancy from increased secretion; while the dripping consequent on defective excretion is more appropriately termed *stillicidium lachrymarum.*

The secretion of the lachrymal gland is increased whenever the external surface of the eye is irritated, as by cold wind, acrid powders or fumes, and various extraneous matters, whether of mechanical or chemical operation. Inflammation of the eye, whether external or internal, or that of the lids, will have the same effect. Epiphora is often kept up for a long time by chronic external inflammation; and it may occur, in scrofulous patients, to a high degree, without any visible signs of inflammation. Under these various circumstances, there is an obvious cause for the watering state of the eye; viz., irritation affecting the surface of the organ; this is the stimulus which naturally calls forth the secretion of the gland. On removing such causes, the effect ceases; the epiphora goes off in proportion as the eye regains its natural state.

We sometimes see an increased lachrymal secretion, which cannot be traced to any of the causes just enumerated. The eye waters, especially when exerted or exposed to the air; there is no external redness, nor any discoverable exciting cause. In such cases, fatiguing exertion of the organ must be avoided, and attention should be paid to the state of the health. The eyes and the head generally should be washed with cold water in the morning. Astringent collyria, such as solutions of sulphate of zinc or of copper in rose-water, may be used three or four times daily, the liquid being allowed to pass between the lids, so as to come in contact with the conjunctiva. If these means are unsuccessful, the nitrate of silver in solution may be employed once a day. The citrine ointment may be applied to the edges of the lids, more especially if there should be any alteration of the Meibomian secretion.

Mr. Middlemore cured an obstinate and troublesome epiphora of one eye by applying three leeches above the eyebrow every week for about two months, and subsequently a narrow blister on the highest part of the forehead. (*Treatise*, vol. ii. p. 636.)

Stillicidium lachrymarum, as distinguished from epiphora, may be produced by any causes which interfere with the regular excretion of the tears.

The puncta lachrymalia may be contracted; and I have seen this affection proceeding to such an extent, that it was difficult to discern the situation of the openings. Under such circumstances, the puncta must first be enlarged with the point of a pin; we shall then be able to introduce the slender gold probes of Anel [fig. 134], and to restore the natural size of the apertures.

Fig. 134.



In introducing these probes, for the purpose either of opening the contracted puncta, or of examining the lachrymal canals, we must bear in mind the exact direction of the tubes, which do not pass in a straight line from the puncta to the sac, but first proceed perpendicularly, then make a sharp bend or elbow, and afterwards run horizontally, or nearly so, to the sac. [See plate V. fig. 27.] The probe, therefore, must be entered perpendicularly downwards in the lower, upwards in the upper lid; it must then be turned and directed almost horizontally to the sac.

Injuries of the lachrymal canals are mentioned as causes of stillicidium lachrymarum. My experience leads me to doubt the correctness of the

statement. In a case of carcinomatous ulceration affecting the lower lid, related at page 139–140, I removed the inferior lachrymal canal. No watering of the eye ensued. I saw a gentleman with ectropium of the lower lid consequent on a lacerated wound. It appeared from his own account, and that of the surgeon who had attended him, that the lid had been quite detached at the inner angle, and had experienced great contusion, followed by partial sloughing. The cicatrix had become fixed to the bone, and thus the lid was drawn downwards, particularly towards the nose. The inner extremity of the tarsus was about twice its proper distance from the nose, and drawn towards the cheek, so as to evert the inner third of the lid. The inferior punctum, on first view, seemed obliterated; but on close search it was found, so reduced in size as to be barely visible; from this circumstance, together with the ectropium, it was obviously incapable of absorption. There was not the slightest stillicidium.

Graefe has mentioned that the two puncta and canals were taken away in an operation performed for the removal of cancerous disease. There was no subsequent watering of the eye. (Graefe and Walther's *Journal*, vol. iv. p. 585.)

I have never seen any obstruction of the lachrymal canals, except as a consequence of injury, operation, or the pressure of tumors. The use of Anel's probes, therefore, in reference to these canals, is unnecessary, except in the contracted condition of the puncta.

The most common cause of stillicidium is obstruction of the nasal duct, which may be produced by thickening of its membrane, by stricture, by partial or general obliteration, or by pressure from various diseases in neighboring parts.

SECTION V.—DISEASES OF THE SEMILUNAR MEMBRANE AND CARUNCULA LACHRYMALIS.

These parts are involved, when the conjunctiva is inflamed. Conjunctivitis may commence and be more active in this quarter, which might be the seat of a somewhat limited inflammatory disturbance under the excitement of a local cause, such as a foreign body of mechanical or chemical action. Under these or similar circumstances, there would be nothing peculiar in the inflammatory disturbance or its treatment.

Warts, polypi, or other excrescences, may grow here as on other parts of the conjunctiva.

Encanthis.—Enlargement of the caruncula lachrymalis has been described under this name. Two forms of the affection are mentioned; the innocent and the malignant. The former, which is represented as simple enlargement usually consequent on inflammation, is described at length in treatises on diseases of the eye, and directions are given for its treatment by applications and operation. Having never seen an enlarged caruncula requiring excision, or any other surgical treatment, I conclude that the case must be rare. I have never seen a malignant encanthis; and speaking from my own experience, I should say that the part is not liable to affections of that character. If an inflammation seated in the internal angle of the eye, were too diligently treated by local means, especially by the stimuli which have been so liberally employed in many cases of ophthalmic inflammation, aggravation of mischief might ensue, with swelling, and an unfavorable appearance of parts that might be mistaken for malignant.

[*Spontaneous Hemorrhage from the Caruncula Lachrymalis.*—Dr. Kersten, of Magdeburg, relates (*Rust's Magazin*, Bd. 58, Heft 1), a

case in which spontaneous hemorrhage took place from the caruncula lachrymalis in a girl eighteen years of age, who came under his notice. This patient was the daughter of phthisical parents, both of whom died during her infancy. In her childhood she had but indifferent health, suffering from rheumatic pains in various parts of her body, and afterwards from fits, resembling epilepsy. When twelve years old, she received a wound over her left orbit, so small that it left no scar visible. Soon after the receipt of this injury, however, blood began to flow from both eyes, and continued to run for fourteen days, in such quantity as to render her very weak. From this time, the bleeding returned every four weeks, but no medical assistance was sought by the patient. In her sixteenth year the preliminary signs of menstruation occurred, but no secretion from the uterus appeared: the hemorrhage from the eyes, on the other hand, continued to occur with regularity. A physician who saw her at this time stated that the bleeding came on with regularity at 10 A. M. and 4 P. M., at each of which periods it continued for half an hour, and recurred daily for a fortnight. The blood issued in drops from the corner of each eye, but during its flow, the patient sometimes fainted. Pain in the head and eyes, a hard pulse, and considerable radiated redness of the conjunctiva, accompanied these attacks. The patient also asserted, that during their continuance, all objects seemed to her of a red color. After the preliminary symptoms had continued for some time, menstruation occurred, and the hemorrhage from the eyes ceased. This amendment, however, continued only for a few months, for, though the menses flowed regularly, yet hemorrhage recurred from both eyes, and on November 29, 1839, the patient came under Dr. KERSTEN's care. Her face was then covered with blood, which constantly oozed forth from between the eyelids, and she was unable to open her eyes, owing to great intolerance of light. She was extremely weak, though quite sensible, and her pulse was extremely small and feeble. At that time the hemorrhage observed a cycle of three days, continuing for that time, then disappearing for three days, and then once more recurring. In the intervals of the hemorrhage, the conjunctiva of the lids and of the globe was seen to be red and tumid, the cornea cloudy, the eyes intolerant of light. When the blood was flowing, its source was evidently the caruncula lachrymalis and the conjunctiva; and in the course of three days, the quantity amounted to eight or ten ounces. The patient's general health was much impaired, and she had an anemic and leucophlegmatic appearance. She remained only ten days under Dr. KERSTEN's observation, but at the end of a year he saw her again. During the interval, her general health had much improved, and the hemorrhage from the eyes occurred much less frequently, and no longer at regular intervals. Sometimes it did not take place for three weeks. She remained in the hospital eighteen days, during which time it occurred once to the amount of four ounces, but ceased within six hours. She did not on this occasion come into the hospital on account of the hemorrhage, and accordingly she left it as soon as another ailment, for which she had sought relief, was cured.]

SECTION V.—AFFECTIONS OF THE LACHRYMAL SAC AND NASAL DUCT.

Capillary aperture in the anterior part of the sac; congenital?—I have seen such an aperture in one instance, that of a boy at school, in whom it seemed to be a natural peculiarity, as no inflammation, nor any other affec-

tion of the part had been noticed. A small drop of clear fluid appeared frequently on the surface of the skin, just below the tendon of the orbicularis. It caused no inconvenience, except the occasional application of the pocket handkerchief. My advice was that it should be left alone.

Inflammation of the internal angle of the eye.—This part may be the seat of erysipelatous inflammation; and the attendant swelling, being over the lachrymal sac, may lead to the erroneous supposition that the sac itself is involved in the mischief. In a mild case the inflammation may subside without any unpleasant result; sometimes, however, it extends to the lids, which become red, swelled, and painful; it may reach the lachrymal ducts and sac, and cause increased mucous secretion, with temporary obstruction to the absorption and excretion of the tears. If it proceeds to suppuration, the matter should be evacuated early, to prevent increase of the collection, and thus diminish the risk of subsequent deformity.

The old writers give the name *anchylops* (or *ancylops*) to inflammatory swellings of the inner angle, whether caused by disease of the lachrymal sac, or of the parts exterior to it; and that of *ægilops* to the same disorder in its ulcerated state. There has been much discussion respecting the exact sense and proper application of these unmeaning terms, which have now become nearly obsolete. BEER, however, calls the inflammation just described, *anchylops erysipelatosa idiopathica* (*Lehre*, vol. i. p. 331); in the ulcerative stage he names it *ægilops simplex*. (*Lib. cit.*, p. 334.)

Acute inflammation of the sac (*Dacryo-cystitis*).—The lachrymal sac and duct are susceptible of inflammation in various degrees. The acute idiopathic form of the affection, as BEER has observed, is comparatively rare. The local suffering and the constitutional disturbance are much more considerable than might have been expected from the small extent of membrane which is the seat of disorder. The explanation of the peculiarity is afforded by the vascularity of the membrane, and its inclosure in an unyielding bony receptacle. A dull pain is felt in the corner of the eye, shooting to the nose, and to the eyeball, and at the same time the lachrymal sac forms a hard, clearly defined, and very sensitive swelling, about the size of a horse-bean. This swelling gradually becomes of a bright red, and will not then bear the slightest touch. The pain is now of the most acute kind, with throbbing and sense of tension, extending from the internal angle to all the surrounding parts of the orbit and head. The internal angle and the palpebræ become swollen by serous effusion, and the latter are tumefied as in erysipelas; but the enlargement is firmer. The swelling sometimes extends to the whole side of the face and temple. In this general tumefaction, the circumscribed enlargement of the sac can still be felt, and is usually pointed out by greater prominence and redness. The swelling of the inflamed membrane closes the nasal canal, and prevents the passage of tears into the nostril; hence dryness of the latter, and watering of the eye. So violent an inflammation seated in the head, and near the eye, may be expected to cause serious febrile disturbance: the general symptoms are of an inflammatory description, sometimes proceeding to delirium at night.

After a certain time increased secretion takes place from the inflamed membrane, but without bringing the relief that might be expected, because the effused matters are prevented from escaping by the unyielding nature of the surrounding parts. Coagulating lymph may be poured out, and cause obliteration of the nasal canal. Suppuration of the lachrymal sac may occur, with increase of the swelling at the internal angle, and fluctuation; the integuments become prominent, and the swelling bursts if not previously opened. I have seen the skin so distended before the bursting of the abscess, that mortification has ensued. This took place in a female

of full habit, in whom the local and general symptoms were most severe. She would not submit to a puncture of the abscess, and the skin sloughed to the size of a shilling. If the abscess burst, or be opened surgically, pus escapes, with which lachrymal fluid may be mixed; or pus may be discharged alone at first, mucus and tears being gradually mingled with it as the inflammation subsides. When the latter has ceased, the discharge consists merely of lachrymal fluid with mucus, the latter being either transparent or opaque; in the latter case it is yellowish, or partially clear with opaque streaks. The opening communicating with the sac, and sometimes where the collection has been left to burst, being at a little distance from it, is a *fistula lachrymalis*, or more properly a *fistula of the lachrymal sac*. There may be more than one external opening. More frequently the case does not proceed to suppuration and fistulous aperture. The natural secretion of the mucous membrane is increased and altered in appearance, becoming thick and yellow, so as to resemble pus. In this state, it either escapes spontaneously through the puncta lachrymalia, or issues from them copiously when pressure is made on the distended sac. As the inflammation subsides, the secretion becomes less thick and yellow; it then appears semi-transparent, with whitish or yellowish streaks, and at last is a clear mucus. These changes indicate the abatement of inflammatory congestion and tumefaction, and the return of the membrane to its natural state. The sac and duct recover their proper caliber, the passage into the nose is restored, and the complaint is at an end. If the nasal duct should have become permanently obstructed during the acute period, its surface and that of the sac pass into a state of chronic inflammation, attended with increased mucous secretion, which, with the lachrymal fluid, accumulates in, and distends the sac, forming a tumor in the corner of the eye. Pressure on this swelling occasions the escape through the puncta lachrymalia of the mingled tears and mucus, under various appearances, according to the degree of inflammation in the membrane. A watery state of the eye, with dryness of the nostril, and flow of tears over the under lid, are consequences of such obstruction in the nasal duct.

Treatment.—The severe local and general symptoms attendant on acute inflammation of the lachrymal sac in a robust subject of full habit, require active antiphlogistic means. According to the urgency of the case, blood must be taken by venesection, cupping on the temple, or leeches. The latter, applied over the sac, and its neighborhood, will generally answer the purpose. The loss of blood must be repeated, until the inflammation is reduced. Fomentations and poultices are the best local applications. The internal treatment and diet must be the same as in other inflammations.

As soon as the existence of fluctuation indicates that suppuration has occurred, an early and free opening is advisable, as a means of immediate relief from acute suffering; and in order to limit the extent of mischief, we persist in the employment of measures calculated to reduce inflammation. The swelling of the membrane subsides; the discharge undergoes the successive changes already described; the natural course of the tears is re-established, and the opening into the sac closes; or the latter may remain open, if the nasal duct should continue impermeable. We should be contented, in these cases, with opening the sac, and not introduce probes, or attempt to force a passage into the nose. The mechanical irritation of such proceedings cannot but aggravate the already acute inflammation of the mucous membrane. If we pursue a soothing plan, the course of the tears will be re-established as the inflammatory tumefaction subsides; or, if the intervention of art should be necessary for clearing an obstructed nasal

duct, it may be resorted to more advantageously when the general inflammatory disturbance has been removed.

Chronic inflammation of the lachrymal sac.—In this affection, as in the more acute disorder, there is swelling of the inflamed membrane, and consequent interruption to the passage of the tears; hence arise the following symptoms. Swelling of the internal canthus, in the situation of the lachrymal sac; watering of the eye so that it is full of tears, which occasionally run over the lower lid and down the cheek (*stillicidium lachrymarum*), dryness of the nostril on the affected side from the absence of the lachrymal fluid. The tumor may be colorless, or more or less red, these differences depending on the degree of inflammation: from the same cause it may be either indolent or painful. In size, it may be equal to a pea, a horse-bean, or a nut: these varieties depend partly on the duration of the affection; however, the sac sometimes enlarges considerably without any apparently adequate cause. Pressure on the tumor causes the contents of the sac to escape through the puncta, or through the nasal duct; the latter event is comparatively rare. Sometimes the contents cannot be forced out in either direction. The fluid thus pressed out varies in appearance, according to the state of the membrane; it may be thick and yellow, like pus, or a viscid, opaque, and streaked mucus, or a clear mucous fluid; tears may be mingled with these in various proportions. When the secretion is copious, and the parts free from active inflammation, it may escape from the puncta spontaneously, or in consequence of the slight pressure caused by contraction of the orbicularis palpebrarum. From this increased discharge, the affection has sometimes been called *blennorrhœa sacci lachrymalis*. If the sac be emptied by pressure, it will fill once, twice, or oftener, in twenty-four hours. Patients sometimes content themselves with this simple mode of relief in preference to a surgical operation.

When disease of the sac has been kept up for some time by obstruction of the nasal duct, the affection generally extends to the palpebræ, of which the mucous lining is found red and villous, with some mucous discharge, and more or less affection of the Meibomian glands, the lids being in some instances agglutinated during the night. The inflammatory disturbance may extend to the surface of the eye generally; but the condition of the latter varies considerably in different instances, and in the same individual at different times. If the atmosphere is mild or warm, and the eye not excited by exertion, there is no watering nor any inconvenience. Exposure to cold air, and especially to sharp winds, causes increased secretion of tears, which occasion serious annoyance by irritating the eye, and flowing abundantly over the cheek. In some cases the eye is permanently irritable, and becomes inflamed from slight occasional causes, such as employment in reading, or writing, or other modes of exertion. The lachrymal sac, too, is liable to attacks of more considerable inflammation, in which the eye is often involved. In the course of such attacks, the sac may become distended, inflame and ulcerate; an external opening or fistula will thus be produced.

The circumstances more particularly deserving our attention in these cases, is the degree of inflammation; the affection being originally inflammatory, and the obstruction being kept up by the inflammation. The increased secretion, or blennorrhœa, proceeds from the inflamed mucous membrane, and the obstruction is from the same cause, which produces tumefaction of the membranous lining, and consequently diminished caliber or closure of the duct. The writers on surgical operations have not, in general, taken a proper view of the subject, having directed their attention merely to the obstruction, and the mechanical means of removing it. The

disorder is considered under the head of *fistula lachrymalis*, which, instead of being an essential circumstance, is merely an occasional concomitant.

In his work on diseases of the eye, SCARPA appropriates one chapter to this affection, of which he takes what appears to me an erroneous view. He says, that "the curdy viscid humor mixed with the tears, which in the first instance flows back again through the puncta lachrymalia, is not formed by the sac, as is commonly believed; but is for the most part transmitted to it from the eyelids by the puncta lachrymalia, from it regurgitates upon the eye whenever the sac, which is gradually filled with it, is pressed upon. This puriform humor is principally furnished by the internal membrane of the palpebræ, and comes more particularly from the lower eyelid along the tarsus, and from the glands of MEIBOMIUS: the sebaceous matter peculiar to those glands, being not only secreted in larger quantity, but also acquiring an acrid and irritating quality, according to the general state of the habits with which they participate." He states, "that the lachrymal sac has no other share in the disease than that of receiving and retaining, together with the tears, the puriform humor which is transmitted to it from the affected palpebræ." He considers that the palpebral mucus is so tenacious, and the Meibomian secretion so thick, that they lodge in the sac and duct, and thus produce obstruction. In conformity with these notions, he calls the disease *puriform flux of the eyelids*, (*flusso palpebrale puriforme;*) and he shapes his practice accordingly, employing astringent washes to the palpebral linings, and stimulating ointments to the ciliary margins to correct these vitiated secretions. Although these means may be employed with advantage in some cases, and after other measures, I consider the pathological views on which they rest to be entirely unfounded, being convinced that the lachrymal sac and nasal duct are the original and essential seat of disease, while the palpebral affection, when it exists, is only secondary.

Is it probable that fluids, which can pass through the small lachrymal puncta and canals, will stick in, and block up, the much larger nasal duct? In many affections of the lids, such as inflammation and ulceration of their margins, catarrhal, purulent and gonorrhœal ophthalmia, there is increased secretion, often very abundant, and generally viscid; but the lachrymal passages do not become obstructed. Again, in lippitudo and psor-ophthalmia, where the Meibomian secretion is much altered, no disease of the sac or duct takes place. On the other hand, the palpebræ may be perfectly healthy when the nasal duct is obstructed.

Treatment.—Our first object, the removal of inflammation, may be accomplished by the application of leeches over the sac, and other corresponding measures. We shall thus prevent the enlargement of the sac, suppuration, ulceration, and fistula, as well as the extension of disorder to the eye. Under these means the swelling of the membrane often subsides, the increased secretion ceases, and the passage of the tears into the nose is restored. If obstruction of the duct, and consequent distension of the sac should continue after inflammation has been removed, the patient should empty it occasionally by gentle pressure in the corner of the eye. The treatment recommended by SCARPA may be advantageously pursued under such circumstances; that is, we may use astringent lotions, and stimulating ointments to the lids. Solutions of the sulphate of zinc, sulphate of copper, or nitrate of silver, answer the former purpose; they may be employed at first in the strength of two grains to the ounce of distilled water. The sac having been previously emptied by pressure, and the mucus removed by a soft handkerchief or rag, two or three drops of the astringent collyrium should be placed in the corner of the eye, from which it will be absorbed by the puncta, and conveyed into the sac. It is unnecessary to impel it directly

into the latter; indeed the use of ANEL's syringe, the point of which is sufficiently small to enter the puncta, often aggravates the mischief by its mechanical irritation. The citrine ointment, that of red precipitate, or the ointment of JANIN (see page 128) may be applied occasionally to the edges of the lids. By such management we may remove the unpleasant effects of the complaint, although obstruction of the duct may continue, with occasional flow of tears over the cheek, and may require pressure on the sac from time to time to prevent its distension.

The lachrymal sac is sometimes distended without permanent obstruction of the duct. In an elderly woman, of spare habit, the left sac formed a conspicuous tumor in the corner of the eye, without redness or pain, so large, that the receptacle must have been three or four times the natural size. On moderate pressure the contents descended into the nostril, and flowed out of the nose if the head were held forward. The fluid thus evacuated consisted at first of mucus with yellow streaks; after surgical treatment, it was a clear mucous fluid. The complaint had existed seven or eight years, and caused but little inconvenience.

Permanent obstruction of the nasal duct.—This may take place as a consequence either of acute or chronic inflammation; or it may be produced by extension of disease from the nose. It occurs occasionally in the latter way, in strumous children: inflammation begins in the Schneiderian membrane, and then creeps on to the lining of the sac. The general management, and the internal remedies recommended for strumous ophthalmia, particularly the sulphate of quinine, may be advantageously employed in strumous ophthalmia of the lachrymal sac.

Inflammation of the sac and obstruction of the nasal duct are occasional consequences of small-pox in children.

If permanent obstruction of the duct should cause repeated inflammations of the sac and of the eye, and if these inconveniences cannot be prevented or removed by the means already pointed out, we must resort to further measures for restoring the passage of the tears into the nose. Much mischief may ensue from neglect. The sac may ulcerate, so as to form a fistulous aperture, giving issue to mucous discharge and tears; this may be either a simple opening, or complicated with thickening of the surrounding cellular tissue, redness of the integuments, or an unsightly growth of fungous granulations. Continued distension of the sac may lead to slow enlargement, in which it forms a swelling in the corner of the eye, as large as a bean or nut, without change of color in the skin. The swelling is soft, and yields to the pressure of the finger, under which its contents, consisting of tears mixed with transparent, or yellowish streaked mucus, escape through the puncta or the nasal duct. To this state of the organ BEER (*Lehre*, vol. i. §§ 367 and 588, vol. ii., pp. 151—183) has given the inappropriate name of rupture of the sac (*hernia sacci lachrymalis*); it has been also called *mucocele*.

If the swelled sac feels firm and resisting, without fluctuation, or with only a very obscure sense of it, and if it cannot be emptied by pressure, BEER calls the case dropsy of the sac (*hydrops sacci lachrymalis*).* This and the former affection are both comprehended by SCHMIDT† under the common name of *varix* of the lachrymal sac. BEER says that in the dropsical affection the sac continues to enlarge, and that it may reach the size

* Loc. cit. In the 41st number of the Chirurgische Kupfertafeln, there is a plate (pl. 208) by Professor VON AMMON, of Dresden, with colored figures, in which it is attempted to show the external characters of the swellings in the corner of the eye caused by various affections of the lachrymal sac.

† Die Krankheiten des Thränenorgans, p. 310.

of a pigeon's egg; that, as soon as the swelling has attained the magnitude of a bean, the integuments become of a livid red, the color growing deeper as the swelling enlarges; that it is quite indolent, and resists pressure; and that the cavity is filled with a secretion like thick glue. Such a state of the sac, in respect to size and contents, has not come under my observation.

Although caries of the os unguis is spoken of as a frequent occurrence in observations on fistula lachrymalis, I do not remember to have seen it as a consequence of disease commencing in the sac.

Treatment.—Numerous and various means have been proposed for removing obstruction of the nasal duct: they are usually mentioned as operations for fistula lachrymalis, although, in the great majority of instances, there is no fistulous opening. A description and consideration of all these proceedings would fill a moderate volume; but it may be well omitted, as the greater part are obsolete.*

Before performing any such operation we should ascertain that there is a permanent obstruction, which cannot be removed by other means. If the inflammation of the sac be treated on the principles already explained, the cases requiring operation will be very few. We should avoid it as long as we can, because it is a temporary and imperfect remedy. If we merely clear away the obstruction, it will probably soon recur. To avoid this the patient must submit to the inconvenience of wearing a foreign body in the duct, to maintain it in a pervious state.

Anel, a French surgeon, who invented the small probes for the puncta, devised a syringe with a fine point for injecting fluid into the lachrymal sac, and thus forcing the obstruction of the duct.† When the latter is so slight that it gives way to the pressure of the finger on the distended sac, and allows the contents to pass into the nose, it might also yield to the syringe. But the force exerted by the latter is altogether insufficient to overcome the ordinary permanent obstruction of the nasal duct. Indeed, the fluid thrown in at one punctum escapes by the other; we can prevent this by compressing the other lachrymal canal; but the inadequacy of the power to the intended effect remains.

The small probes, introduced through the puncta, have been employed to clear the obstructed nasal duct. When the probe has entered the sac through the superior canal, it should be raised from the horizontal to the perpendicular position, which the looseness of the lid allows, and then carried through the nasal duct into the nose. The extremities of these probes are, however, so small, that they easily become entangled in the irregularities of the membrane, so that we cannot readily judge whether the instrument is stopped by that cause, or by an obstruction in the duct. By pushing it, in the former case, we wound the membrane, and drive the instrument between it and the bone. Even if we conduct it safely to the obstruction, in which object failure may often be expected, from the necessary change in the direction of an instrument going first through the lachrymal canal, then through the sac and duct, it is badly calculated in size and strength for forcing the obstructed part. The small opening effected by it is inadequate

* J. L. Petit, Traité des Maladies Chirurgicales, tom. i. pp. 327—404. J. D. Metzger, Curationum chirurgicarum, quæ ad fistulam lachrymalem hucusque fuere adhibitæ, historia critica, 12mo. Monaster, 1772. Sabatier, Médecine opératoire nouvelle edition, 1822, tom. ii. pp. 206—261. Dictionnaire de Médecine et de Chirurgie pratiques, art. Fistules, tom. viii. pp. 179—214. Juengken, die Lehre von den Augenoperationen. Kap. xxii.: Operatio Fistulæ lachrymalis, pp. 406—409.

† Nouvelle Méthode de guérir les Fistules Lachrymales: et Recueil de différentes Pièces pour et contre la Méthode. Turin, 1713. Dissertation sur la nouvelle Découverte de l'Hydropisie du Conduit Lacrimal. Paris, 1716.

to the transmission of the tears, and will soon close again. I therefore consider the employment of ANEL's probes in this way more likely to do harm than good. He himself acknowledges that the method is applicable to mild cases only.

[Our experience with this method of treatment has led us to a very different conclusion as to its value. We are, indeed, persuaded that it is applicable to most cases of obstruction of the nasal duct, and that it is the safest, most rational, and least painful method of treatment. At the end of this section we shall expose our views more fully.]

It has been proposed to fill the lachrymal sac with quicksilver, by means of a glass tube, with a steel stopcock, terminated by a steel tube sufficiently minute to enter the puncta and lachrymal canals.* It has been expected that the weight of the metal thus conveyed into the sac, would cause the obstruction to give way. As the cavity of the sac does not exceed the size of a garden-pea, the force thus applied would certainly cure no obstructions which would not have got well of themselves. A more considerable power, corresponding in degree to the height of the column, may be applied in the act of injecting the sac, if the escape of the mercury through the other punctum be prevented by compressing the corresponding canal. If the obstruction does not yield to this power, we cannot expect it to give way to the weight of the small globule contained in the sac.

As the nasal duct, after having been cleared and enlarged, will contract again, it has been proposed, in order to prevent such relapse, and to maintain a permanent passage for the tears, to introduce, through an opening in the lachrymal sac, a gold or silver tube, [figs. 134, 135,] and to leave it there. In length and size the tube must be accommodated to the nasal duct and the adjoining portion of the sac. Its upper end, which is a little expanded, rests in the lower portion of the lachrymal sac, while the lower extremity, terminating in an aperture cut obliquely, should clear the opening of the nasal duct.† In order to introduce it, the lachrymal sac must be laid open. The tendon of the orbicularis palpebrarum is the guide for this incision. The distended sac must be punctured below the tendon with a double edged pointed knife, the point of which is directed towards the cavity of the sac. If the mere puncture does not make a sufficiently ample opening, the knife may be carried downwards and outwards in a direction parallel to the edge of the orbit. The escape of mucus and tears shows that the sac has been opened. A silver probe is carried through the opening thus made in the sac, and into the nasal duct, not perpendicularly downwards, but a little backwards and inwards; the inclination back-

Fig. 134. Fig. 135.

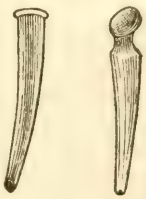

* A New Method of Treating the Fistula Lachrymalis, by Mr. (afterwards Sir WILLIAM) BLIZARD, in the Philosophical Transactions, vol. lxx. p. 239.

† The employment of the tube, proposed in France by PELLIER DE QUENGSY, in his Recueil de Mémoires et d'Observations sur les Maladies de l'Œil, Montpellier, 1783, was strongly recommended in this country by Mr. WATHEN, in "A new and easy Method of applying a Tube for the Cure of Fistula Lachrymalis." 4to. London, 1781; second edition, 8vo., 1792. In this work, the tubes and the other means connected with their employment, are minutely described and figured. [Fig. 135 represents WATHEN's tube.]

The same plan was followed exclusively by BARON DUPUYTREN, whose method, with the forms and dimensions of the tube and subsidiary apparatus, are detailed in the two works already quoted, see note, p. 834. The instruments employed by DUPUYTREN are delineated in FRORIEP's Chirurgische Kupfertafeln, No. xxx., pl. 147. [Fig. 134 represents DUPUYTREN's tube.]

wards being just such as the projection of the eyebrow would give to a probe passed into the nasal duct from above. We shall meet with resistance at the point of obstruction, and we must employ a gradually increased pressure to overcome it; the probe then goes on into the nose, from which, on using a handkerchief, a little blood escapes. If we cannot force the obstruction with the blunt end of the probe, we must have recourse to the sharp point. The resistance may be so great, as to render it advisable to desist, and repeat the attempt after an interval of two or three days. The tube is placed in the nasal duct by means of a steel stilet, [fig. 136,] bent

Fig. 136.

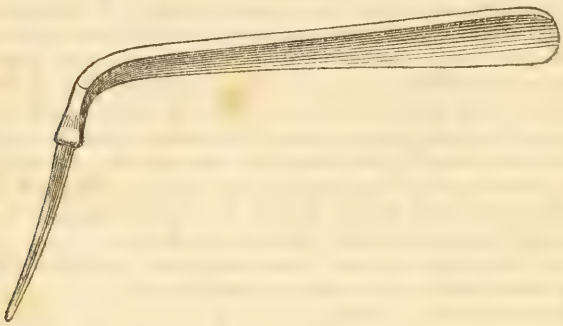

at a right angle, of which the portion beyond the bend corresponds to the cavity of the tube. The latter must be fairly lodged in the duct, with its upper or extended portion occupying the lower part of the sac. The skin heals over, the tube provides an artificial passage for the tears, and the immediate result of the operation appears very favorable. Unfortunately, the future history of these cases is not equally satisfactory. We could hardly expect, *à priori*, that a metallic tube would permanently answer the purpose of the natural duct. We find accordingly, that the artificial substitute, after the lapse of some months, gets out of its place, rising too high, or sinking too low, or that it becomes obstructed. It causes inflammation in some instances, and in others, pain more or less severe, an intolerable aching in the corner of the eye and cheek, which cannot be remedied without removing the tube. I have seen all the inconveniences now enumerated resulting from this practice, and have found it necessary, on account of them, to remove tubes which had been introduced by others, a proceeding often attended with considerable pain. That the necessity for such removal is not a very rare occurrence, may be inferred from the circumstance of the Baron Dupuytren having devised an instrument expressly calculated for the extraction of the tubes.* In one case, after removing the tube, I found it filled with a slender production of the mucous membrane exactly like a mucous polypus, entering above, and extending nearly to the lower end of the tube. That the method, although strongly recommended by Mr. Wathen, was not permanently successful, may be inferred from the cir-

* This instrument, which has received the name of tire-canule, is described and figured in Graefe und Walther's Journal, vol. viii., p. 153, tab. 1, fig. 12. The surgeon, who contributes this account, says that he saw several canulæ extracted while he was in Paris; and that, in the case of a young girl, the tube had sunk so low that it could not be withdrawn from above, so that Dupuytren was obliged to extract it from the nose with forceps, which was only accomplished with considerable trouble.

cumstance that his partner, Mr. WARE, subsequently proposed and advised another mode of proceeding.

VELPEAU says, that it is often necessary to withdraw the canula in consequence of its rising under the integuments; that M. DARCET relates twenty-seven cases, in which its extraction had been required; that it sometimes sinks into the nasal fossa, and hence the operation fails. M. DELPECH had seen a case, in which it had gone through the roof of the mouth. (*Nouveaux Elémens de Médecine Opératoire*, vol. i., p. 647.) Professor JAEGER, of Vienna, informed me that an instance of the latter kind had come under his own observation.

BEER recommends the employment of catgut to enlarge the constricted duct. The sac must be opened, and the obstruction of the duct removed in the manner already described. A piece of catgut [fig. 137] is then to be introduced into the sac, and passed through the duct into the nose, when it will either present itself at the nostril, so that it may be drawn out with forceps, or it must be forced out by the patient blowing his nose. The extremity of the catgut, thus brought out at the anterior aperture of the nostril, is to be fixed by sticking plaster in a convenient position near the ala nasi; and the rest of the string may be fastened in a coil to a cap, or may be fixed on the brow by a turn or two of a narrow roller. Every day a fresh portion of the catgut is drawn down through the duct, and that which had been there the previous day is cut off, the extremity being fastened as before. After thus consuming a piece of catgut of the ordinary length and size of the fiddle-string E, BEER commences with a similar length of the string A, and then with the string D. When this has been passed through, he considers the cure completed, and allows the opening into the sac to heal.*

Fig. 137.

The method, proposed by LAFOREST,† of examining the nasal duct, and removing obstructions in it by means of instruments introduced at the inferior orifice, which seems hardly to have been employed, except by the inventor, has again been brought into notice by Mons. GENSOUL, of Lyons, whose mode of proceeding is thus mentioned in the *Dictionnaire de Médecine et de Chirurgie pratiques*.‡ "M. GENSOUL employs the escharotic method in most cases of fistula lachrymalis, making his applications by the inferior orifice of the nasal canal. He filled that canal, in the dead body, with fusible metal, which, being removed when cold, by breaking away the bone, afforded a model for probes, capable, as he says, of entering and passing the canal with the greatest facility. When the application of caustic is required, the instrument is formed into a porte-caustique analogous to that employed by DUCAMP in strictures of the urethra. The probe is bent, nearly at a right angle, about nine or ten lines from its extremity; near this curve there is a slight lateral inflexion, the direction of which must be opposite for the two nostrils; it corresponds to the projection of the nasal process of the superior maxillary bone. M. GENSOUL represents that his probe passes into the lachrymal sac as easily as a catheter into the bladder."

The mode of proceeding, which I consider the most eligible, as combining the advantages of efficiency, simplicity, and complete safety, is that

* Lehre, vol. ii., in the chapter on the hernia sacci lachrymalis, and hydrops sacci lachrymalis, p. 151—183.

† Nouvelle Méthode de traiter les Maladies du Sac Lachrymal; Mém. de l'Acad. de Chirurgie, tom. ii., p. 175. The instruments are represented in plate xiii.

‡ Tom. viii., p. 210.

introduced by the late Mr. WARE,* of placing in the lachrymal sac and duct what he calls a nail-headed style [see fig. 138], that is, a cylindrical piece of silver, about the thickness of an ordinary probe, long enough to reach from the corner of the eye to the termination of the nasal duct, with a head like that of a nail placed obliquely at its upper end, which is a little curved, so that the style may sit close in the corner of the eye. The sac must be opened by an external incision below the tendon of the orbicularis palpebrarum [see fig. 140], and the obstruction of the duct must be cleared by adequate pressure with a probe, as in other modes of proceeding. The style may then be introduced, taking care that its head is secured, so as to prevent it from sinking into the wound, as it is intended that its head should rest on the integuments in the corner of the eye, where, being blackened, it appears as a small black patch. Instead of introducing the style immediately, I prefer placing a portion of bougie in the duct, turning down its upper end [fig. 139], so as to prevent it from sinking into the sac. The small end of

Fig. 138. Fig. 139.

Fig. 140.

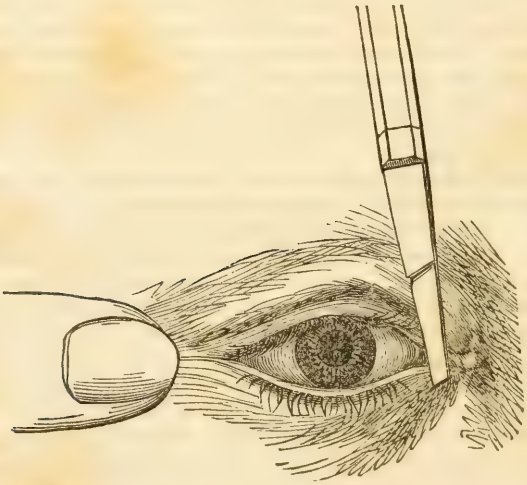

the smallest bougie will answer the purpose; the length should be an inch and a half, or rather less. In one or two days this should be removed, and the passages may be cleared by gently injecting a little tepid water through the wound by means of ANEL's syringe, on which a blunt end is screwed when it is employed for this purpose. Another piece of bougie, of the same or a larger size, is then introduced, and this plan is continued, with a gradual increase in the size of the bougie, for a week or ten days. The

* Observations on the Treatment of the Fistula Lachrymalis, 8vo., London, 1798. These observations are reprinted, together with an Essay on the Epiphora or Watery Eye, and Additional Remarks on the Epiphora, in a volume of tracts on the eye, published after the death of the author by his son, Mr. MARTIN WARE. Plate ii. of this volume contains figures representing the styles.

external orifice will now be reduced to a small round opening, through which a little mucous discharge may escape, and the style may be substituted for the bougie. The patient soon learns to remove and replace the style; and he takes it out and cleans it, from time to time. It might be supposed that the passage of the tears would not be assisted by introducing a solid substance into the duct. Experience, however, shows us that the fluid takes its natural course, when a style is thus kept in the lachrymal passages, and the enlargement of the urethra round a catheter left in the canal affords an explanation of the circumstance. The style, indeed, becomes so loose, that it sometimes falls out when the head is bent downwards. As the presence of the instrument causes neither pain nor inconvenience, I recommend patients to wear it permanently. According to my experience, this method maintains the natural course of the tears with the least trouble to the patient.

[Dr. Edward Lubbock describes, in the *Edinburgh Med. and Surg. Journal* for Oct., 1835, a knife [fig. 141] which he has devised for

Fig. 141.

opening the lachrymal sac and dividing the stricture in obstructions of this canal, which appears to possess advantages over the lancet or bistouries ordinarily employed for that purpose. The blade of the knife is $2\frac{3}{4}$ inches long, including the shoulder, and less than $\frac{1}{8}$ of an inch broad. In shape it resembles a catling, and cuts upon both edges for the extent of half an inch from its point where the knife is thin; but as the thickness of the instrument increases towards the handle, the edges become too thick to cut easily; the groove extends exactly along the centre of the anterior surface; the posterior surface is slightly convex, in order that the groove may be made as deep as possible.

When made according to this fashion, the length, together with the extreme narrowness of the knife, and its being precisely of the same width throughout, allow of its ready passage through the nasal canal, so that the point will fairly rest upon the inferior wall of the nostril, and the groove will be placed looking directly forwards, and most conveniently for the easy passage of the style, which, of course, is readily passed along it, every obstacle having been already overcome by the knife, the point of which has penetrated beyond the limits of the nasal canal into the inferior meatus of the nose. The operation is most easily performed whilst the patient is sitting on a chair, with his head leaning against the breast of the operator, who stands behind the chair, and directs the knife inwards, downwards, and a little backwards [see fig. 142], whilst he keeps the lower eyelid stretched by the finger of the left hand applied upon the margin of the orbit [see fig. 140]. Should it be the right lachrymal sac, the corresponding eyelid is most readily kept tense by the aid of an assistant, provided that the surgeon is not ambidexter. When performed in this manner the whole opera-

Fig. 142.

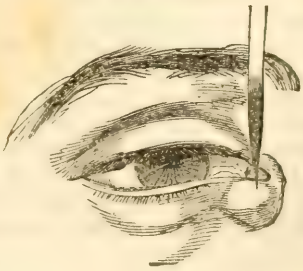

tion is over in two or three seconds; the bistoury withdrawn, and the style safely lodged in the canal. The opening into the lachrymal sac, the division of the obstruction, and the passage of the style are all effected by one movement of the knife.

Dr. Lubbock has found it advantageous to use a pin long enough to rest upon the floor of the nostril, for in this manner we prevent the head of the style from sinking within the lachrymal sac, which, whatever be the shape of the head, whether flat like a nail, or globular, is always sooner or later followed by increased inflammation and suppuration. The length of the pins which Dr. Lubbock employs varies from $1\frac{1}{2}$ to $1\frac{7}{8}$ inch; and in cases where the sac has become much distended by matter, and the surrounding parts have been much thickened by the effusion of lymph, he has in the first instance used them as long as two inches, or $2\frac{1}{8}$ inches. The length of the duct varies in the same manner as the length of the face, which, when measured from the top of the nose to the upper *incisores*, is very different in different persons, and even in the same person. As the swelling subsides, a small piece will require to be cut off from the end of the style. But Dr. L. always prefers having it rather too long than too short, until the swelling and inflammation have completely subsided, when it may be made to rest accurately on the fistulous orifice.

As to the propriety of altogether omitting, after a time, the use of the style, Dr. L. thinks that it is best to discontinue its use gradually; as by taking out the style one hour on the first day, two hours on the second day, and so on.]

If there should be fistula of the lachrymal sac, some modification of the proceeding may be necessary, such as a previous slitting of the fistulous track; or this may be done at the same time with the opening of the sac.

Complicated contrivances for compressing the enlarged lachrymal sac, and thus reducing it to its proper dimensions, are described and delineated in surgical works; I must doubt whether they have been employed, as they seem ill calculated to answer the intended purpose. Of one thing I am certain; that the annoyance of wearing such machinery would be greater than the inconveniences incidental to the complaint.

The various proposals for conveying setons into the nasal duct from the nose, and for attacking the constricted portion with escharotics or the actual cautery, are either obsolete or inappropriate, and therefore do not require detailed consideration.

When inflammation of the sac occurs repeatedly, and the nasal duct is obliterated, so that the foregoing methods are inapplicable, it has been recommended to expose the cavity completely, and to destroy the mucous membrane by the actual cautery, by pure pot-ash, or some other escharotic. Another method, suggested under similar circumstances, is that of perforating the os unguis, so as to make a direct opening into the nostril. I have seen no cases requiring such proceedings.

Obstruction of the duct may arise from syphilitic disease of the nose; from caries or exostosis of the surrounding bone; from morbid growths of various kinds, originating in the nose or antrum. Suppuration and ulceration of the sac, with fistulous openings, may ensue in such cases, which admit of palliative relief only.

Fistula lachrymalis has been kept up by the presence of a calculous concretion, and has healed on its removal. (*Graefe und Walther's Journal*, vol. x., p. 597.) I have not seen such formations in the lachrymal passages.

[The operations described in the preceding pages for the re-establishment of the passage for the tears to the nose, are, we believe, not often required—rarely, if ever, except in cases where the inflammation has been so violent as to cause effusion of lymph and adhesion of the sides of the nasal duct, thus completely obliterating this passage. When the obstruction, however complete, is the result merely of thickening of the mucous membrane lining the nasal canal, forming, as it were, a stricture, it may be cured by a recourse to proper methods of dilatation on the same principle that strictures elsewhere are treated. It is true that the mucous membrane in this case is confined in a bony canal, which does not admit of dilatation, still the principle is applicable, for pressure on the thickened mucous membrane by the sound, causes the removal by the absorbents of the lymph deposited in the mucous tissue.

Mr. Travers' remarks on this subject are very judicious. "It can hardly be required," he observes, "that I should occupy the time of the reader in showing that the practice of restoring a passage partially closed, or even establishing an artificial passage, as nearly as possible in the same direction, when the natural channel is obliterated, commands a decided superiority over the practice of making an artificial opening. This applies to the treatment of the urethra, as well as of the ductus nasalis, and it is only in case of abscess, in which the distended and inflamed integument threatens to give way by ulceration, that in either case it becomes necessary to deviate from it.

"A set of silver probes, of about five inches long, varying in size, flattened at one end, and slightly bulbous* at the point, are the instruments I use for the purpose of restoring the passage. The probe is introduced with perfect facility by one who is familiarly acquainted with the anatomy of the part from either of the puncta lachrymalia into the corresponding nostril, when no obstruction is offered to its passage. If the punctum be constricted, it is readily entered and dilated by a common pin; and upon withdrawing it, by one of the smaller probes; the direction and relative situation of the lachrymal ducts, the sac, and the nasal canal, point out the proper course of the instrument. It is confirmed by its advance without the employment of force, and the sensation conveyed by the free and unencumbered motion of its point: until the point is fairly within the sac, it is necessary to keep the eyelid gently stretched and slightly everted; the upper lid being drawn a little upward toward the zygoma. The point carried home to the sac and touching lightly its nasal side, the lids may be left at liberty, while a half circular motion is performed by the instrument; the surgeon neither suffering the point to recede, nor, on the other hand, allowing it to become entangled in the membrane.

"The probe now rests in a perpendicular direction upon the eyebrow towards its inner angle, and in this direction it is to be gently depressed until it strikes upon the floor of the nostril, where its presence is readily ascertained by a common probe, passed beneath the inferior turbinated bone. The probe of smallest dimensions is of sufficient firmness to preserve its figure in its passage through the healthy duct, but it is too flexible to oppose any considerable obstruction, without danger of a change of figure: for the stricture of the lachrymal ducts it is of sufficient strength.

"Very many cases of recent origin, and in which the stricture has no great degree of firmness, are completely cured by three or four introductions of the probe into the nostril, at intervals of one or two days.

[* We prefer a probe well rounded at the point without a bulb.]

"I have seldom met with a stricture so firm as not to yield to the full-sized probe. I am fully aware of the objection that immediately presents itself, viz., that a passage so obtained is not permanent; by several repetitions of the operation it is often rendered so; but if the resistance is not altogether removed, after a trial of the experiment for some days in succession, I introduce a style having a small flat head, a little sloped, through the punctum lachrymale into the nose, and leave it for a period of twenty-four hours in the duct. If worn longer, as for two days, it ulcerates the orifice; but I have never seen it injure the punctum in the smallest degree, when worn for the full period first named. A day or two should be suffered to elapse before the style is again introduced, and it should then be passed through the other lachrymal duct. The injection of tepid water should be made on the intervening days with ANEL's syringe. The plan requires perseverance, as may be said of all plans by which so difficult an object is sought to be effected. In many cases the resistance, in the first instance opposed, is inconsiderable, yet it is sufficient to maintain the disease. The probe passes daily with increasing facility, and after a very few repetitions, with as much ease as through the healthy canal; yet the stillicidium, and even the mucous discharge do not immediately subside, because, although the obstruction is removed by which these symptoms were originally set up, the parts have not yet recovered the loss of tone which the state of habitual obstruction and inaction has induced; and here the use of the probe is unavailing, if not injurious, as in all cases in which the full-sized probe passes without impediment. It is important that operators should consider this, and not lose sight of the vital function of the parts, in treating the morbid alterations of structure which have interrupted and deranged them. For this mitigated, but not recovered state, time alone, with attention to prevent distension by occasional gentle pressure of the sac if accompanied with mucous discharge, is often sufficient; but the injection of a solution of alum, or even of cold spring water, and the use of astringent washes, will assist. Sniffing a stimulant vapor, as of vinegar, or diluted nitric acid, into the nostril, I have also found useful. It is of course unnecessary to pass a probe, when the fluid injected by the punctum drips in a stream through the nostril or into the throat, as the head of the patient is inclined forwards or backwards; but this test of the freedom of the passage should be had, before the use of the probe is laid aside." (*A Synopsis of the Diseases of the Eye and their Treatment*, 3d ed., pp. 379—383.)

We have practiced this method of treatment for the last fifteen years, and with the most gratifying results. The introduction of the probe requires, it is true, a perfect knowledge of the anatomy of the parts, much practice and tact; but all this may be acquired.

Mr. MORGAN recommends the strictured duct to be dilated by a curved probe, (fig. 143,) introduced by the nose *upward* through the duct, an operation which, he remarks, "although it may require some little prac-

Fig. 143.

tice to perform it with facility is, so far as my experience has gone, most satisfactory in its result." No force must be used in introducing the instrument, the point of which having been carefully fixed in the lower opening of the duct, after being carried under the inferior turbinated bone, is to be gently pushed upwards into the sac through the stricture by depressing the handle of the probe or sound, keeping the convex part next to the handle upwards, then having established a free passage through one canal from below, I generally inject tepid waters from day to day, by means of a small catheter [similar in form to the sound] introduced in the same manner as the sound, and attached to an ANEL's syringe. By following this plan, suppuration may sometimes be prevented, but at all events a fistulous opening in the face is prevented, if the disease is confined to the membrane, (although an abscess may have formed in the sac,) in consequence of the prevention of any accumulation there by frequent injections." (*Lectures on the Diseases of the Eye*, pp. 219, 220.)

We have tried this method of treatment and have found it more unpleasant to the patients than that advised by Mr. TRAVERS, and not, so far as our experience has gone, more effectual or speedy in accomplishing a cure.

Within a few years Dr. PAUL BERNARD has proposed a new method of curing lachrymal fistulæ and chronic lachrymations, which consists in the ablation of the lachrymal gland, and he relates one case in which he resorted to it with success. The patient was a man 30 years of age, who had had lachrymation of the left eye for ten years, during which period he underwent various methods of treatment without receiving any relief. The eye was so constantly suffused with tears as to render vision with it indistinct. After trying various means without success, Dr. B. excised a portion of the lachrymal gland. This having afforded some relief, though it did not effect a cure, two months afterwards Dr. B. extirpated the remainder of the gland. The result, he says, was perfectly satisfactory. Dr. B. says, that though every vestige of the left lachrymal gland was removed, the left eye was more moist than the right, and, what is still more extraordinary, that the left nostril, which had been dry for ten years, has become at times moist.

It will require much stronger evidence of the advantages of this operation, than has been adduced by Dr. B., to lead us to resort to so severe a procedure in preference to the already recognized means of treating lachrymation, and which we have reason to regard as much more frequently successful than is represented by him.

Congenital absence of the nasal duct.—M. BERARD has recorded a case in which the nasal duct was congenitally absent, and in which he made an artificial one. The subject of this case, a man 21 years of age, was admitted into hospital Necker on account of a congenital fistula lachrymalis. This fistula discharged a limpid transparent fluid, and caused continual epiphora. On pressing on the angle of the eye in the morning, a muco-purulent liquid flowed from the fistulous orifice and from the puncta. The nostril of the same side was habitually dry; stimulating powders, such as snuff, becoming dry without exciting the secretion of the pituitary membrane. A stylet introduced into the fistulous orifice in the direction of the nasal duct would not pass, nor was it possible to penetrate its nasal orifice. No doubt could exist, therefore, of its congenital absence, and M. BERARD made an artificial nasal duct by piercing the os unguis after the manner of WOOLHOUSE.

The inferior border of the internal portion of the tendon of the orbicu-

laris being laid bare by incision, M. Berard directed a trocar downwards, backwards, and inwards, perforating the internal wall of the orbit. The trocar was immediately replaced by a silver canula about half an inch long, enlarged at its two extremities, and on closing the mouth and nostrils of the patient, the air passed through the canula, showing that it was well placed. Three days after the operation the small wound had cicatrized; no bad symptoms followed. In two months, the patient having neglected the directions of the surgeon, returned with epiphora, when M. Berard changed the canula, and in two months the epiphora had completely disappeared, and the patient was quite well in February last.—*Bull. Gén. de Thérapeut.*, July, 1841.]

INDEX

TO THE

ANATOMY AND PHYSIOLOGY OF THE EYE AND ITS APPENDAGES.

Annulus albidus, 59
ciliaris, 60
pupillaris, 60
gangliformis, 61
Anterior chamber, membrane of, 54, 74
Aqua Morgagni, 72
Aqueous humor, 73
anterior chamber of, 74
posterior chamber of, ib.
membrane of, 54, 74
Arachnoidea oculi, 66
Arteries, anterior ciliary, 58, 61
long ciliary or iridal, 61, 68
of conjunctiva and cornea, 54, 104
short or posterior ciliary, 58
Artery, central, of retina, 69
Axis, visual, 87

Canal of *Petit*, 71
Fontana, 52
Capsule, crystalline, 71, 72, 73
Caruncula lachrymalis, 106
Catoptric phenomena, 90
Choroid coat, 49, 55
vessels of, 58
Cilia, 101
Chambers of the eye, 50
Chiasma of optic nerves, 89, 95
Ciliary arteries, anterior, 58, 61
long, 61, 68
short or posterior, 58
body, 58, 59
ligament, 70
nerves, 61
processes, 56
Circulus, venosus iridis, 52, 61
Conjunctiva, 102
palpebralis, 103
scleroticæ, 103
semilunar fold of, 106
corneæ, 103
blood-vessels of, 54
lymphatic vessels of, 55
Cornea, nerves of, ib.
49, 52
vessels of, 54
lymphatic vessels of, 55
nerves of, 55
Corpus ciliare, 58
pars fimbriata of, 59
pars non fimbriata of, ib.
Crystalline lens, 71
capsule, 73, 74
how connected with other parts, 63
vessels of, 73

Eyeball, as an optical instrument, parts subsidiary to, 74
a catoptric instrument, 90
humors of, 50, 70, 73
pathology of, 106
anatomy of, 49
appendages of, 91
muscles of, 91
proper fibrous capsule of, 94
shape of, 49
dimensions of, ib.
tunics and humors, 49, 50
connections of coats of, 69
physiology of, 74
anatomy of, 49
fascia, 94
component tissues of, 100
cellular substance of, 101
ciliary margins of, 101
appendages, anatomy of, 91
muscles, 97
Eyebrow, 96
Eyelids, 97
component tissues of, 100

Fascia of eyeball, 94
Foramen retinæ centrale, 68
Fossa hyaloidea, 71

Hyaloid membrane, 70

Humors of the eye, 50

Inverted image on retina, 77, 78, 88
Iris, 49, 59
blood-vessels of, 61
color of, 62
nerves of, 61
circular venous sinus of, 52, 61
its movements, 79, 80, 81, 82, 83, 84, 85, 86
causes of, 80
muscularity of, 63
active and passive state of, 81

Jacob, membrane of, 68

Light, 74
reflection and refraction of, 75
action of transparent media of the eye on, 76, 77
Lachrymal organs, 105
canals, 105
sac, 105
Lamina cribrosa, 52
Lens, crystalline, 71
Lenses of the eye, ib., 78
Ligament, ciliary, 70
Light, nature of, 74
Limbus luteus foraminis centralis, 68

Macula lutea, 68
Membrana fusca, 66
Membrane pupillary, 65
of anterior chamber of aqueous humor, 54, 74
Descemet, ib.
Jacob, 68
chamber of aqueous humor, 65
hyaloid, 70
Muscles of the eye, 91
eyelids, 97

Nasal duct, 105
Nerve, optic, 67, 95
Nerves, ciliary, 61
of the appendages of the eye, 95

Ophthalmic surgery, history of, xxiii

Optic nerve, 67, 95
axis, 87
Orbit, nerves of, 95
Ora serrata, 58

Palpebræ, anatomy of, 97
Papilla conica, 67
Petit, canal of, 71
Physiology of the eyeball, 74
Pigmentum nigrum, 56, 57
uses of, 57, 86
Puncta lachrymalia, 105
Pupil, 49
size of, 79
Pupillary membrane, 65

Retina, 49, 67
central artery of, 69
structure of, 68
transparent point of, 68
fold of, 68
yellow spot of, 68
Retinal picture, 87
inverted position of, 88

Sclerotica, 49, 50
Sebaceous glands, 100
Sight, importance of, xxiii
Single vision with two eyes, 88
Sinus circularis iridis, 52, 61
Soemmering, yellow spot of, 68

Tarsi, 100
Tunica *Ruyschiana*, 57
Tunics of eyeball, 49, 50
Tunica vaginalis oculi, 94
Tensor tarsi, 99

Uvea, 60

Vasa vorticosa, 58
Visual axis, 87
Vitreous body, 70
humor, 70
vessels of, 73

Zinii, zonula, 71
Zonula ciliaris, vel *Zinii*, 71

INDEX.

TO THE

DISEASES OF THE EYE.

Abscess of anterior chamber, 338, 374
cellular tissue of lids, 123
cornea, 168, 337
iris, 386
lachrymal sac, 829
orbit, 753, 757
Absorption, cure of cataract by, 658
of depressed lens, 656, 661
orbit from pressure, 764
Acetate of lead precipitated on ulcerated conjunctiva, 347
Acute ophthalmia, treatment of, 203
Adams, Sir W.'s operation for artificial pupil, 438, 457
Adenitis palpebrarum contagiosa, 241
Ægilops, 829
Albugo, 283, 349
Alopecia, 132
Alum in ophthalmic inflammation, 218, 265
Amaurosis, 490
apoplectic, 496, 505
causes of, 491, 513, 514, 515
congenital, 513
classifications of, 491
definition of, 490
diagnosis of, 519
from affection of nervus trigeminus, 561
aneurism of internal carotid, 497
atrophy of optic nerve, 502
belladonna, 517
blows on eye, 187
cerebral congestion, 493, 494
compression or concussion of brain, 493
congestion or inflammation of nervous optic apparatus, 494, 505, 514, 523
concussion of retina, 176, 185, 186, 188
spinal cord, 555
or other injury of the head, 493
Amaurosis from carious tooth, 561
general account of, 490
hereditary, 514
hydrocephalic, 496
from debility, 523, 555
depressed lens, 505
diarrhœa, 555
disordered digestive organs, 515, 554, 555
excessive exertion of the organ, 514, 523, 555
fractured cranium with depression, 501
fright, 555
fungus hæmatodes, 504
gout, 516
hæmorrhagy, 555
hydrocephalus, 496
hysteria, 560
inflammation of choroid, 460
eye, 553
orbital cellular membrane, 753
retina, 457, 461, 505
injuries of branches of fifth nerve, 117, 561
intense light, 462
irritation of branches of fifth nerve, 117, 561
lead, 517
lightning, 462
loss of fluids, 555
masturbation, 555, 557
melanosis, 504
mercury, 495, 555
miscarriage, 559
morbid changes affecting fifth nerve, 501
in optic nerves, 501
formations in brain, 497
narcotic poisons, 517
organic lesions of brain, 497

Amaurosis from onanism, 555, 557
ophthalmitis, 504
over exercise of sight, 514, 523, 555
plethora, 524
poisons, 517
pregnancy, 559
ptyalism, 495, 555
retinitis, 457, 461, 505
sanguineous extravasation in head, 496, 505
spermatorrhœa, 555
suckling, 557
suppression of accustomed discharges, 515
of menses, 515
perspiration, 515
purulent discharge, 515
sympathy, 553
syphilis, 516
tobacco, 555
tumors in orbit, 502
cerebellum, 497
venery, 555
worms, 554
wounds of eye, 186
wounds of eyebrow, 116
illustration of species of, 491
lactantium, 557
origin and progress, 510
prognosis in, 519
rheumatic, 516
seats of, 491
stages and degrees of, 507
symptomatic and sympathetic, 553
symptoms of, 507, 513
traumatica, 176, 185, 505
treatment of, 521
with debility, 555
iritis, after typhus, 555
Amaurotic cat's eye, 564
Amblyopia, 490, 508
Ammon's operation for ectropium and lagophthalmos, 148
Anchyloblepharon, 169
Anchylops, 829
Anæsthesia of retina, 560
Anel's probes, 826
syringe, injections with, 833
Aneurism by anastomosis in orbit, 773
of eyelids, 162
Anterior chamber, abscess of, 338, 374
dropsy of, 382
effusion of blood in, 178, 186, 378
extraneous substances in, 159, 169
filaria in, 746
foreign bodies in, 169
spontaneous passage of lens into, 488, 655
operation for cataract, 662
Antimony in ophthalmic inflammation, 209
Apoplexy, amaurosis from, 496, 505
of eye, 378
Aphthous inflammation of conjunctiva, 298
Aqueous chambers, diseases of, 365
dropsy of, 382
enlargement of, 382
evacuation of, 376
foreign bodies in, 169
membrane, inflammation of, 369
Aquo-capsulitis, 369
symptoms, 370
treatment, 371
diagnosis, 372
Aridura bulbi, 687
Arcus senilis, 348
Arthritic inflammation of internal tunics, 474, 674
iritis, 410
Artificial eye, adaptation of, 362
dilatation of pupil, 366
pupil, 427
by distortion, 455
detachment and strangulation, 449
excision, 443
incision, 436
separation, 453
diagnosis, 420
general rules regarding, 434
position of, 433
prognosis, 431
states of eye requiring, 435
in sclerotica, 457
Asthenopia, 538, 540
Astringents in conjunctivitis, 226
gonorrhœal ophthalmia, 288
ophthalmic inflammation, 217
purulent ophthalmia, 264, 266
Astringents, in chronic ophthalmia, 217
Atonia palpebrarum, 141
Atoniatonblepharon, ib.
Atresia iridis, 393
Atrophy of eye, 189, 393, 687
optic nerve, 502

Bates' camphorated water, 236
Beer's cataract knife, 637
Belladonna in iritis, 402
amaurosis from, 517
uses of, 366, 400
its action on the pupil, 367
Blear eyes, 125, 129
Bleeding in amaurosis, 521.
ophthalmic inflammation, 205, 207
iritis, 397
purulent ophthalmia, 261
rheumatic ophthalmia, 330
Blennorrhœa of excreting lachrymal organs, 831

Blepharo-blennorrhœa, 241
conjunctivitis catarrhalis, 223
Blepharo-ptosis, 141
Blepharoplastic operation for lagophthalmos and ectropium, 147
Blepharophthalmitis glandulosa idiopathica, 125
Blepharo-ptosis, 141
Blepharospasmus, 143
Blood effused into eye, 178, 186, 378
in cornea, 356
Blows on eye, 176
Brain, morbid formations in, producing amaurosis, 497
Brainard's operation for ectropium, 149
Blepharo-blennorrhœa, 241
Blepharotis glandularis contagiosa, 241
Blepharophthalmitis glandulosa, 229
Blepharophthalmia, 279
Blepharophthalmia ulcerosa, 128
Buphthalmus, 686
Burns of conjunctiva, 190
cornea, 190
eyelids, 116
Bursting of eye, from blows, 176, 177
cornea, from blows, 248

Calculus, lachrymal, 169, 840
Meibomian, 131
Calculous concretions in eye, 744
Caligo tenebrarum, 573
Callosity of eyelids, 132
Cancer of eyeball, 693
lower eyelid, 135
soft, of eyeball, 697
Capsule, aqueous, inflammation of, 369
crystalline, inflamed, 486
injuries of, 180
Carbuncle of eyelids, 124
Carcinoma of the eye, 693
Carcinomatous exophthalmia, 695
Carmichael, turpentine in iritis, 405
Caruncula lachrymalis, inflammation of, 827
enlargement, 827
polypus of, 827
spontaneous hemorrhage from, 827
scirrhus of, 697
warts of, 827
Cartilaginous formations in conjunctiva, 324
Cataracta arida siliquata, 622
arborescens, 612
casseosa, 618
centralis, 619
cum bursa ichorem continente, 623
zonula, 622
cystica, 620, 621
dimidiata, 622
dura, 617
fenestrata, 622
fluida, 618
gelatinosa, 618
gypsea, 624
Cataracta lactea, 618
lymphatica, 612
marmoracea, 622
membranacea, 620
punctata, 622
pyramidalis, 622
stellata, 622
tenax, 617
trabecularis, 622
traumatica, 181, 625
tremulans vel natatilis, 622, 623
tremula, 622
variegata, 622
Cataract, 612
absorbent, operation for, 658
anterior capsular, 620
black, 617
bursal, 623
capsular, 620, 669
capsulo-lenticular, 617, 621, 666
causes of, 625, 487
central, 619
choice of operation for, 634
classifications of, 617
color, 614, 623
complications of, 624
congenital, 666
couching of, 652
cure of, by absorption or dissolution, 658
definition of, 612
depression of, 652
diagnosis of, 614
by catoptric test, 615
displacement of, 652, 662
extraction of, 635
false, 612
firm, 617
fluid, 619
green, 614, 623
hard, 617
lenticular, 617
mature and immature, 624
milky, 618
Morgagnian, 619
operations for, 633
on infants, 668
preparation of patient for, 633
proper age for, 671
position of patient in operations for, 638, 646, 653, 659, 668
posterior capsular, 620
prognosis in, 629
questions regarding removal of, by operation, 630
as to operating on one or both eyes, 635
radiated, 618
reclination of, 653
secondary, 669, 672
season for operating, 635
siliquose, 622
soft, 618
species of, 617
suddenly formed, 613

Cataract, trabecular, 622
traumatic, 181, 625
treatment of, without operation, 629
varieties dependent upon age, 625
various species of, 617
Cataracts, spurious, 612
true, 612
Catarrhal inflammation of eyelids, 125
ophthalmia, 222
causes, 222
diagnosis, 225
prognosis, 225
symptoms, 223
termination, 225
treatment, 225
Catarrho-rheumatic ophthalmia, 333
Cat's eye, 564
Cellular membrane of orbit, induration of, 763
inflammation of, 753
Ceratocele, 283, 348
Cerebral congestion causing amaurosis, 493, 494, 524
Chalazion, 164
Chemosis, 243, 280, 283, 290
Chemical agents, injuries of eye by, 189
Cheselden's operation for artificial pupil, 436
Children, purulent ophthalmia in, 239
Choroid affections of, 458
ossified, 743
wounds of, 179
Choroiditis, 458
Chronic ophthalmia, treatment of, 214
Chrupsia, 609
Cicatrices, eversion of lids from, 144
of cornea, 355
Ciliæ, excision of, 154
extraction of, 158
loss of, 132
Ciliary body, wounds of, 179
fungous excrescence from, 423, 690
yellow prominences from, 689
Cirsophthalmia, 475
Clavus, 421
Colchicum in rheumatic ophthalmia, 332
Collapse of globe from suppuration, 688
Collyria in chronic ophthalmiæ, 218
Concave glasses, 596
Coloboma, 419
Colored vision, 609
Colors, insensibility to, 583
Concussion of brain, a cause of amaurosis, 493
of retina, 185
Congenital cataract, 666
operation for, 668
operation on opaque capsule, 669
proper age for the operation, 671
Congenital opaeity of cornea, 356
Conical cornea, 362
Conjunctiva arida, 320
cartilaginous formations in, 324
copper-colored syphilitic eruption of, 322
cuticular, 320
cysticercus under, 750
diseases of, 222
discoloration of by nitrate of silver, 322
ecchymosis of, 167
excrescences of, 322
foreign substances adhering to, 191, 194
in folds of, 194
fungus of, 323
granular, 268, 271
inflammation of, 222
injuries of, 189
melanosis of, 737
polypus of, 322
tumors of, 322, 324, 327
cartilaginous, 324
encysted, 327
with hairs, 324
ulcers of, 315
vascular excrescences, 323
warts of, 322
wounds of, 167
Conjunctivitis catarrhalis, 222
aphthous, 298
contagiosa, 241
Egyptiaca, 241
eysipelatosa, 298
gonorrhoica, 229, 279, 294, 295
leucorrhoica, 229
morbillosa, 314
phlyctenulosa, 299
puro-mucous, 222
purulent of infants, 229
pustulosa, 298
scarlatinosa, 314
scrofulosa, 299
variolosa, 310
Consumptio purulenta oculi, 688
corneæ, 688
Contagious ophthalmia, 241
nature of purulent ophthalmia, 250
Contusion of eyebrow and eyelids, 114
Copper-colored syphilitic eruption of conjunctiva, 322
Corectomia, 443
Coredialysis, 447
Coremorphosis, 427
Coretonectomia, 443
Cornea, abscess of, 168
bursting of, 218
cicatrices of, 355
congenital opacity of, 356
conical, 362
effusion of blood between layers of, 356

Cornea, fistula of, 348
foreign substances adhering to, 192
imbedded in, 192
globular, 383
gangrene of, 336
hernia of, 283, 348
hypertrophy of, 363
injuries of, 190
inflammation of, 336
with vesication, 345
metallic particles sticking to, 192
non-malignant tumors of, 690
opacity of, 231, 249, 348, 349
congenital, 356
ossification of, 743
paracentesis of, 376
partial inflammation of, 342
peculiar affection of in nurses, 345
penetrating wounds of, 174
punctured wounds of, ib.
rupture of, 248
sloughing of, 231, 248, 281, 336
strumous inflammation of, 343
suppuration, 158, 168, 248, 282, 314, 336
specks or opacities of, 231, 249, 348, 349
ulceration of, 232, 249, 281, 283, 346
vascularity of, 268, 308, 336, 345
wounds of, 168
Corneitis, acute, 337
scrofulous, 343
Coretodialysis, 453
Coretotomia, 436
Corotomia, 436
Couching, 652
after treatment, 654
reascent of crystalline after, 655
Counter-irritation in amaurosis, 522
acute ophthalmia, 210
chronic ophthalmia, 216
Crampton's operation for entropium, 153
Crystalline capsule ossified, 487
absorption of depressed, 656
dislocation, 182, 184, 488
lens and capsule, injuries of, 180
reascent of depressed, 656
whether removed by solution or absorption, 661
Crystallino-capsulitis, 486
Cuticular conjunctiva, 320
Cyanuret of potassium for cure of discoloration of conjunctiva by nitrate of silver, 322
Cysticercus, in anterior chamber, 748
under conjunctiva, 750
Cysts in sclerotica, 335

Dacryocystitis acuta, 829
treatment, 830
Dacryocystitis chronica, 831
Dacryops, 769
Datura stramonium, its effects on iris, 367
Daviel's scissors, 642
spoon, 636
Day-blindness, 376
Debility, amaurosis with, 523, 555
Depression of cataract, 652
through cornea, 654
sclerotica, 652
Dieffenbach's operation for ectropium, 146
Dichromatism of lens in glaucoma, 480
Digestive organs, amaurosis from disordered, 515, 554, 555
Diplopia, 509, 790
Dislocation of lens, 182, 184, 488
Displacement of cataract, 652
Dissolution of vitreous humor, 485
Distichiasis, 158
Distoma in crystalline, 747
Division of cataract, 658
through cornea, 662
sclerotica, 658
Dropsy of aqueous chambers, 382
eye, 686
vitreous humor, 686
sub-choroid, 687
sub-sclerotic, 687
Dry conjunctiva, 320
Dryness of eye, 320
Duct, nasal, congenital absence of, 843
obliteration of, 833
obstruction of, 829, 831
Duffin's operation for strabismus, 806
Dysopia tenebrarum, 573

Ecchymosis of eyelids, 122
under conjunctiva, 167
Ectropium, 143
operation of *Jaeger*, 145, 146
Graefe, 145
Dieffenbach, 146
Fricke, 147
Ammon, 146, 148
Horner, 148
Brainard, 149
and lagophthalmos, 146
operations for, 146
Effusion of blood into eye, 178, 186, 378
Egyptian ophthalmia, 241
Electricity in amaurosis, 533
Emetics in amaurosis, 531
Empyesis oculi, 374
Emphysema of eyelids, 125
Encanthis benigna, 827
maligna, 827
Encysted tumors in orbit, 768
eyelids and eyebrows, 162
subconjunctival, 327
Enlargement of lachrymal gland, 820
Entozoa in eye, 745

Entropium, 150, 241
Epicanthus, 161
Epiphora, 825
Eruptions, syphilitic, affecting eyelids, 133
Erysipelas of eyelids, 124
Erysipelatous ophthalmia, 298
Esquimaux spectacles, 197
Evacuation of aqueous humor, 376
Eversion of eyelids, 143
Examination of eye, 231
Excision, artificial pupil by, 443
of eyelids, 138
Excoriation, eversion of eyelids from, 144
Excrescence of iris, fungous, 423, 690
Exophthalmia, 688, 694, 695, 752, 760
Extirpation of eyeball, 696, 700, 709, 723, 740
eyelids, 138
lachrymal gland, 821, 824
Extraction of cataract, 635
by exterior and inferior section of cornea, 645
by inferior section of cornea, 646
by superior section of cornea, 640, 645
cases suitable for, 651
unsuitable for, 651
instruments for, 636
treatment after operation, 647
without an assistant, 646
Eye, adaptation of artificial, 362
apoplexy of, 378
atrophy of, 687
blows on, 176
bursting of, 176, 177, 248
calculous concretions in, 742
cancer of, 693
dropsy of, 686
effusion of pus in, from spontaneous internal-inflammation, 707
entozoa in, 745
extirpation of, 696, 700, 709, 723, 740
fungous growths from, 689
fungus hæmatodes of, 697
gunshot wounds of, 171
inflammatory diseases of, 220
injuries of, 166, 180
malignant affections of, 689
melanosis of, 720
modes of examining, 231
non-malignant diseases of, 689
oscillation of, 671, 790
penetrating wounds of, 167, 171
sanguineous effusion into, 178, 186, 378
scirrhus of, 693
spongoid or medullary tumor of, 697
wounds of, 166, 167
Eyebrow, injuries of, 114
Eyebrow, injuries of, amaurosis from, 116
tumors in, 162
wounds of, 114
Eyelashes, false, 158
inversion of, 157
loss of, 132
Eyelid, upper, falling down of, 141
palsy of, 141
Eyelids, abscess in, 123
affections of, 114
aneurism by anastomosis of, 162
burns and scalds of, 116
callosity of, 132
cancer of lower, 135
carbuncle of, 124
catarrhal inflammation of, 125
contusion and ecchymosis of, 122
ecchymosis of, 122
emphysema of, 125
encysted tumors in, 162
erysipelatous inflammation of, 124
eversion of, 143
extirpation of, 138
granular, treatment of, 268
half encysted tumors in, 163
horny excrescences on, 165
inflammation of edges of, 125
with ulceration, 128
of cellular tissue of, 123
injuries of, 114
inversion of, 150
malignant pustule of, 116
milium of, 165
morbid connections, 160
nævus maternus of, 162
œdema of, 125
palsy of, 141, 143
phlegmonous inflammation of, 123
phlyctenula of, 165
poisoned wounds of, 116
porrigo larvalis affecting, 129
punctured wounds of, 115
puriform flux of, 832
scalds of, 116
schirrhus of, 135
scrofulous inflammation of, 128
secondary inflammation of, 131
spasm of, 143
syphilitic diseases of, 133
ulceration of, 133
eruptions affecting, 133
tarsal tumors, 164
thickening and induration of margins of, 132
tumors in, 162
ulceration of, 133
verrucæ, 165
warts on, 165
wounds of, 114

False cataracts, 612
Far-sightedness, 600

Fever, inflammation of the eye, consequent on, 466
Fifth nerve, injuries of branches of, 117
irritation of, producing amaurosis, ib.
morbid changes of, producing amaurosis, 561
Filaria in anterior chamber of eye, 746
crystalline, 747
medinensis under conjunctiva, 747
Fistula of cornea, 348
lachrymal sac, 830
lachrymalis, 830
Foreign bodies in anterior chamber, 169
substances adhering to conjunctiva, 191, 194
imbedded in cornea, 192
in lachrymal puncta, 819
passing between lids, 189
Fractures of the orbit, 117, 750
Fricke's operation for lagophthalmos and ectropium, 147
Fungoid growths from anterior part of eye, 689
Fungus hæmatodes of brain, producing amaurosis, 504
diagnosis of, 705
eyeball, 697
seat and nature, 699
treatment, 709

Gerdy's operation for entropium, 155
Gerontoxon, 348
Gibson's operation for artificial pupil, 443
Gland, lachrymal, enlargement or schirrhus of, 820
extirpation of, 821, 824
inflammation and suppuration of, 819
Glasses for long-sightedness, 601
short-sightedness, 596
periscopic, 597
Glaucoma, 476
causes of, 477
catoptrical signs of, 480, 483
dichromatism of lens in, 480
dissections of eyes in state of, 478
its diagnosis from cataract, 479, 480
seat of disease, 477
stages, 482
symptoms, 476
to be distinguished from amaurosis, 519
treatment of, 479
with cataract, 477, 482
Gondret's pommade ammoniacale in ophthalmic inflammation, 210
Gonorrhœal ophthalmia, 279
causes, 285
diagnosis, 283
Gonorrhœal ophthalmia, effects, 281
mild, 294
prognosis, 284
symptoms, 279
treatment, 288
by incision of the sclerotic conjunctiva, 290
conjunctivitis, 291
iritis, 295
inflammation of external tunics and iris, 295
Grando, 164
Granular conjunctiva, 268, 271
Gun-powder, injuries of eyeball from, 174
Gun-shot wounds of eye, 171
Guthrie's nitrate of silver ointment, 218, 227
operation for entropium, 153
strabismus, 803
Gutta serena, 490

Hæmophthalmus, 378
from suppressed menstruation, 378
Half encysted tumors of lids, 163
Half-vision, 508, 577
Hays' operation for strabismus, 808
Helos, 421
Hemeralopia, 573
congenital and hereditary, 575
Hemiopia, 508, 577
Hernia of iris, 421
cornea, 283, 348
lachrymal sac, 833
Hordeolum, 131
induratum, 164
Horner's operation for ectropium, 149
Horny excrescences of eyelids, 165
Hunter's treatment of trichiasis, 159
Hyaloid membrane, ossified, 744
Hydrocephalus, amaurosis from, 496
Hydrophthalmia, 686
Hydrops of lachrymal sac, 833
Hygroma, 769
Hyosciamine, its action on iris, 368
Hyperkeratosis, 363
Hypertrophy of cornea, 363
Hypopyon, 338, 374
Hypolympha, 382
Hypogala, 382
Hysteric amaurosis, 560

Idiopathic ophthalmitis, 673
Incision, artificial pupil by, 436
of sclerotic conjunctiva in treatment of gonorrhœal ophthalmia, 290
Infants, purulent ophthalmia of, 229
operation for cataract on, 668
Inflammation, ophthalmic, 108
acute and chronic, 110
effects of, 112
common and specific, 112

Inflammation, ophthalmic, varieties from difference of texture, 113
other modifications, 113
causes of, 195
Inflammation of aqueous capsule, 369
caruncula lachrymalis, 827
choroid, 458
conjunctiva, 222
cornea, 337
crystalline lens and capsule, 486
eye from injuries, 166
eyelids, erysipelatous, 124
phlegmonous, 123
edges of eyelids, 125
globe of the eye, 673
iris, 384
lachrymal gland, 819
Meibomian follicles, 125
orbital cellular membrane, 753
retina, 461
Injection of lachrymal passages, 833
Injuries of branches of fifth nerve, 117
choroid and ciliary body, 174
conjunctiva, 167
cornea, 168
crystalline lens and capsule, 180
eyeball, 166
eyebrow and eyelids, 114
iris, 177
lens and capsule, 180
retina, 185
sclerotica, 176
Insensibility to certain colours, 582
Intolerance of light, see Light.
Internal inflammation of the eye, 465, 466
Inversion of eyelashes, 158
eyelids, 150
Iridauxesis, 422
Iodide of potassium in rheumatic ophthalmia, 332
iron in scrofulous ophthalmia, 306
Iridoncosis, 422
Iridectomia, 443
Iridodialysis, 447, 449
Iridectomedialysis, 453
Iris, abscess of, 385
change of color of, 385, 391, 420
detachment from ciliary ligament, 177
encysted tumor from, 424
fungous excrescences of, 423, 690
hernia of, 421
inflammation of, 383
injuries of, 177
malformation of, 418
non-malignant tumors of, 423
ossification of, 743
paralysis of, 81, 425
preternatural states of, 425
prolapsus of, 420, 169, 174, 650
Iris, spotted, 420
staphyloma of, 169, 174, 422
tremulous, 426
tumors from, 424
wounds of, 177
Iritis, 383
acute and chronic, 407
after typhus fever, 466
arthritica, 410, 474
gonorrhoica, 295
rheumatica, 410
scrofulosa, 413
sympathetica, 187, 682
syphilitica, 408
turpentine in, 405
whether caused by use of mercury, 395
Irideremia, 418
Iridectomia, 443
Iridencleisis, 454
Iridodialysis, 454
Iridotomia, 436
Irregular refraction, 606
Irritation of fifth nerve, amaurosis from, 561

Jacob's cataract needle, 664
Jaeger's cornea knife, 636
operation for lagophthalmos, 146
Janin's ointment, 128
operation for artificial pupil, 437

Keratitis, 337
Kerato-iritis, 369
Keratoplastie, 351
Keratonyxis, 662
Koretomia, 436

Lachrymal calculus, 840
Lachrymal canals, injuries of, 819
obstruction of, 826
gland, enlargement or scirrhus of, 697, 820
extirpation of, 821, 824
hydatid of, 825
inflammation and suppuration of, 829
puncta, obstruction of, 826
foreign substances in, 819
sac, abscess of, 829
blennorrhœa of, 831
capillary aperture in, 828
fistula of, 830
hernia of, 833
hydrops of, 833
inflammation of, 829
mucocele of, 833
Lactation a cause of amaurosis, 555, 557
Lagophthalmus, 143
Langenbeck's operation for artificial pupil, 449
Lapis divinus, 218
Lapideus scyphus in oculo, 744
Lapsus palpebræ superioris, 141
Lauro-cerasus, effects of on iris, 367

Lens and capsule, affections of, 486
injuries of, 180
calcareous, 487
ossified, 487
dichromatic in glaucoma, 480
dislocation of, 182, 488
entozoa in, 747
opacity of, 180, 612
ossified, 487, 743
spontaneous passage into anterior chamber, 488
whether removed from chambers of the eye by absorption or solution, 661
Lentitis, 486
Leucoma, 349
Leucorrhœal ophthalmia, 229
Light, amaurosis from intense, 462
injurious effects of, 196
intolerance of, 197, 230, 280, 301, 304, 341, 389
Lime, effects of, on the eye, 190
Lippitudo, 126
angularis, 126
pruriginosa, 128
senilis, 126
syphilitica neonatorum, 133
Local applications in the ophthalmiæ, 211
amaurosis, 530
iritis, 405
purulent ophthalmia of infants, 236
purulent ophthalmia of adults, 263
Lubbock's operation for fistula lachrymalis, 839
Lucas's operation for strabismus, 804
Luscitas, 793

Macula, 349
Madarosis, 132
Malignant diseases of the eye, 689
pustule of eyelids, 116
Marasmus senilis cornea, 349
Marmaryge, 508
Masturbation, a cause of amaurosis, 555, 557
Maunoir's operation for artificial pupil, 439, 442
scissors for artificial pupil, 440
Measles, ophthalmia from, 314
Medullary tumor in orbit, 767
of eyeball, 697
Melanosis of eyeball, 720
conjunctiva, 737
Meibomian calculus, 131
Metamorphopsia, 509, 497
Melon, 421
Menses suppressed, a cause of ophthalmia, 201
amaurosis, 515
hæmophthalmus, 378
Mercury in amaurosis, 521
corneitis, 342
Mercury in fungus hæmatodes, 713
iritis, 397, 403, 412
ophthalmic inflammation, 210
purulent ophthalmia, 264
Milium, 165
Monostoma in crystalline, 747
Monoblepsis, 790
Morbillous ophthalmia, 314
Morgagnian cataract, 619
Mucocele of lachrymal sac, 833
Muriate of soda in purulent ophthalmia, 272
Muscæ volitantes, 566
causes of, 567
treatment of, 572
Muscles of orbit, 789
injuries of, 789
paralysis of, 789
irregular motions of, 790
Mydriasis, 425
Myocephalon, 421
Myodesopsia, 509
Myopia, 593
Myosis, 425

Narcotics, their effects on the iris, 367
Nasse, peculiar affection of cornea in nurses, 345
Nævus maternus of eyelids, 162
Nasal duct, congenital absence of, 843
obstruction of, 833
Near-sightedness, 593
Nebula, 349
Night-blindness, 573
Nitrate of silver in ophthalmic inflammation, 218
catarrhal ophthalmia, 226
granular lids, 269
midriasis, 326
purulent ophthalmia, 264, 266
stains of conjunctiva by, 322
Nyctalopia, 491, 577
Nystagmus, 790

Obliteration of pupil, 393
Oculus leporinus, 143
Œdema of eyelids, 125
Oil of turpentine in iritis, 405, 417
purulent ophthalmia, 264
Onanism, amaurosis from, 555, 557
Onyx, 338
Opacities of cornea, 232, 349
congenital, 356
Opacity of crystalline capsule, 180, 612
lens, 180, 617
Opaque capsule, operation for, 660, 669
Operation for anchyloblepharon, 160
cataract, choice of an, 634
symblepharon, 160
Operations for artificial pupil, 436
cataract, 635
preparation of patients for, 633

Operations for cataract, position of patient during, 638, 646, 653, 659, 668
indications and contra-indications for, 629
choice of, 634
eversion of eyelids, 144
inversion of eyelashes, 158
eyelids, 150
Ophthalmia, exciting causes of, 195
injuries, 195
chemical irritants, 195
cold and moisture, 198
colors, 197
contagious matters, 196
excessive use of eyes, 196
atmospheric causes, 196
strong lights, 197
remote causes of, 198
morbid dispositions, 198
age, sex, climate, and situation, 199
excessive exertion of the eye, 199
suppression of habitual discharges, 201
excessive nutrition, 202
impaired nervous energy, 202
natural peculiarities of organization, 198
unhealthy constitution, 199
plethora, 199, 201
constitutional weakness, 201
determination of blood to the head, 201
aphthous, 298
arthritic, 474
bellica, 241
catarrhal, 222
catarrho-rheumatic, 233
contagious, 241
Egyptian, 241
epidemic, 239
erysipelatous, 298
following fever, 466
from absorption of pus, 677
gonorrhoica, 279, 294
interna, 465, 466
leucorrhoica, 229
morbillosa, 314
neonatorum, 229
Ophthalmia of new-born children, 229
phlyctenular, 299
porriginous, 297
psorica, 128
purulent, 228
in adults, 241
children, 239
infants, 229
purulent gravior, 241
mitior, 244
pustulosa, 298
rheumatic, 327
scarlatinous, 314
sclerotic, 327
scrofulous, 299
sympathetic, 682
syphilitic, 408
tarsi, 125
treatment, 203, 214
variolous, 310
varicous, 475
Ophthalmiæ, classification of, 220
remedies for, 203, 214
traumatic, 195
Ophthalmic inflammation, causes of, 195
treatment of, 203
surgery, history of, xxvii
Ophthalmitis phlebitica, 667
arthritica, 677
idiopathica, 673
puerperal, 678
externa idiopathica, 327
interna idiopathica, 465
sympathetic, 683
following typhus, 466
Ophthalmo-blennorrhœa, 241
conjunctivitis catarrhalis, 222
Ophthalmoptosis, 686, 712
Optic nerve, atrophy of, 502
Optic nerves, morbid changes in, producing amaurosis, 501
rupture of, 751
Orbicularis palpebrarum, palsy of, 143
spasm of, 143
Orbiculus ciliaris, inflammation of, 461
Orbit, abscess in, acute, 753
chronic, 757
caries of, 750
diseases of, 750
encysted tumors in, 768
exostosis of, 750
foreign body in, 751
fractures of, 750
gun-shot wounds of, 750
injuries of, 750
medullary tumors in, 767
muscles, affections of, 789
injuries of, 789
irregular motions of, 790
paralysis of, 789
penetrating wounds of, 695, 750
periostitis of, 777
propagation of inflammation from, to contents of cranium, 758
tumors in, 764, 765

Orbit, wound of, with rupture of optic nerve, 751
Orbital aneurisms, 773
cellular membrane, phlegmonous inflammation and abscess of, 753
induration of, 763
scirrhus of, 763
tumors in, 764
Oscillation of eyeball, 671, 790
Ossification of various parts of eye, 742
choroid, 743
cornea, 743
crystalline capsule, 743
hyaloid membrane, 744
iris, 743
lens, 487, 743
membrane of the aqueous humor, 743
retina, 743
sclerotica, 743
vitreous humor, 744
Oxyopia, 508

Pachea, 132
Pachyblepharosis, 132
Pachytes, 132
Pathology of the eye, 106
Palpebra ficosa, 129
Palpebræ, thickening and induration of margins of, 123
Palpebræ, see Eyelids.
Palsy of levator palpebræ superioris, 141
orbicularis palpebrarum, 143
upper eyelid, 141
Pannus, 345
Paracentesis corneæ, 376
Paralysis of iris, 81, 425
the orbicularis palpebrarum, 143
muscles of the eye, 789
Pediculi ciliorum, 166
Pereostitis of orbit, 777
Periscopic glasses, 597
Perspiration, suppressed, a cause of amaurosis, 515
Phlebitic ophthalmitis, 667
Phlegmonous inflammation of eyelids, 123
Phlyctenula of eyelids, 165
Phlyctenular ophthalmia, 299
Photophobia, 197, 230, 280, 301, 304, 389
in iritis, 389
infantum scrofulosa, 301
Photopsia, 508, 610
Phtheiriasis, 166
Phthisis oculi, 688
Pigmentum nigrum, deficient in glaucoma, 478
old age, 461
Pladarotes, see granular conjunctiva.
Porriginous ophthalmia, 302
Porrigo larvalis affecting eyelids, 129
Position of patient during operations for cataract, 638, 646, 653, 659, 668
Pregnancy as a cause of amaurosis, 559
Procidentia iridis, 420
Presbyopia, 600
Prolapsus of iris, 282, 420
Proptosis, 688
Prussic acid, its effects on iris, 367
Pseudo-cilia, 159
Psorophthalmia, 128, 129
Pterygium, 815
crassum, 318
fleshy, 318
pingue, 320
tenue, 317
malignant, 318
Ptosis, 141
Ptilosis, 132
Puerperal ophthalmitis, 678, 679
Puncta lachrymalia, contraction of, 827
foreign substances in, 819
Pupil, adventitious membrane in, 392
artificial, states of the eye requiring, 427
position of, 433
by detachment and strangulation, 449
distortion, 455
excision, 443
incision, 431
separation, 447
artificial dilatation of, 366
adventitious membrane in, 393
adhesions of, 392
closure of, 393
deep-seated yellow shining opacity in, 706, 708
morbid contraction of, 425
dilatation of, ib.
obliteration of, 393
state of in amaurosis, 510
Purulent ophthalmia, 228
in infants, 229
causes, 233
prognosis, 234
treatment, 235
in children, 239
adult, 241
Puro-mucous conjunctivitis, 222
Pustular ophthalmia, 298
Pustule, malignant, of eyelids, 116

Quina, use of, in scrofulous ophthalmiæ, 306

Reclination of cataract, 653
Reisinger's double hooked forceps for artificial pupil, 452
Refraction, diminished, 600
irregular, 606
Retina, affection of from excessive employment, 538
calculous transformation of, 745
concussion, 185
ossified, 743
pressure on by depressed lens, 505
wounds of, 185
Retinitis, 461

Rheumatic iritis, 410
inflammation of tunica vaginalis oculi, 782
nature of gonorrhœal ophthalmia, 287
ophthalmia, 330
Rhinoraphy, 161

Sanguineous effusion into eye, 378, 186, 378
Sanson's catoptrical examination of eye, 90
Scalds of conjunctiva, 190
cornea, 190
eyelids, 116
Scarification in ophthalmic inflammation, 208
Scarlatinous ophthalmia, 314
Scarpa's operation for artificial pupil, 447
mode of depressing cataract, 654
Schmidt's operations for artificial pupil, 447
Scirrhus of eyeball, 693
eyelids, 135
lachrymal gland, 820
orbital cellular membrane, 763
Scirrhous exophthalmia, 694
Sclerotica, cysts and tumors of, 335
artificial pupil in, 457
rupture of, 177
scrofulous tumors on, 335
wounds of, 176
Sclerotico-choroiditis, 459
Sclerotitis, 327
diagnosis, 329
rheumatica, 330
symptoms, 327
Scodelle, 744
Scotomata, 497
Scrofulous corneitis, 343
treatment, 344
iritis, 413
ophthalmia, 299
causes, 299, 305
diagnosis, 304
effects, 303
prognosis, 305
symptoms, 301
treatment, 305
tumors of sclerotica, 335
constitution, 299
Secondary cataract, 669, 672
variolous ophthalmia, 313
Semidecussation of optic nerves, 578, 581
Semilunar membrane, inflammation of, 827
Separation, artificial pupil by, 453
Short-sightedness, 593
Shot in the eye, 171
Sight impaired and altered, 507
Sloughing of cornea, 231, 248, 281, 336
Small-pox, ophthalmia from, 310
Spasm of eyelids, 143
Specks of cornea, 231, 249, 348, 349
Spectacles, concave, 596
convex, 601
Squinting, 792
Staphyloma, 249, 357
conical, 362
conicum, 362
iridis, 420, 422
morbid anatomy of, 351
operation for, 360
partial, 358
pellucidum, 362, 363
racemosum, 282, 358, 421
sclerotic, 333
spherical, 358
total, 358
Steatomatous tumors in orbit, 765
Sternutatories in amaurosis, 533
Stillicidium lachrymarum, 826
Stimuli and tonics in amaurosis, 534
astringents in chronic ophthalmia, 217
Strabismus, 792
convergens, 792
divergens, 792
double converging, 807
causes of, 794
effects of operation, 812
operations for, 801, 802, 808
cases suitable for, 801
state of affected muscles in, 798
treatment, 799
after operation, 811
Stramonium, its effects on iris, 367
Strumous ophthalmia, 299
Strychnia in amaurosis, 535
Stye, 131
Style, use of lachrymal, 835
Suckling protracted, amaurosis from, 555, 557
Suffusion, 490
Sugar-loaf cornea, 362
Suppuration of cornea, 168, 248, 282, 314, 337
Suppressed menses, amaurosis from, 515
perspiration, amaurosis from, 515
purulent discharge, amaurosis from, 515
Sycosis palpebræ, 129
Symblepharon, 169
Symptomatic and sympathetic amaurosis, 553
Sympathetic ophthalmia, 682
Synchesis, 393, 485
Synechia anterior, 233, 283
posterior, 422
Synizesis, 393
Syphilitic iritis, 408
diseases of palpebræ, 133
eruption of conjunctiva, 322
ulcerations of eyelids, 133

Tarsal ophthalmia, 125
tumors, 164
Tetanus oculi, 790
Tinea palpebrarum, 128

Trochoma, see granular conjunctiva.
Traumatic ophthalmiæ, 195
cataract, 187
Tremulous iris, 426
Trichiasis, 157
Trichosis bulbi, 326
Tube for nasal duct, 835
Tumor, encysted, in eyelids, 162
half encysted, in eyelids, 163
spongoid or medullary of eyeball, 697
Tumors, conjunctival, 324
tarsal, 164
in eyelids, 162
iris, 424
brain, producing amaurosis, 497
orbit, 764
vascular, of conjunctiva, 323
cartilaginous, 324
congenital of conjunctiva with hairs, 324
of sclerotica, 335
non-malignant of iris, 424
Tunica vaginalis oculi, inflammation of, 782
Turpentine, its use in iritis, 405, 417
in purulent ophthalmia, 264
Tylosis, 132
Tyrrell's cataract knife, 638

Ulcers of cornea, 231, 248, 343, 346
conjunctiva, 315
eyelids, 133
cancerous, 135
syphilitic, 133
Unguis, 315

Varicositas oculi, 475
Varicose ophthalmia, 475
Variolous ophthalmia, 310
secondary, 313
Varix of lachrymal sac, 833
Vascular cornea, 345
Veratria in amaurosis, 537
Verrucæ on eyelid, 165
Venery, a cause of amaurosis, 555
Vinum opii in chronic ophthalmia, 217
iritis, 405
Vesication of cornea, 345
Vision, colored, 509
defective, various states of, 507
Visus duplicatus, 509
coloratus, 509
defiguratus, 509
dimidiatus, 509
interruptus, 509
lucidus, 508
muscarum, 509
nebulosus, 509
reticulatus, 509
Vitreous body, dropsy of, 485, 686
ecchymosis of, 485
humor, dissolution of, 485
hypertrophy of, 485
change of structure, 486
fluidity of, 393
ossification of, 744
calculous transformation of, 744

Ware's nail-headed style, 835
Warts on eyelids, 165
Watery eye, 825
Weakness of sight, 538, 540
Wenzel's operation for artificial pupil, 437
Wollaston's case of hemiopia, 578
on semidecussation of optic nerves, 578, 581
Worms, amaurosis from, 554
Wounds, gun-shot, of the eye, 171
of the choroid and ciliary body, 179
cornea, 168
conjunctiva, 167
eyeball, 166, 167
eyebrows and eyelids, 114
iris, 177
lens and its capsule, 180
orbit penetrating, 750
retina, 185
retina, punctured, 185
vitreous humor, 184

Xeroma conjunctivæ, 320
Xerosis, 320
Xerophthalmia, conjunctival, 320

THE END.

WORKS
IN THE VARIOUS DEPARTMENTS
OF
MEDICINE AND SURGERY:
PUBLISHED
BY
LEA & BLANCHARD.

ANATOMY.

ANATOMICAL ATLAS, illustrative of the Structure of the Human Body; with over Six Hundred Illustrations; the most complete work of the kind ever issued,—beautifully executed, in One Volume Imperial Octavo; by H. H. Smith, M.D., under the supervision of Professor W. E. Horner.

HORNER'S Special Anatomy and Histology; 6th edition, much improved. 2 vols. 8vo., 1114 pages.

WILSON'S Human Anatomy; a new edition (the second) revised, with additions by Dr. Goddard: 207 beautiful cuts. 8vo., 608 pages.

WILSON'S Dissector, or Practical and Surgical Anatomy; with additions by Goddard—106 cuts. Royal 12mo., 444 pages.

PHYSIOLOGY.

CARPENTER'S Human Physiology; with notes and additions by Meredith Clymer, and over 100 cuts—in 8vo., 618 pages.

DUNGLISON'S Human Physiology; the fifth edition, with numerous additions and 300 cuts—in 2 vols. 8vo., 1304 pages.

HARRISON on the Nervous System; 8vo., 292 pages.

MÜLLER'S Elements of Physiology by Baly, arranged by Bell—8vo., 886 pages.

ROGET'S Outlines of Physiology—8vo., 516 pages.

PATHOLOGY.

ABERCROMBIE on the Brain. 3d edit.

——————— on the Stomach. 4th edit.

ALISON'S Outlines of Pathology. 8vo., 424 pages.

ANDRAL on the Blood in Disease. 130 pages, 8vo.

BELL on the Teeth, with plates—8vo., 350 pages.

BERZELIUS on the Kidneys and Urine. 8vo., 178 pages.

BARTLETT on the Fevers of the United States—8vo., 394 pages.

BILLINGS' Principles of Medicine—8vo., 304 pages.

BRODIE on the Urinary Organs. 8vo., 214 pages.

BRODIE on the Diseases of the Joints. 8vo., 216 pages.

CHAPMAN on Thoracic and Abdominal Viscera. 8vo., 384 pages.

CHAPMAN on Eruptive Fevers, &c. 8vo., 448 pages.

HOPE'S Treatise on the Diseases of the Heart and Great Vessels, with additions by Pennock. 8vo., 572 pages.

JONES and TODD on the Diseases of the Ear, edited by Dr. Hays; with numerous cuts. 8vo., pages—preparing.

LAWRENCE'S Treatise on the Diseases of the Eye, with additions by Hays, and numerous cuts. 8vo., 778 pages.

PROUT'S Treatise on Stomach and Renal Diseases, with coloured plates. 8vo., 466 pages.

PHILIP'S Treatise on Protracted Indigestion. 8vo., 240 pages.

RICORD'S Treatise on Venereal Diseases. 8vo., 256 pages.

WALSHE'S Diagnosis of the Diseases of the Lungs. 12mo., 310 pages.

WILSON on the Diseases of the Skin. 8vo., 370 pages.

WILLIAMS' Principles and Pathology, with additions by Clymer. 8vo., 384 pages.

WILLIAMS on the Respiratory Organs, edited by Clymer. 8vo., 508 pages.

PRACTICE OF MEDICINE.

ASHWELL on the Diseases of Females, by Goddard. 1 vol. 8vo., pages—nearly ready.

CONDIE'S Practical Treatise on the Diseases of Children. 1 vol. 8vo., 650 pages.

CHURCHILL on the Diseases of Females, including those of Pregnancy and Childbed; with additions by Huston. 8vo., 596 pages. 3d edition.

COATES' Popular Medicine. 8vo. 514 pp.

DEWEES on the Diseases of Children. 8th edition; 8vo., 548 pages.

DEWEES on the Diseases of Females. 8vo., with plates, 532 pages.

DUNGLISON'S Practice of Medicine. Second edition, in 2 volumes 8vo., 1322 pages.

TWEEDIE'S Library of Practical Medicine. Second edition, revised; in 3 vols. large 8vo., 2016 pages.

☞Any one of the five volumes of the first edition can be had separate.

WATSON on the Principles and Practice of Physic. 8vo., 920 large pages.

SURGERY.

COOPER'S (Sir Astley) Treatise on Hernia, with lithographic plates. Imperial 8vo., 428 pages.

COOPER (Sir Astley) on the Testis and Thymus Gland, with lithographic plates. Imperial 8vo., 1 vol.

COOPER (Sir Astley) on Dislocations and Fractures, with numerous cuts, and a Memoir and Portrait. 8vo., 500 pages.

DRUITT'S Modern Surgery. Second edition, with 153 cuts; 8vo., 568 pages.

FERGUSSON'S System of Practical Surgery, edited by Norris, with 246 cuts. 8vo., 630 pages.

HARRIS on the Maxillary Sinus. 8vo., 164 pages.

LAWRENCE'S Treatise on Ruptures. 8vo., 480 pages.

MAURY'S Dental Surgery, with numerous plates and cuts. 8vo., 286 pages.

ROBERTSON on the Teeth. 8vo., 230 pages.

THERAPEUTICS AND MATERIA MEDICA.

DUNGLISON'S Therapeutics and Materia Medica; a new work. 2 vols. 8vo., 1004 pages.

DUNGLISON'S Treatise on New Remedies. Fifth edition, 8vo., 616 pages.

ELLIS' Medical Formulary, by Morton. Seventh edition, 8vo., 262 pages.

PEREIRA'S Elements of Materia Medica and Therapeutics; edited by Carson, with 280 cuts. 2 vols. 8vo., 1566 pages.

OBSTETRICS.

CHURCHILL on the Theory and Practice of Midwifery, by Huston; 116 cuts. 8vo., 520 pages.

DEWEES' System of Midwifery, with plates. Tenth edition, 8vo., 660 pages.

RIGBY'S System of Midwifery, with cuts. 8vo., 492 pages.

RAMSBOTHAM on Parturition, with figures in lithography. Imperial 8vo., 458 pages.

CHEMISTRY, MEDICAL PHYSICS AND HYGIENE.

ARNOTT'S Elements of Physics, with numerous cuts. One volume 8vo., 520 pages.

DUNGLISON on Human Health; a second edition revised, with additions. 8vo., 464 pages.

GRAHAM'S Elements of Chemistry, by Bridges, with numerous cuts. 8vo., 750 pp.

MEDICAL JURISPRUDENCE AND MEDICAL EDUCATION.

CHITTY'S Medical Jurisprudence.—8vo., 510 pages.

DUNGLISON'S Medical Student; a new edition, large 12mo.

TRAILL'S Medical Jurisprudence.—8vo., 234 pages.

TAYLOR'S Medical Jurisprudence, by Griffith. 1 vol. 8vo., 540 very large pages.

DICTIONARIES AND JOURNALS.

AMERICAN JOURNAL OF THE MEDICAL SCIENCES; edited by Dr. Isaac Hays, published Quarterly at Five Dollars a Year.

CYCLOPÆDIA OF PRACTICAL MEDICINE; comprising Treatises on the nature and treatment of Diseases, including those of *Women and Children, Materia Medica, Therapeutics, Medical Jurisprudence*, &c., &c. Edited by Forbes, Tweedie, Conolly and Dunglison. 4 large Super-Royal Octavo Volumes. About 3000 pages in double columns.

DUNGLISON'S Medical Dictionary; 4th edition, containing over 40,000 words and synonymes; large 8vo., of 772 pages, double columns.

MEDICAL NEWS AND LIBRARY. Published Monthly at One Dollar a Year.

SELECT MEDICAL ESSAYS, by Drs. Dunglison, Chapman and others.—2 vols. 8vo., 1150 pages.

HORNER'S ANATOMY,

NEW EDITION—NOW READY.

SPECIAL ANATOMY AND HISTOLOGY.

BY WILLIAM E. HORNER, M. D.,

PROFESSOR OF ANATOMY IN THE UNIVERSITY OF PENNSYLVANIA, &c., &c.

Seventh edition.

With many improvements and additions. In two octavo volumes, with illustration on wood.

This standard work has been so long before the profession, and has been so extensively used, that, in announcing the new edition, it is only necessary to state, that it has undergone a most careful revision; the author has introduced many illustrations relating to Microscopical Anatomy, and has added a large amount of text on these various points of investigation that are rapidly advancing and attracting so much attention. This new edition has been arranged to refer conveniently to the illustrations in Smith and Horner's Anatomical Atlas.

"A comparison of the present edition with its antecedents, will, therefore, the Author hopes, show to the student an improved state, in many respects, in regard both to Descriptive Anatomy and to Histology; much of the latter, especially, having been remodelled and written anew since the last edition.

"The present edition has also the advantage of additional illustrations from the best authorities, through numerous figures inserted in its pages; and it is placed in a more immediate relation with the plates of Dr. H. H. Smith's Anatomical Atlas, they having been selected expressly as an elucidation of its text. This connection has been made by specific references at the foot of the page to the plates in question.

"That all has been said that belongs to the science of Anatomy, no one fully acquainted with the subject will admit; but the author trusts that no well-established fact of leading importance has been omitted; and that a sufficient expansion has been given to the subject to realize the principal object, that of furnishing an elementary Text Book for the use of students of Medicine."—*Preface to Seventh Edition, Sept.* 1846

HORNER'S DISSECTOR.

THE UNITED STATES DISSECTOR,

BEING A NEW EDITION, WITH EXTENSIVE MODIFICATIONS,

AND ALMOST REWRITTEN, OF

"HORNER'S PRACTICAL ANATOMY."

IN ONE VERY NEAT VOLUME, ROYAL 12MO.

With many Illustrations on Wood.

The numerous alterations and additions which this work has undergone, the improvements which have been made in it, and the numerous wood-cuts which have been introduced, render it almost a new work.

It is the standard work for the Students in the University of Pennsylvania.

NOW READY.—A NEW EDITION OF DUNGLISON'S PHYSIOLOGY.

HUMAN PHYSIOLOGY,

WITH THREE HUNDRED AND SEVENTY ILLUSTRATIONS.

BY ROBLEY DUNGLISON, M.D.,

PROFESSOR OF THE INSTITUTES OF MEDICINE IN THE JEFFERSON MEDICAL COLLEGE, PHILADELPHIA, ETC., ETC.

Sixth edition, greatly improved.—In two large octavo volumes, containing nearly 1350 pages.

"It is but necessary for the Author to say, that all the cares that were bestowed on the preparation of the fifth edition have been extended to the sixth, and even to a greater amount. Nothing of importance that has been recorded since its publication, has, he believes, escaped his attention. Upwards of seventy illustrations have been added; and many of the former cuts have been replaced by others. The work, he trusts, will be found entirely on a level with the existing advanced state of physiological science."

In mechanical and artistical execution, this edition is far in advance of any former one. The illustrations have been subjected to a thorough revision, many have been rejected and their places supplied with superior ones, while numerous new woodcuts have been added wherever perspicuity or novelty seemed to require them.

"Those who have been accustomed to consult the former editions of this work, know with how much care and accuracy every fact and opinion of weight, on the various subjects embraced in a treatise on Physiology, are collected and arranged, so as to present the latest and best account of the science. To such we need hardly say, that, in this respect, the present edition is not less distinguished than those which have preceded it. In the two years and a half which have elapsed since the last or fifth edition appeared, nothing of consequence that has been recorded seems to have been omitted. Upwards of seventy illustrations have been added, and many of the former cuts have been replaced by others of better execution. These mostly represent the minute structures as seen through the microscope, and are necessary for a proper comprehension of the modern discoveries in this department.—*The Medical Examiner.*

NOW READY.

THE SIXTH EDITION OF DUNGLISON'S MEDICAL DICTIONARY.

MEDICAL LEXICON.

A Dictionary of

MEDICAL SCIENCE,

CONTAINING A CONCISE ACCOUNT OF THE VARIOUS SUBJECTS AND TERMS; WITH THE FRENCH AND OTHER SYNONYMES; NOTICES OF CLIMATES AND OF CELEBRATED MINERAL WATERS; FORMULÆ FOR VARIOUS OFFICINAL AND EMPIRICAL PREPARATIONS, &c.

BY ROBLEY DUNGLISON, M. D.,

PROFESSOR OF THE INSTITUTES OF MEDICINE, ETC., IN JEFFERSON MEDICAL COLLEGE, PHILADELPHIA.

Sixth edition, revised and greatly enlarged. In one royal octavo volume of over 800 very large pages, double columns. Strongly bound in the best leather, raised bands.

"We think that 'the author's anxious wish to render the work a satisfactory and desirable—if not indispensable—Lexicon, in which the student may search without disappointment for every term that has been legitimated in the nomenclature of the science,' has been fully accomplished. Such a work is much needed by all medical students and young physicians, and will doubtless continue in extensive demand. It is a lasting monument of the industry and literary attainments of the author, who has long occupied the highest rank among the medical teachers of America."—*The New Orleans Medical and Surgical Journal.*

"The simple announcement of the fact that Dr. Dunglison's Dictionary has reached a sixth edition, is almost as high praise as could be bestowed upon it by an elaborate notice. It is one of those standard works that have been 'weighed in the balance and (not) been found wanting.' It has stood the test of experience, and the frequent calls for new editions, prove conclusively that it is held by the profession and by students in the highest estimation. The present edition is not a mere reprint of former ones; the author has for some time been laboriously engaged in revising and making such alterations and additions as are required by the rapid progress of our science, and the introduction of new terms into our vocabulary. In proof of this it is stated 'that the present edition comprises nearly two thousand five hundred subjects and terms not contained in the last. Many of these had been introduced into medical terminology in consequence of the progress of the science, and others had escaped notice in previous revisions.' We think that the earnest wish of the author has been accomplished; and that he has succeeded in rendering the work 'a satisfactory and desirable—if not indispensable—Lexicon, in which the student may search, without disappointment, for every term that has been legitimated in the nomenclature of the science.' This desideratum he has been enabled to attempt in successive editions, by reason of the work not being stereotyped; and the present edition certainly offers stronger claims to the attention of the practitioner and student, than any of its predecessors. The work is got up in the usual good taste of the publishers, and we recommend it in full confidence to all who have not yet supplied themselves with so indispensable an addition to their libraries."—*The New York Journal of Medicine.*

Now Ready,—Carpenter's New Work.

A MANUAL, OR ELEMENTS OF PHYSIOLOGY,

INCLUDING PHYSIOLOGICAL ANATOMY,

FOR THE USE OF THE MEDICAL STUDENT.

BY WILLIAM B. CARPENTER, M. D., F. R. S.,

FULLERIAN PROFESSOR OF PHYSIOLOGY IN THE ROYAL INSTITUTION OF GREAT BRITAIN, ETC.,

With one hundred and eighty illustrations. In one octavo volume of 566 pages. Elegantly printed to match his "Principles of Human Physiology."

This work, though but a very short time published, has attracted much attention from all engaged in teaching the science of medicine, and has been adopted as a text book by many schools throughout the country. The clearness and conciseness with which all the latest investigations are enunciated render it peculiarly well suited for those commencing the study of medicine. It is profusely illustrated with beautiful wood engravings, and is confidently presented as among the best elementary text books on Physiology in the language.

"The author has shown singular skill in preserving so marked a line of distinction between the present Manual and the 'Principles of Physiology' previously published by him. They are both on precisely the same subject; but the one is neither a copy, nor an abstract, nor an abridgment of the other. In one thing, however, they are exactly alike—in their general excellence, and in their perfect adaptation to their respective purposes. The reputation of Dr Carpenter as a physiologist is too well established throughout the whole medical world to admit of increase from any commendation of ours; but we should be doing injustice to our own feelings if we did not here express our admiration of his great intellectual powers, of his extensive learning, of the comprehensiveness of his views, of the quickness with which he seizes the important points and bearings of each subject, of the logical order in which he arranges his facts, and of the clearness and precision with which he explains and exposes his doctrines. Dr. Carpenter's various treatises are in fact models in their respective departments. It is their great and varied excellence which accounts for their unrivalled popularity. We can pay no higher compliment to the work before us, than to say, that it is equal in merit to the former productions of the author. This is equivalent to saying that it is, without question, the best manual or short treatise on physiology extant. Although designed for the student, and framed expressly to meet his wants, it is a work, we will venture to say, that may be consulted with advantage by most physicians and surgeons, however learned."—*The British and Foreign Medical Review.*

The merits of this work are of such a high order, and its arrangement and discussion of subjects so admirably adapted to the want of students, that we unhesitatingly commend it to their favorable notice. This work studied first, and then followed by the more elaborate treatise of Dunglison, or Muller, or others of similar character, is decidedly the best course for the student of physiology."—*The Western Lancet.*

Simon's Chemistry of Man.

ANIMAL CHEMISTRY,

WITH REFERENCE TO THE PHYSIOLOGY AND PATHOLOGY OF MAN.

BY DR. J. FRANZ SIMON.

Translated and edited by GEORGE E. DAY, M. A. & L. M., CANTAB., &c.

With plates. In one octavo volume of over seven hundred pages, sheep, or in two parts boards.

This important work is now complete and may be had in one large octavo volume, Those who obtained the first part can procure the second separate. The very low price at which this is offered, in comparison with the cost of the English edition, should secure for it a large demand.

"This excellent work, the most complete on animal chemistry that has ever appeared, has recently been issued by the publishing house of Lea and Blanchard, after the Sydenham edition of London. No physician, who desires to keep pace with the improvements in our science, or to be prepared at all points for the successful treatment of disease, can remain ignorant of physiological and pathological chemistry; and he will seek in vain for as complete and accurate work on the subject, as he will find in the elaborate and finished treatise of Dr. Simon The work is replete with facts of the highest interest, calculated to reflect a broad blaze of light on the pathology and treatment of many diseases hitherto involved in obscurity. We trust it may have a universal circulation among the profession in this country.—*The New York Journal of Medicine.*

Now Ready—A New Edition of

CONDIE ON CHILDREN.

BROUGHT UP TO 1847.

In one octavo volume of over 650 pages.

A NEW EDITION—JUST READY.

Dunglison on New Remedies.

NEW REMEDIES,

BY ROBLEY DUNGLISON, M.D., &c., &c.

Fifth edition, with extensive additions. In one neat octavo volume.

The numerous valuable therapeutical agents which have of late years been introduced into the Materia Medica, render it a difficult matter for the practitioner to keep up with the advancement of the science, especially as the descriptions of them are difficult of access, being scattered so widely through transactions of learned societies, journals, monographs, &c. &c. To obviate this difficulty, and to place within reach of the profession this important information in a compendious form, is the object of the present volume, and the number of editions through which it has passed show that its utility has not been underrated.

The author has taken particular care that this edition shall be completely brought up to the present day. The therapeutical agents added, which may be regarded as newly introduced into the Materia Medica, together with old agents brought forward with novel applications, and which may therefore be esteemed as "New Remedies," are the following:—Benzoic Acid, Chromic Acid, Gallic Acid, Nitric Acid, Phosphate of Ammonia, Binelli Water, Brocchieri Water, Atropia, Beerberia, Chloride of Carbon (Chloroform,) Digitalia, Electro-Magnetism, Ergotin, Ox-gall, Glycerin, Hæmospasy, Hæmostasis, Hagenia Abyssinica, Honey Bee, Protochloride of Mercury and Quinia, Iodoform, Carbonate of Lithia, Sulphate of Manganese, Matico, Double Iodide of Mercury and Morphia, Iodhydrate of Morphia, Iodide of Iodhydrate of Morphia, Muriate of Morphia and Codeia, Naphthalin, Piscidia Erythrina, Chloride of Lead, Nitrate of Potassa, Arseniate of Quinia, Iodide of Quinia, Iodide of Cinchonia, Iodide of Iodhydrate of Quinia, Lactate of Quinia, Pyroacetic Acid, (Naphtha, Acetone) Hyposulphate of Soda, Phosphate of Soda, Iodide of Iodhydrate of Strychnia, Double Iodide of Zinc and Strychnia, Double Iodide of Zinc and Morphia, and Valerianate of Zinc.

Hasse's Pathological Anatomy.

AN ANATOMICAL DESCRIPTION OF THE DISEASES OF THE ORGANS OF CIRCULATION AND RESPIRATION.

BY CHARLES EWALD HASSE,

Professor of Pathology and Clinical Medicine in the University of Zurich, &c.

Translated and edited by W. E. Swaine, M.D., &c.

In one octavo volume. A new work, just ready,—October, 1846.

"The advantages which Professor Hasse has possessed for the preparation of such a work as the present, appear to have been considerable, and of these he has manifestly availed himself to the utmost. As a diligent student in the hospitals of Paris and Vienna, and subsequently as clinical assistant to Professor Carus, and pathological prosector in the principal hospital at Leipsic, he possessed the means of observing and collecting materials for himself, whilst at the same time he was forming that 'pathological collection,' which, under his auspices, has grown into a most interesting and valuable museum. The present treatise, therefore, differs essentially from what is commonly called a compilation. For although he has 'not relied solely on his own investigations, but has largely availed himself of facts recorded by others,' he has been chary in making use of other men's experience. The estimation in which the book is held in Germany, is sufficiently attested by the fact that since its publication the author has had the offer of the chair of Clinical Medicine in five Universities, and holds that vacated by Professor Schöenlein, at Zurich."—*The Medico-Chirurgical Review.*

A NEW WORK.—PHILLIPS ON SCROFULA.—JUST READY.

SCROFULA,

TS NATURE, ITS PREVALENCE, ITS CAUSES, AND THE PRINCIPLES OF ITS TREATMENT.

BY BENJAMIN PHILLIPS, M.D., F. R. S., ETC.

In one neat octavo volume, with a plate.

"The work of Mr. Phillips is immensely in advance of all others that have ever been written on Scrofula.

"The author has extended his researches over a wide and most interesting field. It has been a fault with preceding writers, that they have not enjoyed a very extensive sphere of observation, or extended their inquiries so as to comprise the influence of the many causes which are supposed to be capable of producing the disease.

"He has even extended his inquiries to Russia, Austria, Prussia, Bavaria, Portugal, Holland, France, Switzerland, Belgium and America, to China and the East Indies, Egypt, Syria and Greece; in short, we have fully presented to us, a body of authentic statistics bearing upon this disease,—collected with care, and arranged and classified in a philosophical manner."—*The N. Y. Journal of Medicine.*

Ellis's Medical Formulary,

NEW AND IMPROVED EDITION.

THE MEDICAL FORMULARY;

Being a collection of Prescriptions, derived from the writings and practice of many of the most eminent physicians of America and Europe. To which is added an APPENDIX, containing the usual dietetic preparations and antidotes for poisons. The whole accompanied with a few brief pharmaceutic and medical observations.

BY BENJAMIN ELLIS, M. D.,

LATE PROFESSOR OF MATERIA MEDICA AND PHARMACY IN THE PHILADELPHIA COLLEGE OF PHARMACY.

Eighth edition, with extensive alterations and additions. By SAMUEL GEORGE MORTON, M. D. In one neat octavo volume.

This popular work has been too extensively and favorably known to the profession in the United States to require any remarks in introducing a new edition, except to state that the improvements in it will be found to be numerous and important. Great care has been taken in its passage through the press to insure the utmost accuracy, and it is confidently presented as worthy the increased confidence of physicians and apothecaries.

HOPE ON THE HEART.—New Edition, just published.

A TREATISE ON THE DISEASES

OF THE HEART AND GREAT VESSELS,

AND ON THE AFFECTIONS WHICH MAY BE MISTAKEN FOR THEM.

Comprising the author's view of the Physiology of the Heart's Action and Sounds as demonstrated by his experiments on the Motions and Sounds in 1830, and on the Sounds in 1834—5.

BY J. HOPE, M. D., F. R. S., &c. &c.

Second American from the third London edition. With Notes and a Detail of Recent Experiments.

BY C. W. PENNOCK, M. D., &c.

In one octavo volume of nearly six hundred pages, with lithographic plates.

SMALL BOOKS ON GREAT SUBJECTS.

Under the title of "Small Books on Great Subjects," there has lately appeared in London a series of works which have attracted much attention from their originality, strength and conciseness. Notwithstanding their very high price, they have commanded a large circulation in England, while that cause has limited the demand in this country. In placing them, therefore, before the American public in a neat form, and at the very low price of twenty-five cents each, the American publishers hope to meet with an extended sale. The following have appeared:—

No. 1. Philosophical Theories and Philosophical Experience; No. 2. On the Connection between Physiology and Intellectual Science; No. 3. On Man's Power over himself to Prevent or Control Insanity; No. 4. An Introduction to Practical Organic Chemistry, with reference to the works of Davy, Brande, Liebig, &c.; No. 5. A Brief View of Greek Philosophy, up to the age of Pericles; No. 6. A Brief View of Greek Philosophy, from the Age of Socrates to the Coming of Christ; No. 7. Christian Doctrine and Practice in the Second Century; No. 8. An Exposition of Vulgar and Common Errors adapted to the year of Grace MDCCCXLV; No. 9. An Introduction to Vegetable Physiology, with References to the Works of De Candolle, Lindley, &c. No. 10. On the Principles of Criminal Law. No. 11. Christian Sects in the Nineteenth century.

To be Continued.

NOW READY.—PHILOLOGY OF THE EXPLORING EXPEDITION.

The Ethnography and Philology

OF THE U. S. EXPLORING EXPEDITION,

Under the Command of Captain Wilkes, during the years 1838, 1839, 1840, 1841 and 1842.

BY HORATIO HALE, *Philologist to the Expedition.*

In one large imperial quarto volume, done up with great strength in extra cloth, price only $10.

This is the only edition of this volume, of which but few copies have been printed. Early application is therefore necessary to secure it. It is printed and arranged to match the Congress copies of the "Narrative," and is confidently presented as the most beautiful specimen of typography ever executed in this country.

This work forms the seventh volume of the Publications of the Exploring Expedition. The next volume, by Professor Dana, on Corals, with an Atlas of colored plates, will shortly be ready, to be followed by the remainder of the scientific portion.

THE GREAT SURGICAL LIBRARY

(NEARLY COMPLETED).

CHELIUS' SYSTEM OF SURGERY.

A SYSTEM OF SURGERY.

BY J. M. CHELIUS,

Doctor in Medicine and Surgery, Public Professor of General and Ophthalmic Surgery, etc. etc. in the University of Heidelberg.

TRANSLATED FROM THE GERMAN,

AND ACCOMPANIED WITH ADDITIONAL NOTES AND OBSERVATIONS,

BY JOHN F. SOUTH,

SURGEON TO ST. THOMAS' HOSPITAL.

Edited, with Reference to American Authorities,

BY GEORGE W. NORRIS, M.D.

To be complete in Three large Octavo Volumes of about Six Hundred very large pages each, or in Seventeen Numbers at Fifty Cents.

The completion of this great work has been delayed by the very numerous and important additions of the translator: it is now, however, in a state to enable the publishers to promise its conclusion by the first of March, 1847.

It is unnecessary to call the attention of the profession to this important work. The names which are associated in it, and the unanimous testimony borne by the medical press to its excellence are sufficient to prove its great value. For fullness and completeness it is unapproached by any work of the kind now before the profession, and it may, indeed, be said to be the only real System of Surgery, embracing both the Principles and Practice, that has appeared since the days of Hunter. The consideration which it has long enjoyed abroad may be estimated from the fact of its having passed through six editions in Germany, and its having been translated into no less than seven languages.

"Judging from a single number only of this work, we have no hesitation in saying that, if the remaining portions correspond at all with the first, it will be by far the most complete and scientific System of Surgery in the English language. We have, indeed, seen no work which so nearly comes up to our idea of what such a production should be, both as a practical guide and as a work of reference, as this; and the fact that it has passed through six editions in Germany, and been translated into seven languages, is sufficiently convincing proof of its value. It is methodical and concise, clear and accurate; omitting all minor details and fruitless speculations, it gives us all the information we want in he shortest and simplest form."—*New York Journal of Medicine.*

DRUITT'S SURGERY. New Edition---Now Ready.

THE

PRINCIPLES AND PRACTICE OF MODERN SURGERY.

By ROBERT DRUITT, Surgeon.

THIRD AMERICAN FROM THE THIRD LONDON EDITION.

ILLUSTRATED WITH ONE HUNDRED AND FIFTY-THREE WOOD ENGRAVINGS.

WITH NOTES AND COMMENTS

By JOSHUA B. FLINT, M.D., M.M., S.S., &c. &c.

In One very neat Octavo Volume of about Five Hundred and Fifty Pages.

In presenting this work to the American profession for the third time, but little need be said to solicit for it a continuation of the favor with which it has been received. The merits which have procured it this favor, its clearness, conciseness, and its excellent arrangement, will continue to render it the favorite text-book of the student who wishes in a moderate space a compend of the principles and practice of Surgery.

JONES ON THE EYE. Now Ready.

THE PRINCIPLES AND PRACTICE OF OPHTHALMIC MEDICINE AND SURGERY.

By T. WHARTON JONES, F.R.S., &c. &c.

WITH ONE HUNDRED AND TEN ILLUSTRATIONS.

EDITED BY ISAAC HAYS, M.D., &c.

In One very neat Volume, large royal 12mo., with Four Plates, plain or colored, and Ninety-eight well executed Woodcuts.

This volume will be found to occupy a place hitherto unfilled in this department of medical science. The aim of the author has been to produce a work which should, in a moderate compass, be sufficient to serve both as a convenient text-book for students and a book of reference for practitioners. Thus, by great attention to conciseness of expression, a strict adherence to arrangement, and the aid of numerous pictorial illustrations, he has been enabled to embody in it the principles of ophthalmic medicine, and to point out their practical application more fully than has been done in any other publication of the same size. The execution of the work will be found to correspond with its merit, the illustrations have been engraved and printed with care, and the whole is confidently presented as in every way worthy the attention of the profession.

VÖGEL'S PATHOLOGICAL ANATOMY.

THE PATHOLOGICAL ANATOMY OF THE HUMAN BODY.

By JULIUS VÖGEL, M.D., &c.

TRANSLATED FROM THE GERMAN, WITH ADDITIONS,

By GEORGE E. DAY, M.D., &c.

Illustrated by upwards of One Hundred Plain and Colored Engravings.

In One neat Octavo Volume.

The entire absence of any English work on Morbid Anatomy, embracing the recent discoveries effected by chemistry and the microscope, affords a sufficient reason for the appearance, in the present form, of "Vögel's Pathological Anatomy of the Human Body." It forms in itself a complete treatise on General Morbid Anatomy, and will shortly be followed by a second volume devoted to the consideration of pathological changes affecting special organs. This translation has been made with the approbation and assistance of the author, who has examined a considerable portion of the volume and expressed his satisfaction at the manner in which it was executed.

A PRACTICAL TREATISE

ON

INFLAMMATION, ULCERATION AND INDURATION OF THE NECK OF THE UTERUS:

WITH REMARKS ON THE VALUE OF LEUCORRHŒA AND PROLAPSUS UTERI AS SYMPTOMS OF THIS FORM OF DISEASE.

BY J. HENRY BENNET, M.D.,

In One Duodecimo Volume, cloth.

"The descriptions of disease are throughout clear and concise, the arrangement of the subject is judicious and the remarks are thoroughly practical, and calculated to improve the treatment of a frequent and troublesome class of diseases. In recommending Dr. Bennet's volume, therefore, to our readers as an excellent essay upon the subject, we only convey the impression which its perusal has left upon us."—*Dublin Medical Press.*

ROYLE'S MATERIA MEDICA.

MATERIA MEDICA AND THERAPEUTICS;

INCLUDING THE PREPARATIONS OF THE PHARMACOPŒIAS OF LONDON, EDINBURGH, DUBLIN, (AND OF THE UNITED STATES.)

WITH MANY NEW MEDICINES.

BY J. FORBES ROYLE, M.D., F. R. S.,

Late of the Medical Staff in the Bengal Army, Professor of Materia Medica and Therapeutics, King's College. London, &c. &c.

EDITED BY JOSEPH CARSON, M.D.,

Professor of Materia Medica in the Philadelphia College of Pharmacy, &c. &c.

WITH NINETY-EIGHT ILLUSTRATIONS.

In one large octavo volume of about 700 pages.

Being one of the most beautiful Medical works published in this Country.

No apology is requisite for re-issuing the book in this country. By the student attending upon lectures, as well as by practitioners, a full and large manual like this cannot but be received with favor, and notwithstanding the large and valuable works that have of late been presented to the profession, its merit will insure for it a favorable reception. The illustrations are superior to those heretofore given in works of the kind, every care having been taken both in the engraving and printing. The labors of the editor have been confined to the supervision of the work in passing it through the press, and the addition of such matter in connection with the Pharmacopœia and indigenous Materia Medica of the United States, as would render the work fitted for American students and practitioners.

WILSON'S ANATOMY. New Edition---Now Ready.

A SYSTEM OF HUMAN ANATOMY,

GENERAL AND SPECIAL.

BY ERASMUS WILSON, M.D.,

Lecturer on Anatomy, London.

THIRD AMERICAN FROM THE THIRD LONDON EDITION.

EDITED BY P. B. GODDARD, A.M., M.D.,

Professor of Anatomy in the Franklin Medical College of Philadelphia.

WITH TWO HUNDRED AND THIRTY-FIVE ILLUSTRATIONS BY GILBERT.

In one beautiful octavo volume of over SIX HUNDRED Large Pages,

Strongly Bound and sold at a low price.

Since the publication of the second American edition of this work, the author has issued a third in London, in which he has carefully brought up his work to a level with the most advanced science of the day. All the elementary chapters have been rewritten, and such alterations made through the body of the work, by the introduction of all new facts of interest, illustrated by appropriate engravings, as much increase its value. The present edition is a careful and exact reprint of the English volume, with the addition of such other illustrations as were deemed necessary to a more complete elucidation of the text; and the insertion of such of the notes appended to the last American edition as had not been adopted by the author and embodied in his text; together with such additional information as appeared calculated to enhance the value of the work. It may also be stated that the utmost care has been taken in the revision of the letter-press, and in obtaining clear and distinct impressions of the accompanying cuts.

It will thus be seen, that every effort has been used to render this text-book worthy of a continuance of the great favor with which it has been everywhere received. Professors desirous of adopting it for their classes may rely on being always able to procure editions brought up to the day.

This book is well known for the beauty and accuracy of its mechanical execution. The present edition is an improvement over the last, both in the number and clearness of its embellishments; it is bound in the best manner in strong sheep, and is sold at a price which renders it accessible to all.

SUPPLEMENT TO THE ENCYCLOPÆDIA AMERICANA, UP TO THE YEAR 1847.

ENCYCLOPÆDIA AMERICANA---Supplementary Vol.

A POPULAR DICTIONARY
OF ARTS, SCIENCES, LITERATURE, HISTORY, POLITICS AND BIOGRAPHY.

VOL. XIV.

EDITED BY HENRY VETHAKE, LL. D.,

Vice-Provost and Professor of Mathematics in the University of Pennsylvania, Author of "A Treatise on Political Economy."

In One large Octavo Volume of over Six Hundred and Fifty double columned pages.

The numerous subscribers who have been waiting the completion of this volume can now perfect their sets, and all who want a Register of the Events of the last Fifteen Years, for the Whole World, particularly embracing interesting scientific investigations and discoveries, can obtain this volume separately, price Two Dollars uncut in cloth, or Two Dollars and Fifty Cents in leather, to match the styles in which the publishers have been selling sets.

Subscribers in the large cities can be supplied on application at any of the principal bookstores; and persons residing in the country can have their sets matched by sending a volume in charge of friends visiting the city.

Complete sets furnished at very low prices in various bindings.

"The Conversations Lexikon (Encyclopædia Americana) has become a household book in all th intelligent families in America, and is undoubtedly the best depository of biographical, historical, geographical and political information of that kind which discriminating readers require. There is in the present volume much matter purely scientific, which was all the more acceptable to us that it was unexpected."—*Silliman's Journal.*

THE CHEMISTRY OF THE FOUR SEASONS---A NEW WORK.

THE CHEMISTRY OF THE FOUR SEASONS,

SPRING, SUMMER, AUTUMN AND WINTER.

AN ESSAY PRINCIPALLY CONCERNING NATURAL PHENOMENA ADMITTING OF ILLUSTRATION BY CHEMICAL SCIENCE, AND ILLUSTRATING PASSAGES OF SCRIPTURE.

BY THOMAS GRIFFITHS,

Professor of Chemistry in the Medical College of St. Bartholomew's Hospital, &c.

In One very neat Volume, royal 12mo., of Four Hundred and Fifty large pages, extra cloth, illustrated with numerous Woodcuts.

"The title-page copied at the head of this article sufficiently expresses the objects of the work, and the subjects of which it treats. It is a token from the laboratory, designed for the parlor. The discourses are adapted to the comprehension of those not familiar with the technicalities and details of chemistry, and are written in a pleasing style. The mechanical execution of the work is neat and tasteful. Altogether it is a beautiful volume."—*Buffalo Med. Journal.*

YOUATT ON THE DOG.

THE DOG.

BY WILLIAM YOUATT.

WITH NUMEROUS AND BEAUTIFUL ILLUSTRATIONS.

EDITED BY E. J. LEWIS, M.D., &c. &c.

In One beautifully printed Volume, Crown Octavo, with Twenty-four Plates, done up in rich crimson extra cloth.

"With this explanation of his connection with the work he leaves it, in the hope that it may prove of value to the sportsman from its immediate relation to his stirring pursuits; to the general reader from the large amount of curious information collected in its pages; and to the medical student from the light it sheds on the pathology and diseases of the dog, by which he will be surprised to learn how many ills that animal shares in common with the human race."—EDITOR'S PREFACE.

Valuable Works for Sportsmen, &c.

THE HORSE,

BY WILLIAM YOUATT.

A NEW EDITION, WITH NUMEROUS ILLUSTRATIONS. TOGETHER WITH A

GENERAL HISTORY OF THE HORSE:

A DISSERTATION ON THE AMERICAN TROTTING HORSE

HOW TRAINED AND JOCKEYED. AN ACCOUNT OF HIS REMARKABLE PERFORMANCES;

AND AN ESSAY ON THE ASS AND THE MULE,

BY J. S. SKINNER,

ASSISTANT POST-MASTER GENERAL, AND EDITOR OF THE TURF REGISTER.

This edition of Youatt's well-known and standard work on the Management, Diseases and Treatment of the Horse, has already obtained such a wide circulation throughout the country; that the Publishers need say nothing to attract to it the attention and confidence of all who keep Horses or are interested in their improvement.

STABLE TALK AND TABLE TALK,

OR SPECTACLES FOR YOUNG SPORTSMEN.

BY HARRY HIEOVER.

In one very neat duodecimo volume, extra cloth.

THE SPORTSMAN'S LIBRARY,

OR HINTS ON HUNTERS, HUNTING, HOUNDS, SHOOTING, GAME, DOGS, GUNS, FISHING, COURSING, &c., &c.

In one well printed volume, duodecimo, extra cloth.

EVERY MAN HIS OWN FARRIER;

CONTAINING THE CAUSES, SYMPTOMS AND MOST APPROVED METHODS OF CURE OF THE DISEASES OF HORSES.

BY FRANCIS CLATER,

AUTHOR OF "EVERY MAN HIS OWN CATTLE DOCTOR."

AND HIS SON JOHN CLATER.

First American from the twenty-eighth London edition, with notes and additions, by J. S. SKINNER. In one 12mo. volume, cloth.

EVERY MAN HIS OWN CATTLE DOCTOR.

CONTAINING THE CAUSES, SYMPTOMS AND TREATMENT OF ALL DISEASES INCIDENT TO OXEN, SHEEP AND SWINE; AND A SKETCH OF THE ANATOMY AND PHYSIOLOGY OF NEAT CATTLE.—BY FRANCIS CLATER.

Edited, Revised, and almost Rewritten, by WILLIAM YOUATT. With numerous Additions, embracing an Essay on the Use of Oxen, and the Improvement in the Breed of Sheep, by J. S. SKINNER, Asst. P. M General. In one duodecimo volume, cloth, with numerous illustrations.

Kirby and Spence's Entomology, for Popular Use.

AN INTRODUCTION TO ENTOMOLOGY;

OR, ELEMENTS OF THE NATURAL HISTORY OF INSECTS; COMPRISING AN ACCOUNT OF NOXIOUS AND USEFUL INSECTS, OF THEIR METAMORPHOSES, FOOD, STRATAGEMS, HABITATIONS, SOCIETIES, MOTIONS, NOISES, HYBERNATION, INSTINCT, &c., &c.

With Plates, Plain or Colored.

BY WILLIAM KIRBY, M. A., F. R. S. AND WILLIAM SPENCE, Esq., F. R. S.

From the sixth London edition, which was corrected and considerably enlarged. In one large octavo volume, extra cloth.

We have been greatly interested in running over the pages of this treatise. There is scarcely, in the wide range of natural science, a more interesting or instructive study than that of insects, or one that is calculated to excite more curiosity or wonder.

The popular form of letters is adopted by the authors in imparting a knowledge of the subject, which renders the work peculiarly fitted for our district school libraries, which are open to all ages and classes.—*Hunt's Merchants' Magazine.*

CAMPBELL'S LORD CHANCELLORS.

JUST PUBLISHED.

LIVES OF THE LORD CHANCELLORS AND KEEPERS OF THE GREAT SEAL OF ENGLAND,

FROM THE EARLIEST TIMES TO THE REIGN OF KING GEORGE IV.,

BY JOHN LORD CAMPBELL, A. M., F. R. S. E.

First Series, forming three neat volumes in demy octavo, extra cloth.

Bringing the work to the time of Lord Jeffries.

The second series will shortly follow in three volumes to match.

It is sufficient for us to thank Lord Campbell for the honest industry with which he has thus far prosecuted his large task, the general candor and liberality with which he has analyzed the lives and characters of a long succession of influential magistrates and ministers, and the manly style of his narrative. We need hardly say that we shall expect with great interest the continuation of this performance. But the present series of itself is more than sufficient to give Lord Campbell a high station among the English authors of his age. —*Quarterly Rev.*

The volumes teem with exciting incidents, abound in portraits, sketches and anecdotes, and are at once interesting and instructive. The work is not only historical and biographical, but it is anecdotal and philosophical. Many of the chapters embody thrilling incidents, while as a whole, the publication may be regarded as of a high intellectual order.—*Inquirer.*

A work in three handsome octavo volumes, which we shall regard as both an ornament and an honor to our library. A History of the Lord Chancellors of England from the institution of the office, is necessarily a History of the Constitution, the Court, and the Jurisprudence of the Kingdom, and these volumes teem with a world of collateral matter of the liveliest character for the general reader, as well as with much of the deepest interest for the professional or philosophical mind.—*Saturday Courier.*

A work of enduring interest, as well from the signal ability with which it is written, as from the great names whose personal history and official acts it enumerates.—*Richmond Whig.*

HAWKER ON SHOOTING.

INSTRUCTIONS TO YOUNG SPORTSMEN IN ALL THAT RELATES TO GUNS AND SHOOTING.

BY LIEUT. COL. P. HAWKER.

From the enlarged and improved ninth London edition.

To which is added the Hunting and Shooting of North America, with Descriptions of Animals and Birds. Carefully collated from authentic sources.

BY W. T. PORTER, Esq., Editor of the N. Y. Spirit of the Times.

In one large octavo volume, rich extra cloth, with numerous Illustrations.

"Here is a *book*, a hand-book, or rather a text-book—one that contains the whole routine of the science. It is the Primer, the Lexicon, and the Homer. Every thing is here, from the minutest portion of a gun-lock, to a dead Buffalo. The sportsman who reads this book understandingly, may pass an examination. He will know the science, and may give advice to others. Every sportsman, and sportsmen are plentiful, should own this work. It should be a "vade mecum." He should be examined on its contents, and estimated by his abilities to answer. We have not been without treatises on the art, but hitherto they have not descended into all the minutiæ of equipments and qualifications to proceed to the completion. This work supplies deficiencies, and completes the sportsman's library."—*U. S. Gazette.*

PHILOSOPHY IN SPORT MADE SCIENCE IN EARNEST.

BEING AN ATTEMPT TO ILLUSTRATE THE FIRST PRINCIPLES OF NATURAL PHILOSOPHY, BY THE AID OF THE POPULAR TOYS AND SPORTS OF YOUTH.

From the Sixth and greatly improved London Edition.

In one very neat royal 18mo. volume of 432 large pages with numerous wood-cuts, crimson extra cloth.

"One of the most entertaining, and to a large class of persons, most instructive volumes that we have lately met with. We think we can do a service to our juvenile readers by recommending it to their study, though it may be read profitably by many of either sex who wear beards or bishops."—*Richmond Times.*

"It shows the young reader why his present toys enact such wonderful pranks, and how new ones may be constructed even more remarkable; and contains matter enough within its cover to amuse a household profitably for a twelvemonth."—*Neal's Saturday Gazette.*

PUBLISHED BY LEA & BLANCHARD.

Brought up to 1847.

ENCYCLOPÆDIA AMERICANA.

THE ENCYCLOPÆDIA AMERICANA:

A POPULAR DICTIONARY

OF ARTS, SCIENCES, LITERATURE, HISTORY, POLITICS & BIOGRAPHY.

In Fourteen Large Octavo Volumes of over Six Hundred double columned pages each.

For Sale very low, in various styles of Binding.

"The publishers of the Encyclopædia Americana conferred an obligation on the public when, fourteen years ago, they issued the thirteen volumes from their press. They contained a wonderful amount of information, upon almost every subject which would be likely to occupy public attention, or be the theme of conversation in the private circle. Whatever one would wish to inquire about, it seemed only necessary to dip into the Encyclopædia Americana, and there the outline, at least, would be found, and reference made to those works which treat at large upon the subject. It was not strange, therefore, that the work was popular. But in fourteen years, great events occur. The last fourteen years have been full of them, and great discoveries have been made in sciences and the arts; and great men have, by death, commended their names and deeds to the fidelity of the biographer, so that the Encyclopædia that approached perfection in 1832, might fall considerably behind in 1846. To bring up the work, and keep it at the present point, has been a task assumed by Professor Vethake, of the Pennsylvania University, a gentleman entirely competent to such an undertaking; and with a disposition to do a good work, he has supplied a supplementary volume to the main work corresponding in size and arrangements therewith, and becoming, indeed, a fourteenth volume. The author has been exceedingly industrious, and very fortunate in discovering and selecting materials, using all that Germany has presented, and resorting to every species of information of events connected with the plan of the work, since the publication of the thirteen volumes. He has continued articles that were commenced in that work, and added new articles upon science, biography, history and geography, so as to make the present volume a necessary appendage in completing facts, to the other. The publishers deserve the thanks of the readers of the volume, for the handsome type, and clear white paper, they have used in the publication."—*U. S. Gazette.*

THE SUPPLEMENTARY VOLUME,

(VOL XIV.)

Bringing the work up to 1847.

EDITED BY HENRY VETHAKE, LL.D.,

Vice Provost and Professor of Mathematics in the University of Pennsylvania, &c.; Author of a Treatise on Political Economy, &c.

May be had separate and in any style of binding.

"This volume is worth owning, by itself a most convenient and reliable compend of recent History, Biography, Statistics, &c. &c. The entire work forms the cheapest and probably now the most desirable Encyclopædia published for popular use."—*N. Y. Tribune.*

MURRAY'S ENCYCLOPÆDIA OF GEOGRAPHY.

THE ENCYCLOPÆDIA OF GEOGRAPHY,

COMPRISING

A COMPLETE DESCRIPTION OF THE EARTH, PHYSICAL, STATISTICAL, CIVIL AND POLITICAL.

EXHIBITING

ITS RELATION TO THE HEAVENLY BODIES, ITS PHYSICAL STRUCTURE, THE NATURAL HISTORY OF EACH COUNTRY, AND THE INDUSTRY, COMMERCE, POLITICAL INSTITUTIONS, AND CIVIL AND SOCIAL STATE OF ALL NATIONS.

BY HUGH MURRAY, F. R. S. E., &c.

Assisted in Botany, by Professor HOOKER—Zoology, &c., by W. W. SWAINSON—Astronomy, &c., by Professor WALLACE—Geology &c., by Professor JAMESON.

REVISED, WITH ADDITIONS,

BY THOMAS G. BRADFORD.

THE WHOLE BROUGHT UP, BY A SUPPLEMENT, TO 1843.

In three large octavo volumes.

VARIOUS STYLES OF BINDING.

This great work, furnished at a remarkably cheap rate, contains about

NINETEEN HUNDRED LARGE IMPERIAL PAGES,

AND IS ILLUSTRATED BY

EIGHTY-TWO SMALL MAPS,

And a colored Map of the United States after Tanner's,

Together with about Eleven Hundred Wood Cuts executed in the best Style.

MISCELLANEOUS WORKS

PUBLISHED BY

LEA AND BLANCHARD.

ACTON'S MODERN COOKERY, 420 large pages, with many cuts, 12mo., neat extra cloth.

AMERICAN ORNITHOLOGY, by Prince Charles Bonaparte, in 4 vols. folio, half bound, many colored plates.

AMERICAN MILITARY LAW, by Lieut. O'Brien, U. S. A., 1 vol. 8vo., cloth or law sheep.

ADDISON ON CONTRACTS, at press.

ARNOTT'S ELEMENTS OF PHYSICS, new edition, 1 vol. 8vo., sheep, many cuts.

BOZ'S COMPLETE WORKS, 8 parts, paper, cheapest edition, containing Pickwick, 50 cents; Sketches, 37½ cents; Oliver Twist, 25 cents; Nickleby, 50 cents; Curiosity Shop, 50 cents; Barnaby Rudge, 50 cts.; Martin Chuzzlewit, 50 cts.; and Christmas Stories and Pictures from Italy, 25 cts.—Any work sold separately.

BOZ'S WORKS, in 3 large vols., extra cloth, good paper, price $3.75.—N. B. A fourth vol. is preparing, to contain Dombey & Son, Christmas Stories, and Pictures from Italy.

BOZ'S WORKS, in 8 vols., imperial 8vo., extra cloth, with 136 plates and 140 cuts.

BENTHAMIANA: Extracts from Bentham, in one large vol., 12mo.

BROWNE'S RELIGIO MEDICI, and CHRISTIAN MORALS, 1 vol., 12mo., extra cloth.

BOLMAR'S FRENCH SERIES, consisting of—A Selection of One Hundred Perrin's Fables, with a Key to the Pronunciation; a Series of Colloquial Phrases; The First Eight Books of Fenelon's Telemachus; Key to the same; a Treatise on all the French Verbs, Regular and Irregular. The whole forming five small volumes, half bound to match.

BUTLER'S ATLAS OF ANCIENT GEOGRAPHY, with an Accentuated Index, 8vo., half bound, 27 colored maps.

BUTLER'S GEOGRAPHIA CLASSICA, 1 vol., 8vo.

BRIGHAM ON MENTAL EXCITEMENT AND CULTIVATION, &c., 12mo., cloth.

BIRD'S NATURAL PHILOSOPHY, 1 vol., 12mo., many cuts, [at press.]

BRIDGEWATER TREATISES.—The whole complete in 7 vols., 8vo., various bindings.

BROUGHAM'S HISTORICAL SKETCHES OF STATESMEN, 3d Series, 1 vol., 12mo., cloth.

BARNABY RUDGE, by "Boz," paper or cloth.

BROWNING'S HISTORY OF THE HUGUENOTS, one vol., 8vo., cloth.

BREWSTER'S TREATISE ON OPTICS, 1 vol., 12mo., cuts.

BUCKLAND'S GEOLOGY, 2 vols., 8vo., cloth, many plates.

COMPLETE COOK, paper, price only 25 cents.

COMPLETE CONFECTIONER, paper, price 25 cents.

COMPLETE FLORIST, paper, 25 cents.

COMPLETE GARDENER, do. do.

CAMPBELL'S (LORD) LIVES OF THE LORD CHANCELLORS OF ENGLAND, in 3 vols. neat demy 8vo. Second and concluding series, 3 vols. 8vo. at press.

CURIOSITY SHOP, by "Boz," paper or cloth.

CHRISTMAS STORIES, containing the Chimes, the Carol, the Cricket on the Hearth, and The Battle of Life; together with Pictures from Italy. By "Boz." Neat 8vo., price 37½ cts.

CAMPBELL'S COMPLETE POETICAL WORKS, in one vol., crown 8vo., cloth gilt or white calf, plates.

COOPER'S NAVAL HISTORY OF THE UNITED STATES.

COOPER'S NOVELS AND TALES, in 23 vols., sheep gilt, 12mo., or 47 vols., paper, price 25 cents per vol.

COOPER'S SEA TALES, 6 large vols., royal 12mo., extra cloth.

COOPER'S LEATHER STOCKING TALES, 5 large royal 12mo. vols., extra cloth.

CLATER'S HORSE DOCTOR, 1 vol., 12mo. cloth.

CLATER'S CATTLE and SHEEP DOCTOR, one vol., 12mo., cuts.

CARPENTER'S POPULAR VEGETABLE PHYSIOLOGY, 1 vol., 12mo., extra cloth, many cuts.

CARPENTER'S COMPARATIVE PHYSIOLOGY, one vol., large 8vo., many plates, [preparing.]

CARPENTER'S ELEMENTS OF PHYSIOLOGY, one vol., 8vo., with many cuts.

DANA ON CORALS, &c., 1 vol. imp. quarto, with an Atlas of colored plates, being vols. 8 and 9 of the U. S. Exploring Expedition, [preparing].

DAVIDSON, MARGARET, MEMOIRS OF AND POEMS, in 1 vol., 12mo., paper 50 cents, or extra cloth.

DAVIDSON, LUCRETIA, POETICAL REMAINS, 1 vol., 12mo., paper 50 cents, or extra cloth.

DAVIDSON, MRS., POETRY AND LIFE, in 1 vol., 12mo., paper 50 cents, or extra cloth.

DOMBEY & SON, by Dickens, to be complete in 20 Nos., with 2 plates each; price 8 cts. each.

DOG AND SPORTSMAN, by Skinner, plates, 1 vol., 12mo., cloth.

DUNGLISON ON HUMAN HEALTH, 1 vol., 8vo., cloth or sheep.

ENCYCLOPÆDIA OF GEOGRAPHY, in 3 vols., 8vo., many cuts, various bindings.

ENCYCLOPÆDIA AMERICANA, 14 vols. 8vo., various bindings. The supplementary volume (14th), by Professor Henry Vethake, is just published. To be had separate, price $2.00 uncut in cloth, or $2.50 bound.

EAST'S REPORTS, edited by G. M. Wharton, in 8 vols., large 8vo., law sheep.

EDUCATION OF MOTHERS, 1 vol., 12mo., cloth or paper.

ELECTRO-MAGNETIC TELEGRAPH, by Vail, 8vo., sewed, many cuts.

FREDERIC THE GREAT, by Campbell, 2 vols., 12mo., extra cloth.

FIELDING'S SELECT WORKS, in 1 vol. large 8vo., cloth, or in 4 parts paper, price $1.25.

FRANCATELLI'S MODERN FRENCH COOK, in 1 vol., 8vo., fancy cloth, with many cuts.

FOWNES' ELEMENTARY WORK ON CHEMISTRY, 1 vol., 12mo., many cuts, cloth or sheep.

GRAHAME'S COLONIAL HISTORY OF THE UNITED STATES, 2 vols., 8vo., a new edition.

GROTE'S HISTORY OF GREECE, 8vo., cloth, [preparing.]

GIESLER'S ECCLESIASTICAL HISTORY, 3 vols. 8vo.

GRIFFITH'S CHEMISTRY OF THE FOUR SEASONS, 1 vol., 12mo., extra cloth, cuts.

HAWKER ON SHOOTING, Edited by Porter, one beautiful 8vo. vol., rich extra cloth, plates.

HALE'S ETHNOGRAPHY AND PHILOLOGY, imperial 4to., being 7th vol. of the U. S. Exploring Expedition.

HERSCHELL'S TREATISE ON ASTRONOMY, 1 vol., 12mo., cuts.

HEMANS' COMPLETE POETICAL WORKS, in 7 vols., 12mo.

HEMANS' MEMOIRS, by her Sister, 1 vol., 12mo., cloth.

HILLIARD ON THE AMERICAN LAW OF REAL ESTATE, 2 large vols., 8vo., law sheep.

HILL ON TRUSTEES, Edited by Troubat, 1 large vol., 8vo., law sheep.

HOLTHOUSE'S LAW DICTIONARY, with large additions, 1 vol., royal 12mo.

INGERSOLL'S HISTORY OF THE LATE WAR, 1 vol., 8vo.

IRVING'S COLUMBUS, in 2 vols., 8vo.

IRVING'S BEAUTIES, in 1 vol., 18mo.

IRVING'S ROCKY MOUNTAINS, 2 vols., 12mo., cloth.

JOHNSON'S GARDENER'S DICTIONARY, edited by Landreth, 1 vol., 12mo., with cuts, [at press.]

KEBLE'S CHRISTIAN YEAR, in 32mo., extra cloth, with illuminated title.

KIRBY ON ANIMALS, 1 vol., 8vo., plates.

KIRBY AND SPENCE'S ENTOMOLOGY, 1 large 8vo. vol., with plates, plain or colored.

LIFE OF THOMAS JEFFERSON, by Judge Tucker, 2 vols., 8vo.

LANGUAGE OF FLOWERS, 1 vol., 18mo., colored plates, extra crimson cloth, gilt.

LOVES OF THE POETS, by Mrs. Jamieson, 12mo.

LANDRETH'S RURAL REGISTER, for 1847, royal 12mo.; price only 15 cts., about 100 cuts.

LOVER'S RORY O'MORE, royal 12mo., with cuts, paper, price 50 cts., or extra green cloth.

LOVER'S LEGENDS AND STORIES OF IRELAND, royal 12mo., with cuts, paper, price 50 cts., or in extra green cloth.

LOVER'S SONGS AND BALLADS, royal 12mo., paper, price 25 cts.

MARSTON; or the SOLDIER and STATESMAN, by CROLY, 8vo., sewed, 50 cts.

MACKINTOSH'S ETHICAL PHILOSOPHY, 1 vol., 8vo.

MEDICAL BOTANY, by R. E. Griffith, M. D., with 400 illustrations (at press).

MOORE'S HISTORY OF IRELAND, complete in 2 vols., 8vo., cloth.

MARTIN CHUZZLEWIT, by "BOZ," cloth or paper.

MILLWRIGHT'S AND MILLER'S GUIDE, by Oliver Evans, 1 vol. 8vo., many plates, new ed.

MILLS' HISTORY OF THE CRUSADES AND CHIVALRY, 1 vol., 8vo., extra cloth.

MILLS' SPORTSMAN'S LIBRARY, 1 vol., 12mo., extra cloth.

NARRATIVE OF THE UNITED STATES EXPLORING EXPEDITION, by Captain Charles Wilkes, U. S. N. In 6 vols., 4to., $60; or 6 vols. imp. 8vo., $25; or 5 vols. 8vo., $10.

NIEBUHR'S HISTORY OF ROME, complete, 2 vols. 8vo., extra cloth.

NICHOLAS NICKLEBY, by "BOZ," cloth or paper.

OLIVER TWIST, by "BOZ," cloth or paper.

PICCIOLA,—THE PRISONER OF FENESTRELLA, 12mo., illustrated edition, [preparing.]

PICKWICK CLUB, by "BOZ," cloth or paper.

PHILOSOPHY IN SPORT MADE SCIENCE IN EARNEST, 1 vol. royal 16mo., with many cuts,

RUSH'S RESIDENCE AT THE COURT OF LONDON, new series, 1 neat vol., 8vo., cloth.

RANKE'S HISTORY OF THE POPES OF ROME, 1 vol., 8vo., cloth.

RANKE'S HISTORY OF THE REFORMATION IN GERMANY, to be complete in one vol., 8vo.

RANKE'S HISTORY OF THE OTTOMAN AND SPANISH EMPIRES.

ROGERS' POEMS, a splendid edition, illustrated, imperial 8vo., extra cloth.

ROGET'S OUTLINES OF PHYSIOLOGY, one vol., 8vo.

ROGET'S ANIMAL AND VEGETABLE PHYSIOLOGY, 2 vols., 8vo., cloth, with about 400 woodcuts.

ROSCOE'S LIVES OF THE KINGS OF ENGLAND, a 12mo. series to match the Queens. Vol. 1 now ready.

STRICKLAND'S LIVES OF THE QUEENS OF ENGLAND, 9 vols., 12mo., cloth or paper, [to be continued.]

SELECT WORKS OF TOBIAS SMOLLETT, 1 vol., large 8vo., cloth, or 5 parts, paper, $1.50.

SIBORNE'S WATERLOO CAMPAIGN, with Maps 1 vol., large 8vo.

STABLE TALK AND TABLE TALK, FOR SPORTSMEN, 1 vol., 12mo.

Small Books on Great Subjects—No. 1, "PHILOSOPHICAL THEORIES AND PHILOSOPHICAL EXPERIENCE." No. 2, "ON THE CONNECTION BETWEEN PHYSIOLOGY AND INTELLECTUAL SCIENCE." No. 3, "ON MAN'S POWER OVER HIMSELF TO PREVENT OR CONTROL INSANITY." No. 4, "AN INTRODUCTION TO PRACTICAL ORGANIC CHEMISTRY." No. 5, "A BRIEF VIEW OF GREEK PHILOSOPHY UP TO THE AGE OF PERICLES." No. 6, "A BRIEF VIEW OF GREEK PHILOSOPHY FROM THE AGE OF SOCRATES TO THE COMING OF CHRIST." No. 7, "CHRISTIAN DOCTRINE AND PRACTICE IN THE SECOND CENTURY." No. 8, "AN EXPOSITION OF VULGAR AND COMMON ERRORS, ADAPTED TO THE YEAR OF GRACE 1845." No. 9, "AN INTRODUCTION TO VEGETABLE PHYSIOLOGY, WITH REFERENCES TO THE WORKS OF DE CANDOLLE, LINDLEY, &c." No. 10, "ON THE PRINCIPLES OF CRIMINAL LAW." No. 11, "CHRISTIAN SECTS IN THE NINETEENTH CENTURY," &c.—each work sold separate for 25 cents, or handsomely done up in volumes, in cloth, forming a neat series. (To be continued.)

SPENCE ON THE JURISDICTION OF THE COURT OF CHANCERY, 1 vol., large 8vo., law sheep. Vol. 2, on the PRACTICE, preparing.

THOMSON'S DOMESTIC MANAGEMENT OF THE SICK ROOM, 1 vol., 12mo., extra cloth.

TOKEAH, by Sealsfield, price 25 cents.

TRIMMER'S GEOLOGY AND MINERALOGY, one volume of large 8vo., extra cloth, many cuts.

WALPOLE'S LETTERS, in 4 large vols., 8vo., extra cloth, with a portrait.

WALPOLE'S NEW LETTERS TO SIR HORACE MANN, 2 vols., 8vo., extra cloth.

WALPOLE'S MEMOIRS OF GEORGE THE THIRD, 2 vols., 8vo., extra cloth.

WALPOLE'S JOURNALS, never before published, [preparing.]

WHITE'S UNIVERSAL HISTORY, a new and improved work for schools, colleges, &c., with Questions, by Professor Hart, in 1 vol., large 12mo., extra cloth, or half bound.

WHEATON'S ELEMENTS OF INTERNATIONAL LAW, 1 vol., large 8vo., law sheep or extra cloth, third edition, much improved.

WRAXALL'S POSTHUMOUS MEMOIRS, 1 vol., 8vo., extra cloth.

WRAXALL'S HISTORICAL MEMOIRS, 1 vol., 8vo., extra cloth.

YOUATT ON THE HORSE, &c., by Skinner, 1 vol., 8vo., many cuts.

YOUATT ON THE DOG, in one beautiful volume, crown 8vo., extra cloth, with plates.

Date Issued

YMC JUN - 3 1983

RE46
847ℓ